F. 246

[c. 1839.]

F. 246

A

SYSTEM

OF

ANATOMICAL PLATES

of the

HUMAN BODY,

Accompanied with Descriptions, and

PHYSIOLOGICAL, PATHOLOGICAL, AND SURGICAL OBSERVATIONS, BY

JOHN LIZARS F.R.S.E.

FELLOW OF THE ROYAL COLLEGE OF SURGEONS, CORRESPONDING MEMBER OF THE MEDICAL SOCIETY OF EMULATION OF PARIS, AND

LECTURER ON ANATOMY AND SURGERY, EDINBURGH.

Dedicated by Permission to

THE KING.

EDINBURGH;

PUBLISHED BY W. H. LIZARS, 3, St. JAMES SQUARE; S. HIGHLEY 32, FLEET STREET LONDON,

AND W. CURRY JUNr. & Co. 9, UPPER SACKVILLE STREET DUBLIN.

[c. 1835?]

DEDICATION

(BY PERMISSION)

TO HIS LATE MAJESTY GEORGE THE FOURTH.

SIRE,

The voice of antiquity, the nature of disease, the casualties of ordinary life, and the hazards of war, all conspire, with the dictates of sound philosophy, in enforcing the claims of Anatomy and Physiology, as the basis of a successful system of Medicine and Surgery. It is natural, and an act of duty in me, therefore, to desire, that labours intended, and, I trust, calculated, to promote the interests of a practical science, in which, not only Your Majesty's Subjects, but likewise all the nations of the earth, are essentially and deeply concerned, should receive a due portion of countenance and favour from a Monarch, equally distinguished, by anxiety for the welfare of his People, and estimable, even above the dignity of his exalted station, for the judicious and effectual encouragement of every undertaking and institution, the benefits of which, like the influences of the sun, are common to the human race.

To Your Majesty alone, could admiration, sense of propriety, feelings of loyalty, and generous ambition, unite, in prompting me to look for an adequate Patron; because, from Your Majesty alone, could I hope to obtain, at once, the benevolent pardon of all unintended imperfections, the praise which ennobles success, and the sanction which extends utility.

Sire, You will graciously permit me to assign a very imperative reason for presuming to solicit the notice of Your Majesty. I am emboldened, by the highest of all obligations, to avail myself of the appearance of this Work, to suggest the necessity for speedily adopting some measures, in behalf of the science, to the advancement of which it is conscientiously devoted. It is impossible for me, or for any other teacher, in this department of professional education, not to regret, most painfully, that, through the increase of certain prejudices, as illiberal as they are alien to true philanthropy, obstacles are daily arising, in Your Majesty's United Kingdoms, to the prosecution of Anatomy. It is equally impossible not to believe, what ample observations demonstrate, that the magnitude, to which they have already attained, is, in its infallible and invincible operation, signally and seriously injurious to Your Majesty's Subjects, both in the public service, and in all the ranks of private society. Many more of these, than unsuspecting benevolence could have imagined, are doomed, it were easy to prove, to a premature grave, by the consequent deficiency in this requisite science, on the part of those to whom the care of life and health is committed: And I will state, most respectfully, to Your Majesty, in evidence of this alarming truth, well-known and universally deplored, as it is, in the Schools of Medical Learning, one circumstance, of political importance enough, independently of humane considerations, to justify the freedom which I thus assume.

In France, in Germany, and in Denmark, the prosecution of Anatomy is protected by their respective Governments; and, in them, every facility is afforded for its complete and satisfactory study. Hence, in great degree, it is, that, of late years, such of the medical youth, among Your Majesty's Subjects, as are enabled by their circumstances, proceed to these foreign Kingdoms, in search of information of the most valuable kind,—being compelled thereto by the dread of entering on the practice of their profession, while ignorant of some of its fundamental principles, and of having, through the unavoidable fault of a merely British education, to collect, by repeated failures in their treatment of the living, that knowledge which they might have early, and safely and ably, acquired, from intimacy with the dead.*

Sire, I cannot doubt, that, Your Majesty, impressed with a sense of the awful responsibility and agonizing duties of medical men, will be most graciously pleased to recommend the subject of their effective and thorough instruction, in this claimant particular, to the serious attention of Your Majesty's wise and liberal Ministers, with a view to the accomplishment of what science points out as desirable, and what the calamities of mankind decide to be necessary.

That Your Majesty may long live to witness, with delight, the beneficial results of such cogently called-for interference, and to receive, on this account, as for every other act of a patriotic, an enlightened, and a prosperous government, the heartfelt thanks and blessings of a grateful because a fortunate people, is the fervent prayer of,

SIRE,

Your Majesty's most devoted, very humble, and faithful

Subject and Servant,

JOHN LIZARS.

* Such appeals as these have fortunately led to the passing of the Anatomy Act, a short time ago.

EDINBURGH: PRINTED AT THE UNIVERSITY PRESS.

PREFACE

TO THE FIRST EDITION

OF

LIZARS' ANATOMICAL PLATES.

THE Author was induced to undertake this Work, chiefly because the expense of all the foreign works rendered them accessible only to a few individuals; while hitherto we have no complete system of Anatomical Plates, and those already published do not embrace Surgical Anatomy. To obviate the former of these evils, and to render the price as moderate as possible, this Work was originally undertaken, and in addition to the advantage of cheapness, it is hoped it will also be found a valuable book of reference. The great aim of the Author being the most scrupulous correctness, he has either drawn the different objects himself, or superintended the drawings made by W. H. Lizars; so that by the pencil of the one, and the careful superintendence of the other, he trusts the Plates will be found worthy of examination. At the same time he deems it proper to state, that he has availed himself of whatever advantages might be derived from the works of Albinus, Haller, Sue, Caldani, Cowper, Hunter, Vicq D'Azyr, Scarpa, and others.

The representations of the individual bones are given on as large a scale as the size of the Plates would possibly permit, in order to embrace all the points of reference; a method which the Author deemed preferable to making them bear a relative proportion to each other: indeed, the slightest comparison of the Plates of the skeleton with the trunk and the individual bones, will at once show the futility of making any such attempt.

The descriptive part will be found to assimilate to that of Monro *primus*, whose work on Osteology still stands unrivalled, and whose method the Author has adopted ever since he has taught the science of Anatomy. Besides the bare description of each bone,—its uses, together with the accidents and diseases to which it is liable, are carefully detailed, in order that the student may be progressively conducted from the examination of the healthy, to the consideration of the diseased structure, and that his mind may be constantly led to view each individual part as a living object, not as a dead inorganic mass. It is in this manner that the bones should be demonstrated as parts of the living system, nourished by vessels, and subject to the same changes and diseases as the other organs of the living body; otherwise, as an eminent surgeon judiciously observes, "all we have been examining is like dissecting a dead body, without having any reference to the living, or even knowing it had ever been alive."

At the end of the description of the several bones, their formation, together with a more extended detail of the various diseases to which they are liable, is also given. On this part of the subject the Author has probably dwelt too long, but as he professes to give a succinct account of the present amount of our knowledge in Anatomy, Physiology, and Pathology, and as some of his ideas are new, and he trusts not unimportant, a little minuteness of detail seemed absolutely unavoidable, and will therefore, he thinks, be the more readily forgiven.

The terms *superior*, *inferior*, and others, refer to the natural and relative position of the bones themselves, rather than to the position which the rules of perspective rendered it necessary that they should sometimes assume in the drawings, which, however, have been so adjusted, that the terms apply almost invariably to both: for, when writing the description, the Author had the respective bones before him, by which means there is scarcely a point that is not represented in the Plates. Nevertheless, although in a work of this kind, considerable minuteness was necessary, the Author is far from advising beginners to "commit to memory the numerous processes, grooves, and holes, many of which to know is of no importance, and to remember almost impossible:" the chief object of the student should be to familiarize his mind with those elevations, depressions, and foramina, which either elucidate a physiological fact, or bear some relation to Pathology or Surgery. It is only in this way that the extensive range of sciences connected with Medicine can be made subservient to any great or useful purpose, for if destitute and forsaken by natural philosophy, Medicine, says the father of science, is not much better than an empirical practice.

Such being the nature and object of this Work, the Author trusts he may be permitted respectfully to offer it to the younger part of the profession, as likely to prove in some degree useful and instructive, and to the older, as at least a convenient book of reference.

CONTENTS

OF

PLATES I., II., III., IV., V., VI., VII., VIII.

	Page
Dedication	I.
Preface	III.
Introductory Remarks	1
Bones of the Skeleton (Plate I.)	1
Bones of the Trunk (Plate II.) (divided into)	1
Vertebræ (Plate II. figs. 2, 3, 4, 5, 6)	2
Ribs (Plate II. figs. 7 and 8)	3
Sternum (Plate II. fig. 1, letter *e*)	4
Bones of the Pelvis (Plate III.) (divided into)	4
Os Sacrum (Plate III. let. *a*, and Plate VIII. fig. 1)	4
Os Coccygis (Plate III. letters *b*)	5
Ossa Innominata (Plate III. figs. 1, 2, 3, letters H, ɧ, *h*, ɧ) (divided into)	5
Os Ilium (Plate III. figures 1, 2, 3, *h*, and Plate VIII. fig. 2)	6
Os Pubis (Pl. III. figs. 1, 2, 3, ɧ, and Pl. VIII. fig. 2, ɧ)	6
Os Ischium (Plate III. figs. 1, 2, 3, H, and Plate VIII. fig. 2, H)	7
Remarks on the Pelvis	8
Bones of the Head (Plates IV., V., VI.) (divided into)	8
Bones of the Cranium (Plate V.) (divided into)	8
Os Frontis (Plate V. figs. 1 and 2)	8
Os Parietale (Plate V. figs. 3 and 4)	9
Os Occipitis (Plate V. figs. 5 and 6)	9
Os Temporis (Plate V. figs. 7 and 8)	10
Os Sphenoides (Plate V. figs. 9 and 10)	11
Os Ethmoides (Plate V. figs. 11 and 12)	12
Remarks on the Bones of the Cranium	13
Bones of the Face (Plate VI.) (divided into)	13
Os Nasi (Plate V. figs. 13 and 14)	13
Os Maxillare Superius (Plate VI. figs. 15 and 16)	13
Os Lachrymale (Plate VI. figs. 17 and 18)	14
Os Malæ (Plate VI. figs. 19 and 20)	15
Os Palati (Plate VI. figs. 21 and 22)	15
Os Spongiosum Inferius (Plate VI. fig. 23)	16
Os Vomeris (Plate VI. fig. 24)	16
Os Maxillare Inferius (Plate VI. figs. 25 and 26)	16
Description of the Teeth	17
Remarks on the Cavities of the Nostrils	16
Bones of the Upper Extremity (Plate VII.) (divided into)	17
Bones of the Shoulder, viz. (Pl. II. fig. 1, *p*, *k*; Pl. VII. figs. 1 and 2)	17
Clavicle, and (Plate II. fig. 1, *p*)	17
Scapula (Plate VII. figs. 1 and 2)	18
Os Brachii (Plate VII. figs. 3 and 4)	19
Bones of the Upper Extremity (Plate VII.) continued.	
Bones of the Fore-arm (Plate VII. Figs. 5 and 6) (divided into)	20
Ulna and Radius (Plate VII. figs. 5 and 6)	20
Bones of the Hand (Plate VII. figs. 7 and 8) (divided into)	21
Bones of the Carpus (Plate VII. figs. 7 and 8, letters *a*, *b*, *c*, *d*, *e*, *f*, *g*, *h*)	21
Bones of the Metacarpus (Plate VII. figs. 7 and 8, dig. 1, 2, 3, 4, 5)	22
Bones of the Fingers (Plate VII figs. 7 and 8, dig. 6, 7, 8, 9, 10, 11, 12, 13, 14, 15, 16, 17, 18, 19)	22
Bones of the Lower Extremity (Plate VIII.) (divided into)	23
Os Femoris (Plate VIII. figs 3 and 4)	23
Patella (Plate VIII. figs. 5 and 6)	24
Bones of the Leg (Plate VIII. figs. 7 and 8) (divided into)	25
Tibia and Fibula (Plate VIII. figs. 7 and 8)	25
Bones of the Foot (Plate VIII. fig. 9) (divided into)	25
Bones of the Tarsus (Plate VIII. fig. 9, letters *a*, *b*, *c*, *d*, *e*, *f*, *g*)	26
Bones of the Metatarsus (Plate VIII. fig. 9, digits 1, 2, 3, 4, 5)	27
Bones of the Toes (Plate VIII. fig. 9, digits 6, 7, 8, 9, 10, 11, 12, 13, 14, 15, 16, 17, 18, 19)	27
Physiological and Pathological Observations	28
Formation of Bone	28
Structure of Cartilage	28
Formation of the Cranial Bones	28
Formation of the Long Bones	28
Nature of the Medulla of Bones	28
Formation of the Teeth	29
Pathology of Fetal Bones	30
Pathology of Bones in Youth	30
Pathology of Bones in Adult Life	30
Pathology of Bones in Old Age	30
Sensibility of Bone	31
Vascularity of Bone	31
Absorbents in Bone	31
Pathology of irregularly round figured Bones, including Fracture, Inflammation, and Caries, with their treatment	31
Pathology of long Cylindrical Bones, including Fracture, Inflammation, and Necrosis, with their treatment	32
Pathology of Cranial Bones	13
Exostosis, and its treatment	33
Spina Ventosa	33
Mollities Ossium	34
Rachitis, and its treatment	34
Fragilitas Ossium	34
Anchylosis	34
INDEX	i.

CONTENTS

OF

PLATES IX., X., XI., XII., XIII., XIV., XV., XVI., XVII., XVIII.

Page

Heart (Plate IX. D) 35
Pericardium (Plate IX. C) 35
Lungs (Plates IX. and XII. G, and Plate XI. fig. 1. G) . . 35

Arteries of the Trunk.

Pulmonary Artery (Plate IX. F; X. figs. 1, 3, 4, 5, 6, F; XI. fig. 1, f) (and) 36
Aorta (Plates IX., X., XII., E; XIII., XIV., E, e) (divided into) 39
Thoracic Aorta (Plates IX., X., XII., XIII., E) (gives origin to) 39
Coronary Arteries of the Heart (Plates IX., X., r, s 36
* Arteria Innominata (Plates IX., XII., XV., Q) (see also pages 46 and 53) 39
† Common Carotid Artery (Plates IX., XII., XV., XVI., 39
XVII. P) (see also page 46) 39
‡ Subclavian Artery (Plates IX., XII., XV., XVI., XVII., H) (see also page 53) 39
Bronchial Arteries (Plate XII. dig. 3) (see also page 39) 37
Œsophageal Arteries (Plate XII. *b*, *b*) . . 39
Intercostal Arteries (Plate XII. dig. 12) . . 39
Abdominal Aorta (Plates XIII., XIV., e) (see pages 41 and 42) (gives origin to) 40
Phrenic Arteries (Plates XII., XIII., and XIV. z) 41
Cœliac Artery (Plate XIV. n) (divides into) . . 40
Gastric Artery (Plates IX., XII., XIII., XIV.) 40
Hepatic Artery (Plates IX., XII., XIII., XIV.) 40
Splenic Artery (Plates IX., XII., XIII., XIV.) 40
Superior Mesenteric Artery (Plates XII., XIII., XIV. R) 40
Renal Arteries (Plates XIII., XIV., c) . . 41
Spermatic Arteries (Plates XIII., XIV., *g*) . 42
Inferior Mesenteric Artery (Plates XIII., XIV., b) . 40
Lumbar Arteries (Plate XIV. *t*) . . . 42
divides into
Sacro-Median Artery (Plate XIV. *p*) (see also page 44) (and) 42
Common Iliac Arteries (Plates XIII., XIV., P) (divide into) 42
External Iliac Arteries (Plates IX., XIII., XIV., T) (gives origin within abdomen to) . 42
Epigastric Artery (Plates IX., XIII. let. x) 40
Circumflex Iliac Artery (Plate XIII. *c*) . 43
Internal Iliac Artery (Plates XIII., XIV., let. v) (see page 44) (gives origin to) . . . 42
Ilio-lumbar Artery (Plate XIII. y) . . 44
Sacro-lateral Arteries (Plate XIV. *a*, *a*) . 44
Gluteal Artery (Plate XIV. *c*) . . . 44
Ischiadic Artery (Plate XIV. *f*) . . 44
Obturator Artery (Plate XIV. *d*) . . 44
Uterine Artery (Plate XIV. *e*) . . 44
Hemorrhoidal Artery (Plate XIV. *g*) . 44
Internal Pudic Artery (Plate XIV. *h*) . 44
Umbilical Artery of Fetus (Pl. X., XIV. *n*) 45
* Arteria Innominata. (Plate IX. XII. XV. Q) divides into 46

(*Arteries of the Head.*)

† Common Carotid Artery (Plate IX. XII. XV. XVI. XVII. P) divides into 46
Internal Carotid Artery (Plate XV. XVI. dig. 19) and 46

Page

External Carotid Artery (Plates XV. XVI. XVII. G) (gives origin to) 46
Superior Thyroideal Artery (Pl. XV. XVI., XVII. *a*) 47
Lingual Artery (Plate XV. XVI. *b*) . . . 47
Facial Artery (Pl. XV., XVI., XVII., XVIII., *c*) 47
Occipital Artery (Plates XVI., XVII., XVIII., *d*) 47
Auricular Artery (Plates XVI., XVII., *e*) . . 48
Internal Maxillary Artery (Plates XV., XVII., *f*) 48
Ascending Pharyngeal Artery (Pl. XV., XVI., *h*) 48
Temporal Artery (Plates XV., XVI., XVII., XVIII. *g*) 48
(Vertebral Artery is a branch of) (Plate IX., R) . 54

(*Arteries of the Upper Extremity.*)

‡ Subclavian Artery (Pl. IX. XII. XV. XVI. XVII. H) (see also p. 46) (gives origin to) 53
Superior Intercostal Artery (Pl. XII. dig. 12) . 54
Internal Mammary Artery (Plates IX., XI., fig. 2, dig. 14.) 54
Vertebral Artery (Pl. IX., R.) (properly belongs to the Head) 54
Inferior Thyroideal Artery (Plates XII., XV., s) . 54
Superficial Cervical Artery (Plates XV., XVI., XVII., dig. 52) 54
Supra-Scapular Artery (Plates XV., XVI., XVII., dig 51) 54

Veins of the Head.

Temporal Vein (Plate XVIII., y) (and) . . 48
Facial Vein (Plate XVIII., z) (form) . . . 48
External Jugular Vein (Plates XV., XVI., c.) (ends in Internal Jugular or Subclavian Vein) . . . 48
Occipital Vein (Plate XVIII., dig. 90) (joins either External or Internal Jugular, or Vertebral Vein) . 49
Internal Jugular Vein (Plates XVII., XVI., XIII, IX., M.) (continuation of Lateral Sinus, and in the neck joined by) . 49
Internal Maxillary Veins 49
Pharyngeal Veins (Plate XVI.) 49
Lingual Veins 49
Laryngeal Veins (Plate XVII. T) . . . 49
External Jugular Vein (Plates XVII., XVI., D) . . 48
Vertebral Vein (Plate IX., N) (along with) . . 54
Internal Jugular Vein (Plates XVII., XVI., XV., IX., M) terminates in 49

Veins of the Upper Extremity.

Subclavian Vein (Plates IX., XV., XVI., *u*, *v*) (continuation of Axillary Vein, joined by) 55
External Jugular Vein (Plates XVII., XVI., D) . 55
Internal Jugular Vein (Plates XVII., XVI., XIV., IX., M.) . 55
Cervical Veins (Plates XVI., XVII.) . . 44 & 55
Thyroideal Veins (Plates XV., IX., o) . . . 55
Vertebral Vein (Plate IX., N) (properly belongs to the Head) 54
Internal Mammary Vein (Plate XI., fig. 2) . . 54

Veins of the Thorax.

Subclavian Vein, with that of opposite Arm, form,
Vena Cava Descendens (Plates IX., X., *h*) (joined by) . 34 & 55
Vena Azygos (Plates IX., *t*, XII., dig. 5) (formed by) 54 & 55
Lumbar Veins 39
Diaphragmatic Veins 39
Œsophageal Veins 39

Page

Intercostal Veins 39
Bronchial Veins 39
Vena Cava Descendens (Plates IX., XII., *h*) joins Vena Cava Ascendens, *i*, and forms right Auricle, d, ... 34
Coronary Vein of Heart terminates in right Auricle (Plate X., fig. 1, 2, *k*) 34
Pulmonary Veins end in left Auricle of the Heart (Plate IX., dig. 2, Plates X., XI., figs. 1, dig. 1, 2) 35

Veins of the Pelvis.

External Iliac Vein (Plates IX., XIII., XIV., U) (continuation of Crural Vein, joined by) 43
Internal Iliac Vein (Plate XIV., let. x.) (formed by) . . 43
Internal Pudic Vein 44
Hemorrhoidal Vein 44
Ischiadic Vein 44
Uterine Vein 44
Obturator Vein 44
Gluteal Vein 44
Sacro-lateral Veins 44
Ilio-lumbar Veins 44
External and Internal Iliac Veins form

Veins of Abdomen.

Common Iliac Vein (Plates XIII., XIV., o) (with Vein of opposite side forms) 43
Vena Cava Ascendens (Plates XIV., XIII., XII., X., *i*) (joined by) 43
Sacro-median Vein.
Spermatic Veins (Plate XIII.) . . . 42 & 43
Renal Veins (Plate XIII., L) . . . . 42 & 43
Diaphragmatic Veins, (sometimes) . . 42 & 43

Page

Hepatic Veins (Plates XII., XIII., d) (indirectly formed by) 41 & 43
Vena Portæ (Plate XII., N) (formed by) . . 41
Gastric Vein (Plate XII., *y*) . . 40 & 41
Splenic Vein (Plates XII., XIII., *s*) . . 40 & 41
Superior Mesenteric Vein (Plate XII., U) . . . 41
Inferior Mesenteric Vein (Plate XIII., H) . . . 41

Nerves.

Frontal Nerve (Plate XVIII.) 53
Infra-orbitary Nerve (Plate XVII., dig. 2) . . . 53
Inferior Maxillary Nerve (Plate XV., dig. 6) . . . 51
Facial Nerve (Plates XVI., XVII., dig. 44) . . . 52
Lingual Nerve (Plates XV., XVI., XVII., dig. 3) . . 51
Glosso-Pharyngeal Nerve (Plates XV., XVI., dig. 13) . . 51
Accessory Nerve (Plates XV., XVI., XVII., dig. 12) . . 51
Nervus Vagus in the Neck (Plate XV., dig. 1) . . 49
in the Thorax (Plates IX., XII., XIII., dig. 1) 37 & 39
in the Abdomen (Plate IX., dig. 1) . . 40
Great Intercostal Nerve in the Neck (Pl. XV., IX., dig. 7) . 50
in the Thorax (Pl. XII., XIII., dig. 7) 37
in the Abdomen (Plates XIII., XIV., dig. 7) 43
in the Pelvis (Plate XIV., dig. 7) . 45
Cervical Nerves (Plate XV., dig. 21, 22, 23, 24, 9) . . 50
Axillary Plexus of Nerves (Pl. XV., XVI., XVII, dig. 9) . 51
Phrenic Nerve (Plates XV., XVI., IX., dig. 8) . . 38 & 50
Intercostal Nerves (Plate XII., dig. 9) 39
Twelfth Dorsal Nerve (Plate XIV., dig. 3) 45
Lumbar Nerves (Plate XIV., dig. 6) 45
Obturator Nerve (Plate XIV., dig. 21) 45
Anterior Crural Nerve (Plate XIV., dig. 22) . . . 45
Sacro-ischiadic Nerve (Plate XIV., dig. 20) . . . 45
Internal Pudic Nerve (Plate XIV.) 45

CONTENTS

OF

PLATES XIX., XX., XXI., XXII., XXIII., XXIV., XXV., XXVI., XXVII., XXVIII.

Page

Arteries of the Upper Extremity.

Supra-scapular Artery (Plates XV., XVI., XVII., dig. 51, and Plate XX., fig. 1, dig. 51) 58
Axillary Artery (Plate XIX., fig. 1, H), (gives origin to) . 57
Thoracic Arteries (Plate XIX., fig. 1, letters a) . . 57
Subscapular Artery (Plates XIX., XX., figs. 1, c, *c*) . 57
Posterior Circumflex Artery (Plates XIX., XX., figs. 1, d) 57
Anterior Circumflex Artery (Plate XIX., fig. 1, e) . . 58
Brachial Artery, continuation of Axillary (Plate XIX., fig. 1, h), (gives origin to) 58
Profunda Superior Artery (Plates XIX., XX., figs. 1, f) . 58
Profunda Inferior Artery (Plate XIX., fig. 1, k) . . 58
Anastomoticus (Plate XIX., fig. 1, m) 59
Ulnar Artery (Plates XIX., XX., figs. 2, *h*), (gives origin to) 59
Recurrent Artery (Plate XX., fig. 2, n) 59
Interosseous Artery (Plate XX., fig. 2, p) . . . 59
Volar Arteries (Plates XIX., XX., figs. 2) . . . 59
Digital Arteries (Plates XIX., XX., figs. 2) . . . 59
Radial Artery (Plates XIX., XX, figs. 2, o) (gives origin to) 59
Recurrent Artery (Plate XX., fig. 2, i) 60
Superficialis Volæ Arteria (Plates XIX., XX., figs. 2, *x*) . 60
Magna Pollicis Arteria (Plate XXI. *d*) 60
Volar Arteries (Plate XX., fig. 2) 60

Arteries of the Lower Extremity.

Internal Iliac Artery (Pl. XIII., XIV., let. v.) (gives origin to) 42 & 44
Ilio-lumbar Artery (Plate XIII., *y*) 44
Sacro-lateral Arteries (Plate XIV., *a*, *a*) . . . 44
Gluteal Artery (Plate XIV., c, page 44) Plate XXV., *c* . 64
Ischiadic Artery (Plate XIV., *f*, page 44) Plate XXV., *f*. 64
Obturator Artery (Plate XIV., *d*, page 44) . . . 64
Uterine Artery (Plate XIV, *e*) 45
Hemorrhoidal Artery (Pl. XIV., *g*, p. 45), Pl. XXII., *r* . 64
Internal Pudic Artery (Pl. XIV., *h*, p. 45), Pl. XXII., *h* 63
External Iliac Artery (Plates IX., XIII., XIV., T, page 42), Plate XXIII., T (gives origin to) 64
Epigastric Artery (Plates IX., XIII., x, page 42) Plates XXIII., XXIV., x 65
Circumflex Iliac Artery (Plate XIII., *c*, page 42) Plates XXIII., XXIV., *c* 65
and becomes
Common Femoral Artery (Plates XXIII., XXIV., T), (gives origin to) 65
Inguinal Arteries (Plate XXIII., f) 65
and divides into
Deep Femoral Artery (Plate XXIV., c) (gives origin to) . 65
Internal Circumflex Artery (Plate XXIV., d) . . 65
External Circumflex Artery (Plate XXIV., e) . . 66
Perforating Branches (Plate XXIV.) . . . . 65 & 66
Superficial Femoral Artery (Plates XXIII., XXIV., t) (gives origin to) . . . . . 65 & 66
Muscular Branches (Plates XXIII., XXIV.) . . . 66
Cutaneous Branches (Plate XXIII.) 66
Anastomoticus (Plate XXIV., *a*) 66
and becomes
Popliteal Artery (Plate XXV., T) (gives origin to) . . 66
Muscular Branches (Plate XXV.) 66
Articular Arteries (Plate XXV.) 66
Rami Gastrocnemii (Plates XXV., XXVII., *a*, *a*) . . 66
and divides into
Anterior Tibial Artery (Plate XXVI., *t*), (gives origin to) . 66
Muscular Branches (Plate XXVI.) 67
Recurrent Branch (Plate XXVI., *d*) 67

Page

Rami Malleolares (Plate XXVI., c, c) 67
Rami Tarsei (Plate XXVI. e) 67
Rami Metatarsei (Plate XXVI., e) 67
Digital Arteries (Plate XXVI.) 67
Digito-fibular of great toe, and Digito-tibial of index toe (Plate XXVI., *f*) 67
Posterior Tibial Artery (Plate XXVIII., XXVII. t), (gives origin to) 67
Fibular Artery (Plate XXVIII. y) 68
Internal Plantar Artery (Plates XXVIII., XXVII. *c*) . 67
External Plantar Artery (Plates XXVIII., XXVII., *a*) (gives origin to) 67
Digital Branches (Plates XXVIII., XXVII.) . . 67

Veins of the Lower Extremity.

Venæ Comites of Anterior Tibial Artery (Plate XXVI.) (and) 68
Venæ Comites of Fibular Artery (Plate XXVIII.) (join) 68
Venæ Comites of Posterior Tibial Artery (Plates XXVII., XXVIII.) (and form) 68
Popliteal Vein (Plates XXVIII., XXV., U) (joined by) . 68
Articular and Muscular Veins (Plate XXV) (and) . 68
Saphena Minor Vein (Plates XXVI., XXVII., *z*) . . 68
and becomes
Superficial Femoral Vein (Pl. XXIII., XXIV., U) (joined by) 68
Venæ Comites of Profunda Artery (Plate XXIV. *c*) . 68
and becomes
Common Femoral Vein (Plates XXIII., XXIV., U) (joined by) 68
Saphena Major Vein (Plates XXVI., XXVII , XXVIII., XXIII., *b*) (and) 68
Inguinal and Inguinal Pudic Veins (Plate XXIII., *f*) (and) 68
Vein of Integuments of Penis (Plate XXIII., *e*) (and) . 68
Cutaneous Abdominal Vein (Plate XXIII. *d*) . . 68
and becomes
External Iliac Vein (Plates IX., XIII., XIV., U) (joined by) . 42
Internal Iliac Vein (Plate XIV., let. x) (formed by) . . 43
Internal Pudic Vein (Plates XXII., XXV.) . . 64
Vena Dorsalis Penis (Plate XXIV. dig. 60) . . . 64
Hemorrhoidal Vein (Plate XXII.)
Ischiadic Vein (page 44) (Plate XXV.) . . . 64
Obturator Vein (page 44) 64
Gluteal Vein (page 44) (Plate XXV.) 64
Sacro-lateral Veins 44
Ilio-lumbar Veins 44

Veins of the Upper Extremity.

Median Vein (Plate XIX. fig. 2, s) (joins Cephalic and) . 60
Basilic Vein (Pl. XIX. fig. 2, q, Pl. XXI. q) (joined by) 60
Venæ Comites of Radial Artery (Plate XIX., fig. 2) (and) 60
Venæ Comites of Ulnar Artery (Plate XIX., fig. 2) (and) 60
Venæ Comites of Interosseal Artery (and forms) . . 60
Brachial Vein (Plate XIX. fig. 1, u) (joined by) . . . 60
Muscular Veins (Plate XIX. fig. 1) 60
and becomes
Axillary Vein (Plate XIX. fig. 1, *u*) (joined by) . . . 60
Venæ Comites of Circumflex Arteries (Plates XIX. XX. fig. 1) (and) 60
Venæ Comites of Subscapular Artery (Plate XIX. fig. 1) (and) 60
Venæ Comites of Thoracic Arteries (Pl. XIX. fig. 1) (and) 60
Cephalic Vein (Plates XIX., XXI., figs. 2, r) . . 60
and becomes
Subclavian Vein; see page v. of Contents.

Page

Nerves of the Upper Extremity.

Axillary Plexus (Plates XV., XVI., XVII., dig. 9, p. 50, and Plates XIX., XX., figs. 1, dig. 1) (divides into) . . 61
Thoracic Nerves (Plate XVII., p. 50, and Plate XIX., fig. 1, dig. 7) 61
Supra-scapular Nerve (Plate XX. fig. 1, dig. 8) . . 61
Subscapular Nerve (Plates XIX., XX., figs. 1) . . 61
Cutaneous Nerve of Wrisberg (Plate XIX., fig. 1) . . 61
Internal Cutaneous Nerve (Plate XIX. figs. 1, 2, dig. 4) . 61
External Cutaneous Nerve (Plate XIX. figs. 1, 2, dig. 3) 61
Median Nerve (Plates XIX., XX., figs. 1, 2, dig. 2) (divides into) 61
Digital Twigs (Plates XIX., XX., figs. 2) . . 61
Ulnar Nerve (Plates XIX., XX., figs. 1, 2, dig. 5) (divides into) 62
Anconal Twig (Plate XX. fig. 2, dig. 15, and Plate XXI., dig. 15) 62
Digital Twigs (Plates XIX., XX., figs. 2) . . 62
Deep Twig (Plate XX., fig. 2) 62
Spiral Nerve (Pl. XIX., XX., figs. 1, 2, dig. 6) (divides into) 62
Cutaneous Twig (Plates XIX., XX., figs. 2, dig. 16) (divides into) 62
Palmar Twig (Pl. XIX., XXI., (figs. 2, dig. 36) 62
Anconal Twig (Pl. XIX, XXI., (figs. 2, dig. 46) 62
Deep Twig (Plate XX., fig. 2, dig. 26) . . . 62

Nerves of the Lower Extremity.

External Spermatic Nerve, Twig of first Lumbar Nerve, (Plate XXIII., dig. 1) 69
Spermatic Plexus (Plate XIII., p. 43, Plate XXIV.) . 69

Page

Third Lumbar Nerve (Plate XXIII. dig. 3) . . . 69
Anterior Crural Nerve (Plates XXIII., XXIV., dig. 22) (divides into) 69
Cutaneous Twigs, Muscular Twigs, and Nervus Saphenus (Plates XXIII., XXIV., XXVI.) 69
Obturator Nerve (Plates XIV., XXIV. dig. 21) . . 69
Cauda Equina (Plate XXII., dig. 6) (forming Sacral Nerves, and giving origin to) 69
Superior Gluteal Nerve (Plate XXV.) 69
Inferior Gluteal Nerve (Plate XXV.) 69
Sacro-ischiadic Nerve (Pl. XIV., XXV. dig. 20) (gives origin to) 70
Muscular Twigs 70
Posterior Cutaneous Twig (Plate XXV., dig. 1) . . 70
Inferior Posterior Twig (Plate XXV., dig. 2) . . . 70
and divides into
Posterior Tibial Nerve (Plates XXV., XXVII., XXVIII. dig. 23) (gives origin to) 70
Muscular and Cutaneous Twigs (Pl. XXV., XXVII.) . 70
and divides into
Internal Plantar Nerve (Pl. XXVII., XXVIII., dig. 25) 70
External Plantar Nerve (Pl. XXVII., XXVIII., dig. 24) 70
divides into
Digital Twigs 70
Fibular Nerve (Plate XXV. dig. 26) (divides into) . . 70
Anterior Tibial Nerve (Plates XXV., XXVI., XXVIII., dig. 28) 71
Peroneus Superficialis (Plates XXV., XXVI., XXVIII., dig. 5) 71
Nervus Communicans Tibiæ (Plates XXV., XXVII., XXVI., dig. 4) 71

CONTENTS

OF

PLATES XXIX., XXX., XXXI., XXXII., XXXIII., XXXIV., XXXV.

	Page
Muscles of the Abdomen (Plates XXIX. XXX. XXXI.)	73
External Oblique Muscle (Plates XXIX. XXX. XXXI. XXXIII. letters F, f,)	73
Internal Oblique Muscle (Plates XXX. XXXI. XXXIII. letters G, g, *g*,)	75
Transversalis Muscle (Plate XXXI. letters I, i,)	75
Rectus Abdominis Muscle (Plates XXIX. XXX. letters R, r,)	76
Pyramidalis Muscle (Plate XXIX. T,)	76
External Intercostal Muscles (Plates XXX. XXXIV. letters Z,)	76
Levator Muscles of the Ribs (Plate XXXIV. letters Z,)	77
Internal Intercostal Muscles (Plates XXX. XXXI., letters X,)	77
Sterno-Costalis Muscle (Plate XI., fig. 2, letters B,)	77
Diaphragm (Plate XXXII. letters B, b,)	77
Muscles of the Back (Plates XXXIII. XXXIV. XXXV.)	78
Trapezius Muscle (Plate XXXIII. digits 80,)	78
Latissimus Dorsi Muscle (Plate XXXIII. letters E, in lower half of back,)	79
Rhomboideus Muscle (Plates XXXIII. XXXIV. letters T, t,)	79
Serratus Posticus Inferior Muscle (Plate XXXIII. H,)	79
Levator Scapulæ Muscle (Plates XXXIII. XXXIV. digits 40, and in Plate XV. digits 40)	80
Serratus Posticus Superior Muscle (Plate XXXIV. E,)	80
Splenius Capitis et Colli Muscle (Plates XXXIII. XXXIV. letters p, *p*,)	80
Sacro-lumbalis Muscle (Plates XXXIV. XXXIII. XXXV. letters D, d,)	80
Longissimus Dorsi Muscle (Plates XXXIV. XXXIII. XXXV. letters K, k,)	81
Spinalis Dorsi Muscle (Plate XXXIV. L,)	81
Semi-spinalis Dorsi Muscle (Plates XXXV. XXXIV. M,)	81
Semi-spinalis Colli Muscle (Plate XXXV. N,)	81
Multifidus Spinæ Muscle (Plate XXXIV. Q,)	81
Quadratus Lumborum (Plate XXXIV. C, Plate XIII. C,)	82
Cervicalis Descendens Muscle (Plate XXXV. XXXIV. D,)	82
Transversalis Colli Muscle (Plates XXXV. XXXIV. H,)	82
Trachelo-Mastoideus Muscle (Plate XXXV. F,)	82
Complexus Muscle (Plate XXXV. O,)	82
Obliquus Capitis Superior Muscle (Plate XXXV. B,)	82
Obliquus Capitis Inferior Muscle (Plate XXXV. E,)	83
Rectus Capitis Posticus Major Muscle, (Plate XXXV. A,)	83
Rectus Capitis Posticus Minor Muscle (Plate XXXV. P,)	83
Rectus Capitis Lateralis Muscle (Plate XXXV. H,)	83
Interspinales Muscles (Plates XXXV. XXXIII. letters g,)	83
Intertransversalis Muscle (Plate XXXIV. letters *h*,)	83
Fasciæ and Surgical Operations	73
Fascia Superficialis	73
Gimbernat's Ligament	74
Operation for strangulated Femoral Hernia	74
Fascia Lumborum	75
Anatomy of Inguinal Hernia	76
Operation for strangulated Inguinal Hernia	76
Operation for Ascites	76
Operation for securing Abdominal Aorta, Cæsarian Section, and extirpation of Tumours in Abdomen, page 42 and	76
Ligaments,—Ligamentum Nuchæ	78
Intertransverse Ligaments	83
Internal Ligament of Neck of Rib	83
Capsular Ligament of Tubercle of Rib	83

CONTENTS

OF

PLATES XXXVI., XXXVII., XXXVIII., XXXIX., XL., XLI., XLII., XLIII., XLIV.

Page

Supplement.

Dissections of Inguinal and Crural Hernia (Plates XXXVI. and XXXVII.) 85

Upper Extremity.—Muscles of the Shoulder and Arm.

Greater Pectoral Muscle (Plates XXXVIII. and XXXIX. figs. 1 and 2, and Plate XIX., fig. 1, letters C, *c*) . . 85
Lesser Pectoral Muscle (Plates XXXVIII. and XXXIX. fig. 1, letters D, *d*) 86
Subclavius Muscle (Plate XXXVIII., letter M) . . . 86
Serratus Major Anticus Muscle (Plate XXXVIII., and Plate XXXIV., letters O) 87
Deltoid Muscle (Plates XXXVIII. and XXXIX., figs. 1 and 2, and Plates XIX. and XX., figs. 1, letters B, b) . . 87
Biceps Muscle (Plates XXXVIII., XXXIX., and XL., and in Plates XIX. and XX. figs. 1, letters L, *l*, l, λ, l) . . 88
Coraco-brachialis Muscle (Plates XXXVIII. and XXXIX., and in Plate XIX., fig. 1, letters K) 88
Brachieus Internus Muscle (Plate XXXIX., fig. 1, XL. and XLI., figs. 1 and 2, also Plate XX., fig. 1, letters M, m) . 88
Triceps Muscle (Plates XXXVIII. and XXXIX., and Plates XIX. and XX., figs. 1, letters G, g, *g*) 88
Anconeus Muscle (Plate XLII., figs. 1 and 2, letters E) . . 89
Teres Major Muscle (Plates XXXVIII. and XXXIII., and Plates XIX. and XX., figs. 1, letters F) 89
Teres Minor Muscle (Plate XX., fig. 1, digits 80) . . . 89
Infra-spinatus Muscle (Plate XX. fig. 1, Plate XXXIII., and Plate XXXIX., fig. 1, digits 81) 90
Supra-spinatus Muscle (Plate XX., fig. 1, Plate XXXIII., and Plate XXXIX., fig. 1, digits 66) 90
Subscapularis Muscle (Plates XXXVIII. and XXXIX., figs. 1 and 2, letters I, i, *i*) 90

Muscles of the Fore Arm.

Pronator Radii Teres Muscle (Plates XL. and XXXIX., fig. 1, and Plate XIX., fig. 2, letters I) 92
Pronator Quadratus Muscle (Plates XL. and XLI. figs. 1 and 2, and Plate XX., fig. 2, digits 50) 92
Supinator Radii Longus Muscle (Plates XXXIX, XL., XLI., and XLII., figs. 1, also in Plates XIX. and XX., figs. 2, letters N) 93
Supinator Radii Brevis Muscle (Plates XL. and XLI., fig. 1, and Plate XLII. fig. 2, digits 55) 93
Flexor Carpi Radialis Muscle (Plates XL. and XXXIX., fig. 1, and Plate XLI., figs. 1 and 2, also in Plate XIX., fig. 2, letters P) 93
Flexor Carpi Ulnaris Muscle (Plates XL. and XLI., fig. 1, and in Plates XIX. and XX., figs. 2, letters S) . . . 93
Extensor Carpi Ulnaris Muscle (Plate XLII., figs. 1 and 2, and Plate XXI., letters B) 94
Extensor Carpi Radialis Longior Muscle (Plate XLII. figs. 1 and 2, letters H) 94
Extensor Carpi Radialis Brevior Muscle (Plate XLII., figs. 1 and 2, letters *h*) 94
Palmaris Longus Muscle (Plate XL., and Plate XIX., fig. 2, letters Q) 94
Palmaris Brevis Muscle (Plate XL., digits 54) . . . 95
Flexor Digitorum Sublimis (Plates XL and XLI., and in Plates XIX. and XX., figs. 2, letters R, r, *r*) 95

Page

Flexor Digitorum Profundus (Plates XL. and XLI., and in Plate XX., fig. 2, letters W, w) 95
Lumbricales Muscles (Plate XL., and Plate XLI., fig. 1, let. ϖ) 96
Extensor Communis Digitorum (Plate XLII., fig. 1., and in Plate XXI., letters D, d, *d*) 96

Muscles of the Thumb.

Abductor Pollicis Manus (Plate XL., and in Plate XIX. fig. 2, letter Y) 99
Adductor Pollicis Manus (Plates XL. and XLI., fig. 1, also in Plate XX., fig. 2, letter *w*) 99
Flexor Ossis Metacarpi Pollicis (Plates XL. and XLI., fig. 1, also in Plate XX , fig. 2, digits 52) 99
Flexor Brevis Pollicis (Plates XL. and XLI., fig. 1, also in Plates XIX. and XX. figs. 2, letters Z, *z*) 100
Flexor Longus Pollicis (Plates XL. and XLI., fig. 1, also in Plate XX., fig. 2, letters X) 100
Extensor Ossis Metacarpi Pollicis (Plate XLII. figs. 1 and 2, also in Plate XXI. letters *a*) 100
Extensor Primi Internodii Pollicis (Plate XLII., figs. 1 and 2, also in Plate XXI., letters *b*) 100
Extensor Secundi Internodii Pollicis (Plate XLII., figs. 1 and 2, also in Plate XXI., letters *c*) 101

Muscles of the Fore-Finger.

Indicator Muscle (Plate XLII., fig. 2, letters *f*) . . . 101
Abductor Indicis Muscle (Plates XLII. and XLI., fig. 1., and in Plate XL., digits 70) 101

Muscles of the Little Finger.

Flexor Parvus Digiti Minimi (Plates XL. and XLI., fig. 1, and in Plate XX., fig. 2, digits 52, near 55) . . . 102
Abductor Digiti Minimi (Plates XL. and XLI., fig. 1, and in Plate XX., fig. 2, digits 51) 102
Adductor Digiti Minimi (Plates XL. and XLI., fig. 1, dig. 55) 102

Small Muscles of the Fingers.

Interossei Externi Muscles (Plate XLII. figs. 1 and 2, letters *m*, *n*, *o*) 102
Prior Medii Muscle (Plate XLII., figs. 1 and 2, letter *m*) . 102
Posterior Medii Muscle (Plate XLII., figs. 1 and 2, letter *n*) 102
Posterior Annularis (Plate XLII., figs. 1 and 2, letter *o*) . 102
Interossei Interni Muscles (Plate XLI., fig. 2, letters *p*, *q*, *s*, *t*) 102
Prior Indicis Muscle (Plate XLI., fig. 2, letter *p*) . . 103
Posterior Indicis Muscle (Plate XLI., fig. 2, letter *q*) . . 103
Prior Annularis Muscle (Plate XLI., fig. 2, letter *s*) . . 103
Interosseous Auricularis (Plate XLI., fig. 2, letter *t*) . . 103

Lower Extremity.—Muscles of the Thigh.

Tensor Vaginæ Femoris (Plates XXIII., XXIV., XLIII., and XLVI., letters K) 104
Sartorius Muscle (Plates XXIII., XXIV, XXV., XXVIII., XLIII., XLIV., and L. fig. 1, letters E) 105
Gracilis Muscle (Plates XXIV., XXV., XXVIII., XLIII., XLIV., and L., letters Q) 105
Triceps Muscle (Plates XXIV. XXV., LXIII., XLIV., and XLVI., letters G, g, *g*) 105
Adductor Longus (Plates XXIV., XXV., XLIII., XLIV., and XLVI., letter g) 105

Page

Adductor Brevis (Plates XXIV., XXV., XLIII., XLIV., and LXVI., letter g) 105
Adductor Magnus (Plates XXIV., XXV., XLIII., XLIV., and XLVI., letter G) 106
Pectinalis Muscle (Plates XXIV., XLIII., and XLIV., letter P, near G) 106
Psoas Parvus Muscle (Plate XIII., letter M) 106
Psoas Magnus Muscle (Plates XIII., XIV., XXXII., and XLIII., letters K) 106
Iliacus Internus Muscle (Plates XLIII., XLIV., and XXIV., and Plates XIII. and XIV., letters W) 107
Rectus Femoris Muscle (Plate XXIV., and Plates XLIII. and XLIV, letters I, near P and L) 107
Vastus Internus Muscle (Plate XXIV., and Plate XLIII. and XLIV., letter L) 107
Vastus Externus Muscle (Plate XXIV., letter o) . . . 107
Crureus Muscle (Plate XXIV., and Plates XLIII. and XLIV., letter P, between L and o) 108

Ligaments of the Trunk.

Ligaments of the Sternum (Plate XXXVIII. letter *e*) . . 86
Capsular Ligament of Sternal Articulation of Cartilage of Rib (Plate XXXVIII., digit 3) 87

Ligaments of the Upper Extremity.

Capsular Ligament of Sternal Extremity of Clavicle (Plates XXXVIII. and XXXIX., fig. 3, digit 1) . . . 87
Interarticular Cartilage of Sternal Articulation of Clavicle (Plate XXXVIII., digit 2) 87
Interclavicular Ligament (Plate XXXIX., fig. 3, digit 7) . 87
Rhomboid Ligament (Plate XXXIX., fig. 3, digit 10) . . 87
Ligamentous Expanse between Clavicle and Scapula (Plate XXXVIII., digit 4) 87
Conoid and Trapezoid Ligaments (Plate XXXIX., figs. 1 and 2, digit 8) 91
Capsular Ligament of Scapular Extremity of Clavicle, Plate XXXIX., fig. 1, digit 9) 91
Proper Anterior Ligament of Scapula (Plate XXXIX., figs. 1 and 2, digit 6) 91
Proper Posterior Ligament of Scapula (Plate XXXIX., fig. 2, and in Plate XX., fig. 1, letter *a*) 92
Capsular Ligament of the Shoulder-Joint (Plate XXXVIII., and Plate XXXIX., fig. 2, letter *r*) 91
Radial Intermuscular Ligament (Pl. XLII., figs. 1 and 2, dig. 25) 96
Ulnar Intermuscular Ligament (Plate XLI., fig. 2, digit 28) . 96
Ligaments of the Elbow-Joint 96
Radial Lateral Ligament (Plate XLI., fig. 2, digits 45) . . 96
Ulnar Lateral Ligament (Plate XLI., fig. 2., digits 40) . . 96
Capsular Ligament of Elbow-Joint (Plate XLI., figs. 2 and 3, and Plate XLII., fig. 2, digits 35) 97
Oblique Ligament (Plate XLI., fig. 2, digits 60) . . . 97
Interosseous Ligament (Plate XLI., fig. 2, digits 61) . . 98
Annular Ligament (Plate XL., Plate XLI., fig. 1, Plate XLII., figs. 1 and 2; also in Plate XX., fig. 2, and Plate XXI., letters U) 98
Sacciform Ligament (Plate XLI., figs. 2 and 4, digits 62) . 98

Page

Ligaments of the Wrist-Joint 98
Ulnar Lateral Ligament (Plate XLI., figs. 2 and 4, digits 64) . 98
Radial Lateral Ligament (Plate XLI., figs. 2 and 4, digits 65) 98
Capsular Ligament (Plate XLI., figs. 2 and 4, digits 63) . 98
Ligaments of the Carpal Bones 103
Intertransverse Ligaments (Plate XLI., figs. 2 and 4, Plate XLII., fig. 2, marked thus *) 103
Capsular Ligaments (Plate XLI., figs. 2 and 4, also Plate XLII., fig. 2, marked thus *) 103
Intertransverse Ligaments between Carpal and Metacarpal Bones (Plate XLII., fig. 2, marked thus *) 103
Capsular Ligaments, between Carpal and Metacarpal Bones, (Plate XLII., fig. 2, marked thus *) 103
Ligaments of the Thumb 101
Capsular Ligament of Metacarpal Articulation with Os Trapezium (Plate XLI., figs. 2 and 4, letters *g*,) . . . 101
Capsular Ligament of Articulation between the Metacarpal Bone and Proximal Phalanx (Plate XLI., fig. 2, letter *r*) . . 101
Lateral Ligament of this Joint (Plate XLI., fig. 2, letter *k*) . 101
Capsular Ligament of Distal Joint (Plate XLI., fig. 2, letter *m*) 101
Lateral Ligament of Distal Joint (Plate XLI., fig. 2, letter *n*) . 101
Ligaments of Fingers 101
Vaginal Ligaments of Flexor Tendons (Plate XL., and Plate XLI., figs. 1 and 2, digits 30) 95
Intertransverse Ligaments, between heads of Metacarpal Bones (Plate XLI., fig. 1, digits 34) 95
Capsular Ligaments of Proximal Joints (Plate XLI., fig. 2, letters *r*) 101
Lateral Ligaments of Proximal Joints (Pl. XLI., fig. 2, let. *k*) 101

Ligaments of Lower Extremity.

Fascia Lata (Plate XXIII., and Plates XXIX., XXX., and XXXI., letters K, D) 104

Surgical Observations.

Description of the Operation for the Extirpation of Cancerous Mamma 86
Description of the Operation for Diseased Axillary Glands . 86
Luxation of the Sternal Extremity of the Clavicle, with treatment 87
Diseases of Bursa Mucosa beneath Deltoid Muscle . . . 87
Description of Amputation of the Arm 89
Luxation of Shoulder-Joint, with treatment 91
Luxation of Scapular Extremity of Clavicle, with treatment . 92
Inflammation and Suppuration of Fascia Palmaris . . . 94
Contracted Tendons of Flexor Muscles of Fingers . . . 94
Luxation of Elbow-Joint, with treatment 97
Amputation of Fore-Arm 97
Sprains of Muscles in Contiguity of Wrist-Joint . . . 98
Luxation of Distal Extremity of Ulna, with treatment . . 98
Luxation of Distal Extremity of Radius, with treatment . . 98
Luxation of Wrist-Joint, with treatment 99
Luxation of Individual Carpal Bones 103
Luxation of Metacarpal Bone of Thumb, with treatment . . 101
Luxation of Joints of Fingers, with treatment 101
Amputation at the Joints of the Fingers 101
Psoas or Lumbar Abscess, with treatment 106

CONTENTS

OF

PLATES XLV., XLVI., XLVII., XLVIII., XLIX., L., LI., LII., LIII., LIV.

Page

Lower Extremity.—Muscles of the Thigh.

Gluteus Maximus Muscle (Plates XLV. and XLVI., and Plate XXV., letters F, f) 109
Gluteus Medius Muscle (Plate XXV., and Plate XLVI., let. I) 109
Pyriformis Muscle (Plate XLVI., and Plate XXV., letter A) . 110
Gluteus Minimus Muscle (Plate XLVI., letter C) . . . 110
Obturator Internus Muscle (Plates XLVI. and XLVII., and Plate XXV., letter X) 110
Gemellus Superior Muscle (Plates XLVI. and XLVII., fig. 1, letter X) 110
Gemellus Inferior Muscle (Plates XLVI. and XLVII., fig. 1, letter *x*) 111
Quadratus Femoris Muscle (Plate XXV., and Plate XLVI., letters K) 111
Obturator Externus Muscle (Plate XLIV., and Plate XLVI., letters D) 111
Semi-tendinosus Muscle (Plates XXV. and XXVIII., and Plates XLVI. and L, letter M) 111
Biceps Flexor Cruris Muscle (Plate XLVI., and Plate XXV., letters L, l, *l*) 111
Semi-membranosus Muscle (Plates XXV., XXIV., XXVIII., and XLIV., and Plate L., letter N) 112

Muscles of the Leg.

Gastrocnemius Muscle (Plates XXVII., XXVIII., and XXV., and Plate L., fig. 1, letters R, r, *r*) 117
Plantaris Muscle (Plate L., fig. 1, and Plate XXVII., letters U, u) 118
Popliteus Muscle (Plate XXVIII., and Plates L., LI., and LII., letter V) 118
Flexor Longus Digitorum Pedis Muscle (Plate LI., fig. 1, letters O, *o*) 119
Tibialis Posticus Muscle (Plate LII., fig. 1, letter a) . . 120
Peroneus Longus Muscle (Plate XXVI., and Plates L., LIII., and LIV., figs. 1) 121
Peroneus Brevis Muscle (Plates L., LI., LII., LIII., and LIV., figs. 1, letter I) 122
Tibialis Anticus Muscle (Plate XXVI., letter A) . . . 123
Extensor Longus Digitorum Pedis Muscle (Plate XXVI., letter B) 122

Muscles of the Foot.

Flexor Brevis Digitorum Pedis Muscle (Plate XXVIII., and Plate LI., fig. 1) 119
Musculus Accessorius ad Flexorem Longum Digitorum Pedis (Plate L., fig. 1, letter G) 120
Lumbricales Pedis Muscles (Plate LI., fig. 1, letters k) . . 120
Transversalis Pedis Muscle (Plate LII., fig. 1, letter L) . . 120
Extensor Brevis Digitorum Pedis Muscle (Plate XXVI., letter E) 122

Muscles of the Great Toe.

Flexor Longus Pollicis Pedis Muscle (Plate LI., fig. 1, letters A, *a*) 120
Flexor Brevis Pollicis Pedis Muscle (Plate LI., fig. 1, and Plate XXVIII., letter X) 121
Adductor Pollicis Pedis Muscle (Plate LII., letter *q*) . . 121
Abductor Pollicis Pedis Muscle (Plate XXVIII., letter B) . 119
Extensor Proprius Pollicis Pedis Muscle (Plate XXVI., letter C) 123

Page

Muscles of the Little Toe.

Flexor Brevis Digiti Minimi Pedis Muscle (Plate LI., fig. 1, letter N) 121
Abductor Minimi Digiti Pedis Muscle (Plate LI., fig. 1, letter F) 121

Small Muscles of the Toes.

Interossei Digitorum Interni Pedis Muscles (Plate LIII., fig. 1, letters M, P, Q, T, *w*, *g*, *t*) 124
Abductor Digiti Medii Pedis Muscle (Plate LII., fig. 1, letter M) 124
Abductor Tertii Digiti Pedis Muscle (Plate LII., fig. 1, letter P) 124
Abductor Digiti Minimi Pedis Muscle, (Plate LII., fig. 1, letter Q) 124
Interossei Digitorum Externi Pedis Muscles (Plate LIV., fig. 1, letters G, H, K, L) 123
Abductor Indicis Pedis Muscle (Plate LIV., fig. 1, letter G) . 123
Adductor Indicis Pedis Muscle (Plate LIV., fig. 1, letter H) . 123
Adductor Medii Digiti Pedis Muscle (Plate LIV. fig. 1, letter K) 124
Adductor Tertii Digiti Pedis Muscle (Plate LIV., fig. 1, letter L) 124

Ligaments of the Trunk.

Capsular Ligament of Articular Processes of Vertebræ (Plate XLVIII., fig. 2, dig. 2) 114
Common Anterior Ligament of Vertebræ (Plate XLVIII., fig. 3, letter *a*) 114
Crucial Ligaments of Vertebræ (Plate XLVIII., fig. 1, letter b) 115
Capsular Ligament of Head of Rib (Plate XLVIII., fig. 3, letter c) 115
Obturator Ligament (Plate XLVII., fig. 2, letter U) . . 114
Longer Sacro-Ischiadic Ligament (Plate XLVII., fig. 1, and Plate XLVIII., figs. 1 and 2, letter H) 114
Shorter Sacro-Ischiadic Ligament (Plate XLVII., fig. 1, and Plate XLVIII., figs. 1 and 2, letter h) 114
Ligamentous Expanse of Os Coccygis (Plate XLVIII., fig. 2, letter a) 114
Lacertus Ligamentosus of Pelvis (Plate XLVIII., fig. 1, letter q) 114
Annular Ligament of Symphysis Pubis (Plate XLVIII., fig. 1) 114
Ilio-Sacral Ligaments (Plate XLVIII., fig. 2, letter *z*) . . 114
Transverse Ligaments of Pelvis (Plate XLVIII., fig. 2, letter k) 114
Ligamenta Vaga of Pelvis (Plate XLVIII., figs. 1 and 2, letters *i*) 114

Ligaments, &c. of the Lower Extremity.

Capsular Ligament of Hip-Joint (Plate XLIV., and Plate XLVII., letters A, *a*) 112
Synovial Gland (Plate XLVII., fig. 2, letter R) . . . 112
Ligamentum Teres (Plate XLVII., fig. 2, letter B) . . 112

Ligaments, &c. of the Knee-Joint.

Tendinous Expanse of Fascia Lata and Vasti Muscles (Plate XLIX., fig. 1, letters *l*, *o*) 115
Patellar Ligament (Plate XLIX., fig. 1, letter *y*) . . . 115
Bursa Mucosa of Patellar Ligament (Plate XLIX., fig. 1, letter *g*) 115

Page

Popliteal Ligament (Plates L., LI., LII., and LIII., figs. 1, digits 10) 115
Tibial Lateral Ligament (Plates L., LI., LII., and LIII, figs. 1, digit 2) 115
Fibular Lateral Ligament (Plate XIX., figs. 1 and 2, and Plates LI., LII., and LIII., figs. 1, digit 3) 115
Capsular Ligament (Plate XLIX., fig. 2, and Plate L., figs. 2 and 3, digits 4) 115
Bursa Mucosa, beneath Insertions of Crureus and Rectus Muscles (Plate XLIX., fig. 2, digit 1) 115
Mucous Ligament (Plate XLIX., fig. 2, digit 8) 116
Synovial Gland (Plate XLIX., fig. 2, digit 7) 116
Alar Ligaments (Plate XLIX., fig. 2, digits 10) 116
Crucial Ligaments (Plate L., figs. 2 and 3, digits 11, 12) . 116
Semilunar Cartilages (Plate L., fig. 2, digits 13, 14) . . 116

Ligaments connecting the Tibia and Fibula together.

Intertransverse Ligaments of Head of Fibula (Plate LIII., fig. 1, digit 4) 125
Capsular Ligament of Head of Fibula (Plate LIII., fig. 1) . 125
Interosseous Ligament (Plates LIII., LIV., LII., LI., figs. 1, H) 124
Intertransverse Ligaments of Distal Extremities of Tibia and Fibula (Plate LIV., figs. 1, 2, and 3, digit 7) 125

Liguments, &c. of the Ankle-Joint.

Capsular Ligament (Plate LIV., figs. 1, 2, and 3, and Plate LI., fig. 2, digits 30) 125
Deltoid Ligament (Plate LII., fig. 2, and Plate LIV., fig. 1, digit 11) 125
Fibular Lateral Ligament (Plate LIV. figs. 1, 2, and 3, digits 31, 32, and 14) 125
Fibular Anterior Portion (Plate LIV., fig. 1, digit 31) . . 125
Fibular Middle Portion (Plate LIV., figs. 1, 2, and 3, digit 32) 125
Fibular Posterior Portion (Plate LIV., fig. 3, digit 14) . . 125
Synovial Tissue (Plate LIV., fig. 3, digit 10) 125

Page

Ligaments of the Foot.

Tarsal Ligaments (Plate LIV., fig. 1, letters *z*, and Plates LII. aud LIII., letters *w*, *y*) 126
Patellar Transverse Ligaments (Plate LIV., fig. 1, and Plate LI., fig. 3, letters *z*) 126
Intertransverse Ligament (Plate LI., fig. 2, let. *z*) . . . 126
Plantar Ligaments (Plates LII. and LIII., figs. 1 and 2, letters *w*, *y*) 126

Surgical Observations.

Diseases of Bursa Mucosa, beneath Gluteus Maximus Muscle . 109
Operation of Amputation of the Thigh 112
Luxation of the Hip-Joint 112
Morbus Coxarius 114
Diseases of Bursa Mucosa, beneath Patellar Ligament . . 115
Fracture of the Patella 116
Laceration of the Tendons of the Muscles inserted in Patella . 116
Luxation of the Patella 116
Luxation of the Knee-Joint 116
Displacement of the Interarticular Cartilages in Knee-Joint . 116
Wounds of the Knee-Joint 116
Cartilaginous Bodies in the Knee-Joint 117
Inflammation of the Knee-Joint 117
Dropsy of the Knee-Joint 117
Suppuration of the Knee-Joint 117
White Swelling of the Knee-Joint 117
Excision of the Knee-Joint 117
Ruptured Tendo Achillis 118
Wounds of the Fascia Plantaris 118
Fracture of the Tibia and Fibula 122
Sprains of the Muscles of the Leg 122
Operation of Amputation of the Leg . . . 124
Luxation of Head of the Fibula 125
Luxation of the Ankle-Joint 125

CONTENTS

OF

PLATES LV., LVI., LVII., LVIII., LIX., LX., LXI.

	Page
Division of the Nervous System	129
Cerebrum (Plate LV., letters A)	129
Division of the Cerebrum	129
Hemispheres of the Cerebrum (Plates LV., LVI., and LVII., letters A)	129
Lobes of the Cerebrum (Plates LVI. and LXIV., letters a, *a*, a)	129
Condition of the Hemispheres and Lobes in the Fetus	129
Dura Mater (Plate LV., letters D, d)	129
Tentorium Cerebelli (Plates LXII. and LXV., letter *d*)	129
Falx Cerebri (Plate LVIII., D)	129
Falx Cerebelli (Plate LXV., *δ*)	129
Condition of Dura Mater in the Fetus	130
Tunica Arachnoides (Plates LV., LVI., LVII., LXIV., and LXVI.)	130
Ligamentum Denticulatum	130
Condition of Tunica Arachnoides in the Fetus	130
Pia Mater (Plates LV. and LVI.)	130
Velum Interpositum Halleri (Plate LXI. fig. 2, and Plate LXII., letters i, *i*)	131
Choroid Plexus (Plates LX. and LXI., letters *i*)	131
Condition of Pia Mater in the Fetus	131
Glandulæ Pacchioni (Plate LVII.)	131
Corpus Callosum (Plates LVIII., LIX., and LX., letter *w*)	131
Raphe of Corpus Callosum (Plates LIX. and LX.)	131
Cineritious and Medullary Substances of the Brain (Plates LVIII., LIX., LX., LXI., LXII., LXIII.)	131
Convolutions of the Cerebrum (LV., LVI., LVII., and LXVIII.)	131
Condition of Convolutions of the Cerebrum in the Fetus	131
Centrum Ovale of Vieussens (Plate LIX., letter E)	131
Centra Ovalia of Vicq D'Azyr	131
Lateral Ventricles (Plate LX., letters A, P, I)	131
Corpus Striatum (Plate LX., letter G)	131
Tænia Semicircularis (Plate LX., *t*)	132
Septum Lucidum (Plate LX., letter L)	132
Fifth Ventricle (Plate LXI., fig. 1, dig. 5)	132
Fornix (Plate LX., letter K)	132
Hippocampus Minor (Plate LX., letter *k*)	132
Hippocampus Major (Plate LX., letter ꝁ)	132
Lyra or Psalterium	132
Condition of the Fornix in the Fetus	132
Thalami Nervorum Opticorum (Plate LX., letters F, F)	132
Commissura Mollis (Plate LXI., fig. 3, letter m)	132
Anterior Tubercles of Thalami (Plate LXI., fig. 3, letter f)	132
Corpus Geniculatum Internum, (Plate LXI., fig. 3, letter *f*)	132
Corpus Geniculatum Externum	132
Condition of Corpora Geniculata in the Fetus	132
Foramen Commune Anterius (Plates LXII., LXIII., letter a)	132
Foramen Commune Posterius (Plates LXII., LXIII., letter *a*)	133
Third Ventricle (Plate LXI., fig. 3, dig. 3)	133
Iter ad Infundibulum (Plate LXI., fig. 4, letter I)	133
Infundibulum (Plate LXI., fig. 4, letter *i*)	133
Condition of Infundibulum in the Fetus	133
Iter à Tertio ad Quartum Ventriculum (Plates LXI. and LXVIII., fig. 4, dotted line)	133
Foramen Monroianum (Plates LX., LXI., fig. 2, letter M)	133
Anterior Commissure (Plates LXI., LXIII., LXVIII., fig. 3, letter *c*)	133
Posterior Commissure (Plates LXI., LXII., LXIII., LXVIII., figs. 3 and 4, let. *p*)	133
Pineal Gland (Plates LXI., LXII., LXIII., LXVIII., fig. 3, letter H)	133
Condition of Pineal Gland in the Fetus	133
Corpora Quadrigemina (Plates LXI., LXII., LXIII., LXVIII., figs. 3 and 4, letters e, *e*)	133
Nates (Plates LXI., LXII., LXIII., LXVIII., figs. 3 and 4, letters e)	133
Testes (Plates LXI., LXII., LXIII., LXVIII., figs. 3 and 4, letters *e*)	133
Condition of Corpora Quadrigemina in the Fetus	133

CONTENTS

OF

PLATES LXII., LXIII., LXIV., LXV., LXVI., LXVII., LXVIII., LXIX.

Page

Valve of Vieussens (Plate LIX., letter v) 135
Condition of the Valve of Vieussens in the Fetus . . . 135
Iter à Tertio ad Quartum Ventriculum (Plates LXI. and LXVIII., - - - - -) 135
Condition of Ditto in the Fetus 135
Cerebellum (Plates LV., LVI., LIX., LXIII., LXIV., LXVII., and LXVIII., letters B) 135
Division of Cerebellum 135
Arbor Vitæ (Plate LXVIII., and fig. 3 of Plate LXVI.) . 135
Fourth Ventricle (Plates LIX. and LXVIII., digit 4) . . 135
Calamus Scriptorius (Plate LIX., digit 4) 135
Condition of Fourth Ventricle in the Fetus 135
Valve of Tarin or Reil (Plate LIX., letter *r*) 135
Crura Cerebelli (Plates LXVII. and LXVIII., letter *n*) . 136
Processus Cerebelli ad Testes (Plate LXVIII., and fig. 2, Plate LXVI., letter *l*) 136
Processus Cerebelli ad Medullam Oblongatam (Plates LXVII. and LXVIII., and fig. 2, Plate LXVI., letter *o*) . . 136
Processus Cerebelli ad Pontem Varolii (Plate LXVII., and fig. 2, Plate LXVI., letter *n*) 136
Corpus Dentatum (Plate LXVI., fig. 3, letter D) . . . 136
Condition of the Cerebellum in the Fetus 136

Description of the Base of the Brain, (Plate LXIV.) . . 136
Crura Cerebri (Plates LXIV. and LXVII., letters g, g) . . 136
Condition of Crura Cerebri in the Fetus 136
Tuber Annulare (Plate LXVII., and fig. 2, Plate LXVI., letter E) 136
Condition of Tuber Annulare in the Fetus 136
Foramen Cæcum Anticum (Plates LXVI. and LXVII.) . 137
Corpora Pyramidalia (Plates LXVI. and LXVII., letters G, G) 137
Condition of Corpora Pyramidalia in the Fetus . . . 137
Corpora Olivaria (Plates LXVI. and LXVII., letters F, F) . 137
Condition of Corpora Olivaria in the Fetus 137
Corpora Mamillaria (Plates LXVI. and LXVII., letters *s*, *s*) . 137
Condition of Corpora Mamillaria in the Fetus . . . 137

Nerves from the Base of the Brain (Plate LXIV.) . . . 137
First Pair, or Olfactory Nerves (Plates LXIV., LXV., and LXVII., fig. 7 of Plate LXI., and fig. 5 of Plate LXVI., digits 1, 1) 137
Condition of Olfactory Nerves in the Fetus 137
Second Pair, or Optic Nerves (Plates LXIV., LXV., LXVII., fig. 7 of Plate LXI., and fig. 5, Plate LXVI., digits 2, 2) . 137
Condition of Optic Nerves in the Fetus 137
Corpus Geniculatum Externum (Plate LXVI., fig. 5, letter f) . 137
Third Pair of Nerves, or Motores Oculorum (Plates LXIV. and LXV., and fig. 7 of Plate LXI., digits 3, 3) . . . 138
Condition of Motores Oculorum in the Fetus 138
Fourth Pair of Nerves, or Pathetici (fig. 7, Plate LXI., Plates LXIV. and LXV., and Plate LXVI., fig. 2, digits 4) . 138
Condition of Pathetici in the Fetus 138
Fifth Pair of Nerves, or Trigemini (Plate LXI., fig. 7, Plates LXIV. and LXV., and Plate LXVI., fig. 2, digits 5) . 138
Condition of Trigemini in the Fetus 138
Sixth Pair of Nerves, or Abducentes (Plate LXI., fig. 7, Plates LXIV. and LXV., and fig. 2 of Plate LXVI., digits 6) . 138
Condition of Abducentes in the Fetus 138
Seventh Pair, or Facial Nerves (Plate LXI., fig. 7, Plates LXIV. and LXV., and Plate LXVI., fig. 2, digits 7) . 138
Condition of Facial Nerve in the Fetus 138
Eighth Pair, or Auditory Nerves (Plate LXI., fig. 7, Plates LXIV. and LXV., and Plate LXVI., fig. 2, dig. 8) . . 138
Condition of Auditory Nerves in the Fetus 138

Page

Ninth Pair, or Glosso-Pharyngeal Nerves (Plate LXI., fig. 7, Plates LXIV., LXV., and fig. 2 of Plate LXVI., dig. 9) . 138
Condition of Glosso-Pharyngeal Nerves in the Fetus . . 139
Tenth Pair of Nerves, or Nervi Vagi (Plate LXI., fig. 7, Plates LXIV., LXV., and Plate LXVI., fig. 2, digits 10) . . 139
Condition of Nervi Vagi in the Fetus 139
Eleventh Pair, or Accessory Nerves to the Nervi Vagi (Pl. LXI., fig. 7, Pls. LXIV., LXV., and Pl. LXVI., fig. 2, dig. 11) . 139
Condition of Accessory Nerves in the Fetus 139
Twelfth Pair, or Lingual Nerves (Plate LXI., fig. 7, Plates LXIV., LXV., and Plate LXVI., fig. 2, digits 12) . . 139
Condition of Lingual Nerves in the Fetus 139

Arteries of the Brain (Plate LXIV.) 139
Internal Carotid Artery (Plate LVI., fig. 7 of Plate LXI., Plates LXIV., LXVIII., dig. 19) 139
Ophthalmic Artery (Plate LXV., letter *o*) 139
Lateral Communicant (Plate LXV., letter *t*) 139
Anterior Branch of Internal Carotid, or Anterior Artery of Cerebrum, or Artery of Corpus Callosum, (Plates LVIII., LX., LXII., LXIII., and LXVIII., letter v) 139
Middle Branch of Internal Carotid, or Middle Artery of Cerebrum (Plates LXIV., LXIII., LX., LVIII., and LVI., let. *y*) 140
Vertebral Artery (Plate LVI., LXIV., LXV., LXVIII., and fig. 7 of Plate LXI., and fig. 6, Plate LXVI., letter R) . 140
Posterior Artery of Cerebrum (Plates LXIV., LXII., LXIII., letter *r*) 140
Posterior Meningeal Artery 140
Posterior Spinal Artery 140
Anterior Spinal Artery 141
Posterior Cerebellar Artery (Plate LXIV., letter e) . . 141
Anterior Cerebellar Artery (Plate LXIV., letter *o*) . . 141
Middle Meningeal Artery (Plates LXV. and LVII., digit 5*) . 141

Veins, or Sinuses of the Brain (Plate LXV.) 141
Superior Longitudinal Sinus (Plates LVII., LVIII., LXVIII., letter *x*) 141
Lateral Sinus (Plates LXV., LVIII., LXII., LXVIII., let. *z*) 142
Inferior Longitudinal Sinus (Plate LVIII., letter G) . . 142
Vena Magna Galeni (Plate LXII., letter i) 142
Fourth Sinus (Plates LXVIII., LXV., LXII., digits IV) . 142
Torcular Herophili 142
Ophthalmic Sinus 142
Cavernous Sinus (Plate LXV., letter c) 142
Sinus of Ridley (Plate LXV.) 142
Superior Petrosal Sinus (Plate LXV., letter *p*) . . . 142
Inferior Petrosal Sinus (Plate LXV.) 142
Occipital Sinus (Plate LXV.) 142
Inferior Lateral Sinuses 142
Lateral Basilar Sinuses 142
Middle Basilar Sinus 142
Transverse Clinoid Sinus 142
Sphenoidal Sinuses 142
Vertebral Sinuses 142
Venæ Emissariæ vel Emissaria Santorini 143
Spinal Cord (Plates LV., LVI., LIX., LXIV., LXVII., and LXVIII., figs. 5, 6, 7, Plate LXI., fig. 1, Plate LXVI., let. c) 143
Medulla Oblongata (Plates LXIV., LXVII., letters F, G) . 143
Spinal Nerves (Plate LV., fig. 1 of Plate LXVI.) . . . 143
Fetal Developement of Spinal Cord 143
Description of the Brain according to Willis 144
Description of the Brain according to Varolius, Vieussens, and Gall and Spurzheim 145
Fetal Developement of the Brain 145

CONTENTS

OF

PLATES LXX., LXXI., LXXII., LXXIII., LXXIV., LXXV., LXXVI., LXXVII., LXXVIII., LXXIX.

Page

Muscles of the Neck 149
Platysma Myoides Muscle (Plate XVIII., F) . . . 149
Sterno-Cleido-Mastoideus Muscle (Plate XVII., E) . . 150
Sterno-Hyoideus Muscle (Plate XVII., C) 150
Sterno-Thyroideus Muscle (Plate XVI., B) 150
Thyro-Hyoideus Muscle (Plate XVI., Z) 150
Omo-Hyoideus Muscle (Plate XVII., and Plate XXXIII., U) 150
Crico-Thyroideus Muscle (Plate XIV., and Plate LXX., a) . 150
Digastric Muscle (Plate XVII., and Plate LXX., w, *w*) . 151
Mylo-Hyoideus Muscle (Pls. XVI., XVII., and Pl. LXXI., *m*) 151
Genio-Hyoideus Muscle (Plate XV., and Plate LXXI., *l*) . 151
Genio-Hyo-Glossus Muscle (Plate XV., and Plates LXXI. and LXXII., figs. 1, *k*) 151
Stylo-Hyoideus Muscle (Plate LXX., G) 152
Stylo-Glossus Muscle (Plate XVI., and Plate LXXI., m) . 152
Stylo-Pharyngæus Muscle (Plate XVI., and Plate LXXI., k) . 152
Hyo-Glossus Muscle (Plates XV., XVI., and Plate LXX., *i*) . 152
Lingualis Muscle (Plate XV., dig. 60) 152
Constrictor Pharyngis Inferior Muscle (Plates LXX., LXXI., Y) 152
Constrictor Pharyngis Medius Muscle (Plates LXX., LXXI., F) 152
Constrictor Pharyngis Superior Muscle (Pls. LXX., LXXI., *y*) 153
Constrictor Isthmi Faucium Muscle (Pl. LXXIII., fig. 1, dig. 1) 154
Circumflexus Palati Muscle (Plates LXXII., LXXIII. fig. 1, a) 154
Levator Palati Muscle (Plates LXXII., LXXIII., figs. 1, L) . 154
Azvgos Uvulæ Muscle (Plate LXXIII., fig. 1, *u*) . . . 154
Palato-Pharyngæus Muscle (Plate LXXII., fig. 1, D) . . 154
Crico-Arytænoideus Posticus Muscle (Plate LXXIII., fig. 1, *m*) 156
Crico-Arytænoideus Lateralis Muscle (Plate LXXIII., fig. 1, *p*) 156
Arytænoidei Obliqui Muscles (Plate LXXIII., fig. 1, *r*, *r*) . 156
Arytænoideus Transversus Muscle (Plate LXXIII., fig. 1, *t*) . 156
Thyro-Arytænoideus Muscle (Plate LXXIII., fig. 1, *g*) . . 157
Thyro-Epiglottideus Muscle 157
Arytæno-Epiglottideus Muscle (Plate LXXIII., fig. 1, *q*) . 157
Longus Colli Muscle (Plate LXXI., L) 157
Rectus Capitis Anticus Major Muscle (Plates LXX., LXXI., and LXXII., fig. 1, R) 157
Rectus Capitis Anticus Minor Muscle (Plate LXXII., fig. 1, r) 157
Scalenus Anticus Muscle (Plates IX., XV., and XVI., marked L) 157
Scalenus Posticus Muscle (Pl. XV., and Pl. XXXIV., marked 50) 157

Muscles of the Face 158
Occipito-Frontalis Muscle (Plate XVIII., marked q) . . 158
Orbicularis Palpebrarum Muscle (Plate XVIII., marked w) . 158
Compressor Naris Muscle (Plate XVIII., marked n) . . 158
Levator Labii Superioris Alæque Nasi Muscle (Plate XVIII., marked i) 158
Zygomaticus Minor Muscle (Plate XVIII., marked e) . . 159
Zygomaticus Major Muscle (Plate XVIII., marked a) . . 159
Depressor Anguli Oris Muscle (Plate XVIII., marked b) . 159
Orbicularis Oris Muscle (Plate XVIII., marked f) . . 159
Levator Anguli Oris Muscle (Plate XVIII., marked o) . . 159
Depressor Labii Inferioris Alæque Nasi Muscle (Plate LXXIII., fig. 3, marked *s*) 159
Depressor Labii Inferioris Muscle (Plate XVIII., marked 70) . 159
Levator Labii Inferioris Muscle (Pl. LXXIII., fig. 3, marked *i*) 159
Masseter Muscle (Plates XVII. and XVIII., marked l) . . 160
Buccinator Muscle (Pls. XVI., XVII., and XVIII., marked h) 160
Temporal Muscle (Pls. XVI., XVII., and Pl. LXXI., marked u) 160
Pterygoideus Internus Muscle (Plate XVI., and Plates LXXI. and LXXII., figs. 1, marked n) 160
Pterygoideus Externus Muscle (Plate XVI., and Plates LXXI. and LXXII., fig. 1, marked t) 160

Page

Ligaments of Inferior Maxillary Bone 160
Capsular Ligament (Pls LXX., LXXI., and LXXII., fig. 1, *c*) 160
Interarticular Cartilage (Plates LXX., LXXI., and LXXII., figs. 1, marked *h*) 160

Ligaments peculiar to Atlas and Dentata 161
Transverse Ligament of Atlas (Pl. LXXII., figs. 1 and 2, dig. 1) 161
Lateral Ligaments (Plate LXXII., figs. 1 and 2, marked with the digits 2) 161
Perpendicular Ligament (Plate LXXII., figs. 1 and 2, marked with the digit 3) 161

Pharynx (Pls. LXXI., LXXII., LXXIII., and LXXIV., fig. 1) 153
Velum Pendulum Palati (Plates LXXII., LXXIII., and LXXIV., F) 153
Fauces (Plates LXXII., LXXIII., and LXXIV., digits 1, 2) 153
Amygdalæ, or Tonsils (Pls. LXXII., LXXIII., and LXXIV., dig. 3) 153
Larynx, (Plate LXXIII., fig. 2) 155
Thyroid Cartilage (Plates XV. and XVI., Plate LXXII., fig. 1, and Plate LXXIII., figs. 1 and 2, s) 155
Cricoid Cartilage (Plate XV., Plate LXXII., fig. 1, and Plate LXXIII., figs. 1 and 2, N) 155
Arytænoid Cartilages (Plate LXXIII., figs. 1 and 2, and Plate LXXIV., fig. 1, *c*) 156
Vocal Ligaments (Plate LXXIII., fig. 2, *a*) . . . 156
Glottis (Plate LXXIII., fig. 2) 156
Ventricles of Larynx (Plate LXXIII., fig. 2, v) . . . 156
Epiglottis (Plates LXXI., LXXII., LXXIII., LXXIV., fig. 1) 156
Lateral Ligaments of Epiglottis (Plate LXXIII., fig. 2, *b*) . 156
Os Hyoides (Plate XV., Plates LXX., LXXI., LXXII., fig. 1, and Plate LXXIII., fig. 2, x) 156

Organs of Sense 162
Nose (Plates LXXIV. and LXXV) 162
Septum Narium (Pl. LXXIV., figs. 1 and 2, and Pl. LXXV., fig. 1, marked c) 162
Columna (Pl. LXXIV., figs. 1 and 2, Plate LXXV., fig. 1, D) 162
Anterior Lateral Cartilage, or Pinna, or Ala of Nose (Plate LXXIV., fig. 2, marked E) 162
Perpendicular Cartilage (Plate LXXIV., fig. 2, marked A) . 162
Posterior Lateral Cartilage (Plate LXXIV., fig. 1, marked T) . 162
Aperture to the Eustachian Tube (Pl. LXXIV., fig. 1, marked Z) 162
Mucous or Schneiderian Membrane (Pls. LXXIV. and LXXV.) 162
Cells of the Nares (Plate LXXIV., figs. 1 and 3, and Plate LXXV., figs. 1, 2, and 3) 162
Frontal Sinuses (Plate LXXIV., figs. 1 and 3, and Pl. LXXV., figs. 1, 2, and 3, marked f) 162
Their Canal of Communication with Nares (Plate LXXIV., fig. 3, Plate LXXV., fig. 1, bristle marked 2) . . 163
Ethmoidal Cells (Plate LXXIV., figs. 1 and 3, and Pl. LXXV., figs. 1, 2, and 3, marked *f**) 162
Their Canal of Communication with Nares (Plate LXXIV., fig. 3, and Plate LXXV., fig. 1, bristle marked 5) . 163
Palatine Cell (Plate LXXIV., figs. 1 and 3, and Plate LXXV., figs. 1, 2, and 3, marked P) 162
Its Channel of Communication with Nares (Plate LXXV., fig. 1, bristle marked 7) 163
Sphenoidal Cell (Plate LXXIV., figs. 1 and 3, and Pl. LXXV., figs. 1, 2, and 3, marked *g*) 162
Its Channel of Communication with Nares (Pl. LXXIV., fig. 3, and Plate LXXV., fig. 1, bristle marked 4) . 163

Page

Antrum Maxillare (Plate LXXIV., figs. 1 and 3, and Plate LXXV., figs. 1, 2, and 3, marked A) 162
Its Canal of Communication with Nares (Plate LXXV., fig. 1, bristle marked 6) 163
Lacrymal Duct (Plate LXXIV., fig. 3, and Plate LXXV., figs. 1 and 2, bristle marked with the digits 3) . . . 163
Aperture of Lacrymal Duct in Orbit (Plate LXXIX., fig. 2, marked G) 163
Arteries which supply the Nares 163
Nerves which are distributed in the Nares 163
Organ of Tasting 164
Mouth 164
Labial Glands (Plate LXXIII., fig. 3, marked *l*, *u*) . . 164
Frenum of Upper Lip (Plate LXXIII., fig. 3, marked *f*) . 164
Frenum of Lower Lip (Plate LXXIII., fig. 3, marked f) . 164
Palatine Glands (Plate LXXIII., fig. 1, marked V, F) . . 164
Tongue (Plate LXXIII., fig. 1, and Plate LXXVI., figs. 2, 3) 164
Foramen Cœcum of Morgagni (Plate LXXIII., fig. 1, and Plate LXXVI., fig. 3, *h*) 165
Papillæ Lenticulares (Plate LXXVI., fig. 3) . . . 165
Papillæ Semi-lenticulares (Plate LXXVI., fig. 3) . . . 165
Papillæ Villosæ (Plate LXXVI., fig. 3) 165
Nerves which supply the Tongue (Plate LXXVI., figs. 3 and 4, digits 3, 13, and 32) 165
Glosso-Pharyngeal Nerves (Plate LXXVI., figs. 3 and 4, digits 13) 165
Gustatory Branch of Inferior Maxillary Nerve (Plate LXXVI., figs. 3 and 4, digit 32) 165
Lingual Nerve (Plate LXXVI., figs. 3 and 4, digit 3) . . 165
Arteries which supply the Tongue 165
Ear (Plates LXXVI. and LXXVIII.) 165
External Portion (Plate LXXVII., figs. 1, 2, 3, and 5) . . 166
Pinna (Plate LXXVIII., fig. 16) 166
Lobulus (Plate LXXVII., figs. 1, 2, 3, and 5, marked B) . 166
Helix (Plate LXXVIII., fig. 16, letters *a*) 166
Fossa Innominata (Plate LXXVIII., fig. 16, *i*) . . . 166
Antihelix (Plate LXXVIII., fig. 16, c) 166
Crura of Antihelix (Plate LXXVIII., fig. 16, *c*) . . . 166
Fossa Navicularis (Plate LXXVIII., fig. 16, *n*) . . . 166
Tragus (Plate LXXVIII., fig. 16, *e*) 166
Antitragus (Plate LXXVIII., fig. 16, *o*) 166
Concha (Plate LXXVIII., fig. 16, C) 166
Meatus Auditorius Externus (Plate LXXVII., fig. 5, *p*) . . 166
Cartilaginous Tube (Plate LXXVII., fig. 5, *n*) . . . 166
Fissures of Pinna (Plate LXXVIII., fig. 16, letters T, W, X) . 166

Muscles operating on External Cartilage of Ear . . . 166
Attollens Aurem (Plate XVIII., and Plate LXXVII., figs. 1 and 2, r) 166
Anterior Auris (Plate LXXVII., figs. 1 and 2, D) . . . 166
Retrahens Auris (Plate LXXVII., figs. 1 and 2, R) . . 167
Helicis Major (Plate LXXVII., figs. 1 and 2, H) . . . 167
Helicis Minor (Plate LXXVII., figs. 1 and 2, *h*) . . . 167
Tragicus (Plate LXXVII., fig. 2, T) 167
Antitragicus (Plate LXXVII., fig. 2, *t*) 167
Transversus Auris (Plate LXXVII., fig. 4, U) . . . 167
Sebaceous Glands of External Ear 167
Middle Portion of Ear 167
Tympanic Cavity (Plate LXXVII., fig. 6, and 16, t) . . 167
Membrana Tympani (Pl. LXXVII., fig. 5, and Pl. LXXVIII., figs. 1, 2, 3, and 4, *r*) 167
Eustachian Tube (Pl. LXXVII., figs. 6 and 7, Pl. LXXVIII., figs. 1 and 2, and Plate LXXIV., fig. 1, Z, z) . . . 168
Semi-osseous Canal of Tensor Tympani Muscle (Pl. LXXVII., fig. 6, bristle marked l) 168
Mastoid Cells (Plate LXXVII., fig. 6, m*) 168
Foramen Ovale (Plate LXXVII., fig. 6, o) 168
Foramen Rotundum (Pl. LXXVII., fig. 6, and Pl. LXXVIII., figs. 9, 10, 12, 13, r) 168

Page

Osseous Hollow Pyramid of Tympanum (Plate LXXVII., figs. 6, 9, and Plate LXXVIII., figs. 7, 8, 9, 10, p) . . 168
Fallopian Aqueduct (Plate LXXVII., figs. 6 and 16, bristle 2) 168
Protuberance in Tympanic Cavity (Plate LXXVII., fig. 6, *c*) 168
Promontory of Tympanic Cavity (Plate LXXVII., figs. 6, 9, *a*) 168
Ossicula Auditus 168
Malleus (Plate LXXVII., figs. 11, 12, 7, 8, Plate LXXVIII., figs. 1, 2, 3, 4, 5, 6, 15, marked with the digits 1*, 2, 3, 4, 5) 169
Incus (Plate LXXVII., figs. 13, 14, 7, 8, Plate LXXVIII., figs. 1, 2, 3, 4, 5, 6, 15, marked with the digits 6*, 8, 7*) . 169
Stapes (Plate LXXVII., figs. 15, 7, 8, and 9, and Plate LXXVIII., figs. 9 and 10, marked *w*, 9, and 10) . . 169

Muscles operating on Ossicula Auditus 169
Tensor Tympani (Plate LXXVIII., figs. 1, 2, 3, 4, 7, 8, 15, q) 169
Laxator Tympani Major (Plate LXXVIII., figs. 1, 2, 16, L) . 169
Laxator Tympani Minor (Plate LXXVIII., figs. 3 and 4, l) . 169
Stapedius (Plate LXXVIII., figs. 9 and 10, s) . . . 169
Labyrinth, or Internal Portion of Ear 170
Vestibule (Plate LXXVIII., figs. 12, 13, and 17) . . . 170
Cavitas Semi-ovalis (Plate LXXVIII., fig. 17, *s*) . . . 170
Cavitas Hemispherica (Plate LXXVIII., fig. 17, *h*) . . 170
Cavitas Sulciformis (Plate LXXVIII., fig. 17, *f*) . . . 170
Aqueduct of Vestibule (Plate LXXVIII., fig. 14, K) . . 170
Three Semicircular Canals 170
Superior or Vertical Canal (Plate LXXVII., figs. 7 and 10, and Plate LXXVIII., figs. 3, 4, 5, 6, 7, 8, 9, 10, 12, 13, 15, *p*) . 170
Oblique or Internal Canal (Plate LXXVII., figs. 7 and 10, and Plate LXXVIII., figs. 3, 4, 5, 6, 7, 8, 9, 10, 12, 13, 15, *o*) . 170
Horizontal or External Canal (Plate LXXVII., figs. 7 and 10, Plate LXXVIII., figs. 3, 4, 5, 6, 7, 8, 9, 10, 12, 13, 15, c) 170
Cochlea (Plate LXXVII., figs. 7 and 10, and Plate LXXVIII., figs. 3, 4, 5, 6, 7, 8, 9, 10, 11, 12, 13, and 15, C) . . 170
Internal Auditory Foramen (Plate LXXVIII., fig. 14) . . 171
Auditory Nerve (page 138) 171
Facial Nerve (page 52) 171
Chorda Tympani (Plate LXXVIII., figs. 5, 6, 7, and 8, marked 33; also in Plate XV., and described in page 52 . . 171

Surgical Observations.

Wry Neck 150
Pharyngotomy 152
Cynanche Tonsillaris 153
Extirpation of the Tonsils 154
Cynanche Pharyngea 154
Velu-Synthesis 154
Laryngotomy 155
Tracheotomy 155
Cynanche Laryngea 155
Cynanche Trachealis 155
Luxation of Inferior Maxillary Bone 161
Operation for Removal of Inferior Maxillary Bone . . . 161
Luxation of the Vertebræ 161
Fracture of the Vertebræ 161
Luxation of Atlas 161
Luxation of Vertebra Dentata 162
Epistaxis, and the Manner of Plugging up the Nostrils . . 163
Polypi in Nares, with their Treatment 164
Polypi, or Sarcomatous Tumours in Antrum Maxillare, with their Treatment 164
Operation for Cancerous Lip 165
Tumours on the Gums, with their Treatment 165
Tumours on the Cheeks, Warty Excrescences, and Cancerous Ulcerations, with their Treatment 165
Cancer of the Tongue, with its Treatment 165
Polypus in Meatus Auditorius Externus, with Treatment . 166
Operation of Puncturing Membrana Tympani 167
Eustachian Tube Inflamed, with Treatment 168
Abscess in Mastoid Cells, with Treatment 168

CONTENTS

OF

PLATES LXXX., LXXXI., LXXXII., LXXXIII., LXXXIV., LXXXV., LXXXVI., LXXXVII.

Page

THE EYE (Plates LXXIX., LXXX., and LXXXI.) . . 173
Bones of the Orbit (Plate IV.) 173

External Appendages of the Eye 173
Supercilium (Plate LXXIX., fig. 1, letter S) 173
Corrugator Supercilii Muscle (Plate LXXIX., fig. 2, letter *s*) . 173
Palpebræ (Plate LXXIX., fig. 1, letters T, t) . . . 173
Tarsi (Plate LXXIX., fig. 1, letters T, t) 173
Cilia (Plate LXXIX., fig. 1) 174
Ciliary Glands (Plate LXXIX., fig. 1, letters T, t) . . 174
Lacrymal Gland (Plate LXXIX., figs. 2, 3, and 4, *q*; also Plate LXXX., fig. 1, *q*) 174
Caruncula Lachrymalis (Plate LXXIX., fig. 1, letter C) . . 174
Lacus Lachrymalis (Plate LXXIX., figs. 1 and 2) . . . 174
Plica Semilunaris (Plate LXXIX., fig. 1, letter P) . . . 174
Puncta Lachrymalia (Plate LXXIX., fig. 1, letters *p*) . . 174
Canaliculi Lachrymales (Plate LXXIX., fig. 2, digits 1 and 2) 174
Saccus Lachrymalis (Plate LXXIX., fig. 2, letter G) . . 174
Ductus Lachrymalis (Pl. LXXIII., fig. 1, Pl. LXXV., figs. 17, 16, 27, and 28, digit 3; see also p. 14) 174

Coats of the Eye 175
Tunica Conjunctiva (Plate LXXIX., fig. 1) 175
Cornea (Plate LXXXI., figs. 1, 3, 5, 6, 8, 10, letter *f*) . . 175
Iris (Plate LXXXI., figs. 3, 5, 6, and 7, letter *i*) . . . 175
Tunica Sclerotica (Plate LXXXI., figs. 1, 3, 5, 6, 8, 10, let. *s*) 176
Tunica Choroides (Plate LXXXI., figs. 5, 8, 7, 9, 10, and 11, letter *b*) 176
Ciliary Plicæ (Plate LXXXI., figs. 7, 9, 12, letter *m*) . 176
Ciliary Processes (Plate LXXXI., 5, 6, 7, 9, letter *n*) . 176
Retina (Plate LXXXI., figs. 10, 11, 4, 5, letter *r*) . . 177
Optic Nerve (Plate LXXX., fig. 1, digit 2) 177

Humours of the Eye 177
Aqueous Humour (Plate LXXXI., fig. 5, letters B, P) . . 177
Crystalline Lens (Plate LXXXI., figs. 4, 5, 6, 9, 12, 13, and 14, letter *l*) 177
Tunica Crystalloidea 177
Aqua Morgagni 177
Canal of Petit 178
Vitreous Humour (Plate LXXXI., figs. 12, 4, 5, letter *o*) . 178
Tunica Vitrea 178

Muscles of the Eye 178
Levator Palpebræ Superioris Muscle (Plate LXXIX., figs. 2, 3, 4, letter L, and Plate LXXXI., figs. 15 and 16, letter L) . 178
Attollens Oculi Muscle (Plate LXXIX., fig. 4, Plate LXXX., fig. 1, and Plate LXXXI., fig. 15 and 16, letter A) . . 178
Obliquus Superior Oculi Muscle (Plate LXXIX., figs. 3, 4, and 2, Plate LXXX., fig. 1, and Plate LXXXI., figs. 15 and 16, letter O) 178
Adductor Oculi Muscle (Plate LXXIX., fig. 4, Plate LXXX., figs. 1 and 2, and Plate LXXXI., fig. 16, letter a) . . 179
Abductor Oculi Muscle (Plate LXXIX., fig. 4, Plate LXXX., figs. 1 and 2, and Plate LXXXI., figs. 16, letter *a*) . . 179
Obliquus Inferior Oculi Muscle (Plate LXXIX., fig. 2, letter *i*, and Plate LXXX., fig. 2, letter *o*) 179
Depressor Oculi Muscle (Plate LXXX., fig. 2, letter *d*) . . 179
Musculus Lachrymalis (Plate LXXX., fig. 3, letter l) . . 179

Page

Arteries of the Eye 179
Ophthalmic Artery (Plate LXV., letter *o*, described in p. 139, and Plate LXXXI., figs. 15 and 16, letter *o*) . . . 179
Lacrymal Branch (Plate LXXXI., figs. 15 and 16, dig. 7) 180
Central Artery of Retina (Plate LXXXI., fig. 5, letter *k*) 180
Supra-orbital or Frontal Branch (Plate LXXXI., fig. 15, and Plate XVIII., digits 91) 180
Ciliary Arteries (Plate LXXXI., figs. 16, 1, 8, 10, let. *d*) 180
Muscular Branches 180
Ethmoidal Branch (Plate LXXXI., figs. 15, 16, digit 9) . 180
Palpebral Branches 180
Frontal Branch 181
Nasal Branch 181

Veins of the Eye 181
Frontal Vein (Plate XVIII., letter *z*) 181
Ethmoidal Veins (Plate LXXXI. figs. 15 and 16, lets. *w*) 181
Muscular Veins (Plate LXXXI., figs. 15 and 16, letters *x*) 181
Lacrymal Vein (Plate LXXXI., figs. 15 and 16, letter *y*) 181
Ciliary Veins (Plate LXXXI., figs. 1, 8, 15, and 16, letters *h*) 181
Vena Centralis Retinæ (Plate LXXXI., fig. 5, letter *z*) . 181
Ophthalmic Vein (Plate LXXXI., figs. 15 and 16, letter v) . 181

Nerves of the Eye 181
Pathetic Nerve (Plate LXI., fig. 7, Plates LXIV., LXV., and Plate LXVI., fig. 2, and described in p. 138; Plate LXXIX., fig. 3, digit 4) 181
Trigeminal Nerve (Plate LXI., fig. 7, Plates LXIV., LXV., and described in p. 138; Plate LXXIX, figs. 3 and 4; Plate LXXX., figs. 1 and 2, digit 5) 181
Ophthalmic Branch (Plate LXXIX., figs. 3 and 4, Plate LXXX., fig. 1, digit 5) 181
Frontal Nerve (Plate LXXIX., figs. 3 and 4, Plate LXXX., fig. 1, letter f) 182
Supra-trochlear Twig (Plate LXXIX., fig. 3, Plate LXXX., fig. 1, letter *p*) . . . 182
Lacrymal Nerve (Plate LXXIX., figs. 3, 4, and Plate LXXX., fig. 1, letter *l*) 182
Nasal Nerve (Plate LXXIX., figs. 3, 4, and Plate LXXX., fig. 1, letter *n*) 182
Motor Oculi Nerve (Plate LXI., fig. 7, Plates LXIV., LXV., Plate LXXIX., figs. 3, 4, and Plate LXXX., figs. 1 and 2, digit 3) 182
Lenticular Ganglion (Plate LXXX., fig. 1, letter *g*) . 183
Ciliary Nerves (Plate LXXIX., fig. 4, Plate LXXX., figs. 1, 2, and Plate LXXXI., fig. 8, letter *c*) . 183
Abducens Nerve (Plate LXI., fig. 7, Plates LXIV., LXV., and Plate LXVI., fig. 2, digit 6, also described in p. 138; Plate LXXIX., figs. 3, 4, and Plate LXXX., figs. 1, 2, digit 6) . 183
Optic Nerve (Plate LXI., fig. 7, Plates LXIV., LXV., and Plate LXVI., fig. 5, Plate LXVII., digit 2, and described in p. 137; also in Plate LXXIX., figs. 3 and 4, and Plate LXXX., fig. 1, digit 2) 183
Superior Maxillary Nerve (Plate LXXIX. figs. 3 and 4, and Plate LXXX., fig. 1, digit 2*) 183
Malar Branch (Plate LXXV., fig. 4, letter *c*) . . . 183
Infra-orbitary Branch (Plate LXXV. figs. 4 and 5, Plate XVII., digit 2; and also described in p. 53) . . 184

Page

Posterior Dental Nerve (Plate LXXV., fig. 4, letter *d*) 184
Anterior Dental Nerve (Plate LXXV., fig. 5, let. *a*) 184
Pterygo-palatine Nerve 184
Palatine Nerve (Pl. LXXV., fig. 4, and Pl. LXXVI., fig. 1, letter P) 184
External Palatine Branch (Plate LXXV., fig. 4, letter *p*) 184
Superior Posterior Nasal Nerves (Plate LXXV., figs. 4 and 5) 184
Inferior Posterior Nasal Nerves (Plate LXXV., fig. 5) 184
Pterygoid or Vidian Nerve (Plate LXXVIII., fig. 3, and Plate LXXV., figs. 4 and 5, letter *v*) . . 184
Posterior Superior Nasal Nerves . . . 184

Page

Petrosal Branch (Plate LXXVIII., figs. 3 and 2, and described in p. 171) 184
Intercostal Branch (Plate LXXVIII., fig. 3, letter I) 184

Organ of Touch 185
Epidermis (Plate LXXXII., figs. 1 and 2) 185
Nails (Plate LXXXII., figs. 1 and 2) 185
Corpus Mucosum 185
Cutis Vera (Plate LXXXII., figs. 3 and 4) 185
Cellular Substance (Plate LXXXII., fig. 3) 186
Adipose Substance (Plate LXXXII., fig. 3) 186
Serosity 186
Vasa Subcutanea 186
Hairs 186

CONTENTS

OF

PLATES LXXXVIII., LXXXIX., XC., XCI., XCII., XCIII., XCIV.

	Page
Organs of Mastication and Deglutition	189
Parotid Gland (Plate XVIII., letter s)	189
Submaxillary Gland (Plate XVII., letter *n*)	189
Sublingual Gland (Plate XV., dig. 80)	190
Molar Gland	190
Viscera of the Abdomen	190
Parietes of the Abdomen	190
Peritoneum (Plates IX., X., LXXXIII., and LXXXIV.	190
Regions of the Abdomen	190
Natural Position of the Viscera in the Abdominal Cavity	191
Omentum Minus	192
Omentum Majus (Plate IX., letter h)	192
General Course of the Alimentary Canal	192
Œsophagus (Plates IX., XII., XVI., XXXII., LXX., LXXI., LXXII., LXXIII., LXXIV., LXXXIV., and LXXXV., letter I)	193
Stomach (Plates IX., LXXXIII., LXXXIV., LXXXV., and LXXXVI., fig. 1)	193
Duodenum (Plates IX., XII., LXXXV., and LXXXVI., fig. 2, letter c)	194
Jejunum (Plates XII., LXXXV., fig. 2, and LXXXVIII., fig. 1, letters K)	195
Ileum (Plates XII., LXXXV., fig. 2, and LXXXVII., fig. 1, letter L)	195
Colon (Plates XII., XIII., LXXXIII., LXXXIV., and LXXXVII., letters M, O, P, *z*)	196
Rectum (Plates XIII., XIV., XXII, LXXXIII., and LXXXIV., letter I)	197
Liver (Plates IX., XII., LXXXIII., LXXXIV., LXXXV., and LXXXVI., letter i)	197
Gall-bladder (Plates LXXXV. and LXXXVI., letter e)	199
Spleen (Pls. IX., XII., LXXXIII., LXXXIV., and LXXXV., fig. 2, letter F)	199
Pancreas (Plates XII., LXXXIV., and LXXXV., fig. 2, let. D)	200
Kidney (Plates XIII., LXXXIV., and LXXXVIII. figs. 2, 3, letter Y)	201
Capsula Renalis (Plate LXXXIV., letter *y*)	201
Ureter (Plates XIII., XXII., LXXXIII., LXXXIV., and LXXXVIII., and Plates LXXXIX., XC., XCIII., and XCIV., letter w)	202
Viscera of the Pelvis	202
Urinary Bladder (Plates IX., XIII., XIV., XXII., LXXXIII., LXXXIX., XC., XCIII., and XCIV., letter m)	202
Urethra of the Male (Plate XC., letter U)	204
Prostate Gland (Plates LXXXIX., XC., letter T)	204
Membranous Portion of the Urethra (Plates LXXXIX., XC., letter E)	204
Corpus Spongiosum Urethræ (Plates LXXXIX., XC., letters F, G, K)	205
Corpora Cavernosa (Plates LXXXIX., XC., letters x, x)	205
Scrotum (Plates XXII., XXIII., letter z)	205
Testis (Plate XXIII. letter b, Plate LXXXIX. letter r)	206
Cremaster Muscle (Plate XXII., letter a)	206
Tunica Vaginalis Testis (Plate XXIII., and Plate LXXXIX., letter b)	206
Epididymis (Plate XXIV., and Plate LXXXIX., letter *r*)	206
Vas Deferens (Plate XXIV., digit 1, and Plates LXXXIII. and LXXXIX., letter v)	207
Vesicula Seminalis (Plates XXII., LXXXIII., and LXXXIX., letter u)	207
Spermatic Artery	207
Spermatic Veins	207
Spermatic Plexus of Nerves	207
Descent of the Testis in Fetus	208
Cowper's Glands (Plate LXXXIII., letter N)	208
Muscles of the Perineum in the Male	208
Accelerator Urinæ Muscle (Plate XXII., letter o)	208
Transversus Perinæi Muscle (Plate XXII., letter q)	208
Erector Penis Muscle (Plate XXII., letter p)	209
Sphincter Ani Muscle (Plate XXII., letter r)	209
Levator Ani Muscle (Plate XXII., letter s)	209
Organs of Generation in the Female	209
Mons Veneris (Plates XCI., XCIII., letter A)	210
External Labia (Plates XCI., XCII., XCIII., letters B)	210
Perineum (Plate XCI., letter E)	210
Clitoris (Plates XCI., XCII., XCIII., XCIV., letter G)	210
Præputium Clitoridis (Plates XCI., XCII., XCIII., XCIV., letter H)	210
Crus Clitoridis (Plates XCIII., XCIV., fig. 2, letter g)	211
Nymphæ (Plates XCI., XCIII., XCIV., letters F)	211
Meatus Urinarius (Plates XCI., XCII., XCIII.)	211
Urethra (Plate XCIV., fig. 1, letter U)	211
Hymen (Plate XCI., letter L)	211
Carunculæ Myrtiformes (Plates XCIII., XCIV., letter L)	211
Vagina (Plates XCI., XCIII., XCIV., letter D)	211
Muscles of the Perineum in the Female	212
Sphincter Vaginæ Muscle (Plate XCII., letter N)	212
Erector Clitoridis Muscle (Plate XCII., letter P)	212
Transversus Perinæi Muscle (Plate XCII., letter q)	212
Transversus Perinæi alter Muscle (Plate XCII., letter q*)	212
Sphincter Ani Muscle (Plate XCII., letter r)	212
Levator Ani Muscle (Plate XCII., letter s)	212
Uterus (Plates IX., XIII. XIV., XCIII., XCIV., letter k)	212
Course of the Peritoneum in the Pelvic Region of the Female	212
Broad Ligaments of the Uterus (Plates XCIII., XCIV., lets. *k*)	213
Round Ligaments (Plates XCIII., XCIV., letter *l*)	213
Structure of the Uterus	213
Fallopian Tubes (Plates XCIII., XCIV., letters *k**)	214
Ovarium (Plates XIII., XCIII., XCIV., letter N)	214

CONTENTS

OF

PLATES XCV., XCVI., XCVII., XCVIII., XCIX., C., CI.

	Page
Description of the Gravid Uterus	215
Contents of the Gravid Uterus (Plate XCVI.)	215
Membrana Decidua (Plate XCVI. and Plate XCVII., figs. 1 and 9, letter *f*)	215
Chorion (Plate XCVI. and Plate XCVII., figs. 1, 2, 3, 4, 7, 8, 9, letter *d*)	215
Amnion (Plate XCVI. and Plate XCVII., figs. 1, 2, 4, 9, letter *c*)	215
Liquor Amnii	215
Placenta (Plate XCVI. and Plate XCVII., figs. 1, 9, letters *p*)	216
Umbilical Cord (Plate XCVI. and Plate XCVII., fig. 1, letters g, *n*, *n*)	216
Situation of the Fetus in the Uterus (Plate XCVI.)	217
Peculiarities of the Fetus	217
Lymphatic System	218
Lymphatics of the Stomach	218
Lymphatic Glands of the Stomach	218
Lymphatics of the Small Intestines (Plate XCVIII., digits 12)	218
Mesenteric Lymphatic Glands (Plate XCVIII., digits 3)	218
Lymphatics of the Large Intestines (Plate XCVIII., digits 13)	218
Mesocolic Lymphatic Glands (Plate XCVIII., digits 2)	218
Lymphatics of the Liver (Plate XCVIII., digits 14)	219
Lymphatic Glands of the Liver	219
Lymphatics of the Spleen	219
Lymphatics of the Pancreas	219
Thoracic Duct (Plate LXXXIV. and Plate XCVIII., digit 1)	219
Lymphatics of the Pleura	219
Intercostal Lymphatics (Plate XCVIII., digits 4)	220
Lymphatics of the Lungs (Plate XCIX., fig. 1, digits 18)	220
Bronchial Glands (Plate XCIX., fig. 1, letters b)	220
Lymphatics of the Pericardium	220
Lymphatics of the Heart (Plate XCVIII., digits 20)	220
Lymphatics of the Upper Extremity (Plate XCIX., figs. 1 and 2, digits 21)	220
Superficial Lymphatics of the Thorax	220
Superficial Lymphatics of the Back	221
Lymphatic Glands at Elbow-Joint (Plate XCIX., fig. 1, digs. 2)	221
Brachial Lymphatic Glands (Plate XCIX., fig. 1, digits 22)	221
Axillary Lymphatic Glands (Plate XCIX., fig. 1, digits 3)	221
Lymphatics of the Head and Neck (Plate C.)	221
Superficial Facial Lymphatics (Plate C., digits 23)	221
Superficial Temporal Lymphatics (Plate C., digits 24)	221
Superficial Occipital Lymphatics (Plate C., digits 26)	221
Deep-seated Lymphatics of the Face	221
Deep-seated Lymphatics of the Cranium	221
Superficial Lymphatics of the Neck (Plate C.)	221
Deep-seated Lymphatics of the Neck (Plate XCIX., fig. 1)	221
Lymphatic Glands on the Buccinator Muscle (Plate C., digs. 25)	221
Lymphatic Glands on the Zygoma (Plate C., digits 8)	221
Lymphatic Glands at the Base of the Inferior Maxillary Bone (Plate C., digits 7)	221
Superficial Cervical Glands (Plate C., digits 9 and 10)	221
Superior deep-seated Cervical Glands (Plate XCIX., fig. 1, digits 6)	221
Inferior deep-seated Cervical Glands (Plate XCIX., fig. 1, and Plate C., digits 4)	221
Lymphatics of the Lower Extremities	221
Superficial Lymphatics (Plate CI., figs. 1 and 2, digits 27)	221
Deep-seated Lymphatics	222
Anterior Tibial Lymphatic Gland	222
Popliteal Lymphatic Glands	222
Superior Superficial Inguinal Lymphatic Glands (Plate CI., fig. 1, digits 17)	222
Inferior Superficial Inguinal Lymphatic Glands (Plate CI., fig. 1, letters *a*)	222
Deep-seated Inguinal Lymphatic Glands (Plate XCVIII., digits 15)	222
External Iliac Lymphatic Glands (Plate XCVIII., digits 16	222
Superficial Lymphatics of Abdomen (Plate XCVIII., digits 28)	222
Superficial Lymphatics of the Penis (Plate XCVIII. and Plate CI., fig. 1, digits 32)	222
Superficial Lymphatics of the Scrotum (Plate CI., digits 33)	222
Superficial Lymphatics of the Clitoris and External Labia	222
Deep-seated Lymphatics of the Clitoris and External Labia	222
Deep-seated Lymphatics of the Penis and Scrotum	222
Deep-seated Lymphatics of the Vagina	222
Lymphatics of the Pelvis	222
Lymphatics of the Urinary Bladder	222
Lymphatics of the Prostate Gland and Vesiculæ Seminales	222
Lymphatics of the Vagina and Uterus	222
Lymphatics of the Ureters	222
Hypogastric Lymphatic Glands (Plate XCVIII., digits 17)	222
Sacral Lymphatic Glands	222
Lymphatics of the Testis (Plate XCVIII. and Plate CI., fig. 1, digits 34)	222
Lumbar Glands	222
Lymphatics of the Kidney	223
Lymphatics of the Supra-renal Glands	223
Lymphatics of the Peritoneum and Muscles of the Abdomen	223
Union of the Lymphatics of the Lower Extremities with those of the Intestines to form Thoracic Duct	223
Structure of a Lymphatic Vessel	223
Structure of a Lymphatic Gland	223
Physiological and Pathological Observations	224

ANATOMICAL PLATES.

THE BONES.

INTRODUCTORY REMARKS.

The bones are the hardest and most solid organs of the system; they form the trunk round which the other organs are disposed, afford the necessary support to the rest of the body, and determine its size, proportion, form, and attitude. They are constructed of an osseous shell, with cancelli projecting inwards; a configuration which, independently of rendering them lighter, confers on them a greater degree of strength: they are the levers which, when articulated together, enable us by the aid of muscles to travel to any distance, and to perform all the functions where motion is required.

In the different classes of animals, and even in those which constitute the same class, the bones vary considerably. In the mammalia, great diversity is found: in man, for example, at an intermediate period of time, they acquire a sufficient degree of hardness, become perfected, and limit his growth; the lamellæ are thin and closely applied to each other, and the cellular texture is exceedingly delicate and filled with medullary pouches. In quadrupeds, the bones arrive at perfection in a shorter period of time, and the cellular structure is coarser than in man. In the cetaceous animals, the bones are exceedingly long in attaining perfection, and their structure is still coarser than in quadrupeds; the large exterior fibres can be easily separated by maceration, and there are no large medullary cavities even in their long bones.

In the cartilaginous fishes, among which are the rays and sturgeons, the bones never become ossified; indeed, the bones of ordinary fishes, reptiles, and serpents, although they are ossified, still preserve greater flexibility than those in other animals; and the cartilaginous proportion greatly exceeds that in animals with red blood; hence, in consequence of this peculiarity of structure, they continue to grow almost throughout life. In birds, the lamellæ are thin, firm, somewhat elastic, and appear like layers glued upon each other; their bones are hollow, having the cavities filled with air, by means of a direct communication with their organs of respiration; and hence their extraordinary buoyancy. These are all the classes of animals which possess an internal skeleton surrounded by muscles; the others have merely a shell, within which are contained the soft parts, as the testaceæ; or they have their bodies and members enveloped in scales articulated upon one another, as insects; or they are destitute of any hard structure whatever, as the soft worms.

The constituent principles of bone are, gelatin, cartilage, and phosphate of lime; the gelatin and cartilage constitute the animal property, the phosphate of lime the earthy property.*

The bones in the living state are invested with a vascular membrane named the periosteum.

PLATE I.

BONES OF THE SKELETON.

The bones which compose the skeleton are divided into those of the trunk, letters *a*, those of the head, letters *b*, those of the upper extremity, letters *c*, and those of the lower extremity, letters *d*.

This Plate is introduced chiefly as a diagram explanatory to the other Plates, and to represent the bones in connexion. It is copied from Albinus. If the bones of the head, pelvis, or any other part of the skeleton, are to be examined, the reader must turn to the Plates which illustrate these particular portions.

PLATE II.

BONES OF THE TRUNK,

Represents the bones of the trunk in connexion, with individual figures of the vertebræ and ribs. There are also attached to the trunk, the bones of the shoulder, *p*, *k*. The representation of the trunk is taken from Sue; the separate bones are drawn from nature. The trunk consists of the bones which compose the spine, the thorax, and the pelvis.

Fig. 1.—The letters *a* and *g g* point out the spinal column; from the bone where the upper letter *a* is, to the

* For further information respecting the chemical constituents of bone, consult Turner's Chemistry.

bone where the lower letter *a* is placed, are comprehended the true vertebræ. The letters *g* are placed on the false vertebræ of the column, or what is more generally named, in the adult, the os sacrum.

The os coccygis, the remaining portion of the column, and of the false vertebræ, is not in this view, but is seen in Plate III., Figs. 1, 2, 3, 4, letters *b*.

The true vertebræ are afterwards subdivided into those of the neck, or cervical, which are easily distinguished in the drawing by counting seven from the top, and terminate where the ribs commence; into those of the back, or dorsal, which are twelve in number, and are known by the ribs being attached to them; and into those of the loins, or lumbar, which are five in number, and are ascertained by counting five from the ribs to the false vertebræ or os sacrum. The false vertebræ will be described along with the other bones of the pelvis.

Each vertebra consists of a body, Fig. 2, *a*, and of a ring *b*, *b*, which will be better understood in Figs. 5, 6, and 3, where complete circles are observed, and where the same letter is applied. From this ring arise seven processes, four of which are for articulation, and are named articular or oblique, letters *c*; and three for muscular attachment, or to give origin and insertion to muscles, two of which are denominated transverse, viz. that marked *d*, with the corresponding one of the opposite side, and the third is termed spinous, *e*, from which the whole chain of bones has derived its name. These processes are seen in the other vertebræ, Figs. 4, 3, 6, 5, where some are more distinctly marked, and where the same letters are placed on the same processes. Where the letter *b* is placed, there is a notch formed by this part of the ring, and which, with the contiguous vertebra, forms a hole that gives transmission to one of the nerves arising from the spinal marrow. In Fig. 1, several of the foramina formed by these notches are seen in the neck and loins, and are also marked *b*. There are twenty-four holes on each side, formed by the true vertebræ, to afford a passage to the spinal nerves. Fig. 2 is a lumbar vertebra, and is known by its answering this general description, and having no marked peculiarities.

In the fetus at birth each vertebra consists of the body not fully ossified, and the ring divided into two parts, which are united to each other by cartilage; the junction of the two latter forming the spinous process: the articular processes are complete, but the transverse have only begun to be formed. In some malformations, there is a deficiency of one or more of the rudiments of the spinous processes; generally of the lumbar, sometimes of the sacral, but very rarely of the dorsal vertebræ; a tumor containing a clear fluid, analogous to that found in hydrocephalus, occupies the place of the spinous processes, and the disease is named spina bifida, or hydrorachitis.

Fig. 3 is a representation of the inferior or sacral aspect of a cervical vertebra, and is distinguished from the others by having a foramen, *f*, in each transverse process, which transmits the vertebral artery and vein. The same letter is applied in Fig. 1. There are other peculiarities in this as well as in the other classes of vertebræ, but these it is unnecessary to notice here, as they are seen in the drawings. The inferior view has been chosen, as it shows the foramina more distinctly.

Fig. 4 is a dorsal vertebra, and is distinguished by having one or two depressions, *g*, *g*, on the sides of its body for articulation with the heads of the ribs. These depressions vary; thus, the first dorsal vertebra has a depression which receives the whole head of the first rib, and another depression which assists to form a cavity for the head of the second rib; the eleventh vertebra has often the whole cavity for the eleventh rib; and the twelfth always receives the whole head of the last rib. The others, as will be seen from the drawing, contribute, each to receive the heads of two ribs. Excepting the eleventh and twelfth, the dorsal vertebræ have depressions, *h*, on their transverse processes, to which are articulated the tubercles of the ribs.

Fig. 5 is a representation of the first cervical vertebra or atlas, which differs from the others in having little or no body, and little or no spinous process, but a much larger ring. This is filled up in the fresh subject so as to correspond with the rest of the canal by the processus dentatus, *n*, of the second vertebra, Fig. 6. The letter *k* of Fig. 5, points to the smooth surface on which the processus dentatus revolves, and *i* points to the two small projections which give attachment to the transverse ligament that confines this process: the letter *i*, with the two lines, shows the direction of the ligament. Between these projections and the smooth surface, *k*, is a rough sinuosity, *m*, *m*, giving attachment to the lateral ligaments, which extend between these points and the sides of the processus dentatus, and which are also connected to the margin of the foramen magnum of the occipital bone. The letters *f* show the foramina in the transverse processes with the tortuous canals which are continuous: this circuitous course prevents the vertebral artery from throwing its blood with too much impetuosity into the brain, as well as guards against the too rapid descent of the blood by the vein, or the vessels being injured in the motions of the head and neck. The superior articular processes, *c*, *c*, are large oblong concavities fitted to receive the condyles of the occipital bone; and on these surfaces the nodding motions, or flexion and extension, are performed. In the fetal state, this vertebra also differs from the others; the circle is divided into two lateral pieces, and the part where the dentata revolves, and the spinous process, are both cartilaginous.

Fig. 6 is the second cervical vertebra, named vertebra dentata. The letters denoting the processes and foramina common to the other cervical vertebræ, and to the vertebræ in general, remain the same in this drawing; *n*, indicating the processus dentatus from which the vertebra has derived its name. From the tip of this process extends the perpendicular ligament to be attached to the anterior margin of the foramen magnum of the occipital bone; from its sides the lateral ligaments extend to the atlas and occipital bone; and the transverse ligament of the atlas, which confines this process, forms a smooth surface on it posteriorly, while a corresponding one is formed anteriorly where it plays on the smooth surface of the body of the atlas. The superior articular processes, *c*, *c*, are large, oblong, slightly convex, and nearly horizontal, corresponding to the inferior of those of the atlas. From the foramina, *f*, *f*, are seen slight tortuous depressions made by the vertebral arteries and veins. In the fetus this vertebra consists of four pieces; the body and lateral pieces are the same as in the other vertebræ, but the processus dentatus is ossified in the centre, and joined by cartilage to the body like the lateral portions.

The vertebræ are connected to each other by fibro-cartilage and ligaments. The intervertebral cartilage is seen in Fig. 1, letters *o*, the letters pointing merely to that inter-

posed in the lumbar region, as it is here better defined: this substance is nevertheless found between all the dorsal and cervical vertebræ; excepting between the atlas and dentata, where it is always deficient. The corresponding articular processes of every two contiguous vertebræ are enveloped in a membranous ligament, named capsular or synovial; and as a joint is thus established, each articular process is tipped or covered with cartilage, styled perichondrium. A strong ligament, termed the common anterior, extends from the atlas to the os sacrum, on the anterior or sternal surface of the bodies; and beneath this, nearly equally strong ligaments, named crucial or intervertebral, bind the margin of the one vertebra to that of the other. A ligament, denominated the common posterior, extends in a similar manner to the common anterior ligament, from the atlas to the os sacrum, behind the bodies of the vertebræ, or within the rings; and within this canal other strong ligaments are found, which connect the posterior arches of the vertebræ, and are named subflava. The vertebræ are also connected by strong ligaments passing between their transverse processes, termed intertransverse, and between their spinous processes, named interspinous ligaments. The vertebræ, by this junction through the medium of cartilage and ligaments, form a long canal which lodges the spinal cord. Those portions of the vertebræ which are not covered by cartilage, or ligament, are covered by the membrane common to all the bones, named the periosteum.

This strong bond of union, through the medium of cartilage and ligaments, between the vertebræ, limits their motion; although at the same time they admit of flexion forwards, backwards, and to either side, with a slight rotatory motion. These movements vary in the different classes of vertebræ; thus flexion forwards is performed to the greatest extent by the cervical, next in degree by the lumbar, and, least of all, by the dorsal vertebræ. Flexions backwards and laterally take place in the same ratio. The rotatory motion is most evident in the lumbar region, next in degree in the cervical, and least of all in the dorsal; which motion, denied by some, is very evident in vaulters, in the Indian jugglers, and in some of the natives of Africa, who, in dancing to the guitar or strum-strum, exhibit the most fantastic figures. This rotatory motion is freely performed between the atlas and dentata; which, strictly speaking, is the only true distinct rotatory motion. In these motions, the intervertebral substance is a little compressed on the one, and elongated on the other side.

When the vertebræ are thus united, we observe several undulations or curvatures which tend to increase the strength and add to the grace of the column; and are apparently designed to support the head, the upper extremities, and the viscera. These curvatures of the spine are most remarkable in Europeans; for in the negro, there is no curvature of the loins; and in the lower animals, the curvatures of the spine differ more and more according to their gait.

As the vertebræ are, if we may use the expression, firmly locked together by their articular processes, by the intervertebral cartilage, by their strong ligaments, and by numerous muscles, they are seldom dislocated. From their motions, the cervical vertebræ are more frequently dislocated than either of the other two; and the lumbar are next in liability to this accident.* The dorsal have never been dislocated, nor has the atlas been separated from the occipital bone but by gradual disease.*

This intimate union of the vertebræ renders them much more liable to be fractured; and from their structure, as seen in Plate IV., Fig. 7, the fracture is transverse; in which circumstance they resemble soft wood, and soft minerals as lime or marle. When inflammation attacks them, it terminates either in resolution or caries; and when one is affected, the disease soon spreads to the contiguous vertebræ. Owing to their peculiar structure, they cannot exfoliate; neither can their vessels form an osseous shell, so as to constitute necrosis ossificans. They are particularly liable to caries, and in this they bear a close analogy to the soft parts. From the waving column formed by the vertebræ, and from the powerful muscles connected with them, the spine is peculiarly liable to distortion in feeble or scrofulous constitutions; and the open spongy structure of the bodies of the vertebræ enables absorption to go on rapidly in this affection.

The dorsal or thoracic vertebræ with the ribs, letters *c*, and sternum, letters *e*, constitute the osseous parietes of the thoracic cavity in which the chief vital organs are contained, viz. the heart and lungs.

The ribs are long curved bones, Fig. 1, letters *c*, situated on each side of the dorsal vertebræ, and extending in an arched form towards the sternum, or breast bone, *e*, to which they are attached through the medium of cartilages, letters *d*. They are divided into true and false: the first seven, which are attached to the sternum by individual cartilages, are the true ribs; the remaining five are false ribs, the three first of which are attached by their cartilages to each other and to the seventh rib; the two last are supported by the abdominal muscles, and are named floating ribs.

Fig. 7 is a representation of a true rib, being the seventh. We here observe the surface which looks towards the thoracic cavity, the osseous structure of which is formed by the ribs laterally, the dorsal vertebræ posteriorly, and the sternum anteriorly; we also perceive the two edges of a rib, the superior or atlantal *x*, and the inferior or sacral *a*, to which are attached the intercostal muscles; the letter *a*, however, points to a more important part, the groove made by the intercostal nerve, artery, and vein (objects to be kept in view by the operator in performing paracentesis thoracis): the body or centre of the rib only being grooved. The letter *b* indicates the head of the rib, but only one surface is seen where it is articulated to one of the two contiguous vertebræ; the other surface being easily understood from the wedge-like shape of the head, which forces itself into the intervening cartilage; and this, like all articular surfaces, is tipped with cartilage, and surrounded with a synovial capsule. The letter *c* points out the smooth surface, by which the rib is articulated to the transverse process of the lower of the two contiguous dorsal vertebræ; and the case is the same here as at the head of the rib, and with all other articulations: *d* is the tubercle of the rib, which is sometimes considered along with the smooth surface *c*; *e*, a small depression where mucilaginous glands are lodged; *f*, the angle of the rib; and *g*, the hollow spongy end which receives the cartilage, and which forms so firm a coalition as not to admit of any motion like a joint. The

* See Part IX.

* Petit, Louis, Boyer, and C. Bell have recorded instances of the dislocation of the atlas from the dentata; but the accident has almost immediately proved fatal.

ribs are nearly completed at birth: the heads and tubercles have only larger cartilages on them, while the cartilages which connect them to the sternum are a little longer. These bones protect the heart and lungs, organs essential to life, and have been consequently completed by the great Author of Nature to preserve us from perishing at birth.

Fig. 8 represents the first rib, which differs from the seventh and the generality of the other ribs, by its surfaces looking upwards and downwards, or atlantad and sacrad, and by its edges outwards and inwards, or peripherad and centrad. This rib is therefore horizontal; and has on its upper surface a peculiar tubercle, *h*, which gives attachment to the scalenus primus or anticus muscle, near which is a slight grooved depression, *i*, made by the subclavian artery as the vessel passes out of the thorax. This tubercle should be carefully attended to by the operator, for by means of this and the other directions given in Part III., the taking up the subclavian artery is rendered one of the simplest operations of surgery. The letter *k* points to the head of this rib, which differs from the others by being round, as it is attached only to the first dorsal vertebra. The cartilage of this rib is generally ossified in adults.

The ribs are articulated by their heads to the sides of the bodies of every two contiguous vertebræ, excepting the first and last, the former of which I have already taken notice of; the latter is attached only to the body of the twelfth dorsal vertebra. They are also articulated by the smooth surfaces of the tubercles to the transverse processes of the lower of the two vertebræ, excepting the first, which is articulated to the first dorsal vertebra, both at its body and transverse process; also, excepting the eleventh and twelfth, and sometimes the tenth, which have no depression for articulation to the transverse processes of the vertebræ. The ribs are joined anteriorly to their cartilages, which are articulated to the sternum.

On viewing the ribs, we observe that the first is the most curved, but that they increase in their obliquity to the spine on their descent, so that their cartilages make a greater and greater curve in their progress to the sternum. They also increase in length from the first to the seventh; and from that to the twelfth they gradually diminish.

The ribs are so strongly articulated to the bodies and transverse processes of the vertebræ, and supported by so many muscles, particularly short ones, that they are scarcely ever displaced at this extremity; their elasticity also tends to prevent dislocation either at this end or at their sternal extremity; this, however, sometimes occurs, although they are much more liable to be fractured; and, from their structure being analogous to the section of the thigh bone, delineated in Plate IV., Fig. 10, its direction will depend on the part of the rib which sustains the injury: for the extremes resemble the bodies of the vertebræ, and hence the fracture at either of these is transverse; while the body or centre of the bone being dense like that of the thigh bone, its fracture is oblique and splintery; in which latter they resemble hard wood, and hard and compact minerals. The splintering fracture of the ribs frequently gives rise to fatal symptoms, and should therefore be well considered by the practitioner.

When inflammation attacks the ribs, the disease terminates either in resolution or in caries; and when either of the extremes, particularly the sternal, is the seat of inflammation, caries is the general termination, and this is often accompanied by carious ulcer of the sternum. The centre of the bone is so dense that it seldom ulcerates; and there is no instance recorded of the ribs undergoing necrosis ossificans, although their structure resembles the bones subject to this disease. In scrofulous constitutions, the cartilages are easily distorted, and soon involve the sternal extremities. The ribs are subject to exostosis.

The sternum or breast bone, letters *e*, Fig. 1, is situated in the anterior part of the trunk, or more correctly, the thorax: and is in a manner wedged between the cartilages of the ribs. The sternum is a long flat bone, slightly convex outwardly, and concave, particularly its upper extremity, inwardly, or where the bone looks towards the thoracic cavity; and consists of three portions, on which the letters *e* are placed: the upper, or atlantal, is of a heart-shape, supports the clavicles, *p*, *p*, and receives the whole of the first and the half of the second rib; and at each of these points there are corresponding depressions; those for the clavicles are the largest, and, in the fresh subject, interarticular cartilages are here interposed. The second, or middle portion of the sternum, receives the remaining half of the sternal extremity of the second rib, the whole of the third, the fourth, fifth, and sixth ribs, and the half of the sternal extremity of the seventh rib The third, or inferior, or sacral portion is generally named cartilago ensiformis, or xiphoides, from its continuing long cartilaginous; this receives the remaining half of the seventh rib. In the fetus, the sternum generally consists of four small round bones surrounded with cartilage; but these vary in number. The sternum is one of the best specimens of the formation of bone.

The sternum, from its attachments, is seldom if ever dislocated; accidents commonly either produce fracture, or cause inflammation; and as this bone has the same structure as the body of a vertebra, Fig. 7, Plate IV., the fracture is transverse. For the same reasons, when inflammation attacks this bone, the disease terminates generally in caries; a frequent occurrence in the scrofulous. This bone is subject to exostosis, particularly the syphilitic. In consequence of remaining long cartilaginous, the sternum is easily distorted in the rickety.

In Fig. 1, *g*, *g*, point out the os sacrum or part of the false vertebræ, and the letters *h* the ossa innominata, which, with the os coccygis, constitute the bones of the pelvis.

PLATE III.

BONES OF THE PELVIS.

In this Plate we have representations of the female and male pelvis, and of that of the fetus. Fig. 1 is the female, Fig. 2 the male, and Fig. 3 the fetal. The same letters apply to Figs. 1, 2, and 3.

The pelvis is composed of the os sacrum, *a*, *a*, the os coccygis, letters *b*, and the ossa innominata, letters *h*.

The os sacrum consists of a body, *a*, *a*, which, in Fig. 3, is better defined, as the bone in the fetus consists of five distinct vertebræ; and four transverse lines are seen in the two adult pelves, where the cartilage existed in the early state. The letter Y, Figs. 1 and 2, is named the promontory, which, with the white line, *y*, *y*, *y*, *y*, **y**, **y**, extending around the pelvis, forms the brim or inlet of the pelvis. The rings, which are seen posteriorly, or dorsad, are ossified together so as to form the termination of the canal for the spinal marrow, here named cauda equina; and the letters *l*, Fig. 1, Plate VIII., indicate the begin-

ning and end of this tube, formed by the sacrum. The os sacrum consists also of articular processes, *c*, *c*, which are connected to the two inferior articular processes of the last lumbar vertebra; the other articular processes are soldered together so as to form an irregular indistinct ridge, or a series of tubercles on the posterior or dorsal aspect of the bone seen in Plate VIII., Fig. 1, letters *c*. The sacrum has also transverse processes which are likewise soldered together: the three upper form an oblong process, *d*, *d*, Fig. 1, Plate VIII., which is divided by a long perpendicular ridge into two irregular depressions; the anterior or pubic is smoother, tipped with cartilage in the fresh state, and articulated to a corresponding surface of the os ilium; and this junction is styled the sacro-iliac synchondrosis. The manner of articulation is seen in Plate III., Figs. 1, 2, and 3, at *f*, *f*. The posterior or dorsal depression gives attachment to strong ligamentous bands, which pass between the sacrum and os ilium. The two lower transverse processes, *g*, *g*, Fig. 1, Plate VIII., form a tubercle and oblong flat surface, to which are attached the two sacro-sciatic ligaments. The spinous processes are more distinct, and form nearly a continuous ridge, as seen in Plate VIII., Fig. 1, letters *e*. The two superior letters *n*, Fig. 1, Plate VIII., and Figs. 1, 2, and 3, Plate III., point out the notch which, with the last lumbar vertebra, forms a foramen, as seen in Plate II., Fig. 1; and the same letters mark the foramina in the sacrum corresponding to this, which transmit the large sacral nerves that supply the lower extremities. Similar foramina are seen on the posterior or dorsal aspect in Plate VIII., Fig. 1, letters *n*, which give exit to much smaller nerves. The letters *z*, Fig. 2, Plate III., show the origin of the pyriformis muscle of one side.

The os sacrum is articulated superiorly, or atlantad, by its body, to the inferior surface of the body of the last lumbar vertebra, by intervertebral fibro-cartilage; and, by its proper articular processes, to the two inferior articular processes of the same vertebra by synovial capsules. Laterally, this bone is joined by the anterior smooth oblong process, *d*, *d*, placed on the left side of Fig. 1, Plate VIII., to a corresponding surface of the os innominatum, or os ilium, as seen in Plate III., Figs. 1, 2, and 3, letters *f*. This is covered with fibro-cartilage in the fresh state, and is named the sacro-iliac synchondrosis. The letters *d*, on the right side of Fig. 1, Plate VIII., show the posterior rugged surface where this junction is strengthened by ligaments passing between the sacrum and os ilium posteriorly. In some aged subjects, this junction is ossified, and, in this state, constitutes anchylosis. The sacrum is articulated inferiorly, by fibro-cartilage and ligaments, to the body of the os coccygis; and this articulation, which is seen in Plate III. Figs. 1, 2, and 3, at the lower *a*, becomes also, in advanced life, very frequently anchylosed.

The sacrum, we have already observed, lodges the termination of the spinal cord named cauda equina, and transmits through its foramina the nerves which form this leash: it serves also as the common base and support of the trunk of the body, forming the greater portion of the lower pyramid. The back or dorsal portion of the pelvis, which is enlarged by its curved shape, thus giving support to the viscera in this cavity, is likewise formed by this bone; and its rugged, convex, posterior aspect, affords strong origin to the several muscles which move the trunk and thigh. The upper attachment of this bone to the last lumbar vertebra admits of motion analogous to the other vertebræ, and is therefore seldom or ever dislocated; its attachment laterally to the os innominatum admits only of a limited yielding motion or elastic spring, and is also seldom luxated; the few cases on record show that when this accident did occur, it generally proved fatal. However, from the examination of a number of female subjects who died immediately after childbirth, I have observed a relaxation of the sacro-iliac junction amounting in some to partial displacement, so that I am inclined to give credit to the statements of the older anatomists, Vesalius, Riolanus, Bauhinus, Diemerbroek, Harvey, Spigelius, and Ruysch. Dr Blundell has noticed this relaxation. The articulation with the os coccygis is sometimes dislocated in parturition.

The sacrum, in its structure, corresponds with the vertebræ, but is fully more spongy and lighter; and, when injured, its fracture is usually transverse; but the injury requisite to effect this is so severe, that it is generally followed by a fatal event. This bone is subject to the same diseases as the other vertebræ; and frequently becomes carious from long confinement to bed.

The os coccygis, letters *b*, Figs. 1, 2, and 3, forms the termination of the spinal column, is the apex of the lower pyramid, and consists of four small pieces, as seen in Fig. 4, marked with the letters *b*; the two latter being generally united into one. In old people all the pieces become anchylosed, and frequently even the junction with the os sacrum anchyloses, so as to form one continued bone; while, on the contrary, in the fetus, they are nearly all cartilaginous. The upper, or first bone, as well as the others, has a body analogous to that of the other vertebræ, the letter *b* being placed on this part in Fig. 4, which has a similar surface, *a*, to the other vertebræ, and is covered with cartilage in the fresh state, and articulated to the lower point, *a*, of Fig. 1, Plate VIII. This portion has projections, *c*, *c*, analogous to the articular processes, which are frequently joined, either by cartilage or bone, to the lowest corresponding articular processes, *c*, *c*, of the os sacrum, Fig. 1, Plate VIII.; and through the apertures, or under the arches thus formed, the twenty-ninth pair of spinal nerves pass out. This piece has likewise two lateral projections, *d*, *d*, named shoulders, analogous to the transverse processes; and at the root of each of these is a small notch, *n*, *n*, where the last pair of spinal nerves emerge. The distal or lower end is convex, and is received into a corresponding depression of the second bone, which resembles the same surface of the first bone; and here, as between the others, an intervertebral cartilage exists. This and the other pieces are similarly formed, and evidently admit of motion on each other, and the first on the sacrum. Though well strengthened by ligamentous covering and muscles, they are sometimes dislocated backwards in parturition; and in the case of a parturient female advanced in years, this bone is sometimes fractured; which shows the necessity of the accoucheur supporting the perineum properly in this process of nature. The os coccygis is also sometimes dislocated towards the pelvis by a blow or fall, and is subject to the same diseases as the os sacrum. Boyer describes this bone fractured in advanced life by a fall on the nates.

The os coccygis contributes to form what is named the outlet of the pelvis, supports the rectum and other pelvic viscera, and yields in the expulsion of the feces, and in parturition.

The ossa innominata, *h*, *h*, **h**, **h**, H, H, Figs. 1, 2, 3, Plate III., constitute the rest of the pelvis, and form the

lateral and anterior parietes of the cavity, as also the inferior and lateral walls of the abdomen. Each os innominatum, as seen in Fig. 2, Plate VIII., is divided into the os ilium, *h, h,* Figs. 1, 2, and 3, of Plate III.; into the os pubis, ꝑ, ꝑ, of the same figures and same plate; and into the os ischium, H, H, of the same plate. The division, only seen distinctly in the fetal pelvis, Fig. 3, takes place at the cavity named acetabulum, *r, r.*

The os ilium, which forms the upper portion of the bone, is concave where the letters *h, h,* in Figs. 1 and 2, Plate III., are placed. This is named the venter of the bone, and is covered by the iliacus internus muscle in the fresh state, to which it affords origin or attachment, contributing also from its shape to support the abdominal viscera. Superiorly this flat and slightly concave surface terminates in a semicircular edge, s, s, Figs. 1, 2, 3, Plate III., also Fig. 2, Plate VIII., which is named the crista ilii, is tipped with cartilage in the fresh state, and gives attachment to the three lateral muscles of the abdomen, to some of the muscles of the back, and to part of the gluteus maximus and medius muscles. This crista terminates anteriorly and posteriorly in a small projection, denominated spinous process; *s,* of Figs. 1, 2, 3, of Plate III., and of Fig. 2, Plate VIII., indicates the anterior superior that gives origin to the sartorius muscle; while *f,* Fig. 2, Plate VIII., indicates the posterior superior spinous process which gives origin to muscles of the back, and to strong ligaments proceeding to the transverse processes of the two lower lumbar vertebræ. Proceeding downwards from the anterior superior spinous process, the bone is a little concave, and then terminates in a similar protuberance, *t,* Figs. 1 and 2, Plate III., and Fig. 2, Plate VIII., named the inferior anterior spinous process: from this arises the rectus muscle of the thigh. The concavity between these two processes is occupied partly by this muscle, and partly by the sartorius. A corresponding process, styled the posterior inferior spinous, is seen in Plate VIII., Fig. 2, letter *v.*

On the inside of the anterior inferior spinous process is a gentle depression or groove, *x,* Figs. 1 and 2, Plate III., made by the iliacus internus muscle, and the psoas magnus muscle, in their passage out of the abdomen to the thigh bone. The anterior crural nerve, artery, and vein, which rest upon these muscles, emerge along with them.* Towards the interior or centre of this depression, and venter of the ilium, there is a ridge, *y, y,* of Figs. 1 and 2, Plate III., continuous with one of the pubis ꝑ, and also with one of the sacrum, Y, which is termed the brim or inlet of the pelvis; that of the ilium and pubis is styled the linea-ileo-pectinea; and into the iliac portion the tendon of the psoas parvus is inserted.

On the dorsal aspect, named the dorsum of the bone, which is seen in Plate VIII., Fig. 2, there are several ridges and depressions made by the three glutei muscles; the letters *a,* near the posterior superior spinous process, mark the surface occupied by the gluteus maximus; the letters *b,* the surface which gives origin to the medius; and the letters *c,* that which gives attachment to the minimus: thus a short ridge is formed between the surfaces occupied by the maximus and medius; a long ridge between the medius and minimus, which extends from the anterior superior spinous process to the great sacro-ischiadic notch; and a third is formed by the action of the minimus, which stretches from the inferior anterior spinous process to the same notch. The surface *e, e, e,* gives attachment to the fibrous capsule of the hip joint. The letter *d* points out the spot occupied by the tensor vaginæ femoris, so that the sartorius, the tensor, and gluteus medius muscles, are on the same level. Parallel to the posterior or sacral margin of the gluteus medius, arise some of the fibres of the pyriformis muscle, which is marked *z,* to show that it is the same object which arose also within the pelvis, from the os sacrum, between the anterior foramina, as seen in Plate III., Fig. 2. A number of small foramina are seen on the dorsum of the bone which transmit nutritious vessels; and a conspicuous one is generally found on the venter near the linea-ileo-pectinea.

The os ilium has a smooth surface tipped with fibro-cartilage, which corresponds to that marked *d, d,* on the left side of the os sacrum, Fig. 1, Plate VIII., by which it is joined to this bone, as represented in Plate III., Figs. 1 and 2, *f, f,* named sacro-iliac-synchondrosis; and there are corresponding inequalities to those of the os sacrum, where the ligamentous bands are attached. The os ilium is joined also to the os pubis and os ischium, at the acetabulum, by cartilage in the fetus, as represented in Plate III., Fig. 3, letters *r, o;* and this cartilaginous bond of union becomes completely ossified in the adult, so as to form one bone, as seen in Plate VIII., Fig. 2. The proportion of the acetabulum which the os ilium forms, is a little less than two-fifths, as seen at *r,* Fig. 3, Plate III. Here we observe that the large cartilaginous mass, and the crista which is afterwards united to the bone in the form of an epiphysis, are cartilaginous.

Under the description of the os sacrum, I have remarked, that, in several female subjects who died immediately after parturition, there was a separation of the os ilium and sacrum at the sacro-iliac-synchondrosis. Excepting in childhood, no separation or dislocation between the os ilium and ischium, or pubis, can occur at the acetabulum.

This, although a flat bone, resembles in its structure the round bones, as, for example, the bodies of the vertebræ, seen in Plate IV., Fig. 7; its fracture, therefore, is usually transverse: but this never occurs, excepting in cases similar to those mentioned under the os sacrum. The os ilium is subject to the same diseases as the bodies of the vertebræ, and is rendered carious, sometimes in lumbar abscess, and sometimes in aneurism of the external iliac artery.

The os pubis ꝑ, Figs. 1, 2, and 3, Plate III., and Fig. 2, Plate VIII., forms the anterior portion of the pelvis; the letter ꝑ is placed on the body; *i,* in Figs. 1 and 2, of Plate III., indicates the crista which gives origin to the pyramidalis and rectus abdominis muscles, and insertion to part of the tendon of the external oblique muscle; the crista terminating outwardly in a small tubercle termed the spine, ꝛ, into which also the tendons of the external and internal oblique muscles are inserted.* Running round the upper edge of the bone, from the spine of the pubes to the os ilium and os sacrum, there is a ridge, ꝑ, which is the commencement of the linea ileo-pectinea, or

* This should be considered by the practitioner in reasoning on crural hernia, for these objects, assisted by the external oblique muscle, shut up the abdomen at this point.

* The spine of the pubes and the anterior superior spinous process of the os ilium should be committed to memory, as they form points of measurement for securing the external iliac and superficial femoral arteries.

brim of the pelvis: into this, part of the conjoined tendon of the internal oblique and transversalis muscles are inserted. Between this ridge of the spine and the acetabulum, there is a depression, g, which gives origin to the pectinalis muscle; and between this surface and the depression, *x*, there is a slight elevated portion of the bone, represented in the drawing by its whiteness or lightness, and which is partly formed by the muscles on each side of it, and partly by the junction of the os pubis with the os ilium, where the pubes forms its proportion of the acetabulum, which is about one-fifth, as is seen in Fig. 3, *o*. The body of the bone where the letter h is placed, gives origin to the long head of the triceps, or adductor longus muscle; and nearer the mesial line, and close to the junction or symphysis, k, k, of the two bones of the pubes, and parallel with it, arises the gracilis muscle from the surface, m, m; hence the gracilis, the adductor longus, the pectinalis, and the psoas magnus, and iliacus internus muscles, are nearly on a level, and conceal those more deeply seated. Immediately beneath the letter h, in Figs. 1, 2, and 3, Plate III., the pubes is prolonged so as to form what is named its crus, from which arises the adductor brevis; the crus being more distinctly seen in Fig. 3, where the junction with the crus of the ischium, through the medium of cartilage, is observed at p; and the point where the adductor brevis is attached, being better illustrated in Plate VIII., Fig. 2, q. The inner and lower margin of the crus, which extends from the symphisis to meet the crus ischii, gives attachment to the crus penis in the male, j, j, Fig. 2, Plate III., and to the crus clitoridis in the female, j, j, Fig. 1, Plate III.; and these bodies are also attached to the crus of the ischium. The crus and body of the os pubis are seen to form part of the large foramen thyroideum, or obturatorium, U; and at its upper margin, near the acetabulum, there is a groove, w, made by the obturator nerve and artery, emerging from the pelvis, and by the vein re-entering; which groove, however, is indistinctly seen in the Plates. Hernia sometimes occurs at this niche. The large aperture has in the fresh state a ligamentous expanse which shuts it up, excepting only the small hole for these objects; and the ligament, together with the margins of the aperture, gives attachment to two muscles, the obturator externus and internus.

The bones of the pubes are joined to one another at k, k, by cartilage, which union, as it becomes nearly ossified in mature age, is styled symphisis pubis. This junction is sometimes separated by external violence, when so great as to induce fatal symptoms. A relaxation sometimes occurs during parturition; and in those subjects where relaxation took place at the sacro-iliac-synchondrosis, there was also relaxation at this junction; which confirms the statements of Vesalius and others. This bone, in its structure, fracture, and diseases, resembles the os ilium; but is occasionally the seat of exostosis. Its fetal state I have taken notice of in the description. Its use is to contribute to the formation of the pelvis, by which it assists in protecting and supporting the pelvic and abdominal viscera, together with the urethra and male penis. The urethra, as it passes beneath the symphysis, is supported by a strong ligamentous or fibrous covering from this part, and the canal here is named membranous.

The os ischium, H, in Figs. 1, 2, 3, Plate III., and Fig. 2, Plate VIII., is the most dependent or distal bone of the pelvis. The letter H, in Figs. 1, 2, and 3, is placed on the body of the ischium, while in Fig. 2, Plate VIII., it is placed on the tuberosity of the bone. The part extending upwards to meet the crus pubis, is styled also the crus or ramus of the ischium, which is best illustrated in Fig. 3. From this crus, at its most acute margin, 1, 1, and extending down to the tuberosity, arises the erector penis muscle in the male, as seen in Fig. 2, Plates III. and VIII.; and the erector clitoridis muscle in the female, 1, 1, Fig. 1, Plate III.; and close at the root of the erector arises the transversus perinei muscle. On the outside of the attachments of the crus penis, or crus clitoridis, the erector penis, and transversus perinæi, arises the adductor magnus, or great head of the triceps muscle, from the crus and tuber ischii, 2, 2, 2, Figs. 1 and 2, Plate III., and Fig. 2, Plate VIII. At 3, 3, Fig. 2, Plate VIII., arise the long head of the biceps cruris and semitendinosus muscles conjointly; and from the digit 4, a little nearer the acetabulum and thyroid foramen, arises the semimembranosus muscle, so that the latter is nearly hid by the two former when the subject is on its face: 5, of Fig. 2, Plate VIII., indicates the spot where the gemellus inferior originates, and 6 of the same figure, the surface where the long, or outer, or lower sacro-ischiadic ligament is attached: 8, of Figs. 1 and 2, Plate III., and Fig. 2, Plate VIII., points out the spine of the ischium which gives origin to the superior gemellus muscle, and attachment to the short, or inner, or higher sacro-sciatic ligament; which two ligaments, extending to the tubercle and oblong flat surface of the sacrum, form two apertures, named sacro-sciatic, the larger of which is formed by the short ligament attached to the spine of the ischium, 8, and the semicircle or notch of the os ilium, *v*, of Fig. 2, Plate VIII. In Fig. 2, Plate III., on the right, a dotted line is drawn from the spine, 8, to the tubercle of the os sacrum, which shows the way in which this larger sacro-ischiadic aperture is formed. Out of this aperture emerge the pyriformis muscle, the great sacro-sciatic nerve, and the gluteal, ischiadic, and internal pudic arteries; and the accompanying veins of these arteries enter the pelvis. Hernia sometimes occurs here, and the matter of lumbar abscess occasionally gravitates out at this foramen. Through the smaller sacro-sciatic notch, formed by the two ligaments represented by dotted lines on the opposite side of the same figure, but which is better understood in Plate VIII., Fig. 2, there emerges from the pelvis the obturator internus muscle, and there re-enter the internal pudic artery, vein, and nerve: the smooth sinuosity around which the muscle plays being marked 9. A ridge, 7, Figs. 1 and 2, Plate III., extends from the acetabulum downwards, between the tuberosity of the ischium and the obturator foramen, which gives origin to the quadratus femoris muscle.

The os ischium, as is observed at *r*, in Plate III., Fig. 3, forms the greater portion of the acetabulum, being a little more than two-fifths. The cavity itself is more distinctly seen in Plate VIII., Fig. 2, R, where the depth, increased by the brim, is displayed, and which is tipped with cartilage in the recent state. The brim is incomplete at 10, and is filled up in the recent state with a strong fibro-cartilaginous ligament, but still an aperture is left beneath it which transmits the nutritious vessels to the joint. The letter R is placed in the centre of the cavity, which is not tipped with cartilage, like the smooth surface around it, but is placed below the level of the general surface, in order to lodge the mucilaginous gland which lubricates the joint; and at the pubic portion of this rough surface

the round ligament of the joint is fixed, which point of attachment should be well understood when amputating at the hip joint. The other end of this ligament is attached to *c*, Fig. 3, of Plate VIII., which represents the circular depression on the smooth head of the os femoris. This joint admits of flexion, extension, abduction, adduction, and rotation, which conjointly form a revolving motion. The brim of the acetabulum is highest at 12, and yet dislocation from a variety of causes most frequently takes place here; and next in frequency, in the opposite direction, downwards and inwards on the obturator foramen: the joint may be luxated in the other directions, but these scarcely ever occur; indeed, from the depth of the acetabulum, and the consequent reception of the prominent head of the os femoris, together with the great strength of the capsular ligament and ligamentum teres, as also from numerous muscles which surround the joint, we should imagine dislocation would never take place.

In the fetus the os ischium is cartilaginous where it forms part of the acetabulum, and where its crus unites with that of the os pubis; which is also the case with its tuberosity and its spine.

The ischium is analogous in its structure to the os ilium and os pubis; and also in its fracture and its diseases, with the exception of its tuberosity, which sometimes necroses.

When we compare the two pelves, Figs. 1 and 2, we observe a marked difference in the brims, *y*, *y*, or what is named by accoucheurs, the inlets; the female is oval in the lateral direction, while the male is oval in the mesial direction, or from the symphysis pubis to the promontory of the sacrum; and the promontory of the male advances more towards the pubes than in the female. The greatest diameter of both is from the sacro-iliac-synchondrosis to the opposite or diagonal obturator foramen. The venters of the ossa ilium are more concave and capacious in the female, and the sacrum is broader and projects more dorsad; while the coccyx does not advance so far pubic, and is more moveable. The pelvis in the female is shallower, *i. e.* not so deep from the brim or inlet to the junction of the sacrum and coccyx. The lower aperture of the pelvis, named the outlet, formed between the symphysis pubis inferiorly, the tuberosities of the ischia, and the tip of the os coccygis, is also larger in the female, in whom we observe a much greater width between the rami of the pubes and ischia than in the male: the narrowness in the latter should be attended to by the lithotomist.

PLATES IV. AND V.

BONES OF THE HEAD.

These and the following Plate represent the bones of the head, and, as far as possible, the same letters have been applied to the similar points of the similar bones.

The bones of the head, Fig. 1, Plate IV., are divided into those of the cranium and those of the face; Plate V. represents the bones which compose the cranium, and Plate VI. those which compose the face. Those of the cranium, which are delineated in Plate V., are eight in number, and are named the os frontis, Figs. 1 and 2; the two ossa parietalia, Figs. 3 and 4; the os occipitis, Figs. 5 and 6; the two ossa temporum, Figs. 7 and 8; the os sphenoides, Figs. 9 and 10; and the os ethmoides, Figs. 11 and 12. The first six are improperly said to belong to the cranium, and the two last, the sphenoid and ethmoid bones, to be common both to the cranium and face; but the most superficial investigation will at once show the inaccuracy of this arbitrary arrangement, which the frontal bone itself overturns. The bones of the face are delineated in Plate VI. and are fourteen in number; the two ossa nasi are marked 13 and 14; the two ossa maxillaria superiora, 15 and 16; the two ossa lachrymalia, 17 and 18; the two ossa malarum, 19 and 20; the two ossa palati, 21 and 22; the two ossa spongiosa inferiora, 23; the vomer, 24; and the os maxillare inferius, 25 and 26.

The os frontis, Fig. 1 of Plate V., and also marked 1 in Fig. 1 of Plate IV., is situated in the upper and forepart of the cranium and face, and constitutes a portion of both of these divisions; its shape and appearance are seen in Plate V., where Fig. 1 is an external, and Fig. 2 an internal view. In the centre of the lower half of the bone, is a small projection *a*, named the nasal process, and on each side of it is another, *b*, *b*, not so distinct, termed the internal angular process; and extending outwards from these in an arched form, are the superciliary ridges, *c*, *c*, on which the eye-brows with their muscles, the corrugator supercilii of each side, are placed; these ridges, ending in projections, *d*, *d*, named the external angular processes. Running backwards from these, are two ridges, *e*, *e*, styled the temporal, made by the temporal muscles. Above the internal angular processes and the superciliary ridges, are two elevations, *f*, *f*, made by the frontal sinuses, and above these sinuses are two elevations, *g*, *g*, the centres of ossification in the fetus, which are better understood when compared with Fig. 6, Plate IV., where 1, 1, indicate these points in each half of the os frontis. Below the superciliary ridges are the large concavities *h*, *h*, which contribute to form the sockets for the eyes, and which are more properly depressions than elevations, and better designated as the orbitary plates or depressions than orbitary processes. In each of these depressions there is a smaller one, *i*, close to the internal angular process, which lodges the cartilaginous pulley of the superior oblique muscle of the eye; and also another depression, *k*, larger than the preceding, and near the external angular process, which lodges the lachrymal gland. Behind and somewhat below the temporal ridge, *e*, is the temporal depression, *l*, formed by the temporal muscle. Besides these, there are irregular depressions, *m*, *m*, on the mesial margins of the orbitary plates, which assist to form the ethmoid cells; and above, or coronad to these, are the apertures, *o*, *o*, of the frontal sinuses. On the same margins of the orbitary plates, are two small foramina which are generally formed between this and the ethmoid bone, and are only seen in Plate IV., Fig. 1; where, in the line of the transverse suture, within the orbit, near the lachrymal bone, is observed the anterior of the two, named the foramen orbitarium internum anterius, through which passes the nasal twig of the ophthalmic branch of the fifth pair of nerves, accompanied with a branch of the ophthalmic artery. The posterior is situated immediately behind this, or a little deeper in the orbit, and is termed foramen orbitarium internum posterius, and through it passes another branch of the same artery, also to the nose. A little deeper in the orbit is seen the round optic foramen of the sphenoid bone, and on the outside of it, a large angular slit, the upper portion of which is formed by the foramen lacerum of the sphenoid bone, and the lower by the spheno-maxillary fissure: these

are not joined in the skull, and it is only the perspective view which makes them appear so; but this will be understood after the examination of the other bones of the head. On the superciliary ridges is a notch or foramen, *n*, *n*, which gives passage to the frontal twig of the ophthalmic branch of the fifth pair of nerves with its artery and vein.

On the internal aspect there are a number of elevations and depressions made by the convolutions of the cerebrum, and several foramina, which give transmission to nutritious vessels. There extends across the bone a ridge, *q*, at the commencement of which, near the nasal process, is the foramen cœcum, 6, which towards the coronal aspect becomes a groove, *x*. The foramen, 6, and ridge, *q*, give attachment to the falx cerebri, and the groove, *x*, is formed by the superior longitudinal sinus,—a point of consideration for the surgeon, but not a preventive to operating.

The os frontis is joined to the ossa parietalia by its circular serrated edge, 2, 18, 2, named the coronal suture; from 2, to the external angular process, *d*, it is joined to the temporal process, *f*, of the sphenoid bone, Fig. 9, by part of the sphenoidal suture; and from the external angular process, *d*, by the margin of the orbital plates, *m*, *o*, *b*, *a*, *b*, *o*, *m*, to *d*, the other external angular process, the frontal bone is joined to some of the bones of the face, as the ossa malarum, 19, the os sphenoides, 9, the os ethmoides, 11, the ossa lachrymalia, 17, the ossa maxillaria superiora, 15, and the ossa nasi, 13, of Plate VI., by the transverse suture. The nasal process, *a*, is connected to the nasal lamella, *c*, *c*, of the ethmoid bone, Fig. 12. These connections are seen in Plate IV., Fig. 1. The os frontis assists to form a portion both of the cranium and face; contributes to support the anterior lobes of the cerebrum, as seen in the horizontal section, Fig. 3, Plate IV., *h*, *h*; forms part of the orbit, as seen in Fig. 1 of the same Plate, as also of the organ of smelling; and, by the frontal sinuses, assists in the reverberation of the voice.

In the fetus, this bone consists of two portions, as represented in Fig. 6, Plate IV.; and the superciliary foramina are not formed, and there is no frontal sinus. The two portions contribute to form the anterior fontanelle, *a*. The frontal is one of the thin flat bones, and is lined on each side with a membrane which secretes the bony matter; hence it consists of two tables, and an intermediate spongy substance named the diploe. The outer membrane of this and all the cranial bones, is named pericranium; and the inner membrane is styled dura mater. When the bone is inflamed, the action terminates either in resolution, exfoliation, exostosis, or caries; sometimes a disease analogous to necrosis affects it; and syphilitic exostosis, or what is termed a venereal node, frequently attacks this bone.

The parietal bone of a quadrangular figure is situated in the upper and lateral part of the cranium, or in the coronal and lateral aspect, as seen in Fig. 1, Plate IV. Figs. 3 and 4, of Plate V., are representations of this bone, Fig. 3 being an external view, and Fig. 4 an internal view; consists of four sides and four angles; a superior or coronal side, *a*, *a*; an anterior, *b*, *b*; an inferior or basilar, *c*, *c*; and a posterior or inial side, *d*, *d*; an anterior superior angle **e**; an anterior inferior angle or spinous process, *f*, on the inside of which one of the arteries that supplies the dura mater and bone makes a deep groove, which in some cases is a foramen; a circumstance to be attended to by the operator in trephining, but not a preventive. The parietal bone has a superior posterior angle, *g*, and a posterior inferior angle, **h**, the latter of which has a shallow groove internally, *i*, made by the lateral sinus, another circumstance to be considered in trephining, but not a preventive. Nearly in the middle of the bone, extending from the anterior side almost to the posterior side, in an arched form, is seen the impression, *k*, *k*, made by the temporal muscle; which, however, is better understood in the skull, Fig. 1, Plate IV., where the ridge marked *e* commences at the external angular process of the frontal bone: the same letter indicates the ridge in Fig. 3 of Plate V. In the centre of the parietal bone is an elevation that forms the commencement of ossification in the fetus, which is better seen at 3, in Fig. 6, Plate IV.; and near the superior edge there is a foramen, *o*, which transmits a vein that terminates in the superior longitudinal sinus.

Fig. 4.—The internal aspect represents the corresponding edges and angles: the groove at *f*, with its ramifications made by the artery and its branches; and the impression, *i*, made by the lateral sinus at the inferior posterior angle. There are numerous elevations and depressions made by the convolutions of the cerebrum; and when the two parietal bones are joined by their superior edges, a groove, *n*, *n*, is formed by the superior longitudinal sinus; and to the edges of the groove the falx cerebri is attached.

This bone is joined by its superior edge, *a*, *a*, to the opposite parietal bone by the sagittal suture; by its anterior edge, *b*, *b*, to the frontal bone, by the coronal suture; by its anterior inferior angle between *f* and *c*, to the temporal process, *f*, of the sphenoid bone, 9, by the part of the sphenoidal suture; by the contiguous arched portion of its inferior edge, from *c* to 4, to part of the squamous portion, *c*, *c*, of the temporal bone, Fig. 7, by the squamous suture; by the remainder of its inferior edge, from 4 to **h**, to that part of the mamillary portion from *c* to *d*, of the temporal bone, by the additamentum suturæ squamosæ; and by its posterior edge, *d*, *d*, to the occipital bone, Fig. 5, from 1 to 2, and 3, by the lambdoidal suture. This bone enters only into the formation of the cranium, and contributes to protect the brain.

In the fetus, none of the sides of this bone are complete, as exemplified in Fig. 6, Plate IV., where the two parietal bones, with the frontal, compose the walls of the anterior fontanelle, *a*. This space should be attended to by the accoucheur in parturition, and by the operator in puncturing for hydrocephalus. The parietal resembles the os frontis in its structure, and is subject to the same diseases, only syphilitic nodes much more rarely attack this bone.

The occipital bone, Figs. 5 and 6, of Plate V., is seen in the basilar views, Figs. 2 and 3, of Plate IV., situated in the posterior and basilar aspect of the cranium; and is of an irregular rhomboidal figure, as exemplified in the external view, Fig. 5, and in the internal view, Fig. 6. On the external convex aspect, there is a central eminence, *a*, which should be attended to by the operator, as it indicates where the superior longitudinal sinus divides to form the two lateral sinuses; and there extends from this point, on each side, across the bone, a ridge, **b**, **b**, made by the muscles on the back of the head and neck; the occipito-frontalis is attached to its upper margin; the trapezii to its lower margin near the protuberance, *a*, as between *a* and **b**, **b**; and to the protuberance itself, *a*, is attached the ligamentum nuchæ, which is formed by these

muscles: also to the lower margin, laterad and basilad to the trapezii, and to the letter **b**, the splenii capitis are attached. A little way below, and parallel to this ridge, is another transverse ridge, *c*, *c*, chiefly made by the complexi muscles, arising from the rough surface between these two ridges, but close to the inferior; the bone being a little depressed between these ridges. Between the lower ridge, *c*, *c*, and the foramen magnum, *k*, the bone is roughened, and slightly depressed, by the recti postici capitis minores in the centre; by the majores a little outward, or laterad and coronad; and by the obliqui superiores, still more laterad and coronad. A perpendicular ridge, *d*, *d*, divides these transverse ridges, so as to form a double crucial one. Basilad to these and to the foramen magnum, *k*, there are two smooth elevations, *i*, *i*, named the condyloid processes, which are articulated to the superior articular processes of the first cervical vertebra by capsular ligaments; and a ridge, *f*, extends outwards or laterad to this, which gives attachment to the lateralis muscle. A long projection, *g*, denominated the cuneiform process, on which, near the condyles, is an irregular transverse ridge, **f**, **f**, made by the recti anteriores minores and recti majores muscles; the lesser occupy the space between the condyles and this ridge; the greater occupy the space between the ridge and the end of the process, *g*.

The depressions seen on this surface of the bone are merely those between the different ridges made by the muscles which have been mentioned. At *e*, *e*, however, there is a depression or groove made by the occipital artery,—a matter of consideration for the surgeon, in the event of the vessel being wounded.

The foramina consist of the foramen magnum, *k*, which gives exit to the medulla oblongata of the brain afterwards becoming the spinal marrow, and to the vertebral veins; and affords entrance to the vertebral arteries and the spinal accessory nerves of Willis. Around this foramen, the margin is unequal, to afford attachment to the circular ligament, which by its other end is fixed to the atlas; and between it and each condyle, *i*, there is a rough surface, *n*, to which the lateral ligaments from the processus dentatus of the second vertebra are attached. Between the two condyles at *m*, there is a rough surface on the margin of the foramen, to which the perpendicular ligament from the processus dentatus is fixed. Posterior or inial to the condyles, are other two foramina, *o*, *o*, more distinctly seen in the internal aspect, Fig. 6, which are named the posterior, condyloid foramina, and give passage to veins from without to enter the lateral sinuses. Other two foramina are opposed to this, the anterior condyloid, *p*, *p*, which give exit to the ninth or twelfth pair of nerves of the brain, named lingual.

Fig. 6.—The internal view has a crucial ridge somewhat resembling that on the external view; to the upper perpendicular portion *q*, *q*, is attached a portion of the falx cerebri; to the transverse portion, *r*, *r*, is attached the tentorium cerebelli; and to the lower perpendicular portion, *s*, *s*, is fixed the falx cerebelli: the only other projection on this aspect is the cuneiform process, *g*. The depressions are those divided by the ridges; the large ones, *t*, *t*, contribute to support the posterior lobes of the cerebrum, and the equally large ones, *u*, *u*, support the lobes of the cerebellum: *x*, *x* is the groove or channel made by the termination of the superior longitudinal sinus, which branches into the two lateral that form similar channels, *z*, *z*, and afterwards make the tortuous depressions, *y*, *y*: the course of these sinuses is seen in a connected state in Figs. 3 and 4, Plate IV., as they emerge out of the cranium. The terminations, w, w, of these depressions, along with w, w, of the petrous portions of the temporal bones, contribute to form the large foramina termed the foramina lacera posteriora, which transmit the lateral sinuses, and the glosso-pharyngeal, the nervi vagi, and spinal accessory nerves. On the cuneiform process is a depression, 20, made by the medulla oblongata. The anterior, *p*, *p*, and posterior, *o*, *o*, condyloid foramina, and the foramen magnum, *k*, are also seen in this view.

The os occipitis by the serrated edge, 1, 2, 3, is connected to the posterior edges, *d*, *d*, of both ossa parietalia, Figs. 3 and 4, by the lambdoidal suture; by the partially serrated edge from 1 to *g*, to the mamillary and petrous portions, as from *d* to *e*, of the temporal bone, by the additamentum suturæ lambdoidalis; and by the cuneiform process, *g*, to the same process, **g**, of the sphenoid bone, Fig. 10, by part of the sphenoidal suture.

This bone supports the posterior lobes of the cerebrum, and the lobes of the cerebellum, transmits the medulla oblongata, the continuation of these two organs, through the foramen magnum, to become the spinal marrow, and gives entrance to the vertebral arteries, and the accessory nerves, and exit to the same nerves, the nervi vagi, the glosso-pharyngeal and lingual nerves, and vertebral veins. Between it and the atlas are performed the nodding motions of the head. Dislocation of this from accident has never been known to occur.

The occipital bone in the fetus consists of four parts, as represented in Plate IV., Fig. 5.

The diseases to which the occipital bone is subject, are, generally speaking, the same as those of the preceding bones of the cranium.

The ossa temporum, Figs. 7 and 8, Plate V., are situated in the lateral and basilar aspects of the cranium as exemplified in Plate IV., Fig. 1, marked with the digit 7, and in Fig 2, digit 7, also in Fig. 3 digit 7. This bone is divided in the description, for simplification, into three portions: a line drawn across from *g* to *c* placed posteriorly, Fig. 7, Plate V., indicates the squamous, which is superior; another line from the same *c* to *f*, marks the mamillary or mastoid, which is posterior; and the remainder is the petrous, which is inferior or basilad. On the external aspect of the squamous portion, Fig. 7, arises a conspicuous process, *a*, named the zygomatic, which unites with a corresponding process, A, of the os malæ, as seen in Fig. 1, Plate IV., and forms a jugum, under which passes the temporal muscle. At the root of this process, *a*, is an oblong elevation, *b*, upon which the condyloid process, *b*, of the inferior maxillary bone, Fig. 26, Plate VI. moves; and to enable these two convex surfaces to play on each other, there is interposed in the living state an intermediate cartilage, concave on both sides: thus every joint indicates contrivance and wisdom. Nearly the whole of this squamous portion, letters *k*, is depressed by the temporal muscle; and there is the glenoid cavity, *e*, on which the condyloid process of the inferior maxillary bone rests. The inside of this portion is elevated and depressed by the convolutions of the cerebrum, the middle lobes of which it assists to support; and the artery which forms the groove in the spinous process of the parietal bone, makes also a furrow in this, at **j**, **j**, **j**.

The mamillary portion is named after the process, *m*, which is termed mamillary or mastoid, and gives attachment to the sterno-cleido-mastoideus muscle; while the scabrous surface which extends to join the superior ridge,

b, of the occipital bone, gives attachment to part of the splenius capitis inserted beneath the sterno-cleido-mastoideus; the connection of these surfaces is seen in Fig. 2, Plate IV. This process also affords insertion to the trachelo-mastoideus, which lies beneath the splenius capitis. The mastoid process is hollow and arranged into cells, to form part of the organ of hearing, and is an excellent guide to the course of the lateral sinus; so that by this and the protuberance of the occipital bone, we can calculate the course of these sinuses. The deep rut, b, gives attachment to the posterior head of the digastric muscle, and the shallow fossa, *n*, basilad to it, which in some skulls is much deeper, is made by the occipital artery. The foramen, 9, gives passage to a vein which enters the lateral sinus. In the internal aspect this foramen is also seen on the margin of the fossa of the lateral sinus, *z*, *y*. On this portion, like the other bones of the cranium, are seen elevations and depressions; but here they are very slight. Along with the large depressions, *u*, *u*, of the occipital bone, it contributes to support the lobes of the cerebellum.

The petrous portion, T, I, *f*, of Fig. 7, is of an irregular quadrangular figure, two sides of which are exterior to the cranium, and two interior. On the superior or the glabello-lateral of the two external sides, is, *x*, the auditory ring or process, rough for the attachment of the external cartilage of the ear; at the base of which is a small projection, *r*, named the vaginal process, which overlaps a long process, *q*, the styloid, arising from the basilar side of these two, and giving attachment to three muscles, the stylo-hyoideus, stylo-pharyngæus, and stylo-glossus, also to two ligaments, the one to the lower jaw-bone, the other to the os hyoides. On the superior side is a considerable depression, E, that assists in the formation of the glenoid cavity, but which only lodges part of the parotid gland; and between this portion and that formed by the squamous, there is a fissure, *g*, named after Glaserus, into which part of the capsular ligament of the joint is inserted, and which transmits the chorda tympani nerve. The letter I points out the large foramen auditorium externum, that transmits the aerial vibrations to the internal ear. In the basilar side, there is an oblong depression, W, which, with the corresponding one, W, of the occipital bone, forms the foramen lacerum posterius; the depression is frequently double, with an intervening ridge, dividing the aperture into two, so that the lateral sinus passes through the posterior, and the nerves through the anterior. Posterior to this depression, at the root of the styloid process, is the foramen stylo-mastoideum, *f*, that gives exit to the facial nerve, and entrance to a small artery to the internal ear; and anterior to the depression, W, is a much larger foramen, *t*, the outer aperture of the carotid canal, the inner of which is also seen at T: this allows the internal carotid artery to enter the cranium, and the great sympathetic nerve to emerge. Nearer the squamous portion than the internal aperture of the carotid canal, and close to *g*, is a double aperture, leading to the tympanum of the internal ear, the lower or basilar forming part of the Eustachian trumpet; the upper transmitting a small muscle, the tensor tympum, to the internal ear.

The internal aspect of this petrous portion is easily distinguished, and the anterior side is divided from the posterior by a prominent ridge V, V, named petrosal, to which is attached part of the tentorium cerebelli; and on this ridge there is a small groove made by the superior petrosal sinus or vein, the same letter being applicable: these are more distinctly represented in Fig. 3, Plate IV. On the anterior side are several elevations and depressions, partly made by the convolutions of the middle lobe of the cerebrum, and partly by the parts of the internal ear; and near where this surface joins the squamous portion is a small foramen, 14, that transmits a twig of the Vidian nerve, which is only seen in Fig. 3, Plate IV. On the posterior side are some elevations and depressions, as well as foramina, belonging to the internal ear, which will be considered under that organ; we may notice, however, the large foramen auditorium internum, *u*, that transmits the auditory and facial nerves, and a small artery.

The temporal bone is joined by that part of its squamous edge, from *c* to *c*, to the parietal bone, by the squamous suture; from the posterior *c* to *d*, by the additamentum suturæ squamosæ; from *d* to T, to the occipital bone, by the additamentum suturæ lambdoidalis; from T to *g* and *c*, by part of the sphenoidal suture; and by its zygomatic process *a*, to the same process of the cheek bone by the zygomatic suture. The articulation with the inferior maxillary bone will be considered when I come to describe the latter.

In the temporal bone is contained the internal ear, the chief portion of the organ of hearing, which will be described under the organs of sense. The bone also assists to support the middle lobes of the cerebrum, and the lobes of the cerebellum, as well as to give passage to the different nerves and vessels already mentioned. A disease peculiar to this bone, or rather to the membrane lining the mastoid cells, is an abscess which occurs in children, and where the trephine is requisite.

The temporal bone in the fetus has a small fissure between the squamous and the mamillary and petrous portions; there are no mastoid or styloid processes, and in place of the funnel-like meatus auditorius externus, there is only a smooth bony ring, as exemplified in Fig. 6, Plate IV.; the other parts of the internal ear are not yet completed. The mamillary portion contributes to form part of the posterior fontanelle, as represented in Fig. 6, Plate IV., letter *b*. For a more minute account of this organ, see the Plates on the organs of sense.

The sphenoid bone is delineated in Figs. 9 and 10, Plate V., Fig. 9 being an external view. The letters *a* are placed on the central portion, considered the body of the bone, and point out the processus azygos, that is connected to the vomer, and which terminates superiorly in a projection *b*, named the ethmoidal process, on each side of which extends a delicate process, the transverse spinous, *c*, *c*, more distinctly seen in Fig. 10, the internal view. Anterior to this are the orbitary plates, *h*, *h*, and posterior to the latter, and forming the highest points of the bone, are the temporal processes, *f*, *f*: extending downwards and backwards from these, are the spinous processes, *d*, *d*, from each of which projects a small process, *e*, termed styliform; but these may be considered as one process. From the body of the bone there depend four processes, denominated pterygoid: *z*, *z*, point out the external pterygoid, from which arise the external pterygoid muscles: *x*, *x*, the internal pterygoid, at the extremity of which are the two unciform processes, *l*, *l*, around which the tendons of the circumflexi palati muscles play. The two little projections, *m*, *m*, are named the triangular processes.

The depressions on the external surface are the orbi-

tary, *h*, *h*, at the lower margin of which is a small groove, *i*, made by the temporal twig of the superior maxillary branch of the fifth pair of nerves; and behind the orbitary plate, the temporal process is depressed at *k*, *k*, by the temporal muscle; and there is a depression on the external pterygoid process upwards to the root of the temporal and spinous processes, made by the external pterygoid muscle. The foramina are one on each side of the azygos process, *a*, marked 9, which may be considered either a depression or foramen; when foramina, they are the apertures of the sphenoidal sinuses. Superior and lateral to these are two, 1, 1, the optic holes that transmit the optic nerves and ophthalmic arteries. On each side of the latter is a long lateral aperture, 2, named foramen lacerum anterius, which gives passage to the third, the fourth, the ophthalmic branch of the fifth, and nearly the whole of the sixth pair of nerves to the eye, and also to the ophthalmic vein or sinus. Beneath this there is a round hole, 3, the foramen rotundum, that gives exit to the superior maxillary branch of the fifth pair. Posterior to the rotundum is the foramen ovale, 4, which transmits the inferior maxillary branch of the fifth pair, and allows a small branch of the ascending pharyngeal artery to enter. Posterior to the ovale is the foramen spinosum, 5, through which enters to the cranium the artery that imprints chiefly the temporal and parietal bones. At the root of the internal pterygoid processes, are the foramina Vidiana, 8, 8, which transmit the reflected Vidian twigs of the superior maxillary branches of the fifth pair.

On the internal, Fig. 10, are observed the body and the different processes, as well as the foramina which are seen externally. The body differs in having four processes, named clinoid, two of which are anterior, 10, 10, and two posterior, 11, 11; and these with the depression, 12, which lodges the pituatary gland, have been termed sella turcica. Posterior to this is another process, g, styled cuneiform. The depressions are the central 12, on each side of which is a fossa, 13, made by the internal carotid artery as it passes tortuously into the cranium; and anterior to 12 is a groove, 14, made by the decussation of the optic nerves near where they emerge out of the cranium. The transverse spinous processes, *c*, *c*, and the ethmoidal, *b*, are slightly depressed, where the anterior lobes of the cerebrum rest; and there is a large depression, 16, between the temporal, *f*, and spinous process, *d*, which lodges the middle lobes of the cerebrum; and a large fossa is formed between each of the two pterygoid plates, but chiefly by the internal that lodges the internal pterygoid muscle.

The sphenoid bone is connected by its azygos process to the vomer and nasal lamella of the ethmoid bone by schindylesis; by the ethmoidal process and the body on each side of the azygos process, to the ethmoid bone; the transverse spinous processes, the contiguous edge of the orbitary plate, and part of the temporal process, are connected to the frontal bone; the tip of the temporal process is joined to the spinous process of the parietal bone; the posterior edge of this process onwards to the spinous process, and from the spinous to the cuneiform, is connected to the temporal, and the cuneiform process to the occipital bone; by their anterior surfaces, the pterygoid processes are connected to the palate bones; these processes, again, to the superior maxillary bones; and, lastly, the anterior edges of the orbitary plates to the cheek bones—all by the sphenoidal suture.

The use of this bone has been blended with the description. In the fetal state the bone is tolerably complete, but by a little maceration separates into three pieces, as exemplified in Plate IV., Fig. 9; in the body there are no sinuses; the processus azygos is larger than in the adult; and the thin triangular processes are not ossified. The sphenoid bone is subject to no particular disease.

Figs. 11 and 12 represent the ethmoid bone. Fig. 11 is the internal view; the letters *a* indicating the cribriform lamella through which pass the filaments of the olfactory and nasal twigs of the ophthalmic branch of the fifth pair of nerves, and *b* the crista galli that gives attachment to the commencement of the falx cerebri, which is also connected to the smooth line continuous with the crista galli. Descending perpendicularly into the nose from the crista galli, is the nasal lamella or septum, *c*, *c*, seen in Fig. 12; and on each side of this is the turbinated or spongy portion, letters *d*, on which the olfactory nerves are chiefly distributed: the plain surfaces, *e*, *e*, denominated ossa plana, enter into the formation of the orbit; and *f*, *f*, *f*, are the ethmoidal sinuses or cells. By the crista galli and cribriform lamella, the ethmoid is joined to the frontal bone; by its posterior surface and the same lamella, to the sphenoid bone; by its nasal lamella, to the sphenoid, vomer, and nasal process of the frontal and nasal bones; and by its plain surface, to the frontal, the lacrymal, the superior maxillary, and the palate bones,—all of which, generally speaking, are considered the ethmoidal suture.

Excepting the crista galli, and nasal lamella, which are cartilaginous, this bone, in the fetus, is ossified and complete.

The ethmoid bone is frequently attacked in secondary syphilis and noli me tangere, and soon ulcerates; and the nasal lamella is sometimes so twisted to one side, that the convex surface has been mistaken for a polypus.

The bones of the cranium, which have now been described, form that large cavity, a horizontal section of which is seen in Plate IV., Fig. 3, and a perpendicular one, Fig. 4. In this cavity is contained the cerebrum and cerebellum, with their continuation, the medulla oblongata, and the different nerves centring in them, also the blood-vessels supplying and the membranes enveloping them. The crista galli, *b*, the foramen cœcum, 6, the ridge of the frontal bone, *q*, the delicate ridge of the parietal bone, *n*, *n*, and that of the occipital bone, *q*, all afford attachment to the falx cerebri, which divides the cerebrum into two hemispheres. On *h*, *h*, of the frontal bone, and *c*, *c*, of the sphenoid bone, rest the two anterior lobes of the hemispheres; on 16, 16, of the sphenoid bone, and 7, 7, of the temporal bones, rest the two middle lobes of the cerebrum; on *t*, *t*, of the occipital bone, rest the two posterior lobes, which are also supported by the tentorium attached to the petrosal ridges, letters v, of the temporal bones, and to the ridges, letters *r*, of the occipital bone. A very small portion of the parietal at *i*, also affords attachment to this membrane; while *u*, *u*, of the occipital bone support the two lobes of the cerebellum, which are separated by the falx cerebelli attached to the ridge, *s*, of the occipital bone. In the osseous state, therefore, the two petrosal ridges, and the transverse ridge of the occipital bone, form the bounds of separation between

the cerebellum and cerebrum; the petrosal ridges also separate the posterior from the middle lobes of the cerebrum; while the transverse spinous processes of the sphenoid bone separate the middle from the anterior lobes of the cerebrum. In the living state, these partitions are assisted by productions of the dura mater attached to these ridges. On the depression, 20, of the occipital bone, rests the medulla oblongata.

In these figures, the processes and foramina in the cranium are marked with the same figures and letters as in the individual bones, so that they do not require to be pointed out or described.

The bones of the cranium constitute a class named the flat bones, dense and compact, and consisting of two tables, the exterior of which is the thicker, the interior the more consolidated, and denominated vitrea; and between these is an intermediate spongy substance, termed diploe. From this structure, and from their presenting a convex or globular surface, the line of fracture runs along, occasionally in various directions, similar to a globe of glass when broken; sometimes only the external table is fractured, while the internal remains sound; at other times, the reverse takes place, and not unfrequently with depression: again, the side of the cranium opposite to the spot where the injury has been inflicted, is occasionally fractured. When inflammation attacks these bones, the disease terminates either in resolution, exfoliation, caries, or exostosis. If the external table is deprived of vitality, they generally exfoliate or throw off a scale, which is regenerated by the vessels of the dura mater and internal table, as well as by those of the pericranium; and when both tables are divested of life, a separation takes place between the dead and the living bone; the dead portion is forced outwards, or requires removal, and the part is regenerated by the vessels of the pericranium, of the dura mater, and those of the contiguous living bone. If the portion of the cranium is very large, such injury is done to the pericranium and dura mater, that the bone is not regenerated, but generally only fibro-ligamentous substance; and the same result sometimes takes place, even when no injury or constitutional affection can be traced: in this case, probably the vessels are obliterated by too great a deposition of phosphate of lime; the bone consequently dies, becomes a neutral object, excites irritation, and causes a separation. From their configuration, and not from their structure, the bones of the cranium never end in necrosis, if we consider the term expressive of the death of the old bone with the generation of a new one exterior to it, which is the general acceptation by the profession, although, etymologically, it means merely the destruction of the old bone. Exostosis, as mentioned under the frontal bone, frequently attacks the exterior surface of the cranium, but this tumour sometimes grows from the diploe, making its way through the inner table, and injuring the brain; at other times it grows from the inner table only, and produces either apoplexy, epilepsy, or palsy, which sooner or later proves fatal.

In comparing the fetal cranium with that of the adult, it will be observed that the bones are apart from each other, and no indentations formed, and that there are also three conspicuous deficiencies of bony matter, as at *a* and *b*, Fig. 6, Plate IV. The bones not having united to form sutures before birth, allow the head to be modelled to the passages during parturition; the large anterior fontanelle, *a*, enabling the accoucheur to ascertain whether the child be alive or not. The shape and nature of the fontanelle should be considered by the operator when removing the water in the ventricles of the brain in hydrocephalus.

PLATE VI.

BONES OF THE HEAD (CONTINUED),

Is a representation of the individual bones of the face. Figs. 13 and 14 are drawings of the bones of the nose; Fig. 13 is the external, and 14 the internal view. Their situation in the face is seen in Fig. 1 of Plate IV., where they form the arch of the nose; they are of an oblong figure, slightly convex externally, as seen in Fig. 13, and gently concave internally, as seen in Fig. 14. Their superior edge, which may be termed an extremity, **b**, is thick and rough where it is articulated by the transverse suture to the frontal bone. Each of the long sides, H and N, is alternately depressed a little, that they may form a secure arch with each other, and with the superior maxillary bones on which they rest. The lower or distal extremity is thin and irregular, by which it is joined to the lateral cartilages of the nose. Nearly in the centre of the bone is a foramen, which transmits a small vein. The side, H, is joined to the opposite bone by the anterior nasal suture; the side, N, rests on the anterior margin of the nasal process, B, of the superior maxillary bone, Fig. 15, and forms the lateral nasal suture; and internally, where they form the anterior nasal suture, they rest on part of the septum narium, or nasal lamella of the ethmoid bone, and centre cartilage of the nostrils, forming the arch of the nose, and also defending its root. These bones are almost complete in the fetus, but are shorter and not so thick at their superior or glabellar extremity. In their structure they are firm and solid, and when fractured, the direction is either transverse or varied, according to circumstances, and they are subject to no peculiar disease, except that they are sometimes involved in the inveterate ulceration of the face, named noli me tangere.

Figs. 15 and 16 are delineations of the superior maxillary bone; Fig. 15 is the external, and Fig. 16 the internal view. The situation of this bone is seen in Plate IV., Fig. 1. Its most elevated process, B, enters into the formation of the cavity of the nares, and is named the nasal process; extending downwards and outwards from this is a smooth plate, H, styled the orbitary process; and on the exterior of this is a rough projection, *l*, termed the malar process, the lower anterior margin of which gives origin to part of the masseter muscle. On the nasal process, and exterior to the edge of the orbitar and malar processes, is a delicate ridge, more distinctly seen in the skull, Fig. 1, Plate IV., to which is attached the levator labii superioris alæque nasi. Behind the malar process, the bone terminates in a round prominent manner, named the bulbous process, *g*, from the rough upper portion of which, part of the pterygoideus externus muscle derives its origin. Where the bone receives the teeth, there are numerous slight projections, letters *n*, styled the alveolar processes; proceeding inwards from these, the bone is rough and arched, v, to form the roof of the mouth, which is denominated its palatine process, and gives attachment to the palate, forming also the floor of the nostrils; and from this plate arises a rough edge, *d*, *d*, which, when joined with the opposite bone, forms part of the septum

narium, and is named its spinous process. Above this last, on the nasal and bulbous processes, is a delicate ridge, *e*, *e*, that supports the inferior spongy bone, Fig. 23; this is well exemplified in Fig. 27, in which it is observable that the palate bone, Fig. 21, covers the posterior portion of the ridge, so that the inferior spongy bone is supported by the ridge on the nasal process of the superior maxillary bone, and the ridge, E, E, on the palate bone.

On this bone there are several depressions; one in particular, marked D, on the nasal process, B, where it looks to the orbitary process, and which becomes a conspicuous fossa towards the nostrils; this, with the lachrymal bone, Fig, 17, and the inferior spongy bone, Fig. 23, forms a tube named the lachrymal or nasal duct, that transmits the tears from the eye to the nose; and in Fig. 27, the junction of this bone to the inferior spongy bone is seen, and in Fig. 28, the junction to the lachrymal bone. This fossa being subject to disease, should be attended to by the operator, and the portion which the superior maxillary bone forms, is too dense to be pierced. The ligament of the tarsi is fixed to the nasal process at *t*, nearly at the commencement of the fossa, and is in danger of being injured in the operation of puncturing the lachrymal bone: the inferior oblique muscle of the eye arises within the margin of the orbitary process at *r*, not from the nasal, and is secure from danger. Below the infra-orbitary foramen, *o*, is a depression, *p*, from which the levator anguli oris arises, and beneath the anterior aperture of the nares, a depression, *q*, that gives origin to the depressor labii superioris. Behind the malar process, the bone is depressed by the temporal muscle which is seen more satisfactorily in the connected skull, Fig. 1, Plate IV. The orbitar plate is depressed or concave, so as to form part of the sphere of the orbit; and at its posterior point there is a depression, C, on which rests the orbitary process, *a*, of the os palati, Fig. 21; the junction being well exemplified in Fig. 27. On the bulbous process, *g*, are two rough depressions, *x*, *z*, where the pterygoid portion, *x*, *y*, *z*, of the palate bone, Fig. 22, joins; and immediately above, there is a fossa, *s*, turning obliquely downwards, which, together with the fossa, *s*, of the palate bone, forms the palato-maxillary canal that transmits the palatine twig of the superior maxillary branch of the fifth pair of nerves. The numerous sockets of the teeth are styled alveolar depressions. The concavity of the palatine plate, *v*, where it forms the roof of the mouth, is also concave, and forms the floor of the nostrils. The large cavity, A, that occupies the whole interior of the bone so as to render the walls rather thin, is named the antrum maxillare; and in the fresh subject is lined with a vascular periosteum, leaving merely a small aperture communicating with the nostrils between the superior, *d*, and inferior, 23, spongy bones, as seen in Fig. 4, Plate IV., which is a vertical section of the skull.

The foramina are the infra-orbitary, *o*, and incisive, *b*. The infra-orbitary is a canal open posteriorly on the orbitary plate at *o*, where the nerve, which has the same name, and is a twig of the superior maxillary branch of the fifth pair of nerves, enters. The incisive hole, *b*, is also a canal, transmits one or two nasal twigs of the same branch from the nostrils to the palate, and has one aperture towards the palate common to both superior maxillary bones, and two towards the nostrils, one proper to each bone.

The superior maxillary bone is joined at the tip of its nasal process to the os frontis by part of the transverse facial suture; by the anterior edge of this process to the edge of the os nasi by the lateral nasal suture; by the posterior edge of this process to the os lachrymale by the lachrymale suture; by the mesial edge of its orbitary plate to the lachrymal bone, the plain portion of the os ethmoides, and the orbitary process of the palate bone by the lachrymal, the ethmoidal, and the palato-maxillary sutures; and by its malar process to the os malæ by the internal and external orbitary sutures. The alveolar sockets receive the teeth by gomphosis. The superior maxillary bone is joined to that of the opposite side by the spinous ridges, to form the greater portion of the longitudinal palatine suture, which ridges, when joined, receive the vomer, Fig. 24; the external portion of their union, extending from the external aperture of the nares, between the central incisive teeth, is named the mystachial suture, seen in Plate IV., Fig. 1. By the posterior margin of the palatine plate, the bone is joined to the palatine plate, *n*, of the os palati, Fig. 22, by the transverse palatine suture; and by the depressions, *x* and *z*, to the pterygoid portion similarly marked, of the palate bone, and to the nasal lamella, A, of the same bone, by part of the palato-maxillary suture. Lastly, the ridge, *e*, with a similar ridge, E, of the palate bone, Fig. 21, gives support to the inferior spongy bone, Fig. 22, which is well exemplified in Fig. 27.

The uses of this bone have been mentioned in the description, and need not be repeated. The structure is rendered so thin by the antrum, that it easily becomes carious, and this state always accompanies the tumours which occur in this cavity; a disease of the most fatal nature. All the cases which I have witnessed of this malady, whether operated on or not, have proved fatal.* The antrum is subject to abscess, the matter of which must be evacuated by extracting the second molar tooth and perforating the bone. The anterior part of the bone is sometimes involved in noli me tangere, and the alveolar processes are frequently attacked with caries in the diseases of the teeth and the different affections of the gums, or where too much mercury has been exhibited in the treatment of syphilis or other diseases; and the palatine plate is sometimes involved in the syphilitic ulceration of the soft palate. In the fetus, instead of the large antrum, there is only an oblong depression at the side of the nostrils; the malar process is hollow, with several holes in it; the alveolar sockets are fewer in number; and the palate plate is cribriform in the centre.

Figs. 17 and 18 are representations of the lachrymal bone, situated at the inner angle of the orbit, as seen in Fig. 1, Plate IV. The external view is delineated in Fig. 17, and is distinguished by having two depressions, G, F, separated by a perpendicular ridge, E, E; the depression, G, is the anterior and narrower of the two, and along with the groove, D, of the superior maxillary bone, Fig. 16, and the inferior spongy bone, Fig. 23, forms the lachrymal duct, in the upper portion of which the lachrymal sac is supported: the depression, F, forms part of the orbit. Fig. 18 is the internal view, and has two irregular convex surfaces with a groove running between them. This bone is joined superiorly to the frontal bone by part of the

* John Bell's Principles of Surgery, Vol. III., contain some very valuable remarks on this disease. There is only one instance in which an operation has proved successful that I am acquainted with: the patient, a woman, had a tumour removed from the antrum, some years ago, in the Infirmary, by Mr. Newbigging, and is still living.

transverse suture; anteriorly to the nasal process at D, of the superior maxillary bone; inferiorly, to the orbitary process of the same bone; and posteriorly, or internally, in the orbit, to the plain surface, *e*, of the ethmoid bone, Fig. 11, Plate V., by the lachrymal suture. Besides the uses already mentioned, this bone forms part of the nostrils, and shuts up some of the ethmoidal cells. The anterior depression, G, should be studied by the surgeon in fistula lachrymalis, whether in regard to palliative treatment, or for the purpose of operation. This bone is so extremely thin, being generally cribriform in the anterior portion, that it readily ulcerates either in affections of the eye or nose. The lachrymal bone is fully formed in the fetus.

The os malæ, or cheek-bone, is of a quadrangular figure, as seen in Fig. 19, and forms the prominent part of the cheek, as seen in Fig. 1, Plate IV. This is the cheek-bone of the right side; the superior angle, D, is termed the superior orbitar process, the anterior angle, L, is named the inferior orbitar process; the inferior angle, K, is denominated the maxillary process; and the posterior angle, A, is styled the zygomatic process. Between the two orbitary processes, D, L, the bone extends into the orbit in a concave form, *b*, as seen in the internal view, Fig. 20: this is sometimes named the internal orbitar process; but is more properly a depression than a process. Posterior and inferior to this, is another large depression, *k*, made by the temporal muscle. From the lower edge, between A and K, arise part of the masseter muscle, and the whole of the zygomaticus major; and sometimes from near the middle of the bone arise the zygomaticus minor, and part of the levator labii superioris alæque nasi. Nearly in the centre of the bone externally, is one or more holes which transmit small nerves and blood-vessels to and from the orbit; and on the internal surface are similar holes. The cheek-bone is joined by the superior orbitar process, D, to the external angular process, *d*, of the frontal bone, by part of the transverse suture; by the upper half of the internal orbitar process, *b*, to the orbitar plate, *h*, of the sphenoid bone, by part of the sphenoidal suture, and by the lower half of the internal orbitar process, *b*, to the orbitar process, H, of the superior maxillary bone, by the internal orbitar suture; by the margin of the bone from the inferior orbitar process, L, to the maxillary process, K, to the malar process, *l*, of the superior maxillary bone, by the external orbitar suture; and lastly, by the zygomatic process, A, to the zygomatic process, *a*, of the temporal bone, by the zygomatic suture. The centre of the margin of the internal orbitar process, where the bone is neither connected to the sphenoid nor superior maxillary bones, contributes to form the spheno-maxillary aperture, which is seen in Plate IV., Fig. 2, letter R.

The cheek-bone has a dense structure, and resembles the bones of the cranium, with the exception of some cancelli at the maxillary process; is subject to no particular disease, except being sometimes involved in noli me tangere; and any of its processes, particularly the zygomatic, might be fractured, in which case the direction would be oblique. In the fetus, this bone is completely ossified.

The os palati is depicted in Figs. 21 and 22; the view which looks to the nostrils is represented in 21, and that which looks posteriorly and outwardly in 22. Its situation in the skull is seen in Plate IV., Fig. 2, but more distinctly in this Plate, Fig. 27. The palate bone is generally divided into portions to simplify the description: *n* indicates the palatine, whence the bone has derived its name; P, P, the nasal lamella; *x*, *y*, *z*, the pterygoid portion; and *a*, the orbitar portion. The palatine, *n*, is a square plate which resembles that, V, of the superior maxillary bone: its posterior edge, acutely arched, supports the velum pendulum palati, and projects backwards to join the palatine plate of the opposite bone to give origin to the azygos uvulæ muscle; its anterior edge is a little rugged to form a firm junction with the same plate, V, of the superior maxillary bone, which is exemplified in Fig. 27, where the two bones are represented a little apart. The mesial or inner edge, d, named the spine, precisely resembles the same part, *d*, of the superior maxillary bone. The nasal lamella, P, P, is extremely thin, rises up from the palatine portion, having a ridge, E, E, which assists to support the inferior spongy bone, as represented in Fig. 27; and this ridge makes two concave surfaces, P, P, that enlarge the nares: the lamella itself contributing to shut up the antrum. The pterygoid portion is the inferior posterior part; has three depressions, *x*, *y*, *z*: *x* and *z* are formed by the pterygoid processes of the sphenoid bone, and *y* contributes to form the fossa between them. The orbitar portion, *a*, consists of the proper orbitar process on which the letter *a* is placed, and the posterior projection, *b*, also named orbitar process; the one the anterior, the other the posterior. The open aperture, *o*, that separates these two processes, is sometimes a complete foramen; but as the sphenoid bone generally enters into its formation, it may be denominated the spheno-palatine foramen: through which twigs of the superior maxillary branch of the fifth pair of nerves, accompanied by a branch of the internal maxillary artery, pass to the nose; and generally one or two veins return. The anterior or proper orbitar process has a cell which joins those of the ethmoid bone. A groove, *s*, extends downwards on the external surface of the nasal lamella to the pterygoid and palatine portions, and becomes an entire canal when the bone is joined to the superior maxillary bone; hence named the palato-maxillary canal, and transmits the palatine twig of the superior maxillary nerve. In this canal a small foramen, which gives passage to a nasal twig of the nerve, is generally seen through the nasal lamella.

The palate bone is joined by the spinous ridge, d, to the same part of its fellow, so as to complete the longitudinal palatine suture, as seen in Fig. 2, Plate IV.: the nasal ridge formed by this union giving rest to part of the vomer. The bone is joined by the anterior edge, *n*, of the palatine plate, to the corresponding plate of the superior maxillary bone, by the transverse palatine suture, as seen in Fig. 27 of this Plate, and Fig. 2, Plate IV.; posteriorly by its pterygoid portion, *x*, *z*, and by the edge of the nasal lamella, P, to the pterygoid processes of the sphenoid bone; by the orbitar portion, *a*, to the same bone, by the spheno-palatine suture; by the anterior and outer aspect of the pterygoid portion, along with the nasal lamella and orbitar process, to the bulbous and orbitary processes of the superior maxillary bone, by the palato-maxillary suture; also by the mesial aspect of the orbitar process to the plain surface of the ethmoid bone, by part of the transverse suture. The ridge, E, E, on the nasal lamella, gives support to the inferior spongy bone, as seen in Fig. 27.

From the description, it will appear that the palate bone forms part of the roof of the mouth, the floor and side of the nostrils, the floor of the orbit, and part of the

walls of the antrum, and of the ethmoid and sphenoid cells, as seen in Fig. 27 of this Plate, and in Fig. 4, Plate IV.

Excepting the cells, which are not formed, the palate bone, in the fetus, is complete: the nasal lamella is even thicker than in the adult. This bone is liable to be involved in diseases of the antrum, nostrils, and palate.

Fig. 23 is the view of the os spongiosum inferius, that looks to the antrum maxillare, and is a delicate cribriform bone, like the turbinated portions of the ethmoid with which it is contrasted; rests on the nasal ridges of the superior maxillary and palate bones; and contributes to form the nasal duct, and the walls of the antrum. On this bone the extremes of some of the nasal twigs of the superior maxillary nerve are distributed, which assist in the formation of the organ of smelling. Its connexions are represented in Fig. 27; and the bone is almost complete in the fetus. From its delicate structure, the inferior spongy bone is easily rendered carious, and is very liable to be attacked in the secondary symptoms of syphilis.

Fig. 24 is the vomer, of an irregular rhomboidal figure, situated in the posterior part of the nostrils, and forming the chief portion of the partition, as seen in Fig. 2, Plate IV. The superior edge, *a*, has a deep furrow, which sometimes separates the bone nearly into two laminæ; this receives the azygos process of the sphenoid bone; the anterior edge, *c*, has also a groove for the reception of the nasal lamella of the ethmoid bone, and the cartilaginous septum of the nostrils: the inferior edge, *d*, rests between the nasal spines of the superior maxillary and palate bones; the short edge, *b*, may be considered a continuation of the anterior, for it is grooved and receives the cartilaginous septum. The posterior edge looks to the top of the pharynx. These junctions of the vomer are named schindylesis. Besides the use already mentioned, the vomer contributes to enlarge the organ of smelling, by affording a greater surface for the expansion of the nerves of that sense.

This bone is frequently so much twisted to one side, as to resemble a tumour, and be mistaken for a polypus; and is so delicate in its structure, that it soon yields when attacked with syphilitic ulceration, and is equally easily destroyed in noli me tangere, æzena, and tumours of the nostrils.

The structure of the nostrils is of importance to know, on account of the diseases to which they are liable, independently of the interest of the organ in a physiological view. In Fig. 1, Plate IV., is seen the external aperture formed by the nasal bones, 13, and the superior maxillary bones, 15, and immediately within this opening, the vomer, 24, commencing the septum, which divides the nares into two cavities; and, on the right side, the inferior spongy bone, 23. In Fig. 2 of the same Plate, is seen the internal or posterior opening formed by the palate bones, 21, 22, and the internal pterygoid processes, *x*, *x*, of the sphenoid bone; and the vomer, 24, in the centre, with the inferior spongy bone in each nostril, is also seen in this view. Fig. 4 of the same Plate illustrates a section of the nostrils, the vomer being removed: 13 indicates the os nasi; B, the nasal process, and *d*, d, the palatine processes of the superior maxillary and palate bones; the letter *c* points out the nasal lamella of the ethmoid bone, which forms the upper portion of the septum; *d*, the turbinated portion of the same bone or the superior spongy bone; 23, the inferior spongy bone; and *x*, the internal pterygoid process of the sphenoid bone. From these views of the nostrils, we observe, that in hemorrhage, or epistaxis, and in polypi, there is but a narrow passage close to the floor, or palatine plates, and to the vomer, in each nostril, through which we may introduce probes and ligatures into the throat. In polypi, which hang from the upper spongy bone, *d*, there is considerable difficulty in reaching them. When the polypi are large and firm, we can easily conceive how rapidly they will destroy these cribriform bones and delicate cells; as well as how tumours in the antrum will destroy these delicate bones. The cells which communicate with the nostrils, are the frontal sinuses, *f*, the ethmoid cells, also marked *f*, the cells of the palate bone, and the sphenoid cells, 9, with the maxillary antrum, which has an opening between the spongy bones, *d*, and 23, but scarcely seen in this view: it is, however, well illustrated in Fig. 27, Plate VI. The ethmoid cells are also well exemplified in Fig. 29 of the same Plate, and are marked *f*, *f*. All these cavities are designed to reverberate the voice, but not to assist in the formation of the organ of smelling. Among many of the other mammiferous animals, these cells extend over the greater portion of the cranium, as in the sow and the elephant. In the ox, the frontal sinuses communicate with the cellular structure of the horns.

Figs. 25 and 26 are representations of the inferior maxillary bone; the former is an external, the latter an internal view. From the one mental foramen, *f*, to the other, *f*, is named the body; from this foramen, *f*, to the angle, *d*, is termed the side; and from the angle, *d*, upwards to the two processes, *b* and *k*, is styled the ramus; the bone resting on the base, *a*, *a*. In the centre of the body is a ridge, *c*, cartilaginous in the fetus, and named the symphisis menti; and on each side of this are two rough surfaces, the lower being the more elevated; the upper, *h*, gives attachment to the levator labii inferioris, and between this pair of muscles and a little above, the frænum of the lip is attached; the lower, *i*, gives origin to the depressor labii inferioris, which arises from the base onwards to the contiguous, *a*. Between the letters *a*, the bone is roughened on the base and side, where the depressor anguli oris arises; and the angle, *d*, is also rough, as well as the ramus some way upwards, where the masseter muscle is inserted. The letter *b* marks the smooth condyle which moves on *b* of the temporal bone, through the medium of a doubly concave cartilage; and the root of this, where the bone is narrower, is named the cervix, *e*, to which is attached the capsular ligament. The projection, *k*, is styled the coronoid process, which is rough for some way downwards, to give insertion to the temporal muscle; and the ridge, *g*, which extends forwards from the root of this, gives attachment to part of the buccinator muscle. The upper margin of the bone has alveolar processes, M, and sockets for the teeth. There is only one foramen, *f*, the mental, which gives exit to the osseous branch of the inferior maxillary nerve, with a small artery and vein; the nerve sometimes requires to be divided in consequence of neuralgia; and the foramen can be most accurately ascertained by drawing a perpendicular line from the second molar tooth to the base of the bone.

On the internal aspect, Fig. 26, in the centre, is the symphysis, with two little elevations, and a ridge towards the base; the two elevations, *n*, *n*, affording origin to the genio-hyo-glossi muscles; the frænum linguæ is attached immediately above them; and the genio-hyoidei muscles arise below them from the ridge; and beneath these last,

from the little rough surfaces, *m*, *m*, arise the anterior heads of the digastric muscles. The ridges, *p*, *p*, afford origin to the mylo-hyoidei muscles; the rough surface, *q*, on the inside of the angle, *d*, gives insertion to the pterygoideus internus muscle, and the angle gives attachment to the lateral ligament, which extends to the styloid process of the temporal bone; while the rough surface, *o*, at the root and neck of the condyle, affords attachment to the external pterygoid muscle. The aperture, *r*, gives entrance to the osseous branch of the inferior maxillary nerve, along with a branch of the internal maxillary artery and vein. This nerve becomes sometimes the subject of operation. Extending from this aperture is a groove, *s*, made by a twig of this nerve.

The lower jaw-bone is articulated to the temporal bone by a strong capsular ligament; and as two convex surfaces move on each other, through the medium of a doubly concave cartilage, motion takes place downwards and upwards, and from side to side, and is, in some degree, rotatory. When motion downwards is performed to too great an extent, the condyloid process slips forwards beyond the elevation, *b*, of the temporal bone; and dislocation, which happens most frequently in children whose articulation is shallower, occurs only in this direction. The lower jaw-bone receives the teeth by gomphosis. In the fetus, the inferior maxillary bone consists of two pieces connected to each other, at the symphysis by cartilage, and there are much fewer alveolar processes, sockets, and teeth.

This bone is very dense in its structure, and is one of those most subject to necrosis, affording one of the best illustrations of the modus operandi in this disease. Its alveolar processes are spongy, like those of the upper jaw-bone, and are nearly equally subject to caries consequent on diseases of the teeth and gums. The whole thickness of the bone is occasionally affected with exostosis.

The teeth, sixteen in number, in each maxilla of the adult, are divided into the four anterior, named incisive, the one on each side of these, termed the canine, or cuspidatus, and the five posterior to each of the last, denominated the molar. The five molares of each side are subdivided into the bicuspides, which are the two anterior, and into the proper molares, which are the three posterior; the last of which is named dens sapientiæ. Each tooth consists of a crown, the smooth enamelled portion which is above the gums in the living state, a cervix where the tooth is a little smaller in circumference, and to which the gum is attached, and the root or fang which is lodged in the alveolar socket. At the tip of each fang is a very small hole, that leads up to a cavity in the crown of the tooth: the small twigs of the nerves and blood-vessels enter the foramina, and form a beautiful tissue in this cavity, which is also lined with a sensitive vascular membrane.

The incisive differ from the others, in having their crowns formed of an anterior convex surface, and a posterior or inner concave surface, which meet superiorly, and form a horizontally-cutting edge with two apices:—they have only one fang or root.

The canine or cuspidati have their crowns terminating in one point, and have only one fang.

The bicuspides have their crowns tipped with two points, and have one fang like the two preceding divisions, with this difference, that the fang is flatter, and appears like two united into one. The proper molares have their crowns of a square form, with rounded angles, and are studded generally with five points: the molares of the upper jaw have usually three fangs, while those of the lower have only two; and the last of these, or dens sapientiæ, is smaller than the other two, and has its fangs generally united into one.

The diseases to which the teeth are liable, can be said to be only denudation or desquamation, decay or rottenness, and fractures; for, the other diseases which are generally considered as belonging to them, attack the contiguous substances, and then only sometimes involve them. Thus, odontalgia, or toothach, is an inflammation of the delicate membrane and vessels in the cavity of the tooth. The caries which is said to attack them is simply decay, not ulceration. The tartar which accumulates on them is an external deposition of substance. Caries, exostosis, and abscesses of the alveolar processes, necrosis of the inferior maxilla, gum biles, tumours of the gums, abscess of the antrum maxillare, and neuralgia of either the superior or inferior maxillary nerves, are sometimes sequences of diseased teeth. As the teeth are extremely hard and dense, the fracture is perpendicular, or oblique and splintery.

The condition of the teeth in the fetus, and their formation, will be considered after the description of all the bones.

Besides the bones of the head which have been described, there are in some skulls small portions of bone in the course of the lambdoidal suture, which are named ossa triquetra, or Wormiana, though they are properly parts, either of the occipital or parietal bone. These are more observable in young crania, before the bones are completely formed, than in adult skulls. They are sometimes met with in other sutures besides the lambdoidal.

PLATE VII.

BONES OF THE UPPER EXTREMITY,

Represents these bones, excepting the clavicle, which is seen in Plate I., marked with the letter *c*, nearest the head, and in Plate II., Fig. 1, *p*; this bone, with the scapula, *k*, of the same Plate and figure, or figs. 1 or 2, of this Plate VII., constitutes the bones of the shoulder. Figs. 3 or 4 is the bone of the arm; Figs. 5 or 6 refers to the bones of the fore-arm; and Figs. 7 or 8, to the bones of the hand, which are subdivided into those of the carpus, *a*, *b*, *c*, *d*, *e*, *f*, *g*, *h*, those of the metacarpus, 1, 2, 3, 4, 5, and those of the phalanges, 6, 7, 8, 9, 10; 11, 12, 13, 14; and 15, 16, 17, 18, 19.

The bones of the shoulder are two in number, the clavicle and scapula. The clavicle, *p*, Fig. 1, Plate II., resembling an italic *f* in figure, is situated at the upper and lateral part of the thorax, and forms the connecting link between the bones of the trunk and those of the upper extremity. Its superior posterior, or its atlantal and dorsal margin, gives attachment to the sterno-cleido-mastoideus and trapezius muscles; the latter occupying the scapulary third, 1, 1, and the former a little more than the sternal third, 2, 2, leaving the space between them without any muscles. To the sternal and somewhat sacral margin, are attached the pectoralis major and deltoid muscles; the former occupying nearly the two sternal thirds, 3, 3, 3, and the latter a little more than the scapulary third, 4, 4. The inferior or sacral surface affords insertion to the

subclavius muscle, and attachment to the rhomboid ligament, near which the chief medullary vessels enter the bone.

The clavicle is articulated by its sternal end, which is triangular, to the first or upper portion of the sternum, by a synovial fibrous capsule; and within the joint is interposed an interarticular cartilage. A strong ligament, named interclavicular, extends from the dorsal aspect of this end, which is formed into a sharp ridge, to such another ridge in the opposite clavicle. A strong ligament, termed rhomboid, extends between the bone and the cartilage of the first rib. As the clavicle passes over the coracoid process, 5, of the scapula, *k*, there is a tubercle and roughened surface on its sacral aspect, which gives attachment to the coraco-clavicular, or conoid and trapezoid ligaments, extending from the roof of the coracoid process; and it is articulated by its scapulary extremity, which is flattened horizontally, and of an oblong shape, to the acromion process, 6, of the scapula, by a synovial and fibrous capsule and transverse ligaments. From these strong attachments, the clavicle is seldom dislocated at either of its extremities, being much oftener fractured, an accident which frequently happens to this bone. The articulation at the sternal end allows the clavicle to be moved forwards, backwards, upwards, and downwards; also, a combination of these, termed rotatory motion, or circumduction. The scapulo-clavicular articulation admits of a slight gliding motion. The clavicle forms a lever on which the other bones of the extremity move, allows an extensive latitude for the various motions, and prevents the scapula from falling forwards or sternad on the thorax. This bone is present in all animals that extend their arms or anterior extremities frequently forwards, while it is wanting in those which use the anterior extremities only for progressive motion, as the pachydermata, ruminantia, and solipeda.

In the fetus, the clavicle is completely ossified, and follows the ribs in arriving at perfection; resembles the long cylindrical bones in its structure, though fully more dense at its extremities. Its fracture is oblique and splintery; and it is frequently necrosed, and subject to exostosis from syphilis.

The scapula, Figs. 1 and 2, Plate VII., is situated at the superior and dorsal aspect of the thorax, as is represented in Fig. 1, Plate II., *k*, as also in Plate I., where the dorsal aspect is represented in outline; is a thin, flat, triangular bone; *a*, *a*, indicating its inferior costa; *b*, *b*, its superior costa; and *c*, *c*, its base; *d*, its superior posterior angle; *e*, its superior anterior angle; and *f*, its inferior angle. The external surface or dorsum, *g*, of the bone, is slightly convex, and is divided into two unequal portions by a high ridge, *h*, named the spine, which terminates in the acromion process, 6: to the upper or atlantal edge of this spine and acromion is attached the remainder of the trapezius muscle, the rest being connected to the clavicle at 1, 1, Fig. 1, Plate II.; to the inferior or sacral margin is attached the rest of the deltoid muscle, the other portion arising from the clavicle, 4, 4, Fig. 1, Plate II.: 8, of Fig. 2, indicates the small smooth surface to which the clavicle is articulated. The portion of the bone, g, between the spine, *h*, and the superior costa, *b*, *b*, is occupied by the supra-spinatus muscle, and hence termed the supra-spinal fossa: the inferior portion, *g*, between the spine, *h*, the inferior costa, *a*, *a*, and the base, *c*, is occupied by the infra-spinatus muscle, and therefore styled the infra-spinal fossa: both on this surface, near the spine, and on the supra-spinal fossa, the chief medullary arteries enter. The digit, 5, indicates the coracoid process, round the tip of which, where 5 is placed, is attached the pectoralis minor, the coraco-brachialis, the short head of the biceps flexor cubiti muscles, and the coraco-humeral ligament; to its acromial edge, 7, Fig. 1, is attached the strong ligament that extends to the acromion process, 6, named the proper anterior ligament of the scapula: the two dotted lines in Fig. 2 pointing out its situation. To the root of this process, 9, where it is rough, and sometimes raised to a tubercle, the conoid and trapezoid ligaments, which keep the clavicle in position, are attached; and also a small ligament, stretching across the supra-scapulary notch, *o*, termed the proper posterior ligament of the scapula; this, therefore, is a hole in the fresh state, and transmits the supra-scapulary nerve, artery, and vein: a dotted line indicating where the ligament is stretched. From this ligament, and part of the superior costa, *b*, the omo-hyoideus muscle derives its origin. Into the part of the base, c, c, superior to the spine, is inserted the levator scapulæ muscle; into the portion, between c and *c*, opposite to the spine, *h*, is inserted the rhomboideus minor; and into that from *c* to c, is inserted the rhomboideus major: these rhomboidei are, however, actually one muscle. Into the edge of the base, from the superior posterior angle to the inferior angle, letters *k*, Fig. 2, between the insertion of these muscles, and the circumference of the subscapularis muscle, which occupies all the concave venter, letters *i*, is inserted the serratus major anticus muscle. The letters A, Fig. 1, point out the surface from which the teres major derives its origin, and *a*, *a*, situated on the margin of the bone, the long smooth surface for the teres minor. The inferior angle, at *f*, is flattened by the latissimus dorsi, which passes over and adheres to the scapula. Between the smooth surface, occupied by the teres minor, and the fossa formed by part of the subscapularis, is a ridge, a, that gives origin to the long head of the triceps muscle. The digits, 2, represent what is named the cervix, that gives attachment to the fibrous and synovial capsules, which, after surrounding the smooth head, *c*, of the os brachii, Figs. 3 or 4, are fixed to the cervix, letters *e*, of that bone: the letter *e*, Figs. 1 or 2, indicates the anterior angle, or glenoid cavity, which is extremely shallow, of an oval shape, and adapted to receive the smooth head, *c*, of the os brachii, Figs. 3 or 4. This, however, is deepened in the recent state by a brim of fibro-cartilage, considered by some to be a continuation of the long tendon of the biceps. At the upper point of this cavity is a smooth surface, 3, that affords attachment to the long head of the biceps.

In this manner, the scapula is articulated to the os brachii, or *vice versa*, so as to allow free motion in every direction; which motions are termed extension, flexion, abduction, adduction, rotation inwards, rotation outwards, and circumduction. Were it not for the acromion process, the proper anterior ligament of the bone, and the coracoid process forming nearly the half of the circle round the joint, dislocation would be very frequent. As it is, it is the joint most frequently dislocated. The short muscles around contribute much to strengthen the joint. The scapula is connected by its acromion process to the scapulary end of the clavicle; but it is also held in position by the several muscles already mentioned as attached to the bone. Its motions will be better understood after the description of the bone of the arm.

In the fetus, the anterior angle or glenoid cavity, the

coracoid process, the acromion process, and the base of the scapula, are cartilaginous.

In its structure, the scapula resembles the other flat bones, with this difference, that by the action of the muscles on each side, its body becomes thin and diaphanous. Fracture of this bone is not very common, and when the accident does occur, generally the acromion process, or inferior angle, is the portion; seldom the coracoid process or cervix of the bone; and in these cases the fracture is transverse. This bone is sometimes necrosed.

Fig. 3 represents an anterior view of the os brachii, and Fig. 4 a posterior one. The letters and figures refer to both. The letters *a* indicate the body or shaft of the bone; *c*, *b*, the extremities or epiphyses; *c* indicates the smooth head which rotates in the glenoid cavity of the scapula, and is surrounded with the capsular ligament fixed into the rough circular groove named cervix, letters *e*; *f*, *g*, are two tubercles, divided by a fossa, *h*, on the anterior aspect; the internal or ulnar tubercle, *f*, is the smaller, and affords attachment to the subscapularis muscle; the external, or radial, *g*, Fig. 3, extends round to the back of the bone, or anconal aspect, and has three smooth surfaces; the superior, *g*, Fig. 3, has inserted into it the supra-spinatus muscle; the middle one, g, Fig. 4, the infra-spinatus muscle; and the inferior posterior, or anconal, g, Fig. 4, the teres minor. The letters, *h*, indicate the fossa made by the long tendon of the biceps, and hence named bicipital; this is continued a little way further down the bone by two ridges extending from each tubercle; into the ridge, *m*, continuous with the inner or ulnar tubercle, is inserted the conjoint tendon of the latissimus dorsi and teres major muscles; and into the ridge, *n*, continuous with the outer or radial tubercle, the pectoralis major muscle: this last ridge extends downwards on the bone to *o*, and is then reflected upwards and outwards; and to this is attached the deltoid muscle. On the ulnar margin, opposite to this, is a scabrous surface, *i*, *i*, somewhat in continuation with the inner ridge, into which is inserted the coraco-brachialis muscle; and near this is seen the foramen, pointing downwards, that transmits the nutritious vessels. On each side of the rough triangular surface, *o*, into which the deltoid is inserted, the brachialis internus muscle arises, and continues to proceed from this aspect of the bone downwards to the condyles, *p*, *q*. On the posterior or anconal aspect, Fig. 4, is an interrupted ridge, *r*, *r*, almost continuous with the external large tubercle, from which arises the second head of the triceps; and from the ridge, *s*, *s*, arises the third head of the triceps: this united muscle passes downwards on the bone, adhering and rendering it smooth and somewhat flat, like the brachialis internus on the anterior aspect. Between the ridges which give origin to the second and third heads of the triceps, is a shallow spiral channel, *t*, *t*, made by the spiral nerve. From this point the bone is bounded by two sharp ridges, *k*, *k* and *l*, *l*, which terminate in the condyles, *p*, *q*; and to each of these ridges are attached intermuscular ligaments; to the external or radial, *k*, *k*, and the condyle, *q*, the supinator and extensor muscles; and to the internal or ulnar, *l*, *l*, and the condyle, *p*, the pronator and flexor muscles. From the highest part of the radial ridge at the upper *k*, arises, first, the supinator radii longus; secondly, the extensor carpi radialis longior and brevior; thirdly, the extensor digitorum communis; fourthly, the extensor carpi ulnaris; fifthly, the anconeus; and, lastly, the supinator radii brevis: and from this radial condyle also, there extends a strong lateral ligament, which is afterwards fixed to the neck of the radius, *c*, Fig. 6. The internal or ulnar ridge, *l*, and condyle, *p*, afford origin, first, to the pronator radii teres; secondly, to the flexor carpii radialis; thirdly, to the palmaris longus; fourthly, to the flexor digitorum sublimis; fifthly, to the flexor longus pollicis; and, lastly, to the flexor carpi ulnaris: and from this condyle also, a strong lateral ligament extends to the inside of the coronoid process, 4, of the ulna, Fig. 5. Behind this internal condyle is a fossa, v, made by the ulnar nerve.

Between these condyles is the trochlea or pulley, *b*, which in the posterior view, Fig. 4, appears single in consequence of the ulna only being articulated to it; and in this aspect the greater sigmoid cavity, *z*, is seen that receives the olecranon process, 5, Fig. 5. The anterior or palmar aspect of the trochlea, Fig. 3, appears double in consequence of both the ulna and radius being articulated to it: upon *d*, the smooth cup-like cavity, *e*, of the head of the radius plays; upon *b*, the ulna moves; and the lesser sigmoid cavity, *y*, receives the coronoid process, 3, of the ulna, Fig. 5.

The os brachii is articulated by its smooth head, *c*, through the medium of the synovial and fibrous capsules, powerfully strengthened and supported by the strong short muscles round the joint, and by the long tendon of the biceps which runs within the ligament. As there are no lateral ligaments, free and extensive motion is performed at this joint, which admits both of revolving and sliding. When the os brachii is raised to a right angle with the scapula, it cannot be raised higher, but by the scapula moving on the clavicle and the clavicle on the sternum. The scapula moves on the clavicle forwards and backwards, describing a curve round an axis; also outwards and inwards on another axis perpendicular to the first, and between the scapula and os brachii. The clavicle likewise moves on the sternum in a varied and extensive manner.

In consequence of the free motion allowed at the shoulder joint, the os brachii is peculiarly subject to dislocation. This takes place commonly downwards on the inferior costa, but towards one side of the long head of the triceps; and as there are several muscles on the outside to protect the joint, the head of the os brachii slips out between this head of the triceps and the subscapularis muscles. Dislocation also takes place beneath the last muscle and the venter of the bone, or the origin of the muscle; and below the spine of the scapula, beneath the infra-spinatus, or between it and the teres minor muscle. When dislocation occurs upwards, fracture of the acromion process must happen. In the reduction of the joint, the patient should be bled to syncope, in order to relax the muscles.

In the fetus, both extremities are cartilaginous, and the head with the two tubercles, and the condyles with the trochlea, become epiphyses before they are united to the shaft of the bone. This will be better understood by reading the description of the thigh bone, and examining Fig. 10, Plate IV. It is of importance to recollect that the head of the os brachii and the condyles are not united to the body of the bone till near puberty, as they are liable to be forced off and to be mistaken for fracture. In its structure, this bone resembles the other long cylindrical bones, see Plate IV., Fig. 10, with description. When the shaft is fractured, the direction is oblique and splintery; when the epiphyses are broken, the fracture is transverse; these extremes are subject to caries; the body to necrosis.

Figs. 5 and 6 represent the two bones of the fore-arm; the ulna is marked 1, 1, and the radius *a*, *a*. The ulna is the longer and the more triangular of the two, and resembles the other long bones in having a body, 1, 1, and two epiphyses or extremities, 6, 14; the larger extremity being proximad, the smaller distad. Its proximal extremity, or olecranon, has a flat triangular surface, 6, on which we rest, named ancon; on the radial aspect of this is another somewhat triangular surface, 7, 7, where the anconeus muscle is inserted and situated; the olecranon turns up and forms an acute point, 5, to correspond with the greater sigmoid cavity, *z*, of the os brachii, Fig. 4; and between this acute point and the ancon, the bone is roughened, 2, by the insertion of the triceps muscle. The digit 3, of Fig. 5, indicates the coronoid process into which the brachialis internus is inserted; a little below this, the bone is roughened to give a stronger insertion to the muscle, and between this and the olecranon, a large sigmoid cavity, 8, 8, is formed, divided by a longitudinal ridge to correspond with the trochlea of the os brachii: the small dark line across represents a fossa, which lodges mucilaginous glands. On the radial side of this, a small sigmoid cavity is observable where the button-like head, *d*, of the radius rotates; and around the brims of these two sigmoid cavities, the bone is rough where the capsular ligament, which surrounds the head of the radius and pulley of the os brachii, is implanted. On the side of the coronoid process, opposite to that where the less sigmoid cavity is situated, is a smooth depression where the flexor digitorum profundus begins to arise; and from each side of the coronoid process and olecranon, portions of both the flexors and extensors, and also a portion of the short supinator muscle arise.

The body of the ulna appears somewhat triangular in consequence of the action of these various muscles: the angle marked with the digits, 10, that points to the radius, and to which is attached the interosseous ligament, is the most acute. Near the proximal third, on the anterior or palmar aspect, the foramen, 11, Fig. 5, for the medullary vessels is seen, which slants upwards or proximad. From the anconal aspect, immediately below the insertion of the anconeus muscle, 7, the three extensor muscles of the thumb and the indicator arise, while the extensor carpi ulnaris is attached to the ridge or angle, 12, 12, nearly throughout. At the distal extremity, from the thenal or palmar aspect, an oblique ridge, 18, 18, extends round to the styloid process, 14, and gives attachment to the pronator quadratus muscle. The bone then terminates in a small round head with a cervix and process; on the radial side there is a smooth semilunar surface, 13, that rotates on a corresponding cavity of the radius, and is inclosed in a distinct capsular ligament, named sacciform, inserted into a rough edge around; and from the styloid process, 14, projecting from the head, there extends the strong external or ulnar lateral ligament of the wrist joint, to be attached to the cuneiform, *c*, and pisiform, *d*, bones of the carpus. On the anconal aspect, between this styloid process, 14, and the smooth articular surface, 13, is a small groove, 15, made by the extensor carpi ulnaris. A similar groove, 16, is observable between these on the thenal or palmar aspect, made by the ulnar nerve and artery. Pointing directly distad, is a small semicircular smooth surface, 17, which moves on the cuneiform bone, *c*, of the carpus, and between these is interposed a doubly concave moveable cartilage.

In the fetus the ulna consists of its body and two cartilaginous epiphyses; its structure, therefore, resembles precisely that of the other long bones, see Plate IV., Fig. 10, with description. Its fracture also corresponds with theirs. In dislocation of the radius and ulna forwards on the palmar aspect of the os brachii, the olecranon process is commonly fractured in consequence of its length and the great power of the triceps muscle which retains hold of the bone; and the fracture is transverse. This bone is also subject to necrosis in its body, and to caries in its extremities; and the proximal extremity on which we lean, or the ancon, is very subject to exostosis in the syphilitic constitution.

The radius marked *a*, *a*, in Figs. 5 and 6, forms the other bone of the fore-arm, and like the ulna consists of a body and two extremities; but the upper extremity, *d*, is smaller than the lower or distal, *s*. The letter *d* indicates the smooth circular surface, the ulnar half of which rotates in the smaller sigmoid cavity of the ulna, the whole being surrounded with a thickening of the capsular ligament, named coronary ligament; *e*, the cup-like cavity which moves on the outer surface, *d*, of the trochlea of the os brachii, Fig. 3; *c*, the cervix around which the capsular ligament of the elbow joint is implanted; and *b* the tubercle into which the tendon of the biceps is inserted. Extending downwards from this, on the palmar aspect outwards to the radial edge, is a delicate ridge, *f*, into which the supinator radii brevis is inserted, and from which the flexor pollicis longus begins to arise; and in a manner continuous with this ridge, about the middle of the bone, and somewhat on the anconal aspect of the radial ridge, is a scabrous surface, *g*, into which the pronator radii teres is inserted. Below the ridge, *f*, and beneath the origin of the flexor longus pollicis, the passage, *i*, for the medullary vessels is seen slanting upwards. The body of the bone is flattened on this palmar aspect, as well as on the anconal aspect, by the different muscles of the fore-arm, while it is rounded on the radial by the extensor muscles of the thumb; and towards the ulnar aspect the bone terminates in an acute angle, letters *h*, to which is attached the interosseous ligament. This ligament is deficient between the proximal extremities of the bones, where there is no acute edge on either bone.

The radius terminates in an end, larger and broader, distad than proximad; and near this end, on the palmar aspect, the bone is flat, and a little rough at *k*, where the pronator quadratus is inserted. Radiad to this at *l*, a little rough surface is observable, into which the supinator radii longus is inserted. On the anconal aspect, the extremity is divided by a small tubercle, *n*, which extends proximad so as to form a ridge; ulnad to this a small groove, *o*, is made by the tendon of the extensor secundi internodii pollicis; and between this and the ulna is a larger groove, *p*, made by the extensor digitorum communis and indicator muscles: on the radial side of the little tubercle, *n*, is a corresponding broad depression, *q*, sometimes divided into two, made by the two radial extensor muscles; and still more radiad to the last is a small groove, *r*, made by the other two extensors of the thumb. Near this groove, *r*, the bone projects so as to form a styloid process, *s*, from which extends the radial or internal lateral ligament, to be attached to the os naviculare, *a*, of the carpus. The radius then forms an irregular oblong cavity, *t*, named the greater sigmoid, that receives the os navicular, *a*, and os lunar, *b*, of the carpus; and around this smooth surface there is a ridge that gives attachment to the capsular ligament, which after surrounding the

smooth surfaces of these two bones, and the cuneiform bone of the wrist is implanted into them. On the ulnar aspect of this cavity is a smaller, of a semilunar shape, *z*, named the lesser sigmoid cavity, to receive the distal end, 13, of the ulna; and around which is attached the sacciform ligament.

In its fetal state, and in its structure, the radius corresponds with the ulna: and excepting not being subject to exostosis in the syphilitic constitution, is liable to the same diseases.

These two bones enter into the formation of the elbow joint by their proximal ends, and are firmly articulated to the trochlea of the os brachii, by synovial and fibrous capsules and lateral ligaments, and powerfully supported by muscles; therefore, flexion and extension only are allowed. This forms one of the best specimens of the ginglymoid or hinge-like joint, and admits only of a sliding motion. Dislocation may take place either forwards or backwards; the latter, however, is much the more frequent: when the bones of the fore-arm are forced forwards or palmad, the olecranon, as previously observed, is usually fractured. If the injury done be so great as completely to dislocate these bones laterally, amputation generally becomes necessary. Sometimes an incomplete dislocation laterally occurs. In children, the head of the radius is dislocated sometimes backwards, at others forwards; and this end of the ulna has been displaced individually backwards. The distal extremity of the radius is not so often displaced as the distal end of the ulna; and this takes place either forwards or backwards. Pronation, or the palm of the hand turned downwards, is performed by the head of the radius rotating on the lesser sigmoid cavity of the ulna, and by the distal end of the radius revolving on the smooth distal extremity of the ulna. Supination, or the palm of the hand turned upwards, is performed by the same surfaces. In each of these motions, however, the whole arm is generally called into action.

Figs. 7 and 8 are representations of the bones of the hands; Fig. 7 is a posterior or anconal view, and Fig. 8 a palmar or thenal view. The bones of the hand are divided into those of the carpus, which are eight in number, *a*, *b*, *c*, *d*, *e*, *f*, *g*, *h*; into those of the metacarpus, which are five in number, and are marked 1, 2, 3, 4, 5; and into those of the phalanges, which are three to each finger, 7, 11, 16; 8, 12, 17; 9, 13, 18; 10, 14, 19, excepting the thumb, where there are only two, 6, 15.

Of the bones of the carpus, *a* is the os scaphoides or naviculare, *b*, the os lunare, *c* the os cuneiforme, *d* the os pisiforme, *e* the os trapezium, *f* the os trapezoides, *g* the os magnum, and *h* the os unciforme. The scaphoides and lunare have each a smooth convex surface, where the letters *a* and *b* are placed, by which they are articulated to the radius in order to form the wrist joint; and around these surfaces the bones are rough for the firm adhesion of the capsular ligament. The scaphoides, *a*, is articulated to the lunare, *b*, by a semilunar plane, to the magnum, *g*, by a smooth concavity, and to the trapezoides, *f*, and trapezium, *e*, by a small convex surface. All these surfaces have synovial and fibrous capsules surrounding them, and strong transverse ligaments passing from one bone to another. As this ligamentous arrangement pervades the bones of the carpus, I shall not mention them individually. This bone, as already noticed, affords attachment to the radial lateral ligament.

The os lunare, *b*, exhibits its convex surface where it enters into the formation of the wrist-joint, as already mentioned, and is articulated to the scaphoides, *a*, by a crescentic plane. This bone also contributes, by a semilunar concavity, to form the socket for the head of the os magnum, *g*, and is articulated by a narrow oblong sinuosity to the os unciforme, *h*, and by a small convexity to the os cuneiforme, *c*.

The cuneiform bone, *c*, has a concave surface corresponding to that of the lunare, to which it is joined; a small slightly convex surface opposed to the lower end of the ulna, on which it moves through the medium of an interarticular cartilage, and which the capsular ligament of the wrist joint surrounds; an oblong and somewhat spiral concavity, by which it is articulated to the unciform bone, *h*; and a circular plane for articulation with the pisiform bone, *d*. Its ulnar and somewhat anconal aspect, is rough for the attachment of the ulnar lateral ligament of the wrist joint.

The pisiform bone, *d*, is attached only to the last bone. It affords attachment to the same lateral ligament as the cuneiform bone, and affords insertion to the flexor carpi ulnaris; contributes to give attachment to the palmar annular ligament, which is stretched between this bone, the unciform bone, *h*, and the trapezium, *e*; gives origin to the abductor minimi digiti muscle; and has a small depression on its radial aspect, formed by the ulnar nerve.

The os unciforme, *h*, has a surface corresponding to that of the cuneiform bone, *c*, to which it is articulated, only irregularly convex; a small convexity to correspond with the sinuosity described under the os lunare, *b*; a long and slightly convex surface adapted to the os magnum, *g*; and two small concave surfaces at its distal extremity, on which rest the metacarpal bones of the little, 5, and ring, 4, fingers. From its palmar aspect projects a thin broad process resembling a hook, the radial aspect of which is hollow, to afford passage to the tendons of the flexor muscles of the fingers, which are held in position by the annular ligament attached to this process. The flexor and adductor muscles of the little finger partly arise from this process.

On the ulnar aspect of the os magnum, *g*, is a concave surface to correspond with that of the bone last described, to which it is articulated. Its round head corresponds with the concavity formed between the lunar, *b*, and scaphoid, *a*, bones. Its distal aspect supports three of the metacarpal bones: that, 4, of the ring finger forms a small flat surface; that, 3, of the middle finger, rests on a large triangular surface; and that, 2, of the fore finger, makes a considerable oblong depression, only seen in the palmar view. On the radial side a short plain surface joins this bone to the os trapezoides.

The trapezoides, *f*, has a small surface corresponding with that of the last bone; a distal, convex, angular surface, which sustains the metacarpal bone, 2, of the fore finger; a long convex surface by which it is articulated to the trapezium, *e*; and a small hollow surface for connexion with the scaphoides, *a*.

The trapezium, *e*, has an oblong concave square to correspond with the trapezoides, *f*; a smooth semicircular slightly concave surface for connexion with the scaphoides, *a*; a small oblong smooth surface formed by the metacarpal bone, 2, of the fore finger; and a pulley-like surface by which it is articulated to the metacarpal bone, 1, of the thumb. On its palmar aspect, is a projection that gives attachment to the palmar annular ligament, and the abductor pollicis and flexor ossis metacarpi pol-

licis muscles. Between this elevation and the palmar aspect of the bone, is a groove made by the flexor carpi radialis muscle.

The wrist joint, the formation of which has been described, admits of flexion and extension, and a lateral and slightly rotatory motion; all performed chiefly on the sliding principle. By some the lateral motions are termed abduction and adduction; the combination or rotation, named circumduction. This is not so marked a ginglymoid joint as that of the elbow. Although strongly protected by ligaments and muscles, yet from the free motions this joint performs, and its exposed nature, dislocation frequently occurs: this takes place in every direction, but that backwards or anconad is the most common, partly owing to the nature of the accident which generally occasions it, and partly from the brim of the cavity of the radius not being raised so much anconad as palmad.

The bones of the wrist are so articulated as to form an arch, which is well supported by ligaments, and to allow only a yielding motion; excepting between the scaphoides lunare and cuneiforme on the one side, and the trapezium, trapezoides, magnum and unciforme, on the other, where a ginglymoid joint is formed, and where motion forwards and backwards takes place, which increases considerably the motions of the wrist. From the strong arched connexion of these bones, they are scarcely ever displaced; the os magnum alone has been known to be forced anconad, the only direction in which any of them can be dislocated.

The carpal bones are all cartilaginous at birth, and in their structure resemble the bodies of the vertebræ, so that when one is attacked with caries the disease rapidly spreads to all, which is by no means unfrequent in the scrofulous constitution.

The bones of the metacarpus are five in number, and are marked 1, 2, 3, 4, 5. They resemble the long cylindrical bones in having a body and two epiphyses, the latter of which are cartilaginous at birth. Their bodies are flattened on their anconal aspect, acutely angular in their palmar aspect, and depressed on each side between these surfaces. Their proximal extremities or bases are enlarged and of a triangular shape, somewhat hollowed to correspond with similar surfaces on the carpal bones, to which they are articulated by synovial and fibrous capsules and transverse ligaments, like the carpal bones themselves. They are also flat and smooth on the sides where they are contiguous to each other. Their distal extremities or heads are enlarged, and have smooth oblong surfaces by which they are articulated to the roots of the first phalanx, 7, 8, 9, 10; and round these smooth surfaces a rough edge affords attachment to synovial and fibrous capsules. On each side of these heads are little tubercles, to which are attached transverse ligaments, which tie them together. Close to these tubercles are small depressions, to which are fixed lateral ligaments. The metacarpal bone, 1, of the thumb, differs from the others in having a shorter body, a flatter head, and a pulley-like surface on its base, to correspond with a similar surface of the trapezium, *e*: both of these surfaces are surrounded with a synovial membrane and a strong fibrous capsule, and perform free motion, as flexion, extension, and rotation; some describe adduction and abduction, the rotation being named circumduction; hence this joint is liable to be dislocated, and the direction is either anconad or palmad. In the skeletons of old labourers, two small bones, named sesamoid, are generally found on the palmar aspect of the head of this metacarpal bone, at 20, Fig. 8. I have already described the manner of articulation of the other metacarpal bones with the carpal, excepting that they have synovial and fibrous capsules and transverse ligaments, in consequence of which little motion is allowed. That of the little finger has most; next that of the ring finger; then that of the middle; and last of all that of the fore finger. Dislocation of these articulations has never taken place. The metacarpal bone, 2, of the fore finger is generally the longest; into the anconal aspect of its base, the long head of the extensor carpi radialis is implanted, and to the opposite aspect, or palmar, is attached the flexor carpi radialis: the tubercle on the radial side of its head is the larger of the two. The metacarpal bone of the middle finger is generally the second in length, but it is often as long as, or even longer than the preceding, which sometimes arises from the os magnum not advancing so far distad as it generally does. The fact of these bones, as well as the carpal bones, varying a little in their size and connexions, is of some consequence to be known by the operator, otherwise he may be deceived when one of them requires to be extirpated. To the anconal aspect of the base of this bone is attached the short head of the extensor carpi radialis; and to the anconal and somewhat ulnar aspect of the base of that of the little finger is attached the extensor carpi ulnaris.

As the structure of these resembles that of the long cylindrical bones, their diseases are the same. They are very subject to necrosis.

The bones of the first phalanx, 6, 7, 8, 9, 10, resemble the metacarpal bones in having a body and two epiphyses, which latter are cartilaginous at birth. Their proximal extremities or bases have oblong cavities, to correspond to the heads of the metacarpal bones, with which they are articulated by capsular and lateral ligaments; the former are attached all round the smooth surfaces of both bones, and the latter to the little elevations or tubercles on each side. The bodies of these bones are convex on the anconal aspect, in consequence of the expanded tendons of the extensors, and slightly concave, or flat, on the palmar, by the flexor tendons, with a ridge on each side, marked 21, to which the vaginal ligaments of these flexor tendons are attached. The distal ends have a trochlear or pulley-like surface, and a central depression with a lateral elevation, to correspond with the proximal ends of the bones of the next phalanx; and around these are attached capsular ligaments. There are small lateral tubercles for lateral ligaments. The proximal ends, with the metacarpal bones, perform free motion, as flexion, extension, and slight rotation, excepting that of the thumb, which is limited in this latter motion. These joints are sometimes dislocated, the base of the first phalanx being forced either anconad or palmad. They are also dislocated in the other directions, but not so frequently. In their structure, and consequently in their diseases, they resemble the metacarpal bones.

The bones of the second phalanx, 11, 12, 13, 14, of which the thumb has none, resemble those of the first phalanx, excepting in their proximal ends or bases, where the articular surface has two lateral cavities and a middle elevation. They are also short, and have slight rough surfaces, marked 22, to which the tendons of the flexor sublimis are attached. The mode of articulation is the same as that of the first phalanx, but the joint admits only of flexion and extension. The fetal state, the struc-

ture, and the diseases, are the same as those of the first phalanx; but their proximal extremities are more frequently displaced than their distal ends, or even than those of the first phalanx. The direction is generally palmad.

The bones of the last phalanx, 15, 16, 17, 18, 19, are still shorter than the last. Their articular surfaces resemble the proximal ones of the preceding phalanx; therefore, these two series of articulations correspond with each other. Their palmar aspects are rough at 23, to afford insertion to the tendons of the flexor profundus. Their distal ends are tipped with an arched scabrous surface, to give support to the delicate tissue of nerves, vessels, and fat, where sensation chiefly resides. Their anconal aspects are smoother, to give rest to the nails. The joint formed by the proximal ends of this last series of bones, precisely resembles the contiguous articulation, and admits of only flexion and extension: like it, this joint can be dislocated in every direction, and like it, too, generally palmad. In the fetal state, its proximal extremity is cartilaginous, and continues an epiphysis till maturity.

When we take a review of the upper extremity, we perceive how well the hand is adapted for prehension, and how by multiplying the motion of the phalanges by all the other motions of the extremity, so great a variety of motions is performed; for they even extend to the motion of the clavicle on the sternum. We also find, that when the trunk is fixed, we can bring objects to, or push them from it; and when the fingers are made the fixed point, that we can bring the trunk to, or remove it from them.

PLATE VIII.

BONES OF THE LOWER EXTREMITY.

Figs. 1 and 2 have been already described along with Plate III., as they refer to the same subject.

Fig. 3 is a representation of the anterior or patellar aspect of the thigh bone; *a*, *a*, is the body or shaft of the bone, of a smooth round shape, with a rough line* posteriorly or poplitead, extending longitudinally, as seen in Fig. 4, *a*, *a*. The extremes of the bone are named epiphyses, and are analogous to all the long bones. Fig. 4, the posterior view, will also be here described. At the upper extremity, where the os femoris is articulated to the acetabulum of the os innominatum, is the head, *b*, which is smooth and round to correspond to that cavity. Nearly in the centre, a little inwards or pubic, where the bone is articulated, is a small circular depression, *c*, that gives attachment to the round ligament fixed by its other extremity to the acetabulum. This attachment of the ligament should be considered in reference to amputation of the hip-joint. At the root of the head the bone is smaller in circumference, and is termed the cervix, *d*, which extends to the shaft of the bone, and is bounded by two large processes, the trochanter major, *e*, and the trochanter minor, *f*, and by a ridge extending between both of these, anteriorly, *g*, and posteriorly, *h*. The capsular ligament, arising round the acetabulum, begins to be attached at the root of this cervix, near the trochanters and ridges; and adhering closely to the bone, ascends and terminates around the root of the smooth head. The angle formed by the neck and body of the bone should be considered in amputation at the hip-joint.

The trochanter major, *e*, has three flattened surfaces: the anterior, where *e*, Fig. 3, is placed, gives insertion to the gluteus minimus; **e**, the superior surface, gives insertion to the gluteus medius; and the posterior, e, is made by the gluteus maximus passing over it, and which is inserted in the outer division of the linea aspera, **a**, **a**. The trochanter minor, *f*, gives insertion to the psoas magnus and iliacus internus muscles, and the posterior ridge, *h*, that extends from the trochanter major continuous with linea aspera, gives insertion to the quadratus femoris muscle. The anterior ridge, *g*, is caused by the capsular ligament and part of the origin of the crureus muscle. Into the pit or rut, at the root of the trochanter major, *i*, are implanted several muscles, viz. the pyriformis, obturator externus, and obturator internus, with the two gemelli.

The superior internal, or tibial division of the linea aspera, a, gives insertion to the pectinalis muscle; and from the insertion of the quadratus muscle, along the linea aspera to the tubercle, *k*, behind the internal condyle, are inserted the three adductors, or heads of the triceps muscle. Near the beginning of this lower internal ridge is a discontinuation of the linea aspera, *l*, where the superficial femoral artery with its vein passes between the bone and the tendon of the triceps. From the whole of the inside of the linea aspera, more inwards, or tibiad, than the triceps, originates the vastus internus. From the whole of the outside of the linea aspera, more outwards than the insertions of the gluteus maximus and triceps, arises the vastus externus, which muscle proceeds also from the outer division of the linea aspera, ending at the external condyle. The crureus, which is strictly the central portion of the two vasti, arises from the anterior ridge, *g*, and the anterior aspect of the body of the bone, *a*, *a*, and hence these three muscles nearly surround the bone. The linea aspera, at its centre, *a*, *a*, also gives origin to the short head of the biceps, which lies between the insertion of the triceps and origin of the vastus externus. At the upper part of the linea aspera is seen the foramen, *o*, where the medullary vessels enter and proceed obliquely upwards. The linea aspera divides inferiorly as well as superiorly; and at the termination of each of these divisions is a small tubercle, *k*, *p*; into the internal or tibial, *k*, as I have already observed, the termination of the tendon of the triceps muscle is inserted. Immediately below, or distad to this, is a small smooth surface, *r*, from which arises one of the heads of the gastrocnemius externus. To the inner or tibial aspect of this tubercle is attached the internal lateral ligament. Two of the inner ham-string muscles generally make a slight depression at this point. From the external or fibular tubercle, *p*, arise the other head of the gastrocnemius externus and the plantarius, as well as the external lateral ligament; and the bone is also depressed by the outer ham-string muscle. The fossa, *s*, affords origin to the popliteus muscle. Distad to each of these small tubercles, the bone ends in a large protuberance, named condyle, *m*, *n*, which is smooth and circular for articulation with the head of the tibia, *c*, *c*, Fig. 8. Each smooth surface of a condyle is divided into two parts: *m*, *n*, Fig. 4, indicate the surfaces which move on the tibia; while *m*, *n*, Fig. 3, point out those on which the patella, Fig. 6, moves, where a correspondence of surfaces is observable. Thus *n* of the patella is applied to *n* of the os femoris, Fig. 3; and hence the external condyle is the

* This is generally termed linea aspera.

highest and largest. From the oblique position of the bone, the internal condyle is the longest, while it gives less obliquity to the leg. The surfaces on each condyle are indistinctly separated, those of the external by a slight notch, and those of the internal by a small elevation. Between these condyles is a considerable cavity, *t*, in which the crural vessels and nerves lie immersed in fat in the fresh state; and between this large notch and the lower bifurcation of the linea aspera, the bone is flattened by the same objects. To each side of this notch is fixed a strong ligament, termed crucial, extending to the elevation on the head of the tibia, *b*, Fig. 8. The anterior is attached to the external or fibular depression in the side of the notch, the posterior to the internal or tibial depression, which is more superficial than the other. The letter *t* points to these depressions. Round the smooth surfaces of the condyles is a slight roughness to which the capsular ligament is attached, so as to include in the same joint the two surfaces, *m*, *n*, of the patella, Fig. 6. Exterior to the capsular ligament, between the letters *n*, *p*, Fig. 4, arises, from the external condyle, the posterior ligament, styled popliteal, which crosses the posterior part of the articulation, adheres to the capsular ligament, and terminates at the superior, posterior, and internal part of the head of the tibia.

In the fetal state the os femoris is cartilaginous in all its processes, an idea of which may be formed from Fig. 10, Plate IV., in which the section of the adult bone shows the lines where the cartilage unites the epiphyses that grow upon the body or shaft, and which are marked *a*, *a*, *b*, *b*, *c*, *c*.

The os femoris is articulated by its head to the acetabulum, R, Fig. 2. of the os innominatum, by a very strong capsular, and by a round ligament; and, as was remarked under the description of the os innominatum, page 8, we should imagine dislocation of this joint to be of rare occurrence. By the lower surfaces of the condyles, this bone is articulated to the tibia, by synovial and fibrous capsules, by strong lateral, by the popliteal, and by crucial ligaments; anteriorly the joint is strengthened by a strong tendinous expansion of muscles, and, posteriorly, by tendons of muscles. From this strong attachment, and the configuration of the joint, which resembles a hinge, and is one of the ginglymoid class, it admits of only flexion and extension; while rotation can only be performed to a very trifling extent, when the knee is bent, or in the sitting posture. For these reasons, dislocation is very rare; and when it does occur, such injury is done to the joint itself, and the neighbouring parts, that violent inflammation follows, and almost always terminates in suppuration; so that the practitioner has, in such a case, to consider the propriety of amputation. The injuries of this joint, whether from cannon shot, musket bullets, bayonets, pen-knives, or forks, or from severe bruises occasioned by falls, are generally followed by such extensive inflammation, that, in defiance of the lancet, leeches, cold or warm applications, suppuration and hectic fever too often ensue and carry off the patient. The great extent of delicate surface in this joint should be well considered by the practitioner.

The structure of the thigh bone is displayed in Plate IV., Fig. 10, which has been selected, as it best illustrates the variety found in the long cylindrical bones. Thus we observe, that the shaft or body, letters *d*, consists of a thick cylinder of bone, with few osseous cancelli, while the extremes, *a*, *b*, and *c*, have a delicate bony shell, and numerous delicate cancelli, like the body of a vertebra, Fig. 7. The letters, *a*, *a*, *b*, *b*, and *c*, *c*, point out delicate white lines where the epiphyses are separated by cartilage in the fetal state, and which do not become obliterated by bony union till puberty, from which cause it happens that in early life the head is sometimes displaced and mistaken for fracture. This should be taken into consideration in accidents at this period of life. In structure the extremities, or epiphyses, precisely resemble the vertebræ and other irregular round bones, and consequently, when the head, neck, or condyles are broken, the fracture is transverse; and as the bone is delicate, it seldom unites by osseous junction. When the fracture occurs within the capsular ligament of the hip-joint, the synovial juice contributes to prevent union.*

When the body, *d*, is fractured, the direction is oblique and splintery, and, from the density, bony union readily takes place.

The hip-joint, as already observed, is subject to dislocation, and to the disease named morbus coxarius; the trochanters as well as the head are liable to exostosis and to caries: the condyles are equally subject to caries, particularly in white swelling of the knee-joint, and then anchylosis sometimes ensues, which is much to be desired in this case. Exostosis scarcely ever takes place here. The body of the bone is liable to necrosis, to exfoliation, to spina ventosa, and lastly to caries.

Fig. 5 is an external view of the patella, rotula, or knee-pan: into *a*, *a*, are inserted the rectus and crureus muscles; into *b*, the vastus internus; and into *c*, the vastus externus muscle. To *d* is attached the strong patellar or anterior ligament of the knee-joint, the other end being fixed to the tuberosity, *d*, of the tibia, Fig. 7. The surface of the patella, where this ligament is attached, is better seen in Fig. 6, which exhibits an internal or popliteal view of the bone. The same letter, *d*, points out the rough surface. All round the margin of the bone, letters *e*, Fig. 6, is attached the capsular ligament of the knee-joint, so as to include in the cavity the surfaces, *n*, *m*, which, as I have already remarked, are applied to *n*, *m*, Fig. 3, of the os femoris: hence *n* is the external and larger surface. Between these two surfaces, *m*, *n*, there is an elevation which corresponds with the depression between the anterior superior surfaces of the condyles of the os femoris.

The patella in the fetal state is cartilaginous, and remains so longer than any of the epiphyses of the long bones.

In the description, the attachments of the bone have been already mentioned. From the unyielding nature of the patellar ligament, the patella moves along with the tibia in the motions of the knee-joint; and owing to these strong connexions, is seldom dislocated, and never unless the leg be extended. Dislocation is generally outwards, which proceeds, not from the articulation, but from the nature of the injury necessary to produce this accident. Fracture much more commonly occurs, and is almost always transverse. The structure is represented in Plate IV., Fig. 8, from which it will be understood that the bond of union after fracture is ligamentous or fibro-cartilaginous; but when the fracture is perpendicular, bony union takes place. In its diseases the patella resembles the vertebræ, or rather the bodies of the vertebræ, and other round bodies.

* Several instances of bony union of the neck of the os femoris, when fractured within the joint, are now recorded.

Fig. 7 is an anterior or patellar view of the tibia and fibula, and Fig. 8 is a posterior or popliteal view. The larger bone, which is situated on the inside of the leg, is the tibia, as seen in the connected skeleton, Plate I. The tibia is of a triangular shape, but still resembles the other long cylindrical bones in appearance and structure. The letters *a* indicate the anterior or patellar angle or spine, termed in common language the shin; *d*, the tuberosity to which the patellar ligament is attached; and *c*, *c*, the head of the bone divided by *b*, a considerable irregular eminence, into two smooth oval depressions for the reception of the condyles, *m*, *n*, Fig. 4. These depressions, which are not equal, the internal being deeper and more oblong, are deepened in the fresh state, by two corresponding semicircular cartilages attached to *b*, to one another, and to the condyles of the os femoris and capsular ligament, which is attached all round the head of the tibia. The elevation, *b*, gives attachment also to the two crucial ligaments connected with the notch between the condyles of the os femoris. On the inside of the tuberosity, *d*, is a broad rough surface, *e*, into which the aponeurosis of the vastus internus, the sartorius, gracilis, and semitendinosus muscles are inserted, and to which the internal lateral ligament is attached. The attachment of these muscles should be considered by the operator in amputation of the leg. Posteriorly or poplitead to this, there is an elevation, *f*, to which another ham-string muscle is attached, viz. the semi-membranosus: *g*, another elevation, a little fibulad, gives attachment to part of the posterior crucial ligament; a little more fibulad to which is a slight depression or groove made by the popliteus muscle, as it passes down to be inserted into the oblique ridge, letters *k*, and smooth surface, letters *i*; and still more fibulad is a small flat circular surface, *h*, looking downwards, or distad, to which the head, 2, of the fibula is attached.

Between the patellar or anterior angle, letters *a*, and the fibular angle, letters *m*, arises the greater portion of the tibialis anticus muscle; and from the angle, letters *m*, to the opposite angle, 4, 4, 4, of the fibula, is stretched the interosseous ligament. At the ridge *k* the foramen *n* is seen, which points downwards and transmits the nutritious vessels; and from the lower margin of this ridge, and from the angle, letters *o*, in continuation, which is the posterior tibial, arise one of the heads of the gastrocnemius internus, part of the tibialis posticus, and flexor longus digitorum muscles. These render the bone flattened between letters *o* and *m*, and, in passing round the inner ankle, or malleolus internus, *q*, to the foot, make the grooves, *n*, *p*: *n* is made by the action of the tibialis posticus and flexor longus digitorum pedis; and *p* by another muscle, which arises chiefly from the fibula, viz. the flexor pollicis longus. At *q*, the malleolus internus, is a small notch, to which the chief portion of the internal lateral or deltoid ligament of the ankle joint is attached; the other end being fixed to the inside of the astragulus, *a*, and naviculare, *b*, of the foot, Fig. 9. This end of the tibia has a large smooth hollow cavity, *r*, *r*, that forms the greatest part of the cavity adapted to receive the smooth head of the astragalus, *a*, Fig. 9. On the fibular aspect of this, at *s*, is a rough depression that receives the distal extremity, 9, of the fibula.

In the fetal state the tibia resembles the other long bones; in the adult state it also resembles them in its configuration, as well as in its structure and diseases. Its anterior angle, letters *a*, and tuberosity, *d*, are very subject to exostosis in the syphilitic constitution. This bone is also most liable to necrosis.

The fibula I shall describe before the attachments of the tibia, as the former enters into the formation of the ankle-joint. We observe that the fibula, marked 1, forms the outer bone of the leg, which is the smaller of the two and of an irregular triangular shape. The digits, 1, indicate its exterior angle, rounded by the action of the two peronei muscles, to which it gives origin; the digits, 4, mark the tibial angle to which the interosseous ligament is fixed. From the anterior or patellar aspect between these angles arise the extensor longus digitorum pedis, and inferiorly or distad the extensor proprius pollicis pedis. From the popliteal aspect, between the angles superiorly at 6, arises the outer head of the gastrocnemius internus; distad to this, part of the tibialis posticus; and still more distad, the flexor pollicis longus. About the middle of this surface is seen the entrance, 3, for the medullary vessels, slanting downwards. The digit, 2, is the proximal extremity, which has a smooth surface, corresponding to that of the tibia, to which it is articulated by capsular and strong transverse ligaments, so that only a slight sliding motion backwards and forwards is allowed. On the outside of this, it is rough and protuberant, where the tendon of the biceps and the external lateral ligament of the knee-joint are attached.

The distal extremity, 9, is oblong and spongy, and terminates in a rounded point, named the coronoid process, or malleolus externus, 10, which projects further downwards, or distad, than the malleolus internus; to this is attached the external lateral ligament divided into three parts, the anterior of which is attached to the forepart of the astragalus, *a*, Fig. 9; the middle, termed perpendicular, to the os calcis; and the posterior to the back part of the astragalus. This process is smooth at 11, where it is opposed to a corresponding smooth surface of the astragalus, a, by which it enters into the formation of the ankle-joint. At 12 is a rough irregular cavity, where mucilaginous glands are lodged, and at 13, there is generally a groove formed by the two peronei muscles passing round to the foot.

Under the description of the thigh bone, the manner of articulation of the upper end of the tibia, and the diseases to which it is liable, were detailed. The manner of articulation between the head of the tibia and fibula has been also described, and so strong are the transverse ligaments, that the bones are scarcely ever displaced. The two bones are tied together with equal strength at their distal extremities, and seldom separated. Round the smooth surfaces, both of the tibia and fibula, where they enter into the formation of the ankle-joint, is attached a synovial capsule, surrounding the smooth surface, *a*, of the astragalus, Fig. 9, and inserted into a rough surface round it. There are also strong lateral ligaments. From the manner in which the astragulus is thus received and held in position, dislocation seldom occurs without fracturing either the malleolus internus or externus, or both; most frequently the latter, or the fibula a little higher up: in this accident the dislocation is lateral, and generally inwards. Dislocation forwards or backwards may take place without fracture of the bones.

From the structure of the fibula, which is analogous to that of the os femoris, this bone resembles it in the line of fracture when broken, as also in its diseases. In the fetal state the fibula likewise resembles the os femoris and other long bones.

Fig. 9 is a representation of the bones of the foot,

which are divided into those of the tarsus, seven in number, *a, b, c, d, e, f, g;* into those of the metatarsus, five in number, 1, 2, 3, 4, 5; and into those of the phalanges, three to each toe, 8, 9, 10; 11, 12, 13; 14, 15, 16; 17, 18, 19; and two to the great toe, 6, 7. I have not given individual specimens, as they are extremely difficult to comprehend separately, and of little practical utility even if it were otherwise. The letter *a* indicates the os astragalus; *b*, the os naviculare; *c*, the os calcis; *d*, the os cuneiforme internum; *e*, the cuneiforme medium; *f*, the cuneiforme externum; and *g*, the os cuboides.

The astragulus has a large smooth surface, *a*, flattened on each side by the action of the malleoli, or the distal processes of the tibia and fibula: a, indicates that which moves on the smooth surface, 11, of the fibula, Fig. 7, and is much larger than the internal or tibial surface. All round this, the bone is smooth for the insertion of the synovial capsule of the ankle-joint, and rests on the os calcis *c*, by two smooth surfaces, between which is a rough groove for attachment to strong ligamentous bands passing between it and the os calcis: at *k*, there is a depression made by flexor digitorum longus. Distad or anterior to the fibular of the two surfaces which rest on the os calcis, is a smooth surface looking to the sole of the foot, and resting on a strong broad ligament which extends between the os calcis and os naviculare. The distal or forepart of this bone is formed into an oblong smooth process, *m*, that is received into a corresponding depression of the os naviculare, *b;* around which smooth surface is a rough fossa giving attachment to a capsular ligament. Its connexions have already been described; and its diseases, as well as those of the other tarsal bones, will be taken notice of when the description has been completed. In the fetus, a considerable portion of this bone is ossified.

The letter *c* is the os calcis, and points to the most projecting part of the bone, where the tendo-achillis, the united fibres of the four heads of the gastrocnemii, and the tendon of the plantaris muscles are inserted. Towards the tibial aspect or sole of the foot, near where it is articulated to the distal or anterior of the two surfaces of the astragalus, is a strongly marked fossa, *k*, made by the flexor pollicis longus; between this and the tibial of the two surfaces by which it is articulated to the astragalus, the bone is rough where the powerful ligament that supports the astragulus is fixed. Nearer the sole of the foot, the bone is made hollow by the flexor muscles and vessels from the leg; and from this hollow, the musculus accessorius flexoris longi digitorum proceeds. On the plantar aspect where the bone forms the resting point of the arch, there is a considerable protuberance, which in some measure is divided into two; the internal or tibial gives origin to the flexor brevis digitorum, the abductor pollicis, and part of the plantar fascia; and the external or fibular gives origin to the abductor minimi digiti and rest of the fascia. The same surfaces, corresponding with those of the astragalus, are here formed, with a similar fossa between them. In the plantar aspect, near its junction with the os cuboides, are a protuberance and depression that give attachment to the strong external plantar ligament extending to the os cuboides At r, where it is articulated to the os cuboides, is a smooth pulley-like surface; and between the astragalus and os calcis, at this part, is a large hollow where mucilaginous glands are lodged.

A large portion of the os calcis is ossified in the fetus, and the extremity, *c*, becomes afterwards an epiphysis.

The os naviculare, *b*, has an oblong concavity, corresponding with the process, *m*, of the astragalus. At the tibial aspect there is a considerable knob, into the plantar surface of which the tibialis posticus muscle is inserted; this should be considered by the operator in injuries of the toes requiring amputation, as the preservation of this bone would assist in the extension of the ankle-joint: to this knob, or eminence, are also attached part of the abductor pollicis and two ligaments of the sole of the foot; the one, namely, the internal plantar ligament, has been already mentioned; the other extends to the roots, or proximal extremities of the metatarsal bones of the middle toe, and the toe on its fibular side. Still more plantar to this knob or eminence, the bone is hollowed, in order to lodge the muscles. The distal or anterior aspect has three smooth planes, 1, 2, 3, affording articulation to the three cuneiform bones: *n* indicates a semicircular smooth surface where it is joined to the os cuboides. The naviculare is entirely cartilaginous in the fetus.

The os cuneiforme internum, *d*, is the largest of the three cuneiform bones: at the point where the letter is placed, the tibialis anticus muscle is inserted; a circumstance deserving the consideration of the operator, as the preservation of this bone would ensure to the patient the flexion of the ankle-joint. By its distal surface, which is semilunar and slightly convex, it is articulated to the proximal extremity of the great toe, 1; by the distal of the two fibular surfaces, to the metatarsal bone marked 2, next the great toe; and by the proximal of these two surfaces to the os cuneiforme medium, e. The cuneiforme internum is cartilaginous in the fetus.

The os cuneiforme medium, e, is the smallest of the three cuneiform bones, and has the most wedge-like shape. Its distal extremity, which is a triangular surface, like the proximal, is articulated to the proximal extremity of the metatarsal bone, 2, next the great toe, and its fibular aspect to the os cuneiforme externum, *f*. This bone is also cartilaginous at birth.

The os cuneiforme externum, *f*, intermediate in size between the other two, is more wedge-shaped than the internum, but less so than the medium. Anteriorly, or distad to its articulation with the medium, is a small smooth surface, 2, articulated to the metatarsal bone, 2, of the toe next the great toe; at 3, by an oblong triangular surface, to the metatarsal bone, 3, of the middle toe; at 4, by a small smooth surface to the metatarsal bone, 4, of the toe next the little one; and at 6, by a square smooth surface to the os cuboides. Between these two last surfaces there is a rough hollow. This bone is likewise cartilaginous at birth.

The os cuboides, *g*, is articulated by a smooth pulley-like surface to the os calcis; by a smooth flat surface, slightly divided by a ridge into two planes, with the metatarsal bones of the little toe, 5, and the next toe, 4; the fibular of these two surfaces is nearly circular. Fibulad and plantad to the surface that supports the little toe, is a considerable fossa, g, made by the peroneus longus in crossing the sole of the foot. In the plantar aspect, proximad to this fossa, the bone is rough and hollow for the attachment of the strong external or fibular plantar ligament. In the fetus ossification has scarcely begun in this bone.

Round the smooth surfaces of the tarsal bones is a roughness for the attachment of capsular ligaments, which envelope each articulation; and, indeed, all the surfaces of these bones, excepting where they are articulated to one another and to other bones, are rough, or porous, for

the attachment of strong transverse ligaments. From this attachment, as well as the shape of these bones, we observe that an elegant and strong arch is formed, and that the multiplicity of articulations thus closely compacted, together with the strong plantar ligaments, diffuses an elasticity throughout, but at the same time prevents any free motions, merely a slight gliding of the bones upon one another. When we consider this structure, we are surprised to learn that any of these bones can be dislocated: the os astragalus, however, is sometimes torn from all its connexions; sometimes it is only detached from the naviculare and os calcis; sometimes it is fractured across; at other times the astragalus and os calcis are detached from the naviculare and cuboides, forming a transverse division of the foot: in other cases the cuneiforme internum is dislocated from its connexion with the great toe, the next toe, and the cuneiforme medium; and in some instances, the metatarsal bones are dislocated from the tarsal. From the variety of these accidents, we see the necessity of making ourselves thoroughly acquainted with the mutual connexion of these bones; for if reduction be found impracticable, the extirpation of the bone is the next preferable step, to prevent inflammation and its consequences, which have sometimes led to amputation of the foot.

The structure of these bones is similar to that of the bodies of the vertebræ or to the patella, see Plate IV., Figs. 7 and 8; so that they are very liable to caries, which as in the case of the vertebræ, when it attacks one, generally spreads throughout the whole. Extirpation of one or more, or amputation, according as the bones are affected, becomes here also an object of consideration. In injuries of the toes, to the extent of their destruction, amputation across the foot is recommended, between the proximal extremities of the metatarsal bones, and the cuboid and three cuneiform bones; and in injuries which involve these tarsal bones, amputation may be performed between the os cuboides and os naviculare on the one side, and the os calcis and os astragalus on the other.

The five metatarsal bones, 1, 2, 3, 4, 5, more or less resemble one another, and agree in their general characters with the metacarpal bones. They are, however, longer, thicker, and stronger; their bodies are sharper in their dorsal aspects, and flatter laterally, with their plantar ridges or angles more inclined fibulad; their distal or anterior round heads are not so broad, and are less in proportion to their proximal ends or bases; and the tubercles at their heads are larger in consequence of the ligaments by which they are here united. The first or metatarsal bone, 1, of the great toe, is easily distinguished from the rest by its thickness: the next, marked 2, is the longest, having its plantar edge sharp and almost perpendicular: the others become shorter and more oblique as we proceed fibulad.

The os metatarsi pollicis, as it has nearly the whole weight of the body to sustain, is the thickest and strongest of these bones; its base or proximal extremity, *ε*, has a corresponding concave surface to be adapted to the os cuneiforme internum, *d*. The plantar aspect of this base is rough, and somewhat prominent for the insertion of the peroneus longus muscle, the long lever of which should be considered in dislocation of the ankle-joint, accompanied with fracture of the fibula. A small oblique circular depression is made on the fibular side by the metatarsal bone, 2, of the next toe. At the distal extremity on the plantar aspect, the round head has generally a middle ridge, and two oblong cavities for sesamoid bones. On the fibular aspect, a small depression is made by the tubercle of the head of the next metatarsal bone.

The metatarsal bones of the second toe, 2, the middle toe, 3, and the fourth toe, 4, I need not minutely describe. They have all at their proximal ends, or bases, surfaces corresponding with the tarsal bones to which they are connected; and the point where they are applied to each other is at once seen in the drawing. These connexions should be attended to by the operator, in order that he may be able to remove an individual diseased bone.

The os metatarsi minimi digiti is the shortest of the four fibular toes, flattened dorsad and plantad, and having its ridges disposed laterally. The base is very large, and produced into a long process, *t*, to which the peroneus brevis and part of the abductor minimi digiti are attached.

At their bases, the metatarsal are firmly connected to the tarsal bones, and to each other, by capsular, transverse, dorsal, and plantar ligaments, so that little or no motion, only a gliding of the one bone upon the other, is here allowed, and dislocation rarely takes place; and at their heads, they are tied to each other, with nearly equal firmness, by transverse ligaments, so that the same motions take place here as in the immediately preceding, and dislocation seldom occurs. The strong arch of the foot is formed between these heads and the protuberance on the plantar aspect of the os calcis, so that these being our only supporters, are necessarily strong and limited in their motion.

At birth, these bones are cartilaginous at their extremities, which, like the long bones, become afterwards epiphyses.

The bones of the toes, especially the two of the great toe, are nearly similar to those of the thumb and fingers; they are, however, proportionally much stronger, as they are subjected to a greater exertion by sustaining the force with which our bodies are pushed forward at every step we take, and by supporting in a great measure the weight of the body when we raise ourselves on our tip-toes. Into the base of the first bone of this great toe the flexor brevis is inserted, and into the second and last bone the flexor longus pollicis; and the tendons of the extensor proprius pollicis, and extensor brevis digitorum pedis, are expanded over the dorsal aspect of these bones.

The three bones in each of the other four toes differ from those of the fingers, in being less in proportion to their lengths; in their bodies being narrower, dorsad than plantad; their sides flatter; and their bases much smaller than their heads. The first phalanx, 8, 11, 14, 17, is proportionally much longer than the bones of the second phalanx, 9, 12, 15, 18, or those of the third phalanx, 10, 13, 16, 19. The toe next the great toe has the largest bones, 8, 9, 10, in all dimensions. The little toe, and the one next to it, have frequently the second and third bones, 18, 19, and 15, 16, intimately united into one, which is probably owing to their little motion and the great pressure to which they are subject. Into the bones of the second phalanx the tendons of the flexor brevis are inserted; and into those of the third phalanx, the tendons of the flexor longus. The bones of the two first or proximal phalanges have each a delicate lateral ridge, giving attachment to the vaginal ligaments of these flexor tendons. Into the dorsal aspect, the expanded tendons of the extensor longus and brevis digitorum pedis are inserted.

The bones of the toes are connected at each of their extremities, except the distal of the last phalanx, by capsular and lateral ligaments, so that free motion is performed. At their metatarso-phalangeal articulations, flexion, extension, abduction, and adduction are performed; and at their phalangeal joints, flexion and extension. The toes are of great use to us in walking, as they bring the body with its centre of gravity perpendicular to the advanced foot. They are sometimes dislocated at their metatarsal connexions, and the bone, 6, of the great toe is not unfrequently dislocated from its metatarsal bone, 1.

The first bone, 6, of the great toe, and the two first phalanges, 8, 11, 14, 17, and 9, 12, 15, 18, are cartilaginous at their extremities in the fetus, and their distal ends or heads are afterwards joined as epiphyses. The distal phalanx, 7, 10, 13, 16, 19, are cartilaginous at birth, and remain epiphyses till maturity, which should be recollected in bruises of the toes. The internal structure of these, and of the metatarsal bones, resembles, in general, that of the long bones; and they are also subject to the same diseases.

The contrast between the upper and lower extremity is striking, for if we assume the os innominatum as the bone corresponding to the scapula, the former admits of no motion. The upper extremity is adapted for mobility and prehension, the lower for strength and progression. Hence the thigh bones, where they are articulated to the pelvis, are set off at an obtuse angle, which increases the distance at their proximal ends, while it approximates their distal extremes at the knee-joint. This enables us in walking and running to double the bones on each other at the joints, and proceed without describing a circle either with the trunk or the leg. In these actions, the centre of gravity is uniformly preserved, with this difference, that in running it is not always supported, but is for a time suspended in the air.

PHYSIOLOGICAL AND PATHOLOGICAL OBSERVATIONS.

The bones begin to be formed at a very early period of life. About the third week after conception, the fetus is observable, and towards the end of the fourth, the heart may be seen to move; in the fifth week, the parietes of the thorax are a delicate gelatinous membrane, and in the sixth, the ribs have the appearance of a spider's web. From this period, the ribs, sternum, and clavicles, become cartilaginous,* and in immediate succession the other rudiments of the bones: the flat bones appear simple membranes, and those of the cranium form an extended surface, without the slightest vestige of separation by sutures; the bones of the extremities have visible articulations, and the periosteum appears to extend from the one extremity to the other, enclosing all in a sheath.

Between the seventh and eighth week, points of ossification are seen shooting, like the congelation of water, in different directions in the ribs, sternum, and clavicles; which afterwards spread rapidly throughout the different parts destined to become bone. Nuclei of ossific matter are deposited in the cylindrical bones of the extremities, in the lower jaw-bone, and in some of the other bones of the face and cranium. The bones of the internal ear, however, are found ossified even prior to all the others, in order that this organ of sense may be of early service to the fetus. In each of the bones of the cranium appears one or more nuclei, named the centres or points of ossification, from which the ossific matter branches around like the radii of a circle, presenting a beautifully feathered appearance, as seen in Plate IV., Fig. 6.

In the early stage of the fetus, the dura mater and pericranium form one condensed tunic or membrane, and at the points where ossification begins, the arteries both of the dura mater and pericranium deposit ossific matter; those of the pericranium to a greater extent than those of the dura mater. The experiments of Herissant, and the observations of David, support this opinion; and the diploe which is observable in the adult bone equally confirms it, for we have an osseous lamina or table on each side. The experiments of M'Donald prove that the internal periosteum of the long bones is concerned in their reproduction in necrosis; and considering that the vessels of the medulla pass ultimately outwards through the bone, this opinion seems perfectly consistent. It is also supported by other pathological facts besides necrosis.*

The long bones, as soon as they can be discerned, although purely gelatinous, have a cylindrical figure, and when converted into cartilage, their diaphyses or shafts can be distinguished from their epiphyses or extremities by the interposition of a gelatinous bed; they are also seen invested with a membrane. Rings of bony matter begin to appear in the middle of the shaft, spreading upwards and downwards to the extremities of the bone; blood-vessels then enter the structure of the bone; and within the osseous shell now formed, numerous short vascular villous tubes extend longitudinally, and terminate in delicate villi at the gelatinous stratum interposed between the shaft and epiphyses; some, however, penetrate this stratum, enter the cartilaginous extremities, and terminate in irregular cavities filled with a mucilaginous fluid. Round these longitudinal villous tubes, which are extremely small, ossific matter is deposited, so as to give the bone some consistence; and the tubes, which are arranged in layers, communicate with each other through the medium of other shorter villous tubes.

The external periosteum can now be distinctly seen, and soon afterwards the internal periosteum. The osseous cancelli, which support the medullary pouches, are next formed; the pouches themselves being produced by the internal periosteum shooting across thin membranous septa which unite with others from all sides of the canal, forming so many distinct bags. The medulla, however, does not begin to be secreted till after birth.†

---

* Cartilage is the white semi-transparent dense substance which covers the articular surfaces of the bones in the fresh state, or is interposed between them. It forms a stage in the transition to bone, as is established by the growth of the bones in the fetus, and by many of the cartilages becoming ossified in advanced age. A cartilaginous matter exists in the hardest bones, and constitutes their basis, from which the gelatin and phosphate of lime may be removed. This substance is provided with nerves, arteries, veins, and lymphatics, as is satisfactorily proved by its growth in health, its increased sensibility and absorption in disease. In joints, the cartilaginous surface does not secrete any synovial fluid.

* See Cases recorded by Duvernay, Quesnay, Mareschal, Rouhault, Sarrau, Fabre, and Raygerius.

† The medulla or marrow which is secreted by the arteries, appears

The bone has now acquired a perfect shape, consisting of a cylindrical tube with epiphyses, and has generally a peculiar foramen that gives entrance to a principal nerve, artery, and vein. It then gradually advances in growth according to the stature of the individual; the shaft acquires rings of osseous matter which constitute a sheath to the bone already formed, and consequently extend from the one extremity or epiphysis to the other, in a manner similar to the annual rings or layers of the trunk of a plant; while the cartilaginous epiphyses are progressively converted into bone, and unite firmly with the shaft. Thus, each external layer of ossific matter extends at the epiphyses beyond the internal one, forces the epiphyses further from the shaft of the bone, and hence lengthens the bone to correspond with the growth of the other organs of the body. The layer of gelatinous matter interposed between the shaft and the epiphyses facilitates this progression.

The formation of the annual ring of wood in trees through the medium of the bark, and the growth in height by the prolongation of the annual shoot, beautifully and clearly illustrate the mode in which the long bones are formed. These facts of vegetable physiology are satisfactorily established by the experiments of Du Hamel, Hope, and Knight: for, in physiological inquiries, we are entitled to draw analogies from vegetable anatomy and physiology; however, from comparative anatomy and physiology, we have the most unequivocal proof that this is the manner in which the long bones are formed.*

The experiments of Du Hamel, Blumenbach, Kœhler, Troja, and M'Donald, and the observations of Lewenhoeck, Morand, Belcher, Munro *primus*, Ritcher, and David, all corroborate the fact, that bone is formed chiefly by the periosteum. David differs a little from the others, conceiving that the augmentation of the diameter of a bone is as much the production of the interior texture of the already solid part, as of the external periosteum. He denies the existence of an internal periosteum.

The formation of the teeth, by the vessels of a membranous bag, is an illustration of the formation of the bones;† so is the formation of the cuticle, the nails, and

---

in the fetus and in infancy like a deep red jelly, in consequence of the great number of blood-vessels interspersed. As life advances, it obtains more consistency; the blood-vessels decrease in number, and it assumes a yellow colour. In old age it becomes of a deep yellow colour, and of a thicker consistence. In the tubular portion or shaft of the long cylindrical bones, it has more consistence, and a deeper yellow colour than in the cellular spongy extremities of the same bones, where it is redder and more fluid; which is equally the case, if not more so, in the flat and irregular round bones. The most solid portions of bone are found penetrated with the medullary fluid. When enclosed in the pouches of the internal periosteum, and examined by the microscope, the medulla appears like an accumulation of globules, each of which is about the sixth or eighth hundredth part of an inch in diameter. This fluid is not tinged by madder taken internally. The constituent principles of marrow are found to be the same as other fat substances, viz. oil, water, and sebacic acid. According to Isenflamm, its specific gravity is greater than that of water, while according to Plenk and Soemmering, it is less.

Marrow is more solid and yellow in the male than in the female animal, and it is also in greater quantity in the former than in the latter. The use of the medulla has been long a matter of discussion. Hippocrates and Galen were of opinion that it served for the nutrition of the bones; Havers and many others, that it served for lubricating the joints; Bertin, Haller, and Blumenbach, that it renders the bones flexible, and gives them strength and elasticity; Soemmering, that it was intended only to fill the vacuum in bones. It has been imagined by some physiologists to contribute to the formation and growth of the bones; while others think it of great service in producing callus and restoring the bone to its former strength. Isenflamm conceives that it is intended for different purposes, according to the age of the animal; that in children it may perhaps contribute to nutrition, so that the bones may be considered materia nutritiva; and that in old people it may confine the heat internally. He also considers that the medulla may bind electric matter. Of all these opinions, that of Bertin, Haller, and Blumenbach appears the most rational, with this modification that the medulla contributes little or nothing either to flexibility or elasticity, for the bones of children in which the marrow is not yet perfectly formed, are much more flexible and elastic. The experiment of Bertin, wherein he deprived bones of their marrow by fire, thus rendering them brittle, and then immersed in oil, thus restoring their flexibility, frequently failed. The medulla therefore appears to be intended to moisten the bones, and thus to give them strength. With the exception of the epidermis and its appendages, no part of the body is destitute of moisture, and as water or mucous could not have been in advanced life so easily and readily deposited and absorbed in the bones, the vessels of which at this period are nearly obliterated, the medullary fluid seems admirably adapted for this purpose.

In consumptive diseases, the medulla is absorbed by the lymphatics, but soon deposited, if these disorders are cured. It does not appear to be subject to idiopathic diseases, but is only changed when the bones are affected at the same time. Boon found it spongy and fibrous in the callus of fractured bones; Navier, like fluid fat in mollities ossium; and Troja observed it became white, solid, and beginning to ossify in the upper part of a fractured bone.

---

* Consult Experiments of Du Hamel and John Hunter.

† In the fetus, about the tenth week after conception, there is no vestige either of an alveolar socket or nucleus of the teeth, but simply a gelatinous substance included in a very vascular membrane extended round the maxillary bones.

About the fourth or fifth month after conception, the lower jaw-bone has a distinct shallow groove extending through its whole length; anteriorly this is narrower and deeper, and posteriorly wider and more shallow; and in this canal appear little pulps, enclosed in delicate membranaceous sacs, surrounded with small cells of a rude form. These bags are the rudiments of the teeth to be produced. Nearly about this period delicate bony partitions, separating these membranaceous pouches, are seen extending across this canal; which ultimately become more distinct, and form the alveolar sockets.

The sacs of the incisivi are first visible; next those of the canini; and, lastly, those of the molares.

The nerves and blood-vessels run along the bottom of this channel immediately beneath the pulps of the teeth; and at a more advanced age are encased in a bony canal, and send separate branches and filaments to the individual teeth.

The pulps attached to the bottom of the cells gradually assume the figure of the crowns of the respective teeth which they are to form, and then begin to be converted into bone. In the incisivi and canini, the vessels of the membranous bags commence with depositing ossific matter externally at their tips or points; the ossification then extends downwards, both on their exterior and interior surfaces, and also from without inwards, pressing the pulp gradually downwards. As soon as the crown of the tooth is formed, which is named enamel, the fang or root is produced of a hollow tubular form to afford lodgment for the vessels.

In the molares ossification begins at two points in the first two or bicuspides, which are the milk or deciduous grinders; and at five points in the last three molares or permanent grinders. In the molares, the striæ run on the upper surface from each of these tips to the centre, and from the same points downwards to the neck of the tooth; ossification extends at the same time centrad, squeezing down the pulp, leaving a cavity, and producing the fangs in the same manner as the incisive or canine teeth did.

This process resembles the beautiful appearance displayed by the slow congelation of water, or the elegant surface of fibrous gypsum, or satin spar.

The ten teeth which are now formed, for we must exclude the three last molares, are termed milk, or deciduous teeth, because they fall out, or are shed at a future period of life; they are also denominated temporary. We must here also recollect that at this time the roots or fangs of these deciduous teeth are not yet formed; for they do not begin to be produced till after birth.

About the seventh month after conception, the pulps of the permanent incisores are seen almost in the same plane, only a little underneath the deciduous set, and next the canini; and, lastly, the molares. At birth, therefore, a child has the rudiments of both the deciduous and

the hair, which are all secreted by organs distinct from themselves. It is only in the fetus, and while the bones possess a delicate texture, that they are secreted by vessels which perforate them minutely. The regeneration of the horns of the stag admirably illustrates the formation of bone. The regeneration of the bone in necrosis is another excellent illustration, and although drawn from disease, is perfectly admissible, when it is but one fact selected to elucidate several healthy phenomena.*

In this manner are all the bones formed, which formation is completed about puberty. The elevations, depressions, and foramina, are produced by the muscles and vessels attached to them, or which pass over or through them.

In the fetus, the bones are quite gelatinous, in order that it may be moulded into the shape most convenient for its abode in utero: and even in the latter period of its residence, the greater number of the bones remain cartilaginous, that it may sustain no injury in its entrance into the world. In infancy, and in early life, the bones have a bluer colour than in manhood, in consequence of the greater distribution of blood-vessels, and their not being completely ossified. At this period, the animal property predominates, and therefore they are more yielding and less liable to break. When fractured, they more readily unite, and when inflamed, they are more easily cured. The spongy bones when attacked with inflammation, are less liable to become carious, and the dense compact bones are more easily necrosed. The epiphyses of the long bones are occasionally displaced, an accident sometimes mistaken for fracture.

In youth, the animal and earthy properties exist nearly in equal quantities, but the epiphyses are still unconnected by ossific matter to the shafts or diaphyses, and they have still a blue tinge though not so deep, and when attacked with disease differ very little from what occurs in the preceding stage of life.

In adult age, the earthy portion, or phosphate of lime, preponderates, and the bones assume a whiter colour, although the long ones still possess a bluish tinge at their extremities; they are more brittle, and, when fractured, unite more slowly; they are also less easily inflamed, but when they have assumed this morbid action, it is with greater difficulty subdued; and they readily exfoliate, or become carious, but are tardy in being necrosed.

As life gradually declines, the earthy constituent increases, and displaces the animal, till the bones become extremely brittle; the power of cohesion leaves them, and they appear to be preparing to moulder away into that state from which they sprung. When this loss of union occurs, the heads of the bones, particularly those of the thigh, separate from the shaft; and like that in early life, this has been mistaken for fracture or dislocation. The reason of this separation of the head of the bone from the shaft, appears to be, that the nutritive deposition has ceased, while the absorbent action continues, and that the bond of union between the head and neck of the bone, gelatinous in early life, and cartilaginous nearly till puberty, is later in becoming ossified, and consequently weaker, and more easily and quickly removed by absorption. When fractured in advanced life, the bones unite, if at all, with difficulty; they are slowly inflamed, with

---

permanent teeth lodged in the jaw-bone, and covered with the gum and lining membrane of the mouth. The crowns of the deciduous teeth alone are ossified.

After the child is born, the roots or fangs of the teeth begin to be produced, so as to render them too long to be contained within the alveolar socket, and hence to raise the crowns gradually towards the gum, which, giving less resistance than the alveolar socket, is cut more by mechanical pressure than by absorption. It is this mechanical puncturing, or cutting of the gum, which produces the severe symptoms and diseases of dentition.

At the age of the sixth or seventh month, the middle or mesial pair of the incisivi of the lower jaw protrude through the gum. In a few weeks the opposite pair of incisive teeth in the upper jaw also make their way through the gum. In a few weeks after the appearance of the two last, the two lateral incisores of the lower jaw force their way through the gum; but sometimes the corresponding ones of the upper jaw pierce first. This is the natural and general order in which the incisive teeth appear in the mouth; but I find this order inverted by Richerand, while Albinus, Haller, Hunter, Soemmering, Bichat, and others adopt it. Richerand, I should presume, has either adopted this order from an individual case in nature, or he has followed Eustachius and some of the ancient authorities. The reason that the teeth in the lower jaw come sooner to perfection, appears to arise from the lower jaw being a more dense bone than the upper, and the vessels possessing the power of more easily and more readily secreting bone: from which cause the vessels of the lower jaw can secrete a new bone when the old is dead, while those of the upper cannot.

Towards the end of the first year, the two first molares or bicuspides of either the lower or upper jaw are visible; generally those of the lower jaw first.

During the second year, the canine teeth are pushed forth, and towards the end of the same year, the two second or remaining bicuspides make their appearance. We have, therefore, the whole of the deciduous set, namely, twenty in number, present in the beginning of the third year.

These are the general periods of time in which these teeth make their appearance in the mouth; but they are frequently varied. Sometimes the first tooth appears so early as the fourth month; nay, instances have occurred of children being born with one or two of the incisive teeth of the lower jaw. Pliny and Solinus relate that some were born with all their teeth. Other children have arrived at the age of fourteen months before the appearance of any teeth. It is recorded that Pheretes never possessed a tooth in his life. Again, sometimes the teeth of the upper jaw appear before those of the lower; sometimes the lateral incisivi before the mesial; and in a few instances, the first molaris before the lateral incisores;—while occasionally more teeth appear at the same time than are naturally to be expected.

The pulps of the permanent teeth begin to ossify about the sixth month after birth, and continue advancing to perfection till the seventh year, when the fangs of the deciduous teeth, and the alveolar floor which divided these from the permanent, are absorbed; and the deciduous teeth, having no longer any attachment, fall out. The permanent then make their appearance above the gum in an order similar to the deciduous teeth. The formation and perfection of this set of teeth occupy from twenty to thirty years. The permanent incisive and canine teeth are larger than the deciduous, that they may correspond to the increase of the jaw-bones. This circumstance should be perfectly understood, since not a few have had the permanent teeth extracted by ignorant practitioners, instead of the deciduous. The molares which supplant the deciduous ones are smaller in size, that they may make room for the three which are to appear behind them. By the twelfth year all the diciduous teeth have generally fallen out and been supplanted by the permanent. The anterior of the three backmost molares usually makes its appearance between the seventh and eighth year: the next or the fourth from the canine is ossified about the seventh year, and pushed forth about the eighteenth year: and the last or fifth from the canine appears between the eighteenth and thirtieth year, and sometimes even later.

The natural history of the teeth points out to us the manner of their formation and protrusion through the gums; the latter of which gives rise to many important diseases, which frequently involve the welfare of our offspring. As it is the regular arrangement of the teeth which enables the individual to articulate with distinctness; as they perform very interesting and useful functions which cannot be interrupted without our sustaining the greatest inconvenience; and, lastly, as they involve the contiguous structures in various diseases,—it seems truly surprising that their natural history, as well as their diseases, are not more generally cultivated.

* Consult Cases detailed by Pouteau and Gooch.

equal slowness cured, and readily degenerate into caries, but are with difficulty necrosed.

In health the bones are endowed with little sensibility; but that they possess feeling is proved by the various experiments, particularly of Troja, which have been performed on animals; and by what is daily witnessed in the amputation of a sound limb. It can be demonstrated that they have nerves; and although these pass through foramina, yet the aperture remains as pervious as the foramen opticum, and other holes in the basis of the cranium. Were they not supplied with nervous influence, they could not possess vitality, as no part of the body destitute of this property can be said to live, and no part which possesses vitality is destitute of sensibility. Again, they are supplied with arteries, which also prove the presence of nerves, as no artery exists without nervous influence. This sensation they possess in the greatest degree in infancy and youth, before the ossific process is completed; but, as they become gradually solid, they lose their sensibility and vascularity, the vessels throughout the general structure of the bones being nearly obliterated; still, however, the nutritious artery, with its accompanying nerve and vein, is allowed free ingress to the internal periosteum and medullary pouches, till the last period of life: were this not the case, necrosis would be an inevitable consequence. The sensibility of the bones is greatly increased when inflammation attacks them, which is a collateral proof of their sensibility in health; and the pain in this disease is generally excruciating, apparently in consequence of their structure not yielding. Did the bones not possess nerves, they would be dead matter like the epidermis, the nails, the hair, and the enamel of the teeth; undergoing no change during health, and suffering no derangement from disease. On the contrary, when we consider that they possess nerves and consequently sensibility, blood-vessels and consequently vascularity, we understand that they are parts of the living system, subject to the same changes and diseases as the other organs of the living body.

The vascularity of the bones is satisfactorily shown when a young bone is injected, or when a young animal is fed on madder, for the bones then become tinged of a bright red colour. The blood-vessels can be distinctly seen in a fetal bone, and even in that of an adult. When a bone is injected, and then deprived of its earthy matter by diluted muriatic acid, the blood-vessels are seen to be very numerous. The existence of blood-vessels is also proved in amputation and other surgical operations, in which the cut ends of the bone are observed to bleed. Now, as every artery must be endowed with nervous substance, the presence of arteries in bone proves the existence of sensibility. The blood-vessels are designed for growth and nourishment.

To be satisfied that the bones possess absorbents, we have only to consider the continual regeneration which goes on throughout the system; but we have demonstrative evidence of the fact in the experiments of Du Hamel and others. Young animals were fed on madder for a few days, and then some of them killed, when the bones were found to be tinged of a deep red colour. Those left alive were allowed to range the fields, and live on their natural food for some time longer, and then killed: in these the bones had recovered their natural colour. The hypothesis of this circumstance is, that phosphate of lime is an excellent mordant to the colouring matter of madder. If to a solution of muriate of lime a solution of madder be added, no effect is produced; but when phosphate of soda is added, there is a mutual decomposition, and muriate of soda and phosphate of lime are formed. The phosphate of lime unites with the madder during its formation, and is precipitated of a red colour. This holds out a prospect of curing rickets and mollities ossium; but our ignorance of the operations of medicines renders it doubtful how far, after the administration of phosphate of lime and madder, calcareous depositions might not take place, not only in the bones, but all over the system.

The observations of Monro *primus*, and John Hunter, establish that there is a modelling action of the nutrient and absorbent vessels in the bones; the nutrient vessels, which are the arteries modified in the periosteum and influenced by the nerves, are perpetually secreting osseous matter from the commencement of ossification till its completion, while the absorbents are removing chiefly the inner particles so as to proportion the bone to its growth. In some diseases, such as necrosis and mollities ossium, which attack the bones, the existence of absorbents is also proved.

From all that has been stated, we are entitled to conclude that the bones in their early stage are formed by the arteries influenced by the nerves, and modified partly by the periosteum, and partly by their elaboration through the gelatinous and cartilaginous substances; and that, as they advance gradually towards completion, the vessels which enter their structure are obliterated, the bones becoming more and more dependent on the periosteum for osseous nutrition.

The bones of the skeleton are divided into three classes; the irregularly round-figured bones, the flat bones, and the long cylindrical bones.

The first class, or those of a round shape, comprehends the true vertebræ, the bones of the carpus, and the bones of the tarsus, which consist of a spongy structure encased in a thin osseous shell. In this description of their structure are included the extremities of all the long cylindrical bones, which have equally a cancellated texture enveloped in a bony shell. When fractured, these bones seldom if ever unite by osseous junction, but generally by fibro-cartilaginous or ligamentous union, or by both; and of this the patella is a good example.* The reason of this peculiarity seems to be, that no part or organ of the body is regenerated so perfectly as at first. The skin, when a portion of it is removed, does not repair itself in so perfect a manner as it formerly existed; neither does the cellular, the muscular, the arterial, the venous, or the nervous substance; and all of these structures are regenerated in the inverse ratio of their perfection. Hence the dense bones, when fractured, form a strong bond of union, and exude a superabundance of osseous juice, without any regard to proportion or symmetry, precisely similar to the exudation of the juice in the engraftment of trees.†

In consequence of their structure, the fracture of these spongy bones is transverse, in which they resemble soft wood and soft minerals, as lime or marle. When inflammation attacks them, it terminates either in resolution or

* In confirmation of this manner of reparation, consult Sir Astley Cooper's valuable work on dislocations and fractures of the joints, and Dr. Colles's important paper in the Dublin Hospital Reports.

† There are two able essays on this subject by Messrs. Fabre and Louis, in the Memoires de l'Academie Royale de Chirurgie.

caries. From their structure they seldom exfoliate; neither can their vessels form an osseous shell so as to constitute necrosis. They are particularly liable to caries, in which circumstance they bear a close analogy to the soft parts. Caries is ulceration of the bones, and this ulceration is found to vary or to present different types, in precisely the same manner as the soft parts; thus we have, analogous to what is improperly styled healthy ulcer, healthy caries; analogous to indolent ulcer, indolent caries; to scrofulous ulcer, scrofulous caries; to syphilitic ulcer, syphilitic caries, &c.

The reason why these bones, when inflamed, so readily terminate in caries, appears to be, that as parts soft and loose in their texture, like the cellular tissue, when attacked with inflammation, terminate generally in suppuration, while hard and firm structures, as tendon and skin, end generally in mortification; so the soft spongy bones degenerate into caries, while the hard and dense bones end in necrosis. A part, in order to enter into the suppurative process, or more correctly speaking, to form a surface capable of secreting purulent matter, must apparently enjoy a degree of latitude, to enable the capillary vessels to form secreting papillæ.

When caries attacks the body of one of the vertebræ, or one of the bones of the carpus or tarsus, it rarely ceases, before it involves many of the contiguous ones.

From what has been stated, the treatment of caries will vary according to the condition of the ulceration. When healthy, it will require simple dressing, with adequate support by bandage or machinery, according to the nature of the part affected; when indolent, it will need stimulating dressing and bandage; when irritable, anodyne fomentations and poultices; when syphilitic, either stimulating or soothing dressings, according to its appearance, together with the administration of sarsaparilla, mercury, or gold, and generous diet. In every case, particularly the scrofulous, the diet must depend on the condition of the ulceration.*

When inflammation is not present, and there is no chance of saving the bone by the preceding treatment, or if a joint, by anchylosis, the removal of the bone, or amputation, becomes a consideration for the surgeon.

The second class of bones is the long cylindrical, as those of the arm and fore-arm, and those of the thigh and leg. They consist of a long tube of dense ossific matter, which terminates in enlarged spongy extremities, see Plate IV., Fig. 10; and within the tubular part, and the delicate cancellated structure, the medulla is contained; but it is the consideration of the dense portion, or the diaphysis or shaft only of the bone, that is to engage us at present, as the extremes or epiphyses are strictly analogous in their structure and diseases to the last mentioned bones.

The bodies or shafts of these bones, when fractured, are most quickly united, because their vessels are more endowed with the property of secreting ossific matter, and this according to their multiplied distribution; therefore, we find them more quickly united in early life, more slowly in adult life, and still more slowly, if at all, in advanced life. The callus or bond of union, which is a gelatinous secretion, performed chiefly by the vessels of the periosteum, and also by those of the truncated ends of the bone, does not take place for some time after the fracture, and this sooner or later according to the youth of the sufferer, and according to the duration of the inflammation which supervenes after the accident: again, as no secretion can take place during inflammatory action, as the periosteum is always inflamed, and as the fracture of these bones is oblique and splintery, in which they resemble hard wood, and hard compact minerals, and as the muscles, from the injury they sustain, are in general always excited, it appears fruitless to attempt the setting of the limb, till both the inflammation and irritation of the muscles have subsided, unless called immediately on receipt of the injury. Independently of these reasons, the callus remains gelatinous for some days, which is clearly established by experiments.*

The practice should be to attend first to the inflammation, and when it has subsided, to place the limb in a straight position; twelve days may elapse before a limb be set, and the callus still soft. Whenever an accident occurs, the fractured limb should be laid on a splint, in the easiest position for the feelings of the patient, and warm anodyne fomentations applied, and continued till pain and inflammation subside. At this crisis, let the limb be extended and supported with cushions and splints, and let it be examined daily, and daily extended if found requisite. "There is nothing more certain," says Mr. John Bell, "than that the extending a callus gradually, regularly, and gently, from time to time, will not harm it." This practice will invariably prevent the shortening of the limb.† The only exception to this line of practice is that requisite to be adopted in a fractured rib, where the action of the lungs is incapable of being controlled, and where, to prevent their injury, we are compelled to bring the fractured ends of the rib as nearly as possible in apposition, and to apply a broad roller round the thorax to prevent motion. The lancet must be freely used in this accident, to subdue inflammation. Many conditions of the body, as scurvy, prevent the union of fractured bones; these appear to act by the increased action, and particularly by increased absorption, which prevent the same nutritive deposition taking place in the bones as in the other textures.

The long bones gradually decrease in density from the centre to the extremes, until they consist of a cancellated structure with a delicate osseous shell, see Plate IV., Fig. 10, so that the fracture becomes less and less oblique till it arrives at a transverse direction. The bond of union departs in the same ratio from bone to cartilage and ligament. Hence the fracture of the neck of the os femoris is transverse, and there is no union by ossific matter like the centre of the shaft, but only by fibro-cartilaginous bands; indeed, from the structure we can expect nothing more.‡ This, however, greatly depends on the destruction of the periosteum, for if it be left entire, ossific union takes place.

When inflammation attacks the shafts of these long bones, the disease terminates either in resolution or exfoliation, which is analogous to desquamation of the soft parts, or in necrosis analogous to sphacelus of the soft

* On Caries of all the Bones, see Petit, Gooch, and Histoire Naturelle du Roi.

* The experiments of Du Hamel shows that bandaging a fractured limb increases the evil. See also Pott's Works, and John Bell's Principles of Surgery.

† I have more than once had occasion to amputate fractured limbs that had been imprudently bandaged by others on receipt of the injury, thus exciting inflammation and suppuration, or mortification.

‡ See Sabatier, Boehmer, John Bell, Gooch, Sir Astley Cooper, and Dr. Colles.

parts. If the hypothesis advanced relative to caries be correct, it follows that dense compact bones cannot ulcerate, because there is not room for their vessels to form ulcerative papillæ; again, as inflammation cannot exist without some degree of swelling, and as the shafts of the long bones are so dense and unyielding, that the vessels have no latitude for enlargement adequate to the increased impetus of the blood, they die; and the bone being thus deprived of nourishment, immediately shares the same fate. When the shaft of the bone thus mortifies, a separation takes place between it and the extremities; the periosteum inflames; an accumulation of vessels with thickening of this membrane ensues; and if the inflammation be moderate or towards its subsidence, the vessels, together with those of the epiphyses and of the internal periosteum, if this membrane remains sound and healthy, begin to secrete a greater quantity of ossific matter to replace the decayed portion. But from what has been stated, the vessels of the epiphyses had not originally the property of secreting dense bone, and cannot therefore be expected to secrete it now. The internal periosteum is nourished from without, and as there is an intimate connexion between it and the external periosteum, its vessels are frequently cut off, and consequently can seldom have any concern in the secretion of a new bone. Nature then seems to trust chiefly to the external periosteum, and this membrane appears adequate to the task. After the secretion of the new bone has extended from the one epiphysis to the other, the periosteum loses its injected appearance, and returns to its natural colour and density. The new shell, hitherto incorporated with the old bone, separates, and an internal periosteum begins to be formed; and if the old bone could be extracted at the one extremity to prevent the effusion of the new secretion, the medulla would be in a short while deposited, and the new bone perfected. But the old bone frequently forces its way through the centre of the new shell during the secretion of the gelatinous effusion, which therefore runs into the cavity, and makes the new bone solid for a time; for absorption takes place after the expulsion of the old, so as to enable the new bone to be completed.

This modus operandi is supported by the experiments of M'Donald, and by a well marked case detailed by Pouteau, as well as by several other cases.

Necrosis occurs chiefly in early life, and attacks the tibia more frequently than any other bone, as is proved by the cases recorded by Bousselin, Russel, and others. When it attacks the inferior maxillary bone, it is generally after thirty years of age.*

The dead bone should be removed as soon as it is loose, otherwise the health of the patient may suffer. The danger of removing it too soon, consists in the injury done to the periosteum, and the consequent deficiency of new bone. If allowed to remain, it proves a severe source of irritation. All extraneous bodies, as musket bullets, when lodged in the dense portions of the long bones, should be removed, since they become sources of irritation; and when they are lodged in the epiphyses, they produce extensive caries, and hence they ought to be removed.

Necrosis is sometimes produced by the death of the internal periosteum and medulla, as is proved by the experiments of Troja.

Although I have stated that the dense bones terminate in necrosis, yet I do not mean to contend that they never end in caries. This latter disease, however, occurs only in early life when the bones are soft, or in scrofula, scurvy, &c.; or when their spongy extremities are attacked. They must first become swollen, as in spina ventosa, so as to permit the ulcerative papillæ to be formed.

The third class is the flat bones, as those of the cranium, the structure and fracture of which, as well as their diseases, have been described in page 13.

Many cases of caries of the bones of the skull are detailed by Mr. Louis.

Exostosis, which is a tumour consisting of a diseased secretion of bony matter, with sometimes a thickening of the periosteum, or a tumour that consists only of a diseased thickening of the periosteum, frequently attacks the bones of the cranium; although all bones of any density, and thinly covered with muscular substance, are as liable to this disease as the inferior maxillary bone, sternum, clavicle, ulna, and tibia. Of the bones of the cranium, the os frontis seems most susceptible. Exostosis depends often on a constitutional affection. The corrosive bichloride of mercury, or the bichloride of gold, has a peculiar efficacy in mitigating the pain in the syphilitic exostosis. The manner in which the bichloride of mercury may act in discussing syphilitic exostosis, appears, first as a stimulus, secondly, as affording oxygen, and thirdly, by the chlorine entering into union with part of the lime of the bone, thus breaking the bond of cohesion and permitting absorption to take place. This, so far as analogy goes, is supported by Madame Supiot's case of mollities ossium, and by scurvy, the ancient scourge of our fleets. Both of these diseases can be traced to the eating of chlorate of soda. In scurvy, the bones lose their cohesion, the epiphyses separate from the shafts, fractured bones disunite, and the alveolar processes are quickly absorbed. Of this chemistry affords a satisfactory explanation; and were solids and fluids taken up unchanged by the lacteals, we should be able to cure many diseases, and give rational theories of the operation of medicines.* Petit observes, that exostosis seldom attacks the constitution in this disease.

Spina ventosa appears an aggravated species of exostosis where caries follows with suppuration within the canal of the bone. The disease commences in the centre of the bony matter, and is consequent on inflammation; and attacks all the bones, particularly the lower jaw-bone, and even the extremities of the long bones. Numerous

* It sometimes attacks the scapula. A case is mentioned by M'Donald, wherein nearly all the bones of the body were affected with necrosis. A well marked case of necrosis of the inferior maxillary bone, is related by Guernery, where only the condyloid process of the old bone remained on the one side, and on the other, the ramus and side onwards to the second dens molaris. In this instance the new bone could scarcely have been secreted by the old. Walker of America mentions a case of necrosis of the inferior maxillary bone, where both rami and sides came away, leaving only the body or mental portion. Baier details a case where the inferior maxillary bone was so destroyed by the wheel of a mill, that it could not be saved, and yet was regenerated; Belmain, a case where two-thirds came away; Raygerus, a case of an old woman, eighty years of age, from whom the entire half of the inferior maxillary bone desquamated, without regenerating; and D'Angerville, a case of clavicle necrosed. Ruysch seems to have been the first who took notice of this disease; then Meckren, Scultetus, David, Chopart, &c.

* The preparations of gold were used as early as the sixteenth century by Lecocq, afterwards by Hoffman and others, and latterly by M. Chrestien of Montpelier.

cases are on record of this species of exostosis, the most remarkable of which are detailed by Saviard, Trippin, Bordenave, Morand, Mery, Houstet, and David.

Mollities ossium, or osteo-sarcosis, named also malacosteon, is that disease wherein the bones become so soft that they may be twisted or bent in any direction, and in which, being deprived of their earthy property, as if they had been macerated in diluted muriatic acid, their animal constituent only remains. Bones affected with this malady, when analysed, are found to possess only one-sixth or one-eighth of the phosphate of lime, while healthy bones have more than one-half. Of this disease, there are a few well marked examples, viz. Madame Supiot, Mary Hayes, Mrs. Forster, and James Stevenson. Both Madame Supiot and Mrs. Forster used a great deal of salt in their food. Stevenson's affection depended on a syphilitic taint. Cases are also related by Gagliardi, Courtial, and Morand. Mac Bride considers a prevalent acid in the system as the source of this disease, and recommends a course of lime water, and other antacids.

Rachitis may be considered a species or variety of mollities ossium. It attacks chiefly children, in consequence of the bones having more of the animal than the earthy principle; distorts principally the spinal column and ribs; and is generally combined with scrofula. The treatment of this disease consists more in diet and regimen than physic. The child requires to be supported with machinery, and should remain the greater portion of both day and night on an inclined plane; its diet should be generous, but in no degree stimulating. This treatment, accompanied with gentle exercise, or exposure in the open air, cold bathing, and the use of the flesh brush, will do more to remove the disposition which exists in this malady than all the medicines in the laboratory. Of all the preparations of lime, the phosphate promises most relief; and if madder were given in combination, or administered before or after it, the phosphate would prove a valuable remedy, provided we could prevent earthy depositions taking place in any other parts than in the bones. The experiments of Du Hamel might satisfy us of the safety of this treatment; for he observes, that in them, the skin, the brain, the nerves, the muscles, the cartilages, the membranes, remained perfectly natural; and that only the long osseous tendons which are hard in the middle, and all the true bones, or the most dense bones of birds, were coloured like carmine. The phosphate has been administered, but there was no quicker amendment than when diet and regimen alone were employed. The muriate of lime has been exhibited, but no beneficial result has been observed; and if it ever effects a cure, it must be on the principle that the chlorine combines with any soda existing in the bones, while the phosphoric acid attracts the lime. Soda is said by Berzelius to be present in bones. Carbonate of iron, as a tonic, seems a good remedy.

Fragilitas ossium is a disease which may be considered the opposite of molities, depending on a superabundance of the earthy constituent, and hence attacking people in advanced life. When the bones are broken in the disease, they unite with difficulty.*

Fragility occurs in the syphilitic, scorbutic, arthritic, scrofulous, and rachitic constitutions.

Anchylosis is the union of the extremities of the bones which compose a joint, and which have been rendered carious by inflammation; and in this case, is a result to be wished for by the surgeon, when he has failed to subdue the inflammation of the joint. This disease, however, has occurred without any marked increased action, as in the instance of Clark, detailed in the forty-first volume of the Philosophical Transactions, where all the bones, from the crown of the head, to the sole of the foot, were completely soldered together.

---

* Saviard describes a case of this disease, which occured to a woman only thirty years of age; all the bones broke to pieces in such a manner, that it was impossible to touch her without causing a fresh fracture; and in this condition she lived for six months. On dissection, the vertebræ, ribs, clavicles, bones of the arms, pelvis, thighs, and legs were shattered and bruised: not a bone was without a fracture. Those of the cranium gave way under the fingers, like those of a fetus fifteen days old. No cause could be assigned for this singular disease;—there was no constitutional affection whatever.

THE HEART.†—PLATE IX.* (SUPPLEMENTAL.)

INTRODUCTORY REMARKS.

The blood affords the materials of which the various parts of the body are composed; it matures and maintains them in a condition necessary for the performance of their functions; it is a compound fluid, and contains the elements or principles of which the different organs are formed; and although the whole of these have not yet been found, still a considerable number have, and in proportion as it has been carefully examined more have been added. There have already been discovered in it, the earthy salts which enter so largely into the structure of bone, the particular material which forms the basis of flesh or muscle, substances of which the brain and nerves are composed, water which is diffused throughout nearly every part, and which constitutes a large proportion of the fluids of the body, besides many others in smaller quantity which contribute to the formation of various organs. In the lower animals, after the kidneys have been removed the principal constituent of urine has been obtained from the blood; after the extirpation of the mammæ, the sugar of milk has been found in it; and after extracting the testes from a toad, impregnation has been produced with it artificially. There are two kinds of blood contained in the body, arterial and venous. Arterial blood is of a bright red or vermilion colour, and has the property of nourishing and maintaining the vitality of the various organs. Venous blood, again, is of a dark red colour, and is insufficient of itself to support life; when circulated instead of arterial blood, it speedily destroys the life of the individual.

The heart is the centre of the circulating system; and, in explaining the course of the blood, the description commences at that organ. From the heart, then, it flows along the arteries, being propelled first into the large vessel, the aorta (E), from which numerous branches arise, that subdivide, and ultimately terminate in minute capillary vessels, from which the particles for the nourishment of the different tissues escape by permeation: having accomplished these functions, and having afforded the stimulus necessary for vitality, it changes its character, and becomes venous. The capillaries now begin to unite, and give rise to another set of vessels, the veins, along which the blood continues its progress, and these gradually increasing in size, ultimately form two trunks, the superior vena cava (*h*), and the inferior vena cava (*i*), by which it is returned to the heart. In order that it may return to the state of arterial blood, and have its vivifying properties restored, it is conveyed to the lungs by the pulmonary artery (F), where it is exposed to the action of the atmospheric air, carried to their interior by the wind-pipe or trachea (K), and its subdivision, the bronchial tubes (k, k); and this important change having been performed, it is brought back to the heart by the pulmonary veins (1, 2), to recommence the course just described. The blood in its progress may be said to describe two circles; in the one passing from the heart to the body, and returning to the heart; in the other proceeding from the heart to the lungs, and again coming back to the heart: hence the appellation circulation applied to the course of this fluid, and circulating to the vessels which carry it on.

The heart is situated in the cavity of the thorax, and extends obliquely from the space between the second and third ribs of the right side, to that between the fifth and sixth of the left; here it is placed in a space or compartment termed the middle mediastinum, and is contained in a bag named pericardium (c).

EXTERIOR CONFORMATION OF THE HEART. (PL. IX.* IX. X.)

The heart has the form of a cone, flattened in the antero-posterior direction, and presents a base, an apex, an anterior and a posterior surface, a right and left border, four grooves, and four cavities distinguished by the following names:—Right auricle (d), left auricle (*d*), right ventricle (D), and left ventricle (g).

The *base*, situated superiorly, and directed a little backwards, is opposite the interval between the second and third ribs of the right side, and has attached to it the great vessels (E, *h*, *i*, F, 1, 2). The *apex*, placed inferiorly, is on a level with the space between the fifth and sixth ribs of the left side, and presents a slight notch. The *anterior surface*, directed a little to the left, is convex in its general outline, and exhibits four divisions corresponding with the cavities, separated by grooves, to be noticed more particularly hereafter. The *posterior surface*, which is turned slightly to the right, and partly supported by the central aponeurosis of the diaphragm, is flat; the four divisions with the intervening grooves are also observed. The *right border* is rather narrow and directed a little downwards. The *left border*, much thicker than the preceding, looks somewhat upwards. The *grooves* are four in number. The first, named the right auriculo-ventricular, marks the division between the right auricle and ventricle, and is placed upon the anterior and posterior surfaces, and right border. The second, which receives the name of left auriculo-ventricular, occupies a position upon the left side of the heart, corresponding with that of the preceding upon the right. The third is termed the anterior inter-ventricular; it passes downwards, and to the left, upon the anterior surface between the two ventricles to the apex, where it ends in the notch before mentioned. The fourth is the posterior inter-ventricular; it descends nearly vertically upon the posterior surface to the notch at the apex.

The *right auricle* (d), situated at the upper and right

† Note by the Publisher.—*This representation of the Heart and Lungs, with their descriptions, have been kindly contributed by Dr. A. J. Lizars, and forms the first supplemental Plate promised in our Prospectus; and we have judged it most advisable to place them here, that they may precede the developments which immediately follow.*

side of the heart, is directed forwards, and has an irregularly cubical form. Anteriorly it presents a prolongation named the appendix, shaped somewhat like the ear of a dog, from which the name of the cavity is derived (*auricula*, the ear). Posteriorly it is partly free, and partly bound down to the vessels of the right lung. Superiorly it receives the superior vena cava (*h*), and in the rest of its extent is free. Inferiorly it is joined by the inferior vena cava (*i*) and coronary vein (*k*), and is attached to the right ventricle (D). Externally it is free. Internally it is connected with the left auricle (*d*). It receives the venous blood from the various parts of the body, and also from the substance of the heart, and propels it into the right ventricle.

The *right ventricle* (D) is placed at the inferior and right side of the heart. It has the form of a pyramid, and exhibits a base, an apex, and three walls. The base, situated superiorly and directed to the right, has attached to its right, the right auricle (*d*), and gives off on its left, the pulmonary artery (F). The apex points downwards and to the left, and is in apposition to that of the left ventricle (g); the notch of the heart intervening. The walls are distinguished, according to their situation, into an anterior, a posterior, and an internal; the first is convex, the second is flat, and the third is connected with the opposite cavity (*g*). This cavity obtains the venous blood from the right auricle, and forces it into the pulmonary artery, which conducts it to the lungs in order to be purified.

The *left auricle* (*d*) occupies the superior and posterior aspect of the heart; its form is that of a cube. From its anterior surface projects the appendix, similar to that of the right auricle; the remainder of this surface is obscured by the aorta and pulmonary artery; its posterior surface is flat; the external receives the left pulmonary veins (2); the internal is in connexion with the right auricle (*d*), and receives the right pulmonary veins (1); superiorly it is free; and inferiorly it is united to the left ventricle, with which it communicates. The blood, having been purified in the lungs and changed to arterial, is conveyed to this cavity by the pulmonary veins, thence it proceeds to the left ventricle.

The *left ventricle* (g), in form, resembles the right, but is more rounded. The base, directed upwards and a little to the right, is attached on the left side to the left auricle (*d*), and on the right gives origin to the aorta (E). The apex looks downwards and a little to the left, and is in connexion with that of the right ventricle, with the intervention, however, of the notch at the point of the heart. The anterior wall is convex, the posterior flat, and the internal united to that of the opposite cavity (D). This cavity receives the arterial blood from the left auricle, and propels it into the aorta.

The blood circulated in the various organs of the body is returned by the superior vena cava (*h*), the inferior vena cava (*i*), and the coronary vein (*k*), to the right auricle (d), from which it is conveyed to the right ventricle (D), and thence to the lungs by the pulmonary artery (F) to be purified; from these it is brought by the pulmonary veins (1 and 2) to the left auricle (*d*), from which it is carried to the left ventricle (g), and from this cavity is propelled into the aorta (E), the various branches and subdivisions of which circulate it in the different parts of the body.

ARTERIES OF THE HEART. (PL. IX.* IX. X.)

The substance of the heart is nourished by two arteries, distinguished by the names of right and left coronary.

The *right coronary artery* (*r*) arises from the anterior and right side of the ascending portion of the aorta (E), close to the heart; it immediately enters the right auriculo-ventricular groove, in which it runs, proceeding between the right auricle and ventricle, and applied upon the anterior surface of the heart, the right border, and the posterior surface; in the last situation it reaches the posterior inter-ventricular groove, in which it descends vertically between the two ventricles to the notch at the apex of the heart, where it terminates. In this course, then, it is contained in the right auriculo-ventricular, and posterior inter-ventricular grooves, and runs first between the right auricle and right ventricle, and, secondly, between the two ventricles. It furnishes a number of branches to the right auricle, right ventricle, left ventricle, the commencement of the aorta and pulmonary arteries.

The *left coronary artery* (*s*), considerably smaller than the preceding, arises close to it from the anterior and left side of the aorta; it runs first a little to the left between the pulmonary artery and left auricle, and appears upon the anterior surface of the heart; it now passes into the anterior inter-ventricular groove, and proceeding downwards between the two ventricles, gains the notch at the apex, and ends by anastomosing with the right coronary. It supplies the left auricle and the two ventricles, besides affording branches to the aorta and pulmonary artery; the largest branch is contained in the left auriculo-ventricular groove, and unites with the right coronary upon the posterior surface of the heart. Besides the anastomosis just mentioned, and that at the apex of the heart, the two coronary arteries frequently inosculate by means of their smaller branches.

VEINS OF THE HEART. (PL. IX.* IX. X.)

The blood circulated by the coronary arteries is returned by a number of veins, the largest of which receives the name of coronary, the others are termed the veins of Thebesius.

The *coronary vein* (*k*) commences at the apex of the heart, from which it proceeds and ascends in the anterior inter-ventricular groove, and having gained the upper part, leaves it to enter the left auriculo-ventricular groove; in this it continues its course, sweeping round the left border of the heart, and passing from the anterior to the posterior surface; it now reaches the inferior and posterior part of the right auricle, in which it ends. In this progress it receives a number of branches; the largest of which is situated in the posterior inter-ventricular groove, and unites with it close to its termination in the auricle.

The *veins of Thebesius* are irregular in size and number; the largest are usually seen upon the anterior surface of the heart, accompanying some of the branches of the right coronary artery, and terminating in the anterior and inferior part of the right auricle.

For the internal conformation of the heart see text.

INDEX TO LETTERS OF REFERENCE OF PLATE IX.*

1, Superior pulmonary vein of the right side.
2, Superior pulmonary vein of the left side.
d, Right auricle of the heart.
d, Left auricle of the heart.
D, Right ventricle of the heart.
E, Aorta, truncated.
F, Pulmonary artery.
f, Right and left branches of the pulmonary artery.
f, Fibrous cord, the remains of the ductus arteriosus of the fetus.
g, Left ventricle of the heart.
G, Right and left lungs.
h, Superior vena cava, truncated.
i, Inferior vena cava, truncated.
K, Trachea.
k, Right and left bronchial tubes.
k, Coronary vein.
r, Right coronary artery.
s, Left coronary artery.

BLOOD-VESSELS AND NERVES

OF

THE TRUNK.

As the blood-vessels and nerves of the trunk are so intimately connected, that they require several views to illustrate them, the reader must bear in mind that the first six plates are blended in the following descriptions. The plates are, however, mentioned along with the letters of reference, as often as found requisite for perspicuity.

In Plate IX. we have a representation of the thoracic and abdominal viscera after the anterior or sternal parietes have been removed; the viscera being disturbed as little as possible, in order to exhibit them in their natural position. The letters A are placed on the ribs, truncated near their cartilages, and separated to a considerable extent, which has enlarged the diaphragm, B, and brought the greater number of objects into view. The letters C indicate the pericardium or capsule of the heart, that consists of two layers, the outer being fibrous, the inner serous; the pericardium, C, is laid open to expose the heart, D, which is placed between the lobes of the lungs, G, G, obliquely in the centre of the thoracic cavity, extending from the second rib of the right, to the sixth rib of the left side; and this capsule, which is attached to the central aponeurosis of the diaphragm, to the anterior mediastinum, or the reflected layers of the pleuræ which separate it from the lungs, and to the large blood-vessels connected with the heart, is reflected and continued over its surface, so that the heart is equivocally said to be without the pericardium; the fibrous layer becomes blended with the external coat of the large blood-vessels; the serous only invests the heart and forms a shut sack; at the points where the pericardium is attached to the large blood-vessels, it forms several angles, named its cornua. The nervous threads, 6, 6, distributed on the pericardium, derive their origin from the great sympathetic nerves, 7.* The letter D is placed on the right ventricle of the heart;† d, on the right auricle;‡ *d*, on the left auricle.§ E, is the aorta,‖ which derives its origin from the left ventricle,¶ as seen in Plate X., Fig. 1, letter *g;* and F indicates the pulmonary artery,* arising from the right ventricle. The small arteries ramified on the surface of the heart, are the coronary arteries,† at the side of which are seen the branches of the coronary vein; *r* indicating the right artery; and *s* the left artery; their further distribution is seen in Fig. 1 of Plate X., where they divide the heart into its base, or auricular portion, named also *pars cordis venosæ*, and into its lower or pyramidal part, the groove made by the arteries being named *sulcus auriculo-ventricularis.* The white nervous threads encircling the aorta and pulmonary artery, are the cardiac twigs formed by the great sympathetic and pneumogastric nerves.

In Plate X. is seen the minute structure of the heart, and the same letters are applied as in Plate IX. Fig. 1 represents a posterior view of the heart, injected so as to distend the auricles; *g* indicating the left ventricle; d the right auricle, the proper auricular portion being marked also d, as seen in Plate IX: three veins, the two venæ cavæ and coronary vein, terminate in this latter cavity; the superior or descending vena cava being marked *h*, and its entrance into the right auricle, seen in Fig. 2, also marked *h;* and in Plate IX. this vein is observed to be formed by the vena azygos, *t*, and the two subclavian veins, *u v*. The inferior or ascending vena cava is marked *i;* and its entrance, seen also in Fig. 2, is marked *i:* this vein is seen in the abdominal cavity, before penetrating the diaphragm in Plates XII. and XIII., marked likewise *i*. The letters *k* indicate the coronary vein and its branches; and its entrance into the auricle is marked with the same letter in Fig. 2, where is likewise seen its delicate valve.

In Fig. 2, the right auricle is cut open to show its serous surface and muscular structure, named musculi pectinati, which delicate bands are only seen in the auricular portion, marked with the letters d, the general pouch being termed *sinus auriculæ.* The septum auricularum is the general flat surface seen in this exposed cavity, having the oval impression, l,‡ nearly in the centre, where the foramen ovale existed in the fetus, which aperture is seen in the fetal heart, Fig. 3, marked also l, the membranous

* The attachments of the pericardium should be considered by the practitioner, otherwise he is liable to be deceived in the pulsations of the heart; for that which is felt at the scrobiculus cordis has been mistaken for aneurism of the abdominal aorta.

† Named also anterior or pulmonic; also sinus pulmonalis.

‡ Termed also pulmonic, or anterior, or sinus venosus, or sinus venarum cavarum.

§ Also styled posterior, or systemic, or sinus venosus, or sinus pulmonalis.

‖ Named also systemic, or systematic artery.

¶ Denominated also posterior, or systemic, or systematic, or aortic ventricle.

* Also designated pulmonic.

† Also termed cardiac. Although these arteries are almost invariably two in number; yet in some cases which have occurred, only one has been found; in others three. Where two occur, the one is sometimes larger, and supplies a great portion of the space allotted for the other.

‡ Named also fossa ovalis, vestigium foraminis ovalis.

valve being wrinkled down;* and the superior portion of the surrounding margin, or fleshy ring, which is thicker, is named annulus ovalis or isthmus Vieussenii.† Between the two venæ cavæ there is a gentle elevation, or thickening of the parietes of this cavity, marked m, and named tuberculum Loweri, which tubercle is more distinctly defined in the quadruped; and at the orifice of the inferior vena cava, is seen the valve of Eustachius, n. Over all the internal surface of this cavity are observable small holes, designated after Thebesius, and indicated by little dark spots. The incision is carried downwards, from the auricle to the commencement of the right ventricle, or the auriculo-ventricular opening, which is of an elliptic form and about an inch in diameter, in order to bring into view part of the tricuspid valve,‡ which is attached to its circumference, as seen in Fig. 4, where this cavity is laid open, which extends from the base of the right auricle nearly to the apex of the heart: and the valve marked O in both figures. In this cavity numerous fleshy slips, termed columnæ carneæ,§ p, p, are observed, and seen to terminate, like muscles in general, in tendons, named chordæ tendineæ, which are inserted either into the membranous part of the valve, marked O, or into the opposite side of the cavity. These fleshy pillars are divided into three orders; the first, adherent by both extremities, are free in the rest of their extent; the second are attached by their ends, as also by the greater part of their circumference, and are far from being prominent; the third set consists of three or four bundles which extend from the summit to the base of the cavity, where they are attached to the apices of the tricuspid valve by the chordæ tendineæ; and the whole internal surface of the ventricle is studded with depressions,‖ which give it a reticulated or honeycomb appearance.

The base of the ventricle extends upwards in the figure of a funnel, and gives attachment to the pulmonary artery. The letters q point out the three semilunar¶ valves at the mouth of the artery, and their convex surfaces are represented with a small space between them, to show their shape; and in the centre of their loose edges, where they all meet, are three small papillæ, or one in the middle of each membranous fold, of a redder colour than the rest of the membrane, and generally designated after Aurantius.** On the concave aspect of the valves there are indentations or depressions in the walls or coats of the pulmonary artery, corresponding to the semilunar shape of the valves, named the sinuses of Valsalva; and these form corresponding projections on the outer surface of the artery, that resemble the valves of the veins; two of which projections are seen in Plate IX. at F. The pulmonary artery, F, is seen in Fig. 1 to divide into its right and left branches, f, f; the left or shorter proceeding directly to the left lobe of the lungs, G, of Plate IX., and subdividing into innumerable branches the right or longer branch lies under the arch of the aorta, E, and divides also into numerous branches, to be distributed to the right lobe of the lungs, G, of Plate IX. In the fetal heart, Fig. 3, the pulmonary artery, F, is observed to divide into three branches, f, f, *f*; the two first, marked with the roman character, are the right and left branches which are seen in the adult; the latter, marked with the italic *f*, is the ductus arteriosus, which joins the aorta, E, at the termination of its arch; and the same arrangement of vessels between the heart and lungs is seen in Fig. 6.

In Fig. 1 of Plate X., *d* indicates the left auricle, in which are seen terminating the four pulmonic venous trunks; 1, 1, being the two of the right side; and 2, 2, the two of the left side: the latter are seen in situation on the lung in Plate IX. A peculiarity exists in the lungs, the arteries are more numerous and larger than the veins. The letter *d*, which is more in the shade to the left, is placed on the proper auricular portion of this sinus venosus, and is seen in position in Plate IX., where *d* is also placed on the auricular appendage, the only portion visible in the natural position of the heart. This appendage is smaller than that of the right auricle. This cavity has an appearance, internally, similar to that of the right auricle, and has therefore not been represented.

Fig. 5 is a view of the cavity of the left ventricle, which only differs from the right in having thicker and stronger parietes, and larger columnæ carneæ; those marked *p*, consisting of two fleshy fasciculi, extend to the membrane *o*, and constitute the valvula mitralis, placed between this ventricle and its corresponding left auricle, *d*, or at the auriculo-ventricular aperture; the larger division of the membrane looks towards the aortic opening; and numerous other fleshy columns are observed in the inner surface of this cavity, passsing in various directions, but chiefly from the base to the apex of the heart. The letter *g* indicates the septum ventriculorum, which has an oblique direction and is discovered externally by the left coronary artery, *s*, with its accompanying vein, forming a slight groove, as seen in Figs. 4 and 2 of this plate, and in Plate IX.; while the other or right coronary artery, *r*, Fig. 1, Plate X., with its accompanying vein, points out the septum, on the dorsal aspect of the heart.

The semilunar valves, *q*, at the commencement of the aorta, E, are precisely similar to those at the mouth of the pulmonary artery, F; and at the commencement of the aorta, in two of the cavities or sinuses of Valsalva, the two coronary arteries take their origin. The right one, *r*, Plate IX., is seen to arise from the aorta, and to proceed between the right auricle and right ventricle, till it reaches the septum ventriculorum, as seen in Fig. 1, Plate X., whence descending along the septum near the apex of the heart, anastomoses with the left artery; and in this course, as seen in these figures, gives origin to several branches, some of which anastomose with those of the left artery, while others supply the right auricle, the right ventricle, and also part of the left cavities of the heart and the coats of the vessels. The origin of the left coronary artery, *s*, is not observable, but its emergence between the left auricle and left ventricle is seen in Fig. 1, Plate X., and its course between the left ventricle and right ventricle in Plate IX., where the vessel descends along the septum to unite with the right artery. On reaching the septum ventriculorum, the artery gives off a branch that continues between the two left cavities, and anastomoses with a branch of the artery of the right side; and this left artery supplies chiefly the left cavities; but they both contribute to supply all the cavities, and frequently anastomose with

* Sometimes the aperture remains pervious in the adult female, rarely in the adult male.

† Denominated also columnæ foraminis ovalis, and annulus fossæ ovalis.

‡ Termed also triglochin.

§ Named also lacertuli, and musculi papillares.

‖ Styled also foveæ, pits, or grooves.

¶ Denominated also sigmoid.

** Named also corpusculum Morgagni, corpusculum sesamoideum, nodulus, and triangular granula.

each other; and they also both contribute to supply the coats of the vessels within the pericardium, and even this membrane itself.

The serous tunic of the aorta and pulmonary artery is continuous with that of the heart, while the middle coat has a festooned border with three points, separated by three arched intervals, the points being applied to the margin of the ventricle and connected to a thin ligamentous ring that surrounds it by means of fibrous tissue, which tissue also fills up the intermediate spaces.

The trachea,* K, seen in Plates IX., XI., and XV., commences at the cricoid cartilage, and descends beneath or dorsad to the anterior or sternal muscles of the neck, and superficially or dermad to the œsophagus, I; and on entering the thorax, the left vena innominata, *v*, extends across it: the trachea then descends to the third dorsal vertebra, and on the right side of, or dextrad to, the arch of the aorta, divides into two branches named bronchi;† the right bronchial tube, larger and shorter than the left, proceeds directly across, behind or dorsad to the right pulmonary arterial branch, the two right pulmonary veins, and the vena cava descendens, enters the mass of the right lungs at its middle third, and subdivides into two branches, one being intended for each lobe; these into lesser and lesser branches, but always in this binary division, which ultimately terminate in the most delicate membranous cells.‡ The lower branch of this right bronchus gives off a branch to its middle lobe. The left bronchial tube, longer and smaller than the other, descends obliquely through or under the arch of the aorta, behind or dorsad to the left pulmonary arterial branch and veins, and enters the substance of the left lungs, subdividing like the right aerial tube. The course of the left before its subdivision is necessarily longer than the right tube, and is seen in Plate XII., marked k, where the lungs are transferred to the right side.

In Plate XI., Fig 1, a posterior view of the trachea, K, and its division into the two bronchi, k, k, with a portion of each side of the lungs are represented; and thus the lungs are divided into two portions, but communicating through the medium of the trachea. The smallest bronchial capillary tubes do not terminate in single cells, but in a cluster of delicate membranous cells that communicate with one another, and form what is termed a lobulus; and round these lobuli, or clusters of cells, are disposed the minute ramifications of the pulmonary artery, which from the elegant and wonderful distribution, are known by the name of the rete mirabile of Malpighi; which structure should be well considered by the practitioner in hemoptysis and pneumonia. These delicate objects cannot be seen in the human lungs, but may be satisfactorily traced in the inferior animals, particularly the amphibiæ, as the turtle, crocodile, and boa constrictor. All that we can observe in the human body, are the segments of the fibro-cartilaginous rings of the trachea and bronchial tubes, together with the fibrous, muscular, and mucous structures, and the general parenchyma, all of which are displayed in Plates IX., XI., XII., and XV.

In Plate XI., Fig. 1, the trachea, K, is drawn from its commencement at the cricoid cartilage to its division into the bronchi, k, k, with some of their subdivisions, letters *k*; and these irregular fibro-cartilaginous arches, which vary from sixteen to twenty in number, are so arranged, that the inferior or sacral easily insinuate themselves within the superior or atlantal, in the motions of the trachea and lungs; and are connected to each other by strong thin elastic fibrous membranes fixed to their edges, and by short muscular fibres, which are exterior to them, as seen in Fig. 1, Plate XI., from the inside of the trachea. The trachea and bronchi are completed in their dorsal aspect by the same elastic membrane, together with muscular fibres marked A; the elastic portion is of a bluish tinge; the muscular fibres, a, are arranged longitudinally and transversely, and pervade the whole aerial tubes, from the first cartilaginous semicircle of the trachea to their termination at the cells; the transverse muscular fibres extend between the extremities of the cartilages; and the whole aerial tubes, from the larynx downwards, are lined with a highly sensitive and very vascular mucous membrane, letters C, which is continuous with the lining membrane of the pharynx and mouth. As the bronchial tubes decrease in size, the rings lose their annular shape, and become lamellæ of an irregular form, placed in different parts of the circumference of the tube. The annular figure is present at their points of subdivision. On the outer surface of the elastic fibrous membrane, are observable a number of little mucous glands, as in this figure at A.

In the substance of the lungs, G, G, a portion of each of which is bisected to show the parenchymatous or spongy appearance, the letters f indicate the branches of the pulmonary artery, the digits 1 and 2 the branches of the pulmonary veins. Besides the aerial structure, and the arterial and venous arrangement, there exists in the lungs a considerable quantity of delicate cellular tissue and glands; the former connecting the lobuli, is termed interlobular substance, and is very loose and thin, forming spongy sheaths to the ramifications of the bronchi and blood-vessels, and ultimately spreading over the outer surface of the lungs, and uniting with the pleura pulmonalis: the latter, or glands, which are more numerous about the roots of the lungs, marked b, are styled bronchial, and are lymphatic; so that there are a number of lymphatic vessels leading from the interlobular substance to these glands. There are also found in the lungs, small arteries, named bronchial, which nourish them, and are seen in Plate XII., marked 3, 3, 3, taking their origin from the thoracic aorta, E,* and proceeding to the bronchi, which they accompany through their ramifications: these also supply the pericardium, the coats of the aorta, and pulmonary artery, anastomosing with the coronary branches, the pulmonary and œsophageal arteries, and with the pulmonary veins. The bronchial veins generally terminate in the vena azygos and superior intercostal veins: and one of the bronchial veins of the left side is seen in Plate XII., marked 4, terminating in an anomalous vena azygos,† 5, of the left side.

The nerves which supply the lungs are seen in Plate XII., marked with the digits 2, and are twigs of the pneumo-gastric, 1; and the plexus which they form is

* Named also windpipe, or aspera arteria.

† Also termed bronchiæ.

‡ Styled also vesicles, or follicula.

* The bronchial, like other small arteries, are very irregular in their origin, arising sometimes from the intercostal artery, sometimes from one of the œsophageals, and sometimes from the internal mammary, from the inferior thyroideal, and from the subclavian arteries. The bronchial arteries vary from two to five in number.

† Sometimes named the demi-azygos. This vein of the left side is not uncommon.

denominated bronchial or pulmonic:* these nervous twigs accompany the bronchi, the pulmonary arteries and veins, and the bronchial arteries, throughout their ramifications. Parenchyma is applied to the assemblage of the tissues in the lungs, with the exception of the pleura and the mucous membrane.

The lungs are invested with a thin, semi-transparent, serous membrane, named pleura pulmonalis, as seen in Plates IX. and XII., which membrane, proceeding to the roots of the lungs, and surrounding the bronchial tubes and large blood-vessels, is stronger and thicker, and has received the appellation of ligaments of the lungs; where this membrane arrives at their roots posteriorly, the pleura of each side unites by cellular tissue, and forms the posterior portion of the mediastinum;† and these layers, in descending to the dorsal vertebræ, are soon separated by the termination of the trachea, the œsophagus, the thoracic aorta, the pneumogastric, the great sympathetic nerves, the vena azygos, the thoracic duct, and several lymphatic glands: these objects, connected or surrounded by loose cellular tissue, are contained in a somewhat triangular space, termed the posterior cavity of the mediastinum. The pleura of each side now adheres to the sides of the bodies of the dorsal vertebræ, to the heads of the ribs, and to the intercostal muscles, and extends round, lining all the parietes of the cavity onwards to the sternum, where the laminæ unite a little to the left of the mesial plane, and form the anterior portion of the mediastinum.‡ Where this membrane lines the ribs, it is denominated pleura costalis.

In the fetus behind the first bone of the sternum, the thymus gland is situated, which extended from the thyroid gland to the diaphragm, and consisted of a lobulated structure with its extremities divided into two processes; and in the adult, when this gland is absorbed, a little cellular tissue remains between the laminæ of the pleuræ, before they unite to form the anterior portion of the mediastinum; which space is denominated the anterior cavity of the mediastinum. The mediastinum proceeds dorsad, but is interrupted in its course by the pericardium which it invests, and afterwards by the lungs investing them to their roots, from whence we commenced the description; so that it forms a continuous serous surface, and will probably be more easily understood by stating that the thoracic cavity and its contents have a shining continuous serous surface, which is named pleura. A painter would comprehend it, were he told that this cavity and its contents were glazed. The diaphragm, B, is also invested with the pleura;§ and the thoracic cavity on each side is shut up atlantad, by the pleura extending from the aorta along the subclavian artery and vein to the first rib, forming here a small cul-de-sac; so that the student in dissecting will find, when the thoracic cavity is opened, that every point he touches is pleura, and that there are two shut sacks. Both the anterior and posterior portions of the mediastinum are necessarily removed to expose the heart and other viscera; but the posterior cavity may be easily understood, by examining, in Plate XII., the objects situated between the root of the lungs, G, and the sides of the dorsal vertebræ, T.

* Likewise the anterior pulmonic plexus, as the nerve of this side runs a little more anterior or sternad than the right. This plexus is sometimes termed the left pulmonic.

† Or mediastinum dorsale.

‡ Or mediastinum pectorale.

§ This should be denominated pleura diaphragmatica; and where it invests the heart, pleura cardiaca.

Each lung is of a conical figure, the base resting on the diaphragm, the apex extending a little above the first rib. The outer surface is smooth and convex to correspond with the arched form of the ribs; the inner is compressed and rests on the mediastinum; the apex forms a prominence which ascends between the scaleni muscles; the base is concave with a sharp border, and rests on the diaphragm; the anterior margin is thin and sharp; the posterior border round and prominent, and is received into the groove formed between the vertebral column and the ribs. The right half of the lungs generally consists of three divisions; the left half usually of two, denominated lobes; and these are formed by fissures, or sulci. The upper lobe is conical; the lower quadrilateral. In the drawing of Plate IX. there appear more than three peculiar to the right portion of the lungs, which arises from it being inflated; and the right is shorter and broader than the left, in consequence of the heart lying more to the left than to the right side, and the diaphragm advancing more atlantad on the right than on the left side, owing to the pressure of the liver: the heart occupies a sinus or notch in the left half of the lungs. The conical shape of the lungs, and other peculiarities, are at once seen in Plate IX. Their colour in the adult is bluish-grey; in the fetus it is reddish; and in old age purple or livid, with dark spots; but the colour is greatly modified, according to the relative quantity of blood present at different times. From a dead person being commonly placed on his back, the dorsal parts which are dependent are always of a darker tinge.

The other objects observed in the thoracic cavity of Plate IX., are the phrenic* nerves, and several blood-vessels. The phrenic nerve, marked 8, is seen also in Plate XV., where it is observed to derive its origin from the cervical nerves in conjunction with the axillary plexus, 9, and is generally described as arising from the third and fourth cervical nerves; but this nerve has always a more extensive origin or connexion: in this drawing of the head and neck, the nerve is seen to be connected with all the cervical nerves, and with the great sympathetic nerve, 7. In some instances the phrenic receives a twig from the hypoglossal nerve, 3, and other twigs from the pneumogastric, 1. When formed, the phrenic nerve, 8, descends on the anterior scalenus muscle, L, between the subclavian vein, *u*, and subclavian artery, H, and then enters the thoracic cavity. The left subclavian vein is marked *v*. In this cavity the nerve is only seen on the left side, a very little detached from its connexions, and descends attached to the pericardium, C, and is dispersed in a number of twigs on the diaphragm, B, even to the inferior crura of the muscle; some of them penetrating this muscle, and uniting with the cœliac and renal plexuses of the splanchnic nerve in the abdominal cavity. The phrenic nerve of the right side, besides forming similar junctions, contributes to supply the liver. The phrenic, like other nerves, give origin to twigs, supplying the objects contiguous to them in their course; and in this manner the scaleni muscles, the thymus gland in the fetus, the pericardium, and the pleura are supplied. The letters M point out the internal jugular veins terminating in the subclavian or innominata veins, *v*, *u*; the letters N indicate the vertebral veins, also ending in the venæ innominatæ; O is placed on the trunk of the thyroideal veins, ending in the left vena innominata, *v*; H, H, indicate the subclavian

* Or diaphragmatic.

arteries; P, P, the carotid arteries; Q, the arteria innominata; R, the vertebral artery; and S the inferior or ascending thyroideal artery. The digits 1 point out the pneumo-gastric nerves; 10 indicate their recurrent twigs; 7 the left great sympathetic nerve; and 11 one of its cardiac twigs.

Having thus described the heart and lungs, with their blood-vessels and nerves, I shall proceed with the remaining arteries, veins, and nerves of the thoracic cavity. The aorta, E, which, as we have seen, commences from the left ventricle of the heart, immediately gives origin to the two coronary arteries, *r* and *s*, and makes an elegant curve or arch from the right to the left and dorsad towards the third bone of the vertebral column, T, of Plate XII., along which it descends a little sinistrad to the mesial line, till arriving at the diaphragm, B, through the crura of which the aorta passes into the abdominal cavity, and continues its course until it arrives at the fourth lumbar vertebra, where it divides into the iliac arteries.

In its course in the thoracic cavity, the aorta is named descending or thoracic; its arch ascends to the level of the cartilage of the second rib, the ascending portion being behind the sternum, the transverse part resting on the extremity of the trachea, and the recurrent branch of the left pneumo-gastric nerve encircling it. From its arch, as seen in Plate XII., there arise three conspicuous branches; the first, marked Q, is the arteria innominata; the second, marked P, is the left carotid artery; and the third, marked H, is the left subclavian artery; the description of which will be given afterwards, where they are traced to their destinations, the head and upper extremity.

The aorta next gives origin to small ramusculi, named pericardiacæ, and to the bronchial arteries, 3, 3, 3, which have already been described. The œsophageal arteries, *b*, *b*, are very irregular, both in their number and distribution, generally varying from two to five; and according to the point of the aorta, E, from which they derive their origin, they assist in supplying the contiguous viscera with branches. The intercostal arteries,* marked 12, vary from seven to ten in number, according as the superior intercostal, 12,† near the first rib, which is a branch from the subclavian, H, supplies few or more intercostal spaces, and as one aortic intercostal supplies one or two spaces; for one artery frequently divides so as to proceed to two ribs. These little arteries are observed to run across the spinal column to the inferior or sacral margins of the different ribs, along which they proceed near the cartilages, where they are lost as continuous tubes.‡ In this course they give origin to small branches that supply the spinal column, canal, and cord, the muscles of the back, the intercostal muscles, the ribs, and the pleura, anastomosing with the internal mammary artery, 14, of Plate IX., and 14 of Fig. 2, Plate XI., and with the thoracics, letters a, of the axillary artery of Plate XIX., and some of them with branches of the diaphragmatic artery, Z, of Plate XII., as well as with the epigastric, X, of Plate IX. Those which supply the spinal cord are named medullares; those that supply the theca vertebrarum, vertebro-meningeal; and those supplying the cellular tissue exterior to the theca, vertebro-involucral. Those small arteries are very irregular.

* Named also inferior or aortic.

† Also termed intercostalis prima.

‡ The course of the intercostal arteries should be considered in paracentesis thoracis.

The course of the intercostal veins, 15, is the reverse of the arteries; they are seen terminating in the vena azygos, 5, which is observed to pass under the arch of the aorta, E, in order to join the azygos, *t*, of Plate IX. of the opposite side, where it ends in the vena cava superior, *h*, of Plate IX. The vena azygos of the left side, when it exists, seldom begins so far sacrad as the vein of the right side; the latter generally collecting the blood of the lumbar veins, sometimes deriving its origin from the vena cava inferior, and ascending on the right of the aorta on the spinal column, through the aortic aperture in the diaphragm, similar to the left one represented in Plate XII., receives the blood of the diaphragmatic, œsophageal, intercostal, and bronchial veins in its course along the bodies of the vertebræ, it then turns round the root of the right lungs, hooks the right bronchus, and terminates in the vena cava superior, where this is invested with the pericardium, as seen in Plate IX.

The digits 7, Plate XII., point out the great intercostal or great sympathetic nerve,* which in the neck, before twining round the subsclavian artery, H, gives origin to the twigs, marked 11, that form the cardiac plexus, and unite with the recurrent, 10, of the pneumo-gastric nerve. These twigs are observed surrounding the aorta, E, near the beginning of its arch, and descending to its origin from the left ventricle: they are also seen in Plate IX. encircling the aorta, E, and pulmonary artery, F; and in the same Plate, one or two twigs are observed surrounding the left subclavian vein, *v*. In the thoracic cavity other twigs are seen to derive their origin from the sympathetic nerve, 7; the superior or atlantal, 14, descending obliquely across the aorta, E, to the root of the lungs, where they contribute to form the bronchial plexus; the nervous thread, marked 16, forms a junction with the œsophageal plexuses, *a*, *a*, of the pneumo-gastric nerve, 1, 1; and the remaining twigs which are not marked, are lost on the aorta, E. The twigs, marked 17, unite to form the splanchnic nerve. The digits, 9, indicate the individual intercostal nerves which derive their origin from the spinal marrow, emerge from the foramina common to the vertebræ, accompany the intercostal arteries, and supply with nervous influence the same parts; and their junctions with the great intercostal soon after their commencement are distinctly seen. Two or three of the superior intercostal nerves proceed out of the thorax, penetrate the serratus magnus, which they supply in their course, and extend to the axillary glands, the skin of the axilla, and down along the arm; the longest is named the cutaneous of Wrisburg. These twigs are seen in Plate XIX. of the upper extremity, marked also 9.

The pneumo-gastric or nervus vagus,† of each side, marked 1, is seen in Plate IX. descending between the subclavian vein, *v*, and artery, H, to enter the thoracic cavity; and on the left side is seen behind the pericardium. In Plate XII. the nerve is observed descending sinistrad of the arch of the aorta, E, and giving origin to its recurrent, 10, described afterwards; the trunk then descends on the œsophagus, I, but previously gives origin to the pulmonary twigs, marked 2, which have been described in page 37. On the œsophagus the nerve divides into a multiplicity of twigs, which unite with those of the opposite nerve, and form the œsophageal plexuses, marked

* Also named nervus sympathicus.

† Styled also pars vaga, and by the ancients the eighth nerve from the base of the brain, although properly the tenth.

with the letters *a*.* Each nerve afterwards concentrates, immediately before emerging from the thoracic cavity, to accompany the œsophagus into the abdomen, and is still marked 1. The nerve of the right side sends its recurrent around the subclavian artery.

I shall now proceed to the contents of the abdominal cavity, and must therefore revert to Plate IX. The letters a indicate the muscular parietes of the abdomen reflected and lined on the left side with the peritoneum, *a;* h, h, the great omentum; b, the stomach; c, the duodenum; i, i, the liver; e, the gall bladder; and f the broad suspensory ligament of the liver, with its round margin, g, named the round ligament, which formed the umbilical vein in the fetus, as seen in Plate X., Fig. 6, and marked also, g. The less omentum is the delicate cribriform membrane between the concave arch of the stomach and the liver, where a number of nervous threads are observed expanded on it: F is placed on the spleen; k on the uterus, with *k* on its broad ligament of the left side, and *l, l,* on its round ligaments, that of the right side being divested of its peritoneal envelope; m indicates the urinary bladder, partially distended, and partly covered with the peritoneum, *a,* which is here observed to terminate, and to be reflected on the abdominal muscles.

The arteries seen in this view of the abdominal cavity are chiefly the branches of the cœliac, which is generally the second from the abdominal aorta, as seen in Plates XII. and XIII., where the aorta is marked e, and the cœliac n. This artery, therefore, takes its origin immediately as the aorta passes through the crura of the diaphragm, and becomes abdominal; and, after little or no course, divides into three branches, the gastric, p, the hepatic, q, and the splenic, r. The relation of the cœliac artery to the stomach, liver, and pancreas, is satisfactorily seen by comparing Plates IX. and XII. In Plate IX. the gastric,† p, is observed to sweep round the lesser and concave arch of the stomach, b, and to inosculate with the pyloric branch of the hepatic artery; and in this course to give origin to ramusculi that ascend along the œsophagus and inosculate with the thoracic œsophageals; to a number of small branches, which extend across to the great arch, and anastomose with the branches of the arteria gastro-epiploica dextra, s, and sinistra, w. The gastric also gives origin to other small branches, that supply the cardiac extremity of the stomach, the less omentum and contiguous parts, and which anastomose with the diaphragmatic artery and vasa brevia of the splenic artery.

The hepatic artery, q, extends dextrad to the transverse fissure of the liver, i, lying in front of the vena portæ, and to the left of the hepatic duct, and divides into the right and left branches to supply the same lobes of the viscus; each branch ultimately subdividing into very minute ones, in order to nourish the organ. The trunk of the hepatic, in this course, gives origin to the pyloric artery, which reaching the pyloric extremity of the stomach, proceeds along its concave arch and anastomoses with the gastric artery; next to the gastro-duodenalis, which passes dorsad of the duodenum, c, near the pylorus, sending off branches to the duodenum and pancreas, the larger of which is termed pancreatico-duodenalis, and on arriving at the stomach, changes its name to the arteria gastro-epiploica dextra, s,* which then runs along the convex arch of the stomach, b, and inosculates with the gastro-epiploica sinistra, w, of the splenic artery. As the dextra emerges from under the duodenum, and extends along the arch of the stomach, it gives origin to a number of branches, which supply the epiploon or omentum majus, h, and also to branches ramified on the stomach. The hepatic artery, on entering the liver, sends off a branch to the gall bladder, e, termed ramus cyticus, that usually proceeds from the right hepatic branch, as seen in Plate XII.

The commencement of the third branch, *r,* of the cœliac artery, is observed in Plate IX., and its course and distribution in Plate XII., where it runs under the pancreas, D, for some distance to the left, and emerges accompanied with its vein, *s,* extending a little further, to be distributed in the substance of the spleen, F. This splenic artery, the largest branch of the cœliac, in its course, dorsad or under the pancreas, supplies to this viscus a multiplicity of small branches, named pancreatics; and beyond the spleen several branches are observed, some distributed on part of the omentum majus, h; one truncated and marked w, which is the arteria gastro-epiploica sinistra,† seen in Plate IX.; and others arising from the concave arch of this last, and ramified on the stomach, named vasa brevia. The veins observed to accompany the gastric and splenic branches of the cœliac artery, assist in forming the vena portæ, N, seen in Plate XII.

The letter T, in Plate IX., indicates the external iliac artery, with its accompanying vein, U, divested of the peritoneum, *a,* and giving origin to the epigastric artery, X, which is also observed accompanied with its vein, *x,* and both of which latter are on the pubic side of the round ligament, *l.*

The nerves seen in this view, Plate IX., of the abdomen, are twigs of the right pneumo-gastric, 1, which are minutely distributed on the stomach and omentum minus, sending twigs along the hepatic artery, q, to contribute to the formation of the hepatic plexus; and also twigs of the cœliac plexus, indicated by the digits 3, and distributed on the omentum majus, h, which different nervous threads are observed to proceed chiefly along the arteries.

In Plate XII. there is a further developement of the arteries and veins of the abdomen, the stomach being removed, and the liver more elevated to display its vessels; the same letters are placed as in Plate IX.; k indicates the lobulus spigelii; *e,* the ductus cysticus; *f,* the ductus hepaticus; and *g,* the ductus communis coledochus; c is the duodenum, the continuation of which is represented by dotted lines; K the beginning of the jejunum, and L the termination of the ilium, and between these two last a long coil of intestine is observed; M is the caput cæcum coli; 29 the appendix vermiformis; O the ascending portion of the colon; P the transverse arch of the colon; Q the peritoneum or mesentery covering the duodenum, C, and supporting the small intestines, and the superior mesenteric artery, R, and vein, U. The superior mesenteric artery, R,‡ generally the third branch of the abdominal aorta, is hid at the point where it arises, by the pancreas, D, and the transverse arch of the colon, P, in the duplicature of the mesentery of which intestine the artery runs

* These are improperly named anterior and posterior, as the left nervus vagus descends a little more on the anterior or sternal aspect of the œsophagus than the right nerve.

† Named also coronaria ventriculi, and gastrica superior.

* Also named gastrica dextra, and gastrica inferior dextra.

† Also named gastrica sinistra, and gastrica inferior sinistra.

‡ Named also arteria mesenterica major.

for a short distance; but its origin is distinctly seen in Plates XIII. and XIV. The artery, on emerging from beneath the colon, as seen in Plate XII., runs superficially, or sternad to the duodenum, enters the mesentery, and forming a concave arch towards the ascending portion of the colon, and a convex arch towards the small intestines, it descends to the right iliac fossa, where it anastomoses with the ileo-colic branch. From the concave arch, the superior mesenteric gives origin to branches that supply the termination of the ileum and the one half of the colon, which are named the ileo-colica, *t*, the colica dextra, *u*, and the colica media, *v*; but these are irregular in number. From its convexity arise a multiplicity of small branches, forming elegant arches, that become smaller as they approach the jejunum and ileum between K and L, which distribution is seen in Plate XIII., where the intestines are removed, and where the letters R indicate the trunk of the superior mesenteric artery; but the vessel is here out of situation. This artery supplies also the pancreas and duodenum, and the branches proceeding to them anastomose with those of the cœliac. The colica media, *v*, inosculates with the colica sinistra, *a*, of the inferior mesenteric artery, b, in Plate XIII., which inosculation is termed the great mesenteric arch.* The letter U indicates the superior mesenteric vein.

Having thus described the veins which contribute to form the vena portæ, N, excepting the inferior mesenteric, I shall now trace this vein and its artery, beginning with the latter. The inferior mesenteric artery,† seen only in Plates XIII. and XIV., marked b, takes its origin near the termination of the aorta, e, enters the duplicature of the mesocolon, supplying the left portion or sigmoid flexure of the colon, *z*, and rectum, I. Its first branch, named colica sinistra, is marked *a*, and anastomoses with the colica media, *v*, seen in Plate XII., in order to form the great mesenteric arch: several other branches are perceived proceeding to the sigmoid flexure of the colon, named rami sigmoides, while the continuation of the trunk, *b*, descends along the rectum, I, to the sphincter ani, and assumes the name of superior or internal hæmorrhoidal, which inosculates with the middle and external hæmorrhoidal arteries, seen in Plate XXVII. The veins observed to accompany this artery ultimately concentrate, so as to form the large one marked H, named, after the artery, the inferior mesenteric vein,‡ which is seen ascending, and running dorsad of the superior mesenteric artery, R, to join the splenic vein, *s*; the united trunk being cut off, to bring the nerves into view. In Plate XII. the splenic vein, *s*, is traced from the spleen, F, by dotted lines, running beneath the pancreas, D, to the vena portæ, N, which is also represented by dotted lines, running beneath the pancreas, where it is joined by the superior mesenteric vein, U, under the colon, P. The superior mesenteric vein, U,§ collecting the blood from the right half of the large, and from all the small intestines, is observed to form the greater portion of the vena portæ,‖ N; and a number of smaller veins are perceived to rise from the colon and duodenum, the latter of which is sometimes termed vena duodenalis, and to terminate in this vein.

* The profuse arterial distribution to the intestines is a point of consideration for the physiologist and practitioner, in regard to the mucous secretion, and to enteritis, hernia, and several other diseases.

† Styled also arteria mesenterica minor.

‡ Named also inferior mesariac, or hæmorrhoidalis interna.

§ Termed also vena mesaraica major.

‖ Named also vena portarum.

Immediately atlantad to the termination of the splenic vein, *s*, may be seen the junction of the gastric vein,* *y*, represented by dotted lines running beneath the pancreas, D. These different veins constitute the vena portæ ventralis;† but a number of others join them, as, for instance, several from the pancreas; indeed, all the veins which return the blood circulated by the cœliac, the superior and the inferior mesenteric arteries, with the exception of the hepatic, contribute to form the vena portæ, and the branches of the veins are named after the branches of the arteries. These veins have no valves. Where the vena portæ advances to the liver, i, and acquires an adventitious covering of the peritoneum, or the capsule of Glisson, it is termed vena portæ hepatica; and immediately divides into two large branches, *n*, *n*, one to each lobe, which ultimately subdivides into innumerable branches. The hepatic veins, d, return not only the blood circulated by the hepatic artery in the liver, but also that portion of the blood not converted into bile, which is furnished by the vena portæ; they are very numerous in their commencement in the liver, and previously to emerging from that organ, generally concentrate into three large and five small trunks, which shortly join the vena cava ascendens, *i*, before it passes through the diaphragm, B. One of these hepatic veins is seen in Plate XII. and another in Plate XIII.

The first branch to which the abdominal aorta gives origin is the diaphragmatic artery,‡ Z, Plates XII., XIII., and XIV., which ascends directly atlantad on the concave surface of the muscle, B, extending its branches onwards to the sternum, inosculating with the internal mammary artery, and towards the ribs also with the intercostals. Sometimes, as in this instance, the artery is single, sometimes double; sometimes it is a direct branch from the aorta, at other times a branch from the cœliac artery, n; indeed, like all small arteries, they are very irregular. The second branch from this portion of the aorta, we have seen to be the cœliac, n, of Plate XIV.; the third branch, the superior mesenteric, R, of Plates XII., XIII., and XIV.; the fourth branch, the supra-renal or capsular artery, which is a small vessel supplying the supra-renal capsule. It is often a branch of the renal artery. The fifth branch, the renal artery,§ C, seen only in Plates XIII. and XIV., takes its origin from the side of the aorta, e, and proceeds almost directly across to the kidney, Y, the concave arch of which it enters, and subdivides into five or six branches round the commencement of the ureter, F, or pelvis of the kidney; giving origin to branches that supply the supra-renal gland, G, and the tunics of the kidney, and ultimately proceeding to the cortical substance of the organ. The renal artery of the right is longer than that of the left side, in consequence of the aorta descending more on the left side of the mesial line of the spinal column. This artery is very irregular with regard to its origin; for, in some instances, four branches proceed from the aorta to one kidney; and in rare cases, one trunk supplies both kidneys. Sometimes the renal artery gives origin to the spermatic artery, *g*, Plates XIII. and XIV.; here, however, the latter comes off as a direct branch from the aorta, and may be generally considered the sixth branch of the abdominal

* Styled also vena coronarii ventriculi.

† Denominated also abdominalis.

‡ Styled also phrenic.

§ Named also emulgent.

aorta. The spermatic artery, *g*, descends, on the right side, superficially to the vena cava ascendens, *i*, and ureter, F, f, rests on the psoas magnus muscle, K, and in the female crosses the external iliac artery, T, dips into the pelvic cavity, and enters the broad ligament, *k*, of the uterus, k, near the ovarium, N, and in this course lies dorsad to the peritoneum to which it adheres. This artery sends its branches outwards along the broad ligament, *k*, to the round ligament, *l*, which it contributes to form, and ultimately passes out of the abdomen by the inguinal canal, and is lost on the pubes and groin. The artery, proceeding in this long serpentine path, sends branches to the ureter and other parts, and anastomoses with branches of the lumbar and other arteries. In the male, the artery takes at first the same course, but forms more inosculations at its origin, in consequence of the testis having been contiguous to the kidney in the fetus; as it descends along the psoas muscle, it proceeds to the internal aperture of the inguinal canal, when it joins the vas deferens of the spermatic cord, and supplies the testis, which will be afterwards explained. The spermatic artery arises sometimes from the renal, sometimes from one of the lumbar, sometimes from the common iliac, sometimes from the internal iliac, and sometimes from the epigastric arteries.* The lumbar arteries, which are given off laterally throughout nearly the whole extent of the abdominal aorta, e, are generally five in number on each side, and are observed in Plate XIV., where only four, marked t, are discernible. They proceed directly across to the lumbar and abdominal muscles, supplying the vertebral column in their course, and anastomosing with branches of the internal mammary, epigastric, and circumflex iliac. Those supplying the vertebral canal are distributed like those of the intercostal arteries. Some anatomists divide the arteries arising from the abdominal aorta into two sets; first into those which arise singly from its anterior aspect, viz. the cœliac, the superior, and inferior mesenteric; and, secondly, those which originate in pairs, as the diaphragmatic, renal, capsular, spermatic, and lumbar: but this arrangement is variable.

Many of the veins which return the blood circulated by the branches of the abdominal aorta, have already been described; the lumbar veins contribute to form the vena azygos; and the gastric, splenic, superior, and inferior mesenteric, with several smaller veins, to form the vena portæ. The renal vein of each side is seen in Plate XIII., marked L; the left being the longer, and both ending in the vena cava ascendens, *i*. The diaphragmatic veins accompany their arteries, and end either in the vena azygos, or in the vena cava ascendens dorsad to the liver; but are too trifling for representation. The spermatic veins are two in number; on the right side they are observed to arrange themselves one on each side of the artery, *g*, and to terminate in the vena cava ascendens, *i*; the veins of this side more commonly join the ascending cava nearer the renal vein; while those of the left side usually end in the renal vein of the same side. An anomalous vein, which returns the blood from the surface of the psoas magnus and psoas parvus, M, muscles, is observed immediately above their termination, and is truncated.

† In Plate XIII., the abdominal aorta is observed to divide about the second last lumbar vertebra into two large branches, named common iliacs, P, P;* and into a third and very small branch which arises at this bifurcation, seen only in Plate XIV., marked *p*, and termed sacro-median. Each common iliac artery, P,† descends to the brim of the pelvis, and near the sacro-iliac synchondrosis divides into the external iliac, T,‡ and internal iliac, V,§ arteries; but they are a little displaced, in order to bring into view their accompanying veins and the trunk of the sympathetic nerve. They are more distinctly seen in Plate XIV. The right common iliac artery is a little longer than the left. The external iliac artery, T,‖ with its accompanying vein, U, on its inner or mesial and sacral side, runs along the brim of the pelvis, attached to the inner or mesial margin of the psoas magnus muscle, K; and as the artery advances to the parietes of the abdomen, rests on the muscle, and proceeds along with it out of the cavity; but immediately before its emergence, generally gives origin to the epigastric artery,¶ X, and the circumflex iliac branch,** *c*. The course of the

* The course of the spermatic plexus should be kept in view when throwing a ligature round either the external or internal iliac artery in the living body.

† Should the abdominal aorta become the seat of operation, an incision must be made parallel to the linea alba on the left of the umbilicus, sufficiently extensive to enable the surgeon to keep aside the small intestines, which are to be transferred to the right side, while he dissects or scratches cautiously the peritoneum interposed between him and the artery. The aneurism needle should be inserted between the vena cava ascendens and the aorta, and be turned round from right to left. Plates IX., XII., XIII., illustrate the anatomy of this operation. The superior and inferior mesenteric arteries and their veins must be kept in view.

* Termed also the lumbar portions of the crural arteries.

† To secure the common iliac artery, P, the operator must calculate its course from the second last lumbar vertebra to its emergence from the abdomen, in the centre between the anterior superior spinous process of the os ilium and the spine of the os pubis. An incision proportionate to the depth is then to be made in the course of the fibres of the external oblique muscle, making the centre of it opposite to the spinous process of the os ilium. The external incisions must extend through the integuments and the three lateral abdominal muscles, to the peritoneum, which is then to be carefully separated with the fingers from the iliacus internus and psoas muscles, the operator keeping in view the spermatic plexus and ureter, till he feels the pulsation of the artery. The artery can be distinguished from the external and internal iliacs only by feeling the pulsations of the three. The aneurism needle should be passed round the artery from the pelvic to the iliac or outer side, in order to avoid the vein. The artery should be tied as near as possible to its division into the two iliacs, that a clot of blood may be formed. The reasons why the incision should be made so far iliad, are, in order to avoid the spermatic cord and the epigastric artery, and because the peritoneum is more easily separated from the fascia transversalis: great care is requisite in dividing the fascia transversalis.

‡ Named also the iliac portion of the crural artery, iliaca antica or externa, and arteria cruralis in pelvi.

§ Styled also the hypogastric, or hypo-iliac, or iliaca interna, or iliaca posterior.

‖ When the external iliac artery becomes the seat of operation, the surgeon has to calculate its course like that of the common iliac. It invariably emerges out of the abdomen, at five and a half parts from the spine of the os pubis, and four and a half parts from the spine of the os ilium. Keeping in view this course, the incisions should be the same as in the operation for the common iliac, in order to avoid the spermatic cord, and to be able to separate the peritoneum from the iliacus internus and psoas muscles. The latter muscle is generally a guide to the artery, and should be relaxed when throwing the ligature round the vessel. In several subjects, particularly female, this artery dips very deep by the side of this muscle into the pelvis. The artery should be secured as far from the internal iliac as to ensure the formation of a clot of blood, and as far from the disease as to ensure the vessel sound. The needle should be passed round the artery from the pelvic to the iliac or outer side, in order to avoid the vein. The spermatic plexus, the internal inguino-cutaneous nerve, and ureter, ought to be kept in view.

¶ Named also internal epigastric.

** Termed also internal circumflex iliac.

epigastric artery, x, Plates XIII. and IX., is beneath and internal, or sacrad and pubic to the round ligament of the female, or the spermatic cord of the male, and afterwards upwards or atlantad between the peritoneum, *a*, and the fascia transversalis; and a little above, enters the sheath of the rectus muscle, in the fibres of which it ascends about one-third from the linea alba, and two-thirds from the linea semilunaris, and ultimately anastomoses in the epigastric region with the internal mammary artery, 14, as represented in Plate XXX.; and inosculating in this progress also with the inferior intercostals, the circumflex iliac, *c*, the ilio-lumbar, y, of Plate XIII., and the lumbars, t, of Plate XIV., and the superficial epigastric.* In this course the epigastric sends off a number of branches; but the most important is that which descends along the spermatic cord out of the inguinal canal, and inosculates with the spermatic artery. This branch is seen in Plate XXIII., marked *x*. The circumflex iliac artery,† *c*, Plate XIII., with its accompanying vein, proceeds within the abdominal cavity, between the junction of the abdominal muscles to the psoas, K, and iliacus internus, W, muscles, and near the anterior superior spinous process of the os ilium runs between the transversalis abdominis and the obliquus internus abdominis, where these muscles are attached to the crista of the os ilium, as seen in Plate XXXI.; its branches advancing to anastomose with the last intercostals, the lumbars, and the ilio-lumbar of the internal iliac; and some inosculating also with branches of the epigastric and of the internal mammary arteries. In its course the circumflex iliac sends branches to the inguinal glands, and sometimes to the pubes and spermatic cord, and the muscles in its neighbourhood, inosculating with the superficial circumflex iliac and superficial epigastric arteries. This artery is occasionally a conjoint branch with the epigastric artery.‡

The external iliac vein, U, is the trunk of the veins of the inferior extremity, and is observed to receive the circumflex iliac and epigastric veins on entering the abdomen; and as it proceeds on the inner side of its artery, T, to be joined by the internal iliac vein, X, which, however, is seen only in Plate XIV. These constitute the common iliac vein, O, which forms, with the vein of the other side, the vena cava ascendens, *i*, that ascends on the right of the aorta, e, receiving in its course the spermatic, renal, hepatic, and diaphragmatic veins; and immediately after passing through the right aperture of the diaphragm, enters the pericardium, and unites with the superior cava to form the right auricle of the heart. In Plate XII. the inferior cava, *i*, is seen to pass along the dorsal margin of the liver, where it receives the hepatic veins, d, and forms a sulcus in this viscus.

Having thus finished the description of the arteries and veins of the abdominal cavity, I shall now proceed to the examination of the nerves; the pneumo-gastric were traced to their destination and therefore the great sympathetic nerves remain only to be examined. In Plate XII.

* The course of the epigastric artery should be carefully attended to in operating for strangulated inguinal or femoral hernia, for the cæsarian section, for the extirpation of tumours in the abdominal cavity, and for paracentesis abdominis.

† Named also internal circumflex; abdominalis Halleri; by Boyer, iliaca antica; by Shaarshmid, the iliaca externa minor.

‡ The branches which anastomose with the epigastric are sometimes so large as to prevent the performance of paracentesis abdominis between the umbilicus and anterior superior spinous process of the os ilium, as represented in Plate XXXI.

the sympathetic or great intercostal nerve,* marked 7, consists, in the thoracic cavity, of twelve ganglia situated along the heads of the ribs, connected by short nervous threads passing from the one to the other, and to the contiguous intercostal nerves, marked 9. It gives origin to a number of twigs, marked with the digits 11 to supply the heart, the digits 14 to supply the lungs, and with the digits 17, which form the splanchnic nerve, better seen in Plate XIII.; and this nerve, on piercing the muscular fibres of the diaphragm, B, becomes enlarged, which is styled the semilunar ganglion, *a*; and from the ganglion of each side, are sent off a multiplicity of nervous threads, that unite across the aorta, e, so as to form the great solar or primary plexus. Where this plexus encircles the cœliac artery, which is immediately contiguous, it is termed the cœliac plexus, one of the secondary; and this nervous mesh receives an addition from the right nervus vagus, 1. On the right side, the twigs running along and twining around the hepatic artery, q, are named the hepatic plexus, another of the secondary set; and on the left side, the twigs encircling the splenic artery, r, are termed the splenic plexus: in Plate XII. these nervous threads are seen to accompany the splenic artery to the spleen, F, sending twigs over and around the pancreas, D; and to accompany the hepatic artery onwards to the liver, i. Some twigs are observed to accompany the gastric artery, p, to form the gastric or coronary plexus; others, which supply the omentum majus and arteria gastro-epiploica dextra, are observed in Plate IX., and described in page 41. In Plate XIII., ganglia, marked with the digits 8, are observed situated sacrad to the roots of the hepatic and splenic arteries, q, r, and are generally considered as portions of the solar plexus: from these, nervous threads proceed to the root of the superior mesenteric artery, R, where they appear to accumulate, are named the superior mesenteric plexus, and are circumflected along the artery and its branches, onwards to the intestines.† Other nervous threads are seen encircling the renal artery, C, and forming small ganglia, which constitute the renal plexus of nerves, and accompany the artery, C, and vein, L, to the kidney, Y; some twigs proceed to the gland, G, some encircle the vena cava, *i*, and others the ureter, F. From the superior mesenteric and renal plexuses, and from the nervous threads uniting them on the surface of the aorta, arise a number of twigs which, after surrounding the left renal vein, L, descend on the aorta, e, to its division into the two common iliac arteries, P, P; and in this progress twigs are observed to accompany the spermatic arteries, *g*, *g*, named the spermatic plexuses, which twigs are joined by others proceeding from the trunk of the great intercostal, 7. That plexus on the right side is seen to accompany the artery, *g*, to the ovarium, N, where it is lost on the broad ligament of the uterus. These nervous threads of the splanchnic are also observed to form a plexus on the inferior mesenteric artery, b, which they accompany to its distribution on the colon, *z*, and rectum, I; this plexus, like the others, is named after the artery on which it is distributed: other threads are observed to descend on the inferior mesenteric vein, H, to assist in forming this inferior mesenteric plexus. Twigs are also seen to proceed from the left intercostal trunk, 7,

* Named also nervus sympathicus, nerf de la vie organique.

† This multiplied distribution of the nerves on the intestines should be well considered by the practitioner in cases of enteritis and other intestinal affections.

to run beneath the vein, H, and to join the spermatic, and the inferior mesenteric plexuses. The leash of nerves on the aorta, e, is formed in a considerable measure by the trunks of the great intercostal nerves; those deriving their origin from the right, 7, are distinctly seen. On the left common iliac artery, P, there is a conspicuous ganglion, 9, formed chiefly by the trunk of the left great intercostal nerve; and the twigs which emanate, unite with the nerves descending on the aorta, and constitute what is termed the hypogastric or the most inferior of the mesenteric plexuses; and from this mesh, nervous threads are observed to descend into the pelvis, supplying the termination of the colon, *z*, and the rectum, I, the ureter, f, the uterus, k, the bladder, m, and the common iliac artery, P, with its divisions, T and V; all which are more distinctly seen in Plate XIV. In many, a lesser splanchnic nerve is found, which is formed by filaments from the tenth and eleventh ganglia; this pierces the crus of the diaphragm, and sends twigs to the solar and renal plexuses.

The trunk of the sympathetic nerve, 7, after giving origin to the splanchnic twigs, 17, descends on the sides of the bodies of the lowest dorsal vertebræ, and pierces the muscular structure of the diaphragm, B, as seen in Plates XII. and XIII.; and in the latter, is observed on the right side descending dorsad to the hepatic artery, q, and appearing between it and the renal artery, C, where the nerve generally gives origin to twigs that contribute to form the renal plexus. The trunk, 7, then descends dorsad to the renal artery, C, and vein, L, and appears on the side of the aorta, between it and the vena cava ascendens, *i*, beneath which the nerve proceeds, and is again seen descending on the sacrum into the pelvis. In this course the nerve forms junctions with the individual lumbar nerves, marked 6, similar to what it does with the individual intercostal nerves in the thorax; and these junctions have an oblong gangliform appearance, distinctly seen in Plate XIV.: this nerve also gives origin to a multiplicity of nervous threads, which run over the aorta, where they partly unite with the twigs of the opposite nerve, partly with those of the splanchnic, and partly with the spermatic plexus, all of which are seen in Plate XIII.

Before tracing either the trunk of the sympathetic nerve, or the splanchnic twigs, into the pelvis, it will be necessary to take notice of the viscera and blood-vessels of this cavity. Plate XIV. is a representation of these objects by a section of the pelvis: A is the symphysis pubis; B the sacrum, where it united with the os ilium in forming the sacro-iliac-synchondrosis, the os innominatum of the left side having been therefore removed; and b, the body of the sacrum, kept lighter in the drawing than it should be, to show the nerves and arteries. The letters I indicate the rectum descending on the sacrum; k, the fundus of the uterus, the broad and round ligaments having been removed, to exhibit the nerves and blood-vessels; D, the vagina; and m, the urinary bladder, the dotted lines leading from this viscus to the external iliac artery, T, on the left side, indicating the course of the ureter. The letters F are placed on the bodies of the lumbar vertebræ; K, on part of the psoas magnus muscle, the greater portion being removed to bring into view the lumbar nerves; and W, on part of the iliacus internus muscle, a considerable portion being removed, to show the sacrum, B.

The aorta and its branches have been described as far as the internal iliac artery, V, and sacro-median, *p*. The latter, or sacro-median, *p*, derives its origin from the aorta in the angle formed by its division into the two common iliacs, P, P; descends sacrad on the body of the sacrum, b, to the common iliac vein, O, and terminates generally near the extremity of the os coccygis; giving off small lateral branches, that anastomose with the sacro-laterals, *a*, *a*, of the internal iliac, and supplying the sacrum, coccyx, and rectum. Neither the sacro-median vein, nor the veins accompanying the branches of the internal iliac artery, have been drawn, in order to render the arteries as distinct as possible; and these arteries have generally each one vena comes, but sometimes two, like other small arteries: in general, all smaller arteries have this peculiarity with regard to the accompanying veins, while the larger arteries have only one vein. These veins of the pelvis have generally valves, as represented in Fig. 3, Plate XI.

The internal iliac artery, V,* descending into the pelvis along the sacro-iliac-synchondrosis to the great sacro-ischiadic notch, divides into a number of branches, the ilio-lumbar, y,† seen in Plate XIII.; the sacro-laterals, *a*, *a*; the gluteal, *c*;‡ the obturator, *d*; the uterine, *e*; the ischiadic, *f*; the hemorrhoidal, *g*; and the internal pudic, *h*,§ seen in this Plate XIV.

The ilio-lumbar, y, Plate XIII., is a small branch which runs beneath the psoæ muscles, M, K, supplying them in its course, and anastomosing with the lumbar arteries, t, Plate XIV., and with the circumflex iliac, *c*, Plate XIII., where it supplies the iliacus internus muscle, W, and transversus abdominis. The ilio-lumbar is sometimes a branch of the common iliac. The sacro-lateral branches, *a*, *a*, which are very small, run along the body of the sacrum, b, unite with the sacro-median, *p*, and supply the bone, its canal, the cauda equina, and nerves. The gluteal, *c*, which is the largest branch, proceeds immediately through the greater sacro-ischiadic notch out of the pelvis, as will be described afterwards. The ischiadic, or sciatic, *f*, is the second largest branch, and sometimes with the gluteal gives origin to all the others, and is observed in this plate to branch off along with the internal pudic and middle hemorrhoidal on the left side, while on the right side only with the pudic; such is the irregularity in the origin of all small arteries. This artery, *f*, descends a little further into the pelvis than the gluteal, but also emerges at the same notch out of the pelvis, being only separated by the pyriformis muscle and great sacro-ischiadic nerve, 20, which will be described afterwards. In this subject the artery passed between the portions of the nerve. The obturator artery, *d*, is seen in its natural course only on the right side, for on the left, it is truncated and thrown out of situation by the removal of the os innominatum: on the right, the artery is observed to run on the parietes of the pelvic cavity, along with the obturator nerve, 21, and to make its exit at the obturator foramen. This artery is often given off by the internal epigastric, a deviation to be recollected in strangulated crural hernia.

---

* When a ligature is required to be thrown round the internal iliac artery, the same directions as those given for securing the common iliac are applicable. The psoas magnus muscle becomes an excellent guide to the artery in this, as in the operation for securing the external artery. The internal iliac vein lies sacrad to the artery, as seen in Plate XIV., therefore the needle should be passed round the artery from the pelvic to the abdominal aspect, or from the pelvis to the psoas muscle.

† Named also iliaca parva.

‡ Styled also iliaca postica.

§ Termed also pudica pelviena, pudenda, pudenda communis, pudenda circumflexa, pudenda interna, pudenda media, and pudenda externa.

The uterine artery, *e*, descends between the uterus, k, and rectum, I, and terminates in the neck and body of the uterus; in this progress generally giving origin to branches that supply the urinary bladder, named vesical, and which are sometimes considered regular branches of the internal iliac. The uterine arteries anastomose with each other, and with the spermatics, and both of these pairs enlarge to a great size in pregnancy and diseases of the viscus; and their accompanying veins still more so: the right spermatic vein at parturition may be compared to the vena cava ascendens. The hemorrhoidal artery, *g*, named generally the middle hemorrhoidal, descends by the side of the rectum, I, onward to the sphincter ani, giving origin to branches that supply the gut and urinary bladder; the continuation of the inferior mesenteric being the internal hemorrhoidal, which is here seen truncated where the rectum commences. The internal pudic artery, *h*, of the female differs in its distribution from that of the male, which will be described afterwards. In both sexes, the artery descends out of the pelvis, along with the gluteal and ischiadic arteries, at the greater sacro-ischiadic notch, but at its most distal or ischiadic margin, twines round the short sacro-ischiadic ligament, re-enters the pelvis between the two ligaments, then ascends along the tuberosity of the os ischium, ramus of the ischium, and pubes. In this course, in the female, the pudic gives origin to a number of branches that supply the rectum and vagina with its appendages, and also the muscles and ligaments; and generally anastomoses with the internal circumflex, obturator, and external pudic arteries. A conspicuous branch, *r*, proceeds to the rectum, and is termed the external hemorrhoidal.

The condensed membrane, in the form of a cord, marked *n*, was the umbilical artery in the fetus, and in the adult generally remains previous for a short extent, and gives origin to a vesical branch: this cord is observed to ascend to the fundus of the bladder, along which it runs to the linea alba, and, lastly, to the umbilicus. In the fetus the umbilical artery, *n*, of Fig. 6, Plate X., is the largest branch of the abdominal aorta, e, and naturally pursues the same course as in the adult: the two arteries, *n*, *n*, are observed to twine round the umbilical vein, g, and conjointly to constitute the umbilical cord which at its other extremity is attached to the placenta of the mother. As these arteries proceed towards the pelvis, they are seen to give origin to very small branches, which become those large arteries already described in the adult.

The nerves of the pelvis are seen in Plate XIV. The mesh of nerves on the termination of the aorta, e, described in page 44, are observed to unite with the nerves from the ganglion, 9, on the left common iliac artery, and to descend into the pelvis, forming junctions with the twigs of the trunk of the sympathetic nerve, with the inferior mesenteric nerve (the latter of which is represented truncated with the artery of the same name and the rectum, I), and forming junctions with the great sacro-sciatic nerve, 20, and supplying the viscera and blood-vessels of the cavity.

The trunk of the sympathetic nerve, 7, has been described in page 44, as far as its entrance into the pelvis. In Plate XIV., this nerve is only seen on the right side in this cavity, descending on the side of the body of the sacrum, b, and giving origin to a number of twigs that unite with the sacral nerves, the splanchnic, and twigs of the opposite nerve: the two trunks ultimately form a small ganglion on the os coccygis, named ganglion impar. The nerve marked 20 is the great sacro-sciatic, formed by the two inferior lumbar and the three superior sacral nerves. The nerve which is seen accompanying the internal pudic artery, *h*, throughout its course, is the internal pudic, and generally derives its origin both in the female and male from the second and third sacral nerves, forming junctions with the great sacro-sciatic, the trunk of the sympathetic, and the splanchnic nerves.

The anterior branches of the lumbar nerves, marked with the digits 6, are five in number; the inferior or sacral not being brought into view; these communicate with each other, and the lumbar ganglia of the sympathetic, to constitute the lumbar plexus, and also unite with the last dorsal and first sacral nerves by small branches, named lumbo-dorsal and lumbo-sacral. The nerve marked 3 is the last dorsal. The two superior lumbar are generally distributed on the abdominal and dorsal muscles, while the three inferior supply chiefly the lower extremity. In the preceding Plate XIII., several twigs are seen emerging below the psoas magnus muscle, K, running on the iliacus internus muscle, W, and quadratus lumborum muscle, C, and supplying these muscles in their course onwards to the lateral muscles of the abdomen and the peritoneum; one of them, named inguino-cutaneous, runs beneath Paupart's ligament, down the thigh, which will be described afterwards; another, a twig of which, named ilio-inguinal, passes out of the abdomen at the inguinal canal, and accompanies the round ligament in the female to the pubes, and even descends to the labia; a third, termed genito-crural or external spermatic nerve, takes a similar course with the last. In Plate XIV. the lumbar nerves are seen to send twigs to the sympathetic, as already explained, and also along the external iliac artery, T.

The nerve marked 21 is the obturator, and derives its origin generally from the third and fourth lumbars, descends on the inner or mesial side of the psoas magnus muscle, which it supplies, into the pelvis, and proceeds in company with the obturator artery, *d*, as seen on the right side, to the obturator foramen: its distribution is explained afterwards. The muscle has been removed, excepting that portion marked K, in order to bring into view the nerves which run in its muscular structure.

The digits, 22, mark the anterior crural nerve,* which is commonly formed by twigs of the four superior lumbar nerves, and descends in the body of the psoas muscle,† emerging at its outer or iliac side, and approaching nearer the external iliac artery, T, with which it proceeds out of the abdomen, resting on the iliacus internus muscle; and in its course giving origin to twigs that supply these muscles and the artery: the further distribution of this nerve is detailed afterwards. The posterior branches of the sacral, lumbar, dorsal, and cervical nerves, are much smaller, and of less importance than the anterior; they supply chiefly the muscles and skin.

* Named also simply the crural nerve, and likewise the anterior femoral nerve.

† The multiplicity of nerves which pierce the fibres of the psoas muscle, and their destination, should be considered in psoas or lumbar abscess.

BLOOD-VESSELS AND NERVES OF THE HEAD AND NECK.

I SHALL now proceed to the blood-vessels and nerves of the head and neck, although it would have been more natural and consecutive to have traced those of the pelvis to their distribution in the lower extremity; but this I have been prevented doing, from the impossibility of procuring a subject, for upwards of five months, from which to make the drawings of the leg.

Plate XV. The arteria innominata,* Q, seen in Plate XII., is seen the first branch which derives its origin from the arch of the aorta, E, after emerging beyond the pericardium; and in Plate IX. is observed to ascend by the side of the trachea, K, where the artery is observed by the left subclavian vein, *v*, extending across it, and at the upper extremity of the sternum divides into the right subclavian artery, H, and the right carotid artery, P. In Plate XV. the artery is seen ascending by the side of the trachea, K, but obscured by the inferior thyroideal veins, letters O; in Plate XVI. it is hid by the sterno-thyroideus muscle, B; in Plate XVII. by the sterno-hyoideus muscle, C, and the sterno-cleido-mastoideus muscle, E, with one of the external jugular veins, D; and in Plate XVIII. by the platisma myoides muscle, F.† In Plate XV., the common carotid, P,‡ is observed to ascend on the bodies of the cervical vertebræ, by the side of the œsophagus and pharynx, and the trachea, K, the thyroid gland, *Z*, the cricoid, N, and thyroid, S, cartilages; and opposite to the space between the latter cartilage and os hyoides, X, to divide into the external, G, and internal, 19, carotid arteries. In this course the common carotid has the nervus vagus, 1, on its outer or lateral and dorsal aspect, the internal jugular vein, M, Plate XVI., still more on the outer, or on the lateral and sternal aspect, but somewhat superficially, and the descendens noni nerve, 5, quite superficially, or on the sternal aspect. The sterno-thyroideus muscle, B, crosses obliquely over its lower portion, and also the sterno-hyoideus muscle, C, and omo-hyoideus muscle, U, of Plate XVII.; while the sterno-cleido-mastoideus muscle, E, runs superficially parallel to the artery, and in some measure hides the vessel. The external jugular branch, D, lies superficially throughout.* The internal carotid artery,† 19, ascends close on the vertebræ, deeper and somewhat occipital, or inial to the external carotid, and at the basis of the cranium enters the canalis carotideus (*t*, Fig. 2, Plate IV.), to contribute to supply the brain. This artery will be described in the part which treats of that organ. The external carotid artery,‡ G, immediately on separating from the internal, gives origin to several branches, which are far from being regular; in general, they are eight in number, the superior or descending thyroideal, *a*; the lingual, *b*; the facial, *c*; the occipital, *d*; the posterior auris, *e*; the internal maxillary, *f*; the temporal, *g*; and the ascending pharyngeal, *h*; all of which are seen partly in this plate, and partly in Plates XVI., XVII., and XVIII. The temporal, *g*, is commonly considered the trunk or continuation of the external carotid, so that the direction of the artery is upwards or atlantad to the angle of the inferior maxillary bone, as seen in Plate XVII., where all the parts are undisturbed, having the lingual nerve, 3, with its branch the descendens noni, 5, several lymphatic glands,

* Termed also anonyma.

† In operating, therefore, to throw a ligature round the arteria innominata, the object of greatest moment to be avoided is the left subclavian vein, *v*, seen in Plate IX. There is no nerve of consequence on the artery, but merely a small twig, 4, of the nervus vagus, 1, in Plate XV., descending to the heart; and this is not always present. The patient should be placed on a low table, with the face turned to the right, to relax the sterno-cleido-mastoideus muscle, E, and to render the artery as shallow as possible. An incision of some length, regulated by the muscularity and fatness as well as the age of the individual, is to be made through the skin and cellular tissue, along the tracheal edge of the right sterno-cleido-mastoideus muscle, avoiding as much as possible the branch of the external jugular vein, D. The second incision may be more limited, and should divide the fibres of the sterno-hyoideus, C, and sterno-thyroideus, B, muscles. The operator will feel first the pulsation of the common carotid artery, P; then, by retracing it to its origin, he will feel the pulsation of the right subclavian; and, lastly, that of the arteria innominata, round which a ligature may be easily thrown by means of an aneurism needle. The knot formed by the ligature should be the reef-knot of the sailor. After this operation, as well as all others for securing large arteries, the patient should be confined for several days in bed, in the horizontal position; for the least excitement of the heart and arteries disturbs the adhesive inflammation, and produces secondary hemorrhage. In this operation, some of the inferior thyroideal veins, O, as well as the external jugular branch, D, may be wounded; and when this occurs, they should be tied at both orifices; although it is an axiom in surgery not to tie the veins, yet these are so contiguous to the heart as to endanger life if not secured. The left subclavian or anonyma vein, *v*, may be considerably diminished in its calibre, by compressing the left arm and the left internal jugular vein. This operation fails, from the subclavian artery beyond the ligature continuing distended with blood, by the free inosculation of the vertebrals and internal carotids.

‡ Named also arteria cephalica.

* To secure the common carotid artery, P, the patient should be placed on a low table, with the face turned to the side opposite to that on which the operation is to be performed, in order to remove the sterno-cleido-mastoideus muscle as much out of the way as possible, and thus to enlarge the space for operating. A line should be drawn across from between the thyroid and cricoid cartilages to the margin of the muscle, as there the artery is most exposed and most easily reached. An incision of some extent, depending on the same grounds as mentioned under the directions given for the arteria innominata, should be made through the skin and cellular tissue, along the tracheal margin of the sterno-cleido-mastoideus, E, and a deeper incision through the superficial fascia and the platysma myoides, F, Plate XVIII., carefully avoiding the branch of the external jugular vein, D. The fibres of the sterno-cleido-mastoideus will then be felt, when the deep cervical fascia at its tracheal margin is to be carefully incised, the artery separated from the internal jugular vein, M, the nervus vagus, 1, and descendens noni, 5, and the ligature passed round the artery with the aneurism needle. As they are not connected with very condensed cellular substance, this may be easily accomplished. The laryngeal veins, T, seen in Plates XVI. and XVII., are very liable to be wounded in denuding the artery. The needle should be passed round the artery to the trachea, carefully excluding the vein and nerve; the scalpel lateralized with the cutting edge to the trachea; and the vein compressed above the wound. Lymphatic glands sometimes occur in the way of the knife, and embarrass the operator. The point of the artery selected must depend on circumstances, for the vessel may be required to be secured lower down; in which case, the directions given for the above and the arteria innominata require both to be considered.

† Named also arteria encephalica.

‡ Also termed arteria pericephalica.

v,* and the posterior head of the digastric and stylo-hyoideus, w, muscles,† superficially to it; also the platysma myoides muscle, F, with the common integuments, and sometimes branches of the external jugular vein, as seen in Plate XVIII.; the external carotid artery continuing its course behind the angle and ramus of the inferior maxillary bone, runs superficially to the zygomatic process of the temporal bone, 20, assumes the name of temporal, and branches over the cranium.

The first branch of the external carotid is the superior thyroideal artery,‡ *a*, which descends obliquely downwards under the omo-hyoideus and sterno-thyroideus muscles to the larynx, and is distributed chiefly on the thyroid gland, *Z*. In this course the thyroid gives off one or more branches; a laryngeal, which runs between the os hyoides, x, and thyroid cartilage, s; another to the thyroid cartilage; and a third proceeding backwards across the common carotid, P, to the sterno-cleido-mastoideus muscle, E. The muscles beneath which this thyroid artery runs, and supplies, are readily understood on comparing the plates; as, for example, branches to the inferior constrictor of the pharynx, Y, the thyro-hyoideus, Z, the crico-thyroideus, a, and other muscles of the larynx and vicinity. The thyroid anastomoses with its fellow of the opposite side, and with the inferior thyroid artery, s, of the subclavian; and is accompanied by veins, that ultimately form the vein, T, generally termed laryngeal, and which joins the internal jugular vein, M. The superior thyroid is sometimes as large as the external carotid, so as to form a third branch of the common carotid artery.

The second branch, *b*, is the lingual artery, that runs beneath the hyo-glossus muscle, *i*, a few fibres of which are cut open to show the artery as represented in Plate XV., immediately above, or atlantad to the os hyoides, x; beneath this muscle the artery proceeds onwards, and enters the fibres of the genio-hyo-glossus, *k*, running along the base of the tongue to its tip; and in this course supplying the muscles through which it passes, and those contiguous, as the genio-hyoideus, *l*, the mylo-hyoideus, *m*, the middle constrictor of the pharynx, the stylo-hyoideus, and others; and also the os hyoides, x.§ Its sublingual branch, improperly so named, is the one which proceeds to the symphysis menti, as seen in Plate XV.; and the termination of the artery, which runs by the side of the frænum linguæ, is sometimes termed arteria ranina.‖

The next branch is the facial, *c*,¶ which ascends by the side of the pharynx, *p*, beneath the posterior head of the digastric and stylo-hyoideus muscles, w, to the submaxillary gland, *n*, between the lobes of which the artery runs to the base of the inferior maxillary bone, over which it ascends on the face, beneath the platysma myoides, F, and the depressor anguli oris muscle, b, to the angle of the mouth, then under the zygomaticus major, a, and zygomaticus minor, e, muscles, resting on the buccinator muscle, h, along the upper lip, and ala of the nose, to the inner canthus of the eye, where it anastomoses with the nasal branch of the ophthalmic artery of the internal carotid.*

In this course the artery gives origin to several branches; a palatine that supplies the tongue, the velum palati, the tonsils, the Eustachian tube, and several muscles, as the stylo-hyoideus, stylo-pharyngæus, k, stylo-glossus, m, and pterygoideus internus, n; numerous branches to the submaxillary gland, *n;* and a branch to the hyo-glossus muscle, *i:* also other branches to the tongue and its muscles, to the lining membrane of the mouth, and to the upper part of the pharynx. The second conspicuous branch is the submental or submaxillary, seen to run on the mylo-hyoideus muscle, *m*, beneath the anterior head, *w*, of the digastric muscle, onwards to the symphysis of the chin; which branch sometimes takes its origin directly from the external carotid, G. In Plate XVII. there is a large lymphatic gland over this branch, between the submaxillary gland and anterior head of the digastric muscle. After its appearance on the inferior maxillary bone, the artery sends off branches to the depressor anguli oris muscle, b, to the masseter muscle, l, and the buccinator muscle, h; and near the angle of the mouth, gives origin to the coronary branch of the lower lip, which is hid at its commencement by the depressor anguli oris. The coronary of the upper lip is observed to take its origin a little above the angle of the mouth,† and to meander in the fibres of the orbicularis oris muscle, f, which both it and the trunk supply. Branches also are sent to the zygomatici, the levator labii superioris alæque nasi, i, the levator anguli oris, o, the compressor naris, n, muscles, and the inside of the nostrils.

The occipital, *d*, was the fourth branch enumerated. This artery takes its origin from the posterior or dorso-lateral aspect of the carotid, G, and ascends obliquely over the internal jugular vein, M, and beneath the sterno-cleido-mastoideus, E, and accessory nerve, 12, of the nervus vagus, to the temporal bone, in a groove of which it runs (as seen in Plate V., Fig. 7, letter *n*) to the occipital bone, which the artery also imprints (as seen in the same plate, Fig. 5, letter *e*); and after running beneath the sterno-cleido-mastoideus, the trachelo-mastoideus, the digastric, and splenius capitis, p, muscles, parallel to their insertions, the artery ascends the occipital bone, between the first of these muscles and the insertion of the trapezius muscle, onwards to the coronal suture, where it

---

* These lymphatic glands are very subject to disease, particularly in the scrofulous. When they become indurated and so enlarged as to prove troublesome or dangerous, they may require extirpation. Here the operator has to consider their close proximity to so many important vessels. The surgeon, before operating, should carefully consider also the effect of the platysma myoides, and the cervical fasciæ, in binding down these tumours of the neck, otherwise he will find himself deceived when he comes to operate; for what often appears a superficial tumour before operation, is found to have extensive ramifications among these important objects.

† These two muscles are so intimately connected, that the letter w refers to both.

‡ Named also descendens, and atlanto-thyroidea.

§ This branch is named by Haller the ramus hyoideus.

‖ The artery at this point requires to be guarded against in dividing the frænum linguæ in children. Where the artery runs atlantad to the os hyoides, it requires sometimes to be secured in extirpating the tongu when cancerous; and in throwing a ligature round the artery, the operator must keep in view the lingual nerve, 3, which is sometimes very close to the artery.

¶ Named also labial, angular, and external maxillary.

* When this artery requires to be secured, it may be easily found by dividing the space between the angle of the inferior maxillary bone and its symphisis into three proportional parts. The artery runs over the bone one third from the angle, and two from the symphysis.—(*MS. Lectures of Mr. Walker, formerly Lecturer on Anatomy and Physiology, Edinburgh.*) The facial vein, z, lies superficially to the artery. The facial artery throughout its course should be considered in relation to operations and wounds of the face.

† The coronary arteries should be considered with relation to the operation for hare-lip, or cancer of the lip.

inosculates with the branches of the temporal, *g*. In this course the occipital artery is observed to give off numerous branches: one along the internal jugular vein, M, which it accompanies into the cranium, and anastomoses with the meningeal arteries; some to the lymphatic glands, V, and the muscles in the neighbourhood; one that inosculates with the vertebral artery;* one named arteria princeps cervicis, which descends beneath the complexus to inosculate with the deep cervical; some to the ear, and which anastomose with the posterior auris, *e*; and others, and these the principal, to the occipito-frontalis muscle, q, the periosteum, the other integuments of the cranium, and also to the bones themselves. Some of these latter pierce the lambdoidal suture, and supply the dura mater. This artery, in some cases, takes its origin from the internal carotid. I have a cast where it is the continuation of the deep cervical, *r*, of the inferior thyroideal, s, of the subclavian artery. I showed the subject to that able anatomist, Dr. Barclay.

The posterior auris, or auricular branch, *e*,† ascends, like the occipital, obliquely backwards, through the substance of the parotid gland, to the back part of the cartilage of the ear, on which it is chiefly distributed; sending off branches to inosculate with the occipital and temporal; and supplying also the various muscles of the external ear, as the attollens aurem, r, and the parotid gland, s. This artery sends a particular branch into the foramen stylo-mastoideum (seen in Plate V., Fig. 7, letter *f*), named the stylo-mastoid, which gives origin to branches that supply the mastoid cells, and other portions of the middle ear, anastomosing with the internal auditory branch of the vertebral. The auricular is frequently a branch of the occipital.

The internal maxillary branch, *f*,‡ takes its origin, like the facial, from the anterior aspect of the external carotid artery, G, proceeds behind the ramus of the inferior maxillary bone, 25, and near the neck of the condyloid process,§ ascends between the pterygoideus internus muscle, n, and pterygoideus externus muscle, t, to the bulbous process of the superior maxillary bone, and at the speno-maxillary fissure (seen in Plate IV., letter R), enters the infra-orbitary canal, along which the artery runs, and emerges on the face at the infra-orbitary foramen, *o*, along with the infra-orbitary nerve, 2, where it anastomoses with the facial, the temporal, and ophthalmic arteries, supplying the muscles of the upper lip, the gums, alveolar processes, and teeth. In this course the internal maxillary gives origin to numerous small branches; some to the articulation of the inferior maxillary bone, which also enter the tympanum by the fissure of Glasserus; some to the temporal muscle, u; and one named inferior maxillary,‖ v, that enters the osseous canal of the inferior maxillary bone along with the nervus mandibulo-labialis, 4, as seen in Plate XV., where the bone is represented by dotted lines. Before entering the canal, this branch sends off a small branch to accompany the twig of the nerve, both of which assist to make the groove in the bone (as seen in Plate VII., Fig. 25, letter *s*). In the canal of the bone the artery supplies the respective teeth, and lastly emerges at the foramen mentale, *f*, with the nerve, supplying the muscles of the lower lip, as the depressor labii inferioris, 70, and anastomosing with the facial artery. A branch enters the cranium at the foramen ovale (seen in Plate IV., Fig. 2, digit 4), where the inferior maxillary nerve, 6, comes out; and a conspicuous branch, 5, named the meningeal, is observed to run basilad to the inferior maxillary nerve, 6, to enter the cranium by the foramen spinosum of the sphenoid bone (Plate IV., Fig. 2, digit 5). Its buccal branch is seen in Plate XVI., ramified on the buccinator muscle, h. A pterygo-palatine branch runs down through the canal (marked *s*, Figs. 16 and 22, Plate VI.), along the palate to the foramen incisivum, where it sends a branch upwards to the nostrils, and in this course supplies the velum, tonsils, and palate. A spheno-palatine branch runs through the foramen (o, of Fig. 4, Plate IV.), and is ramified on the nostrils. Its pharyngeal branch is seen in Plate XV. descending on the pharynx downwards to the hyo-glossus muscle, *i*. The trunk of the internal maxillary, as it runs along the infra-orbitary canal, sends branches to the antrum maxillare and orbit.

The ascending pharyngeal, *h*,* is a very small branch, ascends on the pharynx, *p*, upwards to the base of the cranium, supplying the constrictors and mucous membrane of the pharynx, the muscles on the forepart of the bodies of the cervical vertebræ, the muscles of the velum palati, the velum itself, and the tonsils; and a small branch accompanies the internal jugular vein, M, into the cranium.

The temporal branch, *g*, the continuation of the trunk, ascends imbedded in the parotid gland, s, to the zygomatic process, 20, of the temporal bone, over which it runs, and immediately divides into an anterior and posterior branch, that lie imbedded in the tendinous expanse of the occipito-frontalis muscle,† q, q, as they advance to the crown of the head, where the posterior inosculates with the occipital and posterior auris, while the anterior branch inosculates with the frontal branch, 91, of the ophthalmic artery, and both with the arteries of the opposite side. In this ascent the temporal artery gives origin to a number of branches; some to nourish the parotid gland; some to the articular depression, which enter the tympanum by the fissure of Glasserus; branches to the auricle, the temporal muscle, and meatus auditorius externus; some to supply the masseter muscle; a branch named transversalis faciei, which extends across the masseter in company with a conspicuous twig of the facial nerve, immediately above or coronad to the parotid duct, x, to supply the upper lip, the side of the nose, and the orbicularis palpebrarum, w.

The veins which return the blood circulated by the external carotid artery, are generally named after the branches of this artery. The temporal vein, y, is observed to commence about the centre of the coronal suture, and to descend to the trunk of the temporal artery, *g*, at the

* From this inosculation of the occipital and vertebral arteries, the occipital should be a preferable vessel to the temporal artery for abstracting blood in phrenitis, and other similar affections of the head. Of this the ancients seem to have been aware.

† Named also auricularis posterior.

‡ Also named orbito-maxillary.

§ The course of this artery here should be considered by the surgeon, when exarticulating the inferior maxillary bone affected with exostosis.

‖ Termed also genio-maxillary.

* Denominated also simply pharyngeal.

† When the temporal artery is to be opened for fever, or inflammation of the brain, the lancet should be used first as a scalpel, by making an oblique incision downwards and secondly upwards, or in the manner in which it is commonly employed in opening a vein; for the integuments, and the transverse fibres of the tendinous expanse of the occipito-frontalis, are too tough to be cut at once, as in phlebotomy. Generally one of the branches of the artery is selected, but this depends on circumstances.

zygoma, which it then accompanies through the substance of the parotid gland, S, to the angle of the inferior maxillary bone, where the vein assumes the name of external jugular, D, and is generally joined by the facial vein, Z.* The temporal vein receives in its course a number of branches corresponding to those of the artery, and anastomoses with the frontal branch, *z*, of the facial, Z, with the temporal of the opposite side, and with the occipital vein, 90. From the angle of the inferior maxillary bone the external jugular vein, D, descends beneath the platysma myoides, F, obliquely across the sterno-cleido-mastoideus, E, near the origin of the muscle, where, passing beneath, it joins the subclavian vein, *u*. In this course it communicates with the anterior external jugular vein, D, the continuation of the facial, Z.†

The facial vein, Z, is formed by the frontal branch, *z*, that returns the blood circulated by the frontal artery, 91, descends in the fibres of the orbicularis palpebrarum, W, at the inner angle of the eye, where assuming the name of facial, receives a multiplicity of branches as it descends superficially to the levator labii superioris, i, and the zygomaticus minor, e, and beneath the zygomaticus major, a, along the margin of the masseter, l, to the base of the inferior maxillary bone, where the vein accompanies the facial artery, *c*, keeping superficially to the latter. The facial vein then separates from the artery, and continues to descend beneath the platysma myoides, F, and superficially to the submaxillary gland, *n*, and either unites with the temporal vein, y, to form the external jugular vein; or continues its course downwards to the tracheal edge of the sterno-cleido-mastoideus, E, along which the vein runs nearly to the origin of the muscle, where it dips beneath, and terminates in the subclavian vein, *u*. In its descent from the inferior maxillary bone, this vein is observed to receive veins from the muscles extended between this bone and the os hyoides, X, and one from the gland, *n*; also to communicate with the other external jugular vein, and to receive one branch from beneath the sterno-cleido-mastoideus, and another from the larynx which descends obliquely over the sterno-hyoideus, C. This venous trunk may be considered the anterior jugular vein, and the other, previously described, the posterior jugular vein, although a vein which sometimes descends superficially, nearly in the mesial line of the neck, is termed the anterior external jugular. Like the smaller arteries, there is great irregularity in the distribution of these subcutaneous veins; thus, the facial, and many of those on the neck, sometimes end in the internal jugular vein.

The occipital vein, 90, collects the blood circulated by the occipital artery, *d*, anastomoses with the temporal vein, y, and descends on the occiput imbedded in the fibres of the posterior head of the occipito frontalis, q, in those of the sterno-cleido-mastoideus, and splenius capitis, and joins either the internal jugular or vertebral vein: in the subject from which the drawing was taken, it terminated in the latter. Sometimes branches of the occipital end also in the external jugular vein.

* The distribution of the veins here displayed I have found to be as frequently the case as any other; and as this inculcates more practical lessons to the operator, I have preferred them.

† The posterior external jugular vein, crossing obliquely over the sterno-cleido-mastoideus, is opened in croup, &c. In performing this simple operation, the lancet should be used first as a scalpel, and then as a lancet in phlebotomy at the bend of the arm; for the vein is either beneath the fibres of the platysma myoides, or interwoven in them. Great care is requisite to prevent air entering at the wound.

The internal jugular vein, M, which collects nearly all the blood circulated within the cranium by the internal carotid and vertebral arteries (the sources of which will be described when we treat on the brain), emerges along with the glosso-pharyngeal nerve, the nervus vagus, and the accessory nerve, at the foramen lacerum posterius (seen in Plate IV., Fig. 2, letter W), and descends in the neck on the outside, or the dorso-laterad, of the internal carotid artery, 19, afterwards on the common carotid, P, beneath the sterno-cleido-mastoideus muscle, E, downwards to the subclavian vein, *u*, in which it terminates. In this course the internal jugular receives the internal maxillary veins, the pharyngeal veins, one or two occipital veins, the lingual vein, and the superior laryngeal veins, T; and a number of cervical veins end in the angle where the internal and subclavian veins meet.

As portions of the sympathetic nerve and nervus vagus have already been described, with them therefore I shall commence. The nervus vagus, 1, on its emergence from the cranium at the foramen lacerum posterius (seen in Plate IV., letter W), along with the internal jugular vein, M, its accessory nerve, 12, the glosso-pharyngeal nerve, 13, gives and receives twigs from these two nerves, as well as the lingual, 3, and sympathetic nerve, 7, seen in Plate XV.; and at this part the nervus vagus sends a number of soft branches to the internal jugular vein, then descends in the neck between this vein and the internal carotid, and afterwards the common carotid artery, giving twigs to those arteries in its progress downwards to the subclavian artery, between which and the subclavian vein the nerve enters the thoracic cavity. In this course the nervus vagus first gives origin to two or three small pharyngeal twigs, which are seen in Plate XV. ramified on the upper part of the pharynx, immediately above and below the glosso-pharyngeal nerve, 13; and these pharyngeal twigs are generally joined by twigs from the accessory nerve. The superior laryngeal nerve, 55, descends behind the internal carotid artery, and in Plate XVI. is observed to cross the origins of the facial, *c*, and lingual, *b*, arteries, and to divide into a superficial and a deep twig; the former advancing to the hyo-thyroideus, Z, and sometimes supplying many of the superficial muscles in the neighbourhood; the latter, or the deep twig, proceeding to the interior of the larynx, supplies the mucous membrane, and nearly all the little muscles of this organ. The laryngeal nerve, 55, entering the larynx between the os hyoides, X, and thyroid cartilage, S, is better seen in Plate XV., where the superficial is removed. Another twig, 4, named cardiac, is perceived arising nearly opposite to the letter S on the inferior thyroideal artery, and descending on the carotid artery, P, and uniting with the branches of the sympathetic to form the cardiac plexus to the heart: its distribution, along with that of the sympathetic nerves, is seen in Plate IX. on the aorta, E, and pulmonary artery, F. The nervus vagus, 1, on entering the thorax, gives off a recurrent twig, 10,* distinctly seen in Plate IX. to run round the subclavian artery on the right, but on the left side, to turn round the arch of the aorta, E, which is more distinctly observed in Plate XII. This recurrent, 10, at its origin frequently sends off twigs to the pulmonic plexus, and afterwards ascends by the sides of the trachea, K, and œsophagus, to the space between the thyroid

* Also named nervus laryngeus inferior. This nerve is sometimes double on the right side; and in one case found deficient.—*Dr. Stedman, in Edinburgh Medical and Surgical Journal*, No. 77.

gland and larynx, where it sends twigs to the gland, to the œsophagus, the pharynx, the trachea, the mucous membrane of the larynx, and to several of its small muscles. In its ascent the recurrent unites with the cardiac twigs, 11, of the great intercostal, 7, so as to contribute to the formation of the cardiac plexus, which junction is distinctly seen in Plates IX. and XII. The continuation of the nervus vagus has been described in page 39.

The sympathetic or great intercostal nerve, 7, which is formed by reflecting twigs of the 6th pair, and the vidian nerve of the 5th pair (all which will be explained in treating on the organs of sense), emerges from the cranium at the canalis carotideus (seen in Plate IV., Fig. 2, letter, *t*), where the internal carotid artery 19 enters, and descends in the neck on the sides of the bodies of the vertebræ, bound down by loose cellular membrane, till it arrives at the inferior thyroideal artery, s: in this course forming several junctions, and giving origin to some twigs. At its emergence from the canalis carotideus, the great intercostal nerve becomes enlarged, which increase is named its first cervical ganglion, which has an elongated fusiform shape, and at this point forms junctions with the glosso-pharyngeal nerve, 13, with the lingual nerve, 3, with the nervus vagus, 1, and with the first cervical nerve, 21. The ganglion, 7, the nervus vagus, 1, and the internal carotid artery, 19, are encircled with loose cellular membrane; and from this ganglion a number of soft twigs proceed along the artery, which sometimes receives also twigs from the nervus vagus: these soft twigs frequently extend to the external carotid artery, G. The trunk of the intercostal, 7, is observed to unite posteriorly with the different cervical nerves, particularly the four superior, which are marked 21, 22, 23, 24. From the tracheal aspect the intercostal gives origin to some twigs, nearly opposite the third cervical nerve, 23, which unite, descend behind the internal carotid, 19, and appear between the common carotid, P, and the superior thyroideal, *a*, arteries, between which this twig continues its course to the thyroid gland, *Z*. Another twig is given off by the intercostal immediately below the second digit, 7, nearly opposite the third cervical nerve, 23, which descends behind the carotid artery, P, supplying the artery in its course, and generally sending a number of twigs to the muscles on the anterior part of the trachea, and forming junctions with the recurrent, 10, of the nervus vagus, 1, and ultimately distributed on the aorta, E: this is sometimes named the superior superficial nerve of the heart. Where the trunk of the nerve twines round the inferior thyroideal artery, s, another ganglion is commonly formed, which is named the inferior cervical ganglion. Sometimes a third cervical ganglion is found about the fifth or sixth cervical vertebra; indeed, more irregularity occurs in this nerve than in any other, and if the student find the trunk of the nerve in its regular place, he need not be surprised should he find more or less ganglia and twigs proceeding to every nerve, and to every other object in the neck. From the inferior cervical ganglion, named also the cardiac, the twigs generally proceed that constitute the deep or proper cardiac nerves, marked 11 in Plates XV., IX., and XII., which twigs unite with the recurrent, 10, of the nervus vagus, 1, with the superficial cardiac nerve, and with other twigs of the nervus vagus, as that marked 4, Plate XV., and form an extensive cardiac plexus, that supplies the lungs, the heart, and its vessels. Many of them are seen in Plates IX. and XII.

Another mode of describing this portion of the nerve is, that it consists of three cervical ganglia connected to each other by communicating twigs, and to many of the nerves of the neck. From the first cervical ganglion, 7, proceed ascending, descending, external, internal, and anterior branches. The ascending set, two in number, enter the carotid canal, unite with the sixth pair and the vidian nerve, and form the carotid plexus round the internal carotid artery. Filaments from which proceed to the ganglion on the arteria communicans, and to the nasal branch of the ophthalmic nerve of the fifth pair. The other sets of branches have been already described. The two other cervical ganglia, with their branches, have nothing peculiar in their description from that already given.

The trunk of the great intercostal nerve, after dividing and uniting beneath the artery, s, descends on the vertebral artery, R, of Plate IX., on which the nerve sometimes forms a plexus, and again divides at the subclavian, H, as represented in Plate XII., where the nerves unite in the thorax, near the head of the first rib, to form the first thoracic ganglion. The continuation of the nerve has been described in page 39.

The individual cervical nerves, 21, 22, 23, 24, and 9, derive their origin from the spinal cord; like the dorsal and lumbar, they emerge from between the vertebræ, and are distributed chiefly on the muscles and integuments of the neck, excepting the four inferior, marked 9, which constitute the nerves of the upper extremity. They consist of anterior and posterior branches, like the other spinal nerves; but the former only are represented, as they are more important; the latter or posterior supplying merely the muscles and integuments on the back part of the neck. The first four nerves unite to form the cervical plexus; and the first nerve, 21, is observed to form a beautiful plexus with the commencement of the great intercostal, 7, and to unite both directly and indirectly with the second nerve, 22, indirectly through the medium of the sympathetic. This anterior portion, termed the sub-occipital, 21, of the first cervical nerve, sends twigs to the vertebral artery and rectus lateralis muscle, twigs to the recti antici muscles, and a twig to the lingual nerve, 3.

The anterior branch, 22, of the second cervical nerve unites with the first cervical, with the ganglion, 7, of the great intercostal, and with the third cervical nerve, and gives origin to a twig which descends on the internal jugular vein, M, forming a junction with the descendens noni, 5, as seen in Plate XVI., where it is also observed to send a twig to join the nervus accessorius, 12. This twig, however, is formed by the posterior branch of the nerve, which in this case, contrary to the general arrangement, is the larger of the two, and joins the posterior branches of the first and third cervical nerves, and then pierces the muscles, as, for example, the complexus and the splenius capitis. In Plate XVII. this nerve is seen to emerge from beneath the sterno-cleido-mastoideus, E, and to proceed along the posterior margin of the muscle to the occiput, dividing into two twigs in its course. This is named the greater occipital nerve.

The anterior portion, 23, of the third cervical nerve is observed in Plate XV. to form connexions with the preceding and the succeeding nerve, 24, and with the great intercostal, 7, and also contributes to form the phrenic nerve, 8, as explained in page 38; this nerve likewise assists in forming the bond of union with the descendens noni on the internal jugular vein, as seen in Plate XVI. In Plate XVII. there are two nervous twigs observed to emerge from the posterior margin of the sterno-cleido-

mastoideus, and to ascend towards the anterior margin, beneath which they run; the more superior or coronal of the two sending a small branch to the ear; the inferior or sacral, named the less occipital nerve, passing under the sterno-cleido-mastoideus, and emerging on its outer or occipital margin, to accompany the occipital artery, *d*. In Plate XVII., where these twigs commence, a small one is observed giving off by the more sacral of the two, that extends across the sterno-cleido-mastoideus to the external jugular vein, D, along which the twig sometimes descends to the sternum. The third cervical nerve unites also with the accessory, 12.

The anterior part, 24, of the fourth cervical nerve, contributes to form the phrenic, 8, and joins the preceding, the succeeding, and the great intercostal nerves, and gives origin to a multiplicity of twigs, that descend to the clavicle, A, as seen in Plates XVI. and XVII., and which, from their course and situation, are subdivided into superclavicular, supra-clavicular, and sub-clavicular.

The remaining cervical nerves unite with the first dorsal, emerge between the scalenus anticus, L, and scalenus posticus, 50, muscles, and form the axillary or brachial plexus, 9, described afterwards. In Plate XVII. two twigs may be observed crossing obliquely over the subclavian artery, H; the smaller, descending nearly parallel to the external jugular vein, is one of the thoracic nerves; the larger constitutes one of the brachial nerves.

The nervus ad par vagum accessorius, 12,* is formed within the vertebral canal by twigs arising from the roots of the posterior portions of the fourth, fifth, sixth, and seventh cervical nerves, ascends to the foramen magnum (seen in Plate V., Fig. 5, letter *k*), through which it enters the cranium, and proceeds to the nervus vagus, along with which, the glosso-pharyngeal, and internal jugular vein, the nerve makes its exit at the foramen lacerum posterius (seen in Plate IV., Fig. 2, letter w.) Immediately before its emergence, the nerve generally gives origin to a branch termed interior, which joins the twigs of the nervus vagus to form the pharyngeal nerves; and this interior branch sends also a twig to the lingual nerve, 3, and one to the nervus vagus, 1. The exterior branch or trunk of the accessory descends obliquely backwards superficially to the internal jugular vein, M, perforates the sterno-cleido-mastoideus muscle, E, where, uniting with the second cervical nerve, 22, it continues its course along the levator scapulæ, 40, to the trapezius muscle, 80; and in this extent gives origin to twigs supplying these different muscles, and forming junctions with the third cervical nerve, 23, and also with the fourth, 24.

The glosso-pharyngeal nerve, 13, emerges at the same foramen with the last nerve and nervus vagus, and immediately swells into a small ganglion, sending twigs to the facial nerve, to the nervus vagus, 1, to the internal jugular vein, M, and to the internal carotid artery, 19, and forming a plexus with the soft twigs of the great intercostal, 7, and nervus vagus, 1: the nerve then descends behind the stylo-hyoideus muscle, w, giving origin to twigs that supply the stylo-pharyngeus, k, and the constrictors of the pharynx, *p*; and lastly sends off its lingual twig, which, descending sometimes before and sometimes behind the stylo-glossus muscle, m, and hyo-glossus, *i*, to which it affords twigs, enters the root of the tongue, supplying the lingualis muscle, 60, and the genio-hyo-glossus, *k*, in its course to the papillæ capitate vel lenticulares of the tongue. Its pharyngeal twig unites with a twig of the nervus vagus, and forms a plexus that is distributed on the carotid artery, the middle and inferior constrictor muscles of the pharynx.

The lingual nerve, 3,* emerges at the foramen condyloideum anterius of the os occipitis (seen in Plate IV., Fig. 3, letter *p*), receives twigs from the nervus vagus, its accessory, and from the first cervical nerve, then descends between the internal jugular vein, M, and the internal carotid, 19, to the occipital artery, *d*, round which it turns, and proceeds directly across to the tongue. Where the nerve turns round the occipital artery, it gives origin to the descendens noni, 5, which has generally two roots, one of them being either from the nervus vagus, or this nerve and the great intercostal conjointly. The branch, 5, descends on the common carotid artery, P,† downwards to the sternum, giving origin to twigs to the sterno-hyoideus muscle, C, the omo-hyoideus muscle, U, the sterno-thyroideus muscle, B, and the thyro-hyoideus muscle, Z; and unites on the internal jugular vein, M, with the second, 22, third, 23, and fourth, 24, cervical nerves, as well as with the diaphragmatic nerve, 8.

The trunk of the lingual nerve, after giving origin to the descendens noni, proceeds beneath the pharyngeal veins and superficially to the facial, *c*, and lingual, *b*,‡ arteries, near the margin of the hyo-glossus, *i*, where it sends off twigs to this muscle, to the thyro-hyoideus, and to the sterno-hyoideus: the nerve then runs between the hyo-glossus and the mylo-hyoideus, *m*, supplying them with twigs that extend onwards to the genio-hyoideus, *l*, the genio-hyo-glossus, *k*, and the lingualis, 60; the nerve afterwards forms junctions with that of the opposite side, and with the muscular twigs of the inferior maxillary nerve, 6.

The inferior maxillary nerve, 6,§ the third branch of the fifth pair of nerves, emerges at the foramen ovale of the sphenoid bone, as seen in Plate V., Figs. 9 and 10, digits 4, and divides where it descends between the two pterygoid muscles into two branches; the one superior and smaller, the other inferior and greater. The former or smaller branch, as seen in Plate XV., is observed to give origin to a number of small twigs, which proceed to the various muscles in the vicinity; thus, a masseteric twig supplies the masseter, part of the temporal and external pterygoid muscles, and also the articulation of the lower jaw-bone; an exterior deep temporal twig supplies only the temporal muscle; an internal deep temporal twig is also distributed on the temporal muscle, and sends twigs onwards to the orbit, where they join twigs of the second branch of the fifth pair; a superficial temporal twig, also named auricular, supplies the articulation of the inferior maxillary bone, as it proceeds outwards to the cartilage of the external ear, the glands, muscles, and skin: this smaller branch likewise unites with the facial nerve, and sends twigs to the parotid gland, s, to the temporal artery, *g*, imbedded in this body, and even to the skin of the forehead, the temple, and vertex. Some of the latter twigs join the occipital of the second cervical

* Also named accessory nerve of Willis, and spinal accessory.

* Also named the hypo-glossal, or the middle lingual, or the ninth, or the twelfth of the cerebral nerves.

† The situation of this nerve should be attended to by the operator when securing the common carotid artery.

‡ The proximity of the lingual nerve to the lingual artery at the corner of the os hyoides, x, should be considered in securing the artery when wounded, or when extirpating the tongue.

§ Also termed gustatory nerve.

nerve. A buccinator twig, the largest of this branch, proceeds between the pterygoid muscles, but sometimes superficial to the pterygoideus externus, supplying them in its progress onwards to the angle of the mouth, where it unites with the facial and mental nerves; supplies in this course the buccinator muscle, h, the facial vein, z, the facial artery, *c*, where the latter gives origin to the coronaries of the lips, the zygomaticus major, a, the depressor labii inferioris, 70, and the depressor anguli oris, b. These buccinator twigs are seen more distinctly in Plate XVI., distributed on the buccinator muscle, h. The pterygoid nerve is the smallest, and is distributed on the internal pterygoid muscle, n, and the circumflexus palati muscle.

After these small twigs are taken off, the greater branch, or the trunk of the inferior maxillary nerve, 6, proceeds between the pterygoid muscles, and again divides into two branches nearly of equal size: the first, marked 4, named nervus mandibulo labialis,* either surrounds or sends twigs to the internal maxillary artery, and when entering the osseous canal along with the branch, v, of the artery, *f*, gives origin to the mylo-hyoideus twig, 31, which, as its name indicates, proceeds to the muscle, *m*, sending also twigs onwards to the sublingual gland, the anterior head of the digastric muscle, *w*, the chin, and the platysma myoides, F. The nerve, 4, then enters the canal of the bone, giving origin to twigs to the respective teeth and gums.† (The bone is represented in Plate XV. by dotted lines.) Before emerging at the mental foramen, *f*, of Plate XVII., the nerve sends a twig onwards to supply the rest of the teeth, which unites with the nerve of the opposite side: and after its exit from the foramen, divides into a number of twigs,‡ that unite with the facial and the buccinator nerves, and supply the depressor anguli oris, b, the depressor labii inferioris, 70, the levator labii inferioris, the orbicularis oris, f, the glands and skin of the lower lip and chin.

The lingual branch, 32, of the nerve, immediately after its separation from the preceding nerve, receives a twig, 33, named chorda tympani, which emerges from the fissure of Glasserus, and is a twig of the facial nerve; the lingual branch then descends behind or centrad to the internal pterygoid muscle, close to the pharynx, and before or peripherad to the circumflex and levator muscles of the palate, to the submaxillary gland, *n*, supplying them in its course; at this point a ganglion is formed by a junction of some of its smaller threads; and the nerve sometimes sends twigs to unite with the lingual nerve, which are distributed on the gland, the mylo-hyoideus, the stylo-glossus, and genio-hyo-glossus muscles. The nerve then proceeds immediately above, or coronad to the submaxillary duct, as represented in Plate XV., by a bristle introduced onwards to the apex of the tongue, supplying plentifully with twigs the tube. In this course, the nerve gives origin to twigs that descend to unite with those of the lingual nerve: to twigs which ascend to the sublingual gland, 80, to the gums of the posterior molar teeth, and to the skin of the mouth; and sends numerous threads to the stylo-glossus, the genio-hyo-glossus, the back, sides, and apex of the tongue, becoming, as it were, the papillæ which are there placed, the semi-lenticulares and villosæ.

The facial nerve,* 44, emerges at the foramen stylo-mastoideum of the temporal bone (seen in Plate V., Fig. 7, letter *f*), and descends obliquely downwards to the parotid gland, s, dividing in its substance into two branches; but before entering the gland, the nerve gives origin to a posterior auricular or occipital twig, which generally unites with the occipital twig of the third cervical nerve, and afterwards subdivides into a proper auricular twig, and an occipital twig; the former supplying the concha, the retrahentes auris muscle, and the skin; the latter or occipital supplying the sterno-cleido-mastoideus, the splenius capitis, the occipito-frontalis, and the skin behind the ear. A twig from the facial supplies the stylo-hyoideus muscle, w, unites with the great intercostal, 7, and advances as far as the genio-hyoideus muscle, *l*; while another twig supplies the digastric muscle, w, and subdivides into two; the one, ascending near the foramen lacerum posterius, joins the glosso-pharyngeal; the other, descending behind the styloid process, *q*, joins the laryngeal branch, 55, of the nervus vagus.

Where the trunk of the facial nerve, 44, divides into its two branches in the substance of the parotid gland, it lies superficially to the temporal artery and vein, supplying them along with the gland. The superior and larger of these branches ascends in the substance of the gland, and gives origin to a number of branches, that are connected together by small twigs like a net, which arrangement, and a similar one of the lower branch, is compared to a goose's foot, and named pes anserinus, or plexus parotideus. The twigs of the superior branch are, the zygomatic nerve,† the second temporal nerve,‡ the anterior temporal nerve,§ the superior orbital nerve,‖ the inferior orbitary nerve,¶ the superior facial nerve, the middle or great facial nerve, and the inferior facial nerve; which different twigs, represented truncated in Plate XVII., are seen in Plate XVIII. emerging from the parotid gland, s, like white threads, and extensively ramified all over the cranium and face. They unite with the auricular, the occipital, the facial of the other side, the subcutaneous twigs of the second branch of the fifth pair, the frontal twig of the first or ophthalmic branch of the fifth pair, which is seen accompanying the frontal artery, 91, with the twigs of the second branch of the fifth pair in the orbit, with the infra-orbitary nerve, 2, and with the buccinator twig of the third branch of the fifth pair. They supply the muscles of the cartilage of the ear, the temporal muscle, u, the occipito-frontalis, q, the orbicularis palpebrarum, w, the corrugator supercilii, the zygomaticus major, a, muscles, the parotid duct, x, the facial vein, z, the facial artery, *c*, the levator labii superioris alæque nasi, i, the levator anguli oris, o, the depressor labii superioris,

* Also termed inferior maxillary nerve.

† When the nerve at its entrance into the canal of the bone becomes the seat of operation, the surgeon makes an incision with a bistoury from within the mouth on the inside of the ramus, and continuous with the molares. Either the bistoury or a gum lancet may be used to divide the nerve: when the latter is employed, the edge is to be held towards the bone; and when the former, the edge of the knife should be turned downwards or sacrad. The small artery, v, only should be cut.

‡ This nerve may be easily divided from within the mouth by entering the knife between the lip and bone; care must however be taken not to wound the coronary artery of the lip. The artery and vein which accompany the nerve must be divided; but are so small as not to require any consideration. The nerve emerges at the mental foramen, which can be always satisfactorily ascertained, as described in page 16.

* Also named portio dura, and sympatheticus minor.

† Also named jugalis primus, or posterior temporal.

‡ Termed also jugalis secundus.

§ Named also jugalis tertius.

‖ Also styled jugalis quartus.

¶ Also denominated jugalis quintus.

the compressor naris, n, the buccinator, h, and the depressor anguli oris, b, muscles; and are also minutely distributed over the skin and cellular substance.

The inferior branch of the facial nerve descends in the parotid gland, and divides also into several twigs, as the lowest anterior facial nerve, the nerve of the margin of the inferior maxilla, and the subcutaneous nerves of the neck; the first of these extending to the mouth, like some of the twigs of the superior branch, and there forming junctions, of a net-work appearance, with the inferior facial twig, and with the buccinator twigs of the third branch of the fifth pair, and supplying the skin of the mouth, the depressor anguli oris, b, and the platysma myoides, F, muscles. The second branch descends to the angle of the inferior maxillary bone, unites with the other principal twigs of the nerve and those of the third cervical nerve in this region, and then divides into two twigs; the superior ascending on the masseter muscle, l, and running to the mouth, supplying the orbicularis, f, and the depressor labii inferioris, 70, muscles; and in this course, like the other nervous twigs of the face, forming numerous net-work junctions; first, with the preceding twig; secondly, with the buccinator twigs; thirdly, with the different twigs ramified on the lips of the second and third branches of the fifth pair; and fourthly, with the gustatory branch, 32, of the inferior maxillary nerve, 6. The inferior twig runs beneath the depressor anguli oris, supplying this muscle with nervous threads, and is distributed on the skin of the chin, and orbicularis muscle, f, forming junctions with the mental nerve, 4. The subcutaneous twigs of the neck descend below or sacrad to the inferior maxillary bone, unite with the twigs of the mental nerve, with those of the opposite side, with those of the third cervical nerve, and are distributed on the depressor anguli oris, the platysma myoides, and on the skin from the chin downwards below the larynx.

The infra-orbitary nerve, 2, the chief twig, or the continuation of the second or superior maxillary branch of the fifth pair of nerves, enters the infra-orbitary canal at the bottom of the orbit (seen in Plate VI. Fig. 15, letters *o*), along which it runs, giving origin to twigs that supply the teeth, and emerging at the infra-orbitary foramen, *o*, along with the artery of the same name. At its emergence the nerve divides into a number of twigs, which spread in all directions,* uniting with each other, with the buccinator twigs, and with the facial twigs, forming the infra-orbitary plexus; and the twigs which derive their origin from this plexus supply the orbicularis palpebrarum muscle, w, the inferior eye-lid, the caruncula lachrymalis, the ductus lachrymalis, the skin of the cheek, the nose, the compressor naris, n, the levator labii superioris, i, the depressor labii superioris, the orbicularis oris, f, the levator anguli oris, o, muscles, and the skin of the upper lip and nose.

The frontal nerve,† seen in Plate XVIII., accompanying the frontal artery, 91, is a twig of the first or ophthalmic branch of the fifth pair of nerves, and is the continuation of the frontal nerve, and therefore commonly named the proper frontal, to distinguish it from the other twigs given off within the orbit. It emerges along with the artery at the supra-orbitary foramen (seen in Plate V., Fig. 1, letter *n*), ascends on the forehead, sending twigs to the orbicularis palpebrarum muscle, w, the skin of the eye-brow, the occipito-frontalis muscle, q, the skin of the forehead, vertex, and temple, and unites with the twigs of the facial nerve.

---

* The radiated branches of this nerve must be kept in view by the operator. From the distance between the lining membrane of the mouth and this nerve, it cannot be divided from within, but can be easily divided from without, by first drawing a perpendicular line from between the two bicusped teeth to the margin of the orbit, which will bisect the foramen, and then calculating the distance from the orbit, which is about a sixth. A spear-pointed double-edged scalpel should be employed to transfix the integuments and levator labii superioris, i, down to the bone, along which it must grate, making a semicircular sweep, in order to sever all the twigs of the nerve. The knife should evidently be entered a little above the foramen, to secure the division of the superior ascending twigs. The directions here given are only applicable to the adult, for in the young subject the teeth are so much smaller, that the measurement must commence at the anterior edge of the first bicuspis. (See Plate VI., Fig. 15.) This division of the nerve affords no relief; the disease recurs, so that the nerve must be divided deep in the orbit.

† When the frontal nerve becomes the seat of operation, it may be ascertained by drawing a line, which will bisect the foramen infra-orbitarium and the foramen mentale at the same time. This nerve must be divided deeper in the orbit.

BLOOD-VESSELS AND NERVES OF THE UPPER EXTREMITY.

THE subclavian artery, H, on the right side, is a branch of the arteria innominata, Q, but on the left side derives its origin directly from the arch of the aorta, E, as seen in Plate IX., runs between the scalenus anticus muscle, L, and the scalenus posticus muscle, 50, over the first rib, 64, having the brachial plexus, 9, immediately above or atlantad, and the subclavian vein, *u*, below or sacrad, the latter being separated by the scalenus anticus, L, as seen in Plates XV. and XVI.

In Plate IX. the right subclavian artery, before entering between the scaleni muscles, is observed encircled by the sympathetic nerve, 8, the nervus vagus, 1, with its recurrent, 10, and the vertebral vein, N, running superficially to it; and gives origin to the vertebral artery, R, seen only on the left side, to the ascending thyroideal, S, the internal mammary, 14, and the superior intercostal artery, 12, which last is seen in Plate XII. On the left side, the subclavian artery gives origin to the same branches as on the right, and is encircled with similar nerves, but has the thoracic duct lying superficially to it.*

The superior intercostal branch, 12,† descends into the thoracic cavity, as seen in Plate XII., crossing the first rib, and dividing into small branches, which extend as far down as the lower margin of the second rib, and accompany the nerves like the aortic intercostal arteries described in page 39, with the first branch of which it inosculates. The vein which returns the blood of this artery is seen in Plate XII., marked 15.

The internal mammary branch, 14,‡ of Plate IX., runs behind the subclavian vein, *u* or *v*, enters the thoracic cavity exteriorly or peripherad to the pleura, and extends to the cartilage of the first rib, which it crosses near its sternal extremity; descending parallel to the sternum, *e*, as seen in Fig. 2, Plate XI., crossing the cartilages of the other true ribs, near their sternal extremities, and running between them and the sterno-costalis muscle, letters B, downwards to the diaphragm, which it pierces in crossing the seventh rib. The artery then enters the abdomen, where it is named epigastrica superior, and runs between the muscles and the peritoneum nearly as far as the umbilicus, where it divides into small branches, which inosculate with those of the epigastric, X, Plate IX., of the iliac artery; the artery is accompanied by its vein, that joins the subclavian vein. The inosculation of these arteries is distinctly seen in Plate XXX. In Plate IX., on the left side, the muscle is cut up to show the artery and vein. The internal mammary in this extensive course gives origin to numerous small branches; some to the sterno-hyoideus muscle, the sterno thyroideus muscle, the contiguous lymphatic glands, the clavicle, the sternum, the sterno-costalis muscle, the mediastinum, named mediastinæ, the thymus gland in the fetus, the ribs, and the intercostal muscles, these last being named intercostales anteriores, or external branches; and some of these branches pierce the intercostal and the pectoral muscles, supplying the mammary gland in the female, as seen in Plate XIX. Fig. 1, digits 14. A branch, termed comes nervi phrenici, is generally given off to accompany the phrenic nerve, 8, Plate IX., that also contributes to supply the pericardium, C, and anastomoses with the thoracics of the axillary artery, and with the intercostal arteries; and near the cartilage of the sixth rib, a branch is seen proceeding to the diaphragm, named the musculo-phrenic, and giving origin to small branches which anastomose with the aortic intercostals and the aortic phrenic.

The vertebral artery, R, takes its origin from the opposite or atlantal aspect of the subclavian, and ascending in the neck, enters the foramen in the transverse process of either the seventh or sixth cervical vertebra; and in rare instances, one of the more atlantal vertebræ, even the third; the further distribution of this artery will be described when treating on the brain; the foramina are seen in Plate II., Figs. 3, 5, and 6, letters *f*. The vertebral vein, N, that returns a considerable portion of the blood circulated by the artery, descends through the same foramina, and joins the subclavian vein, *v*.

The inferior thyroideal artery, S,* or thyroid axis, immediately after its origin, divides into three branches, the ascending thyroid, the transversalis colli, and the supra-scapular. The thyroideal branch is observed in Plate IX. to ascend behind the vertebral vein, N, on the scalenus anticus muscle, L, and in Plate XV. to be encircled by the sympathetic nerve, 7, then to run behind the nervus vagus, 1, and the common carotid artery, P, to the thyroid gland, *Z*, and the larynx, on which the vessel is ultimately distributed; here this branch inosculates with the superior thyroideal, *a*, of the external carotid, and with its fellow of the opposite side, and in this course gives origin to twigs that supply the trachea, the œsophagus, and pharynx; and usually gives origin to the supra-scapular, 51, the transversalis colli, 52, and the deep cervical, *r*, arteries: the latter was a branch of the thyroideal, and ascends on the scaleni, to the levator scapulæ, 40, and other muscles in the contiguity, inosculating with branches of the vertebral artery issuing out between the vertebræ, and with the descending branch of the occipital artery: but in the subject from which the drawings were taken, the transversalis colli, 52, and the supra-scapular, 51, were given off, after the artery had emerged beyond the scaleni muscles L and 50; the former artery, the transversalis colli or scapularis posterior, 52, dips beneath the axillary plexus, 9, then emerges and extends across the levator scapulæ muscle, 40, which it supplies along with several muscles in the vicinity, and descends along the base of the scapula to its inferior angle, where it inosculates with the subscapular branch of the axillary

* On either side, the subclavian artery in this space should never have a ligature thrown round it for aneurism of the axillary artery; on the right side, the arteria innominata can be secured either for this disease or for a wound of the subclavian on the tracheal side of the scaleni muscles; and on the left side, if the artery be wounded, there can be no alternative but securing it, even at the risk of involving the thoracic duct; but for aneurism this appears scarcely warrantable: yet if the patient be threatened with immediate death, what would he not suffer, and what operation would not the surgeon be justified in attempting, to save his life?

† Also named intercostalis prima.

‡ Also termed sternal artery.

* Also named sacro-thyroidea and thyroid axis.

artery; the supra-scapular, 51, is observed to run beneath the clavicle, and is traced afterwards.* The veins named cervical, which return the blood circulated by these branches, are observed in Plate XVII. to run across the subclavian artery, H, and to terminate in the angle between the internal jugular, M, and subclavian, *u*, veins, as represented in Plate XVI. The subclavian artery, emerging beyond the clavicle, A, assumes the name of axillary, the course and branches of which are described afterwards; also the branches which form the subclavian vein, *u*. The vein *u* is observed to run on the sternal aspect of the insertion of the scalenus anticus muscle, L, to descend into the thoracic cavity behind the sternum, where this subclavian vein is immediately joined by the vein of the opposite side, *v*, in order to form the vena cava descendens, *h*, as seen in Plate IX.; in this course the subclavian vein receives the several cervical branches, the posterior external jugular vein, D, as seen in Plate XVII., the anterior external jugular vein, D, and internal jugular vein, M, as represented in Plate XVI., and various thyroideal veins, O, as delineated in Plate XV.†

Fig. 4, in Plate XI., exhibits the structure of an artery, as afterwards described.

---

* This branch, when it takes its origin from the inferior thyroideal artery, S, runs along the under surface of the clavicle, and is then in the way of the knife in performing the operation of securing the subclavian artery above the clavicle.

* When the subclavian artery, between its emergence from the scaleni muscles and the clavicle, becomes the seat of operation, the following directions render it one of the simplest operations of surgery. The patient should be placed on a low table, sofa, or bed, with his body reclining so as to form an obtuse angle with the thighs, and his head turned to the side opposite to that on which the operation is to be performed, and bent gently backwards. The arm of the affected side is to be held close to his side, and the shoulder brought sternad and sacrad. The space between the two extremities of the clavicle should be divided into seven proportional parts, when the artery will be indicated three from the sternal and four from the scapulary end of the clavicle, running over the first rib. An incision parallel to, but quite clear of, the clavicle, is to be made, proportional in length to the age of the patient, and to the thickness of skin and cellular tissue, through these parts and the platysma myoides, when the operator will feel the scapulary margin of the sterno-cleido-mastoideus muscle, which is to guide him to the artery. The loose watery cellular tissue is then to be carefully dissected aside, when the surgeon will soon feel the pulsation of the artery. The scapulary margin of the scalenus anticus muscle should be felt as well as the tubercle of the first rib into which this muscle is inserted, before the needle is attempted to be used. The aneurism needle should be passed round the artery from the tubercle of the first rib to the scalenus posticus, carefully surrounding the artery, to avoid including any of the nerves forming the axillary plexus. The ligature can be easily tied with the fingers, by twisting its ends round the middle fingers, and inserting the forefingers into the wound down to the artery, which is preferable to all the serre-nœuds ever invented. I witnessed Mr. Wishart perform this operation in the Royal Infirmary, nearly according to these rules, with great dexterity; no veins were wounded, no nerve included, and no serre-nœud employed; and the patient has done well. The measurement and chief directions here given, are from the MS. Lectures of that able anatomist, Mr. Walker, formerly Lecturer on Anatomy and Physiology, Edinburgh. The chief danger in this operation is the wounding the subclavian vein, *u*, seen in Plates XV. and XVI., which may be greatly avoided by compressing the veins of the arm with a tourniquet; for one or more valves are situated at the junction of the internal jugular and subclavian veins, so that the blood flowing down the former cannot retrograde along the latter to the arm, but must run onwards to the heart. In Plate XI., Fig. 3 is a representation of the union of these veins of the left side; M indicates the internal jugular vein descending to terminate in the subclavian vein, *v*, V; italic *v* the proximal extremity of the vein which proceeds to join the other subclavian vein, in order to form the vena cava superior; and the roman capital V the brachial or distal extremity. The valves, three in number, are observed in this latter extremity of the vein, and are marked *a*; these are sometimes two in number, and sometimes only one; but still the one is capable of doing the duty of the three. I may here remark, that three valves are the number generally found in the veins of both the upper and lower extremities. In the event of any vein being wounded, a ligature must be thrown round the vessel on each side of the wound, in consequence of its proximity to the heart. There is a peculiarity in Plate XVII. with respect to the omo-hyoideus muscle, U, but which I have observed to be very common, and have therefore represented it: the muscle adheres to the clavicle, A, so as to take its course below or sacrad to the subclavian artery, H, whereas it is commonly represented running superior or atlantad to the artery, which has arisen, I presume, from the muscle having been too much detached in the dissection before drawn. The artery, H, appears higher up, or more atlantad than is imagined, which is generally the case on the right side, in consequence of the subclavian being a branch of the arteria innominata, and also of the position of the subject here chosen, in order to bring the greater number of objects into view. In the event of the omo-hyoideus, U, interfering in the operation, it may be easily pushed to one side, and to the superior or atlantal will generally be found the easier.

BLOOD-VESSELS AND NERVES

OF

THE UPPER EXTREMITY.

In page 54 the subclavian artery is traced to its emergence beyond the clavicle, where it assumes the name of axillary; and in Plate XIX. we observe the artery, H, entering the axilla, between the thorax and the scapula, having the serratus magnus muscle, O, on its proximal and sternal side, and the subscapularis muscle on its distal and dorsal aspect; while the two pectoral muscles, the major, C, the minor, D, along with the clavicle, A, protect it externally and atlantad: this is very distinctly seen in Plate XXXVIII. Where the two pectoral muscles extend over the artery, they are cut across, and represented with thin scattered fibres. In this course, from the clavicle, A, to its emergence beyond the distal margins of the greater pectoral muscle, C, and latissimus dorsi muscle, E, which, along with the teres major muscle, F, that is incorporated with the insertion of the latter, form the folds of the axilla, the artery is surrounded with the axillary plexus of nerves, 1, the axillary vein, *u*, a number of lymphatic glands, *a*,* and a quantity of adipose cellular tissue,† and gives origin to several thoracic branches, a subscapular branch, a posterior circumflex branch, and an anterior circumflex branch. The thoracic branches, a, a, are so irregular, that it is surprising any anatomist should have given them individual names;* they arise sometimes by one trunk, sometimes by two, three, four, and even by six branches; and supply the two pectoral muscles, the serratus major anticus muscle, O, the intercostal muscles, the subscapular muscle, the deltoid muscle, B, and the glands in the axilla and skin; anastomosing with branches of the supra-scapular artery, the superficial cervical artery, the intercostal arteries, and of the internal mammary artery.

The subscapular, C,† the largest branch given off by the axillary artery, descends on the margin of the subscapular muscle to the inferior angle of the scapula, supplying in this course the different muscles in the vicinity, the axillary glands, and the capsular ligament of the shoulder-joint, and anastomosing with branches of the superficial cervical artery: this continuation of the artery is named scapularis interna. Shortly after its origin, the subscapular artery sends off a branch, *c*, termed the scapular circumflex,‡ that passes between the scapula and the conjoint tendon of the latissimus dorsi, E, and teres major, F, muscles, and which subdivides into branches that supply the teres major, the teres minor, 80, the infra spinatus, 81, and the celtoid, B, muscles; and into one that runs beneath the infra-spinatus muscle on the bone, and ascends to inosculate with the supra-scapular artery, 51, as seen in Fig. 1, Plate XX.

The posterior circumflex artery, d,§ which is the most important branch to the surgeon,‖ twines round the neck

* The close proximity of the axillary glands to the axillary vessels should be attended to in their extirpation when cancerous.

† The intimate connexion of the axillary artery with the axillary vein and axillary plexus of nerves, where it runs under the pectoral muscles, presents such a difficulty to the operator, that no surgeon appears justified in attempting to secure the vessel here, unless when recently wounded. When the artery is wounded on its emergence from the axilla, it may be secured by elevating the arm as high as possible, and supinating the hand, the patient being previously laid on a bed or table; an incision is then to be made over the head of the os brachii, a little on its ulnar aspect, and nearly in the centre of the axilla, parallel with the margins of the pectoralis major and latissimus dorsi muscles, through the skin and cellular tissue, when the pulsation of the artery will be felt, the median nerve, 2, lying superficially, and the axillary vein, *u*, internally or ulnad to the vessel. A few scratches with the knife will sufficiently separate these objects, so as that the operator may insert the aneurism needle between the vein and artery, carrying the instrument closely around the vessel from the ulnar to the radial aspect, in order to avoid including one of the satellite veins, or any of the nerves which too frequently embrace very closely the artery, and again unite. The artery runs a little on the ulnar side of the head of the os brachii, and is nearer the pectoralis major than the latissimus dorsi muscle. As one of the venæ comites frequently crosses the artery from the radial aspect of the arm, the operator should lateralize the cutting edge of the knife towards the radial aspect, in order to avoid wounding the axillary vein. A peculiarity of the muscles frequently occurs here; for example, a thick fleshy slip often extends from the latissimus dorsi across the artery and accompanying vessels, to the insertion of the pectoralis major, which might deceive and embarrass the operator; and which is sometimes as strong as the coraco-brachialis muscle.

* They are named the long or superior thoracic or external mammary; the highest thoracic, or thoracica suprema; the alar; the humeral; the acromial; the external superior; and the external inferior thoracics. The course of the long or external mammary branch, which descends on the inferior or sacral margin of the pectoralis major muscle, and afterwards ascends to the mammary gland, should be considered by the operator when extirpating this gland; and the two external semi-elliptical, as well as the deeper incisions, should be made from the axilla to the sternum, that this artery may be cut only once.

† Syn. Infra-scapular; inferior scapular; and scapular artery.

‡ Named also dorsalis scapulæ inferior.

§ Syn. The anconal circumflex; the articularis posterior; the reflexa humeri; and the humeralis.

‖ The posterior circumflex artery is concerned in amputation of the shoulder-joint; and when this operation is to be performed, the patient should be laid on a low table, and the hand supinated as much as possible, in order to remove the long head of the biceps muscle from the axillary plexus of vessels; and then two semi-elliptical incisions are made from the acromion scapulæ to the axilla, the internal extending merely through the skin, but the external as deep as the operator can accomplish, and both as far distad as to avoid the posterior circumflex

of the os brachii, proximal to the conjoint insertions of the latissimus dorsi and teres major muscles, between the bone and the long head, G, of the triceps muscle, and proceeds to the deltoid muscle, B, as seen in Fig. 1, Plate XX. In this course it naturally supplies these, and other contiguous muscles, as well as the capsular ligament and joint of the shoulder, anastomosing with branches of the subscapular, with which it sometimes arises conjointly from the axillary artery. The commencement of this branch is seen in Plate XXXVIII. In rare instances this branch derives its origin from the brachial artery, distad to the insertion of the latissimus dorsi and teres major muscles.

The anterior circumflex,* e, a small branch of little importance, arises sometimes from the axillary, and sometimes from the posterior circumflex arteries, runs round the thenal aspect of the neck of the os brachii, beneath the coraco-brachialis, K, which is here represented as if it were under the artery, the biceps, L, and deltoid, B, muscles, supplying them and other muscles in the contiguity, and anastomosing with the posterior circumflex and subscapular arteries.

The supra-scapular artery,† 51, Fig. 1, Plate XX., which in Plates XV., XVI., and XVII. is seen to be a branch of the subclavian artery, but often one from the thyroid axis, is observed to run under the proper posterior ligament, *a*, of the scapula, and beneath the supra-spinatus muscle, 66, the greater portion of which is here removed, also below the acromion scapulæ, D, where it surrounds the joint, and inosculates with the subscapular and posterior circumflex arteries. This branch is also seen in Plate XXXIX., Fig. 2. The supra-scapular is sometimes a branch of the inferior thyroideal, and sometimes a branch of the axillary artery.

The axillary artery, H, as soon as it emerges beyond the folds of the axilla, assumes the name of brachial, h,* and descends along the ulnar margins of the coraco-brachialis, K, and the biceps, L, muscles, a little beyond the elbow-joint where the pronator radii teres muscle, I, crosses it, as seen in Fig. 2. In the upper half of this course the artery rests on the triceps muscle; at the middle it crosses the insertion of the coraco-brachialis; in the lower or distal half of the arm, it lies on the brachieus internus; and throughout is covered only by skin, cellular tissue, and the fascia of the arm, excepting at its distal or lower portion, where the tendinous expansion, l, Fig. 2, of the biceps muscle extends across it to the fascia of the fore-arm; and in this extent it is generally accompanied by the median nerve, 2, lying superficially, and the brachial vein, u, internally or ulnad,† This artery gives origin to irregular muscular branches, which are named profunda superior, profunda inferior, and anastomoticus magnus: there are, however, many branches arising from it, equal in magnitude to these.

The profunda superior,‡ f, takes its origin from the ulnar aspect, descends between the second, g, and third, *g*, heads of the triceps muscle, in company with the spiral nerve, 6, winds round the bone of the arm, and emerges on the radial aspect, as seen in Fig. 1, Plate XX., between the supinator radii longus, N, and the brachieus internus, M, muscles, where it inosculates with the radial recurrent, i, and also in this course with some of the branches of the axillary, with others of the brachial, and sometimes with the ulnar recurrent, supplying the various muscles in its progress. The profunda derives its origin sometimes from the posterior circumflex, and sometimes from the subscapular arteries.

The profunda inferior, or minor, k, takes its origin sometimes from the radial, and sometimes from the ulnar

---

artery; the internal or sternal incision through the skin being necessarily made first. The external or dorsal incision having extended through the deltoid muscle to the bone, the operator cuts the insertions of the teres minor, infra-spinatus, and supra-spinatus muscles, and at the same time the capsular ligament; and from the arm being completely supinated, he will reach at this stage of the operation the long tendon of the biceps, by cutting across which the joint is completely dislocated, and the assistant can easily insert his thumb between the bone and the inner flap, so as to compress the axillary artery with its branches: the operator then cuts through the muscles, blood-vessels, and nerves, with one or two strokes of the knife, making the flap correspond with the incision through the skin made at the commencement of the operation. The muscles cut in the inner flap are, first, the insertion of the subscapularis; secondly, the remainder of the acromial and clavicular portions of the deltoid, with the pectoralis major, short head of the biceps, and coraco-brachialis; and thirdly and lastly, the latissimus dorsi, teres major, and long head of the triceps. The posterior circumflex artery adhering to the scapular portion of the deltoid muscle, is reflected along with the outer flap, and hence is seldom wounded till after the assistant has compressed the axillary artery. It would be foreign to the design of this work to enter into an examination of the different modes of amputating the shoulder-joint; but I may observe, that this is the quickest, that less blood is lost, and that there is less risk of sinuses forming in the axilla, which I have seen extend to the crista of the os ilium: the two first positions can be easily verified on the dead body, and to imitate the circulation, an injecting pipe should be inserted on the opposite subclavian artery. When cutting across the insertions of the teres minor, infra and supra-spinati muscles, the edge of the knife should be held at a right angle to the head of the os brachii. If the operator despise well-formed external incisions, he may begin the outer flap from the axilla, carrying it upwards to the acromion scapulæ; and when the assistant has inserted his thumb between the bone and the artery, so as to compress the latter, he may cut outwards, through blood-vessels, nerves, muscles, and skin, making this inner correspond with the outer flap. A strong argument in favour of this latter method is, that in the adhesion of flaps either in amputation or extirpation of the mamma, nature makes so elegant a union, that all irregularities are obscured.

* Also named the thenal circumflex, and articularis anterior.

† Syn. The superspinal; the dorsalis scapulæ superior; the transversalis scapulæ; and the transversalis humeri.

* Also termed the humeral portion of the brachial artery, or simply the humeral artery.

† When the brachial artery becomes the seat of operation, the arm should be laid on a table with the hand supinated, and an incision made through the skin, cellular tissue, and fascia of the arm, along the margin of the coraco-brachialis muscle if in the upper or proximal half of the arm, and along the margin of the biceps muscle if in the lower or distal portion of the arm. The pulsation of the artery will soon be felt, and the vessel must be carefully separated from the median nerve, brachial vein, and other concomitant veins which are generally present, by the scalpel and forceps; the cutting edge of the scalpel being lateralized towards the radial aspect of the arm, in order to avoid wounding the brachial vein. The aneurism needle should be inserted between the artery and nerve and brachial vein, turning it round the artery from the ulnar to the radial aspect. As veins frequently cross the artery to join the brachial vein, the operator should be on his guard to avoid them; and as muscular slips sometimes extend from the pectoralis major muscle, and from the coraco-brachialis muscle to the inner condyle of the os brachii, the operator should be prepared to encounter them. When brachial aneurism occurs at the bend of the arm, it should be treated as a wounded artery, a ligature thrown round the vessel above and below the diseased point. When the artery is wounded in blood-letting, some recommend graduated compresses and bandage. The course of the brachial artery should be considered in relation to amputation of the arm. Fig. 4 of Plate XI. is a portion of the brachial artery, dissected to illustrate the minute structure of an artery. The letters A indicate the extremes, that on the right hand being cut open to exhibit the internal or serous coat, 1, which is also seen in the middle of this portion, marked 1, while a, a, show the exterior or cellular coat, dissected off from the middle or muscular coat, *a*, *a*.

‡ Also named arteria spiralis, and profunda humeri.

aspect; when from the latter, the branch descends on the third head, *g*, of the triceps to the ulnar condyle, anastomosing with the ulnar recurrent; and when from the radial aspect, it penetrates the brachieus internus muscle, and inosculates with the radial recurrent. Shortly after its origin, it gives off the nutritious artery of the bone which pierces the fibres of the coraco-brachialis muscle and enters the oblique canal of the os brachii.

The anastomoticus magnus, or simply anastomoticus, m, derives its origin commonly from the ulnar aspect of the brachial artery, a little above the internal or ulnar condyle of the os brachii, and descends on the third head, *g*, of the triceps, around this protuberance of the bone, to anastomose with the recurrent, n, of the ulnar artery, as seen in Fig. 2, Plate XX. The nutritious artery of the os brachii is described also as a particular branch; but all of them are so irregular, that the student who has dissected two arms, is surprised, from their variability, at the importance given them by authors, and wonders why the large branches to the biceps muscle have got no name.

The brachial artery, h, as seen in Fig. 2, Plate XX., divides into two branches, the radial, o, and the ulnar, *h*,* near where the pronator radii teres muscle, I, extends across the fore-arm. The latter or ulnar artery, *h*, more properly the continuation of the trunk, runs beneath the pronator teres, I, the flexor carpi radialis, P, the palmaris longus, *Q*, and the flexor digitorum sublimis, R, muscles, as seen in this and Plate XIX., and emerges between the latter and the flexor carpi ulnaris muscle, s, about the distal third of the fore-arm, where running between these two muscles, accompanied with its venæ comites and the ulnar nerve, 5,† to the pisiform bone, T, on the radial aspect of which it descends, beneath the palmar aponeurosis, V,‡ and superficially to the annular ligament, U, forming an elegant arch in the palm of the hand, which extends to the thumb, there inosculating with the thenal branch, or superficialis volæ, *x*, of the radial artery, o.

The course of the ulnar artery beneath the palmar aponeurosis is represented in Plate XIX. by dotted lines. This palmar arch, *h*, of the ulnar artery is named the superficial,* to distinguish it from a deeper one of the radial artery. The ulnar palmar arch is observed to give origin to branches denominated volar, which proceed to the space between each two fingers, where they divide into two branches named digital, as digito-radial and digito-ulnar of the respective fingers; these run along the sides of the fingers to the tips, where they anastomose and form beautiful plexuses of vessels.

Shortly after the ulnar has separated from the radial artery, it is observed to give origin to the recurrent, n, Fig. 2, Plate XX., which pierces the flexor muscles of the fore-arm, winds round the inner condyle of the os brachii, and inosculates with the anastomoticus, m, and inferior profunda, k, of the brachial artery, Fig. 1, Plate XIX.; also sometimes with the profunda superior and the interosseous recurrent. This branch is divided by some authors into an anterior and posterior; the anterior recurrent to ascend on the palmar aspect of the inner condyle, the posterior recurrent to ascend on the anconal aspect of the inner condyle of the os brachii. Nearly opposite the commencement of the recurrent, the ulnar artery gives origin to the interosseous artery, p, which pierces the flexor digitorum profundus muscle, W, reaches the interosseous ligament, and divides into an anterior and posterior branch; the anterior interosseous artery descends on the palmar aspect of the ligament to near the carpus, there it pierces the ligament and runs on the anconal aspect of the carpus, inosculating with branches of the posterior interosseous, and radial, arteries. The posterior interosseous branch runs through the aperture in the ligament close to the oblique ligament of the radius, descends on the anconal aspect of the interosseous ligament to the carpus, where it anastomoses with the anterior interosseous, ulnar, and radial, arteries. Immediately on this artery piercing the interosseous ligament near the elbow joint, it gives origin to its recurrent branch, which ascends between the olecranon and external condyle, and divides into branches that inosculate with the posterior ulnar recurrent, the profunda inferior, and profunda superior, arteries. The ulnar artery also gives origin to a number of muscular and other branches in its course.

The radial artery, o, takes its origin at the bend of the arm, runs superficially towards the carpus, first between the pronator radii teres, I, and the supinator radii longus, N, muscles; secondly, between the latter muscle and the flexor carpi radialis muscle, P, resting chiefly on the flexor longus pollicis muscle, X; and is accompanied by two venæ comites, and for a short distance by the cutaneous twig, 16, of the spiral nerve.† At the carpus the radial

* Considerable irregularity exists in the division of the brachial artery, for sometimes this takes place as high up as the axilla, and frequently about the middle of the arm. As the branch which may be said to come off high up in the arm, whether it be the radial or the ulnar, for one of them generally pursues the course of the trunk, sometimes runs superficially or peripherad of the fascia of the arm, the young practitioner should be careful, when performing phlebotomy at the bend of the arm in candle-light, that he does not mistake one of these branches for a vein. The ulnar is the branch which more frequently runs superficially to the fascia, but is not the branch that is oftener given off high up in the arm.

† The ulnar artery can only be easily secured in the distal third of the fore-arm; the arm should be placed on a table with the hand supinated, and an incision made through the skin and cellular tissue over the course of the vessel, then the flexor carpi ulnaris separated from the flexor digitorum sublimis by cutting through the fascia of the fore-arm (for in Fig. 2 of Plate XIX. the fascia is cut open, and the muscles separated a little, to expose the artery, veins, and nerve), when the pulsation of the artery will be felt. The aneurismal needle should be inserted between the nerve and artery, and carried close around the latter, in order to exclude the venæ comites, which is somewhat difficult, in consequence of their smallness and adhesion to the artery. When this artery is wounded in its upper or proximal third, the median nerve becomes the guide to the vessel, and the muscles crossing it must be freely divided. When injured in its middle third, the operator should retrace the artery from its course between the flexor ulnaris and flexor sublimis muscles to its course under the median nerve.

‡ When the artery is wounded in the palm of the hand, it must be secured there, in consequence of the free inosculation with the radial artery.

* Termed also arcus volaris sublimis.

† When the radial artery requires to be secured, it may be done at any part of the fore-arm, by making an incision through the skin and cellular substance, on the ulnar edge of the supinator radii longus muscle, and then cutting cautiously through the fascia of the fore-arm, which connects this muscle with the pronator radii teres and flexor carpi radialis, so closely as to obscure the artery, excepting at their tendons. The artery is afterwards to be separated from its venæ comites and nerve, and the aneurismal needle passed round from the radial to the ulnar aspect, in order to avoid the nerve, which, however, is sometimes so much radiad, as not to require to be taken into consideration. In this operation, the arm should be laid on a table, with the hand supinated. It is generally very difficult to find out the margin of a slender muscle, such as the supinator radii longus, and this forms the chief obstacle to the operator in reaching this and other similarly situated arteries; again, the fascia binding them so closely, becomes another obstacle.

artery passes beneath the extensor ossis metacarpi, *a*, the extensor prima internodii, *b*, and the extensor secundi internodii, *c*, muscles of the thumb, as seen in Plate XXI., winding round the back of this finger, and piercing between the abductor indices and the adductor pollicis muscles, enters the palm of the hand to form the deep palmar arch, *o*, Fig. 2, Plate XX., which inosculates with the ulnar palmar arch.

In this course the radial, like the ulnar artery, gives origin to a recurrent, i, which anastomoses with the profunda superior, f; to numerous muscular and other branches; and, as it twines round the thumb, gives origin to a thenal branch,* *x*, at the carpus, which inosculates with the superficial palmar arch, *h*, of the ulnar artery, as observed in Figs. 2 of Plates XIX. and XX. On the back of the hand the artery sends off one or two small branches, as seen in Plate XXI., that extend across the hand, and generally inosculate with the anconal branch of the interosseous artery; these branches are sometimes of considerable magnitude, and where it runs between the abductor indicis and adductor pollicis muscles, gives origin to a branch named arteria magna vel princeps pollicis, *d*, but, more correctly, the digito-ulnar of the thumb. From the deep palmar arch, *o*, Fig. 2, Plate XX., branches proceed between the metacarpal bones, and are lost at the roots of the fingers; one, however, is observed to form, from its magnitude, the chief volar branch which supplies the fore and middle fingers.

Although this arrangement of the radial, ulnar, and interosseous arteries is one of those most commonly found, yet great irregularity occurs both in their origins and distributions. Besides those variations mentioned by others, I have witnessed a branch, deriving its origin from the ulnar artery immediately as it separates from the radial, descend superficially between the radial and ulnar arteries, pass beneath the fascia palmaris, and join the superficial palmar arch.† I have also observed the trunk of the radial artery run between the metacarpal bones of the index and middle fingers; and even between those of the middle and ring fingers.

The veins which return the blood circulated by the subclavian artery and its branches, are divided into two sets, a superficial and a deep seated; the former returning the blood of the integuments, the latter the blood of the muscles and deeper objects.

The superficial veins are named the cephalic, basilic, and median. The basilic vein, q, Plate XXI., and Fig. 2, Plate XIX., returns the blood of the integuments situated on the ulnar aspect of the back of the hand and fore-arm, inosculating freely with the cephalic vein, r; ascends on the palmar or thenal aspect of the arm, beneath the skin and superficially to the fascia of the fore-arm, and contributes chiefly to form the brachial or basilic vein, u, Fig. 1, Plate XIX.; and at the bend of the arm generally communicates with the cephalic and venæ comites. In Fig. 2, two veins are observed, marked q, and even a third might be lettered, which is seen to be formed on the ulnar aspect; for much greater variety occurs in the veins than in the arteries of the arm. Some anatomists apply the term ulnar cutaneous to the branches of this vein from the hand to near the elbow-joint, and make an anterior and posterior, which unite near the elbow-joint and form the basilic vein.

The cephalic vein, r, collects the blood on the radial aspect of the back of the hand and the fore-arm, as seen in Plate XXI., and Fig. 2 of Plate XIX., inosculating freely with the basilic vein, q; ascends on the thenal or palmar aspect of the fore-arm like the basilic, and at the bend of the arm generally communicates with the basilic vein, and venæ comites; afterwards ascends on the radial aspect of the arm, running between the pectoralis major, c, and the deltoid, B, muscles; ultimately joining the axillary vein, *u*, near the point where it becomes the subclavian vein. Some authors limit the term cephalic to that portion of the vein between the elbow-joint and axillary vein; and name that between the elbow-joint and the back of the hand, the radial cutaneous veins.

The median vein, s,* Fig. 2, Plate XIX., collects the blood from the integuments, between the cephalic and basilic veins on the palmar or thenal aspect of the fore-arm, along which it runs to the bend of the arm, and divides into two branches, the one joining the basilic, and the other the cephalic, and named median cephalic, v, and median basilic, t, veins. In place of this arrangement, there is sometimes merely a communicating branch between the cephalic and basilic veins; indeed, as I have already mentioned, scarcely two arms correspond in the distribution of these veins.†

The radial and the ulnar arteries are observed in Plate XIX., Fig. 2, each to be accompanied by two veins, termed venæ comites, or satellites, which ultimately join the brachial vein, u; and in this course they are observed to communicate with the superficial veins at the bend of the arm.‡ The brachial vein, u, formed by these venæ comites of the radial, interosseal, and ulnar arteries, with the basilic and its median branch, ascends on the ulnar side of the brachial artery, h, to the axilla, where it assumes the name of axillary, receiving branches as it pursues this course; the axillary vein, *u*, then accompanies the axillary artery under the clavicle, and changes its name to subclavian, which is described in page 55. One of the radial satellite veins is seen to continue ascending on the radial side of the brachial artery, which it crosses near the axilla to join the axillary vein, *u;* and in this course forms a communication with the brachial vein, u, by a short transverse branch, a circumstance by no means of unfrequent occurrence.§ Besides these veins, there is observed one or two veins accompanying each of the different small branches of the artery of the arm; and where they join the brachial or axillary vein, two or more valves occur, similar to those represented in Plate XI., Fig. 3,

* Named also superficialis volæ.

† The course of the radial, ulnar, and interosseous arteries, should be well considered in relation to amputation of the fore-arm.

* Named also mediana longa, and mediana longa major.

† One of these veins, generally the median basilic, t, is commonly selected for phlebotomy; but here it is observed to be more than any of the other veins surrounded with nervous threads, while the median cephalic is the least: the former, however, from being the larger, is usually preferred, and hence nervous tumours sometimes result. It is the median basilic vein which is sometimes transfixed, and the brachial artery wounded, so as to form the venous aneurism, but more frequently the false aneurism.

‡ The junction of the venæ comites of the arteries with the superficial veins, accounts for the difficulty that frequently occurs in stemming the bleeding after phlebotomy; and why pressure below or distad to the wound does not arrest the stream of blood.

§ The communication of these veins forms a point of consideration for the surgeon when cutting down in order to secure the artery when wounded, or for aneurism.

or resembling the semilunar valves at the mouth of the aorta, or the pulmonary artery; several other valves are also seen along the course of the brachial vein, u, and more of these occur in the upper than in the lower extremities or the neck.

The axillary or brachial plexus of nerves, 1, described in page 50, divides above the clavicle, as seen in Plates XV., XVI., and XVII., marked with the digit 9, into several nerves, which, in their descent to the axilla, encircle the axillary artery, H,* uniting with each other; and when emerging from the axilla, they again separate into distinct nerves; some, however, take their origin above the clavicle, as the supra-scapular, the subscapular, and the thoracic nerves. The thoracic nerves are small twigs very variable in number, proceeding under the clavicle to the greater pectoral muscle, C, which, as well as the lesser pectoral, D, they supply, and afterwards pierce, to be distributed on the mammary gland and skin; one of these small nerves is seen in Plate XVII., descending parallel to the posterior external jugular vein, D, while two are observed in Plate XIX., Fig. 1, marked with the digits 7, descending in the axilla to the serratus magnus and latissimus dorsi, E. This is named the posterior thoracic, or the external respiratory nerve. The supra-scapular, or simply the scapular, 8, of Fig. 1, Plate XX., accompanies the supra-scapular artery, 51, supplying the supra-spinatus, infra-spinatus, teres minor, and subscapularis muscles. The subscapular or axillary nerves, usually three in number, descend into the axilla, the glands and skin of which they supply, and the subscapular, rhomboidei, and latissimus dorsi muscles; but the chief nerve accompanies the posterior circumflex artery, d, as seen in Figs. 1, Plates XIX. and XX., named the circumflex nerve, and supplies the teres minor and deltoid muscles, and also the skin covering the latter.

The nerves which descend on the arm, are the external cutaneous, 3, the internal cutaneous, 4, the median, 2, the ulnar, 5, the spiral, 6, and the cutaneous of Wrisberg, 9, as seen in Fig. 1, Plate XIX.

The internal cutaneous nerve, 4, situated very superficially, generally over the brachial vein, u, is seen to take its origin from the plexus in the axilla, and to descend on the brachial vein, u, giving off numerous nervous threads in its course to the bend of the arm, where its twigs twine in an elegant manner round the basilic vein, q, and its median branch, t, proceeding downwards on the ulnar aspect of the fore-arm to the ulnar aspect of the hand.† Near the elbow-joint it divides into two branches which pierce the fascia. The nervous threads which supply the skin, divide and meander in a most beautiful serpentine manner, and ultimately become so soft as to be incapable of dissection.

The cutaneous of Wrisberg, 9, a delicate nerve, descends on the internal or ulnar aspect of the arm, sometimes deriving its origin from the axillary plexus, sometimes from the ulnar nerve, and sometimes from one of the intercostal nerves of the thorax; for, as much irregularity and variation occur in the distribution of the axillary plexus of nerves, as in the veins of the arm, the student should therefore be prepared to find a different arrangement in each extremity he dissects. This cutaneous of Wrisberg I have confined to the continuation or branch of one of the intercostal nerves,* which is observed to descend on the triceps muscle, G, g, *g*, which it supplies in its course downwards to the elbow-joint, where it commonly unites with the ulnar and internal cutaneous nerves. Besides this nerve, other intercosto-humeral nerves, marked 9, are seen distributed on the axillary glands, *a*, the plexus of vessels, skin, and muscles, which have been described in page 39.

The external cutaneous nerve, 3,† pierces the coraco-brachialis muscle, K,‡ descends beneath the biceps muscle, L, resting on the brachieus internus muscle, and appears at the bend of the arm, on the radial margin of the biceps, where it pierces the fascia and becomes more cutaneous, and encircles the cephalic vein, r, which it accompanies down the fore-arm to the thumb. In this course it gives origin to twigs that supply the coraco-brachialis, the biceps, the brachieus internus the supinator radii longus, N, and the flexor carpi radialis muscles; twigs to the cephalic vein, and twigs to the integuments; and unites with the cutaneous twig of the spiral nerve.

The median nerve, 2,§ is observed to descend superficially on the brachial artery, h, to the bend of the arm, where it runs a little ulnad, and dips beneath the pronator radii teres, I, the flexor carpi radialis, P, the palmaris longus, *Q*, and the flexor digitorum sublimis, R, muscles; then descends between the latter and the flexor digitorum profundus muscle, W, to the carpus, running on the radial edge of the sublimis,‖ under the annular ligament, U, and dividing into twigs which, like the volar branches of the ulnar artery, descend between the metacarpal bones, and subdivide into a digito-radial and a digito-ulnar to each finger, beginning from the thumb to the ring finger, the latter of which has only its radial side supplied by this nerve, the ulnar being supplied by the ulnar nerve. These digital twigs run along the sides of the fingers to the tips or apices, and subdivide into most minute threads, which end in delicate pulpy points, and these, with the arteries, form a most beautiful arrangement for the seat of sensation.

The median nerve, in this course, gives origin to a number of twigs to the brachial artery and vein, to the different muscles already mentioned, to the flexor longus pollicis, X, the abductor pollicis, Y, the flexor brevis pollicis, Z, the flexor ossis metacarpi pollicis, 52, and the adductor pollicis, W, and also to the lumbricales muscles. Where the median nerve passes beneath or pierces the flexor muscles at the bend of the arm, it gives origin to a branch, 12, of some magnitude, named interosseal, which accompanies the anterior interosseous artery, p, and supplies the flexor longus pollicis muscle, X, the pronator quadratus muscle, 50, and the interosseous ligament, which it pierces near the carpus, and divides into several filaments on the back of the hand. The median nerve, close above the wrist-joint, sends off a branch which

* The axillary plexus of nerves embracing the axillary artery is one of the objections to attempting to secure the artery in this part when affected with aneurism.

† The course of these nervous threads and the basilic vein should be considered when dividing the fascia, l, of the biceps, in the event of matter being lodged beneath.

* Named also intercosto-humeral nerves.

† Also named the musculo-cutaneous, and perforans Casserii.

‡ The nerve is represented in the plate with a few scattered fibres of the coraco-brachialis muscle over it, in order that the course of the nerve might be seen.

§ Also named radial. The relation of this nerve to the artery should be considered when securing the latter.

‖ The course of the median nerve at this part should be considered with regard to its division, when any of its twigs distributed on the fingers are attacked with neuralgia.

descends superficially to the annular ligament and palmar fascia, supplying the skin of the palm of the hand. It is termed the cutaneous palmar branch. In the palm of the hand immediately distad to the annular ligament, U, the median nerve is observed to give origin to a twig that communicates with the ulnar nerve, 5; and as the digital twigs run along the sides of the fingers, they give origin to numerous threads.

The ulnar nerve, 5,* is observed to pass behind the axillary vein, *u*, and to descend on the two distal heads of the triceps muscle, g, *g*, to the inner condyle of the os brachii, on the anconal aspect of which it runs between the condyle and the olecranon of the ulna; and afterwards appears on the thenal or palmar aspect of the fore-arm, as seen in Figs. 2, Plates XIX. and XX., having pierced between the flexor carpi ulnaris, S, and the flexor digitorum sublimis, R, between which muscles it proceeds, resting on the flexor profundus, W, to the carpus, where it runs on the radial aspect of the pisiform bone, T, in company with the ulnar artery, *h*, and superficially to the annular ligament, U. In the palm of the hand the nerve divides into two volar branches, one of which subdivides like the median into a digito-ulnar of the ring-finger, and a digito-radial of the little finger; while the other volar branch subdivides into twigs that supply the ulnar side of the little finger and muscles of the same finger, as the abductor minimi digiti, 51, the flexor parvus minimi digiti, 52, and the adductor minimi digiti. From the palmar or volar portion of the nerve, a deep twig proceeds that generally pierces the adductor minimi digiti muscle, and supplies the deep volar arterial arch of the radial artery, *o*, the interossei and the lumbricales muscles, and sometimes the adductor pollicis muscle, *w*.

The ulnar nerve, in its course along the arm, generally gives origin to twigs that supply the skin, one of which commonly unites with the cutaneous nerve of Wrisberg, and to a twig which usually unites with the spiral nerve, 6; in its course along the fore-arm, the same nerve gives origin to a number of twigs that supply the flexor carpi ulnaris, S, the flexor digitorum sublimis, R, and the flexor digitorum profundus, W, muscles, also to twigs supplying the ulnar artery.†

Near the pronator quadratus muscle, 50, the ulnar nerve gives origin to its dorsal or anconal branch, 15, which descends beneath the flexor carpi ulnaris muscle, S, to the anconal or dorsal aspect of the hand, where, as seen in Plate XXI., it divides into a number of cutaneous threads, that extend to the fingers, supplying in their course the posterior portion of the annular ligament, U, the tendons of the extensor carpi ulnaris muscle, B, the extensor digitorum communis muscle, D; and uniting with each other, and also with the cutaneous threads, 46, of the spiral nerve.

The spiral nerve,* 6, Fig. 1, Plate XIX. emerges from the axilla beneath the axillary plexus of vessels, descends on the first, G, and second, g, heads of the triceps, and runs between the second, g, and third, *g*, heads, in company with the arteria profunda superior, f, around the os brachii to the outer or radial aspect of the arm, where, as seen in Plate XX., Fig. 1, it descends between the brachieus internus, M, and supinator radii longus, N, muscles, resting on the extensor carpi radialis longior, and the supinator radii brevis muscles. Here, as seen in Plate XX., Fig. 2, and Plate XIX., Fig. 2, the nerve divides into a cutaneous, 16, and deep branch, 26; the former, 16, passes near the radial artery, O,† on the radial aspect of which descending on the fore-arm to the distal third, it runs beneath the tendon of the supinator radii longus muscle, N, to its anconal edge, and after a short course subdivides into a thenal or palmar, 36, and an anconal or dorsal twig, marked 46; the former or thenal of the two latter, marked 36, descends on the radial margin of the fore-arm to the abductor muscle, Y, the flexor of the metacarpal bone, 52, and the integuments of the thumb; and the latter or anconal, marked 46, in Plate XXI., descends on the anconal or dorsal aspect of the thumb, fore-finger, middle finger, and half of the ring finger, supplying the extensors and integuments, and uniting with the twigs of the anconal branch, 15, of the ulnar nerve. The deep branch, 26, Fig. 2, Plate XX., of the first division pierces the supinator radii brevis to the anconal aspect, and supplies the supinators and extensors of the hand, and sends off a branch that descends on the anconal aspect of the interosseous ligament, which is named ramus interosseous posticus. At its emergence from the axilla, the spiral nerve gives origin to twigs supplying the triceps muscle and the skin; in its course between the second and third heads of the triceps, to twigs also supplying the muscle; and on its appearance at the radial aspect, gives off cutaneous twigs, some of which descend and supply the cephalic vein.

* Also named nervus cubitalis.

† The relation of the ulnar nerve to the ulnar artery should be considered when securing this vessel.

* Also named radial and spiral-muscular nerve.

† The relation of the cutaneous branch of the spiral nerve to the radial artery should be considered when cutting down to this artery when wounded.

BLOOD-VESSELS AND NERVES

OF

THE PELVIS AND LOWER EXTREMITY.

Plate XXII. represents a section of the male pelvis, A the symphysis pubis, B the sacrum bisected longitudinally, C the os coccygis, m the urinary bladder, *n* a catheter inserted into the urethra onwards to the bladder, the continuation of the instrument being represented by dotted lines, and w the ureter of the right side entering the bladder. The letters o are placed on the acceleratores urinæ muscles; p on the erector penis muscle of the left side, that of the right side being detached to bring into view the corpus cavernosum penis, X; q on the transversus perinei muscle of the left side, that of the right being truncated and marked q; r on the sphincter ani muscle surrounding the anus, I, the two other letters I being on the rectum; s, s, on the levator ani muscle, the right half being cut across to bring into view the prostate gland, t, and vesiculæ seminales, u. The letter Y indicates the gluteus maximus muscle, v the vas deferens, and the white line descending between the rectum, I, and the bladder, m, and afterwards ascending on the fundus of the latter to line the abdominal muscles, represents the peritoneum.

The internal pudic artery, *h*, seen in Plate XIV. to be a branch of the internal iliac, and described in page 45, is observed in Plate XXII., after its re-entrance into the pelvis, to ascend on the left side, on the tuber, G, and ramus ischii and pubis, between the obturator internus muscle and its fascia, behind the transversus perinei muscle, q, to the angle formed by the erector penis, p, and accelerator urinæ, o, muscles,* where it pierces the fascia and divides into the artery, 1, of the corpus spongiosum urethræ, the artery, 2, of the corpus cavernosum penis, and the arteria dorsalis penis, 3, which branches are distinctly seen on the right side, the trunk of the internal pudic artery, *h*, being cut off near this division. The arteria dorsalis penis, 3, considered as the continuation of the trunk, ascends on the ramus to the symphysis pubis, and turns suddenly on the atlantal surface of the penis, on which it runs onwards under the integuments to the glans, accompanied by its nerve, and separated from the artery and nerve of the opposite side by the vena dorsalis penis, 60, as seen in Plate XXIV. The branch, 2, supplying the corpus cavernosum penis, X, termed arteria corporis cavernosi, enters this body, and runs to its further extremity at the glans, giving off numerous twigs, some of which communicate through the septum with those of the artery of the opposite side, as represented by dotted lines in Plate XXII. The artery, 1, supplying the corpus spongiosum urethræ, named arteria corporis bulbosi, enters at the bulb which is immediately beneath the letter o on the right side.* Besides these branches, the internal pudic artery, within the pelvis, gives origin to small branches that supply the prostate gland, t, the vesiculæ seminalis, u, and the urinary bladder, m; and where it emerges out of the pelvis at the great sacro-ischiadic notch, D, Plate XXV., and winds round between the long sacro-ischiadic ligament, H, and the short ligament, this artery commonly sends small branches to the pyriformis, A, the obturator internus with the gemelli, X, and the gluteus maximus, F, muscles; also to the tuberosity of the ischium, Z, and the coccyx, C.

Where the artery re-enters the pelvis, as seen in Plate XXII., it gives origin to the external hemorrhoidal branch, *r*, that supplies the rectum, I, to branches supplying the levator, s, and sphincter ani, r, muscles, the cellular tissue that fills up the cavity between the rectum, I, and the tuberosity of the ischium, G; to a branch which is observed to run above the transversus perinei muscle, q, and afterwards to ascend on the accelerator urinæ muscle, o, denominated arteria transversalis perinei; to a branch named arteria perinei superficialis, which not unfrequently arises conjointly with the last, and takes at first nearly the same course, and ascends in the groove between the erector penis and the accelerator urinæ muscles, supplying the scrotum in the male and the labium in the female; to branches supplying the erector penis muscle, p, and to branches supplying the scrotum, Z, that anastomose with the spermatic artery, and the pudic branches of the femoral artery. All these branches of the pudic artery, though far from being regular, have had specific names given them, either from the importance of the objects they supply, or from the relation they have to operative surgery.

The internal pudic nerve, seen in Plate XIV., and described in page 45, is observed in Plate XXII. accompanying the internal pudic artery, *h*, and its branches, and its dorsal twig accompanying the dorsal branch, 3, of the artery, the further distribution of which latter is seen in Plate XXIV., where the nerve subdivides into small threads that supply the artery, vein, and integuments on the dorsum of the penis. In Plate XXII., its inferior

* The course of the internal pudic artery, along the ramus of the ischium and pubes, where, however, there is a strong protection of a dense aponeurosis, the obturator fascia should be considered by the surgeon in the lateral operation of lithotomy. No branches of the artery, excepting the transversalis perinei, and the external hemorrhoidal, should be wounded; and no muscles, excepting the transversus perinei and the levator ani, ought to be cut in this operation.

* This is the artery which is most liable to be wounded in the lateral operation of lithotomy, when the deeper incisions are made anterior and superior, or dermal and pubic, to the membranous portion of the urethra.

twig is observed supplying the erector penis muscle, p, the accelerator urinæ muscle, o, and the corpus spongiosum urethræ, advancing to the root of the glans, and ending in the prepuce. The internal pudic nerve unites with twigs of the anterior crural nerve.

The trunks of the internal pudic nerve and artery are observed attended by a vena comes, which ultimately re-enters the pelvis and joins the internal iliac vein, as seen in Plate XXV., where the course of the nerve out and into the pelvis is also seen. The vena dorsalis penis, or vena magna ipsius penis, 60, Plate XXIV., returns the blood circulated by the arteriæ dorsalis penis, 3, 3, runs in the groove between the corpora cavernosa penis, to the symphysis pubis, under which, continuing its course to the neck of the urinary bladder, it forms a plexus, as seen in Plate XXII., that ultimately concentrates and joins the internal iliac or hypogastric vein, x, Plate XIV., inosculating at the root of the penis with the internal pudic vein.

In Plate XXIV. the distribution of the spermatic artery, *g*, *g*, is observed on the spermatic cord, after its emergence at the inguinal canal; the commencement being described in page 41, and represented in Plate XIV. Within the abdominal cavity, or in the inguinal canal, the spermatic artery generally divides into two branches that descend on the spermatic cord, beneath the cremaster muscle, supplying the vas deferens, 1, the spermatic veins, and spermatic plexus of nerves, downwards to the epidydymis, *r*, and testis, r, entering the organ where the tunica vaginalis unites with the tunica albuginea; and in this course anastomosing with the spermatic branch of the epigastric, and with branches of the pudic arteries on the scrotum.

In Plate XXII. the ultimate distribution of the internal hemorrhoidal artery, *b*, the continuation of the inferior mesenteric artery, b, seen in Plate XIII. and described in page 40, is observed descending on the rectum, I, in company with the continuation of the inferior mesenteric plexus of the splanchnic nerves, described in page 43.

The truncated nerve, marked 4, which is observed to be distributed on the vesiculæ seminales, u, the prostate gland, t, the urinary bladder, m, and the levator ani muscle, s, is generally formed by the union of twigs from the third and fourth sacral nerves.

The distribution of the other branches of the internal iliac artery, mentioned in page 44 and seen in Plate XIV., is displayed in Plate XXV., with the exception of the obturator artery, which, as soon as it emerges from the pelvis at the thyroid foramen along with the obturator nerve, divides into small branches that supply the obturator externus muscle, the three heads of the triceps muscle, the quadratus femoris muscle, the capsular ligament and hip-joint, anastomosing with the internal circumflex, the ischiadic, and the internal pudic arteries.

The gluteal artery, *c*, is observed emerging at the great sacro-ischiadic notch, D,* along with the ischiadic, *f*, and internal pudic, *h*, arteries, the great sacro-ischiadic nerve, 20, and the pyriformis muscle, A; the arteries are accompanied by their corresponding veins. The gluteal artery immediately divides into several branches that supply the glutei muscles, as the maximus, F, the medius, I, and the minimus, with several other contiguous muscles; and these branches anastomose with the ischiadic, the external circumflex of the profunda femoris, the circumflex iliac, and the last of the lumbar arteries.

The ischiadic artery,* *f*, emerges from the pelvic cavity at the same notch with the gluteal, being separated by the pyriformis muscle, A, and like the latter, divides into several branches which supply the gluteus maximus and medius, the obturator internus with the gemelli, x, and the quadratus femoris, K, muscles, the great sacro-ischiadic nerve, 20, the long sacro-ischiadic ligament, H, the tuberosity of the os ischium, z, and the long head of the biceps flexor cruris, L, the semi-tendinosus, M, and the semi-membranosus, N, muscles, where they arise from this protuberance. The ischiadic artery inosculates with the obturator, internal pudic, gluteal, and internal circumflex branch of the profunda femoris, arteries.

The external iliac artery, T, of Plate XIV., is described to its emergence out of the abdomen, in page 43, and in Plate XXIII., is observed to run beneath Paupart's ligament, B, nearly in the centre between the os pubis, A, and the anterior superior spinous process of the os ilium, C, having the anterior crural nerve, 22, on its iliac side, and the femoral vein, U, on its pubic side,† and resting on the

* When the gluteal artery is wounded, the patient should be placed on his face, the limb extended, and the toes turned tibiad; a line then drawn from the posterior superior spinous process of the os ilium, b, downwards between the tuberosity of the os ischium, z, and the trochanter major of the os femoris, is to be divided into three proportional parts, when the operator may depend on finding the artery emerging out of the pelvis at one-third from the spinous process of the os ilium, and two from the centre of a transverse line extending between the mesial of the tuberosity of the os ischium, and the tibial edge of the trochanter major.

* Also named sciatic. When this artery is wounded, the same position of the patient and measurement as for the gluteal artery are required, with this difference, that the line should approach nearer the tuberosity of the ischium than the trochanter major of the os femoris, and should be divided into two, in place of three proportional parts, as the artery emerges out of the pelvis at the central point. Great care must be bestowed not to injure the great sacro-ischiadic nerve, 20.

† When the femoral artery requires to be secured in the groin, the patient should be placed on a low bed, sofa, or table, with the feet at right angles to each other, but the affected removed or separated from the sound limb. The space between the anterior superior spinous process of the os ilium, and the spine of the os pubis, is to be divided into ten proportional parts, when five and a half measured from the pubes, and four and a half from the ilium, will indicate the point where the artery emerges from the abdomen; which point therefore becomes the centre of an incision that is to be made through the skin and cellular tissue, in the course of the artery within and without the abdomen; calculating the course of the vessel, as described in p. 42. The deeper incisions, atlantad to Paupart's ligament, should not wound the external oblique, or any of the lateral muscles of the abdomen; but the tendinous expanse of the external oblique, or abdominal aponeurosis, should be separated from the fascia lata by a transverse incision, and held upwards by blunt hooks or spatulæ; the incisions distal to the ligament must extend through the fascia superficialis and fascia lata, the latter of which should be carefully cut, as the vessel lies immediately beneath or centrad. The knife ought to be lateralized with its cutting edge to the os ilium, in order to avoid the femoral vein; and for the same reason, the aneurism needle should be inserted between the vein and artery, and brought out between the artery and nerve. As small threads of the anterior crural nerve are frequently distributed on the artery, the latter should be divested of them before surrounding it with a ligature. Measurement is more valuable here than elsewhere; for there is no object like the first rib, or muscle like the scalenus anticus, to direct the operator, as in the operation for securing the subclavian artery: besides, the patient may be very fat, or the limb œdematous, the latter of which is a common occurrence in aneurism. Again, the femoral artery sometimes divides into two, sometimes into three equally sized branches, which descend parallel to each other for some extent down the limb. A lymphatic gland occasionally lies over the artery, which should be kept in view by the operator, as they generally become enlarged when situated over the vessel, in aneurism. In this view of the parts, Plate XXIII., the integuments and part of the fascia lata are merely removed,

psoas magnus and iliacus internus muscles. Here the artery assumes the name of femoral,* descends down the superior third of the thigh, and runs obliquely beneath the sartorius muscle, E, resting on the triceps muscle, *g*, g, G, which it pierces where the three heads form the tendon, near the distal third of the thigh, as seen in Plates XXIV. and XXV.

In this course the artery gives origin to several branches, apparently to the epigastric, X, and the circumflex iliac, *c*, seen in Plate XXIII., both of which, however, are considered to arise within the abdominal cavity. With regard to the origin of the epigastric artery, it is sometimes a branch of the profunda femoris; and I have seen the epigastric giving origin to the circumflex iliac artery. The epigastric artery is observed in Plate XXIII. to give origin to a branch, *x*, that descends in the inguinal canal, where it is represented by dotted lines, and divides into two small branches which run superficially on the spermatic cord, along the cremaster muscle, a, to the tunica vaginalis, b, of the testis; the scrotum, z, and the dartos, anastomosing with the branches of the spermatic and the internal pudic arteries. A number of small arterial branches named inguinal, or external pudic, are seen running across from the tibial side of the femoral artery to the lymphatic inguinal glands, letters *a*, and one marked *f*, named the superior external pudic, is observed to extend across the pubic portion, D, of the fascia lata, to the spermatic cord and scrotum, anastomosing with the branches of the epigastric, spermatic, and internal pudic arteries. The inferior external pudic artery proceeds to the scrotum of the male and labium of the female, and anastomoses with the superficial perineal branch of the internal pudic. The superficial epigastric artery emerges at the saphenic aperture of the fascia lata and ascends on the abdomen between the integuments and the abdominal aponeurosis, imbedded in the fascia superficialis. The superficial circumflex iliac artery ascends to the spine of the ilium under the integuments, and inosculates with branches of the deep circumflex iliac artery. All these are extremely irregular in number, origin, and distribution. Branches are observed to proceed from the opposite side of the femoral artery to the sartorius muscle, E; and the largest is termed the profunda femoris, C, seen only in Plate XXIV. The profunda generally branches off, as here delineated, but great irregularity exists; for I have already mentioned, that the common femoral sometimes divides into two branches on its emergence from the abdomen, and sometimes not until as far distad as its descent to the sartorius muscle.† In one instance, the superficial and deep femoral arteries ran parallel to each other from the groin to the tendon of the triceps, and then united to become popliteal.

In Plate XXIV. the profunda, C, branches off on the fibular aspect of the femoral artery, T; descends deep among the muscles behind and towards the outer side, or centrad and fibulad of the femoral artery, T, t, resting between the vastus internus, L, and the adductor brevis, *g*, muscles; pierces the triceps between this latter head and the adductor longus, g, close to the linea aspera of the os femoris; and appears on the popliteal aspect of the limb, distributing branches to the long head, L, of the biceps, the semi-tendinosus, M, and the semi-membranous, N, muscles, as seen in Plate XXV., and anastomosing with the ischiadic artery. By some, this continuation of the profunda artery is considered the long deep perforant.*

In this course the profunda gives origin to several branches, which are named the internal circumflex, d, the external circumflex, e, and the perforants.† The first, or internal circumflex,‡ d, is always present, but not always a branch of the profunda femoris; deriving its origin almost as frequently from the common femoral, and in

---

for the pubic portion, D, covering the pectinalis and triceps muscles is left, also that portion of the fascia covering the rectus femoris and vasti muscles. The parts therefore are not insulated, in order that the anatomy of aneurism of the femoral, the superficial femoral, and the popliteal arteries, may be displayed in a naturally connected manner.

* Also named crural artery, inguinal portion of crural artery, and common femoral artery.

† When the popliteal artery, T, of Plate XXV., is affected with aneurism, the superficial femoral artery, t, of Plate XXIV. is secured, in order that the vessel may be healthy enough to ensure adhesion, and because the artery is more easily reached. The position of the patient and the measurement are so far the same as those directed for securing the common femoral; the five and a half proportional parts from the spine of the os pubis are made the base of an equilateral triangle, which is to be constructed downwards on the thigh, the apex being therefore distal, the base proximal; and the outer or iliac side of this triangle should be extended downwards from the apex twice its length, when the artery will be found to run beneath this line throughout. But the difficulty, in a pathological point of view, is to calculate where the profunda branches off, for it is ascertained, that if an artery be tied too contiguous to a large branch, no clot of blood can form, as this fluid coagulates by its motion being impeded, and that no contraction of the artery can take place, its sides being kept distended with the blood from the impetus of the stream striking equally on both vessels; while, as we have mentioned in the text, great irregularity existing in the division of the common femoral, we can only endeavour to secure the artery as remote as possible from the groin, and as far as possible from the disease. An incision, therefore, should commence at the apex of the triangle, the point where the profunda commonly takes its origin, and be continued down the thigh proportionally to the depth of skin and cellular tissue of the patient; a second incision, equal in length to the first, should cut through the fascia lata, and this cautiously, when the pulsation of the artery will be felt; a few scratches with the scalpel will then denude the artery sufficiently to enable the operator to insert the aneurism needle between the vessel and the vein on the tibial side, and to carry it round the artery towards the fibular aspect. As one or two nervous twigs, one of which is the saphenus, run spirally along the artery at this part, as observed in Plates XXIII. and XXIV., care should be taken to exclude them; but if this be difficult to be accomplished, they should be cut across with the knife and forceps, and on no account included in the noose of the ligature. When the scalpel is employed to separate the artery and vein, which adhere in this region very closely by thick tough membrane, the cutting edge should be lateralized fibulad in order to avoid wounding the vein.

* This branch should be considered in relation to amputation of the thigh, as it is very regular in its direction.

† When amputation at the hip-joint is requisite, the patient should be placed on a low table, with his nates resting on the edge, and his toes turned inwards or tibiad, the limb being supported by an assistant. Another assistant is next to compress, with one thumb, the external iliac artery, as it emerges from the pelvis; then the operator, with his left hand, rotates the thigh inwards or tibiad, and enters the knife close above or atlantad to the trochanter major and carries it across the thigh, closely anterior or patellad to the head of the os femoris, and out near the scrotum, which with the penis must be kept aside by an assistant. The knife thus across is to cut slowly downwards or distad, to enable the assistant to insert his four fingers into the wound at its back, and by this means grasp the part to be made the flap, and compress more effectively the arteries. The operator now completes the flap. The assistant holding up this flap, the surgeon divides the fibrous capsule of the joint and its round ligament, and then depresses the limb, carrying the knife round both trochanters to the popliteal aspect, and sweeping obliquely downwards, makes a posterior flap. The operator first secures the superficial femoral artery; secondly, the branches of the profunda; thirdly, the obturator; lastly, the arteries of the lower surface, as the ischiadic and the gluteal.

‡ Also named circumflexa major.

some instances from the obturator artery. This circumflex branch descends with its concomitant vein behind the femoral vein, U, between the pectinalis, F, and psoas magnus and iliacus internus, W, muscles, to the capsular ligament, where it divides into several muscular branches that supply the commencement of the adductor magnus, G, the quadratus femoris, K, the gemelli with the obturator internus, X, the long head of the biceps, L, the semi-tendinosus, M, and the semi-membranosus, N, muscles, also the tuberosity of the ischium, Z, as seen in Plates XXIV. and XXV.; in this course the artery naturally gives origin to branches that are distributed on the psoas and iliacus internus, W, the pectineus, F, the adductor longus, g, the adductor brevis, *g*, and the obturator externus muscles; also on the scrotum, the capsular ligament, and the interior of the hip-joint. The internal circumflex artery anastomoses with branches of the different pudic, branches of the obturator, of the ischiadic, and the gluteal, arteries.

The external circumflex artery,* e, generally a conjoint branch with some of the perforants, runs on the vasti, L, O, and the crureus, P, muscles, beneath the rectus femoris, I, the tensor vaginæ femoris, K, and the gluteus medius muscles, where it anastomoses with a branch of the gluteal artery. In this course, branches proceed to the iliacus internus muscle, the gluteus minimus muscle, the trochanter major, anastomosing with the internal circumflex and perforating branches of the arteria profunda femoris.

The perforating branches of the profunda are merely the continuous trunk, as already described, with its branches, which are observed in Plate XXIV. descending on the muscles, as the rectus, I, the vastus externus, O, the crureus, P, the vastus internus, L, and the different heads of the triceps, G, g, *g*. Other and smaller branches are given off to the psoas magnus and iliacus internus, W, and the pectineus, F, muscles, and one to enter the medullary foramen of the bone.

I have hitherto been describing the femoral artery as continuous to the poples, which no doubt is the case; but as it either changes its name or actually divides into two branches, one of which, the profunda, has been detailed, we have now to consider the artery, from the point of its giving off the profunda, to the poples, as the superficial femoral artery.† The course of this artery, and its relation to surgery, have already been described; we have therefore only to consider its branches, which on examining Plates XXIII. and XXIV., are observed to be very few and small; and are merely muscular and cutaneous branches, with one, *a*, at its distal region, named the anastomoticus. The muscular branches are seen to be distributed on the sartorius, E, the vastus internus, L, and the gracilis, Q; and near where the anastomoticus, *a*, takes its origin, branches proceed to the biceps and vastus internus muscles, which are termed perforants. The anastomoticus, *a*, descends generally towards the patella, and branches out to supply the tendons and ligaments on the patellar aspect of the knee-joint, and the fascia of the leg.

The superficial femoral artery having pierced the tendon formed by the three heads of the triceps muscle, and running close round the os femoris, appears in the poples, assumes the name of popliteal, which artery, marked T, Plate XXV., descends deeply nearly in the centre of the ham, between the hamstring muscles, and between the condyles of the os femoris, also beneath and in the centre of the two outer heads, R, R, and the two inner heads, r, r, of the gastrocnemius muscle, to the distal margin of the popliteus muscle, V, where it divides into two large branches, the anterior tibial, *t*, and the posterior tibial, t, Plates XXVII. and XXVIII.*

In this course, the popliteal artery gives origin to several branches to the hamstring muscles, the gastrocnemii muscles, and the knee-joint, the latter of which are styled articular. Several branches are observed in Plate XXV. to proceed from each side of the artery to the semi-membranosus, N, the semi-tendinosus, M, the gracilis, Q, and the biceps, L, muscles, the short head of the latter of which is marked with a roman l. The other lateral branches are the articular, which are divided into two superior articular,† two inferior articular,‡ and an azygos articular, § the latter of which, however, takes its origin from the centre of the popliteal aspect of the vessel; but these are seldom, if ever, regular in their number, therefore I have not marked them: they run round and into the centre of the knee-joint, anastomosing with each other, with the anastomoticus and the perforating branches of the superficial femoral, and with the recurrent of the anterior tibial arteries, as seen in Plates XXIII. and XXIV., rendering the joint very vascular; which should be considered attentively by the practitioner in the diseases of this articulation. The superior articulars in this course give origin to branches that supply the vasti muscles, and the inferior articulars send branches to the popliteus, the gastrocnemius, and the tendons of the hamstring muscles. Between the superior and inferior articulars, branches, marked *a*, *a*, are observed to take their origin from the popliteal artery, and to descend on the outer heads, R, R, of the gastrocnemius, near the tendo-achillis, *r*, as seen in Plate XXVII., and are named rami gastrocnemii from their regularity.

In Plate XXVIII. the popliteal artery, T, is seen to divide into the anterior tibial, italic *t*, and the posterior tibial, roman t, the latter of which is considered the continuation of the trunk. The anterior tibial artery, *t*, is observed to run between the distal extremity of the popliteus muscle, V, and the tibial head, r, of the gastrocnemius muscle, where it passes through an aperture in the inter-

* Also named circumflexa minor.

† Named also the femoro-tibial portion of the crural artery.

* When the popliteal artery is wounded, the patient should be placed on his face, and the toes turned neither tibiad nor fibulad; and an incision proportional in length to the age and fatness of the individual, is then to be made in the centre between the two sides of the distal third of the thigh, through the skin and cellular substance, which is here very adipose and very abundant, and fills up this triangular cavity of the poples. The first incision may be bold, and will require to extend fully the distal third of the thigh; the second incision may be nearly equally bold, and should extend through the fascia and more of the cellular substance, when the popliteal nerve will present itself at the proximal part of the wound, where it runs more superficially or dermad; for at the distal portion the nerve lies a little outwards or fibulad. The operator now proceeds with more caution, lateralizing the knife tibiad, in order to avoid the vein that runs along the artery, a little fibulad proximad, but dermad in the distal portion; the vein and artery being denuded for a little space, the aneurism needle is inserted on the tibial aspect of the vein, between it and the artery, round the latter of which it is carried to the tibial aspect. An artery should be disturbed and insulated as little as possible. In Plate XXV. the drawing represents the limb in an oblique position, or the limb is placed in a tibio-popliteal attitude, to bring into view the different objects in the ham.

† Also named proximo-articulars.

‡ Termed also disto-articulars.

§ Also denominated arteria articularis media.

osseous ligament, and arrives at the anterior or patellar aspect of the leg, as seen in Plate XXVI.; here the artery is perceived to descend between the extensor longus digitorum pedis, B, and the tibialis anticus, A, muscles for a short distance, and then between the latter muscle and the extensor proprius pollicis pedis muscle, C,* to the tarsus, where the last muscle crosses the artery which continues to descend on the foot between the metatarsal bones of the great toe and the index toe, here named the dorsal artery, running beneath the extensor digitorum brevis muscle, E; lastly, the artery dips between these metatarsal bones, and descends into the sole of the foot to inosculate with the external plantar branch, *a*, of the posterior tibial artery, t.

Before the anterior tibial artery, *t*, leaves the popliteal aspect of the leg, it gives origin to numerous branches supplying the heads of the gastrocnemius and tibialis posticus, a, muscles, and the capsular ligament, those distributed on the latter inosculating with the azygos and the inferior articulars.

In the patellar aspect the artery sends off its recurrent, *d*, that ascends between the tibialis anticus, A, and the extensor digitorum longus, B, muscles, supplying them in its course to the knee-joint, nourishing the articulation, and inosculating with the inferior articulars; in the course of the artery to the tarsus, a number of branches are observed proceeding to the tibialis anticus, A, the extensor longus digitorum, B, and the extensor proprius pollicis pedis, G, muscles, some of them piercing the interosseous ligament to inosculate with the branches of the posterior tibial artery.

Where the artery runs beneath the annular ligament, D, two branches, C, C, take their origin, and are distributed around the malleoli, S, *s*, hence named malleolares: after emerging beyond the annular ligament, D, and running along the fibular edge of the extensor proprius pollicis muscle, C, three branches, marked with the letters e, are seen to take their origin, and to run across the foot, some superficially to the extensor digitorum brevis muscle, E, and others beneath it, forming arches somewhat similar to the arteries in the palm of the hand; from these irregular arches, branches proceed between the metatarsal bones, subdividing into digital branches, that supply the toes; while those which extend to the fibular aspect of the foot inosculate with branches of the external plantar artery. The artery that extends across the tarsus is named tarsea, and the one across the metatarsus, arteria metatarsea; but as these are very irregular, they do not seem entitled to so dignified appellations. Where the artery, *t*, is descending to the sole of the foot, between the metatarsal bone of the great toe and the index pedis, here named the arteria communicans, a branch, *f*, is observed to derive its origin, named arteria dorsalis hallucis, and to proceed onwards in the interstice between these toes, dividing into a branch supplying each toe, a digito-fibular of the great toe, and a digito-tibial of the index pedis.

The posterior tibial artery, t, Plates XXVIII. and XXVII., descends deep on the popliteal aspect of the leg, beneath the inner heads, *r*, *r*, of the gastrocnemius, and resting on the flexor longus digitorum pedis, O, or rather between it and the flexor pollicis longus, A,* downwards to the tarsus, where the artery divides into the internal or tibial plantar, *c*, and the external or fibular plantar, *a*, branches, both of which are observed to run beneath the abductor pollicis muscle, B; the internal, *c*, proceeding along its fibular margin, and dividing into several small branches, which extend to the great toe, the index, and the flexor brevis digitorum, C, supplying also several other muscles, tendons, and ligaments of the foot, and anastomosing with the external plantar branch and the anterior tibial artery.

The external plantar artery, *a*, considered the continuation of the posterior tibial, after running beneath the abductor pollicis, B, proceeds beneath the flexor brevis digitorum, C, to its fibular edge, along which it extends a short distance, and again crosses beneath the muscle to its tibial margin, and also beneath the tendons of the flexor longus with the lumbricales, dipping between the interosseous muscle of the middle toe and that of the index toe, to the interstice between the metatarsal bones of the index and pollex pedis, where it gives origin to a branch that unites with the anterior tibial artery, the trunk advancing to the great toe, and dividing into a digito-fibular of the great toe, and a digito-tibial of the index. From the irregular arch, represented by dotted lines in Plate XXVIII., thus formed by the external plantar artery, branches proceed like the volar in the palm of the hand, and subdivide at the partition of the toes into a digito-fibular and digito-tibial to each toe, which extend to the apices, and form a plexus similar to that of the fingers. In this course the external plantar artery is observed to give origin to branches supplying the os calcis, D, the plantar fascia, Y, the abductor pollicis, B, the flexor brevis digitorum, C, the abductor minimi digiti pedis, F, and the other muscles of the little toe, as well as those of the foot; and to anastomose with the internal plantar and anterior tibial artery.†

---

* When the anterior tibial artery becomes the seat of operation, the patient should be laid on a bed or table, with the foot resting on the heel, and the toes turned neither tibiad nor fibulad. An incision proportional to the part of the leg where the artery is to be secured, and to the age and muscularity of the individual, is then to be made through the skin, cellular tissue, and fascia, and between the tibialis anticus, A, and the extensor longus digitorum, B, if in the proximal third of the leg, and between the former muscle and the extensor proprius pollicis, C, if in the two distal thirds of the leg. The anterior tibial nerve, 28, first presents itself, which, being held aside, the aneurism needle may be introduced on either side of the artery, this vessel being previously separated from its two concomitant veins.

* When the posterior tibial artery is wounded in the distal third of the limb, the patient should be placed on his face, and the toes turned neither tibiad nor fibulad, but distad, to relax the muscles; an incision must then be made in the centre between the tibial edge of the gastrocnemius muscle, or rather the tendo-achillis, *r*, *r*, Plate XXVII., and the tibial angle, *q*, *q*, of the tibia, through the skin and cellular tissue, the second incision cautiously cutting through the fascia, investing the muscles and vessels; the artery will then be distinctly felt pulsating, and should be separated from its concomitant veins and the posterior tibial nerve, 22, which generally lies on its fibular side, either with the scalpel, its handle, the nail of the finger, or the aneurism needle, the latter of which ought to be introduced from the fibular aspect, between the nerve and artery, and brought out at the tibial aspect, leaving out, however, the venæ comites. When the artery is wounded in the two proximal thirds of the limb, the position of the patient should be the same, but the measurement must be between the same angle of the tibia and the mesial line of the popliteal aspect of the leg; an incision of considerable extent, in this centre, proportional to the muscularity of the patient, will then be requisite to be made through the skin, cellular substance, and the two tibial heads and bellies of the gastrocnemius muscle, when the artery will be felt pulsating. The same directions apply to the employment of the aneurism needle, as in securing the artery lower down.

† When either of the plantar arteries is wounded, it must be cut down upon and secured.

In the upper third of its course, the posterior tibial artery gives origin to the nutritious artery of the tibia, a branch of considerable size, which enters the foramen of the bone and supplies the medullary membrane.

Shortly after the commencement of the posterior tibial artery, t, a large branch, denominated the fibular or peroneal artery, y, is observed to derive its origin from the fibular aspect, and to descend beneath the fibres of the flexor longus pollicis muscle, A, downwards to the tarsus,* where it generally pierces the interosseous ligament, and supplies the ankle-joint, the malleoli, and tarsus; and in this course gives origin to the nutritious artery of the fibula, to several muscular branches, some to the flexor longus pollicis, A, the flexor longus digitorum pedis, o, the tibialis posticus, a, and the interosseous ligament, the latter of which they pierce to supply the muscles on the patellar aspect; others descend behind the external maleolus, s, and anastomose with branches of the external plantar artery.

Since irregularity as frequently exists in the distribution of these arteries as in those of the fore-arm, the student must not be surprised to find a different arrangement; I have seen several instances where the fibular artery pierced the interosseous ligament near the tarsus, and usurped the place of the anterior tibial artery, descending downwards on the patellar aspect of the foot to the great toe, the latter or anterior tibial artery being extremely small, and not descending so far as the point where the fibular first appeared on the patellar aspect.

The blood which is circulated by the common femoral artery and its branches, is returned by two sets of veins, a superficial and a deep seated, like those of the upper extremity.

The superficial veins of the lower extremity are two, the saphena major vein, *b*, Plates XXVI., XXVII., XXVIII., and XXIII., and the saphena minor, *z*, Plates XXVI. and XXVII. The saphena major or interna, *b*, Plate XXVI., commences on the patellar aspect of the foot, by small digital branches from the sides and interstices of the toes, where they unite with each other, and with the saphena minor, *z*, on the tarsus, forming small irregular arches; these branches concentrate into one or two trunks that ascend on the tibial aspect of the great toe, the tarsus,† and the leg, receiving smaller veins as they proceed, and inosculating freely with the lesser saphena, *z*, as seen in Plates XXVI. and XXVII.; at the knee-joint, the vein consists of one trunk, which ascends more tibiad and poplitead, as observed in Plates XXVI., XXV., and XXIII., round the articulation, and again appears on the tibio-patellar, or internal and anterior aspect of the thigh, ascending and receiving branches in its course to the groin, where it runs beneath some of the inguinal lymphatic glands, *a*, through the saphenic aperture, and joins the femoral vein, U, passing the iliac, K, and pubic portion, D, of the fascia lata, as seen in Plate XXIII.: the junction being more distinctly seen in Plate XXIV., where the saphena major, *b*, is truncated. Just before passing through the saphenic aperture, it is joined by the external epigastric, circumflex iliac, and pudic veins. The saphena runs throughout the whole of its course between the skin and the fascia of the limb.

The saphena minor or externa vein, *z*, Plate XXVI., commences on the fibular aspect of the foot near the little toe, inosculating with the saphena major vein, *b*, runs round the external malleoleus, s, to the popliteal aspect of the leg, and ascends on the tendo-achillis, *r*, and outer surface of the gastrocnemius, R, inosculating freely with the saphena major vein, as seen in Plate XXVII., to the poples, where it joins either the saphena major vein, *b*, the popliteal vein, U, or continues its ascent, as seen in Plate XXV., under the biceps, L, and semi-membranosus, N, muscles, and joins one of the venæ comites of the arteria profunda femoris, as was the case in this subject.* In rare occasions, the saphena minor proceeds upwards round the thigh, and joins the saphena major vein near the groin.

The posterior tibial and anterior tibial arteries are observed in Plates XXVIII., XXVI., and XXVII., to be accompanied each by two venæ satellites, which are formed by small venous branches that return the blood circulated by the divisions of these arteries; in their ascent to inosculate with each other over the arteries,† and to receive numerous veins from the muscles; the anterior tibial veins running through the aperture above the interosseous ligament along with the anterior tibial artery, but in a reverse direction, and joining the posterior tibial veins to form the popliteal vein, U, as seen in Plate XXVIII. The fibular artery is also accompanied by two veins, which join the posterior tibial veins, as observed in the same plate.

The popliteal vein, U, thus formed by these different concomitant veins of the arteries of the leg, ascends on the fibular and dermal, or outer and superficial aspect of the popliteal artery, T, of Plate XXVIII., receiving several venous branches from the outer heads, R, R, of the gastrocnemius muscle, and several articular and other veins in its course upwards, as observed in Plate XXV., to the proximal part of the poples; accompanies the popliteal artery through the triceps to the patellar aspect of the thigh, as seen in Plates XXV. and XXIV., and there assumes the name of femoral or crural vein, U, which ascends on the three heads of the triceps and pectineus muscles, keeping first on the popliteal or posterior, and then on the tibio-popliteal or inner and posterior aspect of the femoral artery, upwards to the parietes of the abdomen.

In its course along the thigh, the femoral vein is joined by numerous muscular branches; by the profunda, *c*, veins; the saphena major, *b*; the inguinal, and inguinal pudic veins, marked with the letters *f*, a vein from the integuments of the penis, marked, *e*, and by another from the integuments of the abdomen, marked *d*: this venous

* When the fibular artery is wounded, the position of the patient's limb is the same as that for securing the posterior tibial artery, and the vessel can only be taken up easily about the middle of the leg. An incision should be made along the fibular edge of the inner gastrocnemius or soleus, which must be pushed tibiad, while the tibial edge of the flexor longus pollicis is held fibulad; the artery will then be felt pulsating, and the aneurism needle may be passed round the vessel either from the fibular or tibial aspect; the venæ comites ought, if possible, to be separated, and not included in the ligature.

† Where the saphena major ascends on the tibial margin of the patellar aspect of the foot, phlebotomy is sometimes performed; and when the scarificator is employed, the operator must keep in view the course of the anterior tibial artery.

* The termination of the saphena minor in the popliteal vein is the most common.

† The union of the venæ comites superficially to the arteries in their course along the extremities should be kept in view when operating to secure these vessels.

trunk might be divided like the artery, into a superficial femoral, a deep femoral, and a common femoral vein.* The common femoral vein, U, as seen in Plates XXIII. and XXIV., runs on the inner or pubic aspect of the common femoral artery, T, under or sacrad to Poupart's ligament, B, and assumes the name of external iliac vein, seen in Plates XIV., XIII., and IX., and described in page 43.

The nerves of the lower extremity have already been partly described, page 45, and are represented in Plates XIII. and XIV.

In Plate XXIII. is observed the genito-crural or external spermatic nerve, marked 1, emerging at the external aperture of the inguinal canal, and accompanying the arterial branch, *x*, of the epigastric artery, x, downwards on the spermatic cord to the tunica vaginalis, b, of the testis, and giving origin to nervous threads, which are distributed on the scrotum, z, and the pubic portion, D, of the fascia lata, where they unite with twigs of the anterior crural nerve; the trunk of the nerve forming junctions with the spermatic plexus. The nervous twigs which accompany the inguinal pudic artery, f, and the inguinal pudic veins, *f*, derive their origin from the anterior crural nerve, 22, but sometimes from the lumbar plexus, and proceed to the scrotum and inside of the thigh, where they unite with the external spermatic, the internal spermatic, and the obturator nerves. The spermatic plexus of nerves, described in page 43, as deriving its origin from the superior mesenteric and renal plexuses, and represented in Plate XIII., accompanying the spermatic artery, is observed, in Plate XXIV., descending on the spermatic cord, in company with the branches of the spermatic artery, *g*, the veins and the vas deferens, 1, to the testis, r; supplying these objects in its course, and uniting with the twigs of the external spermatic, and the inguinal twigs of the anterior crural nerve. The nerve marked 3 is the inguino-cutaneous, descending out of the abdomen beneath Poupart's ligament, B, downwards to the iliac portion, K, K, of the fascia lata, to the knee-joint, dividing into numerous nervous threads in this course, that supply the fascia, the cellular tissue, and the skin.

22 Indicates the anterior crural nerve,† the origin of which has been described in page 45, emerging out of the abdomen beneath Poupart's ligament, B, on the iliac side of the femoral artery, T, and immediately dividing into a number of nervous twigs,‡ which are divided into a superficial and deep set; the superficial generally pierce the fascia lata a little below Poupart's ligament, and are observed descending on the sartorius muscle, E, and the fascia lata, K, downwards to the patella, Y, and the knee-joint; § some on the patellar and popliteal aspects of the femoral artery, T, t, supplying this vessel, the inguinal glands, *a*, the scrotum, Z, and the saphena major, *b*; ‖ the deep set consists of a multiplicity of twigs supplying the different muscles in the vicinity, as observed in this and in Plate XXIV., as the sartorius, E, the rectus femoris, I, the tensor vaginæ femoris, K, the vastus externus, O, the crureus, P, the vastus internus, L, the gracilis, Q, and the pectineus, F. What is termed the nervus saphenus is that twig of the anterior crural nerve that accompanies the vena saphena major, *b*, downwards in its course to the ankle-joint, as seen in Plate XXVI.; and which gives origin to another that descends spirally along the patellar angle, or shin, *a*, *a*, of the tibia to the integuments over the ankle-joint, uniting with cutaneous twigs of the peroneus superficialis nerve. Besides this individual nerve, there are several other twigs distributed on the saphena vein in the region of the thigh.

The obturator nerve, 21, the origin of which is described in page 45, divides into two branches, the anterior of which is only seen in Plate XXIV., emerging between the long head, g, and the short head, *g*, of the triceps muscle, and descending downwards near the knee-joint, supplying these heads and the great head, G, of the same muscle, the pectineus, F, the gracilis, Q, and the obturator muscles, and skin in the neighbourhood. The obturator artery accompanies this branch of the nerve for a short distance. The deep or posterior branch is separated from the anterior by the adductor brevis muscle, which it supplies, as also the adductor magnus and obturator externus muscles.

The cauda equina, 6, Plate XXII., is the continuation of the medullary globules of the four columns of the spinal marrow forming a leash of nerves encased in neurilema, which begin after the last pair of dorsal nerves take their origin, and in the sacrum are named sacral nerves, which, like the other spinal nerves, are arranged into anterior and posterior; the former being the larger, and forming chiefly the great sacro-ischiadic nerve; the latter the smaller, and distributed on the muscles and integuments of the nates. The foramina which transmit these nerves are seen in Plates III. and VIII. marked, *n*. In Plate XXV. several of the posterior nerves, marked with the digits, 2, are observed piercing the gluteus maximus, F, and the gluteus medius, I, near their origins, in order to supply the integuments; three of these are represented truncated.

The anterior sacral nerves have already been partly described in page 46. The superior gluteal nerve formed within the pelvis, from these or from the lumbo-sacral or communicating nerve, emerges at the upper part of the great sacro ischiadic notch, D, atlantal to the pyriformis muscle, A, and supplies the glutei muscles, the gluteal artery, *c*, and the integuments of the nates. The inferior gluteal nerve, now considered a branch of the lesser sciatic nerve, is similarly formed by the sacral plexus within the pelvis as the preceding nerve, issues out at the same notch below or distad to the pyriformis muscle, A, accompanying the ischiadic artery, *f*, and supplying the gluteus maximus, F,* and the integuments of the nates.

The lesser ischiadic nerve derives its origin from the lower part of the sacral plexus, emerges at the greater sacro-ischiadic notch, distad to the pyriformis, on the mesial side of the great sacro-ischiadic nerve, and divides into several branches, the chief of which is the inferior

* The popliteal vein and the superficial femoral vein adhere closely to their respective arteries by strong cellular membrane, points of consideration for the surgeon when securing either of the arteries.

† Named also simply the crural or femoral nerve.

‡ These twigs are absurdly named the lesser superior, the greater inferior, the cutaneous medius, the cutaneous anterior, the cutaneous internus, and the nervus saphenus.

§ The great distribution of nerves to the knee-joint should be considered by the practitioner in diseases of this articulation.

‖ The nerves which cross and run along the femoral artery should be kept in view by the operator when throwing a ligature round this vessel.

* This nerve, in the subject from which the drawing was taken, supplied chiefly the gluteus maximus muscle.

gluteal. Some supply the integuments in the vicinity, others descend to the poples.

The three superior sacral, with the two inferior lumbar nerves, form the great sacro-ischiadic nerve,* marked 20 in Plate XIV., that emerges from the pelvis at the greater sacro-ischiadic notch, D, Plate XXV., along with the pyriformis muscle, A, which frequently runs between its fasciculi, and descends between it and the gemellus superior, X,† beneath the gluteus maximus, F, and superficially to the gemelli and obturator internus muscles, X, poplitead to the quadratus femoris, K, and the great head, G, of the triceps, and beneath or centrad to the long head, L, of the biceps muscles, where it generally divides into the posterior tibial nerve, 23, and the peroneal or fibular nerve, 26. This division, however, sometimes occurs immediately where the great sacro-ischiadic nerve, 20, emerges from the pelvis, and sometimes not until it descends to the poples.

Before its division, the great sacro-ischiadic nerve gives origin to several muscular and cutaneous twigs; the former are distributed on the gemelli and obturator internus, X, the quadratus femoris, K, the long head, L, and short head, l, of the biceps, the semi-tendinosus, M, the semi-membranosus, N, and the great head, G, of the triceps; the latter, or cutaneous twigs, are marked 1 and 2; that marked 1, descending beneath or patellad to the long head, L, of the biceps, and poplitead or superficially to the semi-membranosus, N, muscles, downwards, sometimes as far distad as the knee-joint, is named the posterior cutaneous branch, and supplies the integuments in its vicinity, advancing sometimes the length of the scrotum and perineum; the other cutaneous branch, marked 2, termed the inferior posterior, descends beneath the gluteus maximus, F, superficially to the long head, L, of the biceps, and the fibular of the outer heads, R, of the gastrocnemius muscles, where it encircles the saphena minor vein, *z*, accompanying it downwards to the tendo-achillis, *r*, and in this course supplying the muscles already mentioned, and the quadratus femoris, K, the short head, l, of the biceps, the semi-tendinosus, M, the semi-membranosus, N, and the great head, G, of the triceps, also extensively ramified on the integuments, and uniting with the cutaneous twigs, 4, of the fibular nerve.

The posterior tibial nerve, 23,‡ the continuation of the ischiadic nerve, 20, descends into the poples, where it is named popliteal by some, a little to the outer or fibular aspect of the popliteal vein, U, and artery, T, between and beneath the two outer, R, R, and the two inner heads, r, r, of the gastrocnemius muscle, as seen in Plates XXV., XXVII., and XXVIII., and in the latter plate approaching the posterior tibial artery, t, with its venæ comites, continues to descend between the flexor pollicis, A, and the flexor longus digitorum, O, muscles, near the abductor pollicis muscle, B, where the nerve divides into the two plantar twigs, 24 and 25.

The external or fibular plantar nerve, 24, is observed in Plate XXVIII. to descend in company with the external plantar artery, *a*, beneath the abductor pollicis muscle, B, the flexor brevis digitorum, C, and to appear on the fibular margin of the latter muscle, dividing into volar twigs which subdivide into digital threads that supply the little toe and the fibular side of the fourth or ring toe; while other twigs proceed to the interossei and other muscles of these toes, the adductor pollicis, and the plantar fascia, Y, and integuments; the trunk of the nerve communicating with the internal plantar nerve, 25, and forming an irregular arch. In its course beneath the abductor pollicis, B, the external plantar nerve, 24, gives origin to twigs that supply this muscle, the flexor brevis digitorum, C, and the musculus accessorius ad flexorem digitorum longum.

The internal or tibial plantar nerve, 25, descends, accompanied by the internal plantar artery, *c*, beneath the abductor pollicis, B, to its fibular margin, and divides into volar twigs, which subdivide into digital threads that supply the great toe, the index toe, the middle toe, and the tibial side of the fourth or ring toe; the trunk of the internal uniting with the external plantar nerve, and sending twigs to the flexor brevis digitorum, C, the abductor pollicis, B, the flexor brevis pollicis, X, the adductor pollicis, the transversalis pedis, the lumbricales, and the interossei muscles. The distribution of these and the twigs of the external plantar nerve are also seen in Plate XXVII.

In the course of the trunk of the posterior tibial nerve, 23, in the poples, twigs derive their origin and proceed to the popliteal artery and vein, the tendons of the inner and outer hamstring muscles, the different heads of the gastrocnemius muscle, and the popliteus muscle; also a cutaneous twig arises and accompanies the gastrocnemial arteries.

In its course along the leg, twigs proceed from the nerve, 23, supplying the gastrocnemius internus, the flexor pollicis longus, A, the flexor longus digitorum, O, the tibialis posticus, a, and the posterior tibial artery, t, with its venæ comites; and near the os calcis, D, a branch is observed to be distributed on this bone and the contiguous parts.

The peroneal or fibular nerve, 26,* is observed in Plate XXV., on the tibio-popliteal margin of the long head, L, of the biceps muscle, to divide into two branches, 27 and 28; the former, marked 27, consists of the nervus communicans tibiæ, 4,† and the peroneus superficialis, 5; the latter, marked 28, is the nervus peroneus musculos adiens profundior, or the anterior tibial nerve. The first or the nervus communicans tibiæ, or the long posterior cutaneous twig, 4, is seen in Plate XXVII. to descend on the fibular of the two outer heads, R, of the gastrocnemius muscle, giving origin to twigs which communicate with the inferior gluteal nerve, 2, twigs that supply the saphena minor vein, *z*, and to twigs which run round the leg and communicate with the peroneus superficialis, 5, Plate XXVI.; the trunk running round the maleolus externus, S, and appearing on the patellar aspect of the foot, as observed in Plate XXVI., distributed on the fibular margin of the foot and toes, supplying chiefly the integuments, and uniting with the twigs of the peroneus superficialis, 5. The nervus communicans frequently derives its origin from the posterior tibial nerve in the poples, and descends superficially between the two outer heads of the gastrocnemius, and is joined by this branch of the peroneal nerve.

The peroneus superficialis nerve, 5, the chief portion of this nervous branch, 27, descends on the fibular of the

* Named also nervus ischiadicus and sciaticus.

† Both gemelli muscles and obturator internus are comprehended in the reference, X as they are intimately connected.

‡ Also named popliteus internus.

* Also named nervus popliteus externus.

† Termed also nervus cutaneous longus posterior tibiæ.

two outer heads, R, of the gastrocnemius muscle, as seen in Plate XXV.; and in Plate XXVIII., the nerve is observed to proceed to the head of the fibula, a little distad to which it pierces the peroneus longus muscle, and, as seen in Plate XXVI., emerges near the middle of the patellar aspect of the leg, between that muscle, marked F, and the extensor longus digitorum muscle, B. The nerve then descends superficially to the muscles and fascia of the leg, between the latter and the integuments, downwards to the toes, giving origin in this course to a number of twigs which supply the extensor muscles, as the extensor longus digitorum, B, and the extensor proprius pollicis, C, with the peronei muscles, F; twigs that supply the integuments; twigs to the great toe, the index toe, and the tibial side of the middle toe; and twigs which unite with the nervus communicans tibiæ, 4. The twigs distributed on the foot are sometimes named metatarsal.

The anterior tibial or interosseous nerve, or nervus peroneus musculos adiens profundior, 28, Plate XXV., is observed to commence high in the poples, and descend superficially to the fibular of the outer heads, R, of the gastrocnemius muscle, near the insertion of the biceps muscle, *l*; to pierce the peroneus longus muscle, and the extensor longus digitorum, B, Plate XXVI., and to appear on the patellar aspect of the leg, between the latter muscle and the tibialis anticus muscle, A, running superficially to the anterior tibial artery, *t*, with its concomitant veins, which it accompanies beneath the annular ligament, D, onwards to the great toe and the index pedis; and in this course giving origin to twigs that supply the biceps, the gastrocnemii, the peronei, the extensor longus digitorum, the tibialis anticus, the extensor proprius pollicis, the extensor brevis digitorum, E, and the interossei muscles, and the integuments; and uniting with the nervus communicans and the peroneus superficialis. The student must remember, that although the arrangement here adopted is one of the most common, yet as great irregularity occurs in the distribution of the nerves as of the arteries or veins.

THE DIAPHRAGM.

PLATE XXXII.*

VIEW OF THE DIAPHRAGM OF A MALE SUBJECT, ABOUT FORTY YEARS OF AGE.

1, 2, 3, 4, 5, First, second, third, fourth, and fifth lumbar vertebræ.
6, 7, 8, 9, 10, 11, 12, Cartilages of the sixth, seventh, eighth, ninth, tenth, eleventh, and twelfth ribs.
13, Ensiform cartilage.
14, The superior part of the anterior layer of the lumbar aponeurosis, sometimes termed the ligamentum arcuatum.
15, Central aponeurosis, middle portion.
16, Central aponeurosis, right portion.
17, Central aponeurosis, left portion.
18, Converging muscular fibres, arising from the ensiform cartilage.
19, Converging muscular fibres, which arise by digitations from the cartilages and anterior extremities of the six inferior ribs.
20, Converging muscular fibres, which obtain their origin from the upper part of the lumbar aponeurosis, named ligamentum arcuatum.
21, Right crus, which arises from the bodies of the three or four upper lumbar vertebræ, and the intervening fibro-cartilages; also from a fibrous band placed upon their outer border, named the ligamentum arcuatum proprium.
22, Fibres of the right crus, proceeding to be inserted into the central aponeurosis.
23, The internal fibres of the right crus, passing obliquely to the left, to their insertion in the central aponeurosis.
24, Left crus, arising from the bodies of the two or three upper lumbar vertebræ, the intervening fibro-cartilages, and the ligamentum arcuatum proprium.
25, Fibres of the left crus, which are inserted into the central aponeurosis.
26, The internal fibres of the left crus, crossing to the right, decussating with the corresponding fibres of the right crus, and inserted into the central aponeurosis.
27, The venous aperture, traversed by the inferior vena cava, and one or two delicate filaments of the phrenic nerve.
28, The œsophageal aperture, which affords a passage to the œsophagus or gullet, the two pneumogastric nerves, and some small arteries and veins.
29, The aortic aperture, through which there pass the aorta, the vena azygos, and the thoracic duct.
30, The sacrum.
31, The coccyx.

The Diaphragm is a large flat muscle placed at the superior part of the abdomen; and forming a septum betwixt that cavity and the thorax. In form it somewhat resembles a fan, being broad, thin, flat, and circular, and presenting two limbs at its posterior and inferior part. After death, and when passive during life, it is convex towards the thorax and concave towards the abdomen; the concavity being greater on the right side than on the left, from the position of the liver.

It is composed of two portions, the aponeurotic and muscular; and the latter is divided into three sets of fibres,—the converging, the right crus, and the left crus.

THE CENTRAL APONEUROSIS OF THE DIAPHRAGM.
(15, 16, 17.)

This aponeurosis, situated in the centre of the muscle, is composed of fibres crossing in almost every direction: it has the form of a trefoil leaf, and is accordingly divided into three portions, a central and two lateral; of these the central is the largest and the left the smallest: this division, however, is apparent only in front; behind they are united, and form a concave border directed to the spine. Between the right lateral and central portions, a large aperture of a square form is placed.

THE CONVERGING MUSCULAR FIBRES OF THE DIAPHRAGM.
(18, 19, 20.)

The converging fibres extend from the circumference of the base of the thorax to the central aponeurosis. They arise from the following parts:—1, from the posterior surface of the ensiform cartilage; 2, from the cartilages and anterior extremities of the six inferior ribs by digitations; and 3, from the upper part of the anterior layer of the lumbar aponeurosis, which has received the name of ligamentum arcuatum, in consequence of the fibres, which stretch from the transverse process of the first lumbar vertebra to the lower border of the twelfth rib, having an arched appearance. From these different points of attachment, the fibres slightly curved ascend in a converging manner to the central aponeurosis, into the circumference of which they are inserted; in this progress the anterior fibres proceed upwards and backwards, the posterior upwards and forwards, the lateral upwards and inwards, and the rest with different degrees of obliquity according as they approach the others.

THE RIGHT CRUS OF THE DIAPHRAGM.
(21, 22, 23.)

This is an elongated bundle of muscular fibres, broad above, narrow and pointed below, and placed upon the anterior and lateral aspect of the lumbar vertebræ. It arises tendinous from the bodies of the three or four upper lumbar vertebræ, the intervening fibro-cartilages, and from a fibrous band, termed ligamentum arcuatum proprium, which extends from the body of the second to the transverse process of the first lumbar vertebra. Ascending, the fibres divide opposite the first lumbar vertebra into two sets;—1st, the external, which proceed upwards and forwards to the central aponeurosis,—and, 2d, the internal, which run obliquely to the left, decussate with the corresponding fibres of the left crus, and, passing forwards, are inserted into the central aponeurosis.

THE LEFT CRUS OF THE DIAPHRAGM.
(24, 25, 26.)

This bundle is similar to the last, but somewhat smaller,

and inclines more to the lateral aspect of the bodies of the lumbar vertebræ. Obtaining its origin by tendinous fibres from the bodies of the two or three upper lumbar vertebræ, the intermediate fibro-cartilages, and the ligamentum arcuatum proprium, it ascends, and separates opposite the first lumbar vertebra into two portions, an external and an internal, of which the external, passing upwards and forwards, is inserted into the central aponeurosis, and the internal having decussated with the corresponding fibres of the right crus, proceeds obliquely upwards and forwards to the central aponeurosis, into which it is also inserted.

By this arrangement of the internal fibres of the crura, two apertures are formed; a posterior for the aorta (aortic), in front of which the other is placed for the œsophagus (œsophageal).

APERTURES OF THE DIAPHRAGM.

The foramina of the diaphragm are three:—the venous, the aortic, and the œsophageal.

The Venous Aperture (27), situated between the middle and right lateral portions of the central aponeurosis, is of a square form, and affords a passage to the inferior vena cava, and some minute twigs of the phrenic nerve. The external coat of the vein is intimately united to the margin of the aperture.

The Aortic Aperture (29), for the transmission of the aorta, is placed between the crura and in front of the spine, inclining a little to the left: it is much elongated, and rather a canal than an aperture; its boundaries are, posteriorly, the vertebral column; on the right side, the right crus; on the left side, the left crus; and, anteriorly, the decussation of the fibres of the crura: the margin of its anterior and lateral boundaries is formed by tendinous fibres, by which pressure on the vessels which traverse it, is prevented. Besides the aorta, it affords a passage to the vena azygos and thoracic duct.

The Œsophageal Aperture (28) lies anterior to the preceding; it has an elliptical shape, and is formed by the fibres of the crura. It transmits the œsophagus, the two pneumogastric nerves, and some small branches of the gastric artery and vein.

In addition to the objects mentioned, the following nerves and blood-vessels pass through the diaphragm:—1, the communicating branch between the eleventh dorsal and first lumbar ganglion (or sympathetic nerve) runs under the ligamentum arcuatum proprium;—2, the great splanchnic nerves traverse the crura, anterior and internal to the preceding;—3, the small splanchnic nerves also pierce the fibres of the crura a little external to the great;—4, minute twigs of the phrenic nerve pass through the central aponeurosis and converging fibres;—5, the abdominal branch of the internal mammary of each side traverses the space posterior and to the side of the ensiform cartilage, where the muscular fibres are deficient.

RELATIONS OF THE DIAPHRAGM.

Besides the objects which traverse it, the diaphragm has other relations of considerable importance, which may be arranged in the following order:—

The superior or thoracic surface is related in the middle to the three mediastina and pericardium,—laterally, to the pleura and lungs. *The inferior or abdominal surface* is in relation to the peritoneum, the coronary and lateral ligaments of the liver, the stomach, liver, spleen, and kidneys. *The anterior surfaces of the crura* are covered by the stomach, duodenum, pancreas, supra-renal capsules, semilunar ganglia, and great solar plexus of nerves; the hepatic, splenic, and renal arteries; the renal and splenic veins, vena portæ, and inferior vena cava. *The posterior surfaces of the crura* are related to the vertebral column and intervertebral fibro-cartilages. *The circumference of the converging fibres* is in connexion with the ensiform cartilage, the triangularis sterni muscle, the ribs, the internal intercostal, transversus abdominis, quadratus lumborum, and psoas muscles.

NERVES AND VESSELS OF THE DIAPHRAGM.

The nerves of the diaphragm are derived from the phrenic of the cervical plexus, the twelfth dorsal, and the diaphragmatic plexus of the great solar. It is nourished by the following arteries:—the superior diaphragmatic and musculo-phrenic branches of the internal mammary; the inferior diaphragmatic and lumbars of the abdominal aorta; and branches from the inferior intercostals. The veins accompanying the preceding arteries terminate in the corresponding venous trunks; the principal are the two inferior diaphragmatic, which end in the inferior vena cava. The absorbents join the mediastinal glands and the thoracic duct.

FUNCTIONS OF THE DIAPHRAGM.

When the fibres of this extensive muscle are fixed at their origin, and contract, instead of being curved, they become straight; hence the diaphragm descends, and assumes the form of an elevated portion in the centre (formed by the central aponeurosis), surrounded on all sides by inclined planes formed by the muscular fibres; the thorax is thus increased in size from above downwards, and the muscle is one of inspiration. In relaxing it ascends to its former situation, regains its convex form in the thorax, and diminishing that cavity, contributes to expiration; in this last being passive: but some anatomists suppose that it assists in this function by the contraction of the fibres connected with the ribs; for which purpose the fibres will take their fixed point at the central aponeurosis, and drawing the ribs inwards, will diminish the cavity. The diaphragm is also employed in sighing, yawning, sneezing, coughing, laughing, and in hiccup.

In addition to the functions now mentioned, which refer to the thorax, the diaphragm discharges others connected with the abdomen: in descending, it pushes the various organs contained in that cavity downwards and forwards; and as, by its relaxation, they return to their former position, the progress of the food along the alimentary canal, and the functions of all the organs, are more or less promoted by this continual agitation. When it contracts at the same time with the muscles in the anterior abdominal region, it assists in vomiting, and in the expulsion of the feces, urine, and fetus.

THE

MUSCLES OF THE ABDOMEN.

PLATES XXIX., XXX., XXXI.

In Plate XXIX., on the left side of the subject, the integuments and the fascia superficialis* are removed; while on the right side, the conjoint tendons of the external and internal oblique muscles, now improperly named the abdominal aponeurosis,† are cut open, to bring into view the rectus abdominis, R, and pyramidalis, T, muscles.

The musculus obliquus externus abdominis,* marked with the letters, F, f, and situated in the lateral and anterior aspects of the abdominal cavity, is rather a thin, than

* The fascia superficialis is merely the condensed cellular membrane between the skin and the external oblique muscle, and should not be taken into consideration by the operator in strangulated hernia, since in nine cases out of ten it is so thin as not to be perceptible. In one case of strangulated congenital inguinal hernia, where the patient was upwards of thirty years of age, and on whom I operated, I expected to find this fascia thickened and distinct, but no vestige of it was to be seen. For further information on this subject, consult Monro's Observations on Crural Hernia. The fascia superficialis is supposed to direct the viscera protruding at the crural aperture, upwards or atlantad on the external oblique muscle; but this opinion is incorrect, as the fascia adheres to Poupart's ligament, and is therefore superior or atlantad to the crural aperture, and consequently must prevent rather than facilitate the ascent of the tumour. The reason of the viscera ascending, appears in consequence of the smallness of the aperture, the unyielding nature of the ligaments forming the foramen, and the manner in which the small intestines are bridled to the mesentery.

† I have applied the term *improper* to the modern name and description of this aponeurosis, because it is liable to mislead the student and the young practitioner in their views of the action of these tendons in herniæ. It is thus described:—" This aponeurosis is a broad, thin, and extensive membrane, of a shining and pearly white colour, occupying the middle of this region; commencing superiorly, it extends across from the outer border of the cartilage of the fifth rib on the one side, to the corresponding part on the opposite; whence descending, it so increases in width as to extend between the anterior superior spines of the ilia, below which it again diminishes to the breadth of the bodies of the pubes. Supporting the contents of the abdomen, it has numerous attachments; and various parts having been discovered at different times, have received particular names: it has also many apertures; and forming a sheath for the rectus muscle, besides giving origin and insertion to others, it is divided into different laminæ.

" Attachments. Superiorly, the ensiform cartilage, and the cartilages of the fifth, sixth, and seventh ribs of each side—Inferiorly, the symphysis, superior border, and spine of the pubes, about half an inch of the linea innominata immediately external to the last, the anterior superior spine of the ilium, and a small part of its crest contiguous to the last attachment,—Laterally, the external oblique, internal oblique, and transversales muscles.

" Names of Particular Parts. Linea alba—Lineæ semilunares—Lineæ transversæ—Crural arch, comprising Poupart's ligament and Gimbernat's ligament—Intercolumnar fascia.

" *The Linea Alba* is the middle part of the aponeurosis; it has the form of a white band, extending from the ensiform cartilage to the symphysis pubis. This appearance is caused by the dark fibres of the recti muscles shining through the aponeurosis, but leaving an interval between them occupied solely by the white fibres.

" *The Lineæ Semilunares* are two white lines of a semilunar form, distinguished into a right and left, and situated a short way external to the linea alba. They are bounded externally by the three lateral muscles, comprising the external oblique, internal oblique, and transversalis, and internally by the rectus.

" *The Lineæ Transversæ* are transverse lines which intersect the fibres of the recti muscles; they are usually four in number upon each side, and occupy the following situations:—one is, generally, found opposite the umbilicus; a second, a little below the level of the ensiform cartilage; a third, between these two; and the fourth, when present, is below the umbilicus.

" *The Crural Arch* is the name given to the inferior border of the aponeurosis, which proceeding from the pubes to the os innominatum of each side, thus forms an arch, beneath which various important parts pass. It is attached to three points: 1, to the anterior superior spine of the ilium; 2, to the spine of the pubes; and, 3, to about half an inch of the linea innominata, external to the last point. The fibres connected with the two first parts form Poupart's ligament, and those united to the third, Gimbernat's ligament.

" *The Intercolumnar Fascia* is a name applied to a few fibres arranged in a semilunar direction, their concavity looking upwards and outwards, situated a little superior and external to the spine of the pubes of each side.

" Apertures. Umbilicus—The two external apertures of the inguinal canals—Small apertures for nerves and vessels.

" *The Umbilicus* or navel, placed in the centre of the region, is the remains of an aperture which, in the fœtus, afforded a passage to certain vessels.

" *The External Apertures of the Inguinal Canals* are situated immediately superior and external to the spines of the pubes.

" Layers and Sheath of the Rectus. In the mesial line, the aponeurosis is composed of one layer (the linea alba); but, external to this, in order to enclose the recti muscles, it separates on each side into two, the one proceeding before, and the other behind the muscle; at the outer border of which they again unite, complete the sheath, and form a single layer, which gives attachment to the internal oblique muscle. From the anterior part of the sheath so formed a layer comes off for the external oblique muscle, and from the posterior part another for the transversalis muscle. The layers of the aponeurosis, therefore, may be arranged thus:—in the mesial line there is one layer,—external to this and formed by its separation, there are two, the one situated before, and the other behind the rectus,—and as each of these divides still more externally, there are four layers produced; at the outer border of the rectus the two middle of the preceding layers join, and thus form three, distinguished into an anterior, middle, and posterior.

" At the superior part there are two layers, an anterior before, and a posterior behind the rectus; the former is for the external oblique, and the latter for the transversalis muscle—Inferiorly there are two layers, an anterior and a posterior, the former affords attachment to the external oblique, and the latter to the internal oblique and transversalis muscles: both layers are situated in front of the rectus; so that, at the inferior part, the sheath of the rectus is deficient posteriorly." See *Text-Book of Anatomy for Junior Students*, by Alexander Jardine Lizars, M. D.

* Syn. Oblique descendens; obliquus descendens; obliquus externus; obliquus descendens seu exterior; obliquus descendens externus; obliquus major; grand oblique abdominal; ilio-pubi-costo-abdominal; costo-abdominal.

a thick fleshy muscle in its carneous portion, and has a delicate tendinous expanse superiorly or atlantad, but a strong and dense one inferiorly or sacrad, in its tendinous portion.

This muscle derives its origin from the seven or eight inferior ribs near their cartilages, by the same number of fleshy slips, marked with the letters F, which are at first tendinous, and intermingle with the pectoralis major muscle, C, with the digitations of the serratus magnus muscle, letters O, with those of the latissimus dorsi muscle, letters E, and with the external intercostal muscles situated beneath, as seen in Plate XXX., marked with the letters Z. These fleshy fibres diverge and descend obliquely forwards or mesiad, and downwards or sacrad, till they arrive at the outer or lateral margin of the rectus muscle, R, r; where becoming tendinous, they are marked f, and continue their course over or superficially to the latter muscle, and uniting with the expansive tendon of the internal oblique, marked with the letters g, Plate XXX., proceed onwards to the central or mesial line, letters *f*, of the abdomen, where they interlace with the tendinous fibres of the external oblique and the other two lateral muscles of the opposite side, forming what is named the linea alba, *f*. At the crista of the os pubis, the tendinous fibres cross those of the opposite muscle, to be inserted into the os pubis of the right side; while the fibres of this part are also inserted strongly into the crista, and particularly into the spine of the os pubis of the left side. From this point outwards or iliad, the tendinous fibres, B, are observed to be intimately connected with the iliac portion of the fascia lata, K, and still further iliad to be inserted, partly tendinous, and partly fleshy, into the crista, S, of the os ilium, occupying its two anterior or sternal thirds; the last portion of the muscle descends nearly in a perpendicular line.*

The superior digitation is remarkably delicate both in its carneous and tendinous portions, and is very liable to be removed by the dissector, unless he proceeds with caution; the tendinous fibres are connected with the ensiform cartilage, and interlaced with those of the pectoralis major of the opposite side; and they are so translucent, that the fibres of the rectus muscle shine through. As the digitations descend to the last rib, both the carneous and tendinous portions become thicker. They are irregular in number; sometimes there are seven digitations, sometimes eight or even nine, and this last occasionally takes its origin from the transverse process of the first lumbar vertebra; the ninth, however, is sometimes the first digitation, deriving its origin from the fourth rib. These digitations are occasionally cleft in two.

Where the fleshy fibres become tendinous at the lateral margin of the rectus muscle, they contribute to form what is named the linea semilunaris, marked with the letters f, which is merely the white line of this shape, formed by the three lateral muscles of the abdomen on becoming tendinous at this margin of the rectus muscle. Nearly in the centre of the linea alba, is observed the umbilicus, U, an aperture that transmitted the umbilical cord in the fetus, which is seen in Plate X., Fig. 6, marked, g, *n*, *n*; here the tendinous fibres cross each other, so as to compress the umbilical cord after birth, and prevent not only hemorrhage, but also shut up the aperture in after life, and prevent umbilical hernia from occurring. Near the pubes another aperture is observable, named the external of the inguinal canal, which in the female transmits the round ligament of the uterus, see Plates IX. and XIII. letters *l*; and in the male the spermatic cord, see Plates XXII., letters g, XXIII., letters a, x, XXIV., letters *g*, and in this Plate marked a. Here the tendinous fibres separate into two portions, a superior and an inferior, the superior, marked 1, assumes the name of the upper pillar; and the inferior, marked, 2 the name of the lower pillar, of the external aperture of the inguinal canal. This foramen is beautifully strengthened by transverse tendinous fibres, named the intercolumnar fascia, which prevent the frequent occurrence of rupture.* These lower fibres are seen in Plate XXX., marked with the digit 3, to be inserted not only into the spine of the os pubis, but into the linea-ilio-pectinea contiguous, and into the pubic portion, D, of the fascia lata, and are improperly designated a ligament, which is named after Gimbernat.†

Where the fibres are inserted into the symphysis pubis, they give origin to tendinous fibres, that form the suspensory ligament of the penis, marked, 70, seen also in Plate XXIII. Where the tendinous fibres, marked, B, are inserted into or incorporated with the iliac portion, K, of the fascia lata, they are ‡ absurdly named Fallopius or Poupart's ligament, or crural arch. Where the posterior fibres descend from the last rib to the crista of the os ilium, they are overlapped by the latissimus dorsi muscle, E, as distinctly seen in Plate XXXIII. Throughout the tendinous expanse of the muscle, fissures or apertures are observable, which in some instances permit the viscera of the abdomen to protrude and form ventral rupture.

The external oblique muscle is concerned in the functions of respiration and digestion, in propelling the food

* The modern description is the reverse of this; the insertion being assumed to be the origin, and the origin the insertion.

* The rupture which takes place at this aperture either in the male or female is named inguinal; and when the viscera descend in the male into the scrotum, it is termed scrotal hernia.

† The situation and shape of this portion should be considered in relation to crural hernia, for the iliac margin forms more than two-thirds of the femoral or crural aperture through which the viscera protrude in this disease. This foramen will be more clearly defined afterwards. When the viscera become strangulated at this aperture, the division of Gimbernat's ligament, 3, Plate XXX, affords more relaxation, and is safer than the division of any other tendon or ligament. In the performance of this, a probe-pointed straight bistoury should be inserted between the viscera and ligament, with the back of the knife to the former, and the cutting edge to the latter or ligament, and carried horizontally towards the os pubis. The bistoury should be inserted to the least possible extent, in order to guard against wounding the obturator artery, when this vessel is a branch of the epigastric, a circumstance equally as common as it is a branch of the internal iliac. Here the operator must be aware that the herniary or peritoneal sac is divided at the same time with this ligament. When the division is accomplished, the limb of the affected side of the patient should be brought near the abdomen, and the knee turned inwards or tibiad; and the trunk ought to be bent on the limbs, so as to relax the tendon of the external oblique, and the fascia lata. The same directions as to the position of the limb and trunk are to be observed before an operation is performed: in either case, the viscera should be pushed directly into the abdomen, being careful to return that portion first which was the last in protruding. In the taxis, the tumour must be pressed first downwards or centrad, then upwards or atlantad, so as to push the intestine round and beneath Poupart's ligament. The viscera sometimes descend in the cellular sheath of the crural vessels.

‡ I have applied such an epithet to this ligament, as there is nothing more than the condensed tendinous fibres of the external oblique muscle, which are influenced in every motion of this muscle, and in every motion of the anterior part of the thigh; and because the nature of a ligament is liable to mislead the practitioner in the operation of the taxis in strangulated hernia, or in that of reduction after the stricture has been laid open.

onwards in the intestinal canal, in the expulsion of the feces and urine, in the propulsion of the fetus in parturition; and also in inverted functions, as in vomiting. When the thorax is a fixed point, and when one muscle acts, the pelvis will be elevated obliquely upwards: and when both muscles act, they will pull the pelvis directly upwards. When the pelvis becomes fixed, both muscles will bend the thorax downwards as in stooping; and when only the one muscle acts, it will inflect the thorax obliquely downwards. Besides these general motions, each digitation may be thrown into action, and the inferior portion of the tendon will produce tenseness in the fascia lata.

In Plate XXX., the external oblique muscle of the left side is removed, excepting where its tendon, f, is incorporated with the tendon, letters g, of the internal oblique muscle, G, and where its tendon assumes the name of Gimbernat's ligament, 3. On the right side, the pyramidalis muscle is removed, and the rectus muscle, R, nearly all detached.

The musculus obliquus internus abdominis of the left side, G, g, g, g,* is situated in the lateral and anterior aspect of the abdomen, derives its origin fleshy from that portion of the tendon of the external oblique which is attached to the iliac portion, K, of the fascia lata, or rather from the junction or angle formed by both;† tendinous and fleshy, from the crista, S, of the os ilium; and tendinous from the fascia lumborum, as seen in Plate XXXIII.,‡ or from the transverse processes of the lumbar vertebræ. The fibres radiating from this extent of origin upwards, forwards, and downwards, are inserted fleshy into the three lowest, and tendinous into the four contiguous ribs, letters A; the whole of the muscle becoming tendinous at the linea semilunaris, letters g, divides into two expansive layers, which enveloping the rectus muscle, R, advance onwards to join the muscles of the opposite side, so as to assist in the formation of the linea alba, letters *f*.

On this left side, the anterior or superficial tendinous layer, letters g, is observed to be incorporated with the tendon, f, of the external oblique muscle; while on the right side, the posterior or deep tendinous layer, letters *g*, is seen incorporated with the transversalis muscle from the ribs downwards, or sacrad to the umbilicus, U; but more sacrad, there is merely the peritoneum, *a*, behind the rectus muscle, R; this posterior layer of the internal oblique running anterior to the rectus muscle. At the pubes, in Plate XXXI., both layers are united, and strongly inserted along with the transversalis muscle, i, into the crista, the spine, ℭ, and the linea-ilio-pectinea, 𝔓, contiguous. Near the tenth or eleventh rib, there is frequently a tendinous intersection.

The internal oblique, a little iliad, gives origin to the cremaster muscle, a, as delineated on the left side in Plates XXX. and XXXI., which latter muscle surrounding the spermatic cord, emerges at the external aperture of the inguinal canal, where it derives a few fibres from Paupart's ligament, as represented in Plate XXIX., and descends to the tunica vaginalis testis, b, as seen in Plate XXIII.

The action of the internal oblique may be said to be nearly the same as that of the external oblique muscle.

Plate XXXI. exhibits on the left side the transversalis muscle, marked with the letters I, the external, f, and the internal oblique, G, g, *g*, muscles being both partially removed; while on the right side, the rectus and pyramidalis muscles are detached, and the tendons of the three lateral muscles, the external oblique, the internal oblique, and the transversalis, are cut from that part where they formed the linea alba, *f*, the transversalis, i, being so reflected as to exhibit the peritoneum, *a*.

The musculus transversus abdominis, I, i, i, i,* situated in the lateral and anterior aspects of the abdomen, derives its origin fleshy from the cartilages of the seven inferior ribs, letters A, where their concave surfaces look to the abdominal cavity; tendinous from the fascia lumborum, or from the transverse processes of the last dorsal and all the lumbar vertebræ; fleshy from the ventral margin of the crista ilia, S, S, and fleshy from the iliac portion, K, of the fascia lata. The fibres proceed directly across, become tendinous at i, i, i, where they contribute to form the linea semilunaris, and unite with the posterior tendinous layer, letters *g*, of the internal oblique muscle, G, which they accompany beneath or centrad to the rectus onwards to be inserted into the linea alba, *f*: but nearly intermediate to the umbilicus and pubes, the tendinous expanse proceeds along with the internal oblique superficially or dermad to the rectus, as seen on the right side of the subject, near that part where the epigastric artery, X, is truncated; there being only the peritoneum, *a*, behind or centrad to the rectus muscle, R, in this region.

Where the muscle arises from the cartilages of the ribs, the digitations intermingle with the origins of the diaphragm, as seen in Plate XXXII.; where it derives origin from the fascia lumborum, the internal oblique and transversalis muscles are inseparable; and at its origin from the fascia lata, these muscles are equally inseparable: here they conjointly form a musculo-tendinous expanse, giving transmission to the spermatic cord in the male, and to the round ligament in the female, and are inserted into the crista and spine, ℭ, of the os pubis, and into the linea-ilio-pectinea, 𝔓, contiguous,† as seen on the right

* Syn. Oblique adscendens; obliquus ascendens; obliquus internus; obliquus ascendens internus abdominis; obliquus alter seu interior; obliquus minor; ilio-lumbo-costi-abdominal; ilio-abdominal; petit oblique abdominal.

† In the drawing this muscle appears to arise solely from the iliac portion, K, of the fascia lata, the whole of the tendon of the external oblique having been detached, to show there is no distinct ligament as Fallopius or Paupart's.

‡ The fascia lumborum is the united tendons of the latissimus dorsi, E, the serratus posticus inferior, H, the internal oblique, G, and the transversalis abdominis muscles, as seen in Plate XXXIII. According to modern authors, it is described as follows:—" The lumbar aponeurosis consists of two layers: the anterior layer is found in the posterior abdominal region, and its attachments are as follows: 1. Superiorly to the anterior surface of the twelfth rib.—2. Inferiorly to the outer part of the posterior third of the crest of the ilium.—3. Internally to the anterior surfaces and roots of the transverse processes of the lumbar vertebræ. —4. Externally, it unites with the middle and posterior layers of the same aponeurosis."—" The posterior layer of this aponeurosis is observed in the lower half of the dorsal region, broad and thin; it is attached to the following parts:—1. The spines of the five or six inferior dorsal vertebræ.—2. The spines of all the lumbar vertebræ.—3. The spines of the sacrum.—4. The interspinous ligaments.—5. The rudimentary articular processes of the sacrum;—and, 6. The posterior third of the crest of the ilium." See *Text-Book of Anatomy for Junior Students*, by Alexander Jardine Lizars, M. D.

* Syn. Transversus; transversalis; transversalis abdominis; lumbo-ili-abdominal; and lombo-abdominal.

† We observe on the right side of the subject, that the spermatic cord, marked *g*, formed by the vas deferens, v, and the plexus of vessels

side of the subject, marked with the letter i, close to the spine, ℄, of the os pubis. On the left side, between the transversalis, I, and the internal oblique, g, muscles, the circumflex iliac artery, *c*, is observed running between them and dividing into branches.*

The function of the transversalis may be said to be nearly the same as that of either the external or internal oblique muscles; for all of them are concerned in the same functions. Individually, they so compress the abdomen in different directions, as more effectually to accomplish their numerous actions.

The musculus rectus abdominis,* letters R, Plates XXIX. and XXX., situated in the anterior or sternal aspect of the abdomen, between the tendinous layers of the internal oblique muscle, derives its origin from the crista of the os pubis, being overlapped by the pyramidalis muscle, T, ascends with longitudinal fibres parallel to the linea alba, *f*, upwards or atlantad; and is inserted into the sternum, the seventh, sixth, and fifth ribs. In this course three or more tendinous intersections, r, r, r, r, occur, which are intimately connected with the anterior tendinous layer of the internal oblique muscle. This muscle is concerned in the same functions as the three lateral muscles last described. When the pelvis is fixed, the two muscles will bend the thorax forwards and downwards; and when the thorax becomes fixed, they will raise the pelvis: through the medium of the adhesions of the tendinous intersections to the tendon of the internal oblique muscle, each intermediate arrangement of fleshy fibres will be enabled to act independently.

In Plate XXX., three-fourths of the rectus muscle, R, are removed on the right side, displaying the relation that the muscle bears to the epigastric artery, X, which is observed to inosculate with the internal mammary artery, 14, seen also in Plates IX. and XI. †

The musculus pyramidalis, T, ‡ of Plate XXX., is situated in the anterior aspect of the abdomen near the pubes, and is properly an appendix to the rectus muscle, R, being sometimes deficient. The pyramidalis deriving its origin from the crista of the os pubis, close to the symphysis, and superficially or dermad to the origin of the rectus, ascends close to the linea alba, *f*, becoming narrower and smaller, till it terminates intermediate to the pubes and umbilicus. This muscle assists the rectus in its functions. §

In Plates XXX., XXXI., and XXXIV. the intercostal muscles are depicted; in Plate XXX., both the external, Z, and internal, X, are drawn in Plate XXXI. only the internal, X, and in Plate XXXIV. merely the external, Z. In Plate XXX., the internal, X, are more faithfully represented.

The musculi intercostales externi, letters Z, ‖ are situ-

---

emerging from behind the peritoneum, *a*, descends obliquely from the abdominal cavity on the iliac and dermal aspect, or superficially and outwardly, to the epigastric artery, x, and vein, *x*, through the transversalis muscle, i, and the internal oblique muscle, g, as represented on the left side, and on its emergence from the latter muscle, the cord receives the cremaster muscle, a, with its cellular investments, then continues its course between the internal oblique and external oblique muscles, as seen in Plate XXX., the latter of which muscles the cord pierces, as seen in Plate XXIX., proceeding downwards to the testis, as represented in Plates XXIII. and XXIV. Thus there is formed a long tube or canal, named inguinal, the external oblique muscle forming the external, and the transversalis muscle the internal aperture. In this description, I have followed Nature, and the authority of Vesalius and the earlier anatomists. Monro *primus*, in the Edinburgh Medical Essays and Observations, vol. v., gives a simple and clear account of the course of the spermatic cord. The fascia transversalis is simply that portion of the transversalis muscle, or its investing cellular sheath, which is here thickened and condensed, and pierced by the spermatic cord. The inner cellular investment of the cremaster muscle is named the internal spermatic fascia, and the outer, the external spermatic fascia; the latter is sometimes termed the fascia propria, and the former, the fascia infundibuliformis. When rupture takes place, the viscera descend generally between the cremaster muscle, a, and the spermatic cord; sometimes, though rarely, between the objects forming the cord; and equally seldom beneath or sacrad to the spermatic cord: on as few occasions, the viscera protrude not down along the inguinal canal, but at once through the transversalis, and the internal oblique muscles opposite the external aperture formed by the external oblique muscle: this latter is named ventro-inguinal or direct, the former inguinal or oblique hernia, or bubonocele. When the viscera are strangulated, and an operation deemed requisite, the first incisions are made through the skin, cellular tissue, and cremaster muscle, down to the herniary sac formed by the peritoneum, without the possibility generally of discriminating between the cellular tissue and muscle. In all the instances I have either witnessed the operation or performed it myself, I have never been able to distinguish a fascia superficialis, a fascia spermatica externa, a cremaster muscle, or a fascia spermatica interna. I have in the first or second incision arrived at the herniary sac, which should be opened at the most depending part of the tumour, by a horizontal incision of the scalpel, the sac being previously pinched up with the fingers or dissecting forceps; the sac must be freely laid open by cutting on the finger with a probe-pointed bistoury upwards to the stricture; the latter as well as the former or sac, are to be cut directly upwards with the same instruments. The reason of cutting directly upwards in this hernia, is, to avoid the epigastric artery in the event of the protrusion being ventro-inguinal, a circumstance only to be learned during the operation. The same observation of our ignorance of the species of hernia, applies to inguinal and crural occurring in the female, for the apertures are so contiguous, that the nature of the hernia cannot be ascertained till the operation is begun. In inguinal hernia, after the stricture is removed, which is generally caused by the tendon of the external oblique muscle, seldom by the conjoint internal oblique and transversalis muscles, the viscera are to be returned, pushing them gently upwards and outwards, and in the reverse order from that in which they descended. The position of the body and limb ought to be the same with that for crural hernia, as described in page 74. The same directions are applicable to reduction before operating. Stitches should be applied to this wound, then a compress of lint, and a flannel roller round the loins and thigh in the figure of the digit 8, to prevent a recurrence of the disease. The patient should have the nates raised by a pillow during the after treatment, and have an emollient enema exhibited immediately after the operation.

* From the magnitude of this artery we observe the reason for objecting against puncturing the abdomen for ascites, between the umbilicus, U, and the anterior superior spinous process, C, of the os ilium; the operation is now almost invariably performed between the umbilicus and pubes in the linea alba, care being taken that the urinary bladder is emptied immediately before.

* Syn. Rectus, præter ejus principium superius; rectus; costo-pubien; sterno-pubien; pubio-sternal.

† The rectus muscle and epigastric artery relate to the cæsarian section, and the securing of the abdominal aorta; in the first of these, previous to the operation, the recti muscles are separated from each other at the linea alba to the distance of nearly three inches, and the epigastric artery removed along with them; this fact I have repeatedly witnessed in women who have died immediately after child-birth, so that in this operation there is little fear of wounding the epigastric artery. The incision should be made on the left side, and parallel to the linea alba, sufficiently remote to descend in the fibres of the rectus, that the patient afterwards may not be subject to ventral hernia. The same longitudinal incision is applicable in the latter case, only it should be made closer to the linea alba, provided there is no enlargement of the abdominal cavity.

‡ Syn. An musculus parvus qui procedit a fine musculi longitudinalis. Musculus succenturiatus. Superius principium recti abdominis. Musculus totus carnosus. Carneum operculum. Carneum. Pubio-ombilical. Pubio-sous-ombilical.

§ The pyramidalis muscle relates to puncturing the urinary bladder, and to performing the operation of lithotomy above the pubes; both of which modes of operating are objectionable.

‖ Syn. Inter-lateri-costaux. Intercostales exteriores.

ated between the ribs, as their name indicates; they lie externally or dermad to the internal intercostals, and are covered by several muscles attached and passing over the ribs. They derive their origin, which is partly fleshy and partly tendinous, from the inferior or sacral margins of the ribs, and descend obliquely forwards or sternad, to be inserted, also partly fleshy and partly tendinous, into the upper or atlantal margins of the contiguous ribs. They extend from the spine or vertebral column forwards to the cartilages, where they become more a tendinous expanse than distinct muscular slips.

Near the spine, a series of the external intercostals, marked z in Plate XXXIV., appear longer, and are named the LEVATORES COSTARUM; they derive their origin from the transverse processes of the dorsal vertebræ, and descend to be inserted into the contiguous lower rib; the more sacral, generally three or four of them, descending over the nearest rib to be inserted into the second; the former are by Albinus denominated levatores costarum breviores, and the latter levatores costarum longiores.

The musculi intercostales interni, letters x,* are situated immediately beneath, or centrad to the external intercostals, and have an opposite direction of fibres, as represented in Plate XXXI. They arise from the superior or atlantal margins of the ribs, and ascend obliquely forwards or sternad, to be inserted into the inferior or sacral margins of the contiguous ribs. The internal intercostal muscles extend from the sternum backwards to the angles of the ribs, which is only seen within the thoracic cavity, by detaching the pleura costalis. Some of them near the posterior angle extend over the neighbouring rib, and are attached to the second. In Plate XXX., between the first two upper ribs, both layers of intercostal muscles are exhibited; and we observe the external strong and thick posteriorly or dorsad, but so thin and scattered anteriorly or sternad, that the internal are observed beneath them crossing in the opposite direction, in such a manner as to represent corruscations. Between the next two ribs, a portion of the external layer, z, is reflected, and the internal layer, x, is brought into view.

The intercostal muscles elevate the ribs from the obtuse angles which they form with the spine, near to a right angle, and both seem to co-operate in this action; and as they peculiarly either terminate or cross at the posterior angles, and at the anterior angles formed by their cartilages, are hence well adapted for this purpose. By this action the capacity of the thorax is dilated, so that they are concerned in respiration or in inspiration, provided this function is active. The internal intercostals, particularly where they are inserted into the cartilages, will depress the ribs, and hence act in expiration. These intercostal muscles are concerned in fractured ribs, and in paracentesis thoracis.

The sterno-costalis,† delineated in Plate XI., Fig. 2, marked B, is situated on the thoracic surface of the sternum and ribs, invested with the pleura; deriving its origin from the two inferior or sacral portions of the sternum, and ascending obliquely upwards and outwards in a radiating manner, to be inserted into the second, third, fourth, fifth, and sixth ribs. The muscle is observed to derive its origin, fleshy and tendinous, from the edge of the ensiform cartilage, and the portion of the sternum atlantad, and to be inserted by triangular tendinous and fleshy slips. This muscle approximates the ribs to the sternum, or depresses them, or it may depress the sternum, and is therefore employed in expiration.

* Syn. Inter-pleuri-costaux. Intercostales interiores.

† Syn. Sextus in altero latere thoracem hominis moventium. Sextus thoracis. Qui internæ sterni sedi apponitur. Triangularis et pectoralis internus. Triangularis. Sterno-costales. Triangulares sterni. Triangularis sterni. Sterno-costaux. Sterno-costal.

PLATE XXXII.

Is a delineation of the diaphragma or diaphragm, B, b, b,* or muscular partition between the thoracic and abdominal cavities, which is also represented in Plates IX., XII., and XIII., letters B. Towards the thorax, the muscle is convex, as seen in Plate IX., and invested with the pleura; and towards the abdomen it is concave, as here depicted, and lined with the peritoneum, which has been removed to exhibit the arrangement of the muscular fibres.

This muscle derives its origin from the central aspect of the ensiform cartilage, *e*, from the same aspect of the cartilages, A, of the six inferior or sacral ribs of each side, from the ligamenta arcuata, D, and from the sides of the bodies of the lumbar vertebræ.† The muscular fibres emanating from this circumference, concentrate, and form a central tendon, B, which gives transmission to the vena cava inferior, *i*, on the right, to the œsophagus, I,‡ nearly in the centre, and to the aorta, e, § posteriorly or dorsad.

Where the diaphragm takes its origin from the ensiform cartilage, *e*, the muscle is extremely thin, the pleura and peritoneum almost uniting: and in some instances these membranes are only separated by cellular tissue.

Where the muscle arises from the ligamentum arcuatum, D, its fibres appear to intermingle with those of the quadratus lumborum, C, and the psoas magnus, K. ||

Where they derive their origin from the sides of the lumbar vertebræ, they are generally strong and tendinous, particularly on the right side, and have been generally regarded as a distinct muscle, named the lesser muscle of the diaphragm; the other origins from the ribs and sternum being considered the greater or larger muscle. These fibres from the vertebræ beautifully cross each other over the aorta, e, and ultimately interlace with those from the ribs and sternum, one and all of the fibres intermingling with each other in the central tendon, where the œsophagus and vena cava pierce.

The diaphragm is the chief muscle concerned in the function of respiration, and from the tendency to a vacuum in the thoracic cavity, presents a convex surface,

* Syn. Midriff. Septum musculare. Septum transversum. Thoracico-abdominal.

† These origins are generally described as arising distinctly from the second, third, and fourth lumbar vertebræ; but there is as frequently an origin from the first and last vertebræ, as from any of the intermediate. *Vide Soemmering de corporis humani fabrica.*

‡ The par vagum descend along with the œsophagus from the thorax to the abdomen.

§ The vena azygos and thoracic duct ascend from the abdomen to the thorax, at the same aperture that the aorta descends; but the splanchnic nerves, and the trunks of the great intercostals, pierce the muscular fibres of the diaphragm, as seen in Plates XII. and XIII. The splanchnic nerve is marked 17, and the intercostal 7.

|| The ligamentum arcuatum is the arched tendinous expanse between these muscles, and is generally fixed to the last rib and the lumbar vertebræ: it is sometimes so thin as not to be very distinct.

which extends atlantad or upwards to the fourth rib, in its quiescent state; on which account the slightest contraction of its fibres enlarges the cavity to a considerable extent. In gentle respiration, or that which takes place during sleep, this muscle alone seems to act; and from its great expanse, and this surprising disposition, appears adequate to the function. In gentle inspiration, the fibres being thrown into moderate action, place the surface more in the position of a horizontal plane; and in violent inspiration the abdominal aspect becomes convex, the thoracic concave, by the fibres from the lumbar vertebræ acting with energy, and pulling downwards or sacrad the central tendinous expanse: in both of these actions the abdominal viscera are forced downwards and forwards, or sacrad and pubic.

In expiration, the fibres act with vigour, this being the chief active function of the muscle; they pull the sternum and ribs inwards or centrad towards their central tendon, which being attached to the pericardium in the thoracic cavity, enables the diaphragm to perform this action vigorously. This attachment limits the descent of the central tendon into the abdominal cavity in inspiration. In the dead state, when the diaphragm is viewed from the abdomen, it is concave, and remarkably tense; but when air is admitted into the thoracic cavity, it is thrown into large folds, and becomes loose and floating.*

THE MUSCLES OF THE BACK.

PLATES XXXIII., XXXIV., AND XXXV.

The muscles of the back are arranged into six layers; the first layer comprises the trapezius and latissimus dorsi; the second, the levator anguli scapulæ; the third, the serratus posticus superior and the serratus posticus inferior; the fourth, the splenius capitis et colli; the fifth, the sacro-lumbalis, the longissimus dorsi, the spinalis dorsi, the cervicalis ascendens, the transversalis colli, the complexus minor and the complexus major; and the sixth layer, the obliquus capitis inferior, obliquus capitis superior, rectus capitis posticus major, rectus capitis posticus minor, transverso-spinalis, inter-spinales, inter-transversales, levatores costarum.

On removing the thick and tough integuments of the back, named the dorsal fascia, † we expose the muscles, which are represented on the right side of Plate XXXIII.; and when these are detached we bring into view those exhibited on the left. On the right half of the back the trapezius muscle, 80, occupies nearly the upper portion, and the latissimus dorsi the lower. Superiorly, between the trapezius, 80, and the insertion, E, of the sterno-cleido-mastoideus, part of the splenius capitis, p, and part of the complexus, O, muscles appear; and inferiorly os sacrad to the trapezius, 80, or between it and the latissimus dorsi muscle, E, a portion of the rhomboideus muscle, T, is seen.

The trapezius, 80, ‡ situated in the upper or atlantal half of the dorsal aspect of the trunk, arises tendinous from the superior transverse ridge, **b**, at the side of the protuberance, *a*, of the occipital bone, tendinous from the ligamentum nuchæ, § and tendinous and fleshy from the spinous processes of the two inferior cervical, and all those of the dorsal vertebræ; the fibres proceed converging from this extent of origin across the back, and are inserted tendinous and fleshy into the superior or atlantal margins of the spine, *h*, and acromion, D, of the scapula, and the scapulary third of the clavicle. Where the muscle derives its origin from the occipital bone, there is generally a tendinous expanse extending to the sterno-cleido-mastoideus muscle, E, that conceals the superior fibres of the splenius capitis muscle, p, which has been here removed to exhibit the latter muscle. The fibres of the trapezius at this part are generally thin and scattered. In its descent along the neck, the muscle occasionally has no adhesion to the cervical vertebræ, but only to the ligamentum nuchæ when this latter is merely attached to the dorsal vertebræ. This portion of the tendinous fibres of these muscles, which present an oval form, is termed the cervical aponeurosis. At the inferior or sacral origin of the muscle, the connexions with the dorsal vertebræ are very various, the muscle sometimes not descending further than the eighth dorsal vertebræ. When the trapezii muscles are on the stretch, ligaments are observed extending between the spinous processes of the dorsal vertebræ, that are named interspinous, but which are sometimes described as muscles. ‖ The insertion of the muscle into the root of the spine, *h*, of the scapula ¶, is generally connected to the fascia covering the infra-spinatus muscle, 81, and overlaps the origin of the deltoid muscle, B: the insertion here is purely tendinous, but as it proceeds around to the clavicle, the muscle becomes more and more fleshy, as observed in Plates XVI. and XVII.

When the head and trunk are fixed, the function of this muscle, its fibres acting conjointly, is to pull the bones

---

* In relation to pathology, the diaphragm is subject to inflammation, and is sometimes ulcerated through in abscess of the liver. Hernia, or transposition of the abdominal viscera into the thorax, through one of its apertures, occurs both in the fetal and the adult state.

† From this structure, the integuments at this part of the back, when inflamed, terminate generally in mortification, as occurs in carbuncle, and that brutal degrading practice of flogging.

‡ Syn. Cucullaris; Trapesius; Cucullaris et Trapezius; Secundus scapulam moventium; Occipiti-dorso-clavi-sus-acromien; Dorso-sus-acromien.

§ The ligamentum nuchæ is a strong elastic ligamentous rope, extending between the spinous processes of the cervical vertebræ, and the upper or coronal portion of the perpendicular ridge of the occipital bone contiguous to the protuberance, *a*, and is in a considerable measure formed by the union of the trapezii muscles. In general, this ligament adheres only to the spinous processes of the lower cervical vertebræ and the occipital bone; but sometimes it is merely attached to those of the superior dorsal vertebræ and occipital bone. This ligament is strong and distinct in advanced life, and is still stronger and thicker in the graminivorous animals.

‖ Syn. Interspinales dorsi; Les petits épineux du dos; Lumbo-dorso-spinal.

¶ A synovial bursæ is situated here, which is occasionally affected with chronic inflammation and suppuration.

of the shoulder directly dorsad to the spine. When the same points remain fixed, and the superior or atlantal are thrown into action, they elevate the clavicle and scapula towards the head and neck; when the central fibres alone act, they draw these bones in a similar direction to the entire muscle; and when the inferior or sacral oblique fibres act, they depress these bones. From these actions it will be evident, that any individual fasciculus of a muscle can act independently, and that these may perform a circular movement of the bones of the shoulder. When the clavicle and scapula become fixed points, the muscle acts in the opposite direction, depressing the head to the shoulder, and inflecting the spine either downwards or upwards. This muscle is one of the chief supporters of the head in the infantile state.

The latissimus dorsi muscle,* letters E, derives its origin tendinous from nearly the posterior or dorsal half of the crista, S, of the os ilium, tendinous from the spinous processes, *e*, of the os sacrum, of the lumbar, and of the seven inferior dorsal vertebræ; or according to modern anatomists, from the posterior layer of the lumbar aponeurosis; these tendinous origins soon become fleshy, and ascend obliquely upwards and forwards, or sternad and atlantad, over the ribs, deriving additional fleshy origins from the four or five inferior ribs in their course, and adhering to the inferior angle † of the scapula, as they glide over that bone, where they converge and become connected with the teres major muscle, F, with which they ultimately form a conjoint tendon, that is inserted into the ulnar ridge of the bicipital groove of the os brachii, as seen in Plate XIX., Fig. 1, also in Plates XXXVIII. and XXXIX.

Where the latissimus dorsi arises anteriorly or sternad from the crista, S, of the os ilium, it is extremely delicate, soon becomes fleshy, and overlaps the obliquus externus abdominis, F, as observed on the left side of the subject. The origins from the dorsal vertebræ are covered by the trapezius muscle, 80; the origins from the ribs are delineated in Plate XXIX., marked E, where they are observed to intermingle with the digitations, F, of the external oblique muscle, and the digitations, O, of the serratus major anticus muscle. The muscle, immediately before its insertion, forms a peculiar turn or twist, so as to appear superiorly or atlantad or radiad to the teres major muscle, F, distinctly seen in Plate XIX., Fig. 1, also in Plates XXXVIII. and XXXIX. Here these two muscles form the inferior and outer, or the ulnar and dorsal fold of the axilla, and relate to the securing of the axillary artery, and to amputation at the shoulder-joint, as already described; also to dislocation of this joint. A strong fleshy slip frequently extends from the latissimus dorsi to the pectoralis major muscle, across the axillary plexus of nerves and blood-vessels.

The function of the latissimus dorsi, is to pull the arm or os brachii downwards and backwards, or sacrad and dorsad, as in one of the motions of the sabre exercise; and also contributes to pronate the hand by rolling inwards or ulnad the os brachii on the glenoid cavity of the scapula. When the arm is the fixed point, this muscle aids us in bringing the trunk to the arm.

Beneath or centrad to the trapezius and latissimus dorsi muscles, appear the rhomboidei, T, t, and the serratus posticus inferior, H; the former below the trapezius, and the latter under the latissimus dorsi. The rhomboidei muscles, T, t,* are situated nearly in the centre of the back, immediately beneath or centrad to the trapezius, 80, extending between the spine and the scapula, and are generally considered as two muscles although they are only one; hence Bidloo observes, that he never saw the minor. Wherever anatomy can be simplified, it certainly should, and consequently as these muscles in nine cases out of ten require more than common dissection to separate them, and as they perform the same function, they ought to be described as one muscle, deriving its origin chiefly tendinous from the spinous processes of the two or three inferior or sacral cervical, and the four or five superior or atlantal dorsal vertebræ; the fleshy fibres descending obliquely across the back, to be inserted into the base of the scapula, *c*, C, C, from a little above or atlantad to the root of the spine downwards to the inferior angle. That portion of the muscle marked t, is the rhomboideus minor, and is observed to be separated by a slight shading from the major, marked T. Where the muscle arises from the cervical vertebræ, it is generally connected to the ligamentum nuchæ. The insertion of the rhomboidei is also seen in Plate XXXIV. The rhomboidei elevate the scapula upwards and backwards, or atlantad and dorsad; and when the scapula is made the fixed point, they approximate the spine to the shoulder.

The vertebral aponeurosis is a flat, thin, elongated fascia attached to the serratus inferior muscle, the serratus superior muscle, to the angles of the five or six central ribs, and to the spines of the six or seven of the middle dorsal vertebræ.

Serratus posticus inferior, H,† is situated in the inferior or sacral region of the back, immediately beneath or centrad to the latissimus dorsi muscle, along with which it arises by a conjoint tendon from the spinous processes of the two or three inferior or sacral dorsal vertebræ, and the three or four superior or atlantal lumbar vertebræ. The tendinous fibres ascend obliquely forwards or sternad, becoming partly fleshy, to be inserted into the four or five inferior or sacral ribs. The origin of this muscle contributes to form what is named the fascia lumborum, described in page 75, and is inseparable from the latissimus dorsi. The insertions are frequently very thin and

* Syn. Quartus brachium moventium; Quartus humeri musculus; Quartus musculus movens humerum; Latissimus, ani scalptor, aut dorsalis maximus; Ani scalptor, ani tersor, latissimus; Latissimus dorsi sive ani scalptor; Le grand dorsal ou très large du dos; Lombo-huméral; Dorsi-lumbo-sacro-huméral.

† The connexion of the fibres of the latissimus dorsi muscle by cellular tissue to the scapula in their course over the inferior angle to their destination, should be considered by the practitioner, as this point of the bone is sometimes forced above the margin of the muscle, so as to prove a troublesome accident. The muscle requires to be relaxed, and then put in situation, and kept so by Dessault's bandage for fractured clavicle. A synovial bursa is found here, which is now and then affected with diseased action.

* Syn. of Rhomboideus major. Et pars major quarti scapulam moventium. Quarti scapulæ musculi. Rhomboidis. The inferior part of the rhomboides. La portion inférieure du rhomboide. Cervici-dorso-scapulaire. Dorso-scapulaire. Syn. of rhomboideus minor. Est pars quarti scapulam moventium Quarti scapulæ musculi. Octavus omnoplatæ. Syn. of both muscles, Rhomboidis of Laurentius; superior and inferior parts of the rhomboïdes of Douglas and Cowper; and the same of Winslow; Le Rhomboïde of Sabatier, Boyer, Bichat, and Portal.

† Quintus in altero latere thoracem hominis moventium. Quartus thoracis musculus. Musculus ad infinam dorsi partem, una cum alio musculo exiguo prædicto superposito. Le dentelé postérieur inférieur. Petit dentelé postérieur inférieur. Petit dentelé inférieur. Lombo-costal. Dorsi-lumbo-costal.

scattered, indeed the whole muscle is sometimes so slender, that it can be with difficulty distinguished from a tendinous expanse, continuous and parallel with it upwards or atlantad to the superior serratus: beneath this expanse, the tendons, d, d, d, of the sacro-lumbalis, and those, k, k, k, of the longissimus dorsi muscles, are observed shining through, as represented in the drawing.

The inferior serratus muscle pulls the rib downwards and backwards, or sacrad and dorsad, and is therefore a muscle engaged in expiration.

The levator scapulæ, 40,* is situated superiorly or atlantad to the rhomboideus, T, t, occupies the lateral aspect of the neck, and divides in a manner the anterior or sternal, from the posterior or dorsal muscles. This muscle derives its origin from the transverse processes of the four or five superior or atlantal cervical vertebræ, and descends obliquely in fleshy bundles, to be inserted into the superior portion, **c**, of the base of the scapula, that is not occupied by the rhomboideus muscle. The origins of this muscle are partly fleshy and partly tendinous, intermingling with the tendons of the splenius colli, *p*, on the one side, and those of the scalenus posticus, 50, on the other, as delineated in Plate XXXIV. An anterior or sternal view of these muscles is given in Plate XXXV. The insertion of the muscle is very fleshy, and extends from the superior posterior angle, to the angular projection, a little above the root of the spine of the scapula. The insertion is also seen in Plate XXXIV. For a more minute insertion of this muscle, consult the description of the scapula.

The name of this muscle indicates its chief function; but when the scapula is fixed, it will inflect the neck and head laterad.

On detaching the rhomboideus, T, t, Plate XXXIII., the serratus superior posticus,† E, Plate XXXIV., is brought into view, extending between the spine and the superior or atlantal ribs. This muscle derives its origin tendinous from the spinous processes of the three or four inferior cervical, and the two or three superior dorsal vertebræ, descending obliquely to be implanted by fleshy digitations into the second, third, and fourth, and occasionally the fifth ribs, sternad or forwards to their angles. I have described this muscle as arising from the three or four cervical, and two or three dorsal vertebræ, since it, and all the muscles of the back, have so various an origin, that it appears preferable to commit to memory a general than a particular origin. Its function is to elevate the ribs in increased inspiration; and when the ribs become the fixed point, to inflect the neck laterad, but when both muscles act, to inflect it dorsad.

The splenius capitis et colli,‡ delineated in Plates XXXIII. and XXXIV., and marked with the letters p, *p*, is situated in the posterior or dorsal aspect of the neck, covered by the trapezius, rhomboideus, and serratus superior posticus muscles, and extends obliquely upwards from the spine to the occiput. This muscle derives its origin partly tendinous and partly fleshly from the spinous processes of the five or six superior dorsal, and the five inferior cervical vertebræ, ascending obliquely outwards or laterad, to be inserted tendinous and fleshy into the depression immediately beneath or basilad to the superior or coronal transverse ridge, **b**, of the occipital bone, and the mastoid process, *m*, of the temporal bone, and into the transverse processes of the four or five superior cervical vertebræ. Where the muscle arises, there is no division into origin of capitis et colli, and the atlantal or superior portion is not connected with the cervical vertebræ, but to the ligamentum nuchæ. The insertions into the transverse processes of the cervical vertebræ are elegant small tendons, like all those muscles connected with the same processes of these vertebræ. Those of the levator scapulæ are on the one or tracheal side, and those of the trachelo-mastoideus, F, as seen in Plate XXXV., are on the other or dorsal side. The insertion into the temporal and occipital bones is concealed by the sterno-cleido-mastoideus, E, Plate XXXIII.

The action of this muscle is to inflect the head and neck backwards, to rotate the head on the vertebra dentata, and to rotate the cervical vertebræ.

When the preceding dorsal muscles are detached, there are brought into view several muscles extending the whole length of the back, the sacro-lumbalis, marked with the letters D, d, the longissimus dorsi, K, k; and the spinalis dorsi, L; the semi-spinalis dorsi, M, and the semi-spinalis colli, N: the two latter are only seen in Plate XXXV.

The sacro-lumbalis,* D, and the longissimus dorsi,† K, muscles, named also erector spinæ, arise conjointly, partly tendinous and partly fleshy, from the posterior or dorsal aspect of the crista, S, of the os ilium, from the spinous processes and dorsum of the os sacrum, and from the spinous and transverse processes of the lumbar vertebræ. The sacro-lumbalis, D, ascending, soon terminates in an elegant arrangement of tendons, marked with the letters d, that are inserted into the ribs near their angles. The origin of the sacro-lumbalis is more fleshy than that of the longissimus dorsi, if we separate with violence the two muscles downwards or sacrad to the crista of the os ilium. The manner of separating these two muscles, for they appear one and the same in the drawing, and one and the same in nature, is to press the tendons, letters d, of this muscle to the sternal side, and gently the fleshy mass, k, of the longissimus dorsi towards the spinal column; then to insulate them either with the cutting edge or handle of the scalpel or with the finger, upwards

---

* Syn. Tertius hominis scapulam moventium. Tertius scapulæ musculus. Levatores proprii. Levator. Scapulam attollens, levator, patientiæ musculus. Elevator seu musculus patientiæ. Le reveleur propre de l'Omoplate. L'Angulaire, dit communement releveur propre. Levator anguli scapulæ. Trachélo-scapulaire. Trachélo-anguli-scapulaire.

† Syn. Tertius in altero latere thoracem hominis moventium. Tertius thoracis musculus. Musculus ad supremam dorsi partem prope cervicem. Le dentelé postérieur supérieur. Petit dentelé postérieur supérieur. Petit dentelé supérieur. Dorso-costal. Cervici-dorso-costal.

‡ Syn. Primi paris musculorum aut caput, aut primam vertebram moventium, pars quæ in occipitium finit; et pars quæ in traversos vertebrarum processus nexum mollitur. Primi moventis caput, in occipitium implantata, et in processus transversos inserta. Pars ejus qui a recentioribus anatomicis ante alios descriptus, primum par caput extendentium. Splenii. Triangularis splenii. Superior et inferior splenii. Splenii inserta processui mammillari et inserta vertebris colli. La portion supérieure et inférieure du splénius ou mastoïdien postérieur. Splénius de la tête et splénius du cou. Cervico-mastoïdien et dorso-trachélien. Cervico-dorso-mastoïdien et dorso-trachélien.

* Syn. Quartus in altero latere hominis thoracem moventium. Quintus thoracis musculus. Quartus thoracis musculus. Sacro-lumbus. Alius præterea in dorso musculus, qui cum spinalibus musculus pertinacissime commiscetur. Sacro-lumbus, una cum inferiore parte cervicalis descendentis. La portion externe ou dorso-trachélienne du sacro-spinal. Le lumbo-costo-trachélien.

† Syn. Undecimus et duodecimus dorsum moventium. Secundus musculus dorsi. Quinti paris dorsi musculorum, præter partem spinis vertebrarum thoracis insertam. Semi-spinatus. Longissimus dorsi præter partem quæ inserta spinis thoracis. Longissimus. Le long dorsal. Portion costo-trachélienne du sacro-spinal. Lombo-dorso-trachélien.

to the first rib, and downwards to the last rib, where they are so incorporated, as not to admit of further separation. When this is done, a number of small muscles, named accessory, may be seen deriving their origin tendinous from the superior or atlantal eight or nine ribs, and joining the fleshy mass of the sacro-lumbalis; three of them are represented on the right side of this Plate XXXIV., marked *d*, truncated where they joined the body of the muscle. The tendons of this muscle become longer and more elegant in their ascent.

This muscle, from its numerous attachments, has a variety of motions; when the origin of the muscle is fixed, it elevates and inflects the thorax backwards or dorsad, and to one side; and in active respiration, depresses and approximates the ribs, so as to assist in expiration: when the tendons become the fixed point, the muscle will elevate and inflect dorsad or backwards the pelvis on the thorax; and in active respiration, the musculi accessorii will raise the ribs in inspiration.

The longissimus dorsi muscle, K, k, the situation and origin of which have been described along with the preceding muscle, ascends parallel to the sacro lumbalis, and is inserted into the ribs between their tubercles and angles, and into the transverse processes of the dorsal vertebræ.

The origin of the longissimus dorsi appears entirely tendinous, but beneath or centrad is fleshy, where the muscle arises from the transverse processes of the lumbar vertebræ. In its ascent on the spinal margin, this muscle is connected with the spinalis dorsi, L, either by tendinous or carneous fibres. The insertions into the ribs are chiefly tendinous, and are attached generally to the superior or atlantal ten; they are seen on the right side of this Plate XXXIV., marked *k*, being only displayed when the muscle is separated from the sacro-lumbalis; the insertions into the transverse processes of the dorsal vertebræ are commonly small double tendons, and can be only seen by separating this muscle from the spinalis dorsi, L.

The functions of this muscle resemble those of the sacro-lumbalis in depressing the ribs, in inflecting the thorax dorsad, in elevating the pelvis, and inflecting it dorsad. This muscle assists to inflect the spine laterad.

The spinalis dorsi muscle, L,* situated nearer the spinal column than the longissimus dorsi, K, k, derives its origin, in connexion with that muscle, from the two or three superior lumbar, and the spinous processes of the three or four inferior dorsal vertebræ, ascends between the longissimus dorsi, K, k, and the spine, soon becoming fleshy and again tendinous, to be inserted by small tendons into the spinous processes of the eight or nine superior dorsal vertebræ. The origin of this muscle is connected either by carneous or tendinous fibres to the longissimus dorsi, generally by the latter, which are equally strong with those of the longissimus, of which it evidently forms a part. The tendinous insertions intermingle with those of the semi-spinalis dorsi. This muscle inflects the dorsal vertebræ laterad, and when the muscle of the opposite side acts, they inflect the spine dorsad.

The semi-spinalis dorsi muscle, M,† Plate XXXV., properly the continuation of the spinalis dorsi, as they appear one and the same muscle, arises from the transverse processes of the seventh, eighth, and ninth dorsal vertebræ; ascends with oblique fibres close to the spine, to be inserted into the spinous processes of the five superior or atlantal dorsal, and the two or three inferior or sacral cervical vertebræ. The origin of this muscle is lateral to the insertion of the spinalis dorsi, and mesial to the origin of the semi-spinalis colli, N, of Plate XXXV. The insertion in some measure overlaps that of the spinalis dorsi.

The function of this muscle is to assist the former in inflecting the spine laterad, and when the opposite muscle acts, to bend the spine dorsad.

The semi-spinalis colli, N, Plate XXXV., * apparently the continuation of the semi-spinalis dorsi, is situated on the sides of the cervical vertebræ, beneath the complexus, O, and derives its origin from the transverse processes of the five or six superior dorsal vertebræ; ascends with oblique fibres, which are inserted into the spinous processes of the cervical vertebræ. The origin of this muscle, which is tendinous, lies between the semi-spinalis dorsi and the complexus; and its insertion, which is fleshy, covers at the sacral portion the insertion of the semi-spinalis dorsi. Its use is to inflect the neck laterad, and when both muscles act, to inflect the cervical vertebræ dorsad.

When the spinalis dorsi, L, the semi-spinalis dorsi, M, and the semi-spinalis colli, N, muscles, are detached from the spine, there appear a multiplicity of oblique muscular fibres, extending between the transverse processes of the vertebræ, and the spinous processes of the same bones, which have acquired the name of multifidus spinæ, † marked Q on the right side in Plate XXXIV. Inferiorly the muscle arises from the dorsum of the os sacrum, the posterior contiguous part of the os ilium, the articular and transverse processes of the lumbar vertebræ, the transverse processes of the dorsal and cervical vertebræ, excepting the three superior of the latter. The muscular fibres ascend obliquely to be inserted into the spinous processes of the lumbar, dorsal, and cervical vertebræ, with the exception of the dentata and atlas. The origins of this muscle are observed to be partly fleshy and partly tendinous; fleshy inferiorly, becoming tendinous in their ascent. The muscular slips generally extend over the first, to be inserted into the second vertebra, occasionally

* Syn. Quinti paris dorsi musculorum, pars implantata in spinas vertebrarum thoracis. Semi-spinati. Dorsi longissimi pars, quæ inserta spinis thoracis. Le grand épineux du dos. Lumbo-dorso-spinal.

† Syn. Semi-spinalis. Les vertebraux externes du demi-épineux, ou transversaire épineux du dos. Transverso-spinal. La portion lombo-cervicale du sacro-spinal.—The semi-spinalis dorsi, the semi-spinalis colli, and the multifidus spinæ, are considered by some anatomists to be one muscle, and named transverso-spinalis.

* Syn. Est pars septimi et octavi dorsum moventium. Quarti cervicis musculi. Tertii pars dorsi musculorum. Spinati. Spinalis colli. Spinalis. Les vertebraux externes du demi-épineux, ou tranversaire épineux du col. La portion lombo-cervicale du sacro-spinal. Transverso-spinal.

† Syn. Pars ejus, quæ in lumbis est decimus tertius, et decimus quartus dorsum moventium; Quæ in dorso, est decimus quintus, et decimus sextus dorsum moventium; Quæ in collo, est pars septimi et octavi dorsum moventium. Tertius dorsi musculus; Quartus dorsi musculus; Quarti cervicis musculi. Pars tertii paris dorsi musculorum; quæ in lumbis et dorso, est quarti paris dorsi musculorum. An sacer; quæ in collo pars spinati; quæ in dorso semi-spinati; quæ in lumbis, paris sacri. Transversalis colli; Semi-spinatus; sacer. Transversalis; transversalis dorsis interiores; transversalis lumborum, vulgo sacer; portiones distinctæ in cervice, sunt haud dubie intervertebrales. Sunt les vertebraux internes du demi-épineux, ou transversaire épineux du col: les demi-épineux, ou transversaire épineux du dos, aut fortasse ejus tantum partes internæ: le transversaire épineux des lombes, anciennement le sacré. La portion lombo-cervicale du sacro-spinal. Le transverso-spinal.

over two, into the third vertebræ. The function of this muscle is to inflect the spine laterad; both muscles inflecting the spine dorsad.

The quadratus lumborum muscle,* C, seen in Plate XXXIV., and in Plate XIII., is situated in the lumbar region of the abdominal cavity, between the transversalis abdominis, and the psoas magnus muscles. In this Plate XXXIV., the quadratus, C, is observed laterad to the multifidus spinæ muscle, Q, and to derive its origin from the posterior or dorsal third of the crista, S, of the os ilium, to ascend with oblique fibres, which are inserted into the transverse processes of the lumbar vertebræ, the side of the body of the last dorsal vertebra, and the contiguous part of the last rib. This muscle is covered posteriorly or dorsad by the fascia lumborum, and anteriorly or towards the abdominal cavity, by the peritoneum, as formerly illustrated. The muscle is thick and fleshy, with occasionally tendinous striæ parallel to its carneous fibres. The function of the quadratus lumborum is to inflect the spine laterad, to pull down the last rib, and consequently to act on the diaphragm in inspiration; when both muscles act, they inflect the spine sternad and pubic; when the spine and ribs are fixed, this muscle will aid in elevating the pelvis to the thorax.

Continuous with the sacro-lumbalis muscle, D, d, Plates XXXIV. and XXXV, atlantad in the neck, is the cervicalis descendens, 𝔇, muscle,† which is properly a continuation of the former, On the left side, in Plate XXXIV. this muscle is obscured by the serratus superior posticus, E, and the splenius, *p*, p; while on the right side, merely by the splenius: the sacro-lumbalis, d, is truncated immediately below or sacrad to the third superior or atlantal rib. The cervicalis descendens is described as deriving an origin from the four or five superior ribs, and ascending to be inserted into the transverse processes of the fourth, fifth, and sixth cervical vertebræ. This muscle assists in rotating the lower or sacral cervical vertebræ on each other, in inflecting laterad or dorsad the neck, and in elevating the ribs in active inspiration.

The longisimus dorsi muscle, K, k, of Plate XXXIV., has a continuation atlantad in the neck, similar to the sacro-lumbalis, which is named the transversalis colli, 𝔎;‡ this appendage is concealed on the left side by the serratus superior posticus, E, and the splenius, *p*, p, muscles, while on the right side only by the splenius, *p*, p, so that its commencement is observable. In Plate XXXV., on the right side, the transversalis muscle, 𝔎, is seen on the mesial aspect of the cervicalis descendens, 𝔇, and laterad to the complexus, O, and trachelo mastoideus, F, muscles. It is described as deriving an origin from the transverse processes of the five superior dorsal vertebræ, and ascending obliquely atlantad, to be inserted into the transverse processes of the five or six inferior cervical vertebræ. This muscle assists the cervicalis descendens in rotating the cervical vertebræ on each other, and in inflecting the neck laterad and dorsad.

In Plate XXXV., on the mesial aspect of the transversalis colli muscle, 𝔎, and the lateral aspect of the complexus muscle, O, or between these muscles, the trachelo-mastoideus, F,* a thin slender muscle, is situated, deriving its origin from the transverse processes of the three or four superior dorsal, and the five inferior cervical vertebræ, ascending in the neck, to be inserted into the mastoid process, *m*, of the temporal bone, beneath the splenius capitis. The action of this muscle is to inflect the head laterad; and when the head is fixed, to assist in elevating the trunk towards the former.

The complexus muscle, O,† is situated nearer the mesial line than the trachelo-mastoideus, and is a much bolder muscle; and in Plate XXXIV., is observed to be almost entirely concealed by the splenius muscle, p. This muscle derives its origin from the transverse processes of the six or seven superior dorsal, and the four or five inferior cervical vertebræ, and ascends to be inserted into the occipital bone between the two transverse ridges. The origin of the complexus lies first between the semi-spinalis colli, N, and the longissimus dorsi, k, muscles, and secondly, between the semi-spinalis colli, N, and the trachelo-mastoideus, F. When dissecting these muscles, we should endeavour to reach as soon as possible some well defined portion, as, for example, the insertion of the complexus, and trace it to the origin, otherwise we shall frequently amalgamate one muscle with another. The complexus in its progress has generally one or two tendinous intersections, running either obliquely across, or parallel with the carneous fibres, and the insertion occupies a great extent of the occipital bone in breadth; so that from these appearances, the muscle must be frequently called into action in inflecting dorsad the head, and in giving support to the head when stooping or standing erect. In the event of the head being fixed, the complexus will assist in approximating the trunk.

When the complexus muscle, O, is detached from its insertion into the occipital bone and reflected, the two oblique muscles, B, E, and the two recti muscles, A, P, appear.

The musculus obliquus capitis superior, B,‡ situated beneath the complexus muscle, O, and close to the posterior or inial surfaces of the temporal bone, 7, and the occipital, 5, derives its origin from the projecting transverse process, *d*, of the atlas, ascends obliquely backwards or iniad, running close upon the cranium, to be inserted into the occipital bone, 5, immediately beneath the inferior of the two transverse ridges; see Plate V., Fig. 5.

---

* Nonus et decimus dorsum moventium. Primus dorsi musculus. Sexti paris dorsi. Quadratus. Paris lumborum quadrati. Flectens par lumborum quadratus dorsi. Le quarré ou carré des lombes, ou lombaire externe. Lumbaris externus. Ilio-costal. Ilio-lumbi-costal.

† Syn. Secundi paris dorsi musculorum secundum principium a costa. Pars superior cervicalis descendentis. Sacro-lumbalis pars superior. Sacro-lumbi ea superior pars, quam Diemerbrockius cervicalem descendentem musculum vocat. Le transversaire grêle, ou transversaire collatéral du col. Le dorso-trachélien du muscle sacro-spinal. Le costo-trachélien du lumbo-costo trachélien.

‡ Quintos et sextus dorsum moventium. Tertius cervicis musculus. Secundi paris dorsi musculorum principium prius. Transversarius. Transversalis. Transversalis cervicis. Le grand transversaire du cou. L'accessoire du long dorsal.

* Syn. Secundi paris caput moventium musculus tertius. Pars secundi musculi capitis. Tertius movens caput. Pars complexi. Tertius musculus trigemini aut compositi. Trachelo-mastoidæus, seu capitis par tertium. Le petit complexus ou mastoïdien latéral. Une portion du sacro-lombaire. Trachélo-mastoïdien. Complexus minor.

† Syn. Secundi paris caput moventium, quartus musculus moles carnea. Pars secundi musculi capitis. Secundi moventis caput. Complexus aut biventer cervicis. Pars complexi. Carnea quædam moles quæ trigemino adjimgitur. Pars ejus qui le complexus. Biventer cervicis et complexus. Complexus major. Trachélo-occipital. Dorsi-trachélo-occipital. Le grand complexus.

‡ Syn. Quinti paris caput moventium. Sextus caput movens. Sextus capitis. Obliquus musculus qui retro à transverso primæ vertebræ processu in caput inseritur. Obliquus minor. Paris obliqui superioris. Obliquus superior. L'oblique supérieur ou petit oblique. Atloïdo-sous-mastoïdien. Trachélo-atloïdo-occipital.

Both the origin and insertion of this muscle are tendinous, indeed the whole muscle is so tendinous as to resemble in some measure a ligamentous expanse on the cranium. The insertion conceals that of the rectus major, A, and in some degree that of the minor, P.

The function of the obliquus superior, is to inflect the head dorsad or backwards; when the head is the fixed point, it will inflect the atlas, and assist in inflecting the spine also backwards or iniad to the head; but these latter actions are seldom performed.

The musculus obliquus inferior capitis, E,* situated beneath the complexus muscle, O, and extending between the two superior cervical vertebræ, derives its origin from the spinous process, *e*, of the vertebra dentata, and ascends obliquely outwards to be inserted into the transverse process, *d*, of the atlas. This muscle is more fleshy, thicker, and stronger than the superior oblique, and there are few or no tendinous fibres, excepting at the origin. This muscle rotates the atlas on the dentata, and, when both muscles act, assists in inflecting the head backwards.

The musculus rectus capitis posticus major, A,† situated beneath the complexus muscle, O, and in the angle formed by the two oblique muscles, derives its origin from the spinous process, *e*, of the vertebra dentata, and ascends with less obliquity of fibre than the obliquus inferior, to be inserted into the occipital bone, 5, basilad to the inferior of the two transverse ridges, and the obliquus superior muscle, B. The origin of this muscle is fleshy, and its fibres radiate to their insertion, which is partly tendinous.

The function of the rectus capitis major is to inflect the head dorsad, and to rotate it on the vertebra dentata through the medium of the atlas.

The musculus rectus capitis posticus minor, P,‡ is situated beneath the obliquus superior, B, and rectus capitis major, A, muscles. In the drawing, the head is turned a little to the left side, to bring these muscles more distinctly into view. The rectus minor, P, derives its origin acutely from the spinous process, *e*, of the atlas, ascends with radiating fibres to be inserted into the occipital bone, 5, basilad to the inferior of the two transverse ridges and the obliquus superior, B, and rectus major, A, muscles. Both the origin and the insertion of the rectus minor are tendinous, and the fibres scattered.

The musculus rectus capitis lateralis, H,§ situated deeply beneath the several muscles connected to the mastoid process, *m*, of the temporal bone, 7, derives its origin from the transverse process, *d*, of the atlas, and is inserted into the ridge of the occipital bone which extends between the mastoid process, *m*, of the temporal bone, and the foramen magnum of the occipital bone: for the more minute insertion of this muscle, consult Plate V., Fig. 5, letter *f*. This muscle inflects the head slightly laterad and dorsad.

The musculi interspinales, letters g,* situated between the spinous processes of the contiguous vertebræ, arise from the one spinous process, *e*, of a vertebra, and are ininserted into the spinous process, *e*, of the next vertebra. In the neck, they form distinct pairs of fleshy muscles, while in the back and loins they become more and more ligamentous, as observed in Plates XXXV. and XXXIII.: in the latter Plate they are seen to be ligaments lying superficially between the spinous processes of the lumbar vertebræ.

The musculi intertransversales, letters *h*,† Pl. XXXIV., are short muscular slips extending between the transverse processes of the vertebræ; double in the neck, very slender in the back, and thick and fleshy in the loins. They approximate the vertebræ in the lateral inflections of the spine.

In this Plate XXXV. the intertransverse ‡ ligaments are represented, marked with the digits 1; and, as their name indicates, extend from the one transverse process of a vertebra to the other. One of the ligaments of the necks of the ribs, marked 2, is observed beneath or sternad to the atlantal of these two intertransverse ligaments extending nearly in the same direction; these are named ligamenta interna colli costarum,§ and descend from the transverse processes of the dorsal vertebræ, to be attached to the superior or atlantal surface of the necks of the ribs. The capsular‖ ligaments of the tubercles of the ribs are marked *l*, and are seen surrounding the articulations between the transverse processes of the dorsal vertebræ, and the articular surfaces contiguous to the tubercles of the ribs. These capsules, like those of other joints, have strong ligamentous bands exteriorly to strengthen them, which by some authors are described as separate ligaments, and named ligamenta transversa externa costarum.

---

* Syn. Obliquus inferior capitis. Sexti paris caput moventium. Quintus caput movens. Septimus capitis. Parvus musculus a secundæ vertebræ spina in processum transversum primæ oblique infixus. Obliquus major. Paris obliqui inferioris. Obliquus inferior. Le grand oblique. Oblique inferior, ou axoïdo-atloïdien. Spini-axoïdo-tracheli-atloïdien.

† Syn. Tertii paris caput moventium. Tertius musculus caput movens. Major rectus. Rectus major. Le grand droit postériur de la tête. Axoïdo-occipital. Spini-axoïdo-occipital.

‡ Syn. Quarti paris caput moventium. Quartus musculus caput movens. Rectus minor. Le petit droit postérieur de la tête. Atloïdo-occipital. Tuber-atloïdo-occipital.

§ Syn. Musculus admodum parvus, qui a processu transverso primæ vertebræ ortus. Alter musculus prædictis brevior et angustior. Musculus obliquus, qui ante a transverso primæ vertebræ processu in caput inseriteur. Rectus lateralis. Le rengorgeur droit. Le premier transversaire anterieur.

* Syn. Interspinales colli; interspinales dorsi; interspinales lumborum. Les épineux des lombes; les épineux du dos; les petits épineux du col. Interspinales. Supernumerarii. Musculus superspinalis colli. Inter-épineux du cou. Les inter-cervicaux.

† Intertransversarii priores et posteriores colli, dorsi et lumborum. Les petits transversaires ou intertransversaires du cou, du dos et des lombes. Intertransverse priores et posteriores. Inter-trachéliens.

‡ Syn. Ligamenta processuum transversorum vertebrarum. Ligamenta intertransversalia.

§ Syn. Ligamenta transversa interna costarum.

‖ Syn. Ligamenta capsularia capitulorum minorum.

SUPPLEMENT.

PLATES XXXVI. AND XXXVII.

In the two Supplemental Plates, we have correct representations of a dissection of inguinal and crural hernia, by Sir Astley Cooper.

In Plate XXXVI. the parts are most clearly elucidated, and display a neatness of manipulation seldom equalled. The letters f indicate the tendinous expanse of the external oblique muscle, part of which is cut nearly parallel with Paupart's ligament, B, and reflected to bring into view the internal oblique muscle, G, the transversalis muscle, I, with its tendon, i, together with the outer, *i*, and inner, **i**, portions of the fascia transversalis; the former of which, or iliac, *i*, ascends behind the transversalis muscle to the diaphragm, while the latter or inner or pubic portion, **i**, descends beneath, or sacrad to Paupart's ligament, to form the sheath of the femoral vessels: these are represented as shining through the sheath; the femoral artery being marked T, and the vein U. The internal oblique muscle, G, and transversalis muscle, I, are also divided from their attachment with Paupart's ligament, B, and reflected. The spermatic cord, *a*, is seen descending through the aperture of the fascia transversalis formed by its iliac, *i*, and pubic, **i**, portions, which thus constitute the internal aperture of the inguinal canal; then between the internal, G, and external, f, oblique muscles, receiving the delicate muscular fibres of the cremaster muscle, a, and emerging at the external aperture, 1, 2, of the inguinal canal. In Plate XXXVII. the spermatic cord, consisting of its arteries, *g*, *g*, its veins, **g**, **g**, and its duct or vas deferens, v, is observed to emerge from the abdomen at the internal aperture, marked *i*, **i**, of the inguinal canal, on the iliac side of the epigastric artery, x. The margin of the aperture, on this abdominal aspect, is lined with the peritoneum, *a*, which is also seen to invest the transversalis muscle, I, with its fascia, *i*, **i**, the rectus muscle, R, and the epigastric artery, x, with its vein, *x*.

In Plate XXXVII. the iliacus internus muscle, W, is covered with its tendinous aponeurosis, named fascia iliaca, which unites with the transversalis muscle, I, and its fascia, *i*, **i**, so as to shut up the abdominal cavity. A cellular sheath invests the external iliac artery, T, and its vein, U, which, as they emerge from the abdomen beneath Paupart's ligament, B, as observed in Plate XXXVI., acquire an adventitious covering from the fascia iliaca and fascia transversalis, particularly from the inner or pubic portion of the latter. In Plate XXXVII., on the pubic aspect of the external iliac vein, a dark shade, marked Y, is perceived, which is the internal or abdominal aspect of the crural aperture, that appears almost completely shut up by Gimbernat's ligament, 3, in Plate XXXVI., so that the protruded viscera might descend in the sheath of the blood-vessels.

THE MUSCLES OF THE UPPER EXTREMITY.

PLATES XXXVIII. AND XXXIX.

Superficial to the greater pectoral muscle, there is a layer of condensed cellular tissue, named the pectoral fascia. Superiorly it is continuous with the superficial layer of the deep cervical fascia, inferiorly with the superficial fascia of the abdomen, and at the lower border of the pectoralis major, it passes backwards along the base of the axilla and becomes continuous with the brachial aponeurosis and the dorsal fascia, and outwardly with the deltoid aponeurosis.

The musculus pectoralis major,* letters C, *c*, as represented in Plate XXXVIII. and in Plate XIX., Fig. 1, situated in the upper and anterior, or atlantal and sternal region of the trunk, derives its origin from the two sternal thirds of the clavicle, A, the whole of the sternum, *e*, and from the fifth, sixth, and seventh ribs, a; and ascending obliquely across the axilla with converging fibres, is inserted into the outer or radial ridge of the bicipital groove. Where the muscle arises from the clavicle, A, the fibres are strong and fleshy, and descend rather than ascend along the margin of the deltoid muscle, B; these two muscles being only separated by the cephalic vein, r, Fig. 1, Plate XIX. excepting at their origins, where there is generally some cellular substance; the tendinous insertions being intimately connected. The origin from the sternum, *e*, becomes in its descent more and more tendinous; and at the inferior or sacral portion, the tendinous fibres interlace with those of the external oblique, F, of the abdomen, as represented in Plate XXIX. and more or less with the greater pectoral muscle of the other side, even for some distance upwards or atlantad. The

* Syn. Primus brachium moventium. Primus humeri musculus. Pectoralis. Le grand pectoral. Sterno-huméral. Sterno-costo-clavio-huméral.

inferior or sacral fibres in their course along the axilla beautifully turn inwards to run beneath the superior or atlantal fibres, concentrating the muscle so as to enable it to be inserted by a smaller attachment than its origin: this insertion appears a double tendon. The inferior surface of the muscle is connected by loose cellular substance with the pectoralis minor, and the origins of the coraco-brachialis and the heads of the biceps. Sometimes a muscular slip extends from the pectoralis major obliquely across the axilla to the insertion of the latissimus dorsi muscle, but by no means so frequently as the reverse, see page 57.

The function of this muscle is to throw the arm across the thorax, to elevate the arm when depressed, and to depress it when elevated; likewise to aid in pronating the hand; and also to throw the arm forwards when backwards, as in boxing. When the arm is fixed, this muscle will assist in elevating the trunk to the extremity.* The actions of these muscles of the extremities are easily understood when we know their points of attachments. In Plate XIX., Fig. 1, this muscle is cut across to exhibit the blood-vessels and nerves beneath; and in Plate XXXVIII. the muscle is also cut across to bring into view the pectoralis minor muscle, letters D. The origin and insertion, however, are distinctly seen, the latter being marked *c*: the insertion, *c*, is still more clearly delineated in Plate XXXIX., Figs. 1 and 2, in both of which figures the tendon, *c*, is observed to be inserted on the radial or outer margin of the long tendon, *l*, of the biceps muscle, L.

Musculus pectoralis minor, letters D, *d*,* situated beneath the pectoralis major muscle, letters C, derives its origin from three of the superior ribs near their cartilages, generally the third, fourth, and fifth, sometimes, however, as in this instance, from the second, third, and fourth, by distinct digitations, which are at first tendinous, but soon become fleshy, unite and form a strong carneous mass, that again becomes tendinous immediately before its insertion into the coracoid process, 5, of the scapula. The serrated origins, D, of this muscle intermingle with the external intercostal muscles, Z. The insertion, *d*, is incorporated with the origins of the coraco-brachialis, K, and short head of the biceps, I, muscles, seen also in Plate XXXIX., Fig. 1.† The function of the lesser pectoral muscle is to pull the scapula sternad and atlantad, or forwards and upwards on the thorax; also sternad and sacrad, or forewards and downwards on the chest. When the scapula is fixed, the muscle elevates the ribs in active inspiration: and when the arm becomes elevated and fixed, this muscle will assist in bringing the thorax to the extremity.

Musculus subclavius, M,‡ situated under the clavicle, A, as its name indicates, arising tendinous and fleshy from the cartilage of the first rib, proceeds obliquely beneath the clavicle, and adheres to the bone scapulad near to the coracoid process. This muscle rotates the clavicle sternad or forwards, and in some degree sacrad or downwards. When the clavicle is fixed, it elevates the first rib, as in active respiration: but the rib ossifying at middle age onwards to the sternum, this action will only exist in early life.§ A strong ligamentous expanse, named the costo-coracoid, marked 4, is observed extending between the clavicle, A, and coracoid process, 5, of the scapula, embracing the subclavius muscle, M, and attached to the cartilage of the first rib, and continuous with the deep layer of the cervical fascia. The rhomboid ligament extends between the sternal extremity of the clavicle and the cartilage of the first rib, as represented in Fig. 3 of Plate XXXIX., marked 10.

The ligaments of the sternum, and those connecting the clavicle to the sternum, are delineated in this plate on the left side. The ligamentous fibres of the sternum are observed to derive their origin from the cartilages of the ribs at their articulations, and to extend across to the right side in a radiating manner;‖ these obscure a few longitudinal fibres, some of which, however, are seen descending to the ensiform cartilage, which, along with those arising from the seventh rib, are named ligamentum cartilaginis ensiformis; the former being termed membrana sterni propria.¶ The articulation of one of the ribs, a, to the sternum, e, is laid open, which illustrates the capsular ligament, 3, surrounding the smooth surface of the cartilage of the rib, and the articular depression in the side of

---

* The pectoralis major muscle relates to extirpation of the mamma when attacked with cancer, or medullary sarcoma, to the removal of the axillary glands when similarly diseased, to the securing of the axillary artery when wounded or affected with aneurism in its distal portion, to amputation at the shoulder-joint, and to dislocation of this joint. When the mamma requires extirpation, the patient should be laid on a table or sofa with the arm held at right angles to the body, and the hand slightly supinated, to throw the muscular fibres on the stretch; two semi-elliptical incisions are then to be made from the insertion to the sternal origin of the muscle, or from the region of the axilla to the sternum, the inferior or sacral being made first; these incisions should extend through the skin and cellular tissue to the fascia of the muscle, and both angles or commissures should be clearly defined before proceeding further, as nothing excites more pain to the patient, or looks worse to the eye, than mangling the skin. A few sweeps of the scalpel in the same direction from above downwards will remove the gland, all of which should be invariably extirpated, as this is more easily effected, and there is less chance of a return of the disease. Sometimes a considerable portion of the skin, as well as the muscle, is affected, and requires removal; and hence we see the necessity of cutting in the line of the fibres of the muscle. The reason for making the incisions from axilla to sternum, is to divide at once the root of the long mammary thoracic artery, marked a, in Fig. 1, Plate XIX., since this thoracic branch turns round the greater pectoral muscle, C; the other arteries, marked 14, branches of the internal mammary, being cut across at their roots in any direction.

When the axillary glands are diseased, the first external incision should involve them; but they should not be cut out till the removal of the mammary gland. The arm should be elevated and the hand supinated, to remove this muscle, and to render the axilla as shallow as possible. See page 57.

The manner of securing the axillary artery is detailed in page 57, as also amputation at the shoulder-joint.

When dislocation of the head of the os brachii takes place into the axilla, the great pectoral muscle gradually drags the head of the bone beneath itself, the head of the bone resting on the ribs; this is termed consecutive luxation. The pulley apparatus will in general succeed in returning the bone to its cavity of the scapula within three months after the accident.—See Sir Astley Cooper's valuable work on Fractures and Dislocations, page 36; Lizars' Practical Surgery, page 176. I have succeeded, more than once, at the end of ten weeks.

* Syn. Musculus qui scapulam antrorsum agit. Primus scapulam moventium. Secundus scapulæ. Serratus minor. Serratus anticus minor. Serratus anticus. Le petit pectoral. Costo-coracoïdien.

† The pectoralis minor muscle has no relation to surgery, with the exception of its presenting an obstacle to the operator in his attempt to secure the axillary artery in this region, see page 57, and in being concerned in fracture of those ribs to which it is attached.

‡ Syn. Primus in altero latere thoracem moventium. Primus thoracis musculus. Qui sub-clavicula occultatur. Costo-claviculaire.

§ The subclavius muscle is in some degree concerned in dislocation of either extremity of the clavicle.

‖ Syn. Ligamenta costarum coruscantia. Radiated ligaments.

¶ Membrana ossium sterni.

the sternum. These ligaments are denominated ligamenta capsularia cartilaginum costarum verarum.*

A number of scattered perpendicular ligamentous fibres are observed descending from one cartilage to be inserted into the contiguous cartilage, which are named ligamenta costarum ipsarum propria.

The capsular ligament connecting the sternal extremity of the clavicle, A, to the sternum, *e*,† is marked with the digits 1. This surrounds the smooth surfaces of both bones, and includes a fibro-cartilaginous body, marked 2, to which it adheres. The capsular ligament is subdivided by modern anatomists into the anterior sterno-clavicular ligament, and the posterior sterno-clavicular ligament; and two synovial membranes are described, an external and an internal, the former invests the internal extremity of the clavicle and the outer surface of the fibro-cartilage, the latter or internal lines the articular depression of the sternum and the inner surface of the fibro-cartilage; both also invest the ligaments of the joint. In Plate XXXIX., Fig. 3, this articulation is entire on both sides, and a strong ligament, marked 7, is observed extending from the one clavicle, A, to the other, on the atlantal and central, or upper and posterior, aspect of the sternum, *e*. ‡

Musculus serratus major anticus, letters O, § situated in the lateral aspect of the thorax, derives its origin from the nine superior or atlantal ribs, by distinct fleshy digitations, which immediately unite, and form an elegant expansive muscle, that adheres to the ribs in its progress dorsad to the base of the scapula, into which it is inserted from the superior to the inferior angle. The insertion is distinctly seen in Plate XXXIV., occupying the base of the scapula, between the origin of the subscapularis on the one side, and the insertions of the levator scapulæ and rhomboideus muscles on the other side. The superior origins of this muscle are hid by the pectoralis minor, letters D, and the axillary plexus of vessels and glands. Although all the origins are connected, still a line of separation is generally perceptible onwards nearly to their insertion, and in some cases they are apart, where the superior overlaps the inferior. The function of this muscle is to pull the scapula forwards or sternad on the thorax; and according as the atlantal or the sacral fibres act individually, they elevate or depress the bone. When the scapula becomes fixed, the muscle raises the ribs to the extremity, and hence is employed in active inspiration. ||

* Syn. Ligamenta cartilaginum costarum.

† Syn. Ligamentum capsulare anticum claviculæ; also, anterior sterno-clavicular ligament.

‡ The sternal extremity of the clavicle is sometimes dislocated forwards, backwards, or upwards; the first direction being the most common of this accident. The exposed nature of the joint at once indicates the injury, unless the patient be very fat. The shoulder is to be kept back by the clavicle bandage, with a cushion in the axilla; and a compress should be applied over the sternal extremity of the clavicle, and held there by a roller encircling the shoulders in the figure of 8. After this dislocation, the patient seldom acquires much use of the arm. In a very favourable case I kept the clavicle bandage on for four months, but still no union of the ligaments took place, so as to enable the patient to make any use of the arm. Sir Astley Cooper details a very interesting case of dislocation backwards from disease, wherein the sternal end of the clavicle so pressed upon the œsophagus, as to require to be sawn off. —See his valuable work on Fractures and Dislocations, page 401.

§ Syn. Secundus in altero latere thoracem moventium. Secundus thoracis musculus. Serratus major. Serratus magnus. Le grand dentelé Costo-scapulaire. Costo-basi-scapulaire.

|| The serratus major anticus muscle has no relation to surgery, excepting in fractured ribs.

A delicate aponeurosis invests the deltoid muscle, named deltoid, which is continuous anteriorly with the pectoral fascia; superiorly it is attached to the clavicle, acromion, and spine of the scapula; and distad to the os brachii, where the muscle is inserted, it becomes continuous with the brachial aponeurosis.

Musculus deltoides, letters B, b,* in Plates XIX. and XX., Figs. 1, and Plates XXXVIII. and XXXIX., Fig. 1, situated in the most prominent part of the shoulder, derives its origin from the scapulary third of the clavicle, A, and from the acromion process, D, and spine, of the scapula; it descends over the head of the os brachii with converging fibres, to be inserted into the radial aspect of the middle of this bone. At the origin, the clavicular fibres are occasionally in some degree separated from the acromial, and the latter from those arising from the spine, which makes the muscle have the appearance of three. The clavicular fibres are more fleshy than the spinous, the latter forming a strong tendinous expanse, that is incorporated with the insertion of the trapezius, 80, and which overlaps the infra-spinatus muscle, 81, as represented in Plate XXXIII. The insertion, b, of the deltoid is remarkably strong, and is tendinous where it is incorporated with the greater pectoral muscle, *c*, and fleshy from this radiad, being in some measure connected with the origin of the brachieus internus, M, and the third head of the triceps, *g*: the central or inferior surface is purely tendinous, as depicted in Plate XXXIX., and in Plate XX., Fig. 1.† Where the muscle glides over the head of the os brachii, there is a large bursa mucosa, which is seen in Plate XXXIX., Fig. 1. marked with the letters *a*,‡ formed by a membrano-tendinous expanse common to the deltoid, the infra-spinatus, the teres minor, and the biceps muscles, also to the proper anterior ligament of the scapula. The outer or spinous fibres are connected in their course by cellular substance with the infra-spinatus, the teres minor, and the long head of the triceps; the acromial with the tendinous insertion of the supra-spinatus; and the clavicular with the heads of the biceps and the coraco-brachialis.

The deltoid muscle elevates the arm either directly atlantad, or atlantad and sternad, or atlantad and dorsad, according as either the whole muscle, or its sternal or its spinous fibres are called into action. When the os brachii is fixed, this muscle aids in approximating the trunk to the arm; and when the individual erects himself on his hands, the deltoid preserves the equilibrium, in a similar manner as the gluteal muscles do the pelvis and trunk.

* Syn. Secundus brachium moventium. Secundus humeri musculus, epomis, deltois, et humeralis. Secundus movens humerum. Elevator, attollens humerum, deltiformis. Sous-acromio-huméral. Sous-acromio-clavi-huméral.

† The deltoid muscle relates to amputation at the shoulder-joint, as described in page 57; and to dislocation of this joint, as afterwards detailed. When the head of the os brachii, the form of which is distinctly seen in Plate XXXVIII., beneath the capsular ligament, *e*, is forced into the axilla between the subscapularis muscle, I, and the long head of the triceps muscle, G, there is a depression felt near the origin of the deltoid muscle from the acromion scapulæ, as will be easily understood by comparing Plates XXXVIII. and XXXIX. The deltoid is thrown into violent action, and elevates the arm a little from the side.

‡ This bursa is liable to be attacked with a superabundant secretion of mucus, with matter forming a chronic abscess, with cartilaginous substances, and with hydatids. In either of the two former cases, a small opening and bandage will generally cure the disease; but if no remedies are used, the joint becomes involved, and leads to serious consequences: in the two latter, the bursa requires a freer opening to extract or discharge these substances.

A thin aponeurosis, named brachial, evelopes the muscles of the arm from the shoulder to the elbow-joint: superiorly it is connected to the pectoral fascia, the deltoid and infra-spinal aponeuroses; at the elbow-joint it is continuous with the aponeurosis of the fore-arm. In its progress it furnishes two processes, termed the external and internal intermuscular septa, which are attached to the lateral ridges and the condyles of the os brachii.

Musculus biceps flexor cubiti, letters L, *l*, ⅃, λ, l,* delineated in Plates XXXVIII., XXXIX., and XL., and in Plates XIX., XX., Figs. 1, is situated on the anterior or palmar or thenal aspect of the arm, extending between the scapula and radius; derives its origin by two heads, the longer, *l*, from the superior margin of the glenoid cavity of the scapula, within the capsular ligament of the shoulder-joint, as delineated in Plate XXXIX., Fig. 2; the shorter head, ⅃, from the coracoid process of the scapula, in conjunction with the coraco-brachialis muscle, K. The shorter head, ⅃, remains in connexion with the coraco-brachialis, K, until it joins the longer head, *l;* the longer head, *l*, emerges from the joint, proceeds along the bicipital groove, firmly braced down by a tendinous expanse, and the greater pectoral muscle, until it approaches the point of junction with the shorter head. The two, therefore, unite at the proximal or upper third of the arm, and constitute the strong belly of the muscle, marked L, which descends along the arm to the elbow-joint, forming a long tendon, λ, that runs between the supinators and extensors of the fore-arm on the one side, and the pronator radii teres and flexors on the other side, to be inserted into the tubercle of the radius, as represented in Plate XL., also in Plate XLI., Figs. 2 and 3. At the insertion of the tendon into the tubercle of the radius, there is generally either one or two bursæ mucosæ, as depicted in Plate XL., marked with the digits 2.

At the elbow-joint, the muscle gives origin to a strong tendinous expanse, l, named the semilunar fascia, that descends with oblique fibres across the pronator radii teres muscle, I, and the flexor muscles of the fore-arm, and is incorporated with the general fascia investing these muscles, as represented in Plate XXXIX. and in Plate XIX., Fig. 2.† As the short head descends along the inside of the head of the os brachii, it is connected with the tendon of the subscapularis, where a bursa mucosa frequently exists. In the distal half of the arm, the belly of the muscle is connected by cellular membrane to the brachieus internus.

The biceps muscle elevates the arm, bends the fore-arm, and supinates the hand: it also assists the pectoralis major muscle in bringing the arm to the thorax; and aids the deltoid in throwing the arm and fore-arm forcibly forwards, as in boxing. When the upper extremity is fixed the biceps is used in bringing the trunk to the arm; and when standing on the hands, this muscle assists in preserving the balance.

The coraco-brachialis muscle,* letters K, Pl. XXXVIII. and XXXIX., is situated on the theno-ulnar, or anterior and inner aspect of the arm, ulnad to the short head of the biceps muscle, ⅃, with which it has a common origin from the coracoid process, 5, of the scapula, and with which it descends to the middle of the arm, to be inserted into the ulnar aspect of the os brachii. The origin of this muscle is also connected with the insertion of the lesser pectoral muscle, and is tendinous and fleshy; the insertion appears more fleshy and less tendinous: but on examining that part of the insertion attached to the bone, it is found equally tendinous. This muscle, in its descent, adheres by cellular membrane to the insertion of the subscapularis, the conjoint tendons of the latissimus dorsi and teres major, and the third head of the triceps. To display this muscle, the ulnar margin of the biceps requires to be traced upwards or proximad, till we arrive at the union of the biceps to the coraco-brachialis.† The action of the coraco-brachialis is to assist the biceps in elevating the arm, throwing it across the thorax, and supinating the hand; also in throwing the arm directly forwards, as in pugilism.

The brachieus internus,‡ letters M, in Plates XXXIX., Fig. 1, XL. and XLI., Figs. 1, and 2, also in Plate XX., Fig. 1, situated in the distal half of the arm, on the palmar or thenal aspect, beneath or centrad to the biceps muscle, L, derives its origin fleshy from the os brachii on each side of the insertion, b, of the deltoid muscle, and descends adhering to the bone, and the capsular ligament of the elbow-joint, to be inserted into the coronoid process, 3, of the ulna by a strong tendinous and fleshy mass.§ The origin on the ulnar aspect is connected with the coraco-brachialis, and on the same side as the muscle descends, it is united with the third head of the triceps, the ulnar intermuscular ligament, and the pronator radii teres. On the radial margin this muscle is connected with the triceps, and the supinator radii longus. This muscle bends the elbow-joint.

The triceps extensor cubiti muscle,‖ letters G, g, *g*, in

---

* Syn. Primus flectentium cubitum, præter carnosam partem interiores principii. Primus cubitum flectens, præter alterius initii carnosam partem. Biceps. Cubitum flectentium primus, præter carnosam portionem in humeri medium insertam. Biceps manus. Biceps internus. Biceps brachii. Biceps ou coraco-radial. Scapulo-radial. Scapulo-coraco-radial.

† As matter is sometimes deposited beneath the tendinous expanse of the biceps muscle, we should attend to the course of the fibres so as to divide them, care being taken to avoid the cutaneous veins and nerves as much as possible. See Plate XIX., Fig. 2. The ulnar margin of the belly of the biceps relates to the securing of the brachial artery, as detailed in page 58. The long tendon of the biceps has a relation to amputation at the shoulder-joint, as described in page 57. The muscle is concerned in dislocation of the shoulder-joint, by putting the fore-arm in a semi-bent position; also concerned in dislocation of the elbow-joint when the coronoid process occupies the greater sigmoid cavity, by ithe bone of the fore-arm being forced anconad or backwards of the bone of the arm, making the fore-arm assume the same semi-bent position.

* Syn. Carnosa pars interioris principii cubitum flectentium primi. Carnosa pars alterius initii primi cubitum flectentis. Primi cubitum flectentis insignis musculosa portio, quam inter humeri motores jamdiu recenseo. Coracoideus, sive coraco-brachieus. Portio carnosa quam Placentinus pro peculiari muscule habuit, perforatum appellans. Coraco-brachial. Coraco-huméral.

† The coraco-brachialis relates to the securing of the brachial artery, as detailed in page 58; also to dislocation of the shoulder-joint when into the axilla, by elevating the arm from the side.

‡ Syn. Secundus, seu cubitum flectentium posterior. Secundus cubitum flectens. Cubitum flectentium secundus, brachieus vocatus. Le brachial. Brachial interne. Brachial interne et antérieur. Humero-cubital.

§ The brachieus internus relates to dislocation of the elbow-joint, either when the bones of the fore-arm are forced backwards or anconad of the bone of the arm, or vicê versâ; when the former, this muscle is lacerated, and what remains sound, assists the biceps in putting the arm in a semi-bent position; when the bones of the fore-arm are forced forwards or palmad on the bone of the arm, this muscle is also lacerated.

‖ Syn. Longus est, cubitum extendentium primus; brevis est, tertius cubitum extendentium; brachialis externus, carnosa pars, qua primus extendentium augetur, quem secundum constituere licet. Tertius cubiti;

Plates XIX. and XX., Figs. 1, and in Plates XXXVIII. and XXXIX., is situated on the anconal aspect of the arm, forming the whole muscular mass; the first or long head, G, derives its origin from the inferior costa of the scapula, close to the glenoid cavity, descends along the anconal aspect of the arm, and joins the second head arising from the os brachii from the head downwards or distad, till it meets the third head arising from the remaining anconal surface of the bone; the three heads form a strong muscular mass, that is inserted tendinous into the olecranon ulnæ, as seen in Plate XLII., Fig. 2, marked g, the bone being marked 6. The first head has a broad tendinous origin, that separates the teres major muscle, F, from the minor muscle, 80, as seen in Plate XX., Fig. 1, but is connected with these by cellular membrane. The second and third heads are separated by the spinal nerve, 6, and profunda superior artery, f, as represented in Plate XIX., Fig. 1, and can be only distinguished on the palmar or thenal aspect; for they are united on the anconal; and hence are very perplexing to the young dissector.*

The triceps extends or depresses the arm and fore-arm, assisting the latissimus dorsi and teres major muscles in the first of these functions.†

The anconeus muscle,‡ E, in Figs. 1, and 2, of Plate XLII., is situated on the anconal aspect of the fore-arm in its proximal fourth, and appears as a continuation or appendage of the triceps, g. It derives its origin from the radial or external condyle of the os brachii, by an acute point, and descends with diverging fibres obliquely downwards, to be inserted into the ulna, on its radio-anconal aspect, nearly one-fourth of its length from the olecranon, occupying that triangular space between the olecranon and coronoid process on the anconal aspect of the bone, which is marked 7, in Fig. 6, of Plate VII. The muscle is intimately connected with the capsular ligament of the elbow-joint, with the triceps, g, extensor carpi ulnaris, B, also with the supinator radii brevis, 55.*

The function of the anconeus is to extend the ulna anconad on the os brachii, and hence to assist the triceps in extending the elbow-joint.

When the preceding long muscles extending over the shoulder-joint have been investigated, the short ones round the joint with the ligaments should be examined. The teres major muscle, however, has been forgotten, which might have followed the latissimus dorsi, having the same point of insertion, and appearing at first as an appendage.

The teres major muscle,† letters F, Plates XXXVIII. and XXXIII., also Plates XIX. and XX., Figs. 1, is situated in the inferior or sacral fold of the axilla, being concealed by the latissimus dorsi, E, with which it is incorporated; arises from the posterior or dorsal surface of the inferior or sacral angle of the scapula, and advances along with the latissimus dorsi muscle, keeping on its dorsal or posterior surface, to be inserted conjointly into the ulnar ridge of the bicipital groove.‡ The origin of this muscle is most distinctly seen in Plate XX., Fig. 1, where it is observed arising tendinous, and connected with the expanded tendon enveloping the infra-spinatus, 81, and teres minor, 80, muscles, covering in some measure the origin of the latter. The insertion is represented in Plate XIX., Fig. 1, and in Plate XXXVIII. In Figs. 1 and 2 of Plate XXXIX., the conjoint insertions of the latissimus dorsi and this muscle are more clearly represented, but are only marked with the letter E, which is the index of the latissimus dorsi, since the tendons are so incorporated. On the sternal or thoracic aspect, this muscle is connected with the subscapularis muscle. The function of this muscle is nearly the same as that of the latissimus dorsi, being a depressor of the arm, and a pronator of the hand, by rolling ulnad the os brachii on the glenoid cavity of the scalpula. When the bone of the arm is fixed and elevated, the teres major will assist in bringing the scapula to the arm.

The teres minor muscle, 80,§ delineated in Plate XLII., Fig. 1, is properly an appendage of the infra-spinatus muscle, 81, being enveloped conjointly in a tendinous

---

brevis cum brachiali externo quartus cubiti. Longus; brevis; brachieus externus. Os cubiti extendentium secundus; longus una cum brachiali externo, est os cubiti extendentium primus. Brachieus externus; longus una cum brevi, gemellus. Brachialis externus; biceps externus; triceps totus, triceps cubiti, extensor cubiti magnus, triplici principio natus. Cubiti extensores. Le grand anconé; l'anconé externe; l'anconé interne. Triceps brachii. Scapulo-huméro-olecranien. Tri-scapulo-huméro-olecranien.

* The triceps muscle is concerned in amputation at the shoulder-joint, as described in page 57; also in dislocation of this joint, as afterwards detailed.

† These muscles, as the triceps, biceps, brachieus internus, and coraco-brachialis, should be examined in their relation to amputation of the arm. In every amputation, the surgeon ought to consider what is to be the line of the stump, both as regards the arrangement of the muscles round the bone, and as relates to the exit of the matter while the patient is confined to bed in the horizontal posture. With regard to the former of these, the line of incision or cicatrix should extend from the radial to the ulnar aspect of the arm, so as to have the triceps on the one side, and the biceps with the coraco-brachialis or brachieus internus on the other side. With respect to the position of the limb in bed, the line of cicatrix should run in the reverse direction, or from palmar to anconal aspect. As the arm, however, may be placed in a direction to give exit to the matter, whatever the line of cicatrix may be, this should extend from the radial to the ulnar aspect. When the pulsation at the wrist is found arrested, by an assistant compressing the brachial artery, two semi-elliptical incisions are to be made by transfixing with an amputating knife, their convexities pointing downwards or distad, and their extremes meeting radiad and ulnad; the bone should then be carelessly cleared of the adhering muscular fibre; the flaps held aside by an assistant, and the bone sawn through with long gentle sweeps of the saw, no weight being given to the instrument. The anterior incision should be made first. The artery or arteries are then to be secured, see Plate XIX., Fig. 1. In ascertaining if all the arteries are secured, the pressure should be promptly, not slowly, removed. The ends of the ligatures should be cut off, the lips of the wound approximated, and lint dipped in cold water applied over these. The patient should remain in bed for at least three weeks, to ensure adhesion of the coats of the artery; but this must be regulated by a variety of circumstances, as fever, inflammation, or suppuration. The reason I mention three weeks, I have seen many die from secondary hemorrhage, in consequence of being allowed to get out of bed too soon: again, many sink from too long confinement to bed. See Lizars' Practical Surgery, page 203, *et seq.*

‡ Syn. Anconeus vel cubitalis. Angoneus. Anconæus. Anconeus brevis. Anconeus. Le petit anconé. Epicondylo-cubital.

* This muscle relates to dislocation of the elbow-joint.

† Syn. Tertius brachium moventium. Tertius humeri musculus. Rotundus major. Deprimens humerum rotundus. Le grand rond. Scapulo-huméral. Anguli-scapulo-huméral.

‡ The teres major muscle may be said to have the same relations to surgery that the latissimus dorsi has; that of securing the axillary artery, that of amputation at the shoulder-joint, and to dislocation of this joint, as described in page 91.

§ Syn. Octavus movens humerum. Rotundus minor. Musculus peculiaris a nemine adhuc annotatus, cujus inventionem placentinus, sibi tribuebat. Le petit rond. Plus petit sus-scapulo-trochitérien. Marginisus-scapulo-trochitérien.

expanse, and generally requiring some degree of violence to separate them. The teres minor, situated at the sacral or lower margin of the infra-spinatus, extends along the inferior costa of the scapula, and is separated by the long head, G, of the triceps muscle from the teres major. The teres minor arises from the inferior costa of the scapula, to which, as well as the exterior surface of the capsular ligament of the shoulder-joint, it adheres, and is inserted along with the infra-spinatus muscle, 81, and the supra-spinatus muscle, 66, into the radial and larger tubercle of the head of the os brachii.* The commencement of the origin of the teres minor is concealed by the teres major, as represented in Plate XX., Fig. 1; and the insertion of the muscle is so incorporated with that of the infra-spinatus muscle, 81, that in Plate XXXIX., Fig. 1, the latter only is delineated. The teres minor rotates the head of the os brachii on the glenoid cavity of the scapula, and hence supinates the hand; also depresses the arm sacrad and dorsad, assisting the teres major and latissimus dorsi muscles.

The musculus infra-spinatus, 81,† represented in Fig. 1, Plate XX., in Plate XXXIII., and in Fig. 1, Plate XXXIX., occupies nearly all the infra-spinal fossa of the scapula, and is partly obscured by the deltoid, B, the teres major, F, and latissimus dorsi, E, muscles. The infra-spinatus derives its origin from that portiou of the infra-spinal fossa which is not occupied by the teres major and minor muscles, and from the inferior margin of the spine itself; it proceeds adhering to the exterior surface of the capsular ligament of the shoulder-joint to be inserted along with the teres minor, 80, and the supra-spinatus muscle, 66, into the radial and larger tubercle of the head of the os brachii.‡ This muscle is connected with the teres minor by a strong tendinous aponeurosis, that gives attachment to the tendons of the deltoid and trapezius muscles.

This aponeurosis is named the infra spinal aponeurosis, and is attached superiorly to the inferior edge of the spine of the scapula, and below to the inferior border of the same bone, and to the line at the upper part of the quadrilateral portion near the inferior angle; internally it is connected with the bone between the spine and the inferior angle. A process is sent off from its anterior surface, which passes between the supra-spinatus and teres minor muscles, and is attached to the ridge separating the convex from the elongated portions of the bone.

The insertion is inseparable from that of the teres minor, or of the supra-spinatus, and is with equal difficulty detached from the capuslar ligament: the insertion is depicted in Plate XXXIX., Fig. 1. The infra-spinatus pulls the head of the os brachii dorsad, and rotates it on the glenoid cavity, and hence supinates the hand. The superior fibres contribute to elevate, and the lower fibres to depress the arm.

Superficial to the supra-spinatus muscle is a thin aponeurosis, attached to the upper border of the scapula, the upper edge of the spine, and to its base between the spine and the superior internal angle.

The supra-spinatus muscle, 66,* depicted in Fig, 1, Plate XX., in Plate XXXIII., and Fig. 1, Pl. XXXIX., occupies the supra-spinal fossa of the scapula, being concealed by the insertion of the trapezius muscle, 80, the omo-hyoideus muscle, U, the acromion scapula, D, and the scapular end of the clavicle. This muscle, deriving its origin from the supra-spinal fossa, runs beneath the jugum formed by the junction of the clavicle and acromion scapulæ, adheres to the exterior surface of the capsular ligament in its course, and is inserted into the radial and larger tubercle of the head of the os brachii, together with the infra-spinatus and teres minor muscles. In Plate XXXIII. this muscle is observed to be covered by a strong tendinous expanse, similar to that which covers the infra-spinatus. In Plate XXXIX. the muscle is represented as it advances beneath the clavicle, A, and acromion scapulæ, D, and the origin, B, of the deltoid muscle, to be inserted into the radial tubercle: its tendon adheres strongly to the capsular ligament, and forms part of the bursa, *a*, of the deltoid.†

This muscle assists the deltoid in elevating directly atlantad the arm.

The subscapularis muscle,‡ letters I, in Pl. XXXVIII., and in Figs. 1 and 2 of Plate XXXIX., occupying all the venter of the scapula, adheres by cellular membrane, and sometimes by tendinous bands, to the serratus major anticus muscle, letters O. It arises from the venter of the scapula, and proceeds adhering to the capsular ligament of the shoulder-joint, and running beneath the coraco-brachialis, and short head of the biceps muscle, to be inserted into the ulnar and smaller tubercle of the head of the os brachii. Where this muscle derives its origin from the venter near the base of the scapula, the serratus muscle, O, is inserted; and where the muscle arises near the inferior costa, it is connected with the teres major and minor muscles. In Fig. 2, of Plate XXXIX., the surface of origin of this muscle is marked with the letters *i*: and the tendon where it adhered to the capsular ligament, ℓ, is marked i. A bursa mucosa sometimes exists between the superior or proximal portion of the insertion of this muscle and the capsular ligament, communicating, however, generally with the interior of the joint. In Fig. 1 of the same Plate, the insertion, i, is represented in connexion with the tendon of the supra-spinatus, 66, by strong ligamentous matter, so extending across the bicipital groove as to form a sheath to the long tendon, *l*, of the biceps. §

The function of the subscapularis muscle is to rotate the head of the os brachii inwards or ulnad on the glenoid

* The teres minor muscle relates to amputation at the shoulder-joint, as detailed in p. 57; and to dislocation of this joint, as will be shortly described. In this accident this muscle is more or less lacerated, in consequence of the shortness of the muscular fibres.

† Septimus brachium moventium. Sextus humeri musculus. Circumagentium secundus, super-scapularis inferior. Le sous-epineux. Grand sus-scapulo-trochitérien. Sous-spini-scapulo-trochitérien.

‡ This muscle relates to amputation at the shoulder-joint, as described in page 57; and to dislocation of this joint, as described in page 91. In such an accident, this muscle is more or less torn.

* Quintus brachium moventium. Quintus humeri musculus. Circumagentium humerum primus, super-scapularis superior. Le sus-epineux. Petit sus-scapulo-trochitérien. Sus-spini-scapulo-trochitérien.

† This muscle is concerned in amputation at the shoulder-joint, described in page 57; also in dislocation of the shoulder-joint, as detailed in page 91.

‡ Sextus brachium moventium. Septimus humeri musculus. Immersus sive subscapularis. Circumagentium tertius, subscapularis. Le sous-scapulaire. Sous-scapulo-trochinien.

§ The subscapularis is concerned in amputation at the shoulder-joint, as described in page 57; and in dislocation of this joint, as detailed in page 91. The short distance between its origin and insertion is clearly represented in Fig. 2, and shows how easily and readily this muscle must be lacerated in luxation of the shoulder-joint. The same observation is applicable to the supra-spinatus, the infra-spinatus, and the teres minor muscles.

cavity of the scapula, and hence to assist in pronating the hand. The superior fibres of the muscle assist the supra-spinatus muscle in elevating the arm, while the inferior fibres depress the arm.

The capsular ligament, or fibrous capsule of the shoulder-joint, marked with the letters ℓ, in Fig. 2, of Plate XXXIX., situated beneath or centrad to these short muscles, the subscapularis, supra-spinatus, infra-spinatus, and teres minor, arises round the shallow glenoid cavity, *e*, from the cervix of the scapula, and surrounds the smooth cartilaginous head, *c*, of the os brachii, to be inserted into the cervix of the latter bone. This ligament, consisting of interlaced fibres, is so intimately connected with the preceding short muscles, as to prevent its being injured in the motions of the joint; and they are so closely connected, that in a fresh subject it is extremely difficult to detach these muscles without wounding the ligament. The glenoid cavity is covered with cartilage, and its margin surrounded with a ring of ligamentous substance, named the glenoid ligament, so as to render the socket deeper; and round this cartilaginous brim, between it and the attachment of the capsular ligament, a delicate glandular tissue for secreting synovial juice is placed; a little is also situated where the biceps emerges: indeed, in all the joints, wherever the blood-vessels have latitude and quiescence, these synovial tissues are found.

A synovial membrane invests the fibrous capsule, and by some anatomists considered to cover the glenoid cavity and head of the humerus. Coraco-humeral ligament is a strong band of fibres situated at the upper and anterior aspect of the joint, extending between the coracoid process and the greater tubercle of the os brachii.

The ligamentum proprium scapulæ anticum,* protecting the shoulder-joint in the superior or atlantal aspect, marked 6, in Figs. 1 and 2 of Plate XXXIX., extends from the coracoid process, 5, in a broad triangular expanse, to the acromion process, D, of the scapula.† This ligament is attached to the coracoid process by a greater extent of surface than to the acromion scapulæ; its anterior or distal margin is generally lost in a thin tendinous expanse, which being connected with the deltoid and the short head of the biceps,, assists to form the large bursa mucosa, *a*, of the deltoid muscle.

The ligamentum trapezoideum, and ligamentum conoideum, marked 8, in Figs. 1 and 2 of Plate XXXIX., are, strictly speaking, one and the same ligament, having merely two surfaces which, in consequence of their resembling these geometrical figures, have thus been denominated. The surface looking sternad or forwards, is named trapezoid,* while that which points backwards or dorsad, is termed conoid.† The ligament is connected to the coracoid process, 5, of the scapula by an acute attachment, while it spreads out in its connexion with the clavicle, A, so as to extend near to its scapulary extremity, occupying a rough surface on the inferior or sacral aspect of the bone.‡ Sometimes these ligaments are quite distinct, being separated by the tendinous termination of the insertion of the subclavius muscle.

The capsular ligament or fibrous capsule connecting the scapulary extremity of the clavicle to the scapula, is represented in Fig. 1 of Plate XXXIX., marked 9, where there are also observed strong short exterior ligamentous fibres extending between these bones. These ligamentous fibres appear to be chiefly the tendinous insertion of the trapezius muscle. These are considered by modern anatomists two ligaments, named the superior acromio-clavicular and the inferior acromio-clavicular ligaments; the former extending across the upper aspect of the joint, and the latter across the lower aspect. A synovial membrane invests this fibrous capsule. The articulation here being extremely small and shallow,

---

* Named also ligamentum scapulare proprium anterius, and the acromio-coracoid ligament.

† All the objects connected with the shoulder-joint have now been described, and it must appear evident, that this articulation is least protected at the inferior or sterno-sacral aspect, between the insertion of the subscapularis muscle, I, and the conjoint insertion of the latissimus dorsi, E, and teres major, F, muscles, as represented in Plate XXXVIII., where the muscles are not insulated: and here it is observed that the joint is protected inferiorly or sacrad, by the long head, G, of the triceps muscle. As a natural consequence of this feeble protection, when the arm is violently raised, twisted, or receives a blow upon the shoulder, the head of the os brachii ruptures the capsular ligament, and protrudes in this direction. When the head of the bone of the arm is thus dislocated into the axilla, the capsular ligament is, and must be, always lacerated, as well as one or more of the short muscles torn. The muscles that are put on the stretch are the deltoid, the supra-spinatus, the infra-spinatus, the teres minor, and the biceps; the position of the arm, therefore, is semi-bent, and raised a little outwards from the side. There is a conspicuous depression beneath or distad to the acromion scapulæ, in place of the round swell of the shoulder; and the patient inclines the trunk to the arm to relax the muscles, and supports the arm on his knee, or with the other hand. Besides the direction into the axilla, the head of the os brachii is sometimes forced beneath the subscapularis muscle, between it and the venter of the scapula, and sometimes on the body of this muscle; at other times beneath the infra-spinatus and teres minor muscles, between them and the infra-spinal fossa or dorsum of the scapula, and occasionally on the surface of these muscles. When dislocation occurs upwards, the head of the os brachii is on the coracoid process, close to the clavicle. After the first dislocation into the axilla, reduction not being attempted or effected, the head of the bone of the arm is gradually dragged up on the thorax by the pectoralis major muscle and the biceps, and the latissimus dorsi muscle assists by pulling on the shaft of the bone, and hence forces upwards the head: this direction, however, in place of being consecutive, as thus described, is generally primary, as stated by Sir Astley Cooper, in his work on Fractures and Dislocations.

In one and all of these species of dislocations, when recent, reduction is extremely easy and simple. When the luxation has been of some days' standing, the pulley apparatus becomes indispensable. The objects the surgeon should have in view, are, to fix properly the scapula, to extend slowly and gradually in the direction in which the bone of the arm lies, and when the head of the bone appears opposite its glenoid cavity, to relax suddenly the apparatus, and bend the arm downwards by the side. For example: When the head of the bone of the arm is dislocated into the axilla, and when the scapula has been properly fixed, the arm should evidently be raised a little above the horizontal plane before extension is begun, as the head of the bone must have been in this direction when dislocated, or would assume this direction, did not the weight of the whole arm prevent it. After recent dislocation, a wet hand-towel should be put round the arm, immediately above the elbow-joint, and to this should be affixed the two ends of a dry towel or sheet, the noose of which is to be thrown round the shoulders of the operator, while the patient lies on his back. The surgeon then puts his heel into the axilla of the patient, and then gradually extends, directing the head of the bone of the arm opposite the glenoid cavity. So easily is the reduction effected, that he can scarcely believe the joint was luxated. In old dislocations, the warm bath, the tartrate of antimony administered to produce sickness, and even bleeding, are beneficial; but the apparatus should be ready to be applied during this state of the system, otherwise the muscles soon regain their rigidity and resistance. The mind has considerable influence in opposing an obstacle to reduction, for if diverted, the bone is easily reduced.—For further information on dislocation of the shoulder-joint, consult Dessault, Pott, Sir Astley Cooper, and Lizars' Practical Surgery, p. 169.

* Syn. External coraco-clavicular ligament.

† Syn. Internal coraco-clavicular ligament.

‡ This powerful ligament prevents the frequent dislocation of the scapulary extremity of the clavicle.

the articular surfaces in the dried bones are barely perceptible.*

The ligamentum proprium scapulæ posticum† is marked *a* in Fig. 2 of Plate XXXIX., and is also represented in Fig. 1, Plate XX. It extends between the root of the coracoid process, 5, and the contiguous commencement of the superior costa, *b*, of the scapula, making the notch a foramen, that gives passage to the supra-scapular nerve, artery, and vein; the two latter of which here drawn truncated, are delineated in Plate XX., Fig. 1, and the notch, *o*, with a dotted line representing the ligament, is depicted in Plate VII., Figs. 1 and 2.

The muscles of the fore-arm should next be examined; they arrange themselves into pronators and supinators; and into flexors and extensors; the supinators and extensors are more or less connected with the external condyle of the os brachii, and one of the pronators with the majority of the flexors are more or less attached to the internal condyle of the same bone: the extensors are subdivided into those which extend the carpus, and those which extend the fingers in general; the flexors are subdivided into those which inflect the carpus, and those which bend the fingers, the latter of which have muscles acting as auxiliaries. Besides these classes of muscles, some are peculiar to the thumb, others peculiar to the fore-finger, and others again to the little finger.

These muscles of the fore-arm are encased in an aponeurosis named the cubital which is continuous with the brachial; it receives an addition from the tendon of the biceps termed the semilunar fascia, and another from the tendon of the triceps muscle. Inferiorly or distad it unites with the annular ligaments of the wrist-joint. It is also attached to the olecranon ulnæ and the posterior border of the ulna. In its progress it sends off numerous processes which descend between the muscles, and which are named intermuscular septa.

The two pronators are represented in Plates XL. and XLI.; the teres in Plate XL. is marked I, the quadratus in Plate XLI., Figs. 1 and 2, is marked 50. These are also drawn in Plates XIX. and XX., Figs. 2.

The musculus pronator radii teres, I,‡ situated in the upper or proximal half of the thenal or palmar aspect of the fore-arm, deriving its origin from the internal or ulnar condyle of the os brachii, descends obliquely downwards or distad to the radial or outer margin of the fore-arm, and is inserted into the radial and somewhat anconal aspect of the middle of the radius. The origin of this muscle, distinctly seen in Plate XXXIX., Fig. 1, where it is observed to arise chiefly fleshy and highest or most proximad of the muscles connected with the internal condyle, is, properly speaking, attached to the ridge proximad of this condyle. The brachieus internus muscle, M, is on its proximal aspect, the supinator radii longus, N, on its radial, and the flexor carpi radialis muscle, P, on its distal and ulnar margin. A delicate ligament, named the internal or ulnar intermuscular ligament, marked in Fig. 2, Plate XLI., with the digits 28, separates the precise origin of this muscle from the triceps, *g*. The insertion is bounded proximad by the supinator radii brevis, 55, and distad by the flexor digitorum sublimis, R; running beneath the supinator longus, N, and the two radial extensors, H, *h*. In its course deriving origin from the brachieus internus, the flexor carpi radialis, and the flexor digitorum sublimis, it is frequently pierced by the median nerve. This muscle, and all those of the fore-arm, are intimately connected by the fascia of the fore-arm, as exemplified in Fig. 2, Plate XIX.; and this muscle, together with the flexors, is still more incorporated by the fascia, l, of the biceps, represented in the Plate just alluded to, and more distinctly seen in Fig. 1, Plate XXXIX. The manner of separating these muscles, therefore, is to find out first their tendinous insertions, and retrace them to their origins. The insertion of the pronator radii teres, partly tendinous and partly fleshy, runs around the radius; and a scabrous surface is observed on the bone, as delineated in Plate VII., Figs. 5 and 6, letter *g*.*

This muscle pronates the hand, as its name indicates, and also inflects thenad the fore-arm on the arm. I shall next describe the pronator quadratus, in order to impress on the mind the classification of these muscles of the fore-arm, although it does not come in the order of dissection. The drawings are taken in this order, so that the student can easily investigate them when engaged in prosecuting practical anatomy.

The pronator quadratus muscle,† marked with the digits 50, in Plate XL., and in Figs. 1 and 2 of Plate XLI., also in Plate XX., Fig. 2, is situated at the distal extremity of the bones of the fore-arm, on the thenal aspect, deeply beneath the various flexors. This muscle is represented alone in Fig. 2 of Plate XLI., arising tendinous and fleshy from the ulnar angle of the ulna, and proceeding with fleshy fibres transversely across, adhering to the interosseous ligament, to be inserted with fleshy and tendinous fibres into the radial and also the anconal aspect of the radius. The insertion runs beneath the supinator radii longus, N; and the distal margin of the fibres adheres to the sacciform ligament. The action of the muscle is to assist the teres in pronating the hand.‡

The antagonist muscles of these two preceding pronators, are two snpinators, a long and a short.

---

* Luxation of the scapulary extremity of the clavicle more frequently occurs than that of its sternal end. In this the clavicle starts above the acromion scapulæ on which it rests, so that there does not appear to the surgeon much derangement of structure; the capsular ligament of the joint, and the greater portion of the coraco-clavicular ligament only is torn: sometimes, however, all this ligament is lacerated. If the spine of the scapula is traced from the base onwards to the acromion, the elevated end of the clavicle will interrupt the fingers. A cushion put into each axilla, and the shoulders braced backwards by the clavicle bandage, will reduce the clavicle, and keep it in situation. The straps of the bandage, particularly that over the luxated joint, should be sufficiently broad to cover the bone; and it sometimes requires a pad affixed to it. The fore-arm should be placed across the chest, and supported by a bandage.

† Syn. Posterior or coracoid ligament.

‡ Syn. Tertius radium peculiariter agentium. Septimus manus interior musculus. Superior pronator rotundus. Pronator secundus, sive teres. Pronator teres. Le pronateur rond, ou l'oblique. Grand pronateur. Epitrochlo-radial.

* The pronator radii teres relates to the securing of the radial artery, as detailed in page 59; to luxation of the elbow-joint; and to fracture of either the radius or ulna, or both. When one or both of these bones are fractured, the pronators, being more powerful than the supinators, pronate the hand, an attitude which must be counteracted by splints and bandage.

† Syn. Primus radium peculiariter agentium. Octavus manus interior musculus. Inferior pronator quadratus. Pronatorum primus, sive quadratus. Pronator radii quadratus. Pronator radii quadratus, or inferior quadratus. Le pronateur quarré, ou transverse. Petit pronateur. Cubito-radial.

‡ The pronator quadratus can have little concern in either dislocation or fracture; in the latter, it tends to pronate the hand, an attitude to be avoided in either fracture of the radius or ulna, or both.

The musculus supinator radii longus,* N, in Fig. 1 of Plate XXXIX., in Plate XL., and in Fig. 1 of Plates XLI. and XLII., also in Plates XIX. and XX., Figs. 2, situated on the radial margin of the fore-arm, derives its origin from the radial ridge of the os brachii proximad to the radial or outer condyle, and descends spirally along the fore-arm to the thenal or palmar aspect, to be inserted into the distal extremity of the radius, somewhat on its palmar aspect, being partially overlapped by the extensor ossis metacarpi pollicis, *a*.† The origin of this muscle is very high up or proximal on the os brachii, and is the most superficial or proximal of the muscles connected with the external or radial condyle; it is fleshy, and is separated from the triceps, g, by the external or radial intermuscular ligament, 25, as seen in Figs. 1 and 2 of Plate XLII. In its proximal and thenal margin, this muscle is intimately connected with the brachieus internus, the spiral nerve, 6, forming the only division; as the muscle descends, the thenal and ulnar margin is attached first to the pronator teres, I, and secondly, to the flexor carpi radialis, P. The anconal margin of the muscle is attached to, and in some measure overlaps the extensor carpi radialis longior, H. The muscle becomes tendinous about the distal third of the fore-arm, and is inserted into a ridge of the radius, as delineated in Plate VII., Fig. 5, letter *l*.

This muscle, as its name indicates, supinates the hand, though that able anatomist Dr. Barclay is of opinion, that it merely co-operates with, and moderates alternately the pronators and supinators, bringing the radius to that middle state which is properly neither pronation nor supination, and performing this office with the greatest force when the arm is extended.

The supinator radii brevis muscle,‡ marked with the digits 55, in Plate XL., and in Fig. 1 of Plate XLI., also in Fig. 2 of Plate XLII., is situated on the radial aspect of the proximal third of the fore-arm, beneath all the extensors, adhering close to the bones; derives its origin from the external or radial condyle of the os brachii, descends adhering to the capsular ligament, and embracing the radius from the head downwards about the proximal third, where it is inserted immediately above or proximad to the insertion of the pronator radii teres, I. This muscle is completely concealed by the long supinator, N, and the radial extensors, H, *h*, of the carpus. The origin, and for some extent on the anconal aspect, the muscle is so connected with the extensor digitorum communis, D, that it may be said to arise from the latter; the origin from the condyle is also very closely attached to the extensor carpi radialis brevior, *h*: this muscle arises likewise from the ulna where the anconeus, E, is inserted. The insertion is bounded on the anconal aspect by the extensor ossis metacarpi pollicis, *a*. Sometimes a portion of the origin of this muscle is so strong and tendinous as to be mistaken for the external or radial lateral ligament, 25, of which it in reality forms a part. The deep branch, 26, of the spiral nerve, 6, pierces the substance of the muscle as represented in Plate XL., and in Plate XX., Fig. 2.* This muscle assists in supinating the hand, and prevents the capsular ligament being injured in the motions of the elbow-joint; it must also contribute greatly to the support of the joint.

After the pronators and supinators have been investigated in this order of classification, the flexors and extensors of the carpus should be examined. The flexors are two in number, a radial and an ulnar, while their antagonists the extensors are three in number, an ulnar and two radial; the latter, however, might be considered one muscle with two tendinous insertions.

The flexor carpi radialis,†, P, in Plate XL., in Fig. 1 of Plate XXXIX., in Figs. 1 and 2 of Plate XLI., and in Plate XIX., Fig. 2, situated on the thenal or palmar aspect of the fore-arm, between the pronator radii teres, I, and the palmaris longus, Q, derives its origin from the internal or ulnar condyle of the os brachii, descends obliquely along the fore-arm near the radial margin, to the palmar annular ligament, U, of the carpus, beneath which it runs in a groove of the os trapezium, as represented in Plate XLI., Figs. 1 and 2, to be inserted into the base or root or proximal extremity of the metacarpal bone, 2, of the fore-finger.‡ At its origin, this muscle is connected to the pronator teres and the other flexors, and even for the whole length of its carneous fibres is connected with the pronator teres and the palmaris longus, also with the flexor digitorum sublimis, from which it appears as if deriving fleshy fibres. The tendon begins about the middle half of the fore-arm, and is bold and strong; in the groove of the trapezium, it is encased in a vaginal ligament, remarkably strong, and to which it adheres; and beyond the groove of the trapezium, it runs beneath the flexor longus pollicis, x, the inner or central head, *z*, of the flexor brevis pollicis, and the adductor pollicis, w, all of which is distinctly seen in Figs. 1 and 2 of Plate XLI.

This muscle inflects thenad the carpus on the fore-arm, and the fore-arm on the arm; also assists in pronating the hand; likewise inflects the carpus radiad.

The flexor carpi ulnaris,§ s, Plate XL., and Fig. 1, Plate XLI., also in Figs. 2, Plates XIX. and XX., situated on the thenal or palmar aspect of the fore-arm, close to the ulnar margin, arises from the internal or ulnar condyle of the os brachii, and from that space of the ulna between its olecranon and coronoid processes; also from

* Syn. Quatuor radium peculiariter agentium secundus. Octavus manus exterior musculus longissimus nuncupatus. Longus supinator. Supinatorum primus sive longior. Supinator longus. Grand supinateur. Brachio-radialis. Huméro-sus-radial.

† The supinator longus muscle relates to the securing of the radial artery, as described in page 59; and to dislocation of the elbow-joint, as well as to fracture of the bones of the fore-arm.

‡ Syn. Quartus radium peculiariter agentium. Nonus manus exterior musculus. Brevis supinator. Supinatorum secundus. Supinator brevis. Le court ou petit supinateur. Epicondylo-radial.

* The supinator radii brevis relates to dislocation of the elbow-joint.

† Syn. Secundus brachiale moventium. Tertius interior manus musculus. Radieus internus. Flectentium carpum exterior. Radialis internus. Le radial interne. Le radial antérieur. Grand palmaire Epitrochlo-métacarpien.

‡ The flexor carpi radialis relates to the securing of the radial artery, as described in page 59. When this artery becomes the seat of operation in the proximal third of the arm, the most easy way to ascertain its course, is to retrace the tendon of this muscle upwards or proximad, making a calculation as we advance for the intervention of the pronator teres muscle; the two latter with the supinator radii longus form the boundaries of the radial artery, and these muscles are so connected by the fascia of the arm, as to conceal completely the vessel, in the two upper or proximal thirds of its course. This muscle also relates to dislocation of the elbow and wrist-joints, and to extirpation of the metacarpal bone of the fore-finger.

§ Syn. Primus brachiale moventium. Secundus musculus interior manus. Cubiteus internus. Flectentium (carpum) interior. Flexor carpi ulnaris. Ulnaris internus. Cubital interne. Cubito-carpien. Epitrochlo-cubito-carpien.

the ulnar angle of the same bone downwards or distad upwards of two-thirds of the bone, descending on the ulnar margin of the fore-arm to be inserted into the os pisiforme, T, of the carpus.* The origin from the os brachii is chiefly tendinous, that from the ulna is partly tendinous and partly fleshy; as the muscle descends it appears to grow from the ulna: between the muscle and the projection of the ulnar condyle, the ulnar nerve twines round, as represented in Plate XIX., Fig. 1, and Plate XLII., Fig. 2. The palmaris longus muscle, Q, intervenes between this and the flexor radialis. As the muscle extends along the ulna, it is connected with the extensor carpi ulnaris, B, as seen in Figs. 1 and 2, of Plate XLII., on its anconal aspect, and with the palmaris longus, Q, the flexor digitorum sublimis, R, and profundus, W, on its central and radial aspects. Its insertion is more or less connected with the palmar annular ligament, U.

The extensor carpi ulnaris,† B, in Figs. 1 and 2 of Plate XLII., and in Plate XXI., situated on the ulnar margin of the anconal aspect of the fore-arm, derives its origin from the external or radial condyle, *q*, of the os brachii, in conjunction with the extensor communis, D, and the anconeus, E, from the capsular ligament of the elbow-joint, and from the ulnar margin, 12, of the ulna nearly the two proximal thirds, then becoming tendinous, and running beneath the annular ligament, U, in a groove of the ulna between the distal head and the styloid process onwards to be inserted into the proximal extremity or root of the metacarpal bone, 5, of the little finger. The radial margin of the muscle is connected with the supinator radii brevis, 55, the three extensors of the thumb, *a*, *b*, *c*, and the indicator, *f*.‡

The function of this muscle is to extend the carpus or wrist-joint anconad, also to inflect it ulnad, and to extend the ulna on the os brachii or the elbow-joint.

The extensor carpi radialis is divided into two muscles, a longior, H, and a brevior, *h*, as seen in Plate XLII,. Figs. 1 and 2. The extensor carpi radialis longior, H,§ situated immediately beneath the supinator radii longus, N, on the radial margin of the fore-arm, derives its origin from the radial ridge of the os brachii, proximad to the radial or outer condyle, descends in company with the brevior, *h*, along the radial margin of the radius, becoming tendinous near the proximal third of the fore-arm, and continues its course beneath the three extensors, *a*, *b*, *c*, of the thumb and the annular ligament, U, to be inserted into the root or proximal extremity of the metacarpal bone, 2, of the fore-finger. The origin purely fleshy, is intimately connected with the long supinator, N, the extensor carpi radialis brevis, *h*, and the brachieus internus, M; the external or radial intermuscular ligament, 25, separates the precise origin from the triceps, g, as delineated in Fig. 2. In the same figure, the insertion is more distinctly seen.*

The function of this muscle is to extend the carpus on the distal extremity of the radius, or to inflect anconad the wrist-joint, and to extend the ulna on the os brachii, or to inflect anconad the elbow-joint. It also inflects the carpus radiad.

The extensor carpi radialis brevior,† *h*, Plate XLII., Figs. 1 and 2, is situated immediately beneath the extensor carpi radialis longior, H, on the radial margin of the radius; derives its origin from the radial or external condyle of the os brachii, and descends along the supinator radii brevis, 55, and the radius itself, forming a long tendon that runs beneath the three extensors of the thumb, *a*, *b*, *c*, and the annular ligament, U, to be inserted into the proximal extremity or root of the metacarpal bone, 3, of the middle finger. The origin is a strong roundish tendon, that is closely attached to the longior, H, and to the extensor digitorum communis, D, and also adheres to the capsular ligament of the elbow-joint The insertion is in some degree covered by the tendon of the extensor communis, that goes to the fore-finger. ‡

The function of this muscle is precisely the same as that of the extensor longior.

The palmaris longus muscle, Q,§ in Plate XL., and in Fig. 2, Plate XIX., situated in the centre of the palmar or thenal aspect of the fore-arm, between the flexor carpi radialis, P, and flexor carpi ulnaris, S, muscles, derives its origin from the ulnar or internal condyle of the os brachii, descends somewhat spirally along the fore-arm, and forms an elegant long tendon, which at the annular ligament, U, of the carpus, spreads with radiating fibres, marked V, extending over the whole palm of the hand, and inserted into the cutis vera. The origin is acute, strong, and chiefly tendinous, and intimately connected with the flexor carpi radialis, P, and the flexor digitorum sublimis, R, the former of which it approaches nearer and nearer in its descent along the fore-arm, while it rests on the latter. It becomes tendinous near the upper or proximal half of the fore-arm.‖ At the carpus it is strongly connected

* The flexor carpi ulnaris relates to the securing of the ulnar artery, as described in page 59. When this artery requires to be taken up, the operator should retrace the flexor ulnaris from its insertion into the pisiform bone, upwards to where the artery is to have a ligature thrown around. This muscle relates also to dislocation of the elbow and wrist-joints, and to fracture of the radius and ulna.

† Syn. Tertius brachiale moventium. Sextus manus exterior musculus. Cubiteus externus. Extendentium (carpum) interior. Extensor carpi ulnaris. Ulnaris externus. Le cubital externe. Le cubital postérieur. Cubito-sus-métacarpien. Epicondy-cubito-sus-métacarpien.

‡ The extensor ulnaris relates to dislocation of the elbow and wrist-joints, and also to extirpation of the metacarpal bone of the little finger.

§ Syn. Pars quarti brachiale moventium. Pars septimi manus exterioris musculi. Radieus externus qui ab acumine osseo seu a condylo externo brachii enascitur. Pars extendentium carpum exterioris. Radialis externus longior. Extensor carpi radialis longus aut superior. Radialis externus longus. Le premier radial externe. Grand radial. Huméro-sus-métacarpien.

* The extensor carpi radialis longior relates to dislocation of the elbow and wrist-joints, and to fracture of the radius and ulna.

† Syn. Pars quarti brachiale moventium. Pars septimi manus exterioris musculi. Brevior radieus externus, qui à condylo externo brachii oritur. Radialis externus brevior. Extensor carpi radialis brevis seu inferior. Radialis externus brevis. Le second radial externe. Petit radial. Epicondylo-sus-métacarpien.

‡ The extensor carpi radialis brevior has the same relation to surgery that the longior has.

§ Syn. Musculus, nervosa sua exilitate mediæ volæ et internæ digitorum sedis cuti subnatus. Primus musculus manus interior. Latescentis chordæ musculus. Palmaris. Le cubital grêle, communément nommé long palmaire. Le palmaire grêle, ou long palmaire. Grand palmaire. Epitrochlo-palmaire. Epitrochlo-carpi-palmaire.

‖ The palmaris longus relates to the securing of the ulnar and radial arteries in the carpus, as described in page 59, to injuries of the hand, to abscesses, to dislocation of the wrist-joint and the elbow-joint. When matter is deposited beneath the fascia palmaris, free exit should be given by incisions, even at the risk of the arteries; for when these are wounded, a piece of dry lint and bandage will stem the hemorrhage. Frequently after inflammation of the fascia palmaris, with or without abscess, a contraction of it takes place, so as to bend palmad one or all of the fingers, and retain them in this attitude, thus rendering them of little or no use to the individual. I have examined a number

with the annular ligament, U, from which it appears to derive additional tendinous fibres. The expanse of the tendinous aponeurosis becomes delicate over the muscles of the thumb and of the little finger.

The tendinous threads connected with the cutis vera are inserted chiefly at the roots of the fingers;* some, however, descend between the fingers, run along and around to their anconal aspect; while others run also along the thumb. Some descend on each side of the flexor tendons, and are inserted into the heads of the metacarpal bones. At the roots of the fingers in the palm of the hand there are a number of strong transverse threads interlacing and connecting the longitudinal ones.

The function of this muscle is to corrugate the integuments of the hand during its various motions, to inflect thenad or palmad the first or proximal joints of the fingers, the wrist-joint, and the elbow-joint. It also moves the metacarpal bones on the carpal, and the carpal on each other, and assists in pronating the hand.

The palmaris longus muscle is occasionally deficient, but never the palmar tendinous expanse.

Palmaris brevis muscle,† 54, of Plate XL., situated on the ulnar aspect of the palm of the hand, close to the os pisiforme, T, consists of a few scattered delicate muscular fibres, that arise from the ulnar margin of the tendinous aponeurosis, V, of the palmaris longus, Q, and run imbedded in the adipose substance, to be inserted by elegant tendinous threads, into the cutis vera covering the ulnar margin of the hand, immediately superficial to the origin of the abductor minimi digiti manus, 51.‡ The use of this muscle is to corrugate the skin of the hand in this region.

The flexor digitorum sublimis perforatus, § R, r, in Plate XL., and in Figs. 2, Plates XIX. and XX., situated on the palmar aspect of the fore-arm, hand, and fingers, and partially obscured by the flexor carpi radialis, P, and the palmaris longus, Q; derives its origin from the ulnar or internal condyle of the os brachii, from the coronoid process of the ulna, the capsular ligament of the elbow-joint, and the ulnar aspect of the upper or proximal half of the radius; the fleshy mass descending along the fore-arm, rests on the flexor digitorum profundus, W, becomes tendinous near the annular ligament, U, of the carpus, beneath which it runs, dividing into four distinct round tendons, marked with the letters r, that advance along the palm of the hand and the fingers, to be inserted into the proximal extremities, or roots of the second or middle phalanges, adhering nearly to the distal extremities of these little bones. The origin of this muscle is intimately connected with the flexor carpi radialis, P, the palmaris longus, Q, the flexor carpi ulnaris, S, the flexor digitorum profundus, W, the brachieus internus, M, and the pronator radii teres, I. The ulnar nerve, 5, and ulnar artery, *h*, the latter of which pierces the muscle, separate it from the flexor profundus, W, on its ulnar margin, while the median nerve, 2, which also pierces the muscle, separates it from the profundus, W, and the flexor longus pollicis, X, on the radial margin. Near the first or proximal joints of the fingers, the tendons, r, together with those, w, of the flexor profundus, W, are encased in strong tendinous sheaths, 30: and between the first and second joints, the tendons are split into two, *r*, by the passage of the tendons, w, of the profundus, W. The divided tendons, *r*, diverge a little, so as to run near the edge of the bone. These tendons are generally bound down to the bones in their course by tendinous slips.* Where the tendons run in a mass beneath the annular ligament, U, there is a bursa mucosa or synovial bursa between this muscle and the flexor profundus.†

The vaginal ligaments,‡ 30, of these tendons, extend from the first to the last joint of each finger, and are strongest at the joints. They are attached to the longitudinal ridges at the side of each phalanx, see Plate VII., Fig. 8, dig. 21, and have a mucous or synovial surface looking to the tendons, or pointing centrad. §

At the roots of the fingers, the posterior or anconal surfaces of these sheaths are firmly tied to each other by strong transverse ligaments, as represented in Fig. 1 of Plate XLI., marked 34.

The function of this muscle is to bend the elbow-joint, the wrist-joint, and the first and second joints of the fingers; and also to assist in pronating the hand, and in inflecting ulnad the carpus.

The flexor digitorum profundus perforans, W,‖ in Plate XL., and Fig. 1 of Plate XLI., also in Fig. 2, Plate XX., situated on the palmar aspect of the fore-arm, hand, and fingers, and obscured by the flexor carpi radialis, P, the palmaris longus, Q, the flexor digitorum sublimis, R, and the flexor carpi ulnaris, S, derives its origin from the ulna, between the olecranon and coronoid processes, and from the ulnar angle of the same bone three-fourths of its

---

of such cases which have come into the dissecting-room, and all of these have had the flexor tendons sound and free in their sheaths, proving incontestably that they are never the seat of the contraction. I have kept one as a preparation. When, therefore, such a contraction occurs, a free transverse division of the integuments, and the fascia palmaris threads, now greatly thickened by disease, should be made across that, or those joints which are the seat of the disease. The fingers then ought to be kept extended till the wounds are healed. In confirmation of this opinion, see Sir Astley Cooper's valuable work on Fractures and Dislocations, page 524; and Lizars' Practical Surgery, page 188.

* Syn. Ligamenta cutanea digitorum.

† Est un altro musculo, che distende questa tela. Primus extremæ manus musculus scriptoribus ignotus. Caro quædam, quæ musculorum effigiem habet. Carpiens vel palmaris brevis. Caro quædam quadrata. Le palmaire cutané.

‡ This muscle has little or no relation to surgery.

§ Syn. Primus digitos moventium. Quartus manus interior musculus. Primus musculus. Sublimis. Digitorum secundi internodii flexor. Perforatus. Le sublime perforé, communément le sublime. Fléchisseur digital superficiel. Epitrochlo-phalanginien commun. Epitrochlo-coronio-phalanginien. Flexor digitorum superficialis.

* Syn. Accessory ligaments of the flexor tendons. Tendinous fræna.

† This muscle relates to dislocation of the elbow-joint, the wrist-joint, and the proximal and medial joints of the fingers. It is also concerned in fractures of the radius, ulna, metacarpal bones, and bones of the first and second phalanges of the fingers, and in amputation of those members. It is likewise more or less concerned in the extirpation of either of the bones of the fingers. Sometimes one of the tendons, together with that of the profundus and their vaginal ligament, so contract as to dislocate the proximal and medial phalanges, and prove so troublesome and inconvenient as to require amputation. See Sir Astley Cooper on Fractures and Dislocations, page 523.

‡ Syn. Crucial ligaments of the phalanges. Annular ligaments. Annuli juncturarum ligamentosi. Annuli vel ligamenta obliqua sive cruciata phalangis primæ et secundæ. Fibrous sheaths of the flexor tendons.

§ These vaginal ligaments are often involved in the inflammation and suppuration of paronychia or whitloe, and require free incisions to give exit to the matter collected within them.

‖ Syn. Secundus digitos moventium. Quintus manus musculus interior. Secundus. Profundus. Flexor tertii digitorum internodii. Perforans. Le profond. Le perforant communément le profond. Fléchisseur digital profond. Cubito-phalangettien commun.

length, also from the interosseous ligament. This thick muscular mass descends along the fore-arm, becomes tendinous about the middle, and near the annular ligament, U, beneath which it runs, divides into four tendons, W, that advance along the palm of the hand, to the middle of the first phalanx, where they pierce the tendons, *r*, of the flexor sublimis, R, and continue their course onwards to the last phalanx, into the proximal extremity of which they are inserted by a radiated expanse. The radial margin of the muscle is closely attached to the flexor longus pollicis, X, and the ulnar margin to the flexor carpi ulnaris, S. Where the conjoint tendons run beneath the annular ligament, there is a bursa mucosa placed between the tendons and the bones of the carpus. Where the tendons lie in their vaginal ligaments, or fibrous canals, they are tied down to the bone by tendinous slips. *

The function of this muscle is to inflect thenad the carpus on the radius and ulna, the proximal phalanx on the metacarpal bones, the medial or second phalanx, on the first or proximal, and the third or last or distal phalanx on the second or medial phalanx. This muscle also assists in inflecting the carpus ulnad.

Connected with the tendons of the flexor profundus, are four slender muscles, named lumbricales,† **w**, which are situated in the palm of the hand, and arise from the radial margins of these tendons as they emerge beyond the annular ligament, U; they proceed spirally along, and as they run round the first phalanx, form elegant slender tendons, that are inserted into the broad tendinous expanse of the extensor digitorum communis, D. At first they appear to be connected with the tendons of both the profundus and sublimis. Sometimes there are two to one finger, leaving one of the fingers deficient; and sometimes that to the little finger arises from the tendon of the ring finger. The function of these muscles is to inflect thenad and in some degree radiad the proximal or first phalanx on the metacarpal bones, and to assist in extending the second or medial phalanx on the first or proximal. ‡

The extensor communi digitorum manus,§ D, d, *d*, in Fig. 1 of Plate XLII., is situated on the anconal aspect of the fore arm, hand, and fingers, between the extensores carpi radiales, H, *h*, and the extensor carpi ulnaris, B; it arises by a slender tendinous origin from the external or radial condyle of the os brachii, in conjunction with these muscles and the supinator brevis, 55, descends in the middle of the fore-arm, dividing into four tendons, letters d, that run beneath the annular ligament, U, onwards to the roots or proximal extremities of the first phalanx, 7, 8, 9, 10, where each of them forms an elegant tendinous expanse, *d*, which adhering to these bones, proceeds to the third or last phalanx, 16, 17, 18, 19. As the tendons, letters *d*, extend along the metacarpal bones, they become broad and flat, and are united to each other by transverse tendinous slips, **D**: these tendons appear in this part sometimes double, especially that of the little finger, and hence some anatomists have made an extensor minimi digiti.* These tendons frequently run in distinct sheaths of the annular ligament, U, where small bursæ mucosæ often occur.†

The function of this muscle is to extend the elbow-joint, the wrist-joint, and the three joints of the fingers; also to inflect the carpus ulnad.

There is a ligament, named intermuscular, on each side of the os brachii, extending from its condyles upwards or proximad along the ridges. The radial intermuscular ligament, 25, in Figs 1 and 2 of Plate XLII., is more delicate than the ulnar intermuscular ligament, 28, Fig. 2 of Plate XLI. They separate the triceps from the muscles of the fore-arm; the ulnar separating the triceps from the pronator teres and flexors; and the radial ligament separating the triceps from the supinators and extensors.

The time for investigating the ligaments is whenever the muscles round a joint have been examined, that the relation of the one to the other may be understood.

The ligaments of the elbow-joint, because this is of the ginglymoid class, must have lateral ligaments, besides a capsular ligament or a fibrous capsule and a synovial membrane, which all joints possess. The lateral ligaments are naturally two, an external or radial, and an internal or ulnar. I shall begin with these, because they are most superficial, although evidently the capsular ligament, which is common to all joints, should be considered first, afterwards those which are peculiar to the joint.

The radial or external lateral ligament, ‡ delineated in Fig. 2 of Plate XLI., marked 45, extends between the external or radial condyle, *q*, of the os brachii, and the ulna, adhering in this course to the exterior surface of the fibrous capsule, 35, and embracing the head and neck of the radius. This ligament begins acutely from the condyle, *q*, of the bone of the arm, and radiates over the capsular ligament, 35, to be attached to the ulna. §

Its use is to connect the radius to the os brachii and ulna, to protect the joint in this direction, and to limit in some degree pronation and supination, as also rotatory motion.

The ulnar or internal lateral ligament, ‖ 40, in Fig. 2 of Plate XLI., extends obliquely between the ulnar or inter-

---

* Syn. Accessory ligaments of the flexor tendons. Tendinous fræna. The flexor digitorum profundus relates to dislocation of the wrist-joint, the proximal, medial, and distal joints of the fingers; also to fracture of the radius, ulna, metacarpal bones, and bones of the three phalanges of the fingers. It is likewise involved in extirpation of the bones of the fingers, and in amputation of these members.

† Syn. Musculi quatuor digitos pollici adducentes. Quatuor extremæ manus musculi, post primum. Quatuor qui parvi admodum in vola hærent chordis secundi. Flectentes primum internodium. Les muscles lombricaux. Les palmi-phalangiens. Annuli-tendino-phalangiens.

‡ The lumbricales have little or no relation to surgery, being so slender as not to require consideration in either dislocation of the two first joints of the fingers, or in amputation of these members.

§ Syn. Decimus septimus digitos moventium. Primus manus externus musculus. Magnus extensor digitorum. Digitorum extensor primus. Extensor digitorum communis seu digitorum tensor. L'extenseur des quatre doigts. L'extenseur commun des doigts. Extenseur digital. Epicondylo-sus-phalangettien commun.

* Syn. Decimus octavus digitos moventium. Secundus manus exterior musculus. Extensor proprius digiti auricularis. Extendentium secundus. L'extenseur propre du petit doigt. Extensor proprius digiti minimi. Epicondylo-sus-phalangettien du petit doigt.

† The extensor digitorum communis is concerned in dislocation of the elbow-joint, the wrist-joint, and the three joints of the fingers; also in fracture of the radius and ulna, and in extirpation of the metacarpal bones.

‡ Syn. Ligamentum brachio-radiale seu laterale externum. Ligamentum laterale externum cubiti.

§ This ligament relates to dislocation of the elbow-joint, and to dislocation of the head of the radius backwards or anconad; the latter accident occurring chiefly in children.

‖ Syn. Ligamentum brachio-ulnare seu laterale internum. Ligamentum laterale internum cubiti.

nal condyle, *p*, of the os brachii, and the coronoid process, 3, of the ulna, 1.*

The use of this ligament is to connect the ulna to the trochlear surface of the os brachii, and to protect the joint in this direction. It may be said also to limit the extension of the bones of the fore-arm; but the olecranon is a preventive to this motion: the ligament will prevent injury to the bones, and also rotatory motion.

The capsular ligament of the elbow-joint, † marked 35, in Figs. 2 and 3 Plate XLI., and in Fig. 2 of Plate XLII., surrounds the smooth articular cartilaginous surfaces of the os brachii, ulna, and radius, which are opposed to each other. It adheres to the os brachii, close to the articular or trochlear surface laterally, but thenad and anconad it extends some way proximad, to give lodgement to the synovial glands, as delineated in Fig. 3 of Plate XLI., marked 38, and in Fig. 2 of Plate XLII. It closely surrounds the greater or lesser sigmoid cavities of the ulna, 1, and includes the head and neck of the radius, *a* and here it is considerably thickened, and is named the coronary ligament,‡ 5, of the radius, which is considered a distinct ligament, and described to be attached to each side of the lesser sigmoid cavity of the ulna, and to surround the smooth surface, *d*, of the button-like head of the radius. In a strong muscular and ligamentous subject, if the extremity be putrescent, this ligament can be detached from the capsular, 35. Exterior to the capsular ligament, 35, in a strong muscular subject, a few oblique fibres are observed, as represented in Fig. 2 of Plate XLI. §

These may be considered to constitute the anterior ligament of modern authors, the capsular being in this case the synovial membrane. On the posterior aspect of the joint, a few scattered fibres running transversely and perpendicularly form the posterior ligament. There are thus an anterior, a posterior, an external lateral, and an internal lateral ligament, together with a synovial membrane, belonging to this joint.

Synovial glands are found in both sigmoid cavities of the os brachii, and on each side of the greater sigmoid cavity of the ulna; indeed, wherever the blood-vessels have room to form a glandular tissue. The one that is situated in the lesser sigmoid cavity of the os brachii is represented in Plate XLI., Fig. 3, marked 38.

The use of the capsular ligament is to connect the ulna and radius to the os brachii, and to confine the synovial juice.

The oblique ligament* extends between uhe coronoid process of the ulna and the ulnar angle of the radius dis-

---

* The ulnar lateral ligament relates to luxation of the elbow-joint.

† Syn. Membrana capsularis cubiti. Synovial membrane. Synovial capsule.

‡ Syn. Annular or orbicular ligament of the radius.

§ These ligamentous threads are considered by some distinct ligaments, and named anterior and posterior.

The capsular ligament is concerned in luxation of the elbow-joint. In page 21, the different directions in which this joint is luxated are described; in all of them the capsular and lateral ligaments, as also some of the muscles surrounding the joint, are lacerated. Frequently the coronary and oblique ligaments are torn. Those muscles adhering to the ligament, as the brachieus internus, the supinator radii brevis, and the anconeus, cannot escape; while those which have freer motion may remain sound. When the ulna and radius are forced backwards or anconad, the coronoid process of the ulna occupying the place of the olecranon, the fore-arm, from the position of the bones, will be partially extended; the triceps, however, being relaxed, while the brachieus internus and biceps are much stretched and preternaturally excited, throw the arm into a semi-bent position; and because the radius is locked in its new situation, the hand remains supine, and cannot be pronated. The nature of the accident is readily understood from the preceding alterations, and from the projection of the ulna and radius anconad and proximad, also from a depression felt on each side of the olecranon, and a hard tumefaction on the thenal aspect of the joint caused by the trochlear extremity of the os brachii.

The same apparatus and directions as those described for the shoulder-joint in page 91, may be employed in luxations of this joint. The patient should be placed in the sitting posture, and the apparatus applied round his fore-arm; the operator places one of his knees against the os brachii, close to the elbow-joint, so that when extension begins, he may keep the ulna and radius as much removed as possible from the os brachii. Almost immediately after extension is begun, the surgeon may bend gently the fore-arm on the arm. When reduced, the fore-arm should remain inflected on the arm, and slung across the chest.

Luxation of the ulna and radius forwards or thenad occurs very seldom, and is always accompanied with fracture of the olecranon process of the ulna; therefore this kind of accident is at once ascertained. Extension for reducing it, and the keeping of the arm in the extended attitude, with bandaging from the trunk downwards to the olecranon, to keep its fractured points in apposition, is required in this accident.

The head of the radius alone is sometimes luxated forwards or thenad on the trochlear surface of the os brachii, resting partly on the coronoid process of the ulna, which accident is distingaished by the semi-bent position of the arm, the pronated state of the hand, and by the impossibility of either completely bending or extending the elbow-joint. As this luxation is with difficulty reduced, the patient should be placed on a bed or sofa, the same as in luxation of the shoulder-joint, a towel fixed round the wrist and hand, with the noose over the shoulders of the operator, who puts his heel into the axilla of the patient, and makes extension. When reduced, the arm should be kept in the bent position across the chest. The scapula is made the point of resistance, because the biceps is the chief muscle to be overcome; and the reason for making the carpus the point of extension, is because the distal extremity of the radius is the chief bond of connexion with the carpus, and hence the ulna is almost excluded in the extending process.

The head of the radius is also occasionally though seldom luxated backwards, or anconad to the os brachii, and this accident occurs more frequently in children than in adults. The arm is semi-bent, the hand prone, and a projection felt anconad of the os brachii. Supination cannot be performed. Reduction will be accomplished as in the preceding case, and the limb should be afterwards kept in a similar position.

The proximal extremity of the ulna is sometimes dislocated anconad of the os brachii, without being accompanied with the radius, which accident is distinguished by the projection of the olecranon ulnæ, the violent pronation of the hand, and the inability to bend the fore-arm beyond a right-angle. Reduction is to be accomplished in a similar manner, and the arm kept in the position already described.

Luxation of both ulna and radius laterally is very seldom, and when occurring, may take place either radiad or ulnad. When radiad, the coronoid process of the ulna is forced on the anconal aspect of the radial condyle of the os brachii; therefore there is a greater projection of the olecranon anconad, than in either the preceding or the first species: the radius forms a prominence also on the anconal and radial aspect of the os brachii, producing a hollow above it, and the rotation of its head can be felt by pronating and supinating the hand. When the luxation is ulnad, the ulna is either forced upon the ulnar condyle of the os brachii, producing a hollow above it, and the rotation of the head of the radius is felt on pronating and supinating the hand; or the ulna is thrown upon the same condyle, but the head of the radius is forced into the anconal greater sigmoid cavity of the os brachii, so as to prevent pronation and supination from being performed. In this latter variety, the olecranon projects as much as when the luxation is radiad. The manner of reducing this accident, and the attitude of the arm afterwards, should be the same as those last described. For further information on luxation of this joint, see Petit, Dessault, Duverney, Boyer, Sir Astley Cooper, Evans, and Lizars' Practical Surgery, page 173.

In compound luxations of this joint, either one or both condyles of the os brachii, and occasionally the olecranon ulnæ, are fractured; so that anchylosis or amputation is the alternative. For surprisingly successful cures of this accident, consult Sir Astley Cooper's valuable work on Fractures and Dislocations.

* Syn. Ligamentum cubiti obliquum, membrana transversa. Chorda transversalis cubiti. Ligamentum obliquum. Round ligament.

tad to the insertion of the biceps, λ, and is represented in Fig. 2 of Plate XLI., marked 60. Its fibres run in a contrary direction to the interosseus ligament, 61.*

The function or use is to connect the radius and ulna together, and likewise to limit supination.

The interosseous ligament,† 61, in Fig. 2 of Plate XLI., is that oblique arrangement of ligamentous fibres extending from the radius downwards or distad to the ulna. There are generally a few transverse fibres that interlace with these oblique, and commonly some foramina, particularly at its proximal extremity, for the transmission of blood-vessels. ‡ The use of this ligament is to connect the radius and ulna together.

The ligamentum carpi annulare, § u, in Plate XL., in Fig. 1 of Plate XLI., and in Figs. 1 and 2 of Plate XLII.; also in Fig. 2, Plate XX., and in Plate XXI., is merely that portion of the fascia of the fore-arm, rendered thick and strong by the motions of the wrist-joint: this description is more applicable to its anconal than to its palmar portion, for the latter consists partly of a strong ligament stretched between the os trapezium on the radial side, and the os pisiforme and os unciforme on the ulnar side of the wrist. The various muscles attached to this ligament contribute to give it strength, while on the anconal aspect the muscles merely pass beneath, or are bound down by it; but from the extensor tendons running in distinct sheaths, the adhesion of these different ligaments to this annular, and to the carpal bones, renders it extremely strong. Modern anatomists describe six distinct canals made by these tendons running along. This latter peculiarity is displayed in Fig. 2 of Plate XLII. Both sides of the annular ligament are connected with the fascia of the arm. ‖ That on the back of the hand, named the dorsal fascia, is a thin membrane, extending from the posterior annular ligament to the phalanges of the fingers, bracing down the extensor tendons. That on the palm of the hand is a strong fibrous aponeurosis extending from the anterior portion of the annular ligament along the sheaths of the flexor tendons to the tips of the fingers, being strongly incorporated with the integuments of the palm of the hand and fingers, and running superficially to the superficial palmar arch of the ulnar artery, as depicted in Plate XIX.

The use of the annular ligament is to confine the flexor and extensor tendons like a pulley, to connect the carpal bones, and afford strength to the wrist-joint, and to the articulations of the various carpal bones.

The sacciform ligament,* 62, in Figs. 2 and 4 of Plate XLI., is a delicate capsular ligament surrounding the distal smooth cartilaginous surface, 13, of the ulna, and the lesser sigmoid cartilaginous cavity of the radius, rendered strong by the annular and vaginal ligaments of the muscles in its contiguity, and possessing considerable strength near the capsular ligament of the wrist-joint. There is generally a small aperture close to the radius, that communicates with the capsule of the wrist-joint, so that they might be considered as one.† The use of this ligament is to bind these two points of bone in an articulation which assists in pronatiug and supinating the hand.

The wrist-joint in Figs. 2 and 4 of Plate XLI., like all ginglymoid joints, has a capsular, 63, and two lateral ligaments, 64 and 65. The lateral are a radial or external, 65, and an ulnar or internal, 64.

The ulnar lateral ligament,‡ 64, in Figs. 2 and 4, extends between the styloid process of the ulna, 1, and the os cuneiforme, *c*, of the carpus, adhering to the exterior surface of the capsular ligament, 63, but is more anconad than thenad.§ Its use is to connect the bones of the carpus to the ulna, to protect the wrist-joint laterally, and to limit rotatory motion.

The radial lateral ligament, ‖ 65, in Figs. 2 and 4, extends between the styloid process of the radius, and os scaphoides, *a*, of the carpus, adhering to the capsular ligament, 63. ¶

Its use is to connect the bones of the carpus with the radius, to protect the wrist-joint laterally, and to limit rotatory motion.

The capsular ligament,** 63, in Figs. 2 and 4, appears on first inspection to embrace all the bones of the carpus, the strong intertransverse oblique ligaments which extend

---

* The oblique ligament is generally torn in luxation of the proximal extremity of either the ulna or radius.

† Membrana interossea antibrachii.

‡ The interosseous ligament is sometimes torn in luxation of the proximal extremity either of the ulna or radius.

All the muscles, with the exception of those of the thumb and forefinger, which take nearly the same course, have been described, that have any relation to amputation of the fore-arm. When this operation is deemed necessary, the skin should be retracted proximad or upwards by the hands of an assistant, pressure applied to the brachial artery, then the operator makes two semi-elliptical incisions, by transfixing their convexities pointing downwards or distad, and their extremes radiad and ulnad: and, when finished, the knife is inserted between the bones to divide the interosseous ligament, and some of the muscles adhering both to it and the two bones. The flaps being retracted, the operator saws both bones equally and at the same time, employing the saw as directed in that of amputation of the arm, in page 89. The arteries, as depicted and described in Plates XIX. and XX., are now secured and treated as recommended in page 89. For the subsequent treatment, the reader is referred to the same page, and to Lizars' Practical Surgery, page 217.

§ Syn. Ligamentum anterius, annulare vel transversum carpi. Ligamentum carpi proprium, et ligamentum commune carpi dorsale.

‖ The annular ligament is concerned in sprains of the muscles, and in luxation of the wrist-joint; in the former, the quantity of lymph or mucus fluid effused is frequently so profuse, as to deceive surgeons for dislocation or fracture; and nothing but a knowledge of the anatomy of the parts will remove the deception. Warm anodyne applications should be employed to remove the acuteness of the pain and inflammation, and stimulating liniments with bandage to discuss the tumefaction.

* Syn. Membrana capsularis extremitatum inferiorum antibrachii. Membrana capsularis sacciformis. Synovial membrane.

† This ligament is concerned in luxation of the distal extremity of the ulna, which generally projects anconad, rupturing this ligament, and the ulnar lateral ligament of the wrist-joint, and forming a prominence on the anconal aspect of the wrist. The bone is with facility reduced to its former position, but requires to be bound down by a splint laid along the ulna, with a firm compress or pad over the distal head, and encircled with a roller firmly applied.

‡ Syn. Ligamentum cubitale. Ligamentum transversum. Ligamentum adcessorium obliquum. Ulnar carpal ligament. Internal lateral ligament.

§ The ulnar lateral ligament is concerned in luxation of the wrist-joint; also in dislocation of the distal extremity of the ulna anconad.

‖ Ligamentum transversum. Radio-carpal ligament. External lateral ligament.

¶ The radial lateral ligament is concerned in dislocation of the wrist-joint, and in luxation of the radius alone, this bone being sometimes forced on the thenal aspect of the os scaphoides and os trapezium of the carpus, forming a large projection. The radial margin of the hand is forced anconad, and the ulnar margin thenal, giving the hand an awkward twisted appearance. Resistance being made either by the knee of the surgeon placed on the arm immediately proximad of the elbow-joint, or by an assistant grasping the arm, the operator lays hold of the hand, and gradually extends until the bones become opposed to each other, when the muscles pull the bones into their natural position.

** Syn. Membrana articuli cubiti et carpi capsularis. Synovial membrane. La capsule synoviale.

between the carpal bones, and even between the radius and ulna to these bones, both on the thenal and anconal aspects, deceiving us; these can be with difficulty detached, in consequence of their close adhesion to the capsule, and hence are described by some to form an anterior and posterior ligament of the wrist-joint. The capsular ligament surrounds the greater sigmoid cavity of the radius, and the smooth convex surfaces of the os scaphoides, *a*, the os lunare, *b*, and the os cuneiforme, *c*, of the carpus, also an interarticular cartilage, *i*, at the extremity of the ulna, 1, leaving a small hole of communication with the sacciform capsule; all these surfaces of bone are tipped with cartilage. There generally appears a partial division between the portion of the joint formed by the radius, the ossa scaphoides and lunare, and that by the interarticular cartilage and the os cuneiforme. The capsular ligament may therefore be said to adhere to the distal extremities of the radius and ulna on the one side, and the os scaphoides, os lunare, and os cuneiforme of the carpus on the other, supporting an interarticular fibro-cartilage between the ulna and cuneiforme bone. The cartilage is small, flat, and triangular, and thicker on the ulnar than on the radial aspect.

A number of synovial glands are interspersed round this joint, apparently wherever the blood-vessels have quietness to form them. The oblique intertransverse ligaments on the thenal aspect are represented in Plate XLI., and those on the anconal aspect in Plate XLII. The use of the capsular ligament is to connect the carpus with the radius and ulna, and to confine the synovial fluid.*

The muscles of the thumb are eight in number, an abductor and an adductor, three flexors and three extensors, which I shall describe in the order of classification, as I have done the preceding muscles of the fore-arm. The muscles on the palmar or thenal aspect, when first exposed, appear one mass of carneous fibres, and require generally a little violence or art to separate them. The first that presents itself is the abductor pollicis manus,* y, in Plate XL., also in Fig. 2, Plate XIX., situated on the thenal or palmar surface of the fleshy mass at the root of the thumb; arising from the annular ligament, U, and os trapezium, with fleshy fibres that ascend along the thumb and become tendinous, to be inserted into one of the sesamoid bones, or into the radial aspect of the root or proximal extremity of the first phalanx, 6. This muscle almost entirely conceals the flexor ossis metacarpi pollicis, 52, with which it is intimately connected at its origin, where it is partly tendinous; and it is connected at its insertion with the outer head, Z, of the flexor brevis pollicis.†

The function of this muscle is to abduct the thumb from the other fingers, or to inflect the metacarpal bone and proximal phalanx thenad and ulnad.

The abductor pollicis manus,‡ *w*, of Plate XL., and in Fig. 1, Plate XLI., also in Fig. 2, Plate XX,, is situated deeply in the palm of the hand, beneath the flexor tendons, and appears as a part of the inner head, *z*, of the flexor brevis pollicis; it arises by a broad fleshy origin from the metacarpal bone of the middle finger, and proceeds with converging fibres to be inserted tendinous into one of the sesamoid bones, or the root or proximal extremity of the first phalanx. The manner of distinguishing between the adductor and the flexor brevis muscles, is to consider all those fibres which arise from the metacarpal bone of the middle finger as belonging to the adductor, and those that derive their origin from the carpal bones as belonging to the flexor brevis; then to trace and separate them to their insertions. Sometimes the adductor is very large, and the flexor small, or *vice versa*. The anconal surface of this muscle is connected with the interossei of the middle and forefingers, and the abductor indicis, 70. The origin is delineated in Fig. 2 of Plate XLI.§

The function of this muscle is to adduct the thumb to the fingers, or to inflect the metacarpal bone and first phalanx thenad and ulnad.

The flexor ossis metacarpi pollicis, ‖ dig. 52 of Plate XL., and Fig. 1, Plate XLI., also in Fig. 2, Plate XX., is situated immediately beneath the abductor pollicis, Y,

* The carpal bones are forced either anconad or thenad on the radius and ulna, rupturing the capsular and lateral ligaments; the one anconad being the more common of the two. Both of these accidents are liable to be mistaken for sprains in this quarter, but the tumefaction on both sides of the carpus easily enables an intelligent surgeon to decide that the former is a luxation. When the carpal bones are forced anconad, besides the tumefactions just alluded to, there is a depression proximad of these bones, and the hand is inflected palmad. When the carpal bones are forced palmad of the radius and ulna, there is present the swelling on each side, but the depression is distad to the ends of the radius and ulna, and the fingers and hand are extended. In either case reduction may be accomplished in the same manner as when the distal extremity of the radius alone is luxated.

Occasionally the carpal bones are partially luxated radiad or ulnad, both of which species of accidents are easily distinguished, and with facility reduced.

The radius is frequently fractured near its distal extremity, accompanied with dislocation of the distal head of the ulna thenad on the os pisiforme. The hand is forced anconad on the radius and ulna, and the ulna is felt protruded beneath the tendon of the flexor carpi ulnaris: the fractured end of the radius is distinguished by the crepitus, the articular surface remaining connected with the carpus.

There is sometimes a compound dislocation of the ulna anconad, with a comminuted fracture of the radius, in which case it becomes a matter of consideration whether amputation should be performed immediately. If not deemed necessary, the loose bones may be extracted, the ulna cautiously reduced, and the hand and fore-arm fomented. When the inflammation has been subdued, the fractured ends of the radius should be put in apposition, and the limb supported with splints and bandage. See page 32. Occasionally the distal extremity of the radius is forced through the skin on the thenal aspect.—For further information on these accidents, consult Sir Astley Cooper's invaluable work on Dislocations and Fractures; Petit Traité des Maladies des Os, tome 1; Œuvres Chirurgicales de Dessault par Bishat, tome 1; Boyer Traité des Maladies Chirurgicales, tome 4; Lizars' Practical Surgery, p. 175.

* Syn. Qui pollicem maxime abducit. Septimus extremæ manus musculus. Septimus. Pars thenaris. Abducens pollicem. Abductor pollicis. Abductor brevis pollicis manus. Abductores breves pollicis manus exterior et interior. Partie du thenar. Petit abducteur du pouce. Le court abducteur du pouce. Court adducteur du pouce. Carpo-sus-phalangien du pouce. Scapho-sus-phalangien du pouce.

† The abductor pollicis muscle is concerned in dislocation of the proximal extremity of the metacarpal bone of the thumb, and also in amputation of this finger.

‡ Trium qui secundo pollicis ossi famulantur primus. Pars musculi pollicem flectentis volam versus. Secundus. Pars hypothenaris pollicis. Est haud dubie secundi internodii pollicis flexor primus. Pars flexoris primi et secundi ossis pollicis. Adductor (pollicis) ad minimum digitum. Par ejus qui le meso-thenar. Métacarpo-phalangien du pouce. Métacarpo-phalanginien du pouce.

§ The adductor is concerned in dislocation of the metacarpal bone from the os trapezium in dislocation of the first phalanx from the metacarpal bone, in amputation of the thumb, and in extirpation of the metacarpal bone of the middle finger.

‖ Est illorum duorum, qui pollicis primo ossi famulantur, primus. Decimus una cum undecimo. An et hic pars thenaris. Est primi internodii pollicis flexor secundus, cum primo. Pars flexoris primi et secundi ossis pollicis. Flexor primi internodii pollicis. Opponens pollicis manus. Partie due thenar. Métacarpien du pouce. L'opposant du pouce. Carpo-métacarpien du pouce. Carpo-phalangien du pouce.

derives its origin from the os trapezium, *e*, and annular ligament, U, and ascends with oblique fleshy fibres, that are inserted into the whole length of the metacarpal bone of the thumb. Its origin is partly tendinous but more carneous, and its distal margin is intimately connected with the outer head, Z, of the flexor brevis pollicis. *

The function of this muscle is to inflect the metacarpal bone thenad and ulnad; and also to rotate it ulnad.

The flexor brevis pollicis manus, † Z, of Plate XL., and Z, *z*, in Fig. 1 of Plate XLI., also in Figs. 2, Plates XIX. and XX., situated distad and centrad to the two last described muscles, is divided by anatomists into two portions; the outer or superficial or dermal head, Z, derives its origin from the distal margin of the annular ligament, U, ascends with longitudinal fibres, to be inserted into the root of the first phalanx, 6, or sesamoid bones. The deeper or central head, *z*, appears as part of the adductor pollicis, *w*, being closely connected with it; is a bold fleshy bundle of fibres, deriving its origin from the os trapezium, trapezoides, magnum, and os unciforme of the carpus, and proceeding parallel with the fibres of the outer head, Z, being separated by the tendon, X, of the flexor longus, and is inserted into the root of the first phalanx, 6, and ossa sesamoidea. ‡

The function of this muscle is to inflect thenad and ulnad the metacarpal bone and first phalanx of the thumb.

The flexor longus pollicis manus, § X, in Plate XL., and in Fig. 1, Plate XLI., also in Fig. 2, Plate XX., deeply situated near the radial margin of the palmar aspect of the fore-arm, running distad to the thumb, being concealed by the flexor carpi radialis, P, and the flexor digitorum sublimis, R, derives its origin from the radius, beginning a little distad to the tubercle, *b*, and occupying three-fourths of its extent, and also from the interosseous ligament; it soon forms a strong round tendon that runs beneath the annular ligament, U, around the os trapezium, *e*, to the thumb, where it passes between the portions of the flexor brevis, Z, *z*, bound down by a vaginal ligament, like the other long flexor tendons of the fingers, and is inserted into the second or last phalanx, 15, of the thumb.

This muscle, besides the origin here described, has generally either a fleshy or tendinous slip, X, extending from the ulnar or external condyle of the os brachii, to the origin from the radius, and at this part is intimately connected with the flexor sublimis, R. The ulnar margin is so closely attached to the flexor profundus, W, as to appear a part of the latter. Where the tendon runs round the trapezium, *e*, there is a bursa mucosa.*

The function of this muscle is to assist in inflecting thenad the ulna and radius on the os brachii, the carpus on the bones of the fore-arm, and to inflect thenad and ulnad the metacarpal bone on the trapezium, the first phalanx on the metacarpal bone, and the second and last phalanx on the first.

The three extensors of the thumb, *a*, *b*, *c*, in Figs. 1 and 2, Plate XLII., and in Plate XXI., are situated on the anconal aspect of the fore-arm and pollex, and at their origin are obscured by the extensor communis, D; they are named extensor ossis metacarpi pollicis, *a*, extensor primi internodii pollicis, *b*, and extensor secundi internodii pollicis, *c*; or they are termed extensores primi, secundi, et tertii internodii pollicis: the former appears the better, as there is a flexor ossis metacarpi, to antagonize the extensor ossis metacarpi pollicis.

The extensor ossis metacarpi pollicis,† *a*, in Figs. 1 and 2, Plate XLII., and in Plate XXI., the most proximad or the highest of the three extensors, derives its origin from the anconal aspect of the ulna, a little proximad to its middle, and from the interosseous ligament, descends spirally around the radius and the two radial extensors, H, *h*, forming a strong tendon, that runs in a groove on the radial aspect of the distal extremity of the radius, and bound down by the annular ligament, to be inserted into the os trapezium and proximal extremity or root of the metacarpal bone, 1. The proximal or upper margin of its origin is intimately connected with the supinator brevis, 55, the distal with the extensor primi internodii pollicis, *b*; as the muscle runs over the radius, it is attached to the bone, and the tendon is generally encased in a distinct sheath of the annular ligament, U; where it runs in the groove of the radius, the tendon lies over that of the long supinator, N.‡

The function of this muscle is to inflect the carpus radiad, and the metacarpal bone of the thumb radiad and anconad.

The extensor primi internodii pollicis manus §, *b*, in Figs. 1 and 2, Plate XLII., and in Plate XXI., a much smaller muscle than the preceding, arises immediately distad or below, from the ulna, the interosseous ligament,

---

* The flexor ossis metacarpi pollicis is concerned in dislocation of the proximal extremity of the metacarpal bone of the thumb, and likewise in amputation of this finger.

† Syn. Est trium, qui secundo pollicis ossi famulantur, secundus una cum tertio. Octavus extremæ manus musculus. Tertius cum quarto, et quinto, et sexto, et nono, forte et octavo. Haud dubie pars thenaris, cum parte hypothenaris pollicis. Secundi internodii pollicis flexor secundus, cum tertio et quarto. Pars flexoris primi et secundi ossis pollicis. Flexor secundi internodii pollicis. Partie des muscles: thenar, meso-thenar, et anti-thenar ou demi-inter-osseux du pouce. Le court fléchisseur du pouce. Petit fléchisseur du pouce. Carpo-phalangien du pouce. Carpo-phalanginien du pouce.

‡ The flexor brevis pollicis is concerned in luxation of the metacarpal bone, in luxation of the first phalanx of the thumb, and in amputation of this finger.

§ Syn. Tertius digitos moventium. Sextus manus interior musculus. Tertius musculus, pollici dicatus. Musculus a quo flectitur pollex. Tertii internodii pollicis flexor. Flexor tertii internodii, seu longissimus pollicis. Flexor tertii internodii. Le long fléchisseur du pouce. Grand fléchisseur du pouce. Radio-phalangettien du pouce.

* The flexor longus pollicis is concerned in amputation of the fore-arm, in dislocation of the wrist-joint, and in dislocation of the metacarpal bone, first, and second phalanx of the thumb; also in amputation of this finger.

† Syn. Vigesimus secundus digitos moventium, una cum vigesimi-tertii portione, cujus tendo in primi pollicis ossis radicem implantatur. Quintus manus exterioris musculi. Secundi et tertii pollicis internodii extensoris. *Pars* superior *secundi extensoris* secundi extensoris pollicis. Pars extendentis pollicem. Extensor primi internodii ossis pollicis. Abductor longus pollicis manus. Extensor primus pollicis. Partie du premier extenseur du pouce qui s'attache au bord de la base de la premiere phalange. Grand abducteur du pouce. Cubito-sus-métacarpien du pouce. Cubito-radi-sus-métacarpien du pouce.

‡ The extensor ossis metacarpi pollicis is concerned in dislocation of the wrist-joint, and in luxation of the proximal extremity of the metacarpal bone of the thumb from the trapezium; also in amputation of the metacarpal bone.

§ Syn. Vigesimi tertii digitos moventium portio, cujus tendo in secundi ossis pollicis radicem inseritur. Quinti manus exterioris musculi. Pars inferior secundi et tertii pollicis internodii extensoris. Pars extendentis pollicem. Extensor secundi internodii ossis pollicis. Extensor secundi internodii. Extensor minor pollicis manus. Partie du premier extenseur du pouce qui s'attache sur la face convexe de la base de la seconde phalange. Le court extenseur du pouce. Petit extenseur du pouce. Cubito-sus-phalangien du pouce.

and the radius, and runs round the latter, forming a slender tendon, which passes over the radial extensors, H, *h*, in a sheath of the annular ligament, U, and in a groove at the distal extremity of the radius to the thumb, advancing onwards to the proximal extremity of the first phalanx, 6, where it expands like the tendons of the extensor communis, D; the tendon sometimes proceeding along with that of the extensor secundi internodii, *c*, onwards to the second or last phalanx, 15. The origin of this muscle from the ulna is extremely small, and is obscured by the union of the extensor ossis metacarpi with the extensor secundi internodii pollicis.*

The function of this muscle is to inflect the carpus radiad, and the metacarpal bone and first phalanx radiad and anconad.

The extensor secundi internodii pollicis,† *c*, in Figs. 1 and 2, Plate XLII., and in Plate XXI., larger than the last described muscle, but not so much as the metacarpal extensor, derives its origin also from the anconal aspect of the ulna, distad or below the extensor primi internodii, *b*, and from the interosseous ligament, descends longitudinally, forming a strong tendon, that runs apart from the other two extensors of the thumb, beneath the annular ligament, U, and in a separate groove on the distal extremity of the radius, to the proximal extremity of the first phalanx, 6, where it forms an expansive tendon, that advances onwards to the second or last phalanx, 15. The proximal or upper margin of the origin of this muscle is so connected with the extensor ossis metacarpi pollicis, *a*, as to obscure the extensor primi internodii, *b*. The distal or lower margin is connected with the indicator, *f*.‡

The function of this muscle is to extend the carpus and the metacarpal bone, the proximal, and distal phalanx of the thumb, anconad and ulnad. It also assists in supinating the hand.

The metacarpal bone, 1, of the thumb is articulated to the os trapezium, *e*, by a capsular ligament, *g*, strengthened exteriorly with strong longitudinal ligamentous bands, § as represented in Figs. 2 and 4 of Plate XLI: in the latter figure, the capsular ligament is cut open, to show the trochlear surface of the trapezium and metacarpal bone, which, like other articular surfaces, are covered with cartilage.‖ The use of this capsular ligament is similar to that of the joints previously described; but these longitudinal ligamentous bands, as represented in Fig. 2, partly perform the function of lateral ligaments, by limiting the motions of the articulation.

The articulation between the metacarpal bone, 1, and the first or proximal phalanx, 6, of the thumb as delineated in Fig. 2, of Plate XLI., is completed by a capsular ligament, **c**, and two lateral ligaments, **k**; one only of the latter, however, is in view. The same arrangement pervades the joints between the other metacarpal bones and proximal phalanges, which are marked with the same letters; and the same ligamentous structure joins the distal articulations of the fingers and thumb, therefore only those of the thumb have been drawn. The capsular ligament, **c**, as well as all those of the other articulations of the fingers, surrounds the smooth cartilaginous surfaces forming the joints, and answers the same purpose as the capsular ligaments already described. The radial lateral ligament, **k**, the opposite of which or ulnar does not come into view, is remarkably strong, and extends parallel with the finger, from the radial little tubercle at the side of the distal extremity of the metacarpal bone, 1, to a similar tubercle at the side of the proximal extremity of the first phalanx, 6, adhering to the capsular ligament in its course.* This performs the same function as in those joints where these ligaments prevail, as in the wrist and elbow. The capsular ligament of the second or last joint of the thumb is marked *m*, and one of the lateral ligaments, *n*; and as they precisely resemble those last described, it appears unnescessary to particularize them further.

The muscles peculiar to the fore-finger are an abductor and an extensor, the latter of which is named indicator. The indicator,† *f*, in Fig. 2 of Plate XLII., situated on the anconal aspect of the distal half of the fore-arm, hand, and fore-finger, and concealed by the extensor digitorum

---

* The extensor primi internodii pollicis is concerned in luxation of the wrist-joint, of the metacarpal bone with the trapezium, and of the metacarpal bone with the first or proximal phalanx.

† Syn. Vigesimus primus digitos moventium. Quartus manus exterior musculus. Pollicis tertium os extendens. Extendens pollicem alter. Extensor tertii internodii ossis pollicis. Extensor tertii internodii. Extensor major pollicis manus. Le second extenseur du pouce. Le long extenseur du pouce. Grand extenseur du pouce. Cubito-sus-phalangettien du pouce.

‡ The extensor secundi internodii pollicis is concerned in dislocation of the wrist-joint, in that of the three joints of the thumb, and in amputation of this finger.

§ These ligamentous bands are by some named ligamentum dorsale, ligamentum palmare, ligamentum laterale externum, ligamentum laterale internum. I have never observed them so regularly placed on these four aspects as to deserve such important names. The modern arrangement is better, viz., a fibrous capsule, and a synovial membrane.

‖ This articulation of the metacarpal bone of the thumb is luxated either thenad or anconad of the os trapezium; when thenad, there is a prominence in the palm of the hand, the finger is extended anconad, and cannot be inflected thenad; when luxated anconad, there is a projection on the anconal aspect of the wrist, the thumb is inflected thenad, and cannot be extended. From the great power of the flexor muscles, it is often necessary to have recourse to the tartrate of antimony, and even bleeding to syncope, whenever extension is to be commenced, and then reduction becomes extremely easy. That master of surgery, Sir Astley Cooper, directs the hand to be immersed previously in warm water for a considerable time, then a piece of thin leather soaked in water to be put round the first phalanx, and encircled with a loop of tape, in the form of the sailor's "clove hitch," the tape being about two yards in length. With this, extension is to be made when the patient has fainted, endeavouring to relax the flexors by bending the finger gently thenad, counter extension being applied between the thumb and fore-finger. In compound dislocation of this joint, the thumb appears capable of being saved, provided the tendons, particularly that of the flexor longus pollicis, and that of the extensor secundi internodii pollicis, are sound. The treatment is the same as that described under compound dislocation of the wrist-joint. Consult Sir Astley Cooper's work on Fractures and Dislocations; Boyer Maladies Chirurgicales, tome 4; Petit Traité des Maladies des Os, tome 1; Lizars' Practical Surgery, p. 176.

* The first phalanx is liable to be luxated from the metacarpal bone, either thenad or anconad, both of which are at once distinguished. The same means, excepting the bleeding, may be employed as for the luxation of the metacarpal from the carpal bone. The articulation between the first and second phalanx, or between the proximal and medial, is more subject to be luxated, than the joint formed by the medial and distal phalanx. In this the medial phalanx is generally dislocated thenad of the first or proximal phalanx, and is at once distinguished. Reduction is to be accomplished as in the preceding. In compound dislocation, the same observations and treatment are applicable, as in those detailed under that of the metacarpal bone of the thumb.

† Syn. Decimus nonus digitos moventium. Tertius manus exterior musculus. Indicatorius. Indicem abducens. Indicis abductor. Extensor indicis seu indicator. Extensor secundi internodii indicis proprius vulgo indicator. L'extenseur propre de l'index. L'extenseur propre du doigt indicateur. Extenseur de l'index. Cubito-sus-phalangettien de l'index.

communis, D, derives its origin from the greater extent of the distal half of the ulna, and from the contiguous interosseous ligament; descends longitudinally along the fore-arm, soon becoming tendinous, and running along with the tendons of the extensor communis beneath the annular ligament, U, to the first phalanx, 2, of the fore-finger, where its tendon unites with that of the communis to contribute to the formation of the tendinous expanse spread over the phalanges.* The radial margin is connected with the extensor secundi internodii pollicis, *c*, and the ulnar margin of the muscle with the extensor carpi ulnaris, B. The tendon runs parallel on the ulnar aspect of the tendon of the extensor communis to the fore-finger.

The function of this muscle is to extend the carpus and fore-finger, the latter of which it not only inflects anconad, but a little ulnad.

The abductor indicis manus,† 70, Fig. 1 of Plate XLII., situated between the metacarpal bones of the thumb and fore-finger, on the anconal aspect, is a flat muscular mass, arising from the os trapezium and metacarpal bones of the thumb and fore-finger, and meeting in a central line to form a strong short tendon which is inserted into the radial aspect of the proximal extremity of the first phalanx, and expansive tendon of the indicator and extensor communis. ‡

The function of this muscle is to abduct the fore-finger from the middle and other fingers, and also to inflect the proximal or first phalanx of the fore-finger thenad.

The muscles of the little finger, like those of the thumb, appear to constitute one fleshy mass, and require equal violence or art to separate them; they are represented in Plate XL. and in Fig. 1, Plate XLI., also in Fig. 2, Plate XX. The flexor parvus, 52, is the most superficial and palmar; the abductor, 51, is nearly as superficial, but is situated on the ulnar margin of the little finger; while the adductor, 55, is partly concealed by the flexor and abductor.

The flexor parvus digiti minimi manus,§ 52, Plate XL., also in Fig. 2, Plate XX., arises from the annular ligament, U, and os unciforme, and is inserted into the proximal extremity, or base or root of the first phalanx. The origin of this muscle is partly fleshy and partly tendinous; and so also is its insertion, the latter of which is sometimes also inserted into the distal extremity or head of the metacarpal bone. The origin and insertion are represented in Fig. 1, of Plate XLI.‖ The deep twig of the ulnar nerve pierces this and the adductor muscles, as seen in Plate XX., Fig. 2.

* The indicator relates to amputation of the fore-arm, to dislocation of the wrist-joint, to that of the joints of the fore-finger, and to amputation of this finger.

† Syn. Alter musculus, lateralibus pollicis motibus inserviens. Septimus pollicis musculus. Primus. Abductor indicis. Adducens pollicem. Adductor pollicis. Le demi-interosseux de l'index.

‡ The abductor indicis relates to dislocation of the metacarpal bone of the thumb from the os trapezium, to dislocation of the first phalanx of the fore-finger from its metacarpal bone, to extirpation of the metacarpal bone, and amputation of the proximal phalanx.

§ Syn. Pars sexti extremæ manus musculus. Pars hypothenaris parvi digiti. Pars abductoris minimi digiti. Abductor minimi digiti, hypothenar. Flexor proprius digiti minimi. Le court fléchisseur du petit doigt. Partie du carpo-phalangien du petit doigt. Second carpo-phalangien du petit doigt.

‖ The flexor parvus digiti minimi relates to luxation and amputatiou of the proximal phalanx of the little finger.

The function of this muscle is to inflect thenad the proximal phalanx of the little finger. This muscle is occasionally deficient.

The abductor digiti minimi manus,* 51, in Plate XL., and in Fig. 2, Plate XX., derives its origin from the os pisiforme, T, and the contiguous point of the annular ligament, U; runs along the ulnar aspect of the little finger, to be inserted by a strong tendon into the proximal extremity or root of the first phalanx. The origin is partly fleshy and partly tendinous; both it and the insertion are represented in Fig. 2 of Plate XLI.†

The function of this muscle is to inflect thenad and also ulnad the proximal phalanx of the little finger.

The addnctor minimi digiti,‡ 55, in Plate XL. and in Fig. 1, Plate XLI., lies beneath the two preceding muscles, with one of which, the flexor parvus, 52, it is closely connected; derives its origin from the annular ligament, U, and the os unciforme, *h*; proceeds with oblique fibres to be inserted into the ulnar and somewhat anconal margin of the metacarpal bone of the little finger.§

The function of this muscle is to inflect the metacarpal bone of the little finger thenad and radiad

Between the metacarpal bones on the back of the hand, or on the anconal aspect, there are three little muscles, named interossei externi,‖ seen in Figs. 1 and 2, Plate XLII., marked *m*, *n*, O; each of them arises by a double origin from the opposite sides of the metacarpal bones, which unite in the centre, and form at the head or distal extremity of these bones a delicate tendon, which advances along the side of the first phalanx, to which it adheres, and joins the expansive tendon of the extensor communis near the head or distal extremity of the same phalanx. One of the three, named prior medii,¶ is marked *m*, and its tendon runs along the radial margin of the first phalanx, 8, of the middle finger.**

Its function is to inflect radiad and thenad the first or proximal phalanx, and also to contribute to extend the medial and distal phalanges.

Another, named posterior medii,†† is marked *n*, has a

* Syn. Vigesimus manus digitos moventium. Sextus extremæ manus musculus. Pars hypothenaris parvi digiti. Minimum digitum abducens. Pars abductoris minimi digiti. Extensor tertii internodii minimi digiti. Hypothenar du petit doigt, ou le petit hypothénar. Abducteur du petit doigt. L'adducteur du petit doigt. Carpo-phalangien du petit doigt.

† The abductor minimi digiti has the same relation to surgery that the flexor parvus has.

‡ Illorum octo, qui quatuor subserviunt digitis, parvum digitum flectentium primus. Unus octo aliorum musculorum. Unus illorum octo, qui inter ossa metacarpi continentur. Pars hypothenaris parvi digiti. Interosseus ultimo ossi metacarpi parte manus externa adhærens. Pars abductoris minimi digiti. Flexor primi internodii minimi digiti. Adductor ossis metacarpi digiti minimi. Metacarpien. Le muscle opposant du petit doigt. Carpo-metacarpien du petit doigt. Adductor ossis metacarpi digiti auricularis.

§ The adductor minimi digiti relates to extirpation of the metacarpal bone of the little finger.

‖ Sunt tres illorum octo, qui quatuor subserviunt digitis. Octo aliorum musculorum. Illorum octo, qui inter ossa metacarpi continentur. Interossei. Interossei manus. Les inter-osseux externes, ou dorsaux, ou posterieurs. Metacarpo-phalangien latéraux sus-palmaires. Sous-métacarpo-lateri-phalangiens. Interossei externi digitorum manus. Anconal interossei. Interossei externi seu becipites seu dorsales. Metacarpo-phalangei laterales.

¶ Syn. Anconi-radialis digiti medii.

** The prior medii relates to extirpation of either the metacarpal bone, 3, of the middle finger, or that, 2, of the fore-finger, and to dislocation as well as amputation of the first or proximal phalanx of the middle finger.

†† Syn. Anconi-ulnaris digiti medii.

similar origin, and its tendons runs along the ulnar margin of the middle finger, to have a similar insertion.*

Its function is to inflect radiad and thenad the proximal phalanx, and to extend the medial and distal phalanges.

The third, denominated posterior annularis,† is marked *o*, has also a similar origin and insertion as the other two, its tendon running along the ulnar margin of the ring finger.‡

Its function is to inflect ulnad and thenad the proximal phalanx, and to extend the medial and distal phalanges,

On the thenal or palmar aspect of the hand there are corresponding muscles, termed interossei interni, § that arise from single metacarpal bones, and form slender tendons, which are inserted into the expansive tendon of the extensor communis of the same fingers; these are represented in Fig. 2, Plate XLI., and are named prior indicis, *p*, posterior indicis, *q*, prior annularis, s, interosseus auricularis, *t*: but I have generally found more, viz. a prior medii, *u*, and posterior medii, *v*, and a posterior annularis, *x*.

Prior indices, ‖ *p*, in Fig. 2 of Plate XLI., situated on the radial margin of the metacarpal bone, 2, of the fore-finger, and concealed between the adductor pollicis, *w*, and abductor indicis, 70, as represented in Fig. 1, derives its origin from the radial and palmar aspect of the metacarpal bone, 2, of the fore-finger, and runs along the same aspect of the first joint; then becoming tendinous, is inserted first into the proximal extremity of the first phalanx, and secondly by an expansive tendon into that of the extensor digitorum communis. ¶

Its function is to inflect radiad and thenad the proximal phalanx of the fore-finger, and to extend the medial and distal phalanges.

Posterior indicis,** *q*, in Fig. 2 of Plate XLI., is almost entirely obscured by the prior medii, *u*, on the thenal aspect, and is situated on the ulnar and palmar aspect of the metacarpal bone, 2, of the fore-finger, deriving its origin from the same aspect of the metacarpal bone of the fore-finger, and running with a small tendon around the first joint, to be inserted into the expansive tendon of the extensor communis. † †

Its function is to inflect ulnad and thenad the proximal phalanx of the fore-finger, and to extend the medial and distal phalanges.

Prior annularis,‡‡ *s*, in Fig. 2 of Plate XLI., situated on the radial margin of the palmar aspect of the metacarpal bone, 4, of the ring-finger, arises from the same aspect of this bone, and becomes tendinous at the first joint, around which it runs, to be inserted into the expansive tendon of the extensor communis. § §

Its function is to inflect radiad and thenad the proximal phalanx of the ring-finger, and to extend the medial and distal phalanges.

Interosseous auricularis,† *t*, in Fig. 2 of Plate XLI., is situated on the radial margin of the metacarpal bone, 5, of the little finger, on the palmar aspect, deriving its origin from the same surface of that bone, along which it runs, and becomes tendinous at the first joint, to be inserted into the proximal extremity of the first phalanx, on the radial aspect, and afterwards into the expansive tendon of the extensor communis. ‡

Its function is to inflect radiad and thenad the proximal phalanx of the little finger, and to extend the medial and distal phalanges.

The carpal bones are connected together by capsular and intertransverse ligaments, the latter being exterior to the former. The intertransverse ligaments § are represented in Figs. 2 and 4 of Plate XLI., and Fig. 2 of Plate XLII., marked thus *. They extend between the different carpal bones both on their thenal and anconal aspects, and adhere to the capsules that surround the smooth surfaces of these bones.‖ They bind these bones firmly together, so as to limit their motion, and prevent dislocation.

The capsular ligaments or synovial membranes are observed Figs. 2 and 4 of Plate XLI., beneath the intertransverse *; they include the separate articulations formed by the carpal bones, being attached around the smooth cartilaginous surfaces. A ginglymoid joint is formed by the trapezium, trapezoides, magnum, and unciform, on the one hand; and by the scaphoides, lunar, and cuneiform, on the other: the scaphoides plays on the trapezium and trapezoides, while the magnum on the scaphoid and lunar, and again the cuneiform on the unciform.

The carpal bones are tied to the metacarpal bones by intertransverse ** and capsular ligaments, or synovial membranes,¶ as represented in Fig. 2 of Plate XLII. The same arrangement being present on the thenal aspect.†† The proximal extremities of the metacarpal bones are bound together by intertransverse ligaments.

---

* This interosseus has nearly the same relation to surgery that the preceding has. † Syn. Anconi-ulnaris digiti annularis.

‡ This interosseous muscle relates to extirpation of either the metacarpal bone, 4, of the ring-finger, or to that, 5, of the little finger; and also to dislocation and amputation of the proximal phalanx of the ring-finger.

§ Sunt quatuor illorum octo, qui quatuor subserviunt digitis. Octo aliorum musculorum. Illorum octo qui inter ossa metacarpi continentur. Interossei. Interossei manus. Interossei interni vel palmares. Les interosseux internes, ou palmaires, ou antérieurs. Metacarpo-phalangiens latéraux palmaires. Sous-metacarpo-lateri phalangiens. Metacarpo-phalangei laterales. ‖ Syn. Vola-radialis indicis.

¶ The prior indicis relates to extirpation of the metacarpal bone of the fore-finger, and to dislocation as well as amputation of the first phalanx. ** Syn. Vola-ulnaris indicis.

†† The posterior indicis has the same relation to surgery that the prior indicis has. ‡‡ Syn. Vola-radialis digiti annularis.

§ § The prior annularis is concerned in extirpation of the metacarpal bone of the ring-finger, and in dislocation as well as amputation of the proximal phalanx.

† Syn. Vola-radialis digiti auricularis.

‡ The interosseous auricularis relates to extirpation of the metacarpal bone of the little finger, and to amputation and dislocation of the proximal phalanx.

§ Syn. Ligamenta ossium carpi brevia. Ligamenta obliqua, vel transversa. Anterior, posterior, lateral and accessory ligaments.

‖ The intertransverse ligaments relate to dislocation of one or more of the carpal bones, which is a very rare occurrence; also to extirpation of one of these bones. When the os magnum is luxated anconad, which is almost the only bone of the carpus that is forced out of its situation, there is a marked protuberance anconad. Extension of the hand, and afterwards pressure on this bone, will reduce it; but here is a difficulty of keeping the os magnum in its situation; a compress and roller require to be worn for a long period. The os scaphoides has been dislocated from its carpal connexions, together with fracture of the distal extremity of the radius. Compound dislocation of the carpal bones is more frequent, and then one or more require removal, or amputation becomes necessary. For further information on these accidents.

¶ Syn. Ligamenta articularia. Ligamenta dorsi manus, lateralia, recta, perpendicularia. Ligamenta ossis metacarpi digiti indices sunt tria; ligamentum sublime, ligamentum profundum, et ligamentum literale. Ligamenta ossis metacarpi digiti medii sunt quinque; duo sublimia, unum profundum, alterum perpendiculare, quintum obliquum. Ligamenta ossis metacarpi digiti annularis sunt duo; unum membrana capsularis, alterum lacertus ligamenti inter os magnum et os unciforme. Ligamentum ossis metacarpi digiti auricularis unum est, peculiareque validum. Ligamens étroits et minces.

† † The proximal extremities of the metacarpal bones are so firmly

THE MUSCLES OF THE LOWER EXTREMITY.

THESE may be examined, either as they occur in the order of dissection, or in the arrangement of classification; and since the former of these two naturally comes first, and as there is no necessity for entirely detaching any muscle, until we arrive at the investigation of the ligaments, all the muscles can and should be first explored in the order of presentation, and afterwards examined in classes. This method is much the better, as it imprints the muscles on the mind, not only in an anatomical, but in a physiological and surgical view.

Beneath the integuments and superficial fascia on the anterior or patellar or rotular aspect of the thigh, the aponeurosis of the thigh and haunch named the fascia lata is found, and is depicted in Plate XXIII., and in Plates XXIX., XXX., and XXXI. This is a strong thick fibrous aponeurosis connected with the muscles of the trunk, the crural arch, the anterior superior spinous process of the os ilium, the crest of the ilium, the posterior superior spinous process of the ilium, the posterior sacro-iliac ligament, the articular processes of the os sacrum, the posterior surface of the coccyx, the outer sacro-ischiadic ligament, the tuberosity of the os ischium, the ramus of the ischium, the ramus, the symphysis, the body and the spinous process of the os pubis, and the linea innominata; and from thence descending along the thigh, the muscles of which, as also those of the nates, it surrounds, thus forming an envelope or sheath from the trunk to the knee. The same fascia can be traced distad, enveloping the muscles of the leg downwards to the toes. In its course along the thigh, it is connected with the fibrous capsule of the hip-joint, the linea aspera, and the condyles of the os femoris. Numerous processes of it dip between the muscles to support them. We shall merely consider at present that portion situated on the patellar aspect of the thigh, which is by far the most important, deferring the description of the rest till afterwards.

In the Plates above alluded to, this fascia, consisting of strong interlaced tendinous fibres, is observed to be divided into two portions, where it is connected with the tendon, B, of the external oblique muscle of the abdomen: these are marked D, K, and after a short extent distad, form a uniform surface. The portion, K, is named iliac, is intimately connected with the tendinous fibres, B, of the external oblique muscle, as represented in Plate XXIX., and with those fibres of the same muscle, marked 3, in Plate XXX.; and is elevated above the pubic portion, D, in consequence of the psoas magnus and iliacus internus muscles, together with the anterior crural nerve, 22, artery, T, and vein, U, emerging from the abdominal cavity over the bones of the pelvis, as delineated in Plate XXIV. The pubic portion, D, into which is inserted that portion 3, of the tendon of the external oblique muscle denominated Gimbernat's ligament, closely invests the pectinalis, P, and adductor longus, g, muscles, and continus in its descent distad on the thigh, below the level of the iliac portion, K, till the psoas magnus, K, and iliacus internus, W, muscles, together with the nerve, artery, and vein, begin to dip centrad in the thigh, the muscles to the trochanter minor, and the nerve and blood-vessels, to run beneath or centrad of the sartorius muscle, E. These portions generally unite a little distad of the junction of the saphena major or interna vein, *b*, and trunk of the crural vein, U, forming the saphenic aperture, and afterwards a continuous circular tendinous expanse round the thigh and leg.

Where the loose edge of the iliac portion looks pubic and tibiad, it is named falciforme,* and by that profound surgeon, Dr. Burns of Glasgow, is supposed to form frequently the cause of stricture in crural hernia; † its extremities are termed crura, the superior being connected to Gimbernat's ligament, the inferior to the pubic portion of the fascia lata, with which it is continuous. The fascia lata is thinner in some parts than in others, for example, the pubic portion is often removed by the dissector, as well as that which covers the sartorius muscle, E: while that over the rectus, I, and around to the popliteal aspect is very strong.

The use of the fascia lata is to bind the muscles, so as to afford them greater power in moving the limb, acting in some measure as a pulley, particularly at the knee and ankle-joints, where it is thickest. It also affords origin to some of the muscles of the thigh, and insertion to others; and likewise protects the blood-vessels.

The muscle which acts on this fascia, named tensor vaginæ femoris, ‡ is delineated in Plates XXIII. and XXIV., marked K; likewise in Plates XLIII. and XLVI. The muscular fibres are enveloped in layers of the fascia, and situated between the sartorius, E, of Plate XXIII., and gluteus medius, i, of Plate XXV.; they arise partly tendinous and partly fleshy from the exterior aspect of the crista of the os ilium, between these two muscles, and therefore contiguous to the anterior superior spinous process of that bone, as delineated in Plate VIII., Fig. 2, letter *d*; thence descending distad, poplitead, and fibulad, they terminate a little below the trochanter major, in the tendinous expanse of the fascia lata. The fascia here is remarkably strong, and continues so downwards or distad

tied to the carpal by ligaments, and most of them so locked with these bones by their osseous angles, that they are very seldom luxated, but generally so injured, that amputation of one or more of them becomes necessary.

* Syn. Crescentic border. Semi-lunar edge. Femoral ligament.

† The fascia lata relates to hernia, either inguinal or crural, as described in pages 74 and 75; and also to crural aneurism, as in pages 64 and 65. In Plate XLIII., Gimbernat's ligament, 3, is very conspicuous, in consequence of being drawn from a female subject; and we can easily comprehend, from its breadth, what relief will be afforded by its division pubic in strangulated crural hernia.

‡ Syn. Est pars carnes sexti tibiam moventium. Eadem sexti tibiæ musculi. Membranosi. Extendentium tibiam primi, membranosi, musculus lati tendinis. Fascia lata femoris. Muscle aponévrotique, ou muscle de la bande large, ou muscle de fascia lata. Tenseur aponévrotique crural. Ilio-aponévrosi-fémoral.

to the patella and head of the fibula, which may be said to be points of its insertion; the fascia lata is also strongly attached to the linea aspera of the os femoris, and to the tibia.

The function of this muscle is to render tense this fascia, to bend and abduct the thigh on the pelvis, to rotate the limb tibiad, and to extend or bend the tibia on the os femoris.* When the os femoris is the fixed point, it likewise assists in inflecting the trunk fibulad, and rotating it round by the sternal aspect.

The sartorius muscle,† E, in Plates XXIII., XXIV., XXV., and XXVIII., in Plates XLIII. and XLIV., and in Fig. 1, Plate L., is an elegant arrangement of parallel muscular fibres, extending spirally along the thigh, between the os ilium and the tibia, and situated immediately beneath or centrad to the fascia lata. It derives its origin chiefly tendinous from the anterior superior spinous process, C, of the os ilium, runs with parallel fleshy fibres spirally around the patellar aspect of the thigh, superficially to the rectus, vastus internus, and triceps, to the popliteal aspect of the internal or tibial condyle of the os femoris, round which it runs, forming a flat tendinous expanse, that is inserted into the head of the tibia distad and poplitead to its tubercle, superficially to the gracilis and semi-tendinosus, the expanse uniting with the fascia of the leg. In Plate XXIII., the muscle is represented in its natural situation. In Plates XLIII. and XLIV., the origin is distinctly delineated. In Plate XXIV., the muscle is observed proceeding around the tibial condyle of the os femoris, and forming its tendinous expanse, the insertion of which is seen in Plate XXVIII., covering the tendons of the gracilis, Q, and semi-tendinosus, M, muscles, between which a bursa mucosa is generally found, as represented in Plate L., marked *e*.

The function of the sartorius is to inflect and abduct the thigh on the pelvis, and to rotate the limb tibiad; to inflect the tibia on the os femoris, and when bent to rotate it slightly.‡ When the thigh-bone is fixed, it assists to inflect the trunk fibulad, and to rotate it round by the sternal aspect.

The gracilis muscle,§ Q, depicted in Plates XXIV., XXV., and XXVIII., and in Plates XLIII., XLIV., and L., is an elegant slender muscle, situated on the tibial aspect of the thigh, extending between the pubes and tibia. It derives its origin by a broad tendinous lamina from the os pubis, parallel with its symphysis, which soon becomes fleshy, and descending along the tibial aspect of the thigh, becomes tendinous at the inner or tibial condyle of the os femoris, behind or poplitead to which it runs, to be inserted, together with the sartorius muscle, into the head of the tibia, distad and poplitead to its tubercle. The origin is distinctly seen in Plates XLIII. and XLIV., having the adductor longus, g, on its iliac side, and overlapping the adductor brevis, *g*, and adductor magnus, G, in its descent along the ramus of the os pubis. The point of bone from which this muscle arises is seen in Figs. 1 and 2, Plate III., marked **m**. The insertion is represented in Plates XXVIII. and L.; in that of Plate XXVIII. the sartorius, E, covers it, while in that of Plate L. the tendon is exposed, and observed to be surrounded with the bursa mucosa, *e*.

The gracilis is a flexor and adductor of the thigh, also a rotator tibiad; it is likewise a flexor of the leg on the thigh; and when the thigh is made a fixed point, assists in inflecting the trunk tibiad, and in turning it round by the sternal aspect.*

The triceps adductor femoris, G, g, *g*, in Plates XXIV., and XXV., and in Plates XLIII., XLIV., and XLVI., is a bold muscular mass, forming the greater portion of the flesh on the inside, or tibio-patellar aspect of the thigh, and is situated between the gracilis, Q, and the pectinalis, P, in this view, while on the popliteal aspect it is partially concealed by the hamstring muscles, L, M, N, and the gluteus maximus, F, as represented in Plate XXV. It is, strictly speaking, three distinct muscles, and hence divided into the adductor longus, adductor brevis, and adductor magnus.

The adductor longus femoris,† g, situated the most dermal or superficial of the three adductors, on the patello-tibial aspect of the proximal half of the thigh, between the gracilis, Q, and the pectinalis, P, and resting on the adductor brevis, *g*, so as to conceal it from view, derives its origin from the body of the os pubis, immediately sacrad to the crista, **i**, descends obliquely downwards and inwards or distad and poplitead to the linea aspera of the os femoris, to be inserted into its middle third. The origin is clearly defined in Plate XLIII., between the gracilis, Q, and pectinalis, P, with which it is on the same parallel; and the insertion is observed in this Plate and Plate XLIV., to unite with that of the other two adductors, to form their tendon, **g**, through which the superficial femoral artery, t, and vein, U, are piercing.‡

The function of this muscle is to bend the thigh on the pelvis, to adduct the one limb to the other, and to rotate the limb fibulad, or outwards. When the os femoris is the fixed point, this muscle assists in inflecting the trunk tibiad, and turning it round by the dorsal aspect.

The adductor brevis femoris,§ *g*, situated beneath or centrad to the adductor longus, g, and concealed by it and

* The relation of the fascia lata to surgery has been already noticed. The muscular portion is concerned in luxation of the hip-joint, in amputation at the hip-joint, in fracture of the neck and shaft of the os femoris, and in morbus coxarius.

† Syn. Primus tibiam moventium. Primus tibiæ musculus. Longus sive sutorius. Flectentium tibiam primus, sartorius, fascialis, fascia. Le couturier. Ilio-prétibial. Ilio-créti-tibial.

‡ The sartorius muscle relates to the securing of the superficial femoral artery, as described in p. 65; to amputation at the hip-joint, as detailed in same page; to dislocation of this joint, to morbus coxarius, to fracture of the neck and body of the os femoris, and to amputation of the thigh. It is also concerned in amputation of the leg, in dislocation and other injuries and diseases of the knee-joint.

§ Syn. Secundus tibiam moventium. Secundus tibiæ musculus. Posticus gracilis. Flectentium tibiam secundus, gracilis. Le droit ou grêle interne. Droit interne crural. Sous-pubio-prétibial. Sous-pubio-crêti-tibial.

* The gracilis is concerned in luxation of the hip-joint, in amputation at this joint, as described in page 65; in morbus coxarius, in fracture of the neck and shaft of the os femoris, in amputation of the thigh; and also in amputation of the leg, and in luxation and other injuries of the knee-joint.

† Syn. Pars octavi femur moventium. Fortasse pars septimi femoris musculi. Pars primi quinti femur moventium. Primum caput tricipitis. Pars flectentium tertii tricipitis. Pars tricipitis. Adductor femoris primus. Premier muscle du triceps. Le premiere adducteur de la cuisse. Moyen adducteur. Pubio-fémoral. Spino-pubio-fémoral.

‡ The adductor longus femoris relates to luxation of the hip-joint, to fracture of the neck and shaft of the os femoris, to morbus coxarius, and to amputation at the hip-joint, as described in page 65.

§ Syn. Pars quinti femur moventium. Pars octavi femoris musculi. Secundo pars quinti femur moventium. Alterum caput tricipitis. Pars flectentium tertii. Pars tricipitis. Adductor femoris secundus. Second muscle du triceps. Le second adducteur. Petit adducteur. Sous-pubio-fémoral.

the gracilis, Q, derives its origin from the body of the os pubis, descends obliquely downwards and inwards, or distad and poplitead, and is inserted into the upper or proximal third of the linea aspera of the os femoris. In Plates XLIII. and XLIV. the precise origin and insertion of this muscle are distinctly defined, and the latter is observed uniting with the insertions of the other two adductors, to form their tendon, g. In Plate XLIII., the adductor brevis is seen descending parallel with the fibres of the pectinalis, P. *

The function of this muscle is the same as that of the longus, a flexor, an adductor, and a rotator fibulad of the thigh; and when the os femoris is the fixed point, it assists in inflecting the trunk tibiad, and turning it round by the dorsal aspect.

The adductor magnus femoris,† G, situated poplitead of the other two adductors, derives its origin from the ramus of the os pubis, ramus and tuberosity of the os ischium, and descends with transverse and oblique fibres poplitead, to be inserted into the whole length of the linea aspera of the os femoris, its tendon uniting with those of the adductor longus and brevis, becoming smaller and rounder, to be ultimately inserted into the tubercle poplitead to the tibial condyle of the os femoris, the superficial femoral artery, t, and vein, U, running between this tendon and the bone. The precise origin of this muscle is distinctly seen in Plate XLIV., and the surface of bone in Plate VIII., Fig. 2. The superior or proximal fibres, which run transversely, are parallel and in contact with those of the quadratus femoris, K, with which they are liable to be confounded, as observed in Plates XXV. and XLVI. ‡

The function of this muscle varies according to the fibres which are called into action: thus, those arising from the ramus of the os pubis and os ischium are flexors and adductors, while those deriving origin from the tuberosity of the os ischium are extensors. The whole muscle is a rotator fibulad. When the os femoris is the fixed point, this muscle inflects the trunk tibiad, and turns it round by the dorsal aspect.

The pestinalis muscle, § P, ‖ in Plate XXIV., and in Plates XLIII. and XLIV., situated in the proximal third of the patellar aspect of the thigh, between the adductor longus, g, and the junction of the psoas magnus, K, and iliacus internus, W, muscles, derives its origin from the os pubis between the linea-ileo-pectinea and the acetabulum, and descends obliquely centrad and poplitead, to be inserted into the superior tibial division of the linea aspera, immediately distad to the trochanter minor, *f*. The surface of bone from which this muscle arises, is seen in Plate III. Figs. 1 and 2, marked g, and the surface of insertion in Plate VIII., Fig. 4, marked a. * The function of the pectinalis is to bend and adduct the thigh, and to rotate the limb fibulad. When the os femoris becomes the fixed point, it inflects the trunk tibiad, and rolls it round by the dorsal aspect.

The psoas magnus has occasionally an appendix, named psoas parvus, which is situated within the abdominal cavity, dorsad of the peritoneum, extending along the lumbar vertebræ and brim of the pelvis. This muscle, the psoas parvus, † delineated in Plate XIII., marked M, is a slender muscle, deriving a fleshy origin from the sides of the bodies of the two atlantal lumbar vertebræ, along which, and superficially or sternad to the psoas magnus, K, it descends, forming a long tendon, that expands at the brim of the pelvis, to be inserted into the linea-ileo-pectinea, where the os ilium joins the os pubis. The function of this muscle is to inflect sternad and pubic the spinal column on the pelvis; and when only one muscle acts, it inflects the trunk dextrad or sinistrad. When the lumbar vertebræ are the fixed points, this muscle will assist in elevating the pelvis to the vertebræ.

The psoas magnus muscle, ‡ K, in Plates XIII. and XIV., in Plate XXXII., and in Plate XLIII., situated on the sternal or abdominal aspect of the lumbar vertebræ and brim of the pelvis, is a large round fleshy mass, deriving its origin from the sides of the bodies and transverse processes of the last dorsal, and all the lumbar vertebræ, and descending along the brim of the pelvis to emerge from the abdominal cavity beneath Paupart's ligament, where it unites with the iliacus internus, W, to be inserted into the trochanter minor, *f*, of the os femoris.

This muscle is surrounded with a strong envelope of cellular or fibrous expanse, which unites with that of the iliacus internus muscle, and is named the iliac fascia. It is connected to the lumbar vertebræ, the lumbar aponeurosis, the crest of the os ilium, the outer or iliac half of the crural arch; it descends into the pelvis, and becomes continuous with the pelvic fascia. It is very thin where it invests the origin and upper portion of the psoas muscle. § The origin is partly fleshy and partly ten-

---

* The adductor brevis femoris has the same relation to surgery that the adductor longus has.

† Syn. Pars quinti femur moventium. Pars octavi femoris musculi. Tertia pars cum quarta quinti moventium femur. Tertium caput tricipitis. Pars flectentium tertii, trecipitis. Pars trecipitis. Adductor femoris tertius cum quarto. Troisieme muscle du triceps. Troisieme adducteur. Grand adducteur. Ischio-fémoral. Ischio-pubi-fémoral.

‡ The adductor magnus femoris has the same relation to surgery that the adductor longus or brevis has.

§ Syn. Pars octavi femur moventium. Septimus femoris musculus. Pectineus. Flectentium quartus. Le pectiné. Sus-pubio-fémoral. Pubio-fémoral.

‖ From an inadvertency scarcely to be avoided, two letters P have crept into these plates: the one contiguous to the adductor longus g, and adductor brevis *g*, is the pectinalis.

* The pectinalis has the same relation to surgery that the adductor longus or brevis has.

† Syn. Psoas minor. Prélombo-pubien. Pré-lumbo-pubien.

‡ Syn. Femur moventium sextus. Quintus femoris. Lumbaris sive psoas. Lumbalis musculus. Psoas magnus seu lumbalis. Psoas major. Le psoas ou lombaire interne. Prélombo-trochantinien. Prélumbo-trochantin.

§ The psoas magnus muscle, in consequence of this strong envelope, gives a direction to the matter that is secreted in the region of the lumbar vertebræ, when one or more of them become carious; hence the matter confined by the sheath of the muscle gravitates to the region of the groin, where it is first perceptible to the practitioner. The symptoms of this disease are pain in the region of the lumbar vertebræ, increased on motion, particularly in walking, but this is sometimes so very obscure, that the disease is not evident, until there is a tumefaction in the groin. The matter sometimes gravitates under the fascia lata of the thigh, and sometimes into the pelvis, and emerges at the great sacro-ischiadic notch.

When the disease is ascertained, a small opening is to be made with a bistoury, in the protruding point; previously retracting the skin, that it may afterwards act as a valve, when all the matter is evacuated. The skin is then brought together with adhesive plaister, and tried to be healed at once; and a roller applied round the upper part of the thigh and abdomen. In a day or two afterwards, a seton is to be inserted in the region of the lumbar vertebræ. The diet should be light and nutritive, and the patient much exposed to the open air in a car-

dinous, and the muscle is pierced in several places by the lumbar nerves, and by those of them which form the anterior crural nerve. The external iliac artery and vein lie upon the muscle in its progress along the pelvis, to its emergence from the abdomen.* A bursa mucosa is generally found beneath the junction of this muscle and the iliacus internus muscle, as they proceed over the pelvis and capsular ligament of the hip-joint, to the latter of which these muscles firmly adhere. The bursa is marked 1, in Plate XLIV. The insertion into the trochanter minor, *f*, is also seen in this Plate, and so incorporated with that of the iliacus internus, W, that it cannot be separated.

The function of the psoas magnus is to bend and adduct the thigh on the pelvis, and to rotate the limb fibulad. When the os femoris is fixed, it inflects the trunk sternad and pubic, and when only one muscle acts, it inflects the trunk dextrad or sinistrad, and rolls it round by the dorsal aspect.

The iliacus internus muscle,† W, in Plates XLIII. and XLIV., and in Plate XXIV., and also in Plates XIII. and XIV., situated within the abdominal cavity dorsad of the peritoneum, occupying the venter of the os ilium, from all of which it arises, as also from the transverse process of the last lumbar vertebra, and sometimes from the os sacrum; the fibres descend out of the pelvis, beneath Paupart's ligament, where they unite with the psoas magnus, and continue to descend, to be inserted into the less trochanter, *f*, and contiguous part of the linea aspera of the os femoris, adhering to the capsular ligament, A, of the hip-joint in their course. The insertion is very clearly defined in Plate XLIV. A strong tendinous fascia, named iliaca, covers this muscle, and unites with that of the psoas magnus and that of the transversalis muscle, so as to shut up the abdominal cavity, and prevent the more frequent occurrence of hernia.‡

The function of the iliacus internus is to bend and adduct the thigh on the pelvis, and to rotate it fibulad: and when the thigh is the fixed point, this muscle will inflect the trunk tibiad, and rotate it round by the dorsal aspect.

There are four muscles situated on the patellar aspect of the thigh, and all of them connected with the patella; they are the rectus femoris, the crureus, the vastus internus, and the vastus externus.

The rectus femoris,§ I,‖ in Plate XXIV., and in Plates XLIII. and XLIV., situated on the patellar aspect of the thigh, immediately beneath the fascia lata, extending from the pelvis to the patella, is a bold penniform muscle, arising from the anterior inferior spinous process, *t*, of the os ilium, and descending along the thigh, to be inserted into the proximal point of the patella, Y, together with the crureus, P, the vastus internus, L, and the vastus externus, O. The origin of this muscle is tendinous, and derives some threads from the dorsum of the os ilium, as represented in Plate XLIV., marked *i*; as the muscle descends, it becomes more and more carneous, the tendon running between the bundles of fibres to give it the penniform appearance. The insertion is a strong tendon, intimately united with the vasti and crureus; and beneath or centrad to the insertion there is a bursa mucosa, marked 1 in Fig. 2, Plate XLIX.*

The function of this muscle is to bend the thigh on the pelvis, and to extend the leg on the thigh.

The vastus internus muscle,† L, in Plate XXIV., and in Plates XLIII. and XLIV., situated on the tibial aspect of the thigh, partially covered by the rectus, I, and the sartorius, E, muscles, and strongly adhering to the fascia lata, derives its origin from the tibial edge of the whole length of the linea aspera of the os femoris, patellad to the insertions of the psoas magnus, K, and iliacus internus, W, the pectinalis, P, and the three adductors, g, *g*, G: runs with oblique fibres downwards, that adhere to the os femoris, and which are inserted or incorporated with the crureus, P, the rectus, I, and lastly into the tibial margin of the patella, Y.‡

The function of this muscle is to extend the tibia on the os femoris, together with the rectus, crureus, and vastus externus, through the medium of the patella.

The vastus externus muscle,§ O, in Plate XXIV., situated on the fibular aspect of the thigh, partly concealed by the rectus, I, and entirely covered by the tensor vaginæ femoris, K, derives its origin from the fibular edge of the whole length of the linea aspera of the os femoris, and runs with oblique fibres downwards to be inserted or incorporated with the crureus, P, the rectus, I, and into the fibular edge of the patella, Y. The fascia lata, together with the cellular envelope of the two vasti muscles, which is remarkably strong, and with which it is incorporated, runs over the patella, Y, and its ligament, *y*, to be inserted into the tibia and fibula, as represented in Plate XLIX., marked *l*, *o*.‖

The function of this muscle is to extend the tibia on

---

riage. When matter again collects, the same treatment becomes necessary.

* The psoas magnus muscle is also concerned in the securing of either the common iliac, or the external iliac, or the internal iliac arteries, as described in pages 42 and 44; in luxation of the hip-joint, in morbus coxarius, in amputation at the hip-joint, as described in page 65; and in fracture of the neck of the os femoris.

† Syn. Septimus femur moventium. Sextus femoris. Iliacus. L'iliaque. Iliaco-trochantinien. Iliaco-trochantin.

‡ The iliacus internus muscle relates to luxation of the hip-joint, to fracture of the neck of the os femoris, to morbus coxarius, and to amputation at this joint, as described in page 65.

§ Syn. Nonus tibiam moventium. Nonus tibiæ musculus. Rectus gracilis. Extendentium tibiam secundus, rectus. Rectus. Rectus cruris. Le droit, ou grêle antérieur Droit antérieur crural. Ilio-rotulien.

‖ From an inadvertency scarcely to be avoided, two letters I have come into the Plates. The I indicating the rectus is contiguous to the letters P, which mark the crureus, and to the letter L, that points out the vastus internus; the examination, however, of Plate XXIV., first, where only one I is present, will at once render it clear.

* The rectus femoris relates to luxation of the hip-joint, to fracture of the neck and shaft of the os femoris, to amputation at the hip-joint, as detailed in page 65; to amputation of the thigh, to fracture of the patella, and to dislocation and other injuries, as well as diseases of the knee-joint.

† Syn. Pars octavi tibiam moventium. Pars octavi tibiæ musculi. Pars extendentium tibiam quarti, vasti interni. Le vaste interne. La partie interne du triceps crural. La partie interne du crural. Tri-fémoro-rotulien. Tri-fémoro-tibi-rotulien.

‡ The vastus internus muscle relates to amputation of the thigh, to fracture of the the patella, and to luxation and other injuries, as well as diseases of the knee-joint.

§ Syn. Septimus tibiam moventium. Septimus tibiæ musculus. Extendentium tibiam tertius, vastus externus. Le vaste externe. La partie externe du triceps crural. Tri-fémoro-rotulien. Tri-fémoro-tibi-rotulien.

‖ The vastus externus muscle has the same relation to surgery that the vastus internus has.

the os femoris through the medium of the patella, together with the rectus, crureus, and vastus internus.

The crureus muscle,* P, placed between L and O in Plate XXIV., and in Plates XLIII. and XLIV., is situated on the patellar aspect of the thigh, beneath or centrad to the rectus, I, and between the vasti muscles, L, O, by which it is completely hid. It arises from the patellar surface of the os femoris, commencing between the trochanters, and descending adhering to the bone and the two vasti muscles, to be inserted into the patella, Y. This muscle is merely the central fibres of these two vasti, and properly considered as one muscle by Sabatier and others. Near its insertion the bursa mucosa, 1, in Plate XLIX., is situated beneath or centrad between the tendon and the bone. †

The function of this muscle is the same as that of the two vasti.

* Syn. Pars octavi tibiam moventium. Pars octavi tibiæ musculi. Extendentium tibiam quarti, vasti interni. Femoreus. Crureus seu femoreus. Cruralis. Le crural. Le triceps crural. Crural. Tri-fémoro-tibi-rotulien.

† The crureus has the same relation to surgery that the vastus internus or externus has.

THE MUSCLES OF THE LOWER EXTREMITY.

Having examined the muscles on the anterior or rotular aspect of the limb, we come now to those on the posterior or popliteal aspect

The integuments in the region of the nates are thick and adipose, and require careful removal to display the fascia lata investing the gluteus maximus muscle,* which first presents itself in this dissection: the muscle is marked with the letters F, in Plates XLV., XLVI., and XXV., also in Plate XXII., with the letter Y. To display this muscle, an oblique incision should be made in the centre, parallel † to its fibres, until they appear; then to dissect from the origin to the insertion, or *vice versa,* carefully avoiding both the tendinous slips of the origin, and the strong tendinous fibres of the insertion incorporated with the fascia lata, k. The muscle will then be found to arise by tendinous and muscular slips, from a small surface of the crista of the os ilium,‡ near the posterior superior spinous process, *f*, from this process itself, from the dorsum of the os sacrum, particularly its spinous processes, and the dorsum of the os coccygis, and also from the long or outer sacro-ischiadic ligament, H. The fibres descend obliquely fibulad or outwards, over the trochanter major, e, of the os femoris, where the superior or anterior or iliac are incorporated with the fascia lata, k, from the origin of the gluteus medius, I, downwards to what is termed the fleshy insertion of the muscle, which runs into the outer or fibular division of the linea aspera of the os femoris, while the inferior or sacral or coccygeal fibres are loose and free.

The precise origin and insertion are best seen in Plate XLVI., the latter being marked f. The tendinous expanse of the gluteus medius, I, is, strictly speaking, the fascia lata, which also covers the gluteus maximus; on the latter, however, it is more delicate, and might be considered the cellular envelope of the muscle. This gluteus illustrates the structure of a muscle better than any other. The larger insertion of this muscle is into the fascia lata, which also covers its fleshy insertion. As the muscle glides over the trochanter major, e, there is a large bursa mucosa, which is delineated in Plate XLVI., marked *f*. §

The function of this muscle is to extend and abduct the os femoris, and to rotate the toes fibulad or outwards; the latter of which actions is greatly assisted by the fascia lata being attached to the linea aspera of the os femoris, to the patella, the fibula, and the tibia. This muscle is also through the same fascia, either a flexor or extensor of the tibia. When the os femoris is made the fixed point, the muscle inflects the trunk fibulad, and rotates it by the dorsal aspect.*

To expose the whole of the gluteus medius muscle, † marked with the letters I, in Plate XXV., and Plate XLVI., the gluteus maximus, F, is to be cut across beginning at its coccygeal margin, leaving enough of the origin to examine the muscle afterwards, and keeping the fibres strongly on the stretch to avoid injuring the long sacro-ischiadic ligament, H, the pyriformis muscle, A, and the medius itself, I. The dissector must keep close to the central or internal surface of the maximus as he proceeds, as there is a considerable quantity of cellular tissue between it and the medius.

The gluteus medius, I, now appears, situated on the dorsum of the ilium, and covered by a strong tendinous aponeurosis, the continuation of the fascia lata, K, excepting where it was overlapped by the maximus; deriving its origin from the dorsum of the os ilium, between the anterior superior spinous process, and the greater sacro-ischiadic notch; and descending with converging fibres, to be inserted in the tip of the trochanter major, e.

The surface of the bone whence this muscle arises is clearly defined in Plate VIII. Fig. 2., marked with the letters *b*. The anterior or patellar fibres are so intimately connected with the muscular fibres of the tensor vaginæ femoris, K, that they can with difficulty be separated; and the posterior or sacral or popliteal fibres are so closely attached to the pyriformis muscle, A, that the latter appears an appendage of the former: the tendons are often inseparable. The insertion is distinctly seen in Fig. 1 of Plate XLVII., marked i.

The function of the gluteus medius is chiefly to abduct the limb, for it may either bend or extend the os femoris,

* Syn. Primus femur moventium. Primus musculus femur movens. Primus omnium maximus, sui lateris clunem efformans. Maximus et extimus gloutius. Extendentium primus, glutæus major. Glutæus major. Glutæus maximus. Gluteus magnus. Glutæus magnus. Le grand fessier. Sacro-fémoral. Ilii-sacro-fémoral.

† This line of incision may be calculated by dividing the space between the superior posterior spinous process of the os ilium, and the extremity of the os coccygis into two equal parts, and from this central point drawing a line obliquely over the most prominent part of the trochanter major. The same line of incision is applicable to the securing of the gluteal artery when wounded, as described in p. 64.

‡ See Plate VIII. Fig. 2.

§ This bursa is liable to be affected with a superabundant secretion of mucus, with matter forming a chronic abscess, with cartilaginous substances, and with hydatids. In either of the two former cases, a small opening and bandage will generally cure the disease; in the two latter the bursa requires a freer opening, to extract or discharge these substances.

* The gluteus maximus relates to the securing of the gluteal and ischiadic arteries, as detailed in p. 64; is concerned in morbus coxarius, in dislocation of the hip-joint, in fracture of the neck and shaft of the os femoris, and in amputation of the hip-joint, as described in p. 65.

† Syn. Secundus femur moventium. Secundus femoris musculus. Secundus et medius gloutius. Extendentium secundus, glutæus medius. Glutæus medius. Le moyen fessier. Grand ilio-trochantérien. Ilio-trochantérien.

according as the patellar or sacral fibres are called into action. For the same reason the patellar fibres are rotators tibiad, while the sacral are rotators fibulad. When the os femoris becomes the fixed point, this muscle inflects the trunk fibulad, and rotates it either by the dorsal or sternal aspect.*

Instead of proceeding to the gluteus minimus, I shall first describe the pyriformis muscle, as it appears to be an appendage of the gluteus medius, and requires removal before the gluteus minimus can be properly investigated.

The pyriformis muscle,† A, in Plate XLVI., and in Plate XXV., is situated on the dorsum of the pelvis, running parallel with the sacral fibres of the gluteus medius, I; it derives its origin within the pelvis from the body of the os sacrum, emerges at the greater sacro-ischiadic notch, where it derives additional origin from the os ilium, descends along the sacral margin of the gluteus medius, I, and forms a strong round tendon, which is inserted in the rut behind the trochanter major, e, of the os femoris.

The origin of the pyriformis from the os sacrum within the pelvis, is from the second, third, and fourth portions, close to the foramina which give exit to the sacral nerves forming the great sacro-ischiadic, with which the fibres of the muscle are more or less blended, frequently even to their emergence at the notch, as is exemplified in Plate XLVI. Its emergence at the greater sacro-ischiadic notch is also represented in Plate XLVII., Fig. 1. The muscle is always closely connected with the gluteus medius, particularly the tendon. The point of insertion is clearly defined in Plate VIII., Figs. 3 and 4, letter *i*.

The function of the pyriformis is to extend and abduct the os femoris, and to rotate the toes fibulad or outwards. When the os femoris is made the fixed point, it inflects the trunk fibulad, and rotates the trunk by the dorsal aspect.‡

The gluteus minimus muscle,§ C, in Plate XLVI,. is brought into view, by dividing the pyriformis, A, and the gluteus medius, I, performing the division of the latter by beginning from the pyriformis muscle and ending at the tensor vaginæ femoris muscle, K:‖ between the gluteus medius and minimus there is very little cellular substance; the clear shining fibres of the latter with a conspicuous branch, *c*, of the gluteal artery are the only guides. The gluteus minimus now appears situated on the dorsum of the os ilium, deriving its origin between the inferior anterior spinous process, and the greater sacro-ischiadic notch, and descending with elegant converging fleshy fibres, which almost immediately become tendinous, and are inserted in the anterior or patellar aspect of the trochanter major, e. This muscle adheres to the bone and capsular ligament of the hip-joint throughout its course, or from its origin to its insertion. The precise origin of this muscle is delineated in Plate XLVII., Figs. 1 and 2, marked *c*; and the insertion in Fig. 1, marked c. These points of bone are always represented in Plate VIII., Figs. 2 and 3; the origin in Fig. 2 being marked with the letters *c*, and the insertion in Fig. 2 marked *e*.

The function of the gluteus minimus is chiefly to abduct the limb: it is, however, also a flexor and a rotator tibiad. When the os femoris becomes fixed, it inflects the trunk fibulad, and rotates it by the sternal aspect.*

The obturator internus muscle,† X, in Plate XLVI., and XLVII., Fig. 1, and in Plate XXV., is situated partly within and partly without the pelvis. Within the pelvis, the muscle is covered by the levator ani muscle, S, and on the dorsal or outer aspect of the pelvis, the muscle lies immediately distad to the pyriformis muscle, A.

The obturator internus derives its origin from the internal or pelvic surface of the obturator or thyroid ligament, and the margin of the bones forming the obturator foramen, descends with converging fibres, and emerges from the pelvis at the less sacro-ischiadic notch, where it is joined by the two gemelli muscles, X, *x*, which proceed obliquely across, forming one tendon inserted in the rut behind the trochanter major, e, of the os femoris. Where the muscle glides round the os ischium, between the spine and tuberosity, there is a synovial bursa, marked 1, in Fig. 1 of Plate XLVII. In this figure of the same Plate, the tendinous insertion of the muscle is clearly displayed. The gemelli muscles are appendages or integral portions of the obturator internus.

The gemellus superior‡ is merely the trifling fasciculus of fibres marked X, which arise from the spine of the os ischium, and accompany the muscular fibres of the obturator internus, until they become tendinous, when they unite, and form one tendon. At first a difficulty exists in the separation of the gemelli from the obturator, and the only legitimate way to distinguish them, is to remove the obturator from its origin within the pelvis, and to pull it through the notch, when the fibres constituting the gemelli remain. The precise origin from this gemellus is seen in Fig. 1 of Plate XLVII. The superior gemellus is occasionally deficient.

The gemellus inferior muscle,§ marked *x*, in Plate XLVI., derives its origin from the tuberosity, Z, of the

---

* The gluteus medius relates to the securing of the gluteal artery, and is concerned in morbus coxarius, in luxation of the hip-joint, in fracture of the neck and shaft of the os femoris, and in amputation at the hip-joint, as described in page 65.

† Syn. Quartus femur moventium. Quartus femoris musculus. Primus et superior quadrigeminus, iliacus externus. Circumagentium primus, iliacus externus, pyriformis. Pyriformis, seu iliacus externus. Le pyriforme ou pyramidal. Sacro-trochantérien. Sacro-ili-trochantérien.

‡ The pyriformis muscle is concerned in luxation of the hip-joint, in morbus coxarius, in fracture of the neck of the os femoris, and in amputation at the hip-joint, as described in page 65.

§ Syn. Tertius femur moventium. Tertius femoris musculus. Tertius et internus gloutius. Extendentium tertius, glutæus minor. Glutæus minor. Glutæus minimus. Gluteus minor. Le petit fessier. Petit ilio-trochantérien. Ilio-ischii-trochantérien.

‖ The K indicating the tensor vaginæ femoris, is on the outer or fibular aspect of the limb, this being the left extremity, and the muscle is represented on the stretch; while the quadratus femoris, marked also by K, is divided across.

* The gluteus minimus is concerned in luxation of the hip-joint, in morbus coxarius, in fracture of the neck of the os femoris, and in amputation at the hip-joint, as described in page 65.

† Syn. Decimus femur moventium. Decimus femoris musculus. Circumagentium tertius, obturator internus. Marsupialis seu bursalis. Marsupialis seu obturator internus. L'obturator interne. Sous-pubio-trochantérien interne. Intra-pelvio-trochantérien.

‡ Syn. of Gemellus superior et inferior. Carneæ portiones, decimo femur moventium musculo attensæ. Marsupium carneum. Secundus et tertius quadrigeminus. Carneum marsupium. Marsupium. Gemini. Les petits jumeaux. Le jumeaux. Muscle capsulaire de la capsule du tendon de l'obturateur interne. Ischio-trochantérien. Ischio-spini-trochantérien.

§ The synonymes of the gemellus superior answer also for this. See preceding note.

os ischium, and like the superior, accompanies the muscular fibres of the obturator internus, until they become tendinous, when they unite, and along with the superior form one tendon, inserted in the rut behind the trochanter major, e. The precise origin is distinctly seen in Fig. 1 of Plate XLVII.

The functions of the obturator internus and the gemelli are the same, only the obturator has more power than the gemelli. They extend and abduct the os femoris, and rotate it fibulad; and when the os femoris becomes the fixed point, they inflect the trunk fibulad, and rotate it by the dorsal aspect.*

The quadratus femoris muscle,† letters K, in Plate XXV., and in Plate XLVI.,‡ situated between the os ischium and the trochanter major of the os femoris, derives its origin from the obtuse ridge of the os ischium, between the tuberosity and the obturator foramen, and runs transversely to be inserted in the ridge extending between the trochanter major and minor. This muscle throughout is fleshy: its origin is distinctly seen in Plate XLVII., Fig. 2, and its insertion in Plate XLVI.

The function of the quadratus femoris is to extend and adduct the os femoris, and also to rotate the toes fibulad. When the os femoris becomes the fixed point, it inflects the trunk tibiad, and turns it by the dorsal aspect. §

The obturator externus muscle, ‖ letters D in Plate XLIV., and Plate XLVI., situated beneath the pyramidalis muscle, P, and the three heads, g, *g*, G, of the triceps muscle, derives its origin from the exterior surface of the obturator ligament, and the margins of the bones forming the obturator foramen, and runs with converging fibres round, or poplitead to the cervix of the os femoris, to be inserted by a strong tendon in the rut behind the trochanter major, e, of the os femoris. In Plate XLIV., the radiated origin is distinctly seen; the pyramidalis, P, the gracilis, Q, and the three heads g, *g*, G, of the triceps, being removed close to their origins. The obturator artery, *d*, the vein, d, and the twigs of the nerve, 21, are observed piercing the fibres of the muscle. The muscle is perceived to adhere to the capsular ligament, A, in its course round the neck of the os femoris. In Plate XLVI., the muscle was hid by the quadratus femoris, K, and hence the latter is cut across. In Fig. 2 of Plate XLVII., the origin from the ossa pubis et ischii, where they form the obturator foramen, is represented; that from the ligament, U, having been removed to exhibit the latter. The function of the obturator externus muscle is to adduct the os femoris, and to rotate the toes fibulad. When the os femoris becomes the fixed point, it inflects the trunk tibiad, and rotates it by the dorsal aspect.*

I shall describe the hamstring muscles before proceeding to the hip-joint, because they influence the healthy and diseased functions of this articulation.

The semi-tendinosus muscle,† M, in Plates XXV. and XXVIII., and in Plates XLVI. and L., situated on the popliteal aspect of the thigh, immediately beneath the fascia lata, k, arises by a broad origin, in conjunction with the long head of the biceps muscle, L, from the tuberosity, Z, of the os ischium, descends connected with the biceps muscle, nearly one-half of the thigh, where it separates, and proceeds along the tibial margin of the poples, forming a long tendon, which is inserted along with the sartorius, E, and the gracilis, Q, in the head of the tibia, distad and poplitead to its tubercle, being covered by the tendinous expanse of the former, and situated distad to the latter. The connexion with the biceps, both at the origin and downwards in the thigh, is very strong, and requires to be cautiously separated from the poples upwards. These two muscles conceal the semi-membranosus. The insertion is partly surrounded by a bursa mucosa common to this muscle, the sartorius and the semi-membranosus muscles, as represented in Plate L.; the bursa being marked *e*.

The function of this muscle is to extend and adduct the os femoris, to bend the tibia on the os femoris or the knee-joint, and to rotate the toes tibiad, if the leg be extended.‡

On the popliteal aspect of the thigh, immediately beneath or centrad to the fascia lata, k, and parallel with the semi-tendinosus muscle, the biceps flexor cruris, § letters L, l, *l*, Plate XXV., and Plate XLVI., is found. The long head, L, of this muscle derives its origin from the tuber ischii, Z, in conjunction with the semi-tendinosus, M, descends nearly one-half of the thigh, where it separates from the latter, proceeds to the fibular margin of the poples, and is joined by its shorter head, l, which arises from the distal half of the linea aspera of the os femoris; and thus united, both continue to descend on the fibular aspect of the poples, and are inserted by one tendon, *l*, in the head of the fibula.

The function of the biceps muscle is to extend and adduct the os femoris, to bend the knee-joint, and to rotate the toes fibulad, if the leg be extended. ‖

---

* The obturator internus and gemelli are concerned in luxation of the hip-joint, in morbus coxarius, in fracture of the neck of the os femoris, and in amputation at the hip-joint, as described in page 65.

† Syn. An est pars quinti femur moventium. Pars octavi femoris musculi. Est undecimus movens femur. Undecimus. Quartus quadrigeminus quadratus. Circumagentium quartus. Quadratus femori. Le carré. Carré crural. Ischio-sous-trochantérien. Tuber-ischio-trochantérien.

‡ The quadratus femoris, indicated by the letters K in Plate XLVI., is cut across, so that it is easily distinguished from the tensor vaginæ femoris, inadvertently marked with the same letter, the latter muscle being entire and on the stretch, and having only one letter placed on it, while the quadratus has four.

§ The quadratus femoris muscle is concerned in luxation of the hip-joint, in morbus coxarius, in fracture of the neck of the os femoris, and in amputation at the hip-joint, as detailed in page 65.

‖ Syn. Nonus femur moventium. Nonus femoris musculus. Duodecimus. Externus obturator. Circumagentium secundus, externus obturator. L'obturateur externe. Sous-pubio-trochantérien externe. Extra-pelvio-pubi-trochantérien.

* The obturator externus is concerned in luxation of the hip-joint, in morbus coxarius, in fracture of the neck of the os femoris, and in amputation at the hip-joint, as detailed in page 65.

† Syn. Tertias tibiam moventium. Tertius tibiæ musculus. Semi-nervosus. Flectentium tibiam tertius, semi-nervosus. Semi-nervosus, seu semi-tendinosus. Le demi-nerveux. Le demi-tendineux. Ischio-prêtibial. Ischio-crêti-tibial.

‡ The semi-tendinosus muscle relates to the securing of the popliteal artery, as described in page 66; to amputation at the hip-joint, as detailed in page 65; to dislocation of the hip-joint, to morbus coxarius, to fracture of the neck and body of the os femoris, and to amputation of the thigh. It is also concerned in amputation of the leg, in luxation and other injuries and diseases of the knee-joint.

§ Syn. Quartus tibiam moventium. Quintus tibiæ musculus. Biceps. Flectentium tibiam quintus, biceps. Biceps cruris. Le biceps. Biceps femoris. Biceps crural. Ischio-fémoral-péronier.

‖ The biceps muscle relates to the securing of the popliteal artery, as detailed in page 66; to amputation at the hip-joint; as described in page 65; to luxation of the hip-joint, to morbus coxarius, to fracture of the neck and shaft of the os femoris, and to amputation of the thigh. It is also concerned in amputation of the leg, in luxation and other injuries and diseases of the knee-joint.

The semi-membranosus muscle,* N, Plates XXV., XXIV., XXVIII., and XLIV., and in Plate L., situated on the popliteal aspect of the thigh, beneath or centrad to the biceps, L, and semi-tendinosus, M, muscles, derives its origin from the tuberosity, Z, of the os ischium, and descends along the tibial margin of the poples, forming a strong round tendon, which is inserted in a tubercle, on the popliteal aspect of the head of the tibia. Here the tendon sends off three sets of fibres; the first ascends obliquely upwards and outwards to the back part of the fibular condyle of the os femoris, to which it is attached, and thus forms the popliteal ligament; the second set twines round the inner border of the internal tubercle of the tibia; and the third set descends, and spreads out, so as to cover the popliteus muscle, and is inserted into the oblique ridge on the popliteal aspect of the tibia. The origin is chiefly tendinous, the muscle swelling to a great breadth in its middle, and forming a penniform appearance. The insertion is defined in Plate L. The function is to extend and adduct the os femoris, and to bend the knee-joint.†

When the several muscles round the hip-joint,‡ and those of the thigh have been examined, the ligaments of this joint should be investigated. These are the capsular and the teres, which are represented in Plates XLIV. and XLVII.; the former, or capsular, is marked A, and the latter, or teres, B.

The capsular ligament, A,§ situated round the articulation of the thigh-bone with the pelvis, arises from the os innominatum round the brim of the acetabulum, by strong ligamentous fibres which encircling the head, *b*, and cervix, *d*, of the os femoris, is inserted in the root of the cervix at the trochanters, then glides with more or less scattered fibres upwards to the margin of the head, *b*, where it terminates.

In Plate XLVII., Fig. 2, the capsular ligament is cut across by a circular incision, nearly at equal distances, between its attachment to the os innominatum, and its first attachment to the root of the cervix of the os femoris; the letters A indicate the former, the letter a the latter. The letters *a* indicate the reflection of the ligament, along the cervix, D, to the margin of the head; the letter D being placed merely to disignate the cervix. The fibres of the ligament are strongest opposite the inferior anterior spinous process, as represented in Fig. 1, Plate XLVII., letter a, and are improperly considered by some a distinct ligament named ilio-femoral. The interior surface of this ligament illustrates the synovial membrane in a satisfactory manner. The acetabulum is considerably deepened by a brim of fibro-cartilage, named the cotyloid ligament, marked 1, in Fig. 2, which is better understood by comparing this Plate with Plates III. and VIII.; for this brim, which is incomplete in the osseous state, is here rendered perfect by the continuation of the fibro-cartilage opposite the obturator foramen, 10, named the transverse ligament by some.

The use of this ligament is to connect the os femoris with the os innominatum, and to confine the synovial juice.

The acetabulum or cotyloid cavity, r, is lined or encrusted with cartilage, excepting where the synovial gland, R, is placed. This is a beautiful glandular tissue extremely vascular, its vessels deriving their origin from the obturator, *d*, and running beneath the fibro-cartilaginous ligament, 10; for there remains still a foramen. Its function is to secrete the synovial fluid.

The ligamentum teres,* B, in Fig. 2 of Plate XLVII., situated within the capsular ligament of the hip-joint, extending between the head of the os femoris and the acetabulum, is attached by a circular arrangement of ligamentous fibres condensed into the small round depression a little pubic of the centre of the head, *b*, of the os femoris. From this the fibres expand or radiate, to be attached to the bottom of the acetabulum, which looks pubic, and also to the fibro-cartilaginous ligament, 10, which completes the brim of the acetabulum. This ligament has sometimes the appearanee of being double.†

---

* Syn. Quintus tibiam moventium. Quartus tibiæ musculus. Flectentium tibiam quartus, semi-membraneus. Le demi-membraneux. Demi-aponévrotique. Ischio-popliti-tibial.

† The semi-membranosus muscle relates to the securing of the popliteal artery, as described in page 66; to amputation at the hip-joint, as detailed in page 65; to luxation at the hip-joint, to morbus coxarius, to fracture of the neck and body of the os femoris, and to amputation of the thigh. It is also concerned in amputation of the leg, in luxation and other injuries and diseases of the knee-joint.

The various muscles of the thigh should be considered in their relation to fracture of the shaft of the os femoris, and to amputation of the thigh; with respect to the former, the reader is referred to page 65; and with regard to the latter, he must remember that many of the muscles round the thigh are free and loose; and therefore, when divided in the living state, they retract from the face of the stump, and cannot be retained by the most dexterous bandaging, so as to cover the cut end of the bone. Consequently the muscles which we have to take into more immediate consideration, are the crureus, the two vasti, and the heads of the triceps, with the short head of the biceps, according to the part of the limb to be removed. As the patient will have to lie on his back after the operation, the line of cicatrix should run from the patellar to the popliteal aspect. The patient being placed on a table with the leg hanging over, supported by an assistant, the artery compressed, the skin retracted by an assistant, two semi-elliptical flaps are to be made by transfixing the skin and contiguous muscles on each side of the bone, from the patellar to the popliteal aspect, with their convexities large, and pointing distad, and their extremes meeting patellad and poplitead. The bone is to be cleaned of the adhering muscular fibre, the flaps retracted, and the former sawn by long sweeps of the saw. The arteries are next to be secured, which, generally, are the superficial femoral, the continuation of the profunda femoris, and two or three muscular branches. See Plate XXIV. Both ends of the ligatures should be cut off, the flaps brought in apposition, and retained by stitches.

‡ Syn. Ilio-femoral.

§ Syn. Membrana capsularis femoris. Capsule fibreuse de l'articulation coxo-fémorale. Fibrous capsule.

* Syn. Ligamentum teres capitis femoris. Ligamentum rotundum. Le ligament inter-articulaire. The inter-articular ligament.

† As the hip-joint admits of motions similar to those performed at the shoulder, and as the pelvis and os femoris cannot so readily accommodate themselves to each other's motions as the scapula and os brachii, we should imagine that the hip-joint ought to be more frequently luxated than the shoulder-joint. We have, however, only to recollect, that the head of the thigh-bone is sunk deep into the acetabulum; that the thigh-bone forms an angle with its shaft and neck, the head of which is a fulcrum wedged into the acetabulum of the pelvis, and firmly retained there by ligaments and muscles, while the actions which these muscles perform are less irregular and extensive than those at the shoulder.

The hip-joint is subject to the following kinds of luxation; first, the head of the os femoris may be dislocated upwards and backwards, or, according to Dr. Barclay's excellent nomenclature, atlantad and sacrad, on the dorsum of the os ilium; secondly, it may be driven sacrad and coccygead on the great sacro-ischiadic notch; thirdly, it may be forced downwards and inwards, or distad and pubic, on the obturator foramen; and fourthly and lastly, it may be pushed upwards and forwards, or atlantad and pubic, on the os pubis, near the point of junction between the os pubis and the os ilium. Of these different directions, the first and third are those which commonly occur.

When we consider the obliquity of the plane of the pelvis where the acetabulum is situated, and the line of direction of the neck of the os

Its use is to connect the os femoris with the os innominatum.

After the examination of the ligaments of the hip-joint, either those of the pelvis or of the knee may be investigated; I shall begin with the former.

---

femoris, as well as the direction of the thigh-bone itself, it will appear evident that luxation will most commonly take place upwards and outwards on the dorsum of the os ilium.

When the first of these takes place, or the head of the thigh-bone is forced atlantad and sacrad, the capsular ligament is ruptured, and to a greater or less extent lacerated; an event which must occur in all the luxations of this joint, in consequence of the tenseness and unyielding nature of this ligament. The round ligament is also too short to extend to this distance, and is consequently torn. The gluteus minimus muscle, from the shortness of its fibres, and their adhesion to the capsular ligament, must also be more or less injured. The quadratus femoris and the obturator externus et internus, with the gemelli muscles, from the shortness of their fibres, and from being violently stretched, are also liable to be torn; and for the same reasons the proximal or superior fibres of the great head of the triceps muscle. The gluteus maximus and medius, the pyriformis, the long head of the biceps, the semi-tendinosus and semi-membranosus, the three heads of the triceps, with the exception of the superior fibres of the adductor magnus, the gracilis, the rectus femoris, and the sartorius muscles, will be relaxed by their extremes being approximated. The only muscles, therefore, thrown on the stretch, are the psoas magnus, the iliacus internus, the pectinalis, the obturator externus et internus, with the gemelli, the quadratus femoris, and the superior fibres of the adductor magnus. These, with the exception of the obturator internus and gemelli, are all adductors of the limb, and rotators fibulad; but the limb is shorter, the knee a little thrown across the other limb, with the toes turned inwards or tibiad, and resting on the sound foot. The shortening of the limb is at once accounted for, and also the adduction to the sound one. But why rotated inwards? This can only be satisfactorily accounted for by the natural position of the bones; it is also assisted by the anterior or pubic fibres of the gluteus medius being thrown on the stretch, and pulling the trochanter major forwards or pubic. The pubic fibres of the gluteus minimus, if left sound, and the strong pubic fibres of the capsular ligament, if entire, will assist the gluteus medius in giving this direction; for the head of the bone is pushed sacrad, while the trochanter major looks pubic.

The means to be employed in reducing this luxation are the same as those directed for dislocation of the shoulder-joint. A wet hand-towel is to be applied round the thigh immediately above the knee-joint, and to this is affixed the two ends of a dry towel folded diagonally, the middle or noose of which is to be thrown round the shoulders of the operator, like the belt of a soldier's cartouch-box. The patient lying on a mattress laid on the floor, the surgeon throws the noose of the dry towel over his head, puts his foot on the perineum of the patient, which should be previously cushioned, and gradually extends, while an assistant rotates the limb so as to favour the action of the muscles in directing the head of the os femoris into the acetabulum. When the luxation has taken place beyond a day or so, the pulley apparatus should be adopted, combined with the warm bath and antimonial solution. After reducing any luxation of the hip-joint, the limbs should be so tied, as to prevent the bone from slipping out.

When the head of the os femoris is forced on the greater sacro-ischiadic notch, between the gluteus medius and pyriformis muscle, it is further removed from the acetabulum; consequently there is a greater extent of injury done to the capsular and round ligaments, and also to the muscles, than in the preceding luxation. The capsular ligament is almost entirely or totally lacerated around, the round one is torn across, the gluteus medius considerably destroyed, the pyriformis, obturator internus, gemelli, quadratus femoris, superior fibres of the adductor magnus, pectinalis and obturator externus, are all more or less injured, which must arise from the trochanter major looking pubic, while the head of the thigh-bone points sacrad; and this must depend on the anterior or pubic fibres of the gluteus medius pulling the trochanter major in this direction. The same muscles will be relaxed and thrown on the stretch as in the preceding luxation; so that the position of the limb is nearly the same, only it is shorter, with the knee and toes turned tibiad or inwards, but not so much as in the former, and with the great toe resting upon that of the other foot.

The manner of reduction is the same as in the foregoing case, with this difference, that when extension has begun, the hands of an assistant, or a towel, should be put on the inside or tibial aspect of the top or proximal extremity of the thigh close to the joint, to elevate the head of the thigh-bone over the high brim of the acetabulum.

The third direction of displacement of the head of the os femoris, is on the obturator foramen, in which case the capsular ligament is ruptured, and more or less lacerated round; but the ligamentum teres sometimes remains sound, although it is in general torn. The obturator externus, the pectinalis, the adductor brevis, the gluteus minimus, the pyriformis, obturator internus, gemelli, and quadratus femoris, must be all more or less injured. The three heads of the triceps, the inner and outer hamstring muscles, the gluteus maximus and medius, and the psoas magnus, with the iliacus internus, will be overstretched. The limb is rendered longer from the simple position of the bones, and is a little abducted by the greater power of the glutei; and also rotated slightly outwards or fibulad by the rotators in this direction being more powerful than their antagonist rotators tibiad. The patient bends his body forwards to relax the psoas muscle, the anterior crural nerve, and the blood-vessels; he cannot put his heel to the ground, in consequence of the flexors of the knee-joint being overstretched and bending a little the knee, which is advanced, and far separated from the other, while his toes touch the ground.

Reduction of this accident is accomplished by laying the patient on a sofa, or mattress on the floor, the surgeon placing his knee on the inside or tibial aspect of the top of the affected thigh close to the joint, and then with his hands seizing hold of the limb at the ankle, and bringing the limb across towards the other, when the head of the thigh-bone will slip into the acetabulum. Care must be taken not to adduct the affected limb too much, as the head of the os femoris may start over the outer or sacral margin of the pelvis, and form a worse luxation, which, should it happen, is to be instantly reduced, as directed above. If these directions should not succeed, let the patient be fixed with the pullies, and the affected limb adducted, while an assistant acts with his hands as directed in the luxation on the greater sacro-ischiadic notch.

The fourth and last direction is atlantad and pubic on the os pubis. In this, the capsular ligament is ruptured and more or less lacerated around, the ligamentum teres is also torn across, and the gluteus minimus must likewise be injured, as well as the iliacus internus and psoas magnus, beneath which the head of the bone burrows. The limb is shortened from the position of the bones, the knee and foot rotated outwards or fibulad from the glutei, the pyriformis, the obturator internus, the gemelli, the quadratus femoris, the superior fibres of the adductor magnus, the iliacus internus and psoas magnus muscles being thrown on the stretch; while the pectinalis, the three heads of the triceps, and all the hamstring muscles, are relaxed. The knee is also widely removed from the other, partly from the position of the bones, and partly from the abductor muscles mentioned above being overstretched; the great toe can touch the ground, but the heel is retracted; and the head of the os femoris is felt upon the body of the os pubis.

The mode of reducing this should be the same as in the last; but in the event of its failure, the patient ought to be placed on his sound side, and fixed by a cushioned roller put between his thighs, or on his perineum, and fastened by ropes and a staple in the wall, then the pullies applied to the thigh, and the limb extended backwards and downwards. After the extension has been continued for a little while, a towel should be put round the upper part of the thigh close to the joint, and the noose over the shoulders of the operator; with this the head of the thigh-bone is to be raised over the margin of the acetabulum, the operator, in the meanwhile, pressing down the pelvis. For further information on luxations of the hip-joint, consult Sir Astley Cooper on Fractures and Dislocations, and Lizars' Practical Surgery.

These varieties of luxation of the hip-joint are liable to be confounded with fracture of the neck of the os femoris, particularly the first or the displacement of the thigh-bone on the dorsum of the os ilium, and even that on the body of the os pubis, if the practitioner be not very careful. In fracture of the neck of the os femoris within the capsular ligament, there is a fair trial of strength between the different classes of muscles round the joint, and as the extensors, abductors, and rotators fibulad, are much more powerful than their antagonist flexors, adductors, and rotators tibiad, the limb is consequently shortened, slightly abducted, and rotated outwards or fibulad. When the limb is extended the length of the other, and rotated inwards, a crepitus is generally observable. This fracture is to be treated with Desault's long splint. See Lizars' Practical Surgery, Part I. In many, this part of the bone unites only by ligament, therefore the powerful extensors drag the trochanter major upon the dorsum of the os ilium, the gluteus medius pulling it forwards or pubic, until the limb assumes the same appearance as in luxation on the dorsum of the os ilium. In others, ossific union

In Fig. 2 of Plate XLVII. the obturator ligament,* U, consisting of a variegated arrangement of fibres, is observed to fill up the obturator foramen; part of the obturator externus muscle, D, being left attached to the margin of the bone forming the aperture. This ligament is attached all round to the margins of the bones of the pubes and ischium which form the foramen, but a hole is left under the os pubis, near its junction with the os ilium, for the passage of the obturator nerve, 21, artery, *d*, and vein, d. This ligament forms part of the walls of the pelvis, thereby supporting the viscera, and affording origin to the two obturator muscles. †

In Fig. 1 of Plate XLVII., and Figs. 1 and 2 of Plate XLVIII., the two sacro-ischiadic ligaments, H, h, are represented, the longer being marked H, the shorter, h. The longer ligament,‡ H, which is also broader, and situated more dermal or superficial than the other, arises from the tubercle and oblong flat surface, *g*, on the dorsum of the os sacrum, which are formed by the two lower transverse processes, also from the contiguous surface of the os sacrum, and even the coccyx, *b*. From this broad extent of origin, the fibres run converging to the tuberosity, Z, of the os ischium to which they are attached, and where they again expand. The use of this ligament is to connect these bones of the pelvis, to support the pelvic viscera, to limit the outlet of the cavity, to afford origin to the gluteus maximus muscle, and to assist in forming the less sacro-ischiadic notch or foramen.

The short sacro-ischiadic ligament,§ h, in Plates XLVII. and XLVIII., situated more centrad or pelvic than the other, derives its origin from nearly the same point of the os sacrum, but not from such an extent of surface, and runs transversely, to be attached to the spine of the os ischium. This ligament assists in shutting up the pelvic cavity, supports the viscera contained therein, forms part of the greater and less sacro-ischiadic notches or foramina, and affords origin to the coccygeus muscle.

The os coccygis, *b*, in Fig. 1 of Plate XLVII., and Fig. 2 of Plate XLVIII., is connected to the os sacrum by fibro-cartilage and a broad ligamentous expanse, which is stronger and more conspicuous on the posterior* aspect or dorsum of the bone, than on the anterior.† The former is marked a, in Fig. 2, Plate XLVIII. The fibres of the sacro-ischiadic ligaments are blended both with the posterior and anterior expanses of this ligament. The use of these ligamentous fibres is to connect the os coccygis with the os sacrum. The separate portions of the coccyx are connected together by intervertebral fibro-cartilages, and short intervertebral or corruscating ligaments. Similar to this ligamentous expanse of the coccyx, is one which invests the sacrum and ossa innominata; and where there is an articulation, such as the sacro-iliac, *f*, Fig. 1, Plate XLVIII., it is entitled to the name of a ligament, and termed by some the anterior sacro-iliac; but elsewhere it is merely the periosteum. It is this which reduces in magnitude the foramina in the sacrum which transmit the several nerves; and also runs along and round the ventral aspect of the crista, S, of the os ilium onwards to the symphysis pubis,‡ surrounding this symphysis.§ The former, named lacertus ligamentosus, is marked q; the production of the latter, which encircles the membranous portion of the urethra, will be described under the male organs of generation.

The posterior or dorsal aspect of the sacro-iliac synchondrosis has some powerful ligamentous bands,‖ marked *z*, in Fig. 2 of Plate XLVIII., extending between the posterior superior spinous process, *f*, of the os ilium and the os sacrum, the use of which is to connect these bones.¶ Some ligaments, nearly of equal strength, extend between the crista, S, of the os ilium, and the transverse processes of the two or three inferior or sacral lumbar vertebræ,** and the superior transverse process of the os sacrum. These ligaments are marked k in Fig. 2 of Plate XLVIII. The short ligamentous bands, marked *i*, in Figs. 1 and 2 of Plate XLVIII., extending between the os sacrum and os ilium, both on the anterior or pubic, and on the posterior or dorsal, are named ligamenta vaga.††

The fibrous capsules of the articular processes of the vertebræ are delineated in Fig. 2 of Plate XLVIII., marked 2,‡‡ surrounding the articular processes of each two vertebræ, so as to connect them together.

In Fig. 3 of Plate XLVIII., the common anterior ligament of the vertebræ §§ is delineated, marked *a*, ex-

---

takes place, which depends on the periosteum not being destroyed. Verduc, Paré, and Petit were deceived in their diagnosis of luxation and fracture of the neck of the os femoris. For further information on this subject, see Sir Astley Cooper on Fractures and Dislocations, Colles in Dublin Hospital Reports, Delpech's Chirurgie Clinique, and Lizars' Practical Surgery.

In morbus coxarius, the functions of the muscles round the joint are clearly displayed. In this disease, inflammation, suppuration, and ulceration of the ligaments and synovial membranes first take place, then relaxation of the muscles, when the head of the thigh-bone descends downwards, and the limb becomes elongated with the toes turned outwards or fibulad. This stage is of short duration, as the extensors soon begin to act, pulling the head of the os femoris upwards on the dorsum of the os ilium, thus rendering the limb shorter, and turning the toes inwards or tibiad, as if there was a luxation in this direction. During the inflammatory stage, leeches should be applied, or the part cupped repeatedly, and followed by warm opiate fomentations and poultices, with rest. If these fail, a seton should be inserted. In old age, a communication is frequently established between the bursa mucosa of the psoas magnus and the interior of the joint, by the capsular ligament being worn through; and this synovial pouch is now and then affected with chronic abscess.

* Syn. Ligamentum obturans foraminis ovalis. Membrana obturans foraminis thyreoidis ossium coxæ. Obturator membrane.

† Hernia sometimes takes place at this aperture.

‡ Syn. Large, posterior, external, or great sacro-ischiatic, or sacro-sciatic ligament. Ligamentum tuberoso-sacrum, sive ligamentum sacro-ischiadicum majus.

§ Small internal or anterior sacro-ischiatic, or sacro-sciatic ligament. Ligamentum spinoso sacrum, sive ligamentum sacro-ischiadicum minus internum.

* Syn. Ligamenta postica ossium coccygis. Ligamentum capsulare coccygis. Le ligament sacro-coccigien postérieur. The posterior sacro-coccygeal ligament.

† Ligamenta priora ossium coccygis. Ligamenta longitudinalia coccygis, &c. Le ligament sacro-coccigien antérieur. The anterior sacro-coccygeal ligament.

‡ Syn. Lacertus ligamentosus.

§ Syn. Annular ligament.

‖ Syn. Ilio-sacral ligament. Ligamentum posticum longum et breve ossis coxæ. Le ligament sacro-iliaque et le ligament sacro-epineux supérieur et inférieur. The posterior sacro-iliac ligament.

¶ These ligaments have been found occasionally to be relaxed in parturition, and have been torn in luxation of this articulation.

** Syn. Transverse ligaments: those attached to the lumbar vertebræ are named superior, while that to the sacrum is styled inferior. The latter is also sometimes denominated ligamentum laterale posticum ossis coxæ; and the superior, ligamentum pelvis anticum superius et inferius; also, le ligament ilio-lombaire, ilio-lumbar ligament.

†† Syn. Ligamenta accessoria, vaga, postica ossis sacra. Les ligamens sacro-vertebral. The sacro-vertebral ligament.

‡‡ Syn. Ligamenta processuum obliquorum vertebrarum. Capsular ligaments.

§§ Syn. Ligamentum corporibus vertebrarum commune anterius, sive

tending along the anterior or sternal aspect of the vertebræ. It begins at the atlas, ends at the coccyx, and consists of a longitudinal arrangement of strong ligamentous fibres, which bind the vertebræ to each other. Beneath this longitudinal arrangement of fibres a crucial is found, which is represented in Fig. 1 of Plate XLVIII., marked b. These crucial or intervertebral ligaments extend between the bodies of each two contiguous vertebræ, crossing each other obliquely, and thus binding the vertebræ still more securely together.

In Fig. 3 of this Plate, are depicted two of the fibrous capsules of the heads of the ribs,* marked c; these surround the heads of the ribs, and are attached to the sides of the bodies of the vertebræ, encircling the smooth depressions formed between each two contiguous vertebræ: the articulation being named the costo-vertebral. The superior is left entire, while the inferior is laid open. With the exception of the articulations of the first, eleventh, and twelfth ribs, there is an inter-articular ligament which extends from the ridge on the head of the rib to the intervertebral fibro-cartilage, dividing these articulations into two; so that there are two synovial membranes. These connect the heads of the ribs with the bodies of the vertebræ.

I shall now proceed to the description of the ligaments of the knee-joint, or femoro-tibial articulation, although some of the muscles situated on the back of the leg should be first examined. My reason for adopting this arrangement is, that the drawings of this joint precede those of the leg. In Plate XLIX. the anterior or patellar aspect of the knee-joint is delineated, Fig. 1 being a representation of the exterior, and Fig. 2 one of the interior of the joint. In Fig. 1, the letters *l* and *o* indicate the expanse of the fascia lata united with the cellular envelope of the vasti muscles, as described in page 107, which is laid open and reflected, to bring into view the patella, Y, with its ligament, *y*. This patellar ligament, † *y*, situated on the anterior or patellar aspect of the knee-joint, extends between the distal point or apex, *d*, of the patella, and the tubercle, d, of the tibia. The attachment to the tubercle of the tibia is represented in Fig. 2 of Plate L., the ligament being reflected downwards and truncated. This ligament is remarkably thick and strong, and forms the connecting link between the muscles on this aspect of the thigh and the bones of the leg, and is considered, by some, the continuation of their tendons, the patella in this view being a sesamoid bone interposed between them. ‡ Beneath it, near the patella, Y, a bursa mucosa is found, and is marked 𝔶, in Fig. 1 of Plate XLIX. §

fascia longitudinalis anterior. Le grand surtout ligamenteux antérieur de la colonne vertebrale.

* Syn. Ligamentum capituli costarum. Capsular ligaments of the heads of the ribs. Les ligamens rayonnés. The anterior or radiated ligament.

† Syn. Anterior ligament of patella. Ligamentum patellæ. Le ligament inférieur de la rotule.

‡ The patellar ligament is concerned in fracture of the patella, and in luxation and other injuries and diseases of the knee-joint, as will be immediately explained.

§ This bursa is liable to be affected with a superabundant secretion of synovia; with matter forming a chronic abscess; also with cartilaginous substances and hydatids. In the first of these cases, blistering and bandage will generally effect a cure; in the second, a seton is commonly requisite. In the two latter, the bursa requires a free opening, to extract or discharge these substances. See Lizars' Practical Surgery, Part I., page 167.

The popliteal ligament,* marked 10, in Figs. 1, Plates L., LI., LII., and LIII., situated beneath or centrad to the outer heads, R, R, of the gastrocnemius muscle, the plantaris, U, and the popliteus, V, muscles, extends between the external or fibular condyle, *n*, of the os femoris, and the popliteal aspect of the head of the tibia, marked *i*, and adheres to the capsular ligament in its course. This ligament is considered by some to be a continuation of the tendinous insertion of the semi-membranosus muscle. The use of this ligament is to assist in connecting the tibia and the os femoris together, and in limiting extension of the knee-joint.†

The internal or tibial lateral ligament,‡ marked 2 in Figs. 1, Plates L., LI., LII., and LIII., situated on the tibial aspect of the knee-joint, begins by a broad origin from the internal or tibial condyle, *m*, of the os femoris, descends adhering to the fibrous capsule, and is attached to the tibia a little below its head, being covered by the tendinous insertions of the sartorius, E, the semi-tendinosus M, and the gracilis, Q, muscles.§ The use of this ligament is to connect the tibia and os femoris together, and to prevent rotation of the joint.

The external or fibular lateral ligament, ‖ marked 3, in Figs. 1 and 2, Plate XLIX., and Figs. 1, Plates LI., LII., and LIII., situated on the fibular aspect of the knee-joint, generally consists of two slips, both of which arise from the external or fibular condyle, *n*, of the os femoris; but the one is inserted in the head of the fibula, 6, and is the longer; while the other is attached to the head of the tibia, is the shorter, adheres to the fibrous capsule, and is sometimes deficient. ¶ The subject from which the drawings were taken, though very muscular, had no tibial slip. The use of this ligament is to connect the fibula and tibia to the os femoris, and to prevent rotatory motion of the joint.

These four ligaments, the patellar, the popliteal, with the internal and external lateral ligaments, are all that are situated exteriorly to the fibrous capsule of the joint.

In Fig. 2 of Plate XLIX. a circular incision has been made through the integuments and muscles of the thigh, immediately above or proximad to the synovial bursa, 1, and the fibrous capsule,** 4, laid open by an incision being made near its attachment round the condyles, M, N, of the os femoris, while the patella, 5, with the bursa, 1, and the fleshy insertions of the rectus, crureus, and two vasti muscles, are reflected, so as to bring into view the interior of the joint. In Plate L., Fig. 2, the patella, the mucous ligament, and synovial gland, are removed, and the lateral ligaments divided; while Fig. 3 is a popliteal view of this joint, the fibrous capsule, 4, being cut across. The fibrous capsule, 4, is attached round the condyles, M, N, of the os femoris, as represented in Fig. 2 of Plate XLIX., and Figs. 2 and 3 of Plate L.; from this extent of surface it descends, embracing the patella, 5, to the sides of which it is also attached, and the inter-articular cartilages, 13, 14, in Fig. 2 of Plate L., to be inserted

* Syn. Ligamentum posticum. Posterior ligament of Winslow.

† The popliteal ligament is concerned in luxation and other injuries and diseases of the knee-joint.

‡ Syn. Ligamentum laterale internum genu.

§ The internal lateral ligament is concerned in luxation and other injuries and diseases of the knee-joint.

‖ Syn. Ligamentum laterale externum genu longum et breve.

¶ The external lateral ligament is concerned in luxation and other injuries and diseases of the knee-joint.

** Syn. Membrana capsularis articuli genu. La membrane synovial.

round the head of the tibia, *a*, in Figs. 2 and 3 of the same Plate. By those who consider it a synovial membrane, it is described investing the crucial ligaments, the mucous ligament, the interarticular fibro-cartilages, and the condyles and trochlea of the os femoris. It invests the popliteus tendon and in many it dips into the joint formed by the head of the fibula and tibia. There are evidently two ligaments, a fibrous capsule and a synovial membrane; the latter investing the former but not the cartilaginous incrustations of the os femoris and tibia. The use of this ligament is to connect the tibia and os femoris, to support the patella, and to confine the synovial juice.*

A synovial glandular tissue is seen in Fig 2 of Plate XLIX., marked 7, situated on each side of the apex of the patella, and supported by its delicate ligament, 8, named mucous,† which descends from the notch between the condyles, M, N, of the os femoris. Besides this, there are several smaller glandular tissues situated within the fibrous capsule, as that marked 9 both in this figure and in Figs. 2 and 3 of Plate L.

In Fig. 2 of Plate XLIX., there is observed a delicate ligament, marked 10, on each side of the patella, 5, which is merely a thickening of the fibrous capsule, although it has obtained the name of alar.‡

In Fig. 2 of Plate L., the mucous, the capsular, and the lateral ligaments have been divided to bring into view the crucial ligaments,§ which are two in number, the one being placed anteriorly to the other. The anterior or patellar crucial ligament, 11, arises from the external or fibular depression in the side of the notch of the os femoris, and descends crossing the posterior crucial ligament, 12, on its anterior or patellar aspect, to be attached to the little elevation nearly in the centre of the head of the tibia, anteriorly or patellad to the posterior ligament.

The posterior or popliteal crucial ligament, 12, arises from the internal or tibial depression in the side of the notch of the os femoris, and descends crossing the anterior ligament, 11, on its posterior or popliteal aspect, to be attached to the popliteal aspect of the head of the tibia. This point of attachment is represented in Plate VIII., Fig. 8, letter g. In Fig. 3 of Plate L., the capsular ligament is cut across, so as to expose the popliteal aspect of these ligaments.‖ The crucial ligaments prevent any rotatory motion, and limit the extension of this joint.

The semilunar interarticular fibro-cartilages, 13, 14, in Fig. 2 of Plate L., situated between the condyles, M, N, of the os femoris, and the smooth depressions, *c*, *c*, on the head of the tibia, extend round these depressed surfaces, *c*, c, having their thin edges looking towards these, and their thick margins adhering to the capsular ligament, 4, so as to deepen these hollows in order to receive the condyles, M, N. Each of these cartilages, 13, 14, is fixed by a short ligamentous prolongation¶ from their anterior cornu to the head of the tibia, at the side of the insertion of the anterior crucial ligament, 11, of which they are supposed to be continuous. They are tied to each other, anterior to the insertion of the anterior crucial ligament, by a short transverse ligament,* 15; and their posterior cornua are attached to the tibia posteriorly or poplitead to the insertion of the posterior crucial ligament, 12, along which they send upwards a ligamentous production,* attaching them to the depression between the condyles of the os femoris. The digits 12, in Fig. 3, properly indicate this ligamentous production of these cartilages, enveloping the posterior crucial ligament. The cartilages are thus admirably kept in their place by these ligamentous bands, and move always along with the tibia in flexion and extension of the knee-joint.†

* The capsular ligament is concerned in luxation and other injuries and diseases of the knee-joint. The extension of the synovial membrane under the popliteus tendon should be considered in amputation, as recommended by Larrey.

† Syn. Ligamentum mucosum. Frenulum. Le ligament adipeux. Adipose ligament.

‡ Syn. Ligamentum alare majus et minus.

§ Syn. Ligamenta cruciata, anterius et posterius. Internal ligaments of knee-joint. Ligamentum cruciatum anticum et posticum. Les ligamens croisés.

‖ The crucial ligaments are concerned in luxation and other injuries and diseases of the knee-joint.

¶ Syn. Ligamenta cartilaginum lunatarum.

* Ligamenta cartilaginum lunatarum.

† When the patella is fractured across, there is always more or less læsion of the capsular ligament and tendinous aponeurosis of the fascia lata and muscles, and more or less retraction of the upper or proximal portion of the bone, in consequence of the insertion of the rectus, crureus, and two vasti muscles. This accident is easily recognised, and requires to be treated as follows. The limb is to be extended, with the trunk of the patient so elevated as to relax the rectus muscle. One bandage should be applied round the loins, and carried downwards to the fractured patella, while another should be rolled from the ankle upwards to the same point, so as to approximate the fractured ends, and keep them in that position. Leeches, fomentations, and poultices must then be kept in view. Like the fractured cervix ossis femoris, there results merely fibro-cartilaginous union. Passive motion may be used at the end of eight weeks. In compound fracture of the patella, as the joint is generally laid open, and there is a great extent of inflammatory surface, amputation becomes a matter of consideration for the surgeon. Should this not be considered requisite, topical blood-letting ought to be freely employed, followed by anodyne fomentations and poultices.

The insertion of the conjoint tendon of the rectus and crureus muscles is occasionally lacerated from the patella, and the patellar ligament is sometimes torn through. In both of these cases, the treatment should be the same as that recommended above for transverse fracture of the patella, modified according to circumstances.

The patella is generally luxated outwards or fibulad, seldom inwards or tibiad; but in either case the limb should be extended, and the trunk bent to an acute angle on the thigh, when a little pressure on the projected patella will reduce it. Leeches and fomentations should be used after reduction, since the fibrous capsule and the synovial membrane are more or less injured.

The tibia may be luxated either laterally, or forwards, or backwards, the one laterally being incomplete; but these are accidents which seldom occur. Either of these accidents is easily known, and only requires extension to reduce it, which is commonly accomplished with facility. Topical blood-letting, fomentations, and rest, are required, and afterwards proper support by bandage. In compound luxation of this joint, amputation requires almost invariably to be adopted.

The capsular and small ligaments supporting the interarticular cartilages become sometimes so relaxed as to permit these bodies to be displaced. From the configuration of the condyles of the os femoris, the internal or tibial being longer, while the external or fibular is shorter, the external or fibular interarticular fibro-cartilage is the one which usually slips out, and allows the condyle to rest on the surface of the tibia. In this derangement, the patient cannot perfectly extend the limb. To reduce the cartilage, the leg must be bent on the thigh as much as possible; then the cartilage replaced by the fingers, the leg extended, and a knee-cap laced tightly round the knee with a strong leather strap immediately over the cartilages. Occasionally, while the leg is bent on the thigh, it is requisite to rotate the thigh tibiad, and the foot fibulad, in order to replace the cartilage. This peculiar disease arises frequently from effusion into the joint, and then the treatment must be by blisters, rubefacients, compresses, and bandage.

The knee-joint, from its exposed and depending situation, is peculiarly liable to be wounded; and whether it be a punctured, incised, lacerated, or contused wound, the most active antiphlogistic treatment is requisite, in consequence of the great extent of the synovial surface, which is very susceptible of inflammation, and because, when once the inflammatory action commences, great difficulty exists in subduing it. The repeated application of leeches, warm anodyne fomentations and

The trochlear surface of the condyles of the os femoris, the surface of the head of the tibia, and the surface of the patella looking to the interior of the joint, are all covered with cartilage, but not with synovial membrane.

I shall now proceed to the description of the muscles of the leg, and shall begin with those situated on the posterior or popliteal aspect, because they follow in the arrangement of the plates, and because we have already had occasion to advert to them; however, I would recommend to the dissector to display those on the patellar aspect first. In the mode of investigating these, I shall pursue the same arrangement as I observed in describing the muscle of the thigh; see page 104.

The fascia lata, as I formerly remarked, extends downwards along the leg, forming a sheath to the muscles here, the same as for those of the thigh, and is here named the tibial fascia. In the proximal region it receives additions from the tendons of the biceps, semi-tendinosus, sartorius, triceps, and gracilis, and adheres to the head of the fibula. At the ankle-joint, it becomes continuous with the annular ligaments, and adheres to the malleoli. In its course along the leg, it is connected to the anterior and internal borders of the tibia, and the outer border of the fibula; and sends, besides intermuscular processes, a strong intermuscular septum between the gastrocnemial muscles and those more deeply seated behind the tibia.

When an incision is made through the integuments and the fascia, on the popliteal aspect, from the poples to the os calcis, the first muscle which presents itself is the gastrocnemius,* marked R, r, *r*, in Plates XXVII., XXVIII., and XXV., and in Fig. 1 of Plate L. This muscle consists of four heads, two of which, R, R, derive their origin from the thigh-bone, and two, r, r, from the tibia and fibula; the two former, R, R, are situated superficially or dermad to the two latter, r, r, and all of them unite to form the calf of the leg, and ultimately the tendo achillis, *r*.

The two outer heads, R, R, which are named the gastrocnemius externus,† derive their origin from the popliteal aspect of the condyles of the os femoris, between the hamstring muscles, and descend on the leg, uniting and swelling out into large fleshy bellies, which terminate near the proximal third of the leg, where they join the two inner heads, r, r, or gastrocnemius internus, to form the tendo achillis, *r*, which continues to descend, in order to be inserted into the posterior or popliteal projection of the os calcis, D.

The two inner heads, marked r, r, in Fig. 1, Plate L., and in Plates XXVIII., and XXVII., which are named the gastrocnemius internus,‡ derive their origin, the one from about the middle third of the tibia, the other from nearly the superior or proximal third of the fibula, and immediately unite and descend, being joined by the carneous fibres of the externus, R, R, at the proximal third of the leg, to form the tendo achillis, *r*; the fleshy fibres of the internus, however, continue to descend for upwards

---

poultices to the joint, the limb being gently bent to relax the ligaments, and perfect quietness, are the means to be employed, modifying them according to circumstances. In wounds, blood is occasionally effused into the joint; and if inflammation be averted, there is little danger to apprehend, the blood being readily absorbed. This is assisted by frictions and bandage.

The knee-joint is more susceptible than any other of being affected with floating loose cartilaginous bodies, which are sometimes suspended by delicate ligamentous bands. These substances must be originally attached to some part of the joint, otherwise they could not grow; but by motion or contusion their delicate pedicle is ruptured, and then they float about, and frequently run between the condyles of the os femoris and the concavities of the head of the tibia, so as to lame the individual. The laced knee-cap generally so confines them as to prevent their proving troublesome in walking, and should be persevered in before excision is had recourse to. When the latter is found necessary, the patient should be confined to bed for a day or so previously, and have a cathartic administered; the cartilaginous substance should then be pressed towards one side of the patella, and there held firmly by an assistant, while the operator drawing the skin downwards or upwards or to one side, makes a longitudinal incision over the substance, and extracts it either with the fingers, forceps, or a hook. The skin is instantly to be allowed to retract, the lips of the wound approximated with adhesive plaister and a bandage, the limb gently extended, and perfect rest with low diet enjoined. On the slightest appearance of inflammation, leeches, warm anodyne fomentations, and poultices should be adopted.

From the preceding observations it will be at once apparent that inflammation of the knee-joint is no uncommon occurrence, and that its treatment will be the same as already recommended in wounds of this joint. In inflammation of a joint, there is always an increased secretion of the synovial fluid, only of a more watery or serous nature, which tends to moderate the inflammatory action. This, when profuse, and after the inflammation has subsided, constitutes dropsy of the joint. Blisters, compresses, and bandage, are the best remedies. If the inflammation be severe, and do not terminate in effusion, or be not subdued, suppuration ensues. If in this termination the matter does not soon discharge itself by ulcerous openings, the surgeon ought to make a small valvular puncture with a bistoury, then apply two rollers to the limb, the one below, and the other from above, meeting at the puncture in the joint, otherwise the matter will excite, by its pressure, ulceration of the cartilages. Nourishing diet with perfect rest should be enjoined. Sometimes the cartilages and ligaments, and even the ends of the bones, as well as the capsular ligament, ulcerate, so as to leave no chance but anchylosis or amputation. In the scrofulous constitution, the least injury to this joint too often produces such an increased action and local determination to the part, that inflammation recurs successively, until such excitement is established that hectic fever ensues, and carries off the patient. At first there is merely slight inflammation, but afterwards thickening of the cartilages and ligaments, then ulceration and absorption, and lastly caries of the bones, with profuse suppuration of a purulent shining coagulated matter. There is a large quantity of viscid lymph diffused throughout the cellular tissue, which is soft and thick; and a peculiar alteration in structure of the tendinous and adipose substances round the articulation, which constitutes the chief part of the swelling, accompanies these from the beginning, and from the skin remaining generally pale, has been named white swelling. In some cases the integuments ulcerate and discharge the fluid from the joint. This disease seldom attacks the constitution after manhood, or the twenty-fifth year. In the beginning of this malady, the most active antiphlogistic treatment, such as that recommended in wounds of this joint, should be had recourse to, with long confinement in bed, the knee being kept gently extended on a common fracture splint. If this succeeds in subduing the inflammation, camphorated mercurial ointment, adhesive straps, and bandage should be applied; but if it does not, eschars should be made with potass or setons inserted, and perfect rest strictly enjoined, along with moderate diet; and anchylosis will then most probably occur. A short splint and bandage should be worn even after anchylosis is accomplished for a considerable length of time, to prevent any motion of the knee-joint.

The excision of the knee-joint was invented by Park, or Moreau, as an alternative for amputation in cases of white swelling, or caries of the ends of the bones entering into the formation of the joint; but has been so unsuccessful in the hands of others, that it is now abandoned. Amputation at this joint is only advocated by Velpeau. See Lizars' Practical Surgery, Part I., page 161.

* Syn. Gemelli, gastrocnemii internus et externus. Extensor tarsi suralis, vel extensor magnus. Gastrocnemii. Musculus suræ.

† Primus pedem moventium, cum secundo. Primus pedis extremi musculus, cum secundo. Primus movens pedem, cum secundo. Extendentium pedem primus, gastrocnemius externus, gemellus externus. Gastrocnemius. Gastrocnemius externus item gemellus. Gemellus. Grands jumeaux. Bifémoro-calcanien.

‡ Syn. Quartus pedem moventium. Quartus tibiæ musculus. Soleus. Extendentium pedem secundus, gastrocnemius internus. Le soléaire. Tibio-calcanien. Tibio-peronei-calcanien.

of two-thirds of the leg, to be inserted into the tendo achillis.*

The origins of the gastrocnemius externus are deeply seated in the poples, and are chiefly tendinous from the most superior or proximal points of the condyles of the os femoris. The bellies of the externus join the gastrocnemius internus by a strong thin tendinous expanse, as represented in Plate L., marked R, R. The commencements of the origins of the gastrocnemius internus are not so distinct, in consequence of their being joined together.†

The function of the gastrocnemius muscle is to inflect poplitead the leg upon the thigh or to bend the knee-joint, and to inflect the tarsus poplitead on the leg or to extend the tarsus or the ankle-joint.

The plantaris‡ U, u, in Fig. 1 of Plate L., and Plate XXVII., an elegant slender muscle, situated on the popliteal aspect of the leg, between the outer, R, R, and inner, r, r, heads of the gastrocnemius muscle, derives its origin from the popliteal aspect of the fibular or external condyle of the os femoris, and soon forms a delicate tendon, u, which descends obliquely between the outer, R, R, and the inner, r, r, bellies of the gastrocnemius, to the tibial margin of the tendo achillis, *r*, along which it runs, in order to be inserted together with the latter into the os calcis, D. The fleshy belly, U, is round and of short extent, while the tendon, u, is long and flat, and towards the tendo achillis, *r*, is generally so incorporated with the latter as to require considerable pains in the separation. When this tendon and the tendo achillis are divided across and reflected downwards or distad, a bursa mucosa is found between them and the os calcis. The function of the plantaris is to bend the knee-joint, and to extend the ankle-joint or the tarsus.§

The popliteus muscle,‖ V, in Plate XXVIII., and in Figs. 1, Plates L., LI., and LII., situated on the popliteal aspect of the knee-joint, and adhering to the popliteal ligament, 10, is a short flattish muscle, which, deriving its origin within the capsular ligament by a strong round tendon from the external or fibular condyle, *n*, of the os femoris, descends between the fibular lateral ligament and the outer semilunar cartilage, and becoming fleshy and increasing in breadth instantly on emerging from the joint, descends obliquely across, to be inserted into the tibia a little below its head. The muscle, when first exposed, has a strong fibrous expanse covering its lower or distal half, as delineated in Plate L. In Plate LII., the the muscle is represented emerging from the interior of the joint. The synovial investment of this muscle very often descends into the articulation formed by the head of the fibula and tibia. By some this is named the popliteal bursa. The popliteus is almost exclusively a flexor of the knee-joint; for it is only in the sitting posture, when both flexion and extension of this joint are suspended, that the popliteus slightly rotates the tibia.*

Before proceeding with the more deeply seated muscles on the popliteal aspect of the leg, we must examine some of those on the sole of the foot, as the latter obscure the tendinous insertions of the former. An incision should be made in the centre of the sole of the foot, from the os calcis to the middle toe, through the thick skin and granulated fat, to the glistening silvery tendinous expanse, named fascia plantaris,† which is delineated in Plate XXVII., marked with the letters Y. The condensed granulated fat and skin are to be reflected towards each side of the foot, until the whole fascia is displayed, when it will be found to arise thick and strong from the os calcis, D, and to proceed adhering to the flexor brevis digitorum, the abductor pollicis, and the abductor minimi digiti muscles, onwards to the toes; where becoming thinner and more open in its fibres, it sends some to be inserted on each side of the flexor tendons in the heads of the metatarsal bones, and others to be attached to the sheaths of these flexors.

The plantar fascia is divided into three portions, a middle, a tibial, and a fibular. The middle is the largest and strongest, has somewhat a triangular form, and is attached by its narrow proximal extremity to the plantar aspect of the os calcis, from which the fibres diverging, proceed to the toes and divide into five portions, one for each toe; each of these subdivide into two slips, which adhere to the vaginal ligaments. Through the former of these divisions run the nerves, blood-vessels, and the lumbricales muscles; and through the latter, or subdivisions, the tendons of the flexors. The margins of this portion are connected with the lateral parts of the aponeurosis, and send intermuscular septa between the muscles which are attached to the plantar ligaments of the tarsus. The tibial or inner portion invests the muscles of the great toe, and is much thinner. The fibular or outer portion invests the muscles of the little toe, and is intermediate in thickness to the other two.

The use of this fascia is to support the arch of the foot, to give elasticity to the foot in walking, and to protect the muscles, nerves, and blood-vessels, situated in the sole of the foot.‡

The plantar fascia is removed, by carefully detaching its insertion in the heads of the metatarsal bones, beginning either at the tibial or fibular margin, (the former, however, is less difficult), and reflecting it towards the os calcis, until it be found incorporated with the muscles, namely the abductor pollicis, B, the flexor brevis digito-

* The extent of the fleshy fibres downwards or distad should be considered by the operator in amputating the leg.

† The gastrocnemius muscle is concerned in amputation of the leg; in the securing of the posterior tibial artery, as described in page 67; in the securing of the fibular artery, as detailed in page 68; in luxation of the knee and ankle-joints, and in rupture of its tendon or the tendo achillis. This latter accident is very liable to occur, and is easily recognised. The knee-joint should be bent, and the ankle-joint extended, in order to approximate the attachments and relax the muscle; and the individual should remain quiet for upwards of three months, wearing a strap extending between the heel of the shoe and a leather collar put round the thigh, immediately above the knee.

‡ Syn. Tertius pedem moventium. Tertius tibiæ musculus. Extensor tarsi minor, vulgo plantaris. Le plantaire ou jambier grêle. Plantaire. Petit fémoro-calcanien.

§ This muscle is concerned nearly in the same operations and accidents as the gastrocnemius, only in a very trifling degree.

‖ Syn. Musculus in poplite occultatus. Decimus tibiæ musculus. Oblique movens tibiam, suppopliteus. Le poplitè ou jarretier. Fémoro-popliti-tibial.

* The popliteus muscle is concerned in luxation and other injuries, and diseases of the knee-joint. Its synovial investment is a veto to excision of the head of the fibula, as recommended by Larrey.

† Syn. Aponeurosis plantaris. L'aponévrose plantaire.

‡ The fascia plantaris is concerned in wounds of the sole of the foot, in wounds of the plantar arteries, and in abscesses in the sole of the foot centrad to the fascia. In the first of these accidents, leeches to the patellar aspect of the foot, followed by hot anodyne fomentations and poultices, applied round the foot, are required; for the second, the reader is referred to page 67; and for the third or abscess, a division of the fascia should be made, when if either of the plantar arteries are wounded, compression with lint will stem the hemorrhage.

rum, C, and the abductor minimi digiti, F, as represented in Plate L.

The flexor brevis digitorum pedis seu sublimis perforatus,* C, in Plate XXVIII., and C, *c*, in Fig. 1, Plate LI., is the central of the three little muscles exposed on detaching the fascia plantaris, and derives a fleshy origin from the os calcis, D, and the fascia plantaris, Y; the fleshy belly proceeding onwards to the extent of the middle of the sole of the foot, where it ends in four small tendons which advance to the basis of the first phalanx, each splitting into two slender slips, to give passage to the tendons, *o*, of the flexor longus digitorum perforans. These double tendons of the brevis are ultimately inserted in the second or medial phalanges of the four lesser toes, as represented in Fig. 1 of Plate LI.; and are along with the tendons of the flexor longus bound down by their vaginal ligaments, as delineated in Plate XXVII. These tendinous slips are remarkably delicate, particularly those proceeding to the little toe, which are frequently deficient, and which occasionally derive their origin from the tendons of the flexor longus, and even the musculus accessorius. The precise origin is distinctly seen in Fig. 1 of Plate LI., marked also C. The function of this muscle is to bend plantad the first or proximal phalanx of the four lesser toes on the metatarsal bones, and to bend the second or medial phalanx on the first or proximal of these toes. †

The vaginal ligaments ‡ of these tendons, seen in Plate XXVII., and Plates LI. and LII., Figs. 1, marked with the digits 4, are attached to the ridges on each side of the plantar aspect of the phalanges of the toes, thus forming sheaths or canals for the tendons of the flexor longus and brevis, and confining the synovial juice secreted by the synovial membrane which invests them; they are somewhat thicker and stronger opposite the joints, and are named cruciata, from having a crucial appearance. Within these vaginal ligaments, small ligamentous slips extend between the phalanges and the tendons both of the flexor longus and brevis, are named accessory ligaments § of the flexor tendons, and are designed to confine or limit the motions of these tendons.

The abductor pollicis pedis,‖ B, in Plate XXVIII., obscures also the muscles descending from the popliteal aspect of the leg to the foot, and consequently requires to be previously examined. This muscle is situated on the tibial aspect of the sole of the foot, deriving its origin from the tibial margin of the os calcis, D, and running along the same margin of the foot, where it derives additional origin from the os naviculare, and is inserted in the root of the first or proximal phalanx of the great toe. This muscle is partly tendinous and partly fleshy throughout, and consists rather of a scattered arrangement of fibres. It is incorporated at its origin with the flexor brevis digitorum, and the plantar fascia, and in its course adheres to the internal plantar ligament which extends between the os calcis and os naviculare supporting the astragalus to the os naviculare itself, to the os cuneiforme internum, and the metatarsal bone of the great toe. On the fibular margin near its insertion, this muscle is inseparably connected with the flexor brevis pollicis, X, the insertion being, properly speaking, into the tibial sesamoid bone. The points of origin and insertion are clearly seen in Fig. 1 of Plate LI., the former marked B, and the latter, b. The abductor pollicis not only abducts the great toe tibiad, but also bends the first or proximal phalanx popliteal or plantad.*

The deeply seated muscles on the popliteal aspect of the leg may now be investigated.

The flexor longus digitorum pedis, seu profundus perforans, † may be seen from its origin to its insertion, delineated in Fig. 1, Plate LI., and marked with the letters O, o, *o*. This muscle, situated on the popliteal aspect of the leg and plantar of the foot, derives its origin from the popliteal aspect of the tibia and interosseous ligament, H, and descends with a penniform appearance to the ankle-joint, where becoming tendinous, as at o, it advances along the sole of the foot, and forms a junction with the tendon, *a*, of the flexor longus pollicis, and the musculus accessorius, G; it then divides into four tendons, *o, o, o, o*, which run in the vaginal ligaments, and pierce the tendons, *c, c, c, c*, of the flexor brevis digitorum, to be inserted by a broad expanse in the last or distal phalanx of the four lesser toes. ‡ Small ligamentous slips, formerly described, and named accessory, extend between the phalanges and these tendons. The flexor longus digitorum is also seen in Fig. 1 of Plate L., and in Plates XXVII. and XXVIII. The tendinous slip which unites the tendons of the flexor longus digitorum pedis and the flexor longus pollicis pedis, is generally very strong. As the tendon runs round the malleolus internus, *s*, it is bound down by a strong vaginal ligament, as represented in Plate L., marked ɑ. The flexor longus digitorum extends the ankle-joint, or inflects poplitead the tarsus, bends plantad or poplitead the distal phalanges on the medial, the medial on the proximal, and the proximal on the metatarsal bones, and adducts tibiad the toes or foot, or inflects tibiad the tarsus.

The vaginal ligament, § ɑ, of the tendon of this muscle, delineated in Fig. 1 of Plate L., extends between the malleolus internus, *s*, and the os calcis, D, and binds down the tendons of the flexor longus digitorum, the tibialis posticus, and the flexor longus pollicis; although the two latter have also vaginal ligaments peculiar to themselves.

---

* Syn. Primus pedis digitos moventium. Primus musculos pedis digitis inserviens. Brevis digitum flexor, sive pedieus internus, vel pternodactyleus. Flexor secundi internodii digitorum perforatus. Perforatus. Perforatus, seu flexor sublimus. Le court fléchisseur commun des orteils, ou le perforé du pied. Petit fléchisseur des orteils Calcanéo-sous-phalanginien commun.

† The flexor brevis digitorum is concerned in luxation and amputation of any of the four lesser toes; and also in amputation across the foot.

‡ Syn. Ligamenta vaginalia tendinum flexorum. Ligamenta vaginalia et cruciata. The fibrous sheaths of the toes.

§ Syn. Vincula tendinum sublimis et profundi accessoria, brevia et longa.

‖ Syn. Decimus-octavus pedis digitos moventium. Secundus pedis musculus digitis inserviens, pollicem ab aliis digitis deducens. Parvus musculus ad latus pollicis. Pollicem adducens. Abductor pollicis. Portion de l'antithénar. Abductor hallucis. Adducteur du pouce. Abducteur oblique du gros orteil. Metatarso-sous-phalangien du pouce. Tarso-métatarsi-phalangien du pouce.

* The abductor pollicis is concerned in luxation and amputation of the great toe, and in amputation across the foot.

† Syn. Secundus pedis digitos moventium. Sextus tibiæ musculus. Longus digitûm flexor, sive perodactyleus. Digitorum tertii internodii flexor perforans. Perforans. Perforans seu flexor profundus. Long fléchisseur commun des orteils, ou perforant du pied. Grand fléchisseur des orteils. Tibio-phalangettien commun.

‡ The flexor longus digitorum is concerned in luxation of either of the four lesser toes, and the ankle-joint; in amputating either of these toes, in amputation across the foot, and in that of the leg.

§ Syn. Ligamentum laciniatum. Posterior annular ligament.

It likewise confines the synovia that lubricates the tendon of the flexor longus digitorum.*

The musculus accessorius ad flexorum longum digitorum pedis,† marked G, in Fig. 1, Plate LI., situated in the plantar aspect of the foot, is an oblong carneous mass, deriving its origin from the sinuosity of the os calcis, D, and extends a short course along the sole of the foot, to be attached to the tendon, O, of the flexor longus, at its division into its four tendons.‡ This muscular mass assists the fleshy belly of the flexor longus digitorum in bending the four lesser toes; and from the tendinous union between the latter muscle, and the flexor longus pollicis, it will also assist this muscle in bending the great toe.

Connected also with the tendons, *o*, of the flexor longus digitorum, are four small muscles, named lumbricales pedis, § delineated in Fig. 1 of Plate LI., marked k. They arise from the tibial edge of the tendons of the flexor longus digitorum, just at their commencement, and advance to the same aspect of the four lesser toes, where they become tendinous, and are inserted in the tendinous expanse of the extensor longus digitorum, on the patellar aspect of the toes.‖ These muscles assist the tendons of the flexor longus and brevis in bending the first or proximal phalanx of the four lesser toes, and also occasionally assist the extensor longus and brevis of these toes in extending the second or medial phalanx, as well as the third or distal phalanx.

The flexor longus pollicis pedis,¶ A, *a*, in Fig. 1, Plate LI., situated on the popliteal aspect of the leg, fibulad to the flexor longus digitorum, O, derives its origin tendinous and fleshy from the two distal thirds of the fibula, 1, and the interosseous ligament, H, and becomes tendinous, *a*, at the ankle-joint, running in a groove of the os calcis, bound down by a vaginal ligament, a, and crossing the tendon, O, of the flexor longus digitorum, to which it is attached by a strong tendinous slip; the tendon then advances onwards, to be inserted in the last or distal phalanx of the great toe,** running in another vaginal ligament, as represented in Plate XXVII., and in Plate LII., Fig. 1, marked 4; which sheath resembles those of the lesser toes, marked also 4. The function of this muscle is to bend the ankle-joint or extend the tarsus, to bend poplitead or plantad the two phalanges of the great toe, to adduct or inflect the tarsus tibiad, and by its tendinous union with the flexor longus digitorum, to bend the four lesser toes.

The vaginal ligament,* a, in Fig. 1 of Plate LI., is attached to the sinuosity of the os calcis and to the astragalus, and binds down the tendon of the flexor longus pollicis, confining at the same time the synovia which lubricates the tendon. This is considered, by some, a portion of the posterior annular ligament.

When the flexor longus digitorum and the flexor longus pollicis are removed,† the tibialis posticus muscle, a, in Fig. 1 of Plate LII., presents itself, situated on the popliteal aspect of the tibia, *o*, from which, and the interosseous ligament, H, this muscle arises, and descends adhering to the bone, becoming tendinous near the malleolus internus, *s*, in a groove of which the tendon runs onwards to be inserted in the os naviculare, *b*. This muscle fills up the vacuity at the proximal part of the interosseous ligament, and has therefore been described by some anatomists as deriving part of its origin from the patellar aspect of this ligament and the tibia and fibula. As the tendon glides round in the groove of the malleolus internus, *s*, it is bound down by a strong vaginal ligament, as represented in Fig. 1 of Plate L, marked a, and likewise by a ligament peculiar to itself, so as to confine the synovia which lubricates the tendon. This fibrous sheath is considered by some to be a portion of the posterior annular ligament. The tendon of this muscle is also seen in Fig. 1 of Plate LI., and in Plates XXVII. and XXVIII. The insertion generally expands over the os cuneiforme internum, *d*, and medium, and also over the contiguous ligaments. The function of this muscle is to extend the ankle-joint or the tarsus poplitead, and to adduct or inflect the tarsus tibiad ‡.

The next muscle that presents itself in the order of dissection is the transversalis pedis,§ L, in Fig. 1 of Plate LII., situated, as the name indicates, across the sole of the foot, between the heads of the metatarsal bones of the great and little toe. The tendons of the flexor longus and brevis require to be divided and reflected over the toes, to bring the transversalis into view. This small muscle derives its origin from the tibial aspect of the head, or distal extremity of the metatarsal bone of the little toe, and runs obliquely across the heads of the other metatarsal bones, to be inserted in the fibular aspect of the head of the metatarsal bone of the great toe, and also in the sesamoid bone, on the same aspect.‖ The function of this muscle is to abduct or to inflect fibulad the great toe, and also to approximate the little toe towards the great toe.

Having already examined two of the muscles peculiar

---

* This ligament is concerned in sprains of these muscles, and in luxation of the ankle-joint: for the treatment of the former, see page 122.

† Syn. Pars secundi pedis digitos moventium. Pars sexti tibiæ musculi. Pars longi digitûm flexoris, sive perodactylei. Pars digitorum tertii internodii flexoris, perforantis. Massa carnea Jacobi Sylvii. Pars perforantis. Pars perforantis seu flexoris profundi. Accessoire du perforant. L'accessoire du long fléchisseur commun des orteils. Accessoire du grand fléchisseur. Flexor accessorius.

‡ The flexor accessorius is concerned in forming part of the flap in amputation across the foot between the os astragalus and os calcis, and the os naviculare and os cuboides, as afterwards described.

§ Syn. 19, 20, 21, 22, pedis digitos moventium. Quatuor musculi pedis digitis inservientes. Extremi quatuor musculi, quos inter motores digitorum pedis descripsit Vesalius. Lumbricales. Flexores quatuor primi internodii, lumbricales. Lumbricaux des orteils. Les lombricaux. Les quatre planti-sous-phalangiens. Planti-tendino-phalangiens.

‖ The lumbricales having little power, and being extremely small, have almost no relation to surgery. They may be said to be concerned in luxation and amputation of the different joints of the four smaller toes.

¶ Tertius pedis digitos moventium. Septimus tibiæ musculus. Pollicis flexor. Flexor pollicis longus. Flexor longus. Le long fléchisseur du pouce. Le long fléchisseur du gros orteil. Flexor longus hallucis. Grand fléchisseur du gros orteil. Péroneo-sous-phalangettien du pouce. Péroneo-phalanginien du gros orteil.

** The flexor longus pollicis relates to the securing of the fibular artery, as described in page 68; is concerned in luxation of the great toe and ankle-joint, and in amputation both of this toe and the leg.

* Syn. Vagina ligamentosa flexoris proprii pollicis.

† Syn. Quintus pedem moventium. Quintus tibiæ musculus. Quintus movens pedem. Tibieus posticus. Oblique moventium pedem primus, adducens pedem, nauticus, tibiæus posticus. Le jambier postérieur. Tibio-sous-tarsien. Tibio-tarsien.

‡ The tibialis posticus muscle is concerned in luxation of the ankle-joint, and in amputation across the foot, and of the leg.

§ Syn. Decimus tertius digitorum pedis. Musculus transversus. Transversalis. Transversus pedis. Le transversal des orteils. Abducteur transverse du gros orteil. Métatarso-sous-phalanginien transversal du pouce. Métatarso-phalangien du pouce.

‖ The transversalis pedis has little or no relation to surgery.

to the great toe, situated on the sole of the foot, I shall next describe the flexor brevis pollicis pedis,* X, seen in Fig. 1, Plate LI., and in Plate XXVIII. This muscle, situated in the sole of the foot, between the abductor pollicis, B, and adductor pollicis pedis, *q*, in Fig. 1 of Plate LII., being strongly incorporated with these muscles, derives its origin from the sinuosity of the os calcis near its junction with the os cuboides, and from the os cuneiforme externum, or rather from the ligaments connecting these bones, and therefore frequently derives some of its origin from the tendon of the tibialis posticus; the fleshy fibres advance between the abductor and adductor, and are inserted in the sesamoid bones, situated between the head of the metatarsal bone and the first phalanx.† The function of this muscle is to inflect plantad the proximal phalanx on the metatarsal bone of the great toe, or to bend the first joint of the great toe.

The third muscle peculiar to the great toe in the sole of the foot, is the adductor pollicis pedis,‡ seen in Plate LII., marked *q*, which is situated on the fibular margin of the flexor brevis pollicis, with which it is intimately connected. It derives its origin from the os calcis, the os cuboides, the external or fibular cuneiform bone, and sometimes from the metatarsal bones of the ring toe, the middle toe, and even the index toe; the fibres advance obliquely between the metatarsal bones of the index and great toes, to be inserted in the fibular of the two sesamoid bones situated between the head of the metatarsal bone and the proximal phalanx of the great toe. These small muscles in the sole of the foot are so incorporated together, that they are very perplexing to the dissector. This adductor, properly speaking, arises from the ligaments extending between these tarsal and metatarsal bones.§ The adductor pollicis inflects the great toe fibulad and poplitead.

The abductor digiti minimi pedis,‖ marked F, in Fig. 1 of Plate LI., situated in the sole of the foot, on the same level with the flexor brevis digitorum, and more or less attached to the fibular aspect of this latter muscle, arises from the fibular aspect of the os calcis, and from the plantar fascia, and proceeds along the os cuboides and metatarsal bone of the little toe, from the latter of which it derives additional fibres, to be inserted in the root or proximal extremity of the first or proximal phalanx of the little toe. This abductor, which is intimately connected with the flexor brevis minimi digiti pedis, N, inflects the little toe fibulad, or abducts it, and also inflects it plantad.*

The flexor brevis digiti minimi pedis,† N, in Fig. 1, of Plate LI., situated in the sole of the foot, on the tibial margin of the abductor digiti minimi pedis, with which it is intimately connected, derives its origin from the os cuboides, the vaginal ligament of the peroneus longus, and the metatarsal bone of the little toe, along which it advances to be inserted in the root or proximal extremity of the first or proximal phalanges of the little toe.‡ This muscle inflects the proximal phalanx of the little toe plantad.

I shall defer the examination of the plantar interossei until I have described the muscles on the fibular and patellar aspects of the leg and foot, in order that we may investigate the patellar interossei in immediate succession. On the fibular aspect of the leg are situated the two peronei muscles, the longer being superficial to the shorter. They are delineated in Figs. 1 of Plates L., LI., LII., and LIII., and in Plate XXVI.; the former or longer being marked F, the latter or shorter I.

The peroneus muscle§, F, in Plate XXVI., and in Figs. 1 of Plates L., LIII., and LIV., situated on the fibular aspect of the leg, and the plantar of the foot, derives its origin from a small part of the external tubercle of the tibia, the upper or proximal third of the fibula, and the fascia of the leg, and descends on the latter bone, soon forming a long tendon, which runs on the popliteal aspect round the malleolus externus, being bound down by the vaginal ligament, K; the tendon then runs in a groove of the os cuboides, obliquely across the sole of the foot, to be inserted in the internal cuneiforme bone, *d*, and the metatarsal bone, 20, of the great toe. On first inspection, this muscle is found covered by the fascia of the leg, from which it derives part of its origin, and so completely surrounds the peroneus brevis, I, as to obscure the latter muscle. The tendon running round the malleolus externus, forms a groove in the fibula; and where the tendon runs in the sole of the foot, in the groove of the os cuboides, it is osseous in the adult; and onwards from this to the insertion, the tendon is bound down by the plantar ligaments. The function of this

---

* Syn. *Unus ex* musculis primos articulos flectentibus qui tertium musculum *pedis* in numero succedunt. *Unus ex* musculis digitis pedis binos inservientibus. *Unus ex* parvis musculis, quorum quatuor collocantur in planta. An adducem pollicem, ossi pedii maximo intus attensus? Musculus flexioni pollicis consecratus. Interosseous. Flexor pollicis brevis. Flexor brevis. Pars ejus qui le thenar, quoque una cum parte ejus qui l'antithenar. Le court fléchisseur du gros orteil. Flexor brevis hallucis. Petit fléchisseur du gros orteil. Tarso-sous-phalangien du pouce. Tarso phalangien du pouce.

† The flexor brevis pollicis pedis is concerned in amputation of the proximal phalanx and metatarsal bone of the great toe.

‡ Syn. Decimus-octavus pedis digitos moventium. Decem musculos singulis digitis pedis binos inservientes. Parvus musculus ad latus pollicis. Pollicem abducens. An huc pertinent musculi in pedio ab ipsius ossibus orti. Alius musculus transversus. Interosseus. Interosseus ad indicem pertingens. Adductor pollicis. Portion interne du muscle thenar. Adducteur du pouce. Calcaneo-sous-phalangien du pouce. Calcaneo-phalangien du pouce.

§ The adductor pollicis pedis is concerned in luxation of the proximal phalanx of the great toe, and in amputation of this member, as well as amputation across the foot.

‖ Syn. Decimus septimus pedis digitos moventium. Tertius musculus digitis pedis inserviens. Parvus musculus ad latus minimi. Musculus minimo digito abducendo dicatus. Abductor minimi digiti. Minimum abducens. Le metatarsien et le grand parathénar. L'abducteur du petit orteil. Calcaneo-sous-phalangien du petit orteil. Calcaneo-phalangien du petit doigt.

* The abductor digiti minimi pedis is concerned in luxation of the proximal phalanx of the little toe, in amputation of this toe, or of its metatarsal bone, and also across the foot.

† Syn. *Unus ex* musculis primos articulos flectentibus, qui tertium musculum *pedis* in numero succedunt. Decem musculos singulis digitis pedis binos inservientes. Parvos musculos, quorum quatuor collocantur in planta. Musculus minimum digitum extrorsum inflectens. Interosseus. Flexor primi ossis minimi digiti. Flexor primi internodii minimi digiti. Flexor primi internodii minimi digiti proprius. Petit parthénar. Le court fléchisseur du petit orteil. Tarso-sous-phalangien du petit orteil. Métatarso-phalangien du petit doigt.

‡ The flexor brevis digiti minimi pedis is concerned in luxation of the proximal phalanx of the little toe, in amputation of this phalanx, and the metatarsal bone of the same toe.

§ Syn. Septimus pedem moventium. Quartus anterioris pedis musculus. Peroneus posticus. Oblique moventium pedem, secundus abducens, peronæus primus, fibulæus. Peronæus primus. Peroneus primus, seu posticus. Le long peronier communément dit péronier postérieur. Le long péronier latéral. Grand péronier. Péronéo-sous-tarsien. Tibi-péronéo-tarsien.

muscle is to extend the ankle-joint or to inflect poplitead the tarsus, and to abduct the foot fibulad. *

The peroneus brevis muscle, † I, in Figs. 1 of Plates L., LI., LII., LIII., and LIV., situated on the fibular aspect of the leg, and concealed for some extent by the peroneus longus, F, derives its origin from nearly the whole extent of the fibula, 1, forming a strong short tendon, i, which runs round the malleolus externus, S, to be inserted in the root or proximal extremity, *t*, of the metatarsal bone, 5, of the little toe. The tendon of this muscle contributes to form the groove on the popliteal aspect of the malleolus externus, at which place it is bound down by the vaginal ligament, K. This tendon is also bound down by another vaginal ligament, immediately before its insertion in the metatarsal bone of the little toe. This muscle extends the ankle-joint, or inflects poplitead the tarsus, and abducts the foot fibulad. ‡

The vaginal ligament, K, of these two peronei muscles, § seen in Figs. 1 of Plates L. and LIII., extends between the malleolus externus and the os calcis; in Plate L. it is large and untouched, while in Plate LIII. the ligament is much reduced in breadth and thickness. From this ligament, ligamentous productions descend to the os calcis, between the tendons of the peronei muscles, so as to separate them. The use of this ligament is described under the peroneus longus and brevis. ||

On the patellar aspect of the leg and foot, the muscles are few and simple, and form the antagonists of those on the popliteal and fibular aspects. When the integuments are removed from the patellar aspect of the leg, the muscles present a uniform surface, being covered and held together by the fascia of the leg, which is a continuation of the fascia lata femoris. We have therefore to remove the dorsal fascia and dissect them onwards to their tendons on the foot, before we are able to distinguish them.

The dorsal fascia is a thin aponeurosis spread over the tendons on the patellar aspect of the foot, extending between the distal border of the anterior or patellar annular ligament onwards to the toes, on which it is lost. On each side it is continuous with the plantar fascia, and is connected with the head of the metatarsal bone of the little toe.

The muscles which then appear are the tibialis anticus, A, the extensor proprius pollicis pedis, C, and the extensor longus digitorum pedis, B, as represented in Plate XXVI.; the extensor longus digitorum and the tibialis anticus being united at their surface or dermal aspect by the fascia, so as to conceal the extensor pollicis.

The extensor longus digitorum pedis, * B, in Plate XXVI., situated on the patellar aspect of the leg and foot, derives its origin from the two upper or proximal thirds of the fibula, and forms a flat tendon, which, running under the anterior annular ligament, D, splits into four or five tendons, which proceed onwards to be inserted in the phalanges of the four lesser toes. I have already mentioned, that the muscle is intimately connected with the tibialis anticus, A, more or less with the extensor proprius pollicis, C, and also with the peroneus longus, F. The dissector should therefore trace the muscle from the conjoined tendon, immediately proximad to the annular ligament, D, upwards, cutting through the fascia of the leg which binds it to the tibialis anticus, but leaving the fascia that connects this muscle with the peroneus longus sound, as the two latter cannot be separated without injury. When the tendon divides into five portions, the fifth is inserted in the metatarsal bone of the little toe, and is named peroneus tertius †; but as this tendinous slip is sometimes deficient, and as it cannot be separated from the general tendon and muscle without injury, I have followed Cowper, and some other anatomists, in considering it a portion of the flexor longus digitorum. Where the four tendinous slips arrive at the proximal phalanges of the four lesser toes, they expand, forming a tendinous layer, which covers all the three phalanges. The function of this muscle is to bend the ankle-joint or to inflect patellad or rotulad the tarsus, and to extend the three phalanges of the four lesser toes, as well as abduct the foot and toes fibulad. ‡

The extensor brevis digitorum pedis, § E, in Plate XXVI., situated on the upper or patellar aspect of the

---

* The peroneus longus is concerned in fracture of the tibia and fibula, either singly or conjointly; and such is the power of abduction of this muscle, that it is scarcely practicable to prevent a certain degree of this attitude following a reunion of these bones. It is still more difficult to prevent this position of the foot in luxation of the ankle-joint laterally with fracture of one or both of these bones, a species of accident that frequently occurs. When either of these happens, hot anodyne fomentations and poultices should be used, until inflammation has been subdued; the luxation in the one case, and the fractured ends of the bones in the other, being previously reduced and retained by M'Intyre or Liston's splint, and afterwards by Dupuytren's simple apparatus.

The peroneus longus, besides luxation laterally, is concerned in all the other kinds of luxation of the ankle-joint, and in amputation of the foot and leg.

† Syn. Octavus pedem moventium. Quintus anterioris pedis musculus. Peroneus anticus. Flectentium pedem secundus, peronæus secundus semifibulæus. Peroneus secundus. Peronæus secundus, seu anticus. Le moyen ou petit péronier communément dit péronier antérieur. Moyen péronier. Grand péronés-sus-métatarsien.

‡ The peroneus brevis has the same relation to surgery that the peroneus longus has.

§ Syn. Ligamentum tendinum peroneorum. Retinaculum tendinum peroneorum.

|| This ligament is occasionally lacerated in sprains, and also in luxation of the ankle-joint. When the former occurs, hot anodyne fomentations and poultices should be applied, until the inflammatory action is subdued, and the limb bandaged with a roller, carried from the toes upwards above the ankle-joint, with rest for five or six weeks, when passive motion should be employed. If much swelling is present, frictions, with stimulating medicines, may be employed along with the bandage.

* Syn. Decimus quartus pedis digitos moventium. Secundus musculus anterioris pedis. Longus digitûm tensor, sive cnimodactyleus. Digitorum tertium internodium extendens. Extensor longus. Le long extenseur commun des orteils. Grand extenseur. Péronéo-sus-phalangettien commun. Péronéo-tibi-sus-phalangettien commun.

† Syn. Nonus pedem moventium. Musculus pedis qui tertius decimus annumeratur. Pars extensoris digitorum pedis longi. Quintus tendo-extensoris longi digitorum pedis. Petit péronier. Court péronier. Petit péronéo-sus-métatarsien.

‡ The extensor longus digitorum pedis is concerned in luxation of the ankle-joint, and in that of the four lesser toes; in fracture of the fibula and tibia; in amputation of the four lesser toes, and extirpation of either of the metatarsal bones of these toes; and in amputation across the foot and in that of the leg. This muscle, from its power of abducting the foot, assists the peroneus longus in distorting the limb, after luxation of the ankle-joint accompanied with fracture of the tibia and fibula, either singly or conjointly, and also in simple fracture of these bones. This muscle also relates to the securing of the anterior tibial artery, as described in page 67.

§ Syn. Decimus sextus pedis digitos moventium. Postremus musculus pedis. Brevis digitûm tensor, sive pedieus. Extendens digitorum secundum articulum. Extensor pollicis brevis, una cum extensore digitorum brevi. Extensor brevis una cum extensore brevi. Extensor digitorum brevis. Le court extenseur commun des orteils. Extensor brevis digitorum pedis, *una cum* extensore proprio hallucis. Le pedieux. Petit extenseur des orteils. Calcaneo-sus-phalangettien commun.

foot, derives its origin from the same aspect of the os calcis, runs along the other tarsal bones, dividing into four fleshy slips, which soon become tendinous, and are inserted in the tendinous expansions of the extensor longus digitorum, B, excepting the one to the little toe. The fourth and larger portion of the muscle is therefore inserted in the tendinous expanse of the extensor proprius pollicis, C. The use of this muscle is to assist the extensor longus in extending the phalanges of the three toes next the great toe, and also to assist the extensor proprius pollicis in extending the two phalanges of the great toe.*

The tendons of the extensor longus and brevis have delicate ligamentous threads † running transversely over them, where they extend along the first or proximal joints of the toes.

The extensor proprius pollicis pedis, ‡ C, in Plate XXVI., situated on the patellar aspect of the leg and foot, and concealed in the leg by the extensor longus digitorum pedis, B, and the tibialis anticus, A, derives its origin from the medial third of the fibula and interosseous ligament, and descends between the above mentioned muscles to the annular ligament, D, where it becomes tendinous, and beneath or centrad to the ligament, advancing along the tarsus and the metatarsal bone of the great toe, to be inserted by a tendinous expansion in the two phalanges of the great toe. The function of this muscle is to extend the two phalanges of the great toe, and to bend the ankle-joint or to inflect patellad the tarsus. §

The fascia of the leg binds down the tendon of the extensor proprius pollicis, and adheres to the tarsal and metatarsal bones, so as to form an individual sheath ‖ to the tendon. This is in many places stronger than in others.

The tibialis anticus muscle, ¶ A, in Plate XXVI., situated on the patellar aspect of the leg and foot, derives its origin from the two proximal thirds of the tibia, from the fascia of the leg, and from the interosseous ligament, and descends forming a strong tendon, which runs under or centrad to the annular ligament, D, onwards to the os cuneiforme internum of the tarsus, and metatarsal bone of the great toe. This muscle, as previously described, adheres intimately to the extensor longus digitorum, by means of the fascia of the leg. Its function is to bend the ankle-joint, or to inflect patellad the tarsus. **

* The extensor brevis digitorum pedis is concerned in luxation of the joints of the great toe, and the three contiguous toes; also in amputation of these, of the metatarsal bones, and across the foot.

† Syn. Retinacula lata extensorum.

‡ Syn. Decimus quintus pedis digitos moventium. Tertius musculus anterioris pedis. Extensor pollicis. Pollicis tensor. Extensor pollicis longus. Extensor longus. Grand extenseur du pouce du pied. Extensor proprius hallucis. Péronéo-sus-phalangettien du pouce. Péronéo-sus-phalanginien du pouce.

§ The extensor proprius pollicis pedis relates to the securing of the anterior tibial artery, as detailed in page 67; is concerned in luxation of the ankle-joint, and of the two phalanges of the great toe; and also in amputation of the two latter, across the foot, and of the leg.

‖ Syn. Ligamentum proprium tendinis extensoris proprii longi pollicis.

¶ Syn. Sextus pedem moventium. Primus musculus anterioris pedis. Tibieus anticus. Flectentium pedem primus, tibiæus anticus, catenæ musculus. Le jambier antérieur. Tibio-sus-tarsien. Tibio-sus-métatarsien.

** The tibialis anticus muscle relates to the securing of the anterior tibial artery, as described in page 67; is concerned in luxation of the ankle-joint; and in amputation across the foot, and of the leg.

The anterior annular ligament of the tarsus, D,* is merely that part of the fascia of the leg rendered thicker, where it crosses the articulation by frequent motion, and hence must not be expected to be found so distinct in dissection, being connected both above and below, or proximad and distad, with the general fascia of the leg. † This ligament extends between the malleolus internus, *s*, and the os calcis, and binds down the extensor tendons of the toes, together with that of the tibialis anticus, or forms three canals for these tendons; one for that of the tibialis anticus, another for that of the extensor proprius pollicis, and the third for that of the extensor longus digitorum and the peroneus tertius.

Before proceeding with the ligaments of the ankle-joint, I shall finish the description of the remaining muscles, which are only the interossei, although I should recommend to the student, to investigate the joints immediately after the examination of the muscles which run over them.

The interossei of the foot resemble those of the hand, and consist of two series, the one being situated on the patellar aspect of the foot, and named interossei digitorum externi pedis, or dorsal interossei, the other series being situated on the plantar aspect of the foot, and styled interossei digitorum interni pedis, or plantar interossei.

The interossei digitorum externi pedis, ‡ G, D, K, L, in Fig. 1 of Plate LIV., situated between the metatarsal bones, 20, 2, 3, 4, 5, are four in number, arising by double origins from each two contiguous metatarsal bones, and inserted into the proximal phalanges.

The first is named abductor indicis pedis, § but more correctly adductor, indicated by G, in Fig. 1 of Plate LIV., deriving its origin from the os cuneiforme internum, *d*, and the two metatarsal bones, 20, 2, of the great toe and index, and running along the tibial aspect of the index or second toe, 2, to be inserted in the same aspect of the root or proximal extremity of the proximal or first phalanx, and the expansive tendon of the extensor longus. The function of this muscle is to adduct or to inflect tibiad the index pedis, and to bend or inflect plantad the proximal phalanx of this toe. ‖

The adductor, but properly abductor indicis pedis, D, ¶ in Fig. 1 of Plate LIV., derives its origin from the metatarsal bones, 2 and 3, of the index and medius toe, and runs along the fibular aspect of the index, 2, to be inserted in the same aspect of the root or proximal extremity of the first or proximal phalanx of this toe, and the expansive tendon of the extensor longus. Its function is to abduct or inflect fibulad this toe, and to bend or inflect plantad the proximal phalanx. **

* Syn. Retinacula lata extensorum. Ligamentum vaginale tibiæ.

† The annular ligament is concerned in sprains of the extensor tendons, and in luxation of the ankle-joint. For the treatment of the former, see page 122.

‡ Syn. Musculos primos articulos flectentes, qui tertium musculum in numero succedunt. Decem musculos singulis digitis pedum binos inservientes. Parvi musculi quorum quatuor collocantur inter media ossa pedii. Interossei externi. Interossei pedis. Interosseux superieurs du pied. Metatarso-phalangiens lateraux. Sus-metatarso-lateri-phalangiens.

§ Syn. Adductor secundi digiti.

‖ The abductor indicis pedis is concerned in luxation and amputation of the proximal phalanx, and in extirpation of the metatarsal bone of both this toe and the index toe.

¶ Syn. Abductor secundi digiti.

** The adductor indicis pedis is concerned in luxation and amputation of the proximal phalanx of the index toe, and in extirpation of the metatarsal bone of both this and the middle toe.

The adductor medii digiti pedis, but more strictly speaking, the adductor, K, in Fig. 1 of Plate LIV.,* derives its origin from the metatarsal bones, 3, 4, of the medius and annularis toes, and extends along the fibular aspect of the middle toe, 3, to be inserted in the same aspect of the root or proximal phalanx of the middle toe, and the expansive tendon of the extensor longus. Its function is to abduct or inflect fibulad this toe, and to bend or inflect plantad the proximal phalanx.†

The adductor tertii digiti pedis, L, in Fig. 1 of Plate LIV., but properly the abductor,‡ arises from the metatarsal bones, 4, 5, of the ring and little toes, and runs along the fibular aspect of the annularis, 4, to be inserted in the same aspect of the root, or proximal extremity of the first or proximal phalanx,§ and the expansive tendon of the extensor longus. Its function is to abduct or inflect fibulad this toe, and to bend or inflect plantad the proximal phalanx.

The interossei digitorum interni pedis,‖ represented in Plate LIII., are said to be only three in number; but this varies like the palmar interossei of the hand. The interossei described by authors are an abductor medii digiti pedis, M, an abductor tertii digiti pedis, P, and an abductor minimi digiti pedis, Q. In this subject, however, we have an abductor, T, and an adductor indicis, A, an adductor medii digiti pedis, *g*, and an adductor tertii digiti pedis, *t*, which are very common. I have adhered to these names to prevent confusion, although they should be reversed; for the abductors are adductors, and the adductors abductors. These little muscles are very difficult to separate and distinguish, even according to the number described by authors; indeed they are more difficult to be understood in this way, than when an adductor and an abductor are assigned to each toe. They derive their origins from the sides of the metatarsal bones, and are inserted in the proximal phalanges of the same toes.

The abductor digiti medii pedis muscle, M,¶ Plate LIII., properly speaking the adductor medii digiti, arises from the tibial aspect of the metatarsal bone of the middle toe, along which it runs, to be inserted in the same aspect of the root or proximal extremity of the proximal phalanx of the same toe. Its function is to adduct the middle toe tibiad, and to inflect plantad the proximal phalanx.**

The abductor tertii digiti vel annularis pedis, more properly adductor, P,†† in Plate LIII., and Fig. 1 of Plate LII., derives its origin from the tibial aspect of the metatarsal bone of the ring toe, along which it advances, to be inserted in the same aspect of the root, or proximal extremity of the same toe. The function of this muscle is to adduct tibiad the ring or third toe, and to inflect plantad the proximal phalanx.*

The abductor digiti minimi pedis,† Q, Plate LIII., and in Fig. 1 of Plate LII., strictly speaking adductor, derives its origin from the tibial aspect of the metatarsal bone of the little toe, along which it proceeds, to be inserted in the same aspect of the root, or proximal extremity of the phalanx of the same toe. Its function is to adduct tibiad the little toe, and to inflect plantad the proximal phalanx.‡

I now proceed to the ligaments of the leg and foot.

The tibia and fibula are tied together by several ligaments, of which the interosseous § is the larger. This ligament is represented in Plate LIII., and in Figs. 1 of Plates LIV., LII., and LI., marked H, extending between the tibia, *o*, and the fibula 1, the fibres descending obliquely from the tibia to the fibula. At its proximal or upper portion, the anterior tibial blood-vessels run through an aperture from the popliteal to the patellar aspect, as represented in Fig. 1 of Plate L., but not in LIII., as the muscles on the patellar aspect had not been removed from the extremity when the drawing was taken; this portion of the ligament, however, is observed to be more delicate. There are also found several smaller holes for the passage of blood-vessels. The use of this ligament is to connect the fibula to the tibia, and to afford origin to several muscles of the leg.‖

---

* Syn. Abductor tertii digiti.

† The adductor medii digiti pedis is concerned in luxation and amputation of the proximal phalanx of the middle toe, and the metatarsal bone both of this and the ring toe.

‡ Syn. Abductor quarti digiti.

§ The adductor tertii digiti pedis is concerned in luxation and amputation of the proximal phalanx of the third or ring toe, and the metatarsal bone both of this and the little toe.

‖ Syn. Musculos primos articulos flectentes, qui tertium in numero succedunt. Decem musculos singulis digitis pedis binos inservientes. Parvos musculos quorum quatuor collocantur in planta. Sunt interossei interni. Interossei. Interossei pedis. Inter-osseux inferieurs du pied. Inter-osseux plantaires. Métatarso-phalangiens lateraux. Sus-métatarso-lateri phalangiens. Plantar interossei.

¶ Syn. Abductor digiti tertii pedis.

** The abductor digiti medii pedis is concerned in luxation and amputation of the proximal phalanx, and in extirpation of the metatarsal bone of the middle toe.

†† Syn. Abductor digiti quarti pedis.

* The abductor tertii digiti pedis is concerned in luxation and amputation of the proximal phalanx, and in extirpation of the metatarsal bone of the third or ring toe.

† Syn. Adductor digiti minimi pedis.

‡ The abductor digiti minimi pedis is concerned in luxation and amputation of the proximal phalanx, and in extirpation of the metatarsal bone of the little toe.

§ Syn. Membrana cruris interossea.

‖ The interosseous ligament is concerned in fracture of the tibia or fibula, either singly or conjointly, and in amputation of the leg. When the latter operation is deemed requisite, the insertion of the inner hamstring muscles should be considered as regards the preservation of the motion of the knee-joint; and the extent of the fleshy fibres of the gastrocnemii muscle, as relates to their forming a proper cushion for the bones. The patient ought to be placed on a low table covered with blankets, with his leg projecting beyond its edge, and supported by an assistant; and compression made about the middle of the thigh, as directed in pages 89 and 112. One assistant holds the limb firmly above the knee, another takes hold of the foot, and raises the limb as high as the patient can bear, then the operator, with his left hand, grasps the calf of the leg, while with his right he makes a semicircular incision with an amputating knife on the popliteal aspect of the leg, from the fibula to the tibia if the left leg, and vicê versâ if the right leg; the arc of the circle pointing distad, and the cord extending across the leg. The first incision ought to extend through the skin, cellular substance, and the bellies of the gastrocnemii, and the second through the more deeply seated muscles to the bone. The operator next makes a transverse or semi-elliptical incision on the patellar aspect of the leg, so as to connect the two ends of the popliteal incision, through the skin, cellular tissue, and muscles on the patellar aspect; and then passes the knife between the tibia and fibula, so as to divide any remaining fleshy fibres, and to separate the interosseous ligament. The assistant retracts the soft parts, when the operator saws through the bones as directed in page 89, resting the instrument on both bones, but dividing the fibula before the tibia. The limb being thus removed, the operator searches for the arteries; and at this stage of the amputation, the knowledge of the surgeon is at once recognised. If the limb be removed near the poples, only one arterial trunk, the popliteal, with the gastrocnemii branches, will require to be secured; if a little distad, the three arteries of the leg will require to be secured. See Plate XXVIII. For ligatures and after treatment, see page 89.

The proximal and distal extremities of the fibula are firmly connected with the tibia by a capsular and intertransverse ligaments. The superior or proximal extremity, 60, of the fibula, 1, is attached to the tibia by strong intertransverse ligaments, marked 5, in Plate LIII., which extend between the head of the tibia and that of the fibula on the popliteal aspect and named the posterior ligament; similar ligamentous fibres being found on the patellar aspect, and here termed the anterior ligament. This extremity or head of the fibula is covered with cartilage where it looks to the tibia, and both surfaces are surrounded with a synovial membrane, which is often continuous with that of the knee-joint.*

The inferior or distal extremity of the fibula, 1, is firmly tied to the tibia by intertransverse ligaments,† marked 70, in Figs. 1, 2, and 3 of Plate LIV., which extend from the distal extremity of the tibia, *o*, to that of the fibula, 1, both on the patellar and popliteal aspects. Those fibres on the patellar aspect being named the anterior ligament; and those on the popliteal, the posterior ligament. Similar strong ligamentous bands extend between the ends of these bones, where they are opposed to each other, so as to render their connexion extremely strong and firm.‡ These are termed by some the interosseous ligament. A synovial membrane is described by some, and said to be derived from the ankle-joint.

The ankle-joint, or tibio-tarsal articulation, is formed by the tibia, fibula, and astragalus, surrounded by a synovial membrane, and supported by strong lateral ligaments. The articular surface of each of these bones is tipped with cartilage, and there are several glandular tissues to secrete the synovial fluid, particularly one between the tibia and fibula, marked 10, in Fig. 3 of Plate LIV., and also in Fig. 2 of Plate LI.

The synovial membrane, delineated in Figs. 1, 2, and 3 of Plate LIV., and in Fig. 2 of Plate LI., marked with the digits 30, surrounds the articular surfaces of the tibia, fibula, and astragalus, which enter into the formation of the ankle-joint. This ligament is remarkably thin, abounds with adipose tissue, and is with difficulty preserved in dissection. Exterior to the synovial membrane, are the lateral ligaments which are common to all the ginglymoid joints; the tibial or internal of this joint is single, while the fibula or external consists of three portions.

The tibial or internal lateral ligament, named also deltoid,§ 33, extends between the maleolus internus, *s*, the os astragalus, *a*, and os naviculare, *b*, as delineated in Fig. 2 of Plate LII., and Fig. 1 and 2 of Plate LIV., and, as its name indicates, commences by a narrow beginning or apex, from the tibia, *s*, radiating to the astragalus, *a*, and naviculare, *b*. This ligament is remarkably strong, and binds these bones together.

The fibular or external lateral ligament consists of three portions; an anterior, a middle, and a posterior.

* Syn. Ligamentum capituli fibulæ. Ligamentum capsulare extremitatis superioris.

This joint is sometimes luxated, the head of the fibula being forced poplitead. It is easily brought to its situation, but is as easily displaced again. A roller should be applied tightly around the limb at this part, with a pad poplitead to the head of the fibula; and if much synovia is effused, blistering may be had recourse to.

† Syn. Ligamentum superius anticum et posticum partis inferioris cruris. Ligamentum inferius anticum et posticum partis inferioris cruris. Ligamentum extremitatis inferioris.

‡ These intertransverse ligaments are seldom torn, and only in luxation of the ankle-joint.

§ Syn. Ligamentum deltoides malleoli interni.

The anterior or patellar portion,* marked 31, in Fig. 1 of Plate LIV., extends between the malleolus externus, S, and the astragalus. The middle, or perpendicular portion,† 32, descends from the malleolus externus, S, to be attached to the os calcis, D, as delineated in Fig. 2 of Plate LIV., also in Figs. 1 and 3 of the same plate. The posterior or popliteal portion,‡ 14, in Fig 2 of Plate LIV., is generally included within the synovial membrane, 30, and extends from the malleolus externus, S, to the popliteal aspect of the astragalus, *a*. This external lateral ligament contributes in a powerful manner to connect the bones of the tarsus with those of the leg. §

* Syn. Ligamentum fibulæ anticum vel anterius. The anterior peroneo-tarsal ligament.

† Syn. Ligamentum fibula medium. Ligamentum malleoli externi medium perpendiculare. The external lateral ligament.

‡ Syn. Ligamentum fibulæ posticum. Ligamentum fibulæ posterius. The posterior peroneo-tarsal ligament.

§ The ankle-joint is liable to be dislocated in every direction, either laterally, or forwards, or backwards; dislocation to the inner or tibial side being the most frequent. In this latter accident the synovial membrane is lacerated, excepting where it is attached to the fibula, which bone is generally fractured an inch or two above or proximad, and thus the fibular lateral ligaments remain entire; the tibia is also usually fractured near the malleolus internus, and separated from the fibula by a rupture of the intertransverse ligaments, so that the deltoid or tibial lateral ligament may likewise remain sound. This portion of the tibia rests upon the tibial side of the astragalus, while the proximal fractured end of the fibula rests on the upper or proximal articulatory surface of the astragalus. The accident is easily distinguished, unless much tumefaction has supervened. Reduction is easily accomplished by relaxing the gastrocnemius muscle, by bending the knee-joint, and then extending the foot gently and gradually. When reduced, the limb is to be laid on M'Intyre's splint, and treated with hot anodyne fomentations and poultices, till all inflammatory action is subdued.

In luxation outwards or fibulad, both the malleoli are generally fractured, so as to preserve the lateral ligaments; the proximal part of the trochlear surface of the tibia is thrown somewhat fibulad on the superior or proximal surface of the astragalus, so that the sole of the foot is turned inwards or tibiad, with the fibular margin of the foot resting on the ground. The synovial membrane is more or less lacerated. If the fibula be not fractured, the fibular lateral ligaments are torn. The same mode of reduction and treatment as in the former is here employed.

In luxation forwards or distad, the tibia is either forced a little from its natural situation, so as still to rest upon the os astragalus, or it is driven forwards upon the os naviculare and os cuneiforme internum; the fibula is generally fractured two or three inches above its malleolus, which remains in situation from the strength of the fibular lateral ligaments, while the shaft of the fibula accompanies the tibia, the capsular and deltoid ligaments being more or less lacerated. The position of the foot in the latter of these two accidents is—the heel lengthened and dragged a little poplitead, and the toes pointed downwards, so as to give the foot a shortened appearance; while a large projection is perceived on the upper part of the foot, and a depression between the tibia and tendo achillis. In the former of these two accidents there is much less disfiguration of the foot, the accident being liable to be mistaken for a sprain or contusion. The same manner of reduction and treatment is requisite, as in luxation inwards. Sometimes the trochlear surface of the tibia is fractured.

In compound luxation of the ankle-joint, amputation becomes a matter of consideration, according as there are more or less injury done both to the hard and soft parts, and according as the patient can be well accommodated and remain quiet. If an attempt be made to save the limb, as many pieces of bone should be removed as can be done with facility and promptitude, and the luxation reduced, dividing any portion of skin which may prevent its accomplishment; the limb is then to be treated as recommended above. When the inflammation has ceased and suppuration been established, the wound is to be treated with simple dressing and bandage. Several months generally pass ove before the patient can put his foot to the ground, even with the assistance of crutches.

The protruded portion of bone, when so fractured that it cannot rest upon the astragalus, or when it cannot be easily reduced, is to be sawn

The tarsal ligaments consist of synovial membranes and transverse ligaments; the latter into transverse and peculiar plantar ligaments. By some these ligaments are arranged into those connecting the bones in the posterior row, the os calcis and the astragalus; those connecting the bones of the middle row, the os scaphoides and cuboides; those of the anterior row, the three cuneiform; and, lastly, the ligaments connecting the bones of the rows with each other. As the transverse lie superficial to the capsular, they should be first examined. In Fig. 1 of Plate LIV. are represented the patellar or dorsal transverse ligaments,* marked *z*, which are observed to extend from one tarsal bone to another, so as to connect them together. In Fig. 2 of Plate LI., one of these, *z*, extending between the os calcis, c, and the os cuboides, *g*, is represented truncated. In this figure, another intertransverse ligament,† marked *u*, is observed extending between the os astragalus, *m*, *a*, and the junction of the os naviculare, *b*, with the os cuboides, *g*, to connect these bones more securely. Similar ligaments are found between all the tarsal bones, extending between the scabrous surfaces opposed to each other.‡

On the plantar aspect, the two ligaments, commonly named plantar, present themselves, and are delineated in Figs. 1 and 2 of Plates LII. and LIII., marked *w*, *y*; the latter, *y*, is named the external or fibular plantar ligament, from its situation on the outer or fibular aspect of the sole of the foot, is remarkably strong and conspicuous, and extends from near the projection of the os calcis, D, onwards or distad to the os cuboides, *g*, and external cuneiform bone. This ligament assists in supporting the arch of the foot. §

The internal or tibial plantar ligament, *w*, in Figs. 1 and 2 of Plates LII. and LIII., situated in the sole of the foot, on its internal or tibial aspect, is equally powerful with the preceding, and extends between the sinuosity of the os calcis, D, and the os naviculare, *b*, thus supporting the os astragalus, *a*, and contributing to form the arch of the foot. This ligament is more or less incorporated with the deltoid ligament, 33, of the ankle-joint, as represented in Fig. 2 of Plate LII. ||

Besides these two conspicuous plantar ligaments, much smaller ligaments are found extending between the different tarsal bones, as represented in Fig. 1 of Plates LII. and LIII., marked *x*. ¶

When the tranverse ligaments are carefully removed or divided across, a synovial membrane is found surrounding those articular surfaces, which are opposed to one another, as delineated in Figs. 2 and 3 of Plate LI. In Fig. 2 the articulation between the convex surface, *m*, of the os astragalus and the concave surface, *b* of the os naviculare is observed surrounded with the capsular ligament, *v*; and the articulation between the conchoidal surfaces of the os calcis, c, and the os cuboides, *g*, is also surrounded with a capsular ligament, *e*. These synovial membranes are very delicate, and seem designed chiefly to confine the synovial fluid.*

In Fig. 3 of Plate LI. the articulation formed by the os naviculare, *b*, and the three cuneiform bones, *d*, *e*, *f*, is drawn enveloped in one capsular ligament, *v*. This ligament connects these bones, but chiefly confines the synovial fluid.†

In Fig. 1 of Plate LIV., the transverse ligaments on the patellar aspect of the foot, connecting the tarsal with the metatarsal bones, are delineated and marked *p*, and are observed to extend between the three cuneiform bones, the os cuboides, and the five metatarsal bones. In Fig. 3 of Plate LI., are delineated the delicate synovial ligaments surrounding these articulations, marked *l*, and also the intertransverse ligaments, i, which extend between these bones within the articulations. These transverse, capsular, and intertransverse ligaments connect these bones together, the capsular also confining the synovial fluid.‡

---

off, which moderates the inflammation, and forms a tolerable joint. See Sir Astley Cooper's work on Dislocations and Fractures, and Lizars' Practical Surgery, Part I.

* Syn. Ligamenta pedis dorsalia. Ligamenta transversa dorsi pedis.

† Syn. Ligamenta lateralia.

‡ These ligaments are concerned in luxation or extirpation of any of the tarsal bones, and also in amputation across the foot.

§ The fibular plantar ligament is concerned in extirpation of the os cuboides, and in amputation across the foot.

|| The tibial plantar ligament is concerned in luxation and extirpation of the os naviculare, and also in amputation across the sole of the foot.

¶ These plantar ligaments are concerned in luxation and extirpation of the tarsal bones, to which they are attached, and in amputation across the foot.

* These synovial membranes are concerned in amputation across the foot, at these two articulations, which preserves to the individual the extension of the ankle-joint, and the propulsion of the body forwards, when the distal tarsal and metatarsal bones, and phalanges of the toes, are so injured or diseased as to require removal. But Larrey proves that the individuals on whom this operation was performed, felt so acute pain in walking, that they solicited amputation above the ankle-joint.

These transverse and synovial ligaments are also concerned in luxation and extirpation of either of these tarsal bones, for which see p. 27. In luxation of the astragalus, the bone is forced forwards and inwards, or patellad and tibiad; and also forwards and outwards, or patellad and fibulad; and in either of these two varieties, the tibia or fibula is generally fractured. Reduction in both of these cases is usually very difficult, from the tibia and fibula so approximating as to shut out the astragalus, and also from the skin puckering, and the tendons being on the stretch. Reduction should be attempted by placing the limb in the same attitude as in luxation of the ankle-joint, and, if found impracticable, the astragalus ought to be extirpated. But this has been found, even by Dupuytren, excessively difficult. Some surgeons, therefore, never attempt extirpation, after failing to reduce it, but leave all to nature: the skin and ligaments slough, and the bone is detached. That dexterous surgeon, Mr. Green of St. Thomas's Hospital, was successful in extirpating this bone. Attention must be paid to the fractured bone, after the reduction.

In some cases, the connexion of the os astragalus with the tibia and fibula remains entire, while that with the os naviculare and os calcis is lacerated, forming a luxation of the os astragalus from these two bones, which takes place either tibiad or fibulad, and is much more easily reduced by the same means, than the simple luxation of the os astragalus before described. In luxation of the os naviculare and os cuboides from the os astragalus and os calcis, which takes place generally inwards or tibiad, the foot resembles the club-foot, and is easily reduced.—For further information on this subject, consult Dessault, Hey, Boyer, Dupuytren, and Sir Astley Cooper.

† This capsular ligament is concerned in luxation and extirpation of either of these bones, for which see page 27.

‡ From the manner in which these metatarsal are locked into the tarsal bones, assisted by these transverse and intertransverse ligaments, they are seldom or ever luxated. Amputation is performed across the foot by cutting between these bones, when the metatarsal and phalanges are injured or diseased. The form of the flaps is the same as that recommended between the os astragalus and os calcis, and the os naviculare and os cuboides. The operator grasps with his left hand the fleshy and tegumental substance of the sole of the foot, and with a strong bistoury begins his incision at the projecting head or proximal extremity of the metatarsal bone of the little toe, and carries it around close to the toes, to the base of the metatarsal bone of the great toe; this mass he dissects close to the metatarsal bones backwards to their

The heads or distal extremities of the metatarsal bones, 20, 2, 3, 4, 5, are articulated to the proximal extremities of the proximal or first phalanges, 6, 8, 11, 14, 17, by synovial and lateral ligaments, the former being marked m, and the latter, n, in Fig. 1 of Plates LIV. and LIII., and in Fig. 3 of Plate LI. The lateral ligaments, n, are situated on the tibial and fibular aspects of the joints, extending between the distal extremities or heads of the metatarsal bones, and the proximal extremities of the phalanges. Their use is to connect these bones, and to limit the motions of the joints.

The synovial ligaments, marked with the letters m, surround the articulations, connect these bones together, and confine the synovial fluid.*

The heads of the metatarsal bones are tied to each other in the plantar aspect by short transverse ligaments, which are represented in Fig. 1 of Plate LII., marked e.

The distal extremities or heads of the proximal phalanx, 8, 11, 14, 17, are connected with the proximal extremities or bones of the second or medial phalanx, 9, 12, 15, 18, as represented in Fig. 1 of Plates LIV. and LIII. by synovial, p, and lateral, q, ligaments, which so resemble those at the proximal extremities or bases of the first phalanx, that they need not be described. The same arrangement of ligaments connect the medial, 9, 12, 15, 18, and distal, 10, 13, 16, 19, phalanges, and also the proximal, 6, and distal, 7, of the great toe.

---

tarsal ends, so as to form as thick a flap as possible; he then makes a transverse incision of the skin on the patellar aspect of the foot, so as to connect the extremes of this flap. He now grasps the toes, depresses them with moderate force, and divides the ligaments, commencing at the little toe and ending at the great toe.

* These ligaments are concerned in luxation of these joints, which very seldom occurs; occasionally the proximal phalanx is forced patellad of the heads of the metatarsal bones, and is easily reduced. The same remark is applicable to the distal joints of the toes, because they are constructed in a similar manner. When amputation is deemed requisite at any of the joints of the toes, it should be performed by cutting into the joint on the patellar aspect, and making a flap of the plantar substance.

THE BRAIN.

The nervous system is divided into the cerebrum, letters A, the cerebellum, letters B, and the spinal cord, C,* with the nerves issuing from these different portions, as represented in Plate LV. The cerebrum, cerebellum, and spinal cord constitute the centre of the nervous system, and are named the cerebro-spinal axis. The cerebral mass contained within the cranium is termed encephalon, and consists of the cerebrum, cerebellum, and the cerebral protuberance. The encephalic nerves, twelve in number, are not seen in this view, but are delineated in Plates LXI., LXIV., and LXV. The spinal nerves consist of thirty pairs, but they are not numerically marked in this diagram, as that appeared unnecessary; they are subdivided, like the vertebræ, into 7 cervical, 12 dorsal, 5 lumbar, and 5 sacral pairs.

The cerebrum,† letters A, is that portion of the brain contained within the bones of the cranium, above or coronal to the tentorium, which is the extension of the dura mater between the cerebrum, A, and the cerebellum, B. The tentorium is partially seen in Plates LXII. and LXV., marked *d*.

The cerebrum is divided into two hemispheres, marked A, A, in Plates LV. and LXVII.; and each hemisphere into three lobes, an anterior, marked a, a middle, *a*, and a posterior, **a**, as delineated in Plates LVI. and LXIV. These lobular divisions are not apparent on the upper or coronal aspect of the cerebrum, but are tolerably distinct on the basis, as seen in Plate LXIV.; they are produced partly by the duplicatures of the dura mater, and partly by the bones, as represented in Plates LXV. and IV.

The hemispheres are first observable in the fetus of seven weeks, in the state of two membranous pouches; at the end of three months, the anterior are discernible from the middle lobes, but the middle are not separated from the posterior lobes till the sixth month, and then only by a slight depression, for even in the adult they are not distinctly separated.

The dura mater,‡ D, d, in Plate LV., envelopes the cerebrum, the cerebellum, and the spinal cord; and accompanies the nerves, forming their chief support. This membrane, of a bluish milky colour, having a fibro-serous structure, is remarkably strong, and adheres to the bones of the cranium, forming their internal periosteum, where it surrounds the cerebrum and cerebellum, as formerly described: this surface is fibrous, as represented in Plate LVII., while that which touches the brain is serous, as delineated in Plate LXV.* The dura mater, after lining the frontal, parietal, and part of the temporal bones, and nearly the one-half of the occipital bone, sends forth a transverse septum, which adheres to the internal transverse ridge of the occipital bone, marked *r*, in Figs. 3 and 4 of Plate IV., and to the petrosal ridges, marked *v*, in Figs. 3 and 4, Plate IV. This partition is denominated the tentorium cerebelli,† as it lies over the cerebellum, separating it partially from the cerebrum; a large oval foramen being found in its anterior or glabello-coronal aspect, to enable the crura cerebri to unite with the crura cerebelli. This tentorium is partially represented in Plates LXII. and LXV., marked *d*, and in one of the plates of the organs of sense.

Where the tentorium commences at the transverse ridge of the occipital bone, a layer of dura mater is continued on the bone exterior or peripheral to the lateral sinuses, and also at the petrosal ridges; the dura mater, therefore, coming down from the coronal aspect, and up from the basilar aspect of the cranium, meets at these ridges to form the tentorium, but sends onwards an external lamina peripherad or exteriorly to the lateral and petrosal sinuses, so that these sinuses or veins separate the portions of the dura mater at the ridges. At the sutures, the dura mater sends fibrous productions to unite with the pericranium, for in the fetus, before ossification had begun, these membranes were in contact.

The dura mater sends a partition downwards in the longitudinal fissure between the two hemispheres of the cerebrum, named falx cerebri,‡ which descends nearly to the corpus callosum, *w*, as delineated in Plate LVIII., marked **D**. This septum extends from the crista galli, *b*, and the mesial line of the ethmoid bone, represented in Plate LXV., and in Plate IV., Figs. 3 and 4, along the mesial ridge of the frontal bone, and the junction of the parietal bones, where they form the sagittal suture, and the superior perpendicular ridge, *q*, of the occipital bone in Plate IV., Figs. 3 and 4. At this extremity it is much broader, and unites with the tentorium, *d*.

The falx is formed in the same way as the tentorium, by the lateral portions of the dura mater uniting beneath or centrad to the mesial line of the os frontis, the sagittal suture, and the superior perpendicular ridge of the occipital bone; but leaving a triangular space for the superior longitudinal sinus, which is covered superiorly or coronad or peripherad by the outer lamina of the dura mater, so

* Syn. Medulla spinalis.

† Syn. The great brain. The brain proper. Le cerveau.

‡ Syn. μηνιγξ σκληρη. Meninx dura. Hard membrane.

* The structure of the dura mater should be well considered by the practitioner in injuries and diseases of the head.

† Tentorium cerebello super extensum. La tente du cervelet. Transverse middle septum.

‡ Syn. Vertical or falciform process. Faux cérébrale.

that the trephine may be applied over it without injury, if the operator proceeds with caution.

Besides these conspicuous productions or processes of the dura mater, there are subordinate ones. A small prolongation extends from the inferior transverse ridge of the occipital bone, between the hemispheres of the cerebellum, as represented in Plate LXV., marked δ, which is named falx cerebelli,* and is formed by the two surfaces of the dura mater, which line the cerebellic depressions of the occipital bone, uniting at the inferior perpendicular ridge of this bone. As there are generally no veins or sinuses here, the manner of its formation illustrates still more satisfactorily that of the falx cerebri and the tentorium cerebelli. Other still smaller prolongations extend along the transverse spinous processes of the sphenoid bone, which are marked B in Plate LXV. The sella turcica of the sphenoid bone is observed to be surrounded by the dura mater in Plate LXV., and marked C. This extends from the anterior to the posterior clinoid processes, leaving loose lateral folds, and forming an acute circular edge, which surrounds the infundibulum, *o*, in Plate LXV. A small portion of the pituitary gland is observed uncovered within this circle. The dura mater also invests the floor of the sella turcica, and separates on each side to form the cavernous sinuses, as represented in one of the plates descriptive of the organs of sense. This surface, which forms the cavernous sinuses, and invests the sella turcica, is cellular. The dura mater passes out of the various foramina in the basis of the cranium, either to unite with the periosteum of the bones externally, or to form the envelope of the nerves. At the foramen magnum of the occipital bone, it descends lining the spinal canal, as represented in Plate LV., marked d, adhering loosely to the vertebræ by delicate adipose tissue and the rachidian veins; but towards the lower part of the sacral canal, it is fixed by irregular fibrous bands. Tubular prolongations emerge at the intervertebral foramina, surrounding the nerves.

The dura mater is observable in the fetus of seven weeks.

The membrane observed gliding over the surface of the convolutions of the cerebrum and cerebellum, and still more distinctly on the basis, is named tunica arachnoides.† This envelope is of a bluish milky colour, and so semi-transparent, that it cannot be represented easily on paper. If Plates LV., LVI., LVII., LXIV., and LXVI. were covered with mucilage of gum arabic, this would give, as far as possible, an idea of it.

After surrounding the surface of each hemisphere of the cerebrum, adhering to the pia mater on the convexity of the convolutions, the arachnoid membrane envelopes the veins marked with the digits 1 in Plate LVII., and becomes attached to the cerebral surface of the dura mater, D, so as to form its cerebral lining, which is its serous surface. The arachnoid membrane also descends on each side between the falx cerebri, 𝔇, in Plate LVIII., and the mesial convolutions of the hemispheres, which it invests downwards to the corpus callosum, *w*, where the two unite to form a continuous membrane; which afterwards may be traced posteriorly along the corpus callosum, *w*, in Plate LIX., descending between it and the corpora quadrigemina, marked with the letters e, *e*, where investing the lower surface of the velum interpositum Halleri, marked i, *i*, in Plate LXII., it enters the third ventricle at the foramen commune posterius, *a*, to spread all over the cavities. Thus, after lining the parietes of the third ventricle, 3, in Fig. 3 of Plate LXI., it descends backwards along the iter a tertio ad quartum ventriculum* represented in Plate LXVIII., by a dotted line from 3 to 4, and forwards to the infundibulum, *o*, in Fig. 4 of Plate LXI: it also ascends by the foramen commune anterius, a, in Plate LXII., to invest the fifth, marked 5 in Fig. 1 of Plate LXI. and in Plate LXVIII., and onwards by the foramen Monroianum, marked M in Plate LX., to the lateral ventricles.

To return to the surface of the hemispheres,—we find the arachnoid membrane expanded over the convolutions, extending across the fissure of Sylvius, and descending between the cerebrum, A, and cerebellum, B, in Plate LV. to invest the latter, then continuing its course to the basis of the brain, as observed in Plate LXIV., running onwards to encircle the spinal cord, C, as in Plate LV., down to its termination, where it is reflected on the theca vertebralis, d, in Plate LV. to form a *cul de sac*. In this course, it accompanies the spinal nerves for a short distance, and is then reflected to join that portion of itself which invests the dura mater, here termed theca vertebralis or spinal sheath, marked d in Plate LV. In this canal it sends off, between the anterior and posterior origins of the spinal nerves, simple duplicatures which extend from the pia mater to the dura mater, being attached to the latter by acute points intermediate to the emergence of the various spinal nerves, from the first to the cauda equina, where the tunica arachnoides becomes again plain and continuous. These denticulata, the whole being named ligamentum denticulatum or dentatum, resemble the angular folds, which accompany or envelope the spinal nerves. They adhere to the pia mater by delicate cellular membrane. They are represented in Plate LXIX. of a bluish colour, extending from the spinal cord, c, to the dura mater, d, between the different spinal nerves.

To return to that portion of the arachnoid membrane which adheres to the dura mater,—we find it continuous downwards to the margin of the falx, 𝔇, in Plate LVIII., and all over the dura mater, D, tentorium, *d*, falx cerebelli, δ, and theca vertebralis, d, in Plates LV. and LXV., forming its serous surface, and uniting with that which invests the brain and spinal cord, so as to form a perfect sac. Excepting the very minute injections, or when attacked with inflammation, no blood-vessels can be traced upon it.

The tunica arachnoides begins to be observable between the fifth and sixth month of the fetus.

The pia mater† is that delicate tissue of blood-vessels, supported by soft cellular membranaceous substance, enveloping the whole surface of the cerebrum, A, a, *a*, 𝔞, cerebellum, B, spinal cord, C, and nerves, as represented in Plates LV. and LVI. This delicate membrane may be traced adhering to all the convolutions of the cerebrum and cerebellum, descending between their sulci or grooves; and also between the different lobes. On raising the posterior lobes of the cerebrum from the tentorium, we

* Syn. Falx minor. Faux du cervelet.

† Meninx media. Membrana cellulosa. La lame externe de la méningine.

* In the fetus it descends between the columns of the spinal cord to the cauda equina.

† Syn. Pia meninx. Meninx tennis. Meninx interior. Membrana vasculosa. La lame interne de la méningine; the soft membrane.

observe the broad vascular expanse of the velum of Haller or the choroid web, as seen in Plate LXII., marked i, *i*, and in Fig. 2 of Plate LXI., advancing forwards superficially to the pineal gland, H, the corpora quadrigemina, e, *e*, and the thalami, F, and running beneath the fornix, K, on emerging from which in the lateral ventricles, it forms the choroid plexus,* *i*, *i*, in Figs. 1 and 2 of Plate LXI. and and in Plate LX. From these plexuses, vessels shoot into the ventricles on the thalami, F, and the corpora striata, G; the greater number of which are veins. This web or the choroid plexuses extend on each side around, backwards, downwards, and again forwards, or iniad, basilad, and glabellad, into the inferior cornua of the lateral ventricles, as seen in Plates LX. and LXI. The arteries which supply this web are branches of the posterior artery of the cerebrum, marked *r*, in Plate LXIV. The veins concentrate to form the central vessel, marked i, in Fig. 2 of Plates LXI. and LXII., named after Galen. The pia mater formed by the minute distribution of the branches of the internal carotid and vertebral arteries, can be raised from the surface of the convolutions; and in doing so, a multiplicity of small vessels are dragged out of the substance of the brain.

The pia mater, after enveloping the cerebrum and cerebellum, descends on the annulare, E, in Plate LXIV., where it begins to become thicker, and continues to encircle the spinal cord, C, in Plate LV., being considerably stronger than where it invests the cerebrum and cerebellum: it continues to descend to the cauda equina, investing the nerves in its course, and is lost on them, like their envelope of the dura mater.

The pia mater is formed in the fetus so early as the sixth week.

There are various methods adopted in dissecting the brain; but that which is generally ascribed to Vesalius, being the one most frequently followed, I have preferred, although the method described by Varolius and Vieussens is the more connected. When the different parts have been simply demonstrated, I shall describe this organ in a connected order; for the brain ought to be examined in a variety of ways.

On the mesial aspect of the surface of each hemisphere, close to the longitudinal sinus, and in the sinus itself, are observed small glandular-looking bodies about the size of a pin's head, named glandulæ Pacchioni. These are most numerous towards the posterior or inial aspect of the mesial surface of the hemisphere. A few of them are represented within the sinus, which is marked *x* in Plate LVII.

On separating the hemispheres, A, A, Plates LV. and LXVI., of the cerebrum, at the fissure in which the falx cerebri,† Plate LVIII. descends, we arrive at an oblong white surface, consisting of an arrangement of transverse medullary fibres, termed corpus callosum,† marked with the letters *w*, forming the floor of this fissure. This unites the medullary matter, E, of the one hemisphere with that of the other, as represented in Plate LIX. In the fetus, this commissure begins anteriorly to the anterior crura, k, k, of the fornix, as seen in Plate LXI., Figs. 2 and 3, and in Plates LXII., LXIII., and gradually proceeds backwards with the growth of the hemispheres. This is still better illustrated in Plate LXVIII., where the connexion of the medullary matter is represented. The corpus callosum is not completed till the sixth month. In Plates LVIII. and LX. the fibrous or streaked appearance is more correctly delineated than in Plate LIX., as the weight of the hemispheres from which this latter drawing was taken, had in some degree injured the corpus callosum. In the latter or Plate LIX. the corpus callosum is observed to be somewhat broader posteriorly or iniad, than anteriorly or glabellad. In Plate LX. there are observed three delicate lines running longitudinally along the corpus callosum, the central one of which is named raphe.* Where these lines extend, the corpus callosum is a little elevated. The two lateral lines appear to be formed by the arteries of the corpus callosum, marked *v*, *v*. When we trace the corpus callosum backwards or iniad, we find it joining or uniting with the expanse of the fornix, K, as represented in Plate LXVIII.

In Plate LVIII., a section of the right hemisphere has been made parallel to the corpus callosum, *w*, which brings into view the two substances which compose the general cerebral mass; the white or orange-white matter, E, is named medullary,* and appears to be the efficient constituent of this wonderful mass; the greyish, cineritious, or reddish, or greyish-brown, or wood-brown matter, which every where surrounds this white mass, is termed cortical.† On examining the surface of the hemispheres, A, A, of the cerebrum in Plates LV., LVI., LVII., and LVIII., we remark a multiplicity of elevations and furrows, named the convolutions, which are better understood in the sections of Plates LVIII., LIX., and LX. These are very late in being developed in the fetus; not until the seventh month.

On removing the falx cerebri, D, and the opposite hemisphere parallel with the corpus callosum, *w*, we bring into view the centrum ovale of Vieussens, marked E, E, in Plate LIX. Another oval centre is represented by Vicq D'Azyr, by making a transverse or horizontal section a little above or coronal to this, named centrum ovale latéral ou petit centre ovale. Vicq D'Azyr thus makes an oval centre out of each hemisphere, while Vieussens makes only one. These are simply the condensation of the white medullary matter in the hemispheres.

When a perpendicular incision is made along the lateral margins of the corpus callosum, *w*, we come to large cavities, named the lateral ventricles,‡ which, when their roof is removed, as in Plate LX., exhibit three terminations, denominated cornua, and several bodies. A indicates the anterior cornu;§ P, the posterior cornu;‖ and I, the inferior cornu of each cavity.

The objects seen in each lateral ventricle are the corpus striatum, G, the thalamus, F, tænia semicircularis, *t*, separating these, the plexus choroides, I, and the fornix, K; these two cavities being apparently separated by the septum lucidum, L. The corpus striatum, G,¶ situated in the middle and anterior part of the ventricle, is of an

* Syn. Les plexus choroides superieurs. The choroid plexuses are subject to encysted serous tumours resembling hydatids, and to small tubercles, like glands.

† Syn. σωμα τιλλοειδες. Fornix vera. Corpus laeve. Commissura magna vel maxima cerebri. Middle or central band. Mésolobe.

* Syn. White nervous matter.

† Syn. Brown nervous matter. The extreme vascularity both of the medullary and cortical substances should be carefully considered by the practitioner.

‡ Syn. Ventriculus tricornis. Grand cavité du cerveau.

§ Syn. Anterior sinus of superior ventricle.

‖ Syn. Cavité digitale. Anchyroide.

¶ Syn. Le corps cannelé. Grand ganglion cérébral superieur. Partie interne du grand ganglion cérébral superieur. Processus anterior medullæ oblongatæ. Processus lentiformis. Ganglion anticum.

oblong pyriform shape, and of a reddish-brown colour, extends onwards into the anterior cornu, A, and is bounded posteriorly or iniad by the tænia semicircularis, *t*, and covered by the tunica arachnoides. This body, we shall afterwards find, has acquired its name from the crura cerebri, being radiated through its cineritious substance.

These striated bodies begin to be formed about the third month of the fetal life.

The tænia semicircularis * is a bluish line extending between the corpus striatum, G, and the thalamus, F, and is marked *t* in Plate LX. In the subject from which the drawings of this part were taken, it was a bold distinct vein; but in many, this vein is covered by a layer of medullary matter, so as almost to obscure, and give it only a bluish appearance. This vein can be traced to join the choroid plexus at its anterior aspect.

Tiedemann found in the seventh month of the fetus merely a groove between the corpus striatum and the thalamus; and not until the ninth month was this groove filled by vessels and medullary matter.

The choroid plexus has already been described, and the thalamus cannot be understood in this stage of the dissection; so that we must first examine the septum lucidum, L. † This delicate partition extends from the corpus callosum, *w*, to the fornix, K, and is found to consist of two medullary laminæ, which form a cavity, named the fifth ventricle, ‡ as represented in Fig. 1 of Plate LXI., and in Plate LXVIII. This cavity, marked 5, is found to communicate with the others at the foramen Monroianum, M, in Plate LX., or at the foramen commune anterius, a, Plate LXII; its canal of communication, therefore, descends between the anterior crura, k, k, of the fornix, K, in Figs. 2 and 3 of Plate LXI., also in Plates LXII. and LXIII.

In the fetus, the two laminæ of the septum lucidum are quite apart, and are not observed until the fifth month to extend from the two anterior pillars of the fornix (which are also separate and hence a free communication presents itself between the third and fifth ventricle) to the corpus callosum.

The fornix, § K, in Plate LX., and in Fig. 1 of Plate LXI., situated in the middle and posterior parts of the lateral ventricles, is a broad medullary expanse, which begins at the corpora albicantia, *s*, *s*, of Plates LXIV. and LXVII., ascends by its two anterior crura, *k*, *k*, to the floor of the lateral ventricles, where they unite and form a broad expanse, which runs backwards or iniad, resting on the thalami, F, F, and continuing to expand as it extends backwards and mesiad into the posterior cornua, P, P, to form the hippocampi minores, ‖ *k*, *k*, and as it descends downwards and forwards, or basilad and glabellad, resting on the crura cerebri, into the inferior cornu, I, to form the hippocampi majores, ¶ **K**, **K**: one of these latter white eminences is observed in Plate LXIII. to run a long way onwards, its termination being named pes hippocampi, and its free margin, which overlaps the plexus choroides, *i*, or is overlapped by it, the corpus fimbriatum.* This hippocampus major is considered the posterior crus of the fornix. The posterior part of the fornix forms a continuous substance with the corpus callosum, as may be easily understood from Plate LIX. On elevating the posterior part of the corpus callosum, *w*, we raise at the same time the fornix, bringing into view its inferior or basilar surface connected with the choroid web; the impression which this web forms on the basilar surface of the fornix is termed lyra or psalterum; see Fig. 2, Plate LXI., K. In this figure there is no appearance of a lyre, and it requires a considerable stretch of the imagination to perceive the resemblance.

In the fetus of four months the fornix begins by two slender cords at a bulky shapeless mass (the corpora albicantia, in the base of the brain, marked *s*, *s*, in Plate LXIV.), which ascend and unite under or basilad to the corpus callosum, then separate and extend backwards or iniad over the thalami, descending to the base of the posterior lobes of the hemispheres.

The choroid plexuses have been described in page 131.

The thalami nervorum opticorum,† F, F, in Plate LX., in Figs. 1, 2, 3, and 4 of Plate LXI., and in Plates LXII., LXIII., and LXVIII., are situated beneath or basilad to the fornix, K, and choroid web, i, *i*, forming the sides of the third ventricle, 3, and partially seen in the lateral ventricles. They are of an oblong bulbous shape, narrower anteriorly than posteriorly, applied to each other by their mesial sides, bounded laterally by the tænia semicircularis, *t*, and posteriorly or iniad by the corpora quadrigemina, e, *e*; their mesial sides being connected by a cineritious band, named the commissura mollis, which is marked m in Fig. 3 of Plate LXI. This commissure is not found in the fetus till the ninth month. In this representation the thalami are separated a little to expose this commissure, while in Plates LXII. and LXIII. they touch each other, being drawn in their natural state in these diagrams. Three small elevations on the surface of the thalami are taken notice of by authors: the first, situated anteriorly, and marked f in Fig. 3. of Plate LXI., and in Plates LXII. and LXIII., is named the anterior tubercle; the second, situated posteriorly, and near the pineal gland, H, is termed the inner or internal tubercle, or corpus geniculatum internum, and is marked *f*; and the third, situated exteriorly near the bold termination of the optic nerve, is styled outer or external tubercle, or corpus geniculatum externum: this latter has not been displayed, considering it unnecessary to give a figure for this individual point. The corpora geniculata will be described hereafter under the optic nerve. They are observed about the sixth month of the fetus. The thalami consist of medullary matter externally, and cineritious and medullary internally. They are visible in the fetus of seven weeks.

In Plates LXII. and LXIII., the foramen commune anterius, or vulva, a, and the foramen commune posterius, or anus, *a*, are represented, which form the sources of communication between the lateral and third ventricles.

---

* Syn. Geminum centrum semicirculare. Stria cornea sive semicircularis. Frenulum novum Tarini. Limbus posterior corporis striati Willisii. Tænia fibrossa corporis striati. Tænia striata. Bandelette semicirculaire. La lame cornée. La lame grise ou cendrée.

† Syn. Septum medium cerebri. Cloison des ventricules. Cloison transparente. Septum pellucidum. Speculum lucidum.

‡ Ventriculum septi medii.

§ Syn. La voûte à trois piliers. La masse commune de communication.

‖ Syn. Unguis. Caveæ posterioris ventriculi lateralis. L'éperon. L'ergot. Petit hypocampe. Eminence digitale. Eminence unciforme.

¶ Syn. Cornu ammonis. Le grands hypocampes.

* Syn. Corps frangé. Corps bordé. Bandelette de l'hypocampe. Tænia hypocampi. Borde interne, concave, dentelé ou godronné.

† Syn. Colliculi nervorum opticorum. Optic chambers. Les couches optiques. Les grands ganglions cérébral inferieurs. Juga crurum medullæ oblongatæ. Ganglion posticum. Corpus striatum posterius.

When the thalami, therefore, are held apart, we expose a cavity denominated the third ventricle,* marked 3, in Fig. 3 of Plate LXI., which is formed superiorly and laterally by these thalami, F, F, together with the commissura mollis, and inferiorly or basilad by the crura cerebri, C, and tuber annulare, E, as seen in Plate LXVIII.

The iter ad infundibulum, marked I, in Fig. 4, is observed leading downwards or basilad from the anterior or glabellar extremity of this third ventricle, the infundibulum † itself being marked *i*. This is a delicate tube, which leads to the pituitary gland,‡ P, and which consists of cineritious matter, and is of a funnel-like shape, the base being turned to the third ventricle. The pituitary gland is a small round body situated in the sella turcica of the sphenoid bone, partially covered by the dura mater, and composed of the cineritious and medullary substances of the brain; the posterior or inial portion being medullary, and the anterior or glabellar being cineritious. The infundibulum descends only a short way into its substance.

In the fetus of four months this body is quite hollow.

The iter § à tertio ad quartum ventriculum, indicated by a dotted line in Fig. 4 of Plate LXI., and in Plate LXVIII., is observed leading backwards or iniad from the third ventricle. This canal is also partly seen in this Fig. 4 of Plate LXI., but this I shall describe afterwards, having still to mention how the two lateral ventricles communicate. In Plate LX. is seen a pretty large foramen, marked M, extending across to the opposite cavity, beneath or basilad to the anterior crura, k, k, of the fornix, K, and immediately anterior or glabellar to the apparent anterior extremities of the choroid plexuses, *i*, *i*, and in Fig. 2 of Plate LXI., where the fornix, K, has been cut across at this communication, and reflected back, this communication is further illustrated: it is termed the foramen Monroianum.

When the thalami are held apart, and when we look anteriorly in the third ventricle, we observe a small white cord extending across, apparently between the anterior crura of the fornix, to which, however, it is anterior or glabellar: this is named the anterior commissure, ‖ and unites the medullary matter of the one corpus striatum to that of the other. It is marked *c* in Fig. 3 of Plate LXI., and in Plates LXIII. and LXVIII; also in Fig. 4 of Plate LXI.

This anterior commissure is perceivable at the third month of the fetus.

On looking backwards or iniad in the third ventricle, we perceive another white cord, marked *p* in Figs. 3 and 4 of Plate LXI., and in Plates LXII., LXIII., and LXVIII., which is named the posterior commissure; this unites the medullary matter of the thalami, and is observed in the fetus towards the end of the third month. A small ovate or heart-shaped body, resembling in shape a pine-apple, and hence named the pineal gland,* seen in Fig. 3 of Plate LXI., and in Plates LXII., LXIII., and LXVIII., marked H, is observed attached posteriorly to the mesial sides of the thalami, by two slender crura or peduncles, marked *h*. Where the peduncles run on the thalami, they are named by some authors the tracts of the pineal gland. This object consists chiefly of cineritious matter, and in the adult there is generally found a small quantity of sandy particles, named acervulus cerebri, which are not found in the fetus, and the gland itself is not observable till the fourth month. The peduncles consist of medullary matter.

The corpora quadrigemina are these four small round bodies, situated posteriorly and inferiorly or iniad and basilad to the pineal gland, H; they are represented in Figs. 3 and 4 in Plate LXI., and in Plates LXII., LXIII., and LXVIII., marked e, *e*. The two superior, e, e, are termed nates,† and the two inferior testes:‡ the superior or nates are somewhat larger, rounder or fuller, than the inferior or testes, and are of a redder colour, consisting more of the cineritious substance. These four eminences form part of the roof of the *iter a tertio* (3) *ad quartum* (4) *ventriculum*, as represented in Plate LXVIII. by a dotted line.

The corpora quadrigemina are observed in the fetus of two months in the shape of two membranous laminæ, separated by a longitudinal fissure, which become joined at the end of the third month, and then appear rounder and firmer.

---

* Syn. Ventricule moyen du cerveau. L'intervalle entre les grands ganglions cérébraux inferieurs.

† Syn. La Tige pituitaire.

‡ Syn. Hypophysis sive glandula pituitosa.

§ Syn. Aqueductus Sylvii.

‖ Syn. Commissura nævii æmula.

* Syn. Corps pineal. Conarium. Corpus turbinatum.

† Syn. Corpora Bigemina superiora. Tubercula quadrigemina anteriora. Tubercules quadrijumeaux superieures ou anterieures. Tubercula anteriora. Protuberantiæ orbiculares. Protuberantiæ natiformes.

‡ Syn. Corpora Bigemina inferiora. Tubercula quadrigemina posteriora. Tubercules quadrijumeaux inferieures ou posterieures. Tubercula posteriora. Protuberantiæ minores.

THE BRAIN.

A DELICATE medullary web or expanse, marked v, in Plates LIX. and LXVIII., is observed extending from the corpora quadrigemina, e, *e*, to the cerebellum, B; and in some instances, transverse striæ of cineritious matter are found on this web, which is named valvula Vieussenii;* it assists in forming the connecting link between the cerebrum and cerebellum, and contributes to form the iter à tertio, 3, ad quartum ventriculum, 4,† marked with a dotted line in Plate LXVIII. This canal is formed basilad or inferiorly by the crura cerebri, g, and superiorly or coronad by the posterior commissure, *p*, the corpora quadrigemina, e, *e*, and this medullary velum, v, also laterad, or on each side by all these bodies.

The iter à tertio ad quartum ventriculum is apparent in the fetus of seven weeks, is very large at this period, and open superiorly or coronad, the two sides of the cerebral and cerebellic masses being separated; at eleven weeks, these bodies are found united, and the tube completed, so that at this period the valve of Vieussens is also formed.

The valve of Vieussens is connected laterally with the medullary substance, extending from the testis, *e*, to the cerebellum, B, which is termed the processus cerebelli ad testes,‡ and is marked *l* in Plate LXVIII. This medullary process is part of the crus cerebelli, marked *n*; and is visible at the eleventh week of the fetal life.

The cerebellum, B, B,§ in Plates LV., LVI., LIX., LXIII., LXIV., LXVII., and LXVIII., is that portion of the brain situated beneath or basilad to the tentorium, *d*, resting on the two inferior depressions, *u*, *u*, of the occipital bone in Fig. 3 of Plate IV., and in Plate LXV., the same letters being employed, although the bone in the latter is invested with the dura mater. It is divided, like the cerebrum, into two hemispheres,‖ marked with the letters B, B, and by Malacarne, Reil, Bichat, and Gordon, subdivided into several lobes, lobules, and laminar leaflets; this subdivision, however, appears unnecessary, and has therefore been discarded. To enable the dissector to examine the cerebellum with any satisfaction, the whole brain must be removed from the calvarium. In Plates LV., LXIV., and LXVII., we observe distinctly two hemispheres, which are separated by the falx cerebelli, marked δ in Plate LXV; but in Plate LXIII. these are observed to be united, in consequence of the falx not extending so high up, or coronad, which bond of union has been fancifully named superior vermiform process;* the inferior vermiform process being a continuation of this to the base of the cerebellum. The outer or peripheral surface of the cerebellum has a number of furrows, or sulci, which run horizontally, and somewhat regularly, but not so deep as those of the cerebrum, dividing it into laminæ or plates; and hence we observe a difference between the outer surface, or convolutions of the cerebrum, and these plates of the cerebellum.

When a section is made between the two hemispheres, B, B, an elegant arborescent appearance presents itself, formed by the divarication of the medullary in the cineritious matter, which is named arbor vitæ; the root or concentration of which, marked *m* in Plate LXVIII., is considered the commissure of the cerebellum, and forms the roof of the fourth ventricle,† marked 4 in Plate LIX., which is fully displayed when the two hemispheres, B, B, are bisected, as in Plate LXVIII. The floor of the cavity is formed by the spinal cord, C, and the tuber annulare, the sides by the crura cerebelli, *n*, the anterior or glabellar margin by the valve of Vieussens, v, and the posterior or inial, or inio-sacral margin, by the valve of Tarin, *r*. These are seen partly in Plate LIX. and partly in Plate LXVIII. An expanse of the pia mater is described by authors as forming a tissue, like the choroid plexus in the lateral ventricles, and named choroides minor; but I have never witnessed any vascular plexus deserving this appellation. In Plate LIX., there is observed in this fourth ventricle, marked 4, a line extending longitudinally, which is named calamus scriptorius.

The fourth ventricle, between the fifth and sixth week of the fetus, is an open cavity, communicating freely with a long canal or tube, extending along the spine, and with the third ventricle, and is not roofed in until the eleventh week.

The valve of Tarin,‡ marked *r*, in Plate LIX., is a delicate medullary web, extending between the posterior part of the hemispheres, B, B, of the cerebellum, and the spinal cord, C, thus shutting up the fourth ventricle. This valve is perceptible at the seventh month of the fetal life.

---

* Syn. Velum cerebri medullare. Velum interjectum Halleri. Valvula cerebri. Great valve of the brain. La lame medullaire du cervelet. Valvula. Frenulum. Voile médullaire supérieur du Reil.

† Syn. Aquæductus Sylvii. Canalis medius. Iter ad quartum ventriculum.

‡ Syn. The pillars of the Vieussenian valve. Superior peduncle. Ascending portion of the limb of the cerebellum.

§ Syn. Parencephalis. Cerebrum posterius. Pars posterior cerebri. Le petit cerveau. Le cervelet.

‖ Syn. Globi cerebelli. Lobes du cervelet.

* Syn. Le ver supérieur du cervelet. L'eminence vermiforme. Ligne médiane et ondulée des lobules supérieures du cervelet. Vermis superior. Epiphysis scolecoeïdes.

† Syn. Le ventricule du cervelet. The central fissure of the cerebellum.

‡ Syn. Inferior medullary valve of Reil. Valvulæ semicirculares, inferiores et posteriores quarti ventriculi. Posterior medullary velum of the cerebellum.

The general medullary matter of the cerebellum appears produced from two processes or prolongations, named crura cerebelli * marked *n* in Plates LXVII. and LXVIII., which are large roundish medullary pillars, extending upwards from the tuber annulare, E, into the mass of the hemispheres, where they radiate to form the arbor vitæ, † as represented in Plates LIX. and LXVIII., and which are convex outwardly or peripherad, and slightly concave inwardly or centrad. In their ascent they form the sides of the fourth ventricle, marked 4, in Plates LIX. and LXVIII., and the commissure of the cerebellum, ‡ marked *m*, in Plate LXVIII. Their anterior, or glabello-coronal aspect, *l*, Plate LXVIII., and Fig. 2 of Plate LXVI., is termed processus cerebelli ad testes, § and their posterior or basilar aspect, marked *o*, in Plates LXVII. and LXVIII., and in Fig. 2 of Plate LXVI., which connects the medullary matter of the cerebellum with the spinal cord, is named processus cerebelli ad medullam oblongatam. ‖ The aspect between these, which looks outward or peripherad, and descends to, or ascends from the tuber annulare, or pons Varolii, E, is marked *n*, in Plate LXVII., and in Fig. 2 of Plate LXVI., and named processus ad pontem Varolii. ¶ In making a slightly oblique section of the crus cerebelli, near the part where it branches out in the hemispheres, we perceive an oval-shaped serrated mass, of a delicate yellowish-red colour, named corpus dentatum, ** represented in Fig. 3 of Plate LXVI., marked D.

In the fetus, between the fifth and sixth week after conception, the brain appears a sac, or pouch, with slight longitudinal and transverse depressions, presenting the appearance of several small vesicles agglomerated together; between the seventh and eighth week, the tentorium is seen separating the mass into cerebrum and cerebellum, and the latter consists of two thin narrow plates, which incline inward, and are applied to each other, but do not unite; at the ninth week, the processus cerebelli ad medullam oblongatam are found arising from the spinal cord (which consists of two portions), in the figure of two plates, bending forwards to meet each other, in order to form the cerebellum, the latter of which is very narrow and thin, ribboned, convex without and concave within; these two processes are not symmetrically applied to each other, the right advancing before the left.

At the eleventh week, the crura or peduncles of the cerebellum extend forwards and outwards, or coronad and laterad, with a slight curvature, and are united by a narrow junction at the mesial or median line, and the external surface of the cerebellum is convex, smooth, and without furrows; at the fourth month, or between fourteen and fifteen weeks, the cerebellum is broader in its transverse or lateral diameter, than in the perpendicular or mesial line, and where the processus cerebelli ad medullam oblongatam may be said to enter the cerebellum, a small round swelling is visible, which appears to be the origin of the corpus dentatum.

At the fifth month, the exterior surface presents the division into two hemispheres, each having four transverse lines or furrows, subdividing it into the five lobules of Reil, whose stems have no branches or ramifications, or divarications, as in the adult; at the sixth month, the transverse lines are very deep, and on making a perpendicular section, the ramification of the medullary matter is seen, as in the adult, and the processus cerebelli ad testes are fully developed; at the seventh month, the exterior surface presents a great number of transverse furrows, some of which penetrate more deeply than others; and when a perpendicular section is made, the stems, branches, and ramifications of Malacarne and Reil are observed, but not the leaves; at the eighth month, the cerebellum is nearly completed, the leaflets, however, are not so numerous as in adult life, and can be removed along with the pia mater, thus leaving the branches of the stems exposed; at the ninth month, the fissure separating the hemispheres is quite distinct, the furrows are very numerous, the deepest of which separate the lobes, the less deep the lobules, and the shallowest the leaflets or plates of Malacarne and Reil; the vermiform body, with all its divisions by these authors, as the short cross bands, the pyramid, the spigot, and the nodule, are developed; also the valve of Tarin, and the flocks, and the tonsils or almonds, of Malacarne and Reil.

I shall now proceed to the examination of the base of the brain; and to enable the dissector to examine this surface, the brain must be removed from the skull, by carefully dividing the various nerves, blood-vessels, and spinal cord, as they make their exit at the different foramina, having previously taken care to cut across on each side the tentorium cerebelli. Plates LXIV. and LXVII. represent the basis on which we observe the different convolutions of the cerebrum and lamellæ of the cerebellum, together with their divisions into hemispheres and lobes. The letters a indicate the anterior, *a* the middle, and **a** the posterior lobes of the cerebrum, the last of which are hid by the hemispheres, B, B, of the cerebellum, in Plate LXIV. In Plate LXVII., these two great divisions of the brain appear to unite at E, the tuber annulare, by four large prolongations, named crura, those of the cerebrum being marked g, and those of the cerebellum *n*. The crura cerebri,* g, g, are large round pillars of medullary matter, which ascend from the tuber annulare, E, and radiate into the substance of the hemispheres, as seen in Fig. 4 of Plate LXVI. The crura cerebri are recognisable about the seventh week of the fetus, in the form of two lengthened cords.

The tuber annulare, E,† Plate LXVII., and Fig. 2 of Plate LXVI., is that large round eminence, apparently formed by the union of the crura cerebri, g, g, and the crura cerebelli, *n*, *n*, marked with transverse lines, and has a slight sulcus running perpendicularly or mesiad.

The annular protuberance is observable at the fourth month of the fetus, being very narrow, and in the fifth

* Syn. Peduncles of the cerebellum. Racines du cervelet. Les bras du cervelet. Les jambes ou les petits cuisses du cervelet. Les petits branches de la moëlle alongée.

† Syn. Centrum medullare hemispheriorum cerebelli.

‡ Syn. Mons cerebelli.

§ Syn. Processus ad corpora quadrigemina. La portion ascendante des bras du cervelet. Le pédoncule supérieur du cervelet.

‖ Syn. Processus a cerebello ad medullam spinalem. Corpus restiforme. Le corps pyramidal postérieur. Colonne de la moëlle alongée. Portion descendante dos bras du cervelet. Prolongement du cervelet vers la moëlle alongée. Pyramides posterieures.

¶ Syn. Processus anterior.

** Syn. Corpus ciliare. Corpus rhomboideum. Corpus serratum. Le corps dentelé. Le corps festonné du cervelet. Le corps frangé. Zigzag. Ganglion du cervelet. Le noyau.

* Syn. Peduncles of the cerebrum. Processus medullæ cerebri.

† Syn. Pons Varolii. Protuberance annulaire ou semicirculaire. Ponticulus. Pons cerebelli. Protuberantia annularis Willisii. Protuberantia transversalis. Nodus encephali. Nodus cerebri. La grande réunion du cervelet. The cerebral protuberance.

month is clearly seen to be formed by medullary fibres, descending from the cerebellum, exterior to the processus cerebelli ad medullam oblongatam and winding round the spinal cord, where they unite.

Immediately anterior or glabellad to the tuber annulare, E, and between the crura cerebri, g, g, there is a small sulcus or aperture, which is named foramen cæcum anticum; and posterior or iniad and sacrad to the tuber, E, and between the corpora pyramidalia, G, G, is another sulcus or aperture named foramen cæcum posticum. Continuous with the tuber annulare, E, and the crura cerebri, g, g, et cerebelli, *n*, *n*, downwards or sacrad, is the spinal cord, which on this aspect is observed to consist of four bodies, the corpora pyramidalia, G, G, and the corpora olivaria, F, F, the whole being named the medulla oblongata.* The corpora pyramidalia, G, G,† are those oblong bundles of medullary matter, situate in the upper or atlantal region of the spinal cord, on its anterior or glabellar aspect, and which may be traced ascending within or centrad or corono-iniad of the tuber annulare, E, to join or become the crura cerebri, g, g.

The corpora pyramidalia are not distinguishable till the fourth month, although the spinal cord is much more early formed.

The corpora olivaria, F, F,‡ situate on the side of, or laterad to, the corpora pyramidalia, consist also of ascending medullary fibres. The corpora olivaria, although a component part of the spinal cord, which is very early formed in the fetus, are not fully developed until the seventh month. Between the corpora olivaria and rectiformia, are narrow white lines traced along the medulla oblongata, downwards between the anterior and posterior roots of the spinal nerves, named tractus respiratorii. I shall defer the examination of the spinal cord, until I have finished the description of the base of the brain.

Between the crura cerebri, g, g, the tuber annulare, E, and the tracts, 2*, 2*, of the optic nerves, 2, 2, are situated the two corpora mamillaria §, which are small round medullary eminences, that rest on the pituitary gland, and which form the commencements of the anterior pillars of the fornix. The corpora mamillaria appear as one large rude soft mass in the fetus of three months, and are not separated until the seventh month. Anterior or glabellad to the corpora mamillaria, *s*, *s*, the infundibulum, *i*, is situated, which has been described in page 133.

The nerves which originate from the brain are divided by some authors into nine, and by others into twelve pairs; the latter of which arrangements I have preferred, as being more explicit. These are the first pair, or olfactory nerves, marked with the digits 1, 1; the second pair, or optic nerves, 2, 2; the third pair, or motores oculorum, 3, 3; the fourth pair, or pathetic nerves, 4, 4; the fifth pair, or trigemini, 5, 5; the sixth pair, or abducentes, 6, 6; the seventh pair, or facial, 7, 7; the eighth pair, or auditory, 8, 8; the ninth pair, or glosso-pharyngeal, 9, 9; the tenth pair, or nervi vagi, 10, 10; the eleventh pair, or accessory nerves of Willis, 11, 11; and the twelfth pair, or lingual nerves, 12, 12.

The first pair, or olfactory nerves,* marked 1, 1, in Fig. 7 of Plate LXI., in Plates LXIV. and LXV., Fig. 5 of Plate LXVI., and Plate LXVII., are delicate pulpy medullary objects, rather of a cineritious colour, deriving their origin apparently from the anterior lobes, a, a, of the cerebrum, but which can be easily traced to arise from the medullary expanse of the corpora striata, which are hence named by Bichat, *couche du nerf ethmoidal*, and colliculus nervi ethmoidalis. In Plate LXVI., Fig. 5, the olfactory nerve of the left side is traced dividing into striæ, which are observed to come from the posterior or inial margin of the anterior lobe of the cerebrum, and to arise from the corpus striatum. As they proceed towards the cribriform lamella of the ethmoid bone, they form peculiar oblong turgescences, 1, 1, Plate LXIV., which immediately before their emergence out of the cranium, 1, 1, Plates LXV. and LXI., divide into numerous small delicate threads, varying from twelve to fourteen in number, that are distributed on the mucous membrane investing the turbinated portions of the ethmoid bone, and the mesial septum of the nares.

The olfactory nerves are not perceptible until the eleventh week of the fetus, and then they are very bulky, forming two little bands, which spring from the sylvian fissure, and end in a small round tubercle; they are hollow, their cavity being continuous with the anterior cornu of the lateral ventricle, which is observable even in the seventh month.

The second pair, or optic nerves,† marked with the digits 2, in Fig. 7 of Plate LXI., in Plates LXIV. and LXV., in Fig. 5 of Plate LXVI., and in Plate LXVII., are large round nerves, which are observed in the two last of these plates to twine round the crura cerebri, g, g, where they are termed optic tracts, and are marked 2*; and their origins may be traced to the thalami, F, F, and corpora quadrigemina, e, *e*, as represented in Fig. 5 of Plate LXVI. The optic nerve, or optic tract, 2*, is at first a flat medullary expanse, which in Fig. 5 of Plate LXVI., is observed to derive its origin partly from the thalamus, F, and partly from the corpora quadrigemina, e, *e*, and, after descending round the crus, g, of the cerebrum, becomes more condensed and cylindrical, unites with the opposite nerve, 2, and again separates, in order to emerge from the cranium at the optic foramen, as delineated in Plate LXV. The further course of this nerve will be traced in treating on the Organs of Sense.‡ We now observe the small elevation, which is named the corpus geniculatum externum, **f**, in Fig. 5 of Plate LXVI., considered by some the commencement of this nerve. The optic tracts are flat onwards nearly to their union, and it is still undecided, whether this junction be merely a bond of union, or a decussation. Tiedemann found the

* Syn. Bulbus medullaris.

† Syn. Les éminences medianes. Corpora pyramidalia anteriora. Les éminences medianes du bulbe rachidien. Les corps olivaires. Corpora pyramidalia antica. Les bandes medullaires.

‡ Syn. Corpora pyramidalia lateralia. Les corps pyramidaux. Corpora ovata. Corpus dentatum eminentiæ olivaris. Le ganglion ovale du grand renflement. Le ganglion olivaire.

§ Syn. Apophyses. Corpora albicantia. Corpora candicantia. Tubercules pisiformes. Eminences mamillaires. Tubercules mamillaires. Les bulbes ou oignons de la voute à trois piliers. Tubera candicantia. Eminentiæ candicantes. Les éminences blanches.

* Syn. Olfactilia. Olfaciendi organa. Carunculæ mamillares. Processus medullares. Processus mamillares cerebri ad nares. Ductus nervei a media cerebri magnitudine ad supremam narium partem. Par primum, sive olfactorium, sive nervi olfactorii. Nervus olfaciens. Nerf ethmoidal du olfactif.

† Syn. Prima nervorum a cerebro exorientium conjugatio. Nervus visivus seu visorius. Nervi optici sive secundæ conjugationis. Nerf oculaire ou optique.

‡ In Plate LXV. the ophthalmic artery, *o*, is observed accompanying the optic nerve, a point of consideration for the practitioner in Amaurosis.

nerves united in the third month of the fetus, and in the second month they were imperceptible; at the eleventh week they were bulky, and could be traced into the thalami and the corpora quadrigemina; at the sixth month, the optic nerve, when raised from the crus cerebri, elevated along with it the corpus geniculatum externum, in the form of a layer, and the nerve could be traced into the thalami and corpora quadrigemina.

The third pair, or motores oculorum,* marked 3, 3, in Fig. 7 of Plate LXI., and in Plates LXIV., and LXV., are moderately sized nerves, which are observed in the former of these to derive their origin from the crura cerebri, anterior to the margin of the tuber annulare, E. Each nerve, however, can be traced to arise by two origins, the one running coronad and iniad, or upwards and backwards, to the medullary matter of the cerebellum; the other ascending coronad and glabellad, or upwards and forwards, between the crura cerebri, and along the thalamus, anterior or glabellar to the posterior commissure, until it is lost in the peduncle of the pineal gland. The nerve descends from its external origin to the side of the sella turcica, where it enters the cavernous sinus, as observed in Plate LXV. to proceed out of the cranium, at the foramen lacerum anterius, to the muscles of the eye.

These nerves are perceptible in the third month of the fetus.

The fourth pair, or pathetici, † marked 4, in Fig. 7 of Plate LXI., and in Plates LXIV. and LXV., and in Fig. 2 of Plate LXVI., are small delicate nerves, which derive their origin from the valve of Vieussens, marked V, in Plate LIX., and are hence connected both with the testes and cerebellum; they descend around the crura cerebri to the folds of the tentorium, which they enter, as represented in Plate LXV., and advance onwards through the cavernous sinus, as will be delineated in treating on the Organs of Sense, to emerge at the foramen lacerum anterius, and to be expended on the superior oblique muscle of the eye.

This nerve is observable in the third month of the fetal life.

The fifth pair, or Trigemini,‡ marked 5, in Fig. 7 of Plate LXI., and in Plates LXIV. and LXV., large roundish-shaped nerves, appear to derive their origin from the side of the tuber annulare, E, but each may be traced in the tuber annulare, dividing into two portions, the one ascending to join the crura cerebelli, the other ascending to the floor of the fourth ventricle. This nerve descends from its apparent origin at the tuber annulare, to enter the cavernous sinus, beneath or basilad to the tentorium, where it divides into its three branches, as will be described in treating on the Organs of Sense. When the nerve is drawn forwards, there is a nervous cord lying behind it on the bone, which emerges along with the third branch.

This nerve is apparent in the fetus at three months.

The sixth pair, or abducentes, § marked 6, in Fig. 7 of Plate LXI., and in Plates LXIV. and LXV., rather small nerves, appear to derive their origin between the tuber annulare, E, and the medulla oblongata, F, F, G, G, but each nerve may be traced upwards through the medulla oblongata to the corpus restiforme, or processus cerebelli ad medullam oblongatam. The sixth pair descend from the surface of the brain, to pierce the dura mater, investing the basis of the cranium, between the sella turcica and the foramen magnum, as represented in Plate LXV. From this they advance onwards in the cavernous sinus to emerge at the foramen lacerum anterius, to supply the abductor muscles of the eyes. Their more minute description will be given under the Organs of Sense.

This pair is observable in the fetus at the third month.

The seventh pair, or facial nerves, * marked 7 in Fig. 7 of Plate LXI., and in Plates LXIV. and LXV., are small round nerves, which appear to derive their origin from the sides of the tuber annulare, E, but each nerve may be traced through the substance of the tuber annulare, towards the floor of the fourth ventricle, dividing into two portions, the one ascending towards the cerebrum, the other descending to the cerebellum. This nerve proceeds almost directly across, accompanied with the auditory nerve, to the meatus auditorius internus, as delineated in Plate LXV., the upper aperture of which it enters, and runs in the fallopian aqueduct, receiving a reflected twig from the vidian branch of the superior maxillary nerve, and giving origin to the chorda tympani, and twigs to the small muscles of the tympanum, as will be described under the Organs of Sense. The nerve emerges at the foramen stylo-mastoideum, and is described in page 52.

This nerve is observable in the third month of the fetus.

The eighth pair, or auditory nerves, † marked 8, in Fig. 7 of Plate LXI., and in Plates LXIV. and LXV., are large round soft nerves, which appear to arise from the sides of the tuber annulare, E, but may be traced running upwards around the root of the processus cerebelli ad medullam oblongatam to the floor of the fourth ventricle. The auditory proceeds from the tuber annulare, E, in company with the facial nerve, across to the meatus auditorius internns, as represented in Plate LXV., the lower aperture of which it enters, dividing into minute filaments, to supply the labyrinth of the internal ear, as will be described under the Organs of Sense.

This nerve is perceptible in the third month of the fetus.

The ninth pair, or glosso-pharyngeal nerves,‡ marked 9, in Fig. 7 of Plate LXI., and in Plates LXIV. and LXV., derive their origin from the medulla oblongata, laterad or exterior to the corpora olivaria, F, F, and proceed almost

---

* Syn. Second pair of Galen, Vesalius, &c. Tertiæ conjugationis nervi of Vieussens, &c. Nerf oculo-musculaire. Nerf oculo-musculaire commun. Nerf moteur commun des yeux ou de la troisième paire.

† Syn. Gracilior radix tertii paris of Vesalius. Par octavum of Fallopius. Nonum par of Columbus. Nervi quartæ conjugationis sive pathetici of Willis, &c. Nerf oculo-musculaire interne. Trochleares.

‡ Syn. Tertium par of Vesalius, &c. Nervi gustatorii sympathatici medii. Tri-facial. Paire mixte. Nervus trigeminus, seu divisus, seu mixtus.

§ Syn. Radix gracilior quinti paris of Vesalius. Quartum par of Fallopius. Par octavum of Gaspar Bauhinus. Oculo-musculaire externe. Nervus timidus. Nerve oculaire externe. Nerf abducteur de l'œil. Nerf moteur oculaire externe.

* Syn. Pars quinti paris of Vesalius, &c. Pars durior, vel potius nervus durus quinti paris of Fallopius. Ramus durior septimæ conjugationis. Communicans faciei. Portio dura of the seventh, the facial and auditory being formerly considered as one nerve.

† Syn. Pars mollier quinti paris of Vesalius, &c. Portion dure de la septieme paire ou du nerf auditif of Winslow, &c. Nervus auditorius sive acousticus. Nerf labyrintheque. Portio mollis of the seventh, the facial and auditory having been formerly reckoned as one nerve.

‡ Syn. Pars sexti paris of Vesalius, &c. Nervus anterior et minor sexti paris of Fallopius. Pars octavi paris. Par octavum. Petite portion ou première branche de la huitième paire. Pharyngo-glossien. Formerly part of the eighth, this, with the nervus vagus and accessory, having been considered one nerve.

directly across to the foramina lacera posteriora, as represented in Plate LXV., out of which they emerge, in company with the tenth, or nervi vagi, 10, 10, the accessory nerves, 11, 11, and the lateral sinuses, *z*, *z*. The further distribution of these nerves is described in page 51. The origin of this nerve may be traced to the fourth ventricle, and the posterior part of the cerebellum.

This nerve is observable in the third month of the fetus.

The tenth pair of nerves,* marked 10, in Fig. 7 of Plate LXI., and in Plates LXIV. and LXV., derive their apparent origin from the medulla oblongata, laterad or exterior to the corpora olivaria, F, F, and can be traced to the fourth ventricle, and the posterior part of the cerebellum. They proceed almost directly across to the foramina lacera posteriora, as represented in Plate LXV., out of which they emerge, in company with the ninth, or glosso pharyngeal nerves, 9, 9, the accessory nerves, 11, 11, and the lateral sinuses, *z*, *z*. The further distribution of this nerve is described in page 49.

This nerve is observable in the third month of the fetal life.

The eleventh pair of nerves, or the accessory nerve to the nervi vagi,† marked 11, in Fig. 7 of Plate LXI., and in Plates LXIV. and LXV., derive their origin from the posterior origins, or fasciculi, of the fourth, fifth, sixth, and seventh cervicle pairs, within the theca vertebralis, as delineated in Fig. 7 of Plate LXI., and in Plate LVI., ascend between the anterior and posterior fasciculi, enter the foramen magnum of the occipital bone, and proceed towards the nervi vagi, 10, 10, which they accompany out of the foramina lacera posteriora, as described in p. 51.

These nerves are perceptible at the third month of the fetal life.

The twelfth pair, or lingual nerves,‡ marked 12, in Fig. 7 of Plate LXI., and in Plates LXIV. and LXV., appear to derive their origin from the medulla oblongata, between the corpora pyramidalia, G, G, and olivaria, F, F, as represented in Plate LXIV.; but they can be traced into the medulla oblongata, dividing into two portions, the one ascending apparently to join the cerebrum, and the other descending to join the cerebellum.

Having finished the description of the nerves, I shall now proceed to that of the arteries of the brain. In page 46, the internal carotid artery,§ marked 19, in Plates XV. and XVI., is described to its entrance into the canalis carotideus (*t*, Fig. 2, Plate IV.) of the temporal bone; this artery is delineated in Plate LVI., in Fig. 7 of Plate LXI., and in Plates LXIV. and LXVIII.; in Plate LVI. it is merely represented ascending anterior, or sternad, to the bodies of the vertebræ, x; but in Plate LXVIII., the artery is observed to ascend anterior to the vertebræ, and opposite to E, to become tortuous in its course through the temporal bone, which has been removed to exhibit this peculiar tortuosity. This winding course of the artery is also represented in some of the plates illustrative of the Organs of Sense.

The internal carotid artery, after winding in its channel of the temporal bone, and by the side of the sella turcica of the sphenoid bone, where it is bathed in the blood of the cavernous sinus, and encircled by the threads of the sixth pair and vidian, which form the great sympathetic nerve, emerges beyond the dura mater into the cavity of the cranium, as delineated in Plate LXV.; and in this course gives origin to very small branches, which supply these nerves, and the third, fourth, and fifth pairs, which run in the cavernous sinus; also the dura mater in its vicinity, and the tunics of the carotid artery itself.

In Plate LXV., the internal carotid artery, 19, is observed after its entrance into the cranium, to give origin to a small branch, marked *o*, which is named the ophthalmic artery,* that emerges from the cranium at the optic foramen of the sphenoid bone, accompanied by the optic nerve, 2; and which, before its emergence, gives off a small twig, that proceeds towards the olfactory nerve, 1. The further distribution of the ophthalmic artery will be described under the Organs of Sense. The internal carotid, when minutely injected, is found, before its division into larger branches, to give origin to many small twigs or threads, which are ramified on the pituitary gland, the infundibulum, and the neighbouring parts.

The internal carotid artery, marked 19 in Plate LXIV., ascends between the anterior, a, and middle, *a*, lobes of the cerebrum, close to the optic nerve, 2, and after a short course divides into an anterior, v, a middle, *y*, and a retrograde branch, *t*. The last, or retrograde branch, *t*, named lateral communicant, is either sent off from the trunk, 19, before its division, as in this case, which, I may remark, is the general place of its origin, or it arises from the middle branch, *y*. This small branch, *t*, proceeds directly backwards or iniad, to unite with the posterior artery of the cerebrum, *r*, the ultimate division of the basilar artery, *q*; so that it may be said to be formed partly by each of these arteries.

The anterior branch, v,† proceeds forwards and upwards, or glabellad and coronad, between the anterior lobes, a, a, of the cerebrum, to the corpus callosum, *w*, (as delineated in Plates LVIII., LX., LXII., LXIII., and LXVIII., but by mistake is marked *u* in the last plate), along which this artery runs backwards or iniad, being gradually lost between the hemispheres, near the tentorium; and in this course, gives origin to numerous branches, the greater number of which supply the cerebral substance of the hemispheres, as illustrated by these plates. The first conspicuous branch sent off is marked *u* in Plate LXIV., which is observed to form a junction between the two anterior arteries, v, v, and is hence named the anterior communicans. When the basis of the brain is first exposed, this branch is obscured by the tunica arachnoides, the approximation of the anterior lobes, a, a, of the cerebrum, and by the optic nerves, 2, 2. There are frequently more than one branch forming a communication between the anterior arteries of the cerebrum. No other branches of this artery are described, as they are very irregular. In Plate LXIV. we observe

* Syn. Par sextum of Galen, &c. Quinta conjugatio. Septimum conjugium. Sextum par. Nonus nervus capitis. Par octavum sive par vagum. Moyen sympathique, paire vague ou huitième paire. Nervus vagus. Pneumo-gastrique. Nerf vocal.

† Syn. Nervus spinalis sive accessorius ad par vagum. Nerfs accessoires de la huitième paire. Spinal or accessory nerve of Willis. Nerf spino-cranio-trapézien. Nerf trachélo-dorsal.

‡ Syn. Par septimum of Galen, &c. Par octavum of Piccolhomini. Pars paris sexti of Casserius. Par decimum of Bartholinus. Par undecimum of Bidloo. Par nonum of Willis. Grand Hypoglosse ou de la neuvième paire of Winslow. Nerf lingual ou de la douzième paire of Vicq d'Azyr. Nervus hypo-glossus, vulgo nervus lingualis medius sive nonus, quamvis sit nervorum cerebri revera duodecimus of Soemmering. L'hyo-glossien of Chaussier.

§ Syn. Arteria carotis profunda. Arteria encephalica.

* Syn. Ocular artery.

† Arteria callosa. Arteria cerebri anterior.

several running on the surface of the two anterior lobes, a, a, some of which are dipping into the substance of the cerebral matter, while others are inosculating with twigs of the middle branches, *y*, *y*. In Plate LXVIII., which is a vertical section of the brain, the anterior artery, by mistake marked *u*, is seen ascending and running along the corpus callosum, *w*, giving origin in this course to numerous branches, which ascend between the convolutions to the coronal surface of the hemisphere; some of which run into the substance of the brain, and others inosculate with twigs of the posterior artery of the cerebrum, a branch of the basilar. In Plate LVI., several of the ultimate ramifications of this artery are seen, some of which terminate in the veins, while others anastomose with the small twigs of the middle artery of the cerebrum. In the different horizontal sections, represented by Plates LXI., LXII., and LXIII., we observe the numerous subdivisions of this artery, indicated chiefly by the red dots in the anterior aspect of the cerebrum.*

The middle branch† of the internal carotid artery, marked *y*, in Plates LXIV., LXIII., LX., LVIII., and LVI., ascends between the anterior, a, and middle, *a*, lobes of the cerebrum, or in the fissure of Sylvius, to the exterior, or coronal and lateral surface of the hemisphere, as represented in Plates LXIV. and LVI., where it inosculates with the twigs of the anterior and posterior arteries of the cerebrum; which inosculation is also delineated in Plate LVII. Before entering the fissure of Sylvius, this branch gives origin to twigs, which supply the crura cerebri, the base of the anterior and middle lobes, and the choroid plexus. In Plates LVIII., LX., and LXIII., is represented the manner in which the branches of this artery pierce the cerebral substance, and in comparing the two latter with Plate LXIV., it will be easily understood how this artery supplies the choroid plexus.

The two vertebral arteries, described in page 54, and represented in Plates IX. and XII., marked R, also in Plate LVI., in Fig. 7 of Plate LXI., in Plates LXIV., LXV., in Fig. 6 of Plate LXVI., and in Plate LXVIII. of the brain, ascend in the foramina of the transverse processes of the cervical vertebræ, anterior or sternal to the cervical nerves, 21, 22, 23, in Fig. 6 of Plate LXVI., and enter the cavity of the cranium at the foramen magnum, k, Plate LXV., and in Fig. 6 of Plate LXVI., having previously pierced the dura mater and tunica arachnoides. The course of these arteries through the foramina of the five inferior or sacral cervical vertebræ is nearly straight, while that through the two superior, or the dentata and atlas, is fully more tortuous, as delineated in Fig. 6 of Plate LXVI., than the course of the internal carotids, immediately before their entrance into the cranium. On entering the cavity of the cranium, the vertebral arteries, R, R, in Plate LXIV., run along the medulla oblongata, and unite near the tuber annulare, E, to form the basilar artery, marked *q*, which extends along the mesial line of this body, and at its anterior or glabellar margin, divides into the two posterior arteries, *r*, *r*, of the cerebrum.

* This profuse distribution of blood-vessels, and their extreme delicacy, should be considered by the practitioner in determination of blood to the head, and in many diseases. The quantity of blood sent to the brain, compared with that to the rest of the body, is calculated by Malpighi to be one-third, by Haller to be one-fifth, and by Munro secundus to be one-tenth.

† Syn. Arteria Sylviana. Arteria cerebri media.

These ultimate branches, *r*, *r*, ascend between the posterior lobes of the cerebrum and the hemispheres of the cerebellum, running on the former to the upper or coronal surface of the hemispheres of the cerebrum, where they unite with the ramifications of the middle and anterior arteries of the cerebrum, branches of the internal carotids. At their beginning, they give origin to the lateral communicants, marked *t*, which, as mentioned in page 139, unite with either the trunk of the internal carotid, 19, or with its middle branch, *y*. These lateral communicants, with the ultimate division of the basilar artery, the trunks of the internal carotid arteries, 19, 19, their anterior branches, v, v, and their anterior communicant, *u*, form what is named the circle of Willis, thus effecting a free inosculation between the internal carotids and vertebrals, and shewing that little danger is to be apprehended from securing one of these arteries in the living body; also that the ligaturing of the arteria innominata or of the subclavian artery on the tracheal margin of the scalenus anticus muscle, will fail in curing aneurism of the subclavian artery on the scapulary margin of the scalenus.* From either these lateral communicants, *t*, *t*, or from the commencements of the posterior arteries, *r*, *r*, of the cerebrum, small twigs are sent off to the corpora mamillaria, *s*, *s*, the infundibulum, *i*, the optic nerves, 2, 2, and the crura cerebri. As these posterior arteries ascend, they give origin to small branches, which supply the thalami, the corpora quadrigemina, the pineal gland, the choroid plexus, the fornix, and the third and lateral ventricles. These posterior arteries of the cerebrum are also seen in Plates LXII. and LXIII.

The vertebral arteries, in their course through the transverse processes of the vertebræ, give origin to small twigs, which enter the spinal canal, to supply the spinal cord and its tunics, as may be understood by examining Plate LV. and Fig. 1 of Plate LXIX. Other branches, comparatively larger, emerge between the vertebral spaces, to supply the muscles of the neck, and to inosculate with the deep cervical and occipital arteries, the branches forming the junction with the latter, being marked *e*, in Fig. 6 of Plate LXVI.: those which form these anastomoses proceed from the trunk of the artery between the dentata and the atlas, and between the latter and the occipital bone. The vertebral artery, in its course between the atlas and foramen magnum, and before it pierces the dura mater, gives origin to the posterior artery of the dura mater, named posterior meningeal, which ascends between the occipital bone and the dura mater that encompasses the cerebellum, to supply this membrane and the bone, as represented in Plate LXV.; and generally inosculates with the middle meningeal artery.

Shortly after the vertebral arteries have pierced the dura mater, and entered the foramen magnum, they give origin to branches, which are named from their course anterior and posterior spinal arteries. The two posterior † are described descending on the posterior aspect of the spinal cord, anastomosing in their course downwards or sacrad with the small medullary branches of the vertebral, cervicle, intercostal, and lumbar arteries, and also with the small branches of the anterior spinal arteries, to the cauda equina: but such a distribution is very seldom met with, as may be comprehended by examining Plate LV., and Fig. 1 of Plate LXIX., which were drawn from two

* See Lizars' Practical Surgery, Part I., page 113.

† Syn. Dorsal spinal arteries.

different subjects, one of which (Plate LV.) was most minutely injected, while the other (Plate LXIX., Fig. 1) was taken from a young subject, about three years old, uninjected. In Plate LV., these spinal arteries extend no length downwards or sacrad; and in Fig. 1 of Plate LXIX., there appears only one spinal artery descending and forming numerous inosculations with the medullary branches of the vertebral, cervical, dorsal, and lumbar arteries. These posterior spinal arteries frequently arise from the posterior or inferior cerebellar arteries.

The two anterior spinal arteries * are as small as the posterior, and derive their origin either from the vertebral arteries, or their junction the basilar; descend along the sternal aspect of the spinal cord for a short distance, and unite, continuing their course downwards or sacrad to the extremity of the cauda equina, and inosculating with the medullary branches of the vertebral, cervical, dorsal, lumbar, and sacro-lateral arteries, and also with the posterior spinal twigs. The same irregularity exists in the extent of these, as in the posterior spinal arteries, for soon after their junction they often terminate, by inosculating with some of the medullary branches of the vertebral or cervical; the remainder, or sacral portion of the spinal cord, being supplied by the medullary branches of the intercostal, lumbar, and sacral arteries. After their union, and when this extends for any distance, the anterior spinal are more tortuous than the posterior spinal arteries. The medullary branches of the vertebral, cervical, intercostal, lumbar, and sacral arteries, like all small arteries, are very irregular, as is satisfactorily exemplified in Plate LV., and Fig. 1 of Plate LXIX.

In Plate LXIV., small branches, marked *e*, are observed to arise, some from the vertebral arteries, and others from the basilar, which are named posterior or inferior cerebellar arteries; † those on the left side of the brain are two in number, while those on the right are three in number, the latter of which pursue the regular course around the medulla oblongata, G, F, upwards to the basilar surface of the cerebellum, B, B, and onwards even to its coronal aspect. In this course, they supply the corpora pyramidalia, G, G, the corpora olivaria, F, F, the lingual, 12, the accessory, 11, the pneumo-gastric, 10, the glosso-pharyngeal, 9, the auditory, 8, the facial, 7, and the abducentes, 6, pairs of nerves; also the fourth ventricle, where they sometimes form a plexus, similar to the choroid in the lateral ventricles. These inferior cerebellar arteries are also seen in Plate LXIII.

When the basilar artery, *q*, has advanced to the anterior or glabellar margin of the tuber annulare, E, it gives origin to the anterior or superior cerebellar arteries, marked *o*, *o*, Plate LXIV., which wind round the tuber annulare, E, ascending between the posterior lobes of the cerebrum, and the hemispheres of the cerebellum, B, B, on the crura cerebelli, to the anterior and superior, or the glabellar and coronal aspect of the cerebellum. In this course, these arteries send branches to the tuber annulare, E, the nerves in its vicinity, the crura cerebelli et cerebri, the velum interpositum of Haller, the pineal gland, the corpora quadrigemina, the valve of Vieussens, and the fourth ventricle. A small branch accompanies the facial and auditory nerves, to the meatus auditorius internus, to supply the internal organ of hearing, which is as frequently a direct branch from the basilar, as a subordinate one of the anterior cerebellar. In Plate LXIV., this artery, *o*, inosculates on the left side of the brain, with the posterior cerebellar artery, *e*, and the vertebral artery, R. The anterior cerebellar arteries are also seen in Plate LIX.

The other arteries which enter the cranium are distributed to the dura mater, and are named meningeal The chief one is the middle meningeal,* marked 5* in Plates LXV. and LVII., which derives its origin from the internal maxillary artery, as described in page 48, enters the cranium at the foramen spinosum of the sphenoid bone, and ascends between the dura mater † and the bones of the cranium, imprinting the sphenoid, temporal, and parietal, and supplying both these and the dura mater. Where the artery begins to imprint the parietal bone, which it does at its anterior inferior angle, or spinous process, it frequently forms for itself a complete canal or tube, from a line to a quarter of an inch in length. ‡ These meningeal arteries are accompanied by venæ comites, which emerge at the foramina spinosa, and terminate in the internal jugular veins; and are very conspicuous in the fetal and youthful head. The other meningeal arteries are small subordinate twigs of the internal maxillary, the occipital, and the ascending pharyngeal, which enter the cranium at the foramen ovale and foramen lacerum posterius.

The veins which return the blood from the brain concentrate and form what are named sinuses. The veins marked with the digits 1, on the surface of the hemispheres, terminate in the superior longitudinal sinus, marked *x*, § as delineated in Plates LV., LVI., LVII., LVIII., and LXVIII.; in Plates LVII. and LVIII., these veins are observed to run from behind forwards, or from the inial to the coronal aspect, by which the venous circulation is apparently rendered tardy in its course. The superior longitudinal sinus, *x*, begins about the crista galli of the ethmoid bone, as represented in Plates LVII., LVIII., and LXVIII., ascends in the middle or mesial line of the cranium, ‖ running backwards or iniad to the tentorium, where it divides, and forms the two lateral sinuses, marked *z*, in Plates LVI., LXIII., LXV., and LXVIII. In the posterior or inial region of the superior longitudinal sinus, small threads of fibres are found stretching across, which are named chordæ Willisii, or Willisianæ; and where the different veins terminate in

* Syn. Sternal spinal arteries.

† Syn. Arteriæ profundæ cerebelli.

* Syn. Meningeal artery.

† When the meningeal artery is wounded, either by a blow on the head, or during the operation of trepanning, it may be easily secured by a ligature passing a curved needle between the vessel and the dura mater.

‡ In injuries of the head, in consequence of the meningeal artery being imbedded in the bone, it is very liable to be ruptured, apparently from the coats of the vessel not being able to yield when the blood is violently agitated by the shock; and when the operator conceives that blood is extravasated here, the course of the artery in the spinous process of the parietal bone may be ascertained by dividing the space between the external angular process of the frontal bone, and the centre of the external auditory meatus, into two proportional parts, and raising a perpendicular from this central point. The artery will then be found to run centrad of, or underneath, this perpendicular line, for some extent, coronad or upwards.

§ Syn. First sinus.

‖ Since the superior longitudinal sinus or vein is strongly protected by the dura mater, as represented in Plate LVII. (for the veins supported by the dura mater possess the same tunics as other veins), the operator may apply the trephine in this region, without any risk of wounding the vessel, if he proceeds with caution. This sinus must be carefully guarded against, when operating for the removal of water, in either acute or chronic Hydrocephalus.

this sinus, there are elongations of the venous membrane with their free edges pointing forwards or glabellad into the cavity of the sinus, answering the purpose of valves. Similar fibres, threads, and membranous elongations, are observable in the lateral sinuses.

Each lateral sinus, *z*, Plate LXV.,* runs round in the folds of the tentorium, *d*, to the petrous ridge of the temporal bone,† where it descends downwards or basilad, running a circuitous course in its groove of the occipital, parietal, and temporal bones, as displayed in Plate IV., Fig. 3, marked *z*, *i*, *z*, to the foramen lacerum posterius, marked *w*, where it emerges out of the cranium, and becomes the internal jugular vein, the course of which is described in page 49.

In this course, the lateral sinuses receive several veins or sinuses; indirectly the inferior longitudinal sinus, G, Plate LVIII., which collects the blood from between the hemispheres, and from the surface of the corpus callosum, beginning at the anterior, or glabellar, or ethmoidal attachment of the falx cerebri, D, and extending backwards or iniad in its folds to the tentorium, *d*, Plate LXII., where it meets with the vena magna Galleni, i, that collects the blood of the lateral, fifth, and third ventricles, together with the choroid plexuses and velum interpositum Halleri.

The inferior longitudinal sinus, G, uniting with the vena magna Galeni, i, forms the fourth sinus,‡ marked IV, in Plates LXVIII., LXV., and LXII., which runs backwards or iniad in the folds of the tentorium, *d*, and terminates directly in the commencement of one of the lateral sinuses, which is almost invariably the left; sometimes, however, it ends in the superior longitudinal at its division into the two lateral sinuses; and the enlargement formed by this junction of the fourth with the left lateral, is named the torcular Herophili.§ Considerable irregularity or variety is found both in the inferior longitudinal and the fourth sinus. The lateral sinus throughout its course receives several small veins directly from the cerebrum and cerebellum, similar to those which join to form the superior longitudinal; and the same arrangement of small veins is observable with respect to all the sinuses. In Plate LVIII., several small veins are delineated, running in the folds of the falx cerebri, D, forming a communication between the superior, *x*, and the inferior longitudinal, G, sinuses, some of which are marked 2. Sometimes the one lateral sinus is larger than the other, and the right branches off the higher of the two, appearing to be the continuation of the superior longitudinal sinus; and Lieutaud mentions, that the left was deficient in one instance: again, in some cases, one of the lateral sinuses is the continuation of the fourth sinus, and has no connexion with the superior longitudinal, or the other lateral sinus, the latter of which is then very large; at other times, the occipital sinus has been found conveying the greater portion of the blood of the superior longitudinal, and extending around the foramen magnum to the foramina lacera posteriora, while the lateral sinuses have been found very diminutive. The lateral sinuses are observed to terminate sometimes in the external jugular veins.

The blood circulated by the ophthalmic arteries in the orbits, is returned into the cranium by the ophthalmic veins or sinuses, which enter at the foramina lacera anteriora, and terminate in the cavernous sinuses, one of the latter of which is marked C, in Plate LXV. The ophthalmic veins will be represented in illustrating the Organs of Sense; so also will the cavernous sinuses. In Plate LXV. of the brain, the cavernous sinus is shut up by the folds of the dura mater, which form its outer walls; when laid open, it is of an irregular triangular shape, extending from the pituitary gland to the spinous foramen of the sphenoid bone, and has a number of fibrous threads which traverse and give it a cellular appearance.

A very small vein runs round the termination of the infundibulum, *i*, at the pituitary gland, between the latter and the dura mater, and terminates in the cavernous sinus, which is named the sinus of Ridley,* and which frequently cannot be observed, from its minuteness.

Each cavernous, C, Plate LXV., ends in the superior petrosal sinus, *p*, which is observed to run along the petrosal ridge of the temporal bone, in the folds of the tentorium, *d*, and to end in the lateral sinus, *z*.

An inferior petrosal sinus, and an occipital sinus, are described by authors, but they are so irregular and small, that they appear not to deserve attention. The inferior petrosal, when present, extends along the angle formed between the squamous and petrous portions of the temporal bone to the lateral sinus.

An occipital sinus is found occasionally in the folds of the falx cerebelli, δ, ending in one of the lateral sinuses, at the torcular Herophili, which sinus is sometimes double. In Plate LXV., several small veins are delineated ascending between the dura mater and the occipital bone, and ending in the lateral sinuses, which are named by some authors the inferior lateral sinuses; sometimes similar veins are found on the cuneiform process of the occipital bone, and are named either petrous or lateral basilar sinuses, with a middle basilar sinus.

A small vein is occasionally found extending across the cuneiform process near the posterior clinoid processes, forming a junction with the preceding lateral basilar sinuses, and is termed the transverse or posterior clinoid sinus.

Two sphenoidal sinuses are also described; the one situated on the margin of the transverse spinous process of the sphenoid bone, named the superior, receiving blood from the orbit and dura mater, and emptying itself either into the ophthalmic or cavernous sinus; the other, the inferior, which is situated on the cerebral or interior surface of the temporal process of the sphenoid bone, empties itself also into the cavernous sinus. These different small sinuses are so irregular, that they need not be taken into consideration, still less committed to memory, by the pupil.

The vertebral sinuses begin near the foramen magnum, and generally inosculate with the occipital and lateral basilar sinuses, descend in the beginning or atlantal aspect

* Syn. First and second sinuses of the ancients.

† The superior longitudinal sinus, *x*, divides into the two lateral, precisely opposite the protuberance of the occipital bone, and the lateral sinuses imprint the internal aspect of the mastoid processes of the temporal bones, so that by means of these processes of the occipital and temporal bones, the operator can calculate the course of these sinuses, and hence avoid them when applying the trephine in these regions. Beneath or basilad to the petrosal ridges, the trephine cannot be easily applied In very rare instances, the superior longitudinal sinus has been found to divide at the beginning of the lambdoidal suture; but this deviation I have never witnessed.

‡ Syn. Synus quartus perpendicularis. The internal sinus. The straight sinus. The torcular Herophili.

§ Syn. Lenos Herophili. Pelvis. Laguncula. Palmentum. Tertia vena. Platea. Lacuna. Cisterna.

* Syn. Posterior clinoid sinus, or elliptic sinus.

of the tube between the theca vertebralis and the vertebræ, then in the foramina of the transverse processes of the cervicle vertebræ, and join the subclavian veins, as described in page 54, and delineated in Plate IX., collecting the veins from the spinal cord, and its membranes, in the region of the neck. The veins or sinuses which descend in the vertebral tube, between the theca vertebralis and the vertebræ, collect the blood from the spinal cord and its membranes, and form communications with the intercostal, lumbar, and sacral veins.

Besides these veins of the dura mater, and those of the brain, which empty themselves into the former, there are a number of small veins running through the various little foramina of the bones of the cranium, previously described, forming a communication between the sinuses and the exterior veins of the head; some of which run from without inwards, emptying themselves into the sinuses, while others emerge and join the exterior veins but do not commuicate with the sinuses; these are named the emissaria Santorini, or Venæ emissariæ.

I shall now describe the spinal cord.* This, which is represented in Plates LV., LVI., LIX., in Figs. 5, 6, 7 of Plate LXI., in Plate LXIV., in Fig. 1 of Plate LXVI., and in Plates LXVII. and LXVIII., marked c, is continuous with the cerebrum and cerebellum, and like them consists of cineritious and medullary matter. It is seen in Plate LV., and in Fig. 1 of Plate LXVI., letters c, to be a long cord of a roundish figure, encased in the spinal canal, and surrounded or protected by its membranes, the dura mater, d, the arachnoid membrane, *e*, and the vascular pia mater, the same as the cerebrum and cerebellum.

The spinal cord is considered by some to consist of four columns, two ascending to the cerebrum, and two descending from the cerebellum; by others, to consist only of two columns, the latter of which is substantiated by the indefatigable researches of Tiedemann, as will be shortly detailed. In the adult, the spinal cord, which appears to be a continuation of the cerebrum and the cerebellum, is larger at its commencement, where it is named the medulla oblongata,† marked G, G, F, F, in Plates LXIV. and LXVII., and tapers gradually in its descent to the second lumbar vertebra, where it ends by a conical point. In this extent, slight variations occur in its transverse diameter, as, for example, in the cervical portion, it is greater in the sacral than the atlantal extremes, which occurs also in the dorsal portion. Soemmering takes notice of a double swelling in this latter portion; but this is not always present. A narrow line of white matter is described by Sir C. Bell, extending between the corpus olivare and restiforme, downwards between the anterior and posterior origins of the spinal nerves, named *tractus respiratorius*. The cord has a fissure both on its anterior or sternal surface, and on its posterior or dorsal aspect, the latter of which is the more evident, as will be better understood from the fetal description. At this latter fissure, the pia mater entered, and the cineritious matter was deposited, the exterior of the spinal cord consisting of medullary matter, as represented in the sections displayed in Plate LIX., in Figs. 5 and 6 of Plate LXI., and in Plate LXIV. When the corpora pyramidalia, g, g, are held apart, as in Fig 6 of Plate LXI., there are observed extending across the anterior fissure, small transverse fibres, which have been hitherto considered a decussation of the medullary fibres of the corpora pyramidalia; but Tiedemann observes, that these fibres are scarcely sufficiently numerous to warrant the conclusion of a complete decussation of the chief cords of the spinal marrow; he witnessed, in the fourth month, some of the fibres proceeding from behind forwards from the right bundle to the left pyramid, and others from the left bundle to the right pyramid.

Throughout the extent of the spinal cord, the different spinal nerves derive their origin, and are variously arranged or divided by authors; by some, they are classed into eight cervical, twelve dorsal, five lumbar, and five sacral nerves, making in all thirty pairs, which is the most common arrangement; by others, the first cervical, which are also named the sub-occipital pair, are classed along with the cerebral nerves; a third arrangement is classing the glosso-pharyngeal, the nervi vagi, the lingual, and the accessory among the spinal nerves, making the cerebral only eight in number. Of these, the first and most ancient is as good as any other, all of them being arbitrary; and as the whole nerves are derived from the nervous centre, the brain and spinal cord, there appears less necessity for such divisions or classifications, which, on this very account, do not admit of a perspicuous arrangement. Thus we have seen so many nerves derive their sole origin from the cerebrum, others from the cerebellum, others again partly from the one organ, and partly from the other; hence it would be fastidious to class the nerves into cerebral, cerebellar, and cerebro-cerebellar. Again, the nerves apparently arising from the medulla oblongata, which is strictly a portion of the spinal cord, would require to be classed separately, and here the sixth pair interferes; so that the old arrangement into cerebral and spinal nerves, is probably as good and perspicuous as any other. In Plate LVI. the spinal nerves are observed to have double origins from the spinal cord, the one fasciculus arising from the anterior or sternal aspect of the cord, and the other from the posterior or dorsal aspect. The fibres of the latter converge towards one another, and form a ganglion in the investment of the dura mater. Those of the anterior root proceed to the same point and unite with the preceding immediately external to the ganglion. In Plate LV., and Fig. 1 of Plate LXVI., which are both posterior views, we observe the medullary substance of the cord terminating as it were in a leash of nerves, which is named the cauda equina.

The fetal developement of the spinal cord throws more light on its organization, than all the dissections of anatomists I formerly mentioned, that when the head and trunk of a fetus, between the fifth and sixth week, are examined, a canal or tube is found, containing a whitish and almost diaphanous fluid, the canal forming a rounded pouch in the head. At the seventh week, the spinal cord, bent like the spinal column, is very large and thick, compared to the size of the embryo, and particularly to that of the brain; it possesses the same thickness throughout its whole extent, has a pulpy white appearance, of the consistence of the white of an egg, and is marked on its posterior or dorsal aspect by a longitudinal groove into which the pia mater penetrates; the margins of this groove are very thin, and if separated by a flat needle, and held aside, the inner canal is continuous with the fourth ventricle, and extends to the end of the cord, like

* Syn. Le prolongement rachidien. Spinal marrow. Vertebral marrow.

† Syn. Principium medullæ spinalis. Pars cephalica medullæ spinalis. Le bulbe rachidien. Cranial portion of the cord.

that in the horse, and many other quadrupeds. The anterior or sternal surface of the cord consists of two strings or cords, separated by a slight longitudinal furrow.

At the upper or atlantal extremity, the cord, after bending forwards, forms on each side a considerable projection, corresponding to a tubercle at the nape of the fetus; and above, or coronad to this projection, the canal is dilated, where it is continuous with the fourth ventricle. The substance of the cord and brain, when examined at this period of life with a suitable magnifier, appears to possess no fibrous structure, but to consist of extremely minute globules. At eleven weeks, the spinal cord extends along the back to the region of the sacrum, where it terminates in a point without caudiform expansion; it appears a little thicker only at the origin of the nerves of the pectoral and pelvic members, but its bulk is much augmented at the upper or atlantal extremity, where it is continuous with the brain. The two sides of the spinal cord give origin to the spinal nerves, the bulk of which is very considerable.

The medulla oblongata is perceptibly thicker and broader, and inclines forwards, but the pyramidal and olivary eminences are not yet visible; its margins, or the restiform bodies, separate to form the fourth ventricle, while before and below, or glabellad and basilad, they are continuous with the crura cerebri, the annular protuberance not being yet formed.

At the fourth month, the pyramidal bodies appear in the form of two oblong eminences, but the lateral surfaces are plain and uniform, there being no appearance of the corpora olivaria. Fibrous or linear portions can now be detached from the surface of the cord, along its whole length, but none transversely. Each half of the cord at the medulla oblongata divides into three bundles, the posterior or restiform body, the middle, or that which subsequently forms the corpus olivare, and the anterior or pyramidal body, and which with the middle bundle is subsequently continued into the crus cerebri. The annular protuberance is now for the first time apparent, formed by medullary bands descending from the cerebellum.

At the fifth month, the spinal cord terminates at the sacrum, in a delicate filament, and the nerves arise distinctly by anterior and posterior roots. If a small blowpipe be inserted into the calamus scriptorius, with its point downwards or sacrad, the whole canal may be distended with air. Some of the fibres of the pyramidal bodies cross each other, and are continued forwards, above, or corono-iniad to the annular protuberance, to form the crura cerebri.

At the sixth month, the pyramidal bundles may be seen to cross at their inner edge, and proceed forwards, to traverse the annular protuberance, with the transverse fibres of which they are covered, and partly intermixed, and terminate in the crura cerebri. The olivary bodies, though broad, are still flat, and without the proper olive-shaped eminences; their component fibres do not mutually cross, but proceed forwards through the annular protuberance, and are then applied to the upper and outer part of the corpora pyramidalia, and contribute with them to form the crura cerebri: from these bundles, also fibres penetrate into the walls of the common mass of the corpora quadrigemina, some uniting with the corresponding ones of the opposite side, and others going forwards to the thalami.

At the seventh month, the spinal cord terminates in a point extending to the last lumbar vertebra, and in bulky nervous threads corresponding with the caudiform expansion. The capacity of the canal is diminished, and its walls are covered with a thin layer of unfibrous or cineritious substance, which adheres in patches to the folds of the pia mater destined to clothe the canal. Each of the olivary bundles now support an olivary oval-shaped body, consisting of non-fibrous or cineritious pulp, deposited on the surface of the cerebral fibres, which proceed forwards or coronad to the common mass of the corpora quadrigemina.

At the eighth month, the canal of the spinal cord still exists, although much contracted by a soft vascular matter deposited on its inner wall.

At the ninth month, the spinal cord extends near the third lumbar vertebra, where it forms a considerable caudiform expansion; its dorsal portion is a little larger in its transverse diameter, as well as in those portions which give origin to the brachial and crural nerves. The pia mater, extremely vascular, penetrates by the anterior and posterior fissures, the latter of which, or the canal, is now small and narrow, and its walls support a thick bed, of a soft reddish substance, the cineritious matter, throughout which is distributed a multiplicity of vascular ramifications, produced by the pia mater, and which substance is most abundant at the origin of the nerves.

I have now demonstrated the brain according to the method of Vesalius, which is most generally practised in the schools, and shall next proceed to the description of the mode ascribed to Willis, and the Grecian anatomists. This consists in raising the posterior lobes of the cerebrum from the cerebellum, when we arrive at the corpora quadrigemina and the pineal gland, and penetrate between the lower or basilar surface of the fornix, and the thalami, exposing at the same time the velum interpositum of Haller. We thus bring at once into view all the cavities, and if the arachnoid membrane and pia mater be removed, we observe their manner of communication. We perceive on each side of the fornix, which is now reflected forwards, the two lateral ventricles freely exposed, their roof formed by the corpus callosum and the contiguous medullary matter of the hemispheres, both of which are also reflected forwards. We perceive the septum lucidum, likewise reflected forwards and inverted, extending between the corpus callosum and the fornix, with the aperture which leads to its cavity, or the fifth ventricle, situated between the anterior crura of the fornix. We see, on the same level, the corpora striata, the tænia semicirculares, and the thalami, with the pineal gland a little below this level, the corpora quadrigemina still lower, and the valve of Vieussens beneath the latter bodies, and lastly the cerebellum, which rises to the level of the thalami. We observe between the thalami, the commissura mollis, with the foramen commune anterius immediately before or glabellad leading to the third ventricle and infundibulum, and glabellad to this foramen, the anterior crura of the fornix, with the anterior commissure extending across between the crura, but anterior or glabellad; posterior or iniad to the commissura mollis, we perceive the foramen commune posterius, with the pineal gland and its peduncles behind or iniad, and beneath or basilad to the latter, the posterior commissure, and still lower or basilad to the last, the iter à tertio ad quartum ventriculum, the roof of which channel is formed by this posterior commissure, the corpora quadrigemina and the valve of Vieussens. This method, therefore, enables us to comprehend the nature, extent, and communication of

the ventricles better than any other. I have not given a drawing of this mode, as it is extremely simple to understand, and easily displayed on the subject; it is probably more easily developed on the brain of the sheep than in that of man, in consequence of the smallness and shortness of the posterior lobes of the cerebrum. The reader may easily follow the above description, by comparing Plates LVI., LIX., LXI., LXII., LXIII., and LXVIII.

It now remains to describe the brain after the manner adopted by Varolius and Vieussens, and followed by Gall and Spurzheim, which is the most natural order; at the same time keeping in view the researches of Tiedemann concerning the early formation of the brain. The chief objection to the description of Varolius, Vieussens, and Gall and Spurzheim, is, their considering the cerebellum and cerebrum to be produced by the spinal cord, an idea satisfactorily confuted by Tiedemann, who found, in the embryo between the fifth and sixth week after conception, a canal or tube, occupying the head and spine, filled with a whitish and nearly diaphanous fluid, which swelled out in the form of a round pouch in the head. This whitish fluid became gradually firmer, until it assumed the appearance and character of cerebral matter; so that the nervous system, as early as it is discernible, consists of the brain and spinal cord, and hence we may begin its description at any point. The supposition that there are four columns constituting the spinal cord, the two anterior being the ascending, and the two posterior the descending, is quite hypothetical, for, according to Tiedemann's researches, no such division can be found in the early state, where an open fissure, continuous from the fourth ventricle to the caudi equina only presents itself.

I shall begin with the medullary fibres, G, G, of the corpora pyramidalia, in Fig. 4 of Plate LXVI., and in Plates LXVII. and LXVIII.; in Plates LXVI. and LXVIII., they are observed to ascend through the cineritious substance of the tuber annulare, E, forwards or glabellad through that forming the corpus niger, N,* diverging upwards or coronad in the crura, g, g, cerebri, radiating upwards and forwards, or coronad and glabellad, into the thalami, f, and into the corpora striata, G*, and lastly terminating in the hemispheres, A, A, Plate LXIX. The olivary bundles of medullary fibres partly join those of the corpora pyramidalia, to constitute the crura cerebri, and partly form the corpora quadrigemina, e, *e*. The medullary fibres of the processus cerebelli ad medullam oblongatam, *o*, or restiform bodies, Plate LXVII., and Fig. 2, Plate LXVI., ascend to form the cerebellum. Some of the fibres of the corpora pyramidalia descend to the corpora mamillaria. The preceding is the manner in which the medullary fibres are traced by Varolius, Vieussens, and Gall and Spurzheim, combined with the modification consequent on the discoveries of Tiedemann, the latter of which I shall now detail in a connected order, to confirm the above.

Under the description of the spinal cord, I traced the medullary fibres of the pyramidal bundles through the tuber annulare into the crura cerebri; but I shall retrace the description to the fetus at the seventh week. At this period, the crura cerebri are in the form of two lengthened cords, at the bottom of the aqueduct of Sylvius, which is very large and open. From the summit of the crura or cords, menbranous and inverted figures corresponding to the corpora quadrigemina, arise; anterior to which, two round protuberances, the thalami, are seen separated above by the aqueduct of Sylvius, but joined below or basilad, where they are supported or formed by the crura cerebri; still more anterior to these last, and joined or applied to them, two other eminences, the corpora striata, are observable; lastly, from each of these latter, a membranous production extends inwards and backwards, or centrad and iniad, to form the hemispheres of the cerebrum.

The spinal cord, immediately posterior or iniad to the crura cerebri and the corpora quadrigemina, gives off a thin narrow plate, which inclines inwards, but does not unite to form the cerebellum, as described in page 136. The dura mater at this period is found enveloping the brain and spinal cord, and dividing the cranial cavity into two equal parts, through the medium of the tentorium. The pia mater adheres intimately to the cerebral substance. At nine weeks, the corpora quadrigemina appear two oblong oval eminences, convex and smooth above, separated by a longitudinal furrow, and formed by two plates, mutually inclining towards each other, which issue from the crura cerebri. The thalami appear convex and smooth above, forming between them the third ventricle, which communicates freely and openly with the aqueduct of Sylvius, and the fourth ventricle. The corpora striata appear two distended bodies, from which the cerebral substance in the form of a thin membrane bends backwards and inwards, or iniad and centrad, to form the rudiments of the hemispheres.

At eleven weeks, the dura mater is seen to penetrate between the hemispheres, so as to form the falx cerebri; the tentorium is well marked: the longitudinal and lateral sinuses are formed; the pia mater of some thickness is observed forming the choroid plexus; and the restiform bodies at their anterior and inferior, or glabellar and basilar aspect, are seen to be continuous with the crura cerebri, which union is very distinct, in consequence of the annular protuberance not being yet formed.

On the upper or coronal aspect of the brain, are seen the cerebellum, the rudiments of the corpora quadrigemina, uncovered by the hemispheres of the cerebrum, which are very minute, and are separated by a deep fissure. On the inferior or basilar aspect, are seen the crura cerebri, anterior or glabellar to which a large mass, indicating the commencement of the mamillary eminences, the pituitary gland hollow and communicating with the third ventricle by the infundibulum, the union of the optic nerves, the olfactory nerves very short and ending in a bulbous enlargement, and the two hemispheres of the cerebrum, the middle and posterior lobes being mingled together.

The rudimental substance of the corpora quadrigemina is divided into two portions by a slight longitudinal furrow, which does not penetrate into the aqueduct of Sylvius, this being now shut up by the union of these bodies, and by the extension of the valve of Vieussens. The thin walls of the corpora quadrigemina inclose a spacious cavity continuous before with the third, and behind with the fourth ventricle.

The thalami now appear in the form of two oblong smooth convex massive eminences, which, when separated, expose the posterior commissure, and the third ventricle, onwards to the infundibulum. The anterior lobes of the cerebrum are now distinct, but the middle and posterior

* The corpus niger is merely a little cineritious matter, extremely vascular, the veins of which contribute to deepen the colour; and hence the term black.

resemble two appendages, placed before and on the sides of the crura cerebri; all of them are smooth on the surface, there being no appearance of furrows or convolutions. When the falx is removed, and the hemispheres held apart, the thalami and third ventricle are seen, the corpus callosum and fornix not yet being formed. Anterior or glabellad to the thalami, the hemispheres are joined by the origin or generative point of the corpus callosum; these resemble two membranous vesicles, about the fourth of a line thick, containing the choroid plexus of enormous bulk, and, when everted, they are seen to be formed by the fan-like expansion of the corpora striata, which bodies are now more fully developed. The membranous hemispheres, after bending backwards and inwards, to form the ventricles and cover the corpora striata, unite before the thalami to form the origin of the corpus callosum. Previous to this period, the membranous hemispheres are so little developed, that they do not cover the thalami, but after the eleventh week they become so large that they are gradually prolonged backwards or iniad, until they terminate by stretching over the corpora quadrigemina and the cerebellum.

From the corpora mamillaria, two narrow medullary stripes, the anterior pillars of the fornix, ascend before, or glabellad to the thalami, in a curved figure, upwards and backwards, or coronad and iniad, to these bodies, and join with their outer margins the membranous hemispheres, but remain apart on their inner or mesial margins, so as to leave a free communication between the lateral and third ventricles. The olfactory nerves are very bulky, and similar to the mamillary eminences of quadrupeds, are hollow, and communicate with the anterior cornu of the lateral ventricles. The optic and other nerves are visible.

At the fourth month, the pia mater, firm and traversed with numerous blood-vessels, covers the brain and spinal cord, and penetrates into the cavities. On the base of the brain, the annular protuberance is now apparent, but very narrow, and consisting of transverse fibres, which cover the spinal cord, and unite in the mesial line The olfactory nerves are seen to issue from the fissura Sylvii. The middle and posterior lobes of the cerebrum are now distinguishable by a slight furrow. The fifth pair of nerves are seen to derive their origin either from, or immediately before, the annular protuberance; the other nerves arising from their apparent external points of origin. The restiform bodies are seen to send fibres both to the cerebellum and the annular protuberance. The upper or coronal surface of the cerebrum has some furrows here and there. The thalami are now united by the posterior commissure, and the pineal gland small and flat with its peduncles are now apparent; so also is the anterior commissure.

The two anterior pillars of the fornix, after ascending near the corpus callosum, unite, and almost immediately again separate, and extend backwards or iniad in the figure of thin plates, which cover and surround the thalami, and descend to the base of the posterior lobes of the hemispheres, thus forming part of the body, the corpora fimbriata, and the posterior crura or pillars of the fornix. The Hippocampi are also observable at this period.

The medullary matter can now be distinctly traced. The medullary fibres of the medulla oblongata proceed above or corono-glabellad of the tuber annulare, give off ascending fibres to the corpora quadrigemina, mutually separate to the right and left, and penetrate into, or form the thalami; some fibres descending to the corpora mamillaria. The remaining fibres, which are very numerous, proceed under or basilad of the thalami, forwards and outwards, or glabellad and laterad, and radiate like the branches of a fan, into the striated bodies, and into the membrane of the hemispheres, upwards, forwards, outwards, and backwards. Some are reflected inwards, or mesiad, to form the roof of the lateral ventricles, and afterwards descend to join the fornix; those of the two sides uniting anteriorly or glabellad to form the corpus callosum.

At the fifth month, there are visible, on various points of the pia mater, thin transparent patches, which are the rudiments of the tunica arachnoides. Several deep furrows and convolutions are now apparent on the mesial or inner aspect of the hemispheres where they are applied to the falx cerebri, which convolutions make corresponding elevations or folds in the interior of the lateral ventricles; but no convolutions, furrows, or folds, are found on the outer or peripheral aspect. The septum lucidum is seen arising, by two very thin plates, from the anterior pillars of the fornix, to be attached to the corpus callosum, thus leaving a free communication between the fifth and third ventricles. The fornix is now united to the posterior or inial aspect of the corpus callosum, where its two portions also join each other. A deep fissure is observable between the corpus striatum and the thalamus.

At the sixth month, the falx cerebelli is observable, and the arachnoid membrane distinct. The posterior lobes of the cerebrum now cover the corpora quadrigemina, and almost the whole cerebellum, although in the preceding month, they do not entirely cover the corpora quadrigemina. The external or lateral walls of the lateral ventricles are considerably increased in thickness, much more so than the internal or mesial; the ventricles themselves are very spacious, of an oblong form, and elevated above, or coronad to, the corpus callosum; the three cornua are very distinct. The choroid plexus is very voluminous, and sends out vessels here and there over the cavities. The laminæ of the septum lucidum are joined so as to form the fifth ventricle, which has an aperture between the anterior crura of the fornix, near the foramen of Monro. The corpus callosum extends more backwards or iniad, but not yet sufficient to cover the thalami and third ventricle. The medullary substance forming the corpora quadrigemina is much thicker, thus rendering the iter à tertio ad quartum ventriculum considerably narrower. The optic tracts, when traced to the thalami, and the corpora quadrigemina, have now the corpus geniculatum externum, which can be raised along with the tract, in the form of a layer, from these bodies. On the basis, the tuber annulare is much broader, consisting of transverse fibres, descending from the cerebellum, and uniting on the mesial line, where the basilar artery makes a longitudinal furrow.

At the seventh month, the cerebrum is greatly increased in volume, the posterior lobes now covering and even extending beyond the cerebellum, and several furrows and convolutions are observable on the surface. The corpus callosum covers the thalami, and consists of transverse fibres passing from one hemisphere to the other; the fornix is now complete, the two sides being united by a thin plate or layer of medullary matter, which corresponds with that portion named lyra; the corpora quadrigemina are divided by a transverse line or furrow, rendering them complete and distinct, the two superior,

or nates, being a degree larger than the two inferior, or testes, and their parietes so thick, that the iter à tertio ad quartum ventriculum may be said to be perfect. The cerebral nerves are very large, compared to the mass of the brain.

At the eighth month, the brain is almost perfect in its organization, the furrows and convolutions are more numerous on the anterior and middle lobes of the cerebrum, than on the posterior. When the pia mater is detached from the outer or peripheral surface of the cerebrum, a layer of soft substance adheres to this membrane; and if this be removed by immersion in water, the pia mater presents a multiplicity of flocculent processes, which are very delicate blood-vessels, that penetrate the substance of the brain.

At the ninth month, the commissura mollis is formed, and the tænia semicircularis is a soft mass, traversed by blood-vessels, beneath which runs a large vessel, that when removed, detaches also the tænia.

With respect to the cineritious and medullary substances which compose the brain, it is impossible to distinguish between them in the fetus. All the parts of which the fetal brain consists are formed of a homogeneous reddish-white substance, the tinge of which depends on the numerous delicate blood-vessels that are distributed throughout its substance. In the corpora striata, the thalami, &c., the blood-vessels are found to be more voluminous and abundant. The outer layer, which in the adult is named cineritious, is softer in the fetus than the inner or medullary.

THE MUSCLES OF THE HEAD AND NECK.

In dissection, I would recommend it to the student to begin with the muscles of the face, as they spoil much more quickly than those of the neck. The latter, however, I shall describe first, as I intend next to advance to the muscles of the face, and then proceed to those of the organs of sense.

Several of the muscles of the back of the neck have been already described, so that only those on the anterior or sternal aspect of this part require to be detailed. The neck is divided into the following regions: the superficial cervical, the superior hyoid, the inferior hyoid, the lingual, the pharyngeal, the palatine, the laryngeal, and the deep cervical. When the skin is dissected off on the anterior and lateral aspects of the neck, a thin layer of condensed cellular membrane is exposed, which is here termed the superficial cervical fascia; this is continuous above with the adipose tissue of the face, and below with that of the anterior part of the thorax; and encases the platysma myoides muscles. On reflecting off the outer lamella, therefore, of this fascia, a delicate expanse of muscular fibres presents itself, as displayed in Plate XVIII., marked F, which is named the platysma myoides.* To display this muscle, an incision should be cautiously made through the outer layer of this fascia, parallel with the fibres of the muscle, from over the centre of the base of the inferior maxilla, to the middle of the clavicle, A, and the integuments reflected to each side. The muscle will then be observed to be attached nearly to the whole extent of the clavicle, A, and to the cellular web enveloping the pectoralis major and deltoid muscles; also to the base of the inferior maxilla and the cellular envelope of the parotid gland, S, and that of the masseter muscle, l, the anterior or glabellar fibres mingling with those of the depressor anguli oris, b. The attachment to the clavicle is considered the origin of this muscle. The function of this muscle is chiefly to corrugate the skin of the neck, with which it is intimately connected, and to assist the cutaneous venous circulation.† It also assists the depressor anguli oris in depressing the angle of the mouth and in drawing the skin of the cheek downwards; has some effect in depressing the head laterally, and the inferior maxilla downwards, or sternad; likewise in rotating the head on the vertebra dentata; and when the head is fixed, in elevating the skin and even the trunk. In physiognomy, this muscle assists in the expression of seriousness or gravity, and when violently thrown into action, in performing various grimaces.

Beneath the platysma myoides, a strong fascia, named the deep or proper cervical fascia, is found; this commences at the ligamentum nuchæ below the trapezii muscles, and extends forwards to the sterno-mastoid muscles which it encases, the one layer being superficial, the other centrad. At the anterior borders of these muscles, the two lamellæ of this fascia unite, and continue their course to the mesial line, where they unite. This fascia also invests the muscles in the superior and inferior hyoid regions. Superiorly, it adheres to the inferior border of the lower jaw-bone, its angle, and to the styloid process of the temporal bone; the fibres which extend between these two last points form the lateral ligament of the inferior maxillary bone, or the stylo-maxillary ligament. The fascia is likewise attached to the cartilage of the external auditory canal, to the mastoid process of the temporal bone, and ascending in front of the ear, superficial to the parotid gland, it is attached to the zygoma; here it is named the parotideal fascia. At the lower part of the neck, this fascia separates into two layers, the superficial, passing over the clavicle, becomes continuous with the pectoral aponeurosis, and also adheres to the sternum; the deep layer adheres to the central surface of the sternum and runs behind the clavicle, where it encases the subclavius muscle, and is ultimately attached to the cartilage of the first rib, and the coracoid process of the scapula.

A strong elegant muscle, named the sterno-cleido-mastoideus,* marked E, in Plate XVII., and situated beneath

* Syn. Est alterius lateris primus musculus, eorum qui buccas et labra movent. Musculus latus in collo positus: πλατυσμα μυῶδες. Quinti paris maxillæ. Musculus auriculæ et utrique labro communis. Musculus latus. Detrahens quadratus, communis buccarum labiorumque. Quadratus genæ, seu tetragonus. Quadratus genæ, vel latissimus colli. Platisma myodes. Le péaucier. Pars ex mala nascens, est risorius novus. Pars ad auriculam pertinens est portio musculi cutanei supra parotidem ad aurem adscendentis. Adducens ad anteriora. Sunt fibræ carneæ a musculo quadrata colli ad partem auriculæ inferiorem dilatæ. The common proceeding from the quadratus genæ. Musculus cutaneus. Le thoraco-facial. Thoraco-maxilli-facial.

† The platysma myoides is concerned in opening the external jugular vein, D, in Plate XVII.; in the securing of the common carotid artery; in the extirpation of diseased lymphatic glands of the neck; in the extirpation of diseased submaxillary gland; and in the various other surgical operations of the neck. The manner of performing the first of these operations is described in page 49 and the second at page 46. When the submaxillary or the lymphatic glands in this region are diseased, the platysma myoides so binds them down, that the magnitude of the tumour cannot be ascertained until the operation is begun, on which account the operator is frequently deceived: in all such cases, a free incision through this muscle is requisite, and the operator should dissect from the sterno-cleido-mastoideus muscle, towards the symphisis menti and trachea, keeping the edge of the scalpel to the tumour, and the back to the carotid artery and internal jugular vein.

* Syn. Musculi a pectoris osse et clavicula in caput inserti, pars ex pectoris osse pronata. Pars eadem septimi caput moventis. Eadem

the platysma myoides, F, extends obliquely along the side of the neck, derives a tendinous and fleshy origin from the upper or atlantal margin of the sternum, and the sternal third of the clavicle, A, and ascends with parallel muscular fibres, to be inserted tendinous in the mastoid process of the temporal bone, and in the ridge extending backwards or iniad, to meet the superior transverse ridge of the occipital bone. The origin of this muscle from the clavicle occasionally occupies more of this bone than the third; and the insertion is sometimes blended with that of the trapezius, 80.

The sterno-cleido-mastoideus inflects the head obliquely laterad, and forwards or sternad; when both muscles act, they inflect it directly forwards or sternad; and when this is the fixed point, they assist in approximating the trunk to the head.*

The inferior hyoid region embraces the sterno-hyoidei, the sterno-thyroidei, the thyro-hyoidei, and the omo-hyoidei muscles.

In the mesial line of the neck, beneath the integuments and the platysma-myoides, two slender muscles, having parallel fibres, are situated, which are named the sterno-hyoidei.† They are marked C, C, in Plate XVII., and Plate LXX. The sterno-hyoides derives its origin from the upper or atlantal margin of the first bone of the sternum, from a small portion of the clavicle and first rib in its contiguity, and ascends in conjunction with its fellow to be inserted in the inferior or sacral aspect of the body of the os hyoides, X. This muscle depresses the os hyoides to one side; and through the medium of this bone, by keeping it fixed, the sterno-hyoideus contributes to depress the inferior maxillary bone, thus assisting in opening the mouth, and in a similar manner assisting in deglutition. When the inferior maxillary bone and the os hyoides become the fixed points, the sterno-hyoideus aids in elevating the trunk towards the head.‡

The sterno-thyroidei, § B, in Plate XVI., and in Plate LXX., are situated immediately beneath, or centrad to the sterno-hyoidei; they therefore occupy the same region of the neck. This pair of muscles are broader and shorter than the sterno-hyoidei; they derive their origin from the atlantal margin of the first bone of the sternum, and from the first rib, ascend with parallel fleshy fibres, and are inserted into the lower or sacral margin of the thyroid cartilage. The sterno-thyroidei assist in depressing the larynx, and when only one muscle acts, it depresses the larynx laterally. They indirectly depress the inferior maxillary bone, and indirectly aid in deglutition.*

Continuous with the fibres of the sterno-thyroideus, there is a short muscle extending between the thyroid cartilage and the os hyoides, which appears to be a continuation of the sterno-thyroideus, and is named the thyro-hyoideus.† It derives its origin from the sacral margin of the thyroid cartilage, where the sterno-thyroideus is inserted, and ascends with parallel fibres to be inserted in the cornu of the os hyoides. The action of this muscle is to approximate the os hyoides and thyroid cartilage in the various motions of the larynx.‡

The omo hyoideus§ marked U, in Plate XVII., and in Plate XXXIII., situated in the lateral region of the neck, beneath or centrad of the sterno-cleido- mastoideus, E, and parallel for some extent with the sterno-hyoideus, C, is a delicate muscle, which derives its origin from the superior costa, and from the proper posterior ligament of the scapula. The slender muscular fibres ascend obliquely forwards, running beneath the trapezius, 80, the clavicle, A, and the sterno-cleido-mastoideus, E, until they advance to the middle of the sterno-hyoideus, C, to which they adhere, and ascend on its outer margin, to the body of the os hyoides, X, in which they are inserted.‖ Where the muscle passes beneath the sterno-cleido-mastoideus, it is tendinous from the friction at this part. The muscle is therefore digastric. The function of the omo-hyoideus is chiefly to operate on the larynx, depressing the os hyoides laterally and dorsad when one muscle acts, and directly sacrad when both muscles are in action. This muscle also assists indirectly in deglutition, and in depressing indirectly the inferior maxillary bone. When the os hyoides is a fixed point, this muscle assists in elevating the scapula atlantad and sternad.

The crico-thyroideus ¶ is a small arrangement of muscular fibres, represented in Plate XIV., and in Plate LXX., marked a, situated beneath the sterno-thyroideus, and, as its name indicates, extends between the cricoid and thyroid cartilages. The fibres derive their origin

septimi paris, eorum qui caput movent. Eadem mastoidei, seu mastoidæi. Eadem ejus, qui le sterno-mastoidien, ou mastoïdien exterieur ou anterieur. Cleido-mastoideus. Sterno-mastoideus. Sterno-cleido-mastoideus. Sterno-cleido-mastoidien. Sterno et cleido-mastoideus. Sterno-clavio-mastoïdien.

* The sterno-cleido-mastoideus is concerned in securing the arteria innominata (see page 46); in securing the common carotid artery (see page 46); in securing the subclavian artery (see page 55); in extirpating the thyroid gland; in the extraction of tumours in the region of the neck (see page 41); and in wry-neck this muscle is divided. Sometimes only a portion of the muscle is rigid, as, for example, the clavicular attachment, and then a division of it is made by cutting carefully the origin of the fibres from the clavicle, keeping close upon the bone, and in view the anterior external jugular and the subclavian veins. If the operator deems it necessary to divide the whole of the muscle, this may be also done at the origin. When this muscle has been divided, the chin or head-stay should be used to prevent a re-union of the muscle to the same extent as formerly. See Lizars' Practical Surgery, Part I., page 188.

† Ossi υ referenti propriorum alterius lateris primus. Primus hyoides. Primi paris hyoidis ossis. Primi paris ossi hyoidi, ad linguæ motum destinatorum. Secundi paris ossis hyoidis. Sterno-hyoidæus. Secundi paris, detrahentis, sterno-hyoidei. Sterno-hyoides. Le sterno-hyoïdien, ou sterno-cleido-hyoïdien.

‡ The sterno-hyoideus is concerned in performing laryngotomy and tracheotomy, in extirpation of the thyroid gland, in securing the common carotid artery near its commencement, and in securing the arteria innominata (see page 46).

§ Syn. Communium laryngis musculorum tertius et quartus. Primus communis laryngis. Secundi paris communium laryngis musculorum. Primi paris communium laryngis. Bronchius. Primi paris extendentium thyroidem, vulgo bronchii dicti, at nobis sterno-thyroidei. Sterno-thyroides. Le sterno-thyroïdien.

* The sterno-thyroidei are concerned in tracheotomy, in extirpation of the thyroid gland, in securing the common carotid artery near its commencement, and in securing the arteria innominata (see page 46).

† Syn. Communium laryngis primus et secundus. Secundus communium laryngis. Hyothyroïdeus. Hyothyroïdes. Hyo-thyroïdien.

‡ The thyro-hyoideus is concerned in laryngotomy.

§ Syn. Est septimus et octavus propriorum ossis υ referenti. Quartus hyoidis. Quarti paris hyoidis. Quarti paris, ossi hyoidi, ad linguæ motum distinatorum. Quarti paris ossis hyoidis. Coraco-hyoideus. Paris quarti, oblique deorsum trahentis, coraco-hyoidei appellati. Coraco-hyoides. Coraco, seu costo-hyoides. L'omoplat-hyoïdien, communément coraco-hyoïdien. Omo-hyoïdien. Scapulo-hyoïdien.

‖ The omo-hyoideus is concerned in securing the carotid artery (see page 46), and in securing the subclavian artery (see page 55).

¶ Syn. Quartus propriorum laryngis. Primus musculorum propriorum laryngis. Ex propriis laryngis musculus anterior exteriorque. Crico-thyroïdeus anticus. Crico-thyroïdes. Crico-thyreoïdeus. Dilatateur antérieur.

from the base of the cricoid cartilage, and run obliquely backwards, to be inserted in the sacral margin of the thyroid cartilage. The two muscles nearly meet anteriorly at their origin, and separate wider and wider in their progress backwards, towards the thyroid cartilage, leaving a triangular space where laryngotomy is performed.* This pair of muscles operate on these cartilages of the larynx, approximating the one to the other in the various motions of this organ.

I shall now proceed to the description of those muscles which extend between the inferior maxilla and the os hyoides, comprehended under the superior hyoid region.

Immediately beneath the integuments between the inferior maxilla and the os hyoides, two muscles are seen nearly uniting with each other; these are the anterior bellies of the digastric † muscles, and are marked *w*, in Plate XVII., and in Plate LXX. Each anterior belly, or head, *w*, is attached to the base of the inferior maxilla, 25, where it unites with the opposite muscle and is considered its insertion. From this point, the muscular fibres converging descend obliquely backwards, to the side of the body of the os hyoides, where they become tendinous, and adhere to that bone, or are bound to it by ligament; whence the fibres again ascend obliquely upwards and backwards, run generally through the delicate muscular fibres of the stylo-hyoideus, G, soon become fleshy, W, and proceed in their course to the rut in the temporal bone where they are attached, (see Plate V. Fig. 7, letter **b**) and covered by the sterno-cleido-mastoideus, E. ‡ This latter part of attachment is considered its origin, and from this to the os hyoides is named the posterior head, or belly. Sometimes fleshy fibres arise from the os hyoides and join the anterior tendinous ones. The digastric muscle depresses the inferior maxilla, and raises the larynx and pharynx in the action of deglutition.

The mylo-hyoideus § muscle, *m*, in Plates XVI., XVII., and LXX., situated beneath or centrad of the anterior belly, *w*, of the digastric muscle, may be considered as one muscle, as adopted by Chaussier, instead of a pair of muscles, as it is a broad fan-like arrangement of muscular fibres, descending from the inferior maxilla to the os hyoides. As a pair, each is described as deriving its origin from a ridge on the interior or central surface of the inferior maxilla (see Plate VI., Fig. 26, letter *p*), between the last dens molaris and the symphysis menti; the muscular fibres descend forwards in a converging manner, unite with those of the opposite side, and are inserted into the convex portion of the body of the os hyoides, x. ‖ The function of the mylo-hyoideus is to elevate the os hyoides in the action of deglutition, and to depress the inferior maxilla in opening the mouth.

* The crico-thyroidei are concerned in performing laryngotomy.

† Syn. Alterius lateris maxillam moventium quartus. Maxillæ inferioris quartus os aperiens. Quarti maxillæ paris. Alterius paris maxillæ deprimentis biventris. Paris digastrici, sive biventris. Digastricus seu biventer. Biventer maxillæ. Mastoïdo-génien. Mastoïdo-hygénien.

‡ The digastric muscle may become concerned in the extirpation of diseased lymphatic glands at the angle of the inferior maxilla. The operator should remember, that the branches of the external carotid artery, with the exception of the greater portion of the facial, are beneath or centrad to this muscle.

§ Syn. Secundi paris ossi υ referenti propriorum. Secundi paris hyoidis ossis. Secundi paris ossi hyoidi, ad linguæ motum destinatorum. Primi paris ossis hyoidis. Milo-hyoideus. Primi paris, recta attollentis, genio-hyoidei. Milo-hyoides. Le mylo-hyoïdien.

‖ The mylo-hyoideus muscle relates only to the removal of the inferior maxillary bone (see page 33)

When the mylo-hyoideus is carefully detached at its origin from the inferior maxillary bone, and reflected downwards to its insertion, a pair of short muscles are brought into view, the genio-hyoidei, * marked *l*, in Plate XV., and in Plate LXXI. They are so close together, that it requires some pains to separate them. They arise tendinous from a small ridge on the internal or central surface of the inferior maxillary bone, forming part of the symphysis menti (see Plate VI., Fig. 26, ridge between *n* and *m*, page 16), and descend to be inserted fleshy into the centre of the body of the os hyoides. The genio-hyoidei depress the inferior maxilla, so as to open the mouth, and elevate the larynx and pharynx in deglutition. †

Under the lingual region, come the genio-hyo-glossi, the hyo-glossi, the stylo-glossi, and the lingualis muscles.

When the genio-hyoidei are neatly insulated, and divided across, there appear a pair of muscles precisely similar, but which, on more minute inspection in the lateral aspect, are observed to radiate towards the tongue, and are therefore named genio-hyo-glossi. ‡ They are marked with the letters *k*, in Plate XV., and in Plates LXXI. and LXXII., Figs. 1. They derive their origin from two small elevations on the internal or central surface of the inferior maxillary bone, on each side of the symphysis menti (see Plate VI., Fig. 26, letters *n*, *n*), descend in a radiating form, to be inserted in the base of the os hyoides, and the tip, middle, and root of the tongue; the latter bundle of fibres intermingling with those of the stylo-glossus and lingualis muscles. The function of this muscle, from the radiation of its fibres, is very varied and extensive; it pushes the tongue to the palate, and out of the mouth, retracts it, moves it from side to side, draws the tip downwards in the mouth, and renders its dorsum convex or concave. The fibres extending to the os hyoides depress the inferior maxilla, or elevate the larynx and pharynx in deglutition. §

Before proceeding with the other muscles of the tongue, the three styloid muscles should be examined; indeed, it would have been preferable to display the stylo-hyoideus immediately after the digastric, as it obstructs, in some degree, the student in examining the mylo-hyoideus. The stylo-hyoideus ‖ muscle, G, in Plate LXX., accompanies the posterior head, W, of the digastric muscle, by which it is often perforated, and, as its name indicates, it extends between the styloid process and the os hyoides. It derives a tendinous and fleshy origin from the middle and inferior part of the styloid process of the temporal bone, soon becomes fleshy, and descends to be inserted in the side of the os hyoides. The precise origin of this muscle is better seen in Plate LXXI. Near its insertion, it is generally pierced with the posterior head, W, of the digastric muscle. The function of the stylo-hyoideus is to elevate the os hyoides, and through it the larynx and pharynx, in deglutition. ¶

* Syn. Quinti paris hyoidis ossis. Quinti paris ossi hyoidi, ad linguæ motum destinatorum. Le genio-hyoïdien.

† The genio-hyoideus is concerned in removal of the inferior maxillary bone (see page 33).

‡ Syn. Nonus linguæ. Quartus linguæ. Quintus linguæ. Primum par linguæ. Genio-glossus.

§ The genio-hyo-glossus is concerned in extirpation of the tongue, and in removal of the inferior maxillary bone.

‖ Syn. Tertii paris ossi υ referenti propriorum. Stylo-ceratoïdes. Stylo-cerato-hyoideus. Stylo-hyoïdes major.

¶ In operating at the angle of the jaw-bone, the surgeon should be aware that the stylo-hyoideus muscle lies superficially to the branches

A small slender slip is sometimes found descending to the cornu of the os hyoides, which, when present, is named stylo-hyoideus alter.

A delicate ligamentous slip, *s*, generally extends from the styloid process, *q*, of the temporal bone, to the angle, *d*, of the inferior maxillary bone, as represented in Plate LXX. This ligamentous slip commonly arises in conjunction with the stylo-hyoideus, G, from the styloid process, and is considered part of the deep cervical fascia. Another ligamentous slip, still more delicate, frequently extends from the styloid process to the cornu of the os hyoides.

When the posterior belly of the digastric muscle, and the stylo-hyoideus, are removed, the other two styloid muscles are brought into view, viz. the stylo-glossus, m, and the stylo-pharyngeus, k, both of which are delineated in Plates XVI. and LXXI. The styo-glossus muscle,* m, the situation of which is indicated by its name, derives a tendinous and fleshy origin from the styloid process, *q*, and the ligamentous slip, *s*, extending to the inferior maxillary bone, and descends obliquely forwards to the root of the tongue, where its fleshy fibres spread, extending onwards along the side nearly to the apex or tip, blending or intermingling with the fibres of the lingualis and the genio-hyo-glossus muscles. The function of the stylo-glossus muscle is to pull the tongue upwards, laterally, and backwards, or coronad, laterad, and iniad; by this means approximating the root of the tongue to the fauces, so as to diminish the isthmus faucium, and therefore concerned in deglutition. By pulling the root of the tongue upwards and backwards, it overhangs the glottis, and prevents the bolus of food getting into the larynx. When one muscle acts, it moves the tongue dextrad or sinistrad. They must also have the power of pushing the tongue upwards and forwards towards the roof of the mouth, as is exemplified in other muscles of the tongue, viz. the genio-hyo-glossi; and must, therefore, be concerned in speech.†

The situation of the stylo-pharyngeus,‡ k, is indicated by its name. This muscle derives a fleshy origin from the styloid process of the temporal bone, and descends obliquely downwards; its fibres blend with those of the inferior constrictor of the pharynx, and some are capable of being traced downwards to the thyroid cartilage. The function of this muscle is to dilate or compress the pharynx, and to elevate both it and the larynx, upwards and backwards in deglutition.

When these styloid muscles have been removed, the deeper seated muscles of the tongue may be examined. The hyo-glossus§ muscle, marked *i*, in Plates XV. and XVI., and in Plate LXX., derives its fleshy origin from the cornu of the os hyoides, x, and ascends with a broad arrangement of parallel fibres, to the side of the root of the tongue, where they intermingle with those of the genio-hyo-glossus, the stylo-glossus, and the lingualis muscles. The function of this muscle is to elevate or depress the root of the tongue, and also to expand its breadth, wherefore it is concerned in speech and deglutition

The lingualis muscle,* marked 60 in Plate XV., is partly obscured by the insertions of the hyo-glossus, *i*, and the genio-hyo-glossus, *k*, muscles, between which some of the fibres of the lingualis are seen. It arises by scattered fibres from the side of the root of the tongue, advances onwards more or less blended with the fibres of the stylo-glossus muscle, and is lost in scattered fibres at the apex or tip of the tongue. The function of this muscle is to direct the tongue upwards, downwards, laterally, forwards, and backwards; hence it is employed in speech and deglutition.

Besides the fibres of the lingualis, there are a number of muscular fibres distributed throughout the tongue, as will be represented in sections of that organ. These are arranged longitudinally,† transversely,‡ and perpendicularly,§ and multiply the motions of the tongue to a great extent. In their individual strata they contract or relax that portion of the tongue wherein they are situated.

In a regular order of dissection, the muscles of the pharynx should follow those of the tongue, and embrace the pharyngeal region, as the stylo-pharyngeus, and the three constrictors. There are three constrictor muscles described by the majority of authors, but these are in reality but one. They are delineated in Plates LXX. and LXXI., the inferior being marked Y, the middle, F, and the superior, *y*. The inferior is only separated from the medius, and the medius from the superior, at their origins, all of them being blended in their course and insertions. The constrictor pharyngis inferior, Y,‖ derives a fleshy origin from the sides of the cricoid and thyroid cartilages; the inferior fibres proceed directly across, and the superior obliquely upwards around the mucous bag of the pharynx, where they unite with the muscular fibres of the opposite side, forming a delicate white line.¶ The constrictor pharyngis medius,** F, derives a fleshy origin

---

of the external carotid artery, with the exception of the continuation of the facial branch.

* Syn. Quintus et sextus linguæ musculorum. Tertii paris linguæ musculorum. Tertii paris propriorum linguæ. Secundi paris linguæ. Sexti paris, oblique trahentis, stylo-glossi.

† The stylo-glossus is only concerned in extirpation of the tongue, when cancerous.

‡ Syn. Quarti paris linguæ, quod et faucibus adscribi potest. Tertii paris faucium, stylo-pharyngei. Stylo-pharyngæus.

§ Syn. Pars tertii et quarti linguæ musculorum. Secundum par linguæ. Tertium par linguæ musculorum. Basio-glossus. Quintum par deprimens, sive cerato-glossus. Cerato-glossus, Basio-glossus et Chondro-glossus. Hio-glossus. Hyo-glossi. Hio-chondro-glossi.

* Syn. Les fibres longitudinales. † Syn. Fibræ longitudinales.

‡ Syn. Fibræ transversales. § Syn. Fibræ perpendiculares.

‖ Syn. Thyro-pharyngeus et crico-pharyngeus. Pars œsophagæi seu sphincteris gulæ. Thyro et crico-pharyngien. Le constricteur inférieur du pharynx. Portion du stylo-pharyngien. Crico-thyro-pharyngien.

¶ Where the inferior constrictor, Y, surrounds the œsophagus, or joins the œsophagus, I, there is a diminution of the calibre or a constriction of the continued tube of the pharynx and œsophagus, which is best understood by inserting the finger from the pharynx into the œsophagus. This constriction is the point where foreign bodies, when swallowed, are arrested in their progress to the stomach. In such an event, forceps of different shapes should be first employed, and if ineffectual, an incision ought to be made on that side of the neck where the body projects most (if one side is not more prominent than another, the right should be preferred), parallel with the tracheal margin of the sterno-cleido-mastoideus, through the integuments and platysma myoides muscle, avoiding the external and the internal jugular veins, the common carotid artery, and the nervus vagus. The knife should be ateralized with the edge towards the larynx and trachea. The important vessels should be held aside to the dorsal aspect, when the prominent object will appear, which should then be liberated by a careful incision through the constrictor muscle and mucous membrane of the pharynx. The external wound is to be approximated by stitches. The patient to be kept extremely quiet, on low diet, nothing but milk or water for some days, which should be introduced into the stomach by an elastic tube. See Lizars' Practical Surgery, Part II., page 154.

** Syn. Hyo-pharyngeus. Pars œsophagæi seu sphyncteris gulæ. Hyo-pharyngien. Le constricteur moyen du pharynx. Portion du stylo-pharyngien. Hyo-glosso-basi-pharyngien

from the cornu of the os hyoides, x, and from the root of the tongue, and the fibres proceed obliquely upwards, uniting, as they advance, with those of the opposite side, to be inserted into the cuneiform process of the occipital bone, anterior or glabellad to the foramen magnum. The constrictor pharyngis superior,* *y*, arises from the inferior and superior maxillary bones, near the dentes sapientiæ; between these from the root of the tongue, the palate, and the buccinator muscle; from the pterygoid muscles, particularly the internal; and from the cuneiform process of the occipital bone, near the anterior condyloid foramina. The fibres proceed almost directly across, to unite with those of the opposite side. The points of origin of the superior constrictor are more delicate than those of either the medius or inferior, the superior is overlapped by the medius, while the medius in its turn is overlapped by the inferior constrictor; and the three muscles constitute the chief strength of the bag of the pharynx. This pouch, as delineated in Plates LXX., LXXI., LXXII., LXXIII., and LXXIV., Figs. 1, is a muscular and mucous membranous sac, extending from the basis of the skull, or the cuneiform process of the occipital bone, to the œsophagus, I, or to the sacral margin of the cricoid cartilage, N; and bounded posteriorly or dorsad by the cervical vertebræ, and anteriorly or glabellad by the posterior apertures of the nares, T, T, Plates LXXII., LXXIII., and LXXIV., Figs. 1, the velum pendulum palati, F, Plates LXXII., LXXIII., and LXXIV., Figs. 1, the arches of the fauces, 1, 2, the root of the tongue, G, the epiglottis, Q, Plates LXXII., LXXIII., and LXXIV., and the arytenoid, the thyroid, and cricoid cartilages.

The pharynx is widest behind the nares, which portion is named the arch; it then contracts a little on each side, and again expands behind the epiglottis, which latter portion is termed the body; and lastly it contracts, where it terminates in or becomes the œsophagus, which portion is styled the sphincter. At the arch, or immediately behind the posterior apertures of the nares, the Eustachian tubes terminate, as delineated in Fig. 2 of Plate LXXIV., letter z; and in this neighbourhood there are several longitudinal rugæ. There are also rugæ behind the larynx.

Besides the mucous and muscular structures, the muscular is surrounded by a cellular expanse, which is troublesome to dissect off, in order to display the former.

I shall here continue the description of the pharynx, although it would probably be more systematic to describe it along with the organs of mastication, deglutition, and digestion. In Plate LXXI., and Fig. 1 of Plate LXXIV., the pharynx is seen lined with a soft mucous membrane, marked b, resembling velvet, which is a continuation of that of the nares and mouth; and in Plates LXXII. and LXXIII., this membrane is observed to be studded with a multiplicity of small glands of the conglobate kind, named pharyngeal. These glands secrete the greater portion of the mucous fluid, which lubricates this surface in deglutition and respiration. The termination of the capillary arteries here is into secreting points, which contribute also to supply the mucous fluid.

After the investigation of the pharynx and its muscles, the dissector should proceed to the muscles of the soft palate; but the muscles attached to the inferior maxillary bone require to be previously examined, and, as formerly mentioned, those of the face should precede the latter. Keeping this natural order in view, I shall proceed to the muscles of the velum pendulum palati, previously describing the velum itself. This curtain,* marked F, in Figs. 1 of Plates LXXII., LXXIII., and LXXIV., consisting of a number of muscles and glands, invested with a mucous membrane, hangs elegantly down in the back part of the mouth, from the posterior or inial free margin of the palate bones (see Plate IV., Fig. 2, digits 22), and terminates in a central pendulous point, named the uvula, or pap of the throat, which is marked *f*, and which forms the central apex, or junction, of four arches,† marked with the digits 1, 2, or what is named in architecture, the central point of a groined arch; their lower extremities resting on, or arising from the root of the tongue, and the sides of the body of the pharynx. The digits 1 indicate the two anterior, which arise from the root of the tongue; and the digits 2 the posterior arches of the fauces, which arise from the sides of the body of the pharynx. The space bounded by these arches and the uvula is named the fauces. The glandular object, situated on each side between two of these arches, marked 3, is termed the tonsil, amygdala, or almond. This glandular tissue has a number of lacunæ opening towards the fauces, as represented in Fig. 1. of Plate LXXIV., is of a reddish colour, and has some resemblance to the exterior of the shell of the almond, and is classed under the conglobate glands. The mucous glands of the velum are distinctly represented in Fig. 1 of Plate LXXIII. Both these and the amygdale secrete mucus, to lubricate these surfaces in deglutition and speech.‡

* Syn. Milo-pharyngæus, glosso-pharyngæus, pterygo-pharyngæus. Mylo-glosse glosso-pharingien, pterygo-pharyngien, génio-pharyngien. Pars œsophagæi seu sphincteris gulæ. Le constricteur supérieur du pharynx. Portion du stylo-pharyngien. Ptérigo-syndesmo-staphili-pharyngien.

* Syn. Valvula palati. † Syn. Columnæ septi palati.

‡ The amygdalæ, or tonsils, are subject to inflammation, which, when it assumes the phlegmonous type, constitutes cynanche tonsillaris, being circumscribed, of a deep red or purple colour, and greatly swollen The tumefaction is sometimes so great, that when both tonsils are inflamed, they approximate and prevent deglutition, chiefly, however, by impelling the action of the muscles. The treatment is to scarify the tonsils with a bistoury, to apply the vapour of water through the medium of a tube, or what is termed a *douche*, to the tonsils; leeches to the neck, poultices round the exterior of the throat. Brisk cathartics should be given, the feet immersed in hot water twice or thrice a-day, and low diet with rest enjoined. Blisters are often found very efficacious after leeches; and whenever suppuration appears established, the tonsil should be incised, carrying the instrument from the side of the throat to the mesial line. See Lizars' Practical Surgery, Part II., page 117.

The tonsils and velum are equally subject to erysipelatous inflammation, in which case there is little or no tumefaction, but only a rose-coloured inflammation, with one or more whitish-coloured ulcers, resembling aphthæ more than ulceration. The ulceration, however, is generally deep and extensive, occurring in patches. This affection is much more liable to spread downwards to the larynx, than the former, or phlegmonous, and is then indicated by acute pain in swallowing, with a sort of convulsive action. The patient seems horrified when the saliva or any thing induces him to swallow. The submucous cellular tissue is infiltrated with lymph or serum, constituting œdema glottidis, and proving suddenly fatal. I have known patients fall victims to this affection, before the practitioner appeared in the least degree aware of the danger; and on dissection, I have found the cellular tissue round and between the sterno-hyoideus, sterno-thyroideus, and other muscles in contiguity, infiltrated with purulent matter; and the glottis, the epiglottis, the tonsils, and the velum, with lymph or serum. The treatment requires to be much more active than in the preceding, tracheotomy becoming indispensable. This erysipelatous affection is what occurs in scarlatina, and is then named cynanche maligna. The inflammation sometimes ends in mortification. Cynanche pharyngæa is characterised by nearly the same symptoms, requires active treatment, and is seldom

The muscles operating on the velum palati, constituting the palatine region, are the constrictor isthmi faucium, the palato-pharyngeus, circumflexus or tensor palati, and the levator palati, of each side, with the azygos uvulæ in the centre.

The constrictor isthmi faucium,* marked with the digit 1, in Fig. 1 of Plate LXXIII., is situated at the back part of the mouth, forming the chief portion of the anterior arch of the fauces, deriving its origin from the side of the root of the tongue, and ascending with delicate fibres, which are lost in the velum palati, near the uvula. This delicate muscle is covered by the mucous membrane of the mouth and velum, and its carneous fibres are distinctly seen through this membrane, indeed fully more distinctly than when removed. The use of this muscle is to contract the fauces in deglutition, by bringing the velum to the tongue, and elevating the tongue to the former. †

The circumflexus palati, ‡ marked a, in Fig. 1 of Plates LXXII. and LXXIII., situated at the posterior aperture of the nares, and base of the cranium, extending along the mesial aspect of the internal pterygoid muscle, arises by delicate scattered fibres from the spinous process of the sphenoid bone, and around the cartilaginous portion of the Eustachian tube, descends obliquely outwards, along the mesial aspect of the internal pterygoid muscle, n, and runs round the unciform process, *l*, of the sphenoid bone, in the form of an elegant round tendon, which expands in a broad tendinous web, forming the chief strength of the velum palati; the tendon of the one muscle uniting with that of the other, and with some of the other muscles of the velum, as the palato-pharyngeus. The function of this muscle is to stretch the velum, and to elevate it towards the posterior apertures of the nares, so as to prevent solids or fluids ascending in the act of deglutition. §

The levator palati || muscle, marked L, in Figs. 1 of Plates LXXII. and LXXIII., situated at the back part, or inial aspect of the velum palati, immediately below or sacrad to the circumflexus palati, is a much bolder muscle than the circumflexus, and separated from it by a small quantity of soft adipose substance; it derives its origin from the exterior of the osseous and cartilaginous portions of the Eustachian tube, and descends obliquely forwards to the velum, where its fleshy fibres spread so as to unite with those of the opposite side, and some of the other muscles implanted in the velum. The function of this muscle is to elevate the velum upwards and backwards, so as to shut up the posterior apertures of the nares in deglutition.*

In the centre of the uvula, a small round muscle, named azygos uvulæ† is situated, and which is displayed by making a perpendicular incision from the longitudinal palatine suture to the apex of the uvula, either on the anterior or posterior aspect of the velum. This muscle, marked *u*, in Fig. 1 of Plate LXXIII., derives its origin from the small projecting point formed by the junction of the palatine plates of the palate bones, and descends perpendicularly along the velum and uvula to the apex or tip of the latter. This muscle assists the circumflexus and levator in elevating the velum and uvula, so as to shut up the posterior apertures of the nares in deglutition.‡

The palato-pharyngeus muscle,§ marked D, in Fig. 1 of Plate LXXII., situated in the side of the palate and pharynx, requires to have the fibres of the superior constrictor of the pharynx, *y*, removed, in order to bring it into view, and is then observed to consist of muscular fibres extending between the velum palati and the pharynx, which neither arise nor terminate at any definite point. It forms the posterior arch of the fauces. The origin of this muscle is blended with the tendinous expanse of the circumflexus palati, and the fibres in their descent mingle with those of the stylo-pharyngeus, k, some of them being ultimately inserted in the thyroid cartilage. The function of the palato-pharyngeus is to contract the aperture of the fauces, so as to propel the bolus of food backwards and downwards in deglutition; in doing which it assists in elevating the pharynx and larynx. ||

---

an idiopathic affection, but supervenes one of the preceding. The tonsils are very subject to be attacked with ulceration in secondary syphilis. They are also occasionally attacked with chronic inflammation and induration, which tumefies them to so considerable a magnitude, as to impair the voice and deglutition, and to require removal by the knife. The mouth of the patient is to be held open, when the operator grasps the enlarged tonsil with a vulsellum; with this instrument he is enabled to pull forwards the tonsil with his left hand, and to excise the tonsil with a probe-pointed bistoury. See Lizars' Practical Surgery, Part II., page 120.

* Syn. Glosso-staphylinus. Glosso-staphylinus seu glosso-palatinus. Palato-glossus.

† This muscle is concerned in the operation of staphyloraphy, or velu-synthesis.

‡ Syn. Primum par musculorum qui faucibus dilatandis aut constringendis inserviunt. Pterystaphilinus externus. Pterygo-staphilinus externus. Pterigo-palatinus, seu spheno-pterigo-palatinus, seu pterigo-staphylinus. Palato salpingæus. Pterigo-palatinus. Spheno-salpingo-staphylin. Le péristaphylin externe ou inférieur. Pterygo-staphylin. Tensor palati.

§ The circumflexus palati muscle is concerned in velu-synthesis, or staphyloraphy.

|| Syn. Secundum par musculorum, qui faucibus dilatandis aut constringendis inserviunt. Pterystaphylinus internus. Par internum gargareonis. Pterygo-staphylinus internus. Sphæno-palatinus. Salpingo-staphylinus. Columellæ musculos, in triangularem expansionem deorsum productus, seu spheno-palatinus. Levator palati mollis. Petro-salpingo-staphylin, ou salpingo-staphylin interne. Petro-staphylin.

* The levator palati muscle is concerned in staphyloraphy, or velu-synthesis.

† Columellæ musculus teres, seu azygos uvulæ. Palato-staphylinus. Staphylins ou êpistaphylins moyens. Releveur de la luette.

‡ The azygos uvulæ muscle is concerned in velu-synthesis, or staphyloraphy.

§ Syn. Pharyngo-staphylinus. Staphylino-pharyngæus. Thyreo-staphylinus. Pars œsophagæi. Pharyngo-staphylin; peristaphyli-pharyngien. Le pharyngo-staphylin ou palato-pharyngien. Portion du stylo-pharyngien.

|| The palato-pharyngeus muscle is concerned in velu-synthesis, or staphyloraphy. This operation, which was first performed on my friend, Dr. Stephenson, Professor of Surgery, Montreal, Canada, consists in rendering raw the edges of the cleft velum palati, and approximating them by means of the interrupted suture. It is performed on those born with the malformation of the velum, consisting of two symmetrical halves, being as it were separated into two, by a perpendicular incision from the posterior or inial point of the longitudinal palatine suture, through the centre of the uvula. Sometimes the one half of the uvula is a little larger than the other. The way to perform this operation, is to seat the patient on a chair opposite a good light, to pass a ligature of four threads through the one tip of the uvula, by means of a curved needle-shaped instrument, to the other tip of the uvula, and this ligature should be so portioned as that a noose commanding each half of the velum may be held out of the mouth, to facilitate the future steps of the operation. The operator should now lay hold of the one-half of the ligature that commands the one side of the velum with the left hand, and stretch it gently; then with the right hand, having Wenzell's or Ware's eye-knife, pare the margin of the velum from the point where it is attached to the palate bones down to the uvula, a step of the opera-

These little muscles perform various other functions, which will be better understood when we come to deglutition and speech.

Before proceeding to the examination of the muscles of the larynx, it is necessary to describe the objects which it forms.

The larynx is an assemblage of cartilages at the top or beginning of the trachea, opening into the pharynx immediately posterior or iniad to the root of the tongue, and is the commencement of the windpipe; it is held in this situation by several ligaments and muscles, which have been already described, and is lined with a continuation of the same mucous membrane which invested the pharynx. Five cartilages enter into its formation, of which the thyroid and cricoid are the largest, and constitute chiefly the parietes.

The thyroid cartilage, marked S, in Plates XV. and XVI., and in Plate LXXII., Fig. 1, and Plate LXXIII., Figs. 1 and 2, situated on the anterior aspect of the neck, about the superior or atlantal third, is of an angular shape, the angle pointing forwards, or glabello-sternad; and the two flat sides, named alæ, pointing laterad, and terminating in long free edges, which look backwards, or dorsad, and end in oblong points named cornua. When insulated, it has some resemblance to the old-fashioned cocked hat. Its superior or atlantal margin is arched on each ala, having a depression, or notch, between the alæ, representing a cordiform appearance, and is terminated at the free posterior edge of each ala, by a small elongated point, which is named the superior cornu, to distinguish it from another cornu at the inferior margin, which is shorter than the preceding. The two superior are marked *s*, *s*, in Figs. 1 and 2 of Plate LXXIII., and the two inferior cornua, s, s. The posterior free edge, extending between these cornua, is smooth, and nearly straight, as exemplified in these figures. The inferior or sacral margin is slightly concave at each ala. On the convex or lateral aspect of each ala, an irregular oblique ridge extends between the superior and inferior edges, made by the attachments of the crico-thyroideus, the thyro-hyoideus, and constrictor pharyngis inferior muscles. The superior margin of the thyroid cartilage is connected to the os hyoides, x, by a membranous expanse extending between them, named the thyro-hyoid membrane, marked *r*, in Fig. 2 of Plate LXXIII., which at *e* is round, stronger, and somewhat ligamentous, and proceeds from the superior cornu, *s*, to the cornu, *x*, of the os hyoides, and is termed the thyro-hyoid ligament. This round ligament has generally a small cartilaginous body, either near the superior cornu of the thyroid cartilage, or near the cornu of the os hyoides. This ligament is also stronger and flatter, where it extends between the notch of the thyroid cartilage and the body of the os hyoides. Stronger and shorter ligaments extend between the inferior cornua, s, s, to the cricoid cartilage, N, termed the crico-thyroid ligaments; here synovial membranes surround the articulations, and a strong membranous expanse proceeds from the inferior margin of the thyroid cartilage to the cricoid cartilage, particularly in the centre or mesial aspect, which is named the crico-thyroid membrane. On the inner aspect of each of the inferior cornua, is a small articular facet. Besides these attachments, the thyroid cartilage is connected to the arytenoid cartilages, *c*, *c*, by the vocal ligaments, *a*, *a*. The thyroid cartilage becomes ossified in advanced life.

The cricoid cartilage, marked N, in Plate XV., and in Fig. 1 of Plate LXXII., and in Figs. 1 and 2 of Plate LXXIII., situated immediately beneath or sacrad to the thyroid cartilage, and atlantad to the first ring of the trachea, K, is of a circular or annular shape, as its name indicates, and is much broader posteriorly than anteriorly. The anterior aspect is thick, convex, and narrow; and on each side extending obliquely upwards, there is a conspicuous tubercle, which affords rest and attachment to the inferior cornu of the thyroid cartilage. The posterior aspect, which is very deep, has a distinct line, marked N, in Fig. 2 of Plate LXXIII., extending perpendicularly, with a slightly flattened or concave surface on each side. The lower or sacral margin, which rests on the first cartilaginous ring of the trachea, is arched like the sacral margin of the thyroid cartilage, and is connected by a circular ligament. The upper or atlantal margin is very oblique and slightly arched, and immediately superior to each slightly flattened surface, is a gently convex smooth articular surface, for the articulation of the arytenoid cartilage, *c*.*

---

tion which is excessively difficult and troublesome, from the involuntary actions of the patient to swallow, vomit, and cough. The same is now to be done on the other side, and when the operator is satisfied that the edges are sufficiently raw to ensure adhesion, he brings the halves of the uvula together by means of the long ligature, which he ties, but does not yet cut off the loose ends, for by means of them he is so enabled to keep the velum on stretch, as to pass the other ligatures with much more facility. Other two ligatures are required, and may generally be passed, by transfixing the velum on the one side from before backwards, and on the opposite side from behind forwards, which saves pain and time. These ligatures being tied, and the operator satisfied that every point is in contact, he may cut off the loose ends of the ligatures, see his patient to bed, and enjoin absolute quiescence in eating, drinking, speaking, or even swallowing the saliva; for upon this depends the chance of success. On the third day after the operation, the stitches should be withdrawn, and the starvation enjoined for two days longer. During the evening of the day of the operation, and the succeeding five days, the patient must be nourished solely with injections made of beef-tea, milk, and gruel. I performed this operation on a young gentleman about eighteen years of age, and succeeded in uniting the edges, with the exception of about a quarter of an inch of the top near the hard palate. This want of union or aperture, however, is now closed, a circumstance which generally occurs after this operation. See Lizars' Practical Surgery, Part II., page 115.

* In Plate XV. there is an oblong square space between the thyroid and cricoid cartilages, which is filled up with a thick and strong ligamentous membrane, in which space laryngotomy is performed. This point can be easily ascertained in the living state, from the projection of the anterior angle of the thyroid, and the firm rotundity of the cricoid cartilages. A longitudinal incision should be made in the mesial line of the neck over this part, through the skin and cellular tissue, so as to bring into view the contiguous margins of the cartilages, when the operator should then plunge a scalpel at this ligamento-membranous space, and instantly after, a laryngotomy tube.

Laryngotomy, sometimes named tracheotomy, is performed in cases of foreign bodies getting into the larynx or trachea; and in cases of foreign bodies entering the œsophagus, threatening instant suffocation, and incapable of being dislodged.

Tracheotomy, which is an opening made into the trachea, is not so simple an operation as the preceding. A longitudinal incision is made in the mesial line of the trachea, through the skin and cellular tissue, when the operator should feel if there be any artery pulsating, as the arteria innominata, and even the right carotid artery, may come in the way of the knife. He must then proceed, cautiously avoiding the isthmus of the thyroid gland, and plunge the scalpel through the rings of the trachea, with its back towards the sternum. This latter operation has been performed in cynanche laryngea and cynanche trachealis, and also for the same diseases as those for which laryngotomy has. Whenever laryngotomy promises to answer, it ought to be preferred. Tracheotomy ought to be performed in cynanche laryngea, whenever the practitioner conceives that the inflammatory action has become

The arytenoid cartilages, *c*, *c*, in Figs. 1 and 2 of Plate LXXIII., and Fig. 1 of Plate LXXIV., are two small pyramidal, or triangular cartilages, situated with their bases on the upper margin of the cricoid cartilage, and having their apex pointing upwards or atlantad. Their posterior or dorsal surfaces are concave; their anterior convex; their external or lateral, oblique and convex; and their inner or mesial surfaces are nearly straight, being only a little concave. Their apices are sometimes so loose as to appear appendages, and in some instances distinct cartilaginous appendages are found. Their bases, which rest on the cricoid cartilage, are gently concave smooth articular surfaces, and are surrounded by a synovial membrane and fibrous bands, the articulation admitting of motion in every direction. In Fig. 2 of Plate LXXIII., on the right side, the capsular ligament is cut open to show the articulation, which is marked *f*. The arytenoid are connected to the thyroid cartilage, S, by the two vocal ligaments, *a*, *a*, or thyro-arytenoid ligaments, which extend from the bases of their anterior or glabello-sternal convex margins, to the angular fossa, on the posterior or dorsal aspect of the thyroid cartilage, where these cords meet or touch each other. The arytenoid cartilages are also connected to the epiglottis, Q, by delicate broad ligamentous membranes, marked *b*, in Fig. 2 of Plate LXXIII., extending between the apices of the arytenoid and the root and sides of the epiglottis, which are named the lateral ligaments of the epiglottis.

The space between these cords, or the entrance into the windpipe, is named the glottis. Immediately above, or atlantad to these two ligaments, *a*, *a*, are two small pouches, or sacculi, or recesses, marked v, in Fig. 2 of Plate LXXIII., named the ventricles of the larynx, which are formed of the mucous membrane of the larynx. Two ligaments are situated immediately above or atlantad to these ventricles, and extend between the arytenoid and the thyroid cartilages, from the centre of the convex anterior margin of the arytenoid, immediately above or atlantad to the vocal chord, and are attached to the angular fossa on the posterior or dorsal aspect of the thyroid cartilage, also immediately above or atlantad to the vocal chords; so that the fissures or ventricles are between these ligaments and the vocal chords.

The epiglottis, Q, in Plate LXXI., in Fig. 1 of Plates LXXII., LXXIII., and LXXIV., situated at the root of the tongue, which it very much resembles in appearance, is a small cartilaginous body, attached to the upper margin of the thyroid cartilage and the os hyoides, through the medium of ligaments, but more so to the former than the latter. In Fig. 2 of Plate LXXIII., the epiglottis, Q, is partially bent backwards and downwards, which brings into view a small ligament, marked *d*, extending between its base and the body of the os hyoides, x: the base is also connected to the notch of the upper margin of the thyroid cartilage, so that a triangular space is left between these two ligaments, the epiglottis, and that extending between the os hyoides and the notch of the thyroid cartilage, which is filled up with ligamentous substance. The lateral ligaments of the epiglottis, marked *b*, in Fig. 2 of Plate LXXIII., extend between the sides of the epiglottis and the tips of the arytenoid cartilages. Other membranous ligaments extend upwards from the sides of the epiglottis, to the sides of the fauces, as represented in Fig. 1 of Plate LXXII.

The os hyoides, x, in Plate XV., and in Plates LXX., LXXI., LXXII., Fig. 1., and LXXIII., Fig. 2, situated horizontally at the root of the tongue, is a slender round bone, of the shape of the Greek υ, from which it has got its name, and consists of a body and two cornua. All the views, excepting that in Fig. 2 of Plate LXXIII., are representations of the outer convex aspect of the bone, and give a more natural appearance than this. In this, however, which is an internal or central view, we perceive the body of the bone, x, and the two cornua, *x*, *x*; and extending outwards from the body, x, we observe two little projections, named appendices.* The body is much thicker and stronger than the rest of the bone, is convex outwardly, or peripherad, having a delicate perpendicular ridge in the centre, and concave inwardly or centrad, and until mature age it is not joined to the cornua by cartilage. There are several small elevations and depressions made by the muscles, already described, and therefore unnecessary to be particularized at present. The cornua extend laterad and iniad or dorsad, and end in small round points, or tubercles, from which moveable cartilages project, to meet the superior cornua of the thyroid cartilage.

I shall now proceed to the investigation of the muscles of the larynx, of which there are several.

The crico-arytænoideus posticus,† *m*, Fig. 1, Plate LXXIII., situated on the posterior aspect of the cricoid cartilage, as its name indicates, derives its origin from the flattened surface of the cricoid cartilage, N, as represented in Fig. 2, ascends with oblique fibres, to be inserted in the posterior aspect of the root of the arytenoid cartilages, *c*. The function of this muscle is to inflect directly backward the arytenoid cartilage, and through it, to render tense the vocal chord.

The crico-arytænoideus lateralis,‡ *p*, is merely the outer or lateral portion of fibres of the preceding muscle, and therefore will have the effect of pulling the arytenoid cartilage backwards and outwards, and by this means separate the vocal chords, so as to widen the glottis.

The arytænoidei obliqui,§ *r*, *r*, are short muscular fibres, extending from the base of the one arytenoid cartilage to the apex of the other, mutually crossing each other; one of them, however, is occasionally deficient. Their function is to approximate these cartilages, and through their medium to diminish the aperture of the glottis.

The arytænoideus transversus,‖ *t*, is a short arrange-

chronic. To perform it sooner, only aggravates the evil, by increasing the inflammatory action, of which I have witnessed not a few instances. I have lately seen three cases of cynanche laryngea occurring in adults, where, besides effusion of matter round and in the glottis, the muscles on the anterior part of the neck, as, for example, the sterno-hyoidei, sterno-thyroidei, omo-hyoidei, and crico-thyroidei, were infiltrated with pus. The symptoms during life were very insidious, two of them appearing as cynanche tonsilaris, the third more severe, and all of them accompanied, when any thing was swallowed, with a convulsive motion of the throat. See Lizars' Practical Surgery, Part II., page 151.

* Syn. Styliform processes, crura superiora, ossa graniniformia.

† Syn. Propriorum laryngis quintus et sextus. Secundus musculorum laryngis seu par cucullare. Ex propriis laryngis musculis posterior. Crico-arytænoideus. Crico-arytænoideus posterior. Dilatateur postérieur. Crico-creti-arithénoïdien. Le crico-aryténoïdien postérieur.

‡ Syn. Propriorum laryngis septimus et octavus. Musculorum laryngis tertius. Ex propriis laryngis musculis, internorum primum par. Le crico-arytenoïdien-lateral. Le crico-lateri-arithénoïdien.

§ Syn. Arytænoideus minor. Thyro-arytænoïdes obliquus atque ary-epiglottidæus. L'aryténoïdien croisé, le crico-aryténoïdien supérieur et l'aryténo-epiglottique. L'aryténoïdien oblique. L'aryténoïdien.

‖ Syn. Propriorum laryngis undecimus ac duodecimus. Musculus

ment of muscular fibres, which extend directly across from the one arytenoid cartilage to the other, and are attached to the inner or mesial aspect, from the apex to the base. Its function is to approximate the arytenoid cartilages, and thus to narrow the glottis.

The thyro-arytænoideus,* *g*, derives a broad extensive origin from the interior or central surface of the thyroid cartilage, and ascends with converging fibres to be inserted in the outer aspect of the base of the arytenoid cartilage, embracing the ventricle of the glottis in its course. Its function is to pull the arytenoid cartilage forwards, backwards, and outwards, so as either to stretch or relax the ligaments of the glottis, and by its forming the wall of the ventricle and the lip of the glottis, it is the chief muscle employed in the modulation of the voice.

The thyro-epiglottideus and arytæno-epiglottideus muscles, are so delicate as scarcely to be distinguishable; and, as their names indicate, they extend between these different cartilages. The arytæno-epiglottideus muscle is represented in Fig. 1 of Plate LXXIII., marked *q*, consisting of very slender fibres, which run from the apex of the arytenoid cartilage, *c*, along the outer aspect of the rima glottidis, to the side of the epiglottis, Q. This muscle is so delicate as to be more distinctly seen when the mucous membrane is allowed to remain on, than when dissected off. The function of this pair of muscles is to approximate the epiglottis to the arytenoid cartilage, and thus to shut the glottis in deglutition.

The thyro-epiglottideus arises from the thyroid cartilage, and is inserted in the side of the epiglottis; but the fibres are so pale and separated, as to be with difficulty seen. These fibres assist the arytæno-epiglottideus in its functions.

When the pharynx, larynx, and inferior maxillary bone have been removed, three pair of muscles are found on the anterior or glabello-sternal aspect of the cervical vertebræ, viz. the longi colli, L, the recti antici majores, R, and the minores, r, represented in Plates LXX. and LXXI., and in Fig. 1 of Plate LXXII.

The longus colli† muscle, marked L, in Plate LXXI., is situated on the anterior aspect of the cervical vertebræ, close to the mesial line, and derives a fleshy and tendinous origin from the sides of the bodies of the three atlantal or superior dorsal, and from the transverse processes of the four or five inferior or sacral cervical vertebræ; the fibres ascending obliquely mesiad, to be inserted in the bodies of all the cervical vertebræ. The function is to inflect the neck laterad, and when both muscles are in action, to inflect it directly forwards or sternad.

The rectus capitis anticus major,‡ marked R, in Plates LXX. and LXXI., and in Fig. 1 of Plate LXXII., is situated immediately on the lateral aspect of the upper half of the longus colli, derives a fleshy and tendinous origin from the anterior aspect of the transverse processes of the third, fourth, fifth, and sixth cervical vertebræ, and ascends to be inserted in the cuneiform process of the occipital bone, anterior or glabellar to the condyle. Its function is to inflect the head slightly laterad, and when both muscles act, directly forwards or sternad. It has also a slight effect in rotating the head on the vertebra dentata.

The rectus capitis anticus minor* muscle, r, in Fig. 1 of Plate LXXII., is also situated on the anterior or glabellar aspect of the cervical vertebræ, and is obscured by the rectus major; it derives a fleshy origin from the anterior aspect of the body of the atlas, and ascends to be inserted in the cuneiform process of the os occipitis, nearer the condyle, and more laterad than the rectus major. Its function is to inflect the head forwards or sternad.

The scaleni muscles, which I shall next describe, are divided variously by different authors, some making one, and others no less than five. I shall follow the arrangement of Boyer, who makes only two, as it is more natural and simple.

The scalenus anticus† muscle, marked L, in Plates IX., XV., and XVI., is situated on the lateral aspect of the cervical vertebræ, immediately exterior or lateral to the longus colli, and separated from the scalenus posticus by the subclavian artery and axillary plexus of nerves; it arises by distinct tendons from the fourth, fifth, and sixth cervical vertebræ, which soon become fleshy, and form a flat muscle, which is inserted in the tubercle (marked *h*, in Fig. 8, of Plate II., on the atlantal surface of the first rib, marked 64, in Plates LXXVI. and LXXVII., near its cartilage.‡ The function of this muscle is to inflect the neck laterad, and when the neck becomes the fixed point to elevate the ribs, as in active inspiration; when both muscles act, they bend the neck and head sternad or forwards.

The scalenus posticus§ muscle, marked 50, in Plate XV., and in Plate XXXIV., is situated immediately dorsal to the scalenus anticus, L, being only separated by the subclavian artery and the axillary plexus of nerves; it derives its origin from the transverse processes of all the cervical vertebræ, by distinct tendons, and descends to be inserted in the atlantal surface of the first rib, nearer its head than the insertion of the scalenus anticus, and also in the atlantal edge of the second rib, near its articulation with the dorsal vertebræ. Its function is to inflect the neck laterad, and when the neck is a fixed point, to elevate the ribs, as in active respiration; when both muscles act, they bend the neck and head slightly dorsad or backwards.

---

extremus laryngis omnium minimus. Musculus laryngis conjuge destitutus. Arytænoïdeus. Arystænoideus major. Arytænoïdeus proprius. Ary-arytænoïdis fibræ interiores. Arytænoides. Arytenoïdien transversal.

* Syn. Propriorum laryngis nonus et decimus. Ex propriis laryngis musculis, internorum secundum par. Quartum par laryngis propriorum. Thyro-arytænoïdes; una cum thyro-epiglottidæo majore. Thyreo-arytænoïdeus. Le thyro-arytenoïdien.

† Syn. Pars eadem primi et secundi dorsum moventium. Primi cervicis musculi. Pars alterius lateris musculi stomacho subjectorum. Longus. Cervicem flectentium primi paris, sive longi. Le long du cou. Pré-dorso-atloïdien. Prédorso-cervical.

‡ Syn. Pars eadem primi et secundi dorsum moventium, pars in os occipitis inserta. Primi cervicis musculi pars occipitio annexa. Nonus musculus capitis. Alterius lateris musculi stomacho subjectorum, portio in occipitis os inserta. Qui cum mastoideo caput flectit. Rectus internus major. Rectus capitis internus major. Le grand droit antérieur de la tête. Grand trachelo-sous-occipital. Grand trachelo-basilaire.

* Syn. Rectus internus minor. Le rengorgeur oblique. Rectus anticus minor. Le petit droit antérieur de la tête. Petit trachelo-sous-occipital. Petit trachelo-basilaire.

† Syn. Tertius et quartus dorsum moventium. Secundus cervicis musculus. Septimus thoracis. Scalenus. Par triangulare. Scalenus primus. The first scalenus. Le premier scalène. Costo-trachélien. Trachelo-costal.

‡ The scalenus anticus muscle relates to the securing of the subclavian artery, as described in page 55.

§ Syn. Tertius et quartus dorsum moventium. Secundus cervicis musculus. Octavus et nonus thoracis. Scalenus. Par triangulare. Scalenus secundus et tertius. Le second scalène. Scalenus minimus, lateralis, medius, et posticus. Costo-trachélien. Trachelo-costal.

I shall now proceed to the muscles of the face, which, I formerly observed, should have been examined first. Great care is requisite in dissecting these, as they are either adherent to the skin, or involved in the adipose tissue, according to the emaciation or plumpness of the countenance. They are mostly all represented in Plate XVIII.

The student should begin with the occipito-frontalis, q, and then proceed in succession to the orbicularis palpebrarum, w, the compressor naris, n, the levator labii superioris alæque nasi, i, the zygomaticus minor, e, the zygomaticus major, a, the depressor anguli oris, b, the orbicularis oris, f, the depressor labii inferioris, 70, the levator labii inferioris, the depressor labii superioris alæque nasi, the buccinator, h, and the masseter, l. The different superficial muscles of the face should be developed at once, as they are so blended with each other, that the student cannot comprehend them until this is done. They are divided into the following regions: the epicranial, the temporal, the palpebral, the orbital, the nasal, the oral, and the zygomatic.

The occipito-frontalis * muscle, q, Plate XVIII., is chiefly a tendinous expanse, situated between the integuments of the scalp and the periosteum of the cranium, adhering intimately to the former. It derives its origin either from the anterior or posterior aspect of the cranium, by two fleshy slips, or bellies; the anterior arise from the superciliary ridges of the frontal bone, where they are incorporated with the corrugatores superciliorum, and the orbiculares palpebrarum, and where they send down a fleshy slip to the compressor naris and levator labii superioris alæque nasi. This slip is considered by some a distinct muscle, and named pyramidalis nasi. † The two fleshy bellies, ascending on the cranium, separate more and more, assume a semicircular shape, and are lost in the tendinous expanse, before they arrive at the coronal suture: this expansive tendon proceeds backwards or iniad, and on each side or laterad, until it again forms two fleshy bellies, which are attached to the superior transverse ridge of the occipital bone, and to part of the temporal bone continuous with it. These posterior bellies are much stronger both in their carneous and tendinous fibres, especially the latter, than the anterior. The tendinous expanse unites both the anterior and posterior fleshy bellies to each other, and descends on each side superficial to the temporal aponeurosis, and beneath or centrad to the attollens aurem, r, towards the ear, where it is attached to the zygoma.

By the modern anatomist, the tendinous expanse is named the epicranial aponeurosis; the anterior fleshy bellies, the frontalis muscle; and the posterior bellies, the occipital muscle. ‡

To display this muscle, a longitudinal incision must be made from the root of the nose over the cranium, to the superior transverse ridge of the occipital bone, cautiously through the skin, when a peculiar granulated fat will direct the student that he has arrived at the tendinous expanse. The skin is then to be carefully dissected off, the dissector never proceeding deeper than this granulated fat.

The function of the occipito-frontalis muscle is to corrugate the skin of the scalp and forehead, to elevate the eye-brows and eye-lids, to wrinkle the skin of the nose, and to assist in knitting the eye-brows.

The orbicularis palpebrarum * muscle, w, in Plate XVIII., situated between the skin and the eye-lids, is a delicate arrangement of circular muscular fibres, deriving their origin from the nasal process of the superior maxillary bone, encircling the upper and lower eye-lids, or tarsi, and inserted in the outer edge of the orbitar process of the superior maxillary bone, near their origin. Here they are intimately connected with the ligament of the tarsi, and more or less so with the lacrymal sac. As the fibres sweep round the lower eye-lid, they adhere to the tarsus, and overlap and join the fibres of the levator labii superioris alæque nasi, i, and also those of the zygomaticus minor, e, which latter is frequently a slip of this muscle. As the fibres run round the upper eye-lid, they adhere to the tarsus, to the occipito-frontalis, the corrugator supercilii, and the internal angular process of the os frontis. To dissect this muscle, nearly as much care and patience are requisite, as in the displaying of the occipito-frontalis, and the student should display first the fibres of the lower, as they are much bolder than those of the upper eye-lid.

The function of this muscle is to open or shut the eye-lids, to compress the eye-ball and the lacrymal gland, and to convey the tears towards the puncta lacrymalia. †

The student may now proceed either to the examination of the corrugator supercilii, or the compressor naris. I shall describe the latter here, as the former will be represented in one of the plates of the eye.

The compressor naris ‡ muscle, n, Plate XVIII., situated across the nose, immediately beneath the integuments, is a delicate arrangement of muscular fibres, deriving their origin from the ala nasi, and the levator labii superioris alæque nasi, and ascending with parallel fibres to the dorsum or bridge of the nose, where they join those of the opposite side, and the fibres of the occipito frontalis. Their function is to compress or expand the anterior apertures of the nares, and to corrugate the skin of the nose.

The levator labii superioris alæque nasi § muscle, ı, Plate XVIII., situated between the eye and the side of the nose and upper lip, derives its origin from the nasal

---

* Syn. Pars carnea anterior, musculosa frontis cutem movens substantia. Partes ejus carneæ posteriores sunt supercilium trahentes et musculi frontis. Occipitii musculi, et musculus frontis. Occipitales, et musculi frontales. Musculi cutis frontis. Epicranius. Les muscles occipitaux, et les muscles frontaux. Muscle épicrane.

† Syn. Frontalis pars per dorsum nasi ducta. Elevator alæ nasi. Fronto-nazal. Procerus nasi. Pyramidal du nez. Pyramidalis nasi.

‡ The occipito-frontalis is materially concerned in punctured wounds of the scalp. When inflammation supervenes, an incision is made across the fibres of the tendon to remove the tension, and when suppuration takes place, the same direction of incision is made. This muscle is also concerned in opening the temporal artery, see page 48.

* Syn. Duo palpebrarum musculi. Palpebrarum primus, orbicularis. Exterior qui totum oculum ambit. Orbicularis palpebræ musculus major. Orbicularis latus cum ciliari. Qui claudentes palpebras, sive semicirculares. Sphincter. Orbicularis oculi. Le muscle orbiculaire des paupières. Naso-palpébral. Maxillo-palpébral.

† The orbicularis palpebrarum relates to the opening of the lacrymal sac in fistula lacrymalis. This muscle, and no other, should be cut in the operation.

‡ Syn. Nasum dilatantes. Transversus. Triangularis nasi.

§ Syn Musculus supercilii musculo junctus, superiori labro insertus. Ex propriis qui superius labrum sursum trahit. Pars primi nasi alas abducentis. Dilatator seu retractor alæ nasi et elevator labii superioris. Pars elevatoris labii superioris proprii. Elevator proprii labii superioris seu incisorius. La grande et la petite portion de l'incisif latéral. Releveur de la lèvre supérieure et de l'aile du nez. Grand sus-maxillo-labial, et moyen sus-maxillo-labial. Maxillo-labii-nazal, et orbito-maxilli-labial.

process and the margin of the orbitar and malar processes of the superior maxillary bone, onwards to the cheek-bone, from which the fibres descend obliquely inwards, to be inserted in the skin of the upper lip and orbicularis oris, and cartilaginous ala of the nose. In some subjects, there is a slight separation of the origin, the portion which originates from the nasal process being apart from that which arises from the orbitar process, and hence the muscle is divided into two by some authors. The origin is overlapped by the orbicularis palpebrarum.* The function of this muscle is to elevate the upper lip, and to expand or dilate the anterior aperture of the nares.

The zygomaticus minor muscle,† e, is a very delicate assemblage of muscular fibres, which are frequently deficient, situated on the outer or inio-lateral margin of the levator labii superioris alæque nasi muscle, i, with which they are not unfrequently connected. This slender muscle is either a production of the orbicularis palpebrarum, w, or derives its origin from near the middle of the external surface of the os malæ, and descends to be attached to the orbicularis oris, f, and the upper lip, near the angle of the mouth. Its function is to elevate the upper lip, especially the angle of the mouth.

The zygomaticus major muscle,‡ a, is a larger assemblage of muscular fibres than the minor, having a similar course, and situated on its outer or inio-lateral margin. It derives its origin from the zygomatic process of the os malæ, and descends obliquely to the angle of the mouth, where it is attached to the skin, the orbicularis oris, and the depressor anguli oris. Its function is to elevate the angle of the mouth upwards and outwards. The platysma myoides, already described, may be with great propriety dissected at this period, as its fibres are blended with those of the depressor anguli oris, b.

The depressor anguli oris § muscle, b, is a triangular arrangement of muscular fibres, extending between the inferior maxillary bone and the angle of the mouth, immediately beneath the integuments. It derives an extensive origin from the base of the inferior maxillary bone, (marked with the letters *a*, *a*, in Fig. 25 of Plate VI.), and ascends with converging fibres, to be attached to the angle of the mouth, where its fibres mingle with those of the orbicularis oris, f, and those of the zygomaticus major, a. In its course the outer or inio-lateral fibres are blended with those of the platysma myoides, F. Its function is to depress the angle of the mouth.

The orbicularis oris‖ muscle, f, is a circular arrangement of muscular fibres encircling the lips, formed apparently in some measure by the insertion of the various muscles around, viz. the levator labii superioris alæque nasi, the depressor labii superioris alæque nasi, the two zygomatici, the levator anguli oris, the depressor anguli oris, and the depressor labii inferioris, with which they are connected. The fibres adhere intimately to the skin, so that they are with some difficulty displayed elegantly; they run along the upper and lower lips, and are either continuous or decussate at the angles: to me they appear to be continuous. Their function is to open or shut the mouth, and to perform various motions in speech, gesture, and deglutition.*

The levator anguli oris† muscle, o, in Plate XVII., situated beneath or centrad to the levator labii superioris alæque nasi, i, and the zygomatici, e, a, derives its origin from the superior maxillary bone immediately below or basilad to the infra-orbitary foramen, *o*, and the infra-orbitary nerve, 2; and descends obliquely to be inserted in the angle of the mouth, where its fibres mingle with those of the orbicularis oris, f, and the depressor anguli oris, b. Its function is indicated by its name.

The depressor labii superioris alæque nasi ‡ muscle, *s*, in Fig. 3 of Plate LXXIII., is situated between the upper lip and the alveolar processes of the superior maxillary bone. To display it, the upper lip must be held up, as represented in the diagram, and the lining membrane of the mouth carefully removed, when the fibres will be seen to arise from the alveolar processes of the two incisive and canine teeth of the one side, and to ascend to be inserted in the upper lip, and cartilaginous ala of the nose, the fibres intermingling with those of the orbicularis oris. Its function is to antagonize the levator labii superioris alæque nasi, and consequently depresses the upper lip, and contracts the anterior aperture of the nares by pulling downwards the cartilaginous ala of the nose.

The depressor labii inferioris§ muscle, marked 70, in Plate XVIII., situated between the lower lip and the chin, is a scattered arrangement of delicate muscular fibres, adhering so intimately to the skin that they are with difficulty displayed. These fibres derive their origin from the base of the inferior maxillary bone, as indicated in Fig. 25 of Plate VI., between the symphysis menti, *c*, and midway between the letters *a*, and ascend obliquely mesiad, uniting with those of the opposite side, to be inserted in the lower lip, the orbicularis oris, and the skin. The origin is overlapped by that of the depressor anguli oris. The function of this muscle is indicated by its name, depressing the lower lip downwards and laterad; and when both muscles act, depressing the lip directly downwards or basilad. ‖

The levator labii inferioris,¶ marked *i*, in Fig. 3 of

* The levator labii superioris is concerned in the division of the infra-orbitary nerve in neuralgia, as described in page 53.

† Syn. Le petit zygomatique. Petit zygomato-labial.

‡ Syn. Unus ex quatuor musculorum labris propriorum. Zygomaticus. Primi paris, sive attollentis labium superius. Le grand zygomatique. Grand zygomato-labial.

§ Syn. Pars alterius lateris primi musculi eorum qui buccas et labra movent. A menti lateribus adscendens in labrum supernum. Labium superius deorsum movens, a mento in illud labium delatus. Ex propriis quo superius labrum deorsum movetur. Quarti paris propriorum labiis. Depressor labiorum. Depressor labiorum communis. Labrorum communis depressor, seu triangularis. Le triangulaire ou abaisseur de l'angle des lèvres. Maxillo-labial. Sous-maxillo-labial.

‖ Syn. Moles carnea, musculosa tamen, quæ utrumque labium format. Musculus orbicularis. Quartum par constringens. Constrictor labiorum sive orbicularis. Sphyncter labiorum. Les sur-demi-orbiculaires. Le muscle orbiculaire des lèvres. Labial.

* This muscle is concerned in the operations for hare-lip and cancer of the lips.

† Syn. Secundus ad latera trahens sive abducens. Elevator labiorum. Elevator labiorum communis. Elevator labiorum seu caninus. Le canin. Petit sus-maxillo-labial.

‡ Syn. Constrictor alæ nasi ac depressor labii superioris. Depressor labii superioris proprius. Musculus labri superioris arctandis naribus communis, ac myrtiformis seu pinnarum dilatator proprius. L'incisif mitoyen. Depressor alæ nasi. Labial. Maxillo-alveoli-nasal.

§ Syn. Unus ex quatuor musculorum labris propriorum duobus inferioribus. A quo labrum inferius deorsum movetur. Tertii paris, deprimentis inferius labrum. Quinti paris propriorum labiis. Depressor labii inferioris. Depressor labii inferioris proprius. Labri inferioris depressor proprius. Le quarrè du menton ou abaisseur de la lèvre inférieure. Mento-labial. Mentonnier-labial.

‖ The depressor labii inferioris is concerned in cancer of the lower lip.

¶ Syn. Elevator labii inferioris. Elevator labii inferioris proprius. Elevator menti. De la houppe du menton, ou l'incisif inferieur. Portion de mento-labial. Sous maxillo-cutané.

Plate LXXIII., is situated on each side of the frenum labii inferioris; and in order to display it, the lower lip must be held downwards, as represented in the drawing. This muscle derives its origin from the alveolar processes of the incisive and canine teeth, and descends in a fan-like shape, to be inserted in the lower lip. It can generally be seen shining through the lining mucous membrane of the mouth. This muscle, as its name indicates, elevates the lower lip.*

The masseter muscle,† marked l, in Plates XVII. and XVIII., is a bold, tendinous, and fleshy mass, situated on the side of the face, extending between the cheek-bone and the lower jaw-bone. It derives its origin, which is partly fleshy and partly tendinous, from the inferior or basilar edge and zygomatic process of the os malæ, and from the zygomatic process of the temporal bone; and descends along the ramus of the inferior maxillary bone, to be inserted partly in the ramus, and partly in the angle of the same bone. Its function is to approximate the inferior to the superior maxillary bone, and is therefore employed in breaking and triturating the food, but more so in the former than in the latter action.‡

The buccinator muscle,§ h, in Plates XVI., XVII., and XVIII., situated beneath or centrad of the masseter, zygomatici, and depressor anguli oris muscles, and immediately exterior or peripherad of the mucous membrane of the mouth, derives a tendinous and fleshy origin from the alveolar processes of the superior and inferior maxillary bones, and proceeds with straight or horizontal fibres to be inserted in the angle of the mouth and orbicularis oris. The function of this muscle is to inflate or compress the cheeks, and to draw the angle of the mouth backwards, and therefore employed in mastication to move the bolus of food from one side of the mouth to the other.||

The temporal muscle,¶ u, in Plates XVI. and XVII., and in Plate LXXI., situated on the side of the face, beneath the occipito-frontalis muscle, and having a strong tendinous aponeurosis covering it, derives its origin from the temporal depression of the frontal, parietal, temporal, and sphenoid bones; and descends with converging fibres below the jugum or zygoma, to be inserted in the coronoid process of the inferior maxillary bone, and also along the ramus. The tendinous aponeurosis of this muscle is attached all round the muscle to the scabrous ridge, marked *e*, in Fig. 1 of Plate IV., and to the zygoma. The muscle has elegant glistening tendinous fibres exteriorly or peripherad, and fleshy fibres internally or centrad. The function of this muscle is to approximate the inferior to the superior maxillary bone; and it is therefore employed in breaking and triturating the food, but more so in the former than in the latter function.*

The two pterygoid muscles should now be investigated; they are situated centrad or within the ramus of the inferior maxillary bone, and are named external and internal, appellations however which do not distinguish them clearly from each other. To display them with satisfaction, the inferior maxillary bone should be sawn midway between the symphysis menti and angle of the bone.

The pterygoideus internus† muscle, n, in Plate XVI., and in Plates LXXI. and LXXII., Fig. 1, situated internally or centrad to the ramus of the inferior maxillary bone, derives its origin from the fossa between the two pterygoid plates of the sphenoid bone, and descends to be inserted on the inner or central aspect of the angle, and part of the ramus of the inferior maxillary bone. The internal maxillary artery, *f*, separates this muscle from the pterygoideus externus. Its function is to move the inferior maxillary bone on the superior from side to side or laterally, and hence employed in triturating the food in mastication.‡

The pterygoideus externus§ muscle, t, in Plate XVI., and in Plates LXXI. and LXXII., Fig. 1, situated coronad or above the pterygoideus internus, and separated from the internal pterygoid plate of the sphenoid bone, the bulbous process of the superior maxillary bone, and the root of the temporal process of the sphenoid bone, and extends directly across with horizontal fibres to be inserted in the cervix and capsular ligament of the articulation of the inferior maxillary bone. The function of this muscle, like that of the pterygoideus internus, is to move the inferior maxillary bone laterally, or from side to side; and it is therefore employed in triturating the food in mastication.||

Having examined all the muscles in this region, I shall now proceed to the ligaments of the articulation of the inferior maxillary bone.

The condyloid process of the inferior maxillary bone is articulated simply by a fibrous capsule and a synovial membrane, marked *c*, in Plates LXX., LXXI., and LXXII., Fig. 1. The fibrous capsule arises round the glenoid cavity, *e*, of the temporal bone, glides over the condyle, *b*, of the inferior maxillary bone, to be inserted round the cervix. This is divided by modern anatomists into an external lateral and an internal lateral ligament. Within this capsule is interposed an interarticular fibro-cartilage, *h*, which is concave on both surfaces, and adheres to the synovial membrane and fibrous capsule. The synovial membrane is double, a superior and an inferior; the su-

* The levator labii inferioris is in some degree concerned in dividing the branch of the inferior maxillary nerve, which emerges at the mental foramen.

† Syn. Inferiorem maxillam moventium alterius lateris secundis, seu masseter. Masseterius et mansorius dictus. Masseter. Tertius attollens maxillam masseter. Tertii paris laterales. Zygomatico-maxillaire.

‡ The masseter muscle is concerned in excision of the inferior maxillary bone, and also in luxation of this bone.

§ Syn. Buccarum, labrorum, et nasi alarum secundus alterius lateris. Musculus buccæ. Bucco. Contrahens communis buccarum lamiorumque. Le buccinateur. Bucco-labial. Alveolo-maxillaire.

|| The buccinator is concerned in wounds aud operations of the face, and in fistula of the parotid duct, this tube piercing the muscle, as seen in Plate XVIII., marked x.

¶ Syn. Inferiorem maxillam moventium primus alterius lateris musculus, seu temporalis. Le temporal ou crotaphite. Temporo-maxillaire. Arcadi-temporo-maxillaire.

* The temporal muscle is concerned in excision of the inferior maxillary bone, and in luxation of this bone.

† Syn. Tertius musculus qui in ore latitat. Musculus in ore latitans. Latens in ore. Quinti paris maxillam abducens. Paris pterygoidis sive alaris interni. Pterygoides interior. Le grand ptérygoïdien ou ptérygoïdien interne. Le grand ptérygo-maxillaire. Ptérygo-anguli-maxillaire.

‡ The pterygoideus internus muscle is concerned in excision of the inferior maxillary bone, and in luxation of this bone.

§ Syn. Novi paris musculorum. Musculi temporalis illa pars quod ab externa sede processuum, quos vespertilionum alis comparamus. Quintum par exerendæ Fallopio adscriptum. Quarti paris pterygoïdes abducentis. Pterygoïdes exterior. Le petit pterygoïdien ou pterygoïdien externe. Petit pterygo-maxillaire. Pterygo-colli-maxillaire.

|| The pterygoideus externus is concerned in excision of the inferior maxillary bone, and in luxation of this bone.

perior invests the glenoid cavity, the tubercle of the zygomatic process, and the upper surface of the interarticular cartilage: the inferior clothes the lower surface of the cartilage and the condyle of the inferior maxillary bone.*

I have not yet described the ligaments peculiar to the atlas and dentata. These are represented in Fig. 2 of Plate LXXII.

In this figure, the letters D point out the extension of the dura mater, or theca vertebralis; and the letter E the ligamentum commune posticum, both of which are reflected off, to show these ligaments. The ligamentum commune posticum, E, extends, like the anticum, from the foramen magnum of the occipital bone, to the coccyx, but is not so strong a ligament. That portion of the ligamentum commune anticum and posticum, which extends from the foramen magnum of the occipital bone to the atlas, is named by some authors the circular ligament. The ligamentum commune anticum is described in page 115. The ligamenta subflava are short strong ligaments, which extend from the ring, *b*, of the one vertebra to that, *b*, of the other. One of which is distinctly seen in Fig. 6 of Plate LXVI., extending between the atlas and dentata. In Fig. 2 of Plate LXXII., they are merely covered by the theca vertebralis.

Some of the fibrous capsules of the articular processes are also displayed in Fig. 2 of Plate LXXII. The letters c indicate these capsules, one of which, viz. that between the vertebra dentata and the atlas, is cut open to show the pouch; these ligaments adhere around the smooth articular processes of the vertebræ, and are rather delicate capsules. The inferior or sacral, c, is placed on one of the articular surfaces of the vertebræ.

The intervertebral fibro-cartilage, C, connecting the bodies of the vertebræ, is also displayed in Fig. 2 of Plate LXXII. This is a soft spongy elastic body, with a mucous fluid in the centre.

The transverse ligament of the atlas, marked with the digit 1, in Figs. 1 and 2, is a very strong broad ligament, of a yellowish colour, extending between the tubercles of the atlas (marked *i*, in Fig 5 of Plate II., the dotted line receding on each side from the letter *i*, indicating the course of the ligament). This confines the processus dentatus of the vertebra dentata, and prevents it disturbing or injuring the spinal cord, during the rotatory motion of the head.

The digits 2 indicate the lateral ligaments which extend between the sides of the tip of the processus dentatus, *n*, and the margin of the foramen magnum, *k*, (the precise points being marked *n*, in Fig. 5 of Plate V.). These lateral ligaments are of a round figure, very strong, and moderate the rotatory motions of the head.

The digit 3 points out the perpendicular ligament, which extends from the processus dentatus, *n*, to the margin, *m*, of the foramen magnum, *k*. This ligament is of a flattish figure, much more slender than the lateral, and assists in moderating the flexion of the head forwards or sternad.*

---

* In page 17, the motions of the inferior maxillary bone are described; and it is there mentioned that luxation occurs most frequently in children, in consequence of the shallow state of the articulation. This bone is only luxated forwards, an accident which occurs most commonly while yawning; it has been however produced by laughing, gaping, or biting too large an object; also by a blow on the chin while the mouth is wide open, and during the extraction of a tooth. Considerable pain is experienced, which the patient is unable to describe from the extended state of the mouth, the saliva flows in profusion, a large depression is felt before the ear, a prominence under the cheek-bone, and the cheeks and temples are flatter than usual. The accident cannot be mistaken. If not reduced, the patient can neither speak nor swallow for the first few days. In a few weeks the symptoms are not so strongly marked, the chin gradually approximates the superior maxilla, the individual recovers progressively the power of speaking and swallowing, but still stammers and slavers from the mouth. Occasionally only one condyle is luxated, and then the mouth is distorted and turned to one side, while the teeth of the two maxilla do not correspond. To reduce this luxation, the operator puts on a pair of thick gloves, inserts his thumbs far back on the last molares, and places his fingers under the chin; he then gradually depresses the molares, while at the same time he elevates the chin, and when the luxation is reducing, the operator should endeavour, by gliding his thumbs to the sides, between the teeth and the cheeks, to prevent them being checked. If gloves are not at hand, cotton or linen may be rolled round the thumbs. When the reduction is accomplished, a four-headed roller should be applied, placing the centre or union of the heads under the chin, and then carrying two of the ends upwards to the crown of the head, and the other two backwards to the occiput. The patient should abstain from eating any hard food for some time, as this luxation is very liable to recur.

When the greater portion, or the whole of the inferior maxillary bone, requires to be removed for exostosis, the operator extracts one or two teeth, where the sound bone is to be ultimately sawn, then incises the soft parts along the base of the jaw, and also upwards behind the ramus, if it be deemed necessary to remove any or the whole of this portion of the bone. In making this incision, the facial artery is necessarily divided, and should be secured with a ligature. This flap is now to be dissected upwards from the tumour, and the saw applied to the side of the bone, near its symphysis. The operator seizes hold of this end of the bone, and separates it from its muscular connexions. The side and ramus being divested of the soft attachments, and the surgeon having considered it necessary to remove the bone at its articulation, he proceeds cautiously and divides the fibrous capsule and external pterygoid muscle, carefully avoiding the internal maxillary artery, while he depresses and carries outwards the bone.

The arteries are now to be secured, the flap replaced and stitched. See Lizars' Practical Surgery, Part II., page 126.

* As observed in page 3, the vertebræ are in a manner so firmly locked together, by the vertical direction of their articular processes which overlap each other, by the intervertebral cartilage, by the strong ligaments, as the crucial, the common anterior and posterior, the subflava, the capsular, the intertransverse and interspinous, also by a number of short muscles, that dislocation seldom occurs. We therefore look more for fracture of these bones, or fracture and luxation; for when once any of them is fractured, we can easily conceive that luxation may also occur. Thus, suppose the articular processes either of the superior or the inferior vertebra, to be fractured; these articulations may then be easily luxated. Some time ago, I was called to a lady, who, in looking over her bed-room window, three stories high, between thirty and forty feet in height, lost her balance, and fell on a large washing-tub, her back striking the edge of the tub. Paralysis of the lower extremities, of the bladder of urine, and the rectum, continued for two months, when she died. On examination of the spine (the object in question, for it is foreign to my purpose to detail minutely the case), the last dorsal vertebra was found fractured, and the spinal canal obliterated. Several examples of the luxation of one of the articular processes of a cervical vertebra, from that of the contiguous vertebra, are recorded. In this accident, the position of the head and neck at once distinguishes it, and also the impossibility of turning the neck to the opposite side. From the elongation or laceration which would necessarily accrue to the spinal cord, in any attempt to reduce this luxation, all idea of reducing it must be abandoned. Petit-Radel attempted reduction in a young child, which died in his arms. Desault and Chopart left their patients to nature, and they lived.

Boyer mentions, that in violent flexions of the spine, forwards or sternad, the interspinous ligaments and ligamenta subflava have been ruptured. When the former only were lacerated, no injury of the spinal cord followed; but when the latter, paraplegia and death resulted.

The occipital condyles have never been displaced from the atlas by external violence, but occasionally by disease. Daubenton, Sandifort, Boyer, Duverney, Schupke, Frank, Rust, and Reil, detail cases of this last event. These arose from scrophulous affections, or caries, or exostosis of either the articular or transverse processes of the atlas, or from

The general motions of the vertebræ are detailed in page 3. The nodding motions of the head are performed between the condyloid processes of the occipital bone, and the superior articular processes of the atlas; while the rotatory motions of the head are performed between the inferior or sacral articular surfaces of the atlas, and the superior of the vertebra dentata, these latter motions being limited in their extent by the lateral ligaments of the dentata. In these last motions the processus dentatus is prevented pressing on the spinal cord by the transverse ligament of the atlas, and the perpendicular of the vertebra dentata, and also by the ligamentum commune anticum, which is sometimes named the circular ligament, and likewise by the theca vertebralis.

Having already described the minute anatomy of the brain, or sensorium commune, I now mean to describe the organs of sense, which are the instruments by which that sensorium becomes acquainted with external objects.

The senses are five in number, viz. seeing, hearing, smelling, tasting, and touch; of these I shall first describe that of smelling, next that of tasting, thirdly, that of hearing, fourthly, that of seeing, and lastly, that of touch; not that I think this the natural anatomical order, but that I am compelled to adopt it, in consequence of the difficulty of procuring perfectly fresh eyes.

I have here to regret, therefore, that owing to the above circumstance, all the plates of the eye are not yet engraved, because, in a naturally connected anatomical order, the eye should be described as the first organ of sense, as some of its nerves proceed to the nose; this latter organ should come next; thirdly, the mouth; fourthly, the ear; and lastly, the skin. In a physiological view of the senses, this order should be reversed. I have no alternative, therefore, but to begin with the nose. I am happy to say, that only one plate of the eye remains to be engraved, and that it is well advanced.

The nose is delineated in Plates LXXIV. and LXXV., and consists of bones, cartilages, a delicate mucous membrane, several cells, blood-vessels, nerves, and lymphatics. In page 16, several bones are described as entering into the formation of this organ of sense, viz. the nasal, the superior maxillary, the lacrymal, the frontal, the ethmoid, the sphenoid, the vomer, the inferior spongy, and the palate bones.

The septum narium, marked with the letters c, in Figs. 1 and 2 of Plate LXXIV., and in Fig. 1 of Plate LXXV., formed by the azygos process of the sphenoid, the spinous processes of the palate and superior maxillary, and the nasal lamella of the ethmoid bones, together with the vomer, is completed in the fresh state by an extension of cartilage, onwards to the tip of the nose, where there is also a loose or moveable piece of cartilage, appearing a continuation of the latter, which is covered with skin, studded with bristly hairs, and named columna, and marked D in the same figures. Between these cartilages a small elliptical depression is observable, represented in the plates by a slight shading.

On each side of the anterior aperture, E, of the nares, in Fig. 2 of Plate LXXIV., is placed an irregularly oblong shaped cartilage, B, which forms the ala or pinna of the nose, and which is named the lateral cartilage. This is connected by a ligamentous membrane, C, to the nasal and superior maxillary bones, and to the columna, D, and the perpendicular cartilage, A. The perpendicular cartilage, A, of a long roundish figure, extends from the longitudinal nasal suture, resting on the cartilaginous septum narium, to the columna, D, on which it also rests; and, in some instances, appears merely a thickening or overlapping of the cartilaginous septum narium. This is named the dorsum of the nose, and the one extremity is termed the tip, apex, or point of the nose, and the other extremity, or rather the point where the nasal bones join the frontal bone, is styled the root or radix. At the back or inial part of the nares, we have two large apertures, one of which is marked T, in Fig. 1 of Plate LXXIV., leading to, or communicating with the pharynx, b; and here there are also lateral cartilages, on one of which the letter T is placed. Besides these four large apertures to and from the nares, there are all those to the cells and cavities, and to the Eustachian tubes, one of the latter of which is marked z in this figure; and also the apertures to the lacrymal duct, indicated by the bristle, 3. All these bones and cartilages are observed in the figures of Plates LXXIV. and LXXV. to be clothed with a delicate vascular mucous membrane,* having an infinite number of small mucous follicles, and on which the nerves of smelling are minutely and extensively ramified. This mucous membrane is a continuation of the cutis vera, beautifully modified for this higher order of function. Besides investing all the bones and cartilages of the nares, it extends into all the cells, cavities, and ducts, connected with the nares, becoming, however, much thinner and more delicate. These cells are delineated in Figs. 1 and 3 of Plate LXXIV., and in Figs. 1, 2, and 3 of Plate LXXV.; the frontal sinuses being marked *f*, the ethmoidal cells *f**, *f**, *f**, the palatine cell P, the sphenoidal cell *g*, and the antrum maxillare A. The bristle, marked 3 in Fig. 3 of Plate LXXIV., and in Figs. 1 and 2 of

---

the existence of similar tumours on the occipital bone, or petrous portion of the temporal bone. The anterior or posterior portion of the bony ring, or one of the sides of the atlas, has been so pushed to one side, as to diminish the diameter of the foramen magnum a third, the half, and even two-thirds. Notwithstanding so great a displacement of the atlas, and consequent pressure on the spinal cord, individuals so affected have lived for many years, apparently from its taking place gradually, until these tumours have acquired either a prodigious magnitude, or the head has become anchylosed with several of the cervical vertebræ. In these cases, not only was the atlas displaced from the occipital bone, but anchylosis had taken place in the articulation between the processus dentatus and the atlas, and even between the point of the processus dentatus and the occipital bone. Other varieties of displacement and anchylosis were observable. The treatment of this peculiar affection consists in keeping the head and neck as straight as possible, by means of the chin-stay, and in applying blisters, or setons, or issues.

The vertebra dentata has been displaced from the atlas, particularly its processus dentatus, and this has occurred both from external violence and from disease, and has generally proved very soon fatal. The external violence has in some cases been extremely trifling; thus Petit details a case wherein the lifting a child up by the head produced it, and Sir C. Bell relates also a case where a man hurling a wheel-barrow forcibly from the causeway upon the pavement, fell upon his chin, and ruptured the transverse, lateral, and perpendicular ligaments. Boyer imagines, that in some instances the perpendicular and lateral ligaments are ruptured, that the processus dentatus slips sacrad of the transverse ligament of the atlas, and that this result happened in the case of a child related by Petit, and to the malefactors executed at Lyons, as detailed by Louis. In all the above cases from accident, death instantly ensued; but should such an event not immediately occur, the patient should be placed on his back, and the head and neck put in such a straight position, as to remove the pressure of the processus dentatus from the spinal cord. In displacement occurring from disease, the patient ought to be laid in the horizontal posture, the chin-stay applied, and eschars made. See Lizars' Practical Surgery, Part I., p. 164.

* Syn. Schneiderian membrane.

Plate LXXV., is introduced along the lacrymal or nasal duct, showing its course from the nose upwards, or from the eye downwards to the nose, the latter being the natural course of this conduit for the tears from the eye to the nose. The aperture leading from the orbit is developed in Plate LXXIX., Fig. 2, marked G. This tube, as already mentioned, is formed by the lacrymal, superior maxillary, and inferior spongy bones, as illustrated in Plates IV., V., and VI., and lined with a continuation of the mucous membrane of the nares. In Fig. 3 of Plate LXXIV. the inferior spongy bone is marked 23, and we observe the bristle, 3, emerging from below this bone; in Fig. 1 of Plate LXXIV. a considerable portion of this bone, 23, has been removed to exhibit the course of this tube; while in Fig. 2 of the same plate, this bone is still further cut up to display this passage. This lacrymal duct conducts the tears from the lacrymal sac at the inner canthus of the eye to the nares, from thence they glide along the floor of the nares, flow out at the posterior apertures, T, Fig. 1 of Plate LXXIV., and down along the velum palati, F, to the pharynx, *b*, and œsophagus, into the stomach.* The mucous secretion from the extensive surface of the Schneiderian membrane of the nares flows along the same course to the stomach.

The bristle marked 2 in Fig. 3 of Plate LXXIV., and in Fig. 1 of Plate LXXV., indicates the aperture or canal of communication of the frontal sinus with the nares. Both the sinus, *f*, and its canal are clearly developed in Fig. 2 of Plate LXXV., the channel being exposed.

The bristle marked 5, in Fig 3 of Plate LXXIV., and in Fig. 1 of Plate LXXV., indicates the aperture which leads to the ethmoidal cells; all of which are laid open in Fig. 2 of Plate LXXV., and where the centre of one of the three is, they communicate individually with the nares. Sometimes they communicate directly, and sometimes through the medium of one another.

The bristle marked 7, in Fig. 1 of Plate LXXV., indicates the channel of communication to the palatine cell, P, which is seen in Fig. 2 of Plate LXXV., and in Fig. 1 of Plate LXXIV. The bristle 4, in Fig 3 of Plate LXXIV., and in Fig. 1 of Plate LXXV., indicates the mode of communication with the sphenoidal cell, *g*.

The bristle marked 6, in Fig. 1 of Plate LXXV., indicates the aperture leading backwards to the antrum maxillare, which is situated between the superior and inferior spongy bones, as will be easily understood by comparing Fig. 3 of Plate LXXIV. with Figs. 1 and 2 of Plate LXXV., in the last of which figures the aperture is distinctly seen. In Fig. 3 of Plate LXXV., and in Figs. 1 and 3 of Plate LXXIV., this cavity is fully displayed. In Fig. 5 of Plate LXXV., the delicate mucous membrane, which invests this cavity, is displayed, the bone having been removed. All of these cavities, I have already mentioned, are invested with the mucous membrane of the nares, and all of them have small apertures or canals of communication, in order to prevent the cold atmospheric air being freely admitted.

The nares are supplied with blood by the internal maxillary artery, marked *f*, in Plate XV., and described in page 48, and are extremely vascular, being, in health, of a bright red colour. The ophthalmic artery also contributes to supply the nares, giving origin to two small arteries, named ethmoidal, which enter at the foramina orbitaria interna, and are ramified on the ethmoid and other cells in their contiguity.

The nerves, which are distributed on the nares, are the first pair or olfactory, the nasal twig of the ophthalmic or first branch of the fifth pair of nerves, and the nasal twigs of the second or superior maxillary branch of the same nerves.

The olfactory nerves, delineated in Fig. 7 of Plate LXI., in Plates LXIV., LXV., Fig. 5 of Plate LXVI., and Plate LXVII. of the brain, and marked with the digits 1, are described in page 137. Their distribution on the mucous membrane investing the turbinated portions, *d*, in Fig. 3 of Plate LXXIV., and the mesial septum, *c*, in Fig. 1 of Plate LXXIV., is so soft and delicate as to be with difficulty depicted.

The fifth pair, or trigeminal nerves, are represented in Fig. 7 of Plate LXI., and in Plates LXIV. and LXV., marked 5, and their origin described in page 138; but as the nasal twig of the ophthalmic branch is not seen in the present plates, but in those which follow, and as several other branches of this nerve are not now seen, it appears preferable to defer its description until I can do it in a connected order. In the meanwhile, the reader is directed * to the nasal twigs which are given origin to by the palatine nerve, marked P, in Figs. 4 and 5 of Plate LXXV. In Fig. 5, where they are better seen, five nervous threads are observed to enter the nares at the spheno-palatine aperture (marked *o*, in Fig. 4 of Plate IV.) These nervous threads are distributed on the mucous membrane investing the mouth of the Eustachian tube, the sphenoid and other cells contiguous, and the septum narium, while one of them descends along the septum to the foramen incisivum, which it perforates, and unites with twigs of the palatine nerve, marked P, in Fig. 1 of Plate LXXVI. These nervous threads are named by some authors the superior posterior nasal nerves, to distinguish them from other nasal nervous threads, termed the inferior posterior nasal nerves, which are represented in Fig. 5 of Plate LXXV., arising farther down from the palatine nerve, P, and which are piercing the nasal lamella of the palatine bone, to be distributed on the mucous membrane investing the inferior spongy bone and floor of the nares. †

* The course of the lacrymal duct should be well understood, being subject to inflammation and diseased secretion, which sometimes ends in thickening of the membrane that closes up the channel, forming the disease named fistula lacrymalis. We sometimes require to introduce a probe or syringe into it, either from the nares or from the eye.

* The names of the nervous twigs seen in Figs. 4 and 5 of Plate LXXV., are given in the Index to the Letters of Reference.

† In page 16, some observations are made on the structure and configuration of the nares. From the great vascularity of the mucous membrane, and its exposed nature, hemorrhage or epistaxis is a frequent occurrence. If cold styptic lotions, as vinegar and cold water, or a solution of the sulphate of zinc or copper, have no effect, the posterior apertures require to be plugged up with lint, which is accomplished by introducing either a long-eyed probe (carrying the eyed end first) or a double canula armed with the noose of a ligature, along the floor of the nares, keeping close to the mesial septum, backwards to the pharynx, and downwards behind or dorsad to the velum palati, until the ligature is seen in the throat, when it is to be brought forwards by forceps into the mouth, and then have attached to it a dossil of lint, which is to be pulled upwards by the canula and ligature, into the posterior aperture of the naris, so as to shut it up. If the lint be too large or too small, it must be returned into the mouth and modified accordingly. The canula should then be removed, but the ligature left hanging out at the anterior aperture of the nares, which must be also stuffed with lint. The same steps are to be taken with regard to the other nostril. The patient

I shall now proceed with the description of the organ of tasting, which may be said to reside in all the soft parts of the mouth, from the lips to the fauces. This, therefore, comprehends the whole of the mouth, which is bounded by the lips anteriorly, the velum palati, F, *f*, in Figs. 1 of Plates LXXII., LXXIII., and LXXIV., by the cheeks laterally, by the palate superiorly, and by the tongue and inferior maxilla inferiorly. All this surface is lined with a soft vascular mucous membrane, immediately beneath which a profusion of small mucous glands are situated. This mucous membrane is an extension of the cutis vera, modified to perform this other function, and is also covered by the cuticle. The osseous structure of the mouth is formed by the superior maxillary, the palate, and the inferior maxillary bones, together with the teeth. In Fig. 3 of Plate LXXIII., the lips are everted, and several of the glands, which are named labial, are represented by a removal of the mucous membrane; these are marked *u* in the upper lip, and *l* in the lower lip; and in the red part of the lip, they are so small as to appear delicate villi. The frenum of the upper lip is marked *f*, and that of the lower lip f, and each of them is an extension of the mucous membrane with some degree of muscularity, which adheres to the alveolar processes, between the mesial incisive teeth. The glands, which are situated between the mucous membrane and the buccinator muscles, are precisely of the same order and nature, and are named buccal. Those on the palate, both on the hard marked V, in Fig. 1 of Plate LXXIII., and on the soft palate, F, are termed palatine.

The gums investing the alveolar processes on each side, and surrounding the neck of each tooth, to which they adhere, are formed of a compact interstitial substance, thick in consistence, and very vascular. They run into, or unite with, the mucous membrane and the periosteum.

The tongue, which is the chief organ of tasting, consists of muscles, glands, nerves, blood-vessels, and absorbents. The muscles have been already described.

In Fig. 1 of Plate LXXIII., the tongue is represented *in situ*, and is described as having a root, which is connected by muscles with the os hyoides, X, and epiglottis, Q, as delineated in Fig. 2 of Plate LXXVI., in which plate other views of this organ are also depicted; as having a body or middle part of the tongue, an apex or tip, A, a dorsum or convex surface, D, two sides or margins, S, and an inferior surface, extending from its middle to the apex, which has the frænum linguæ extending along it from the apex to the symphysis of the inferior maxillary bone. The lining mucous membrane of the mouth, of which the frænum is a doubling, surrounds the whole tongue, and connects loosely its sides to the inferior maxillary bone, so that we have here also a continuation or extension of the integuments; the cuticle being

---

will be able to breathe through the mouth. See Lizars' Practical Surgery, Part II. p. 92.

Polypous growths frequently shoot from the superior spongy bones, and from every part of the mucous membrane of the nares. The distinctions of the various kinds of polypi, as adopted by Pott, appear, as the late Mr. J. Bell says, to be either unintelligible or nugatory, since they become malignant and fatal from the pressure they produce on the contiguous parts. For, "Polypus," as Mr. Bell justly observes, "is one of the most loathsome and fatal diseases. It is described in terms little suited to convey this idea to the young surgeon, who, while he reads a systematic author, or hears a lecturer talk in slight and familiar terms of the disease, and its cure, little suspects the dismal scenes which are passing in the chambers of the sick, and puts his hand, with little forethought or prudence, to operations the most difficult for a man of experience, the most impossible for an unskilful person to perform."

In all cases of polypi, where it can be accomplished, they should be removed by forceps. The tumour may be seized with a hook, when the forceps, opened over the tumour, a limb being on each side of it, are to be carried along to the root, which is then to be bruised and cautiously pulled away. The bleeding to be stemmed with lint. Where this line of practice cannot be pursued, the tumour should be removed by ligature. When ligatures are employed, that of catgut, or silver-wire, is applied, by means of a double canula; and this is the best remedy where polypi project and hang down the pharynx. After the tumour is removed, either by forceps or ligature, the root of the polypus should be touched with caustic for several times, in order to stunt its growth. The caustic produces some irritation. Caustic, used as the sole means, is much too inefficient, and produces too much irritation. I have witnessed violent headache and smart fever induced by its application. The knife, either the common scalpel, or that recommended by Mr. John Bell, is exceedingly difficult of being applied. I have witnessed that great and dexterous surgeon even foiled in its application.

When polypi, or sarcomatous tumours, grow in the antrum, they either force their way into the nares, up into the orbit, or out towards the cheek, or in all these directions. "More frequently," says Mr. John Bell, "the upper jaw-bone is destroyed; the tumour makes its way into the antrum; the whole upper jaw-bone becomes carious; the teeth drop from their places; and a fœtid matter distils from their sockets; and the patient dies, wasted by pain and hæmorrhagy."

All the cases that have come within my own knowledge (with the exception of one) wherein these sarcomatous tumours have been removed by laying open the antrum, have either returned, or terminated fatally. I am therefore decidedly of opinion, that unless we remove the whole diseased surface, which can only be done by taking away the entire superior maxillary bone, we merely tamper with the disease, put our patient to excruciating suffering, and ultimately to death. An incision should be made through the cheek, from the angle of the mouth backwards or iniad to the masseter muscle, carefully avoiding the parotid duct, then the lining membrane of the mouth divided, and the soft parts separated from the bone upwards to the floor of the orbit; thirdly, the half of the velum palati detached from the palate-bone. Having thus divested the bone to be removed of its soft coverings, the mesial incisive tooth of the affected side is to be removed; then the one superior maxillary bone to be separated from the other, at the mystachial and longitudinal palatine sutures, and also the one palate-bone from the other, at the same palatine suture, as the latter bone will require to be removed either by cutting pliers or the saw; thirdly, the nasal process of the superior maxillary bone should be cut across with the pliers; fourthly, its malar process, where it joins the cheek-bone; fifthly, the eye with its muscles and cellular cushion being carefully held up by a spatula, the floor of the orbit is to be cleared of its soft connexions, and the superior maxillary bone separated from the lacrymal and ethmoid bones with a strong scalpel. The only objects now holding the diseased mass, are the pterygoid processes of the sphenoid bone with the pterygoid muscles. These bony processes will readily yield by depressing or shaking the anterior part of the bone, or they may be divided by the pliers, and the muscles cut with the knife. The bone, or bones, are frequently so soft in this disease, as to be easily cut with a knife or scissors. After the bone with its diseased tumour has been removed, the flap is to be carefully replaced, and the wound in the cheek held together by one or two stitches. In no other way do I see that this formidable disease can be eradicated, and those who have had the misery to witness the exposure of the antrum by laying open the cheek, and the alternate cutting and cauterizing, and afterwards the protracted treatment by the cautery, the inflammation, the offensive suppuration, and the hectic fever which supervene, and ultimately carry off the patient, will listen to any means which hold out a prospect of a happier result. Two formidable objections exist against the present mode of operating; the one is the exposure of the mucous surface of the antrum to the cold external air, which invariably inflames it, and frequently involves the whole face and head in erysipelas; the other is the leaving the roots of the disease: whereas in the operation proposed, only the small ethmoidal and palatine cells may be exposed, but not necessarily so, and even if exposed, they are only so for a few seconds, as they are speedily covered by the flap. Again, instead of being compelled to lay open the wounded antrum day after day, we at once cover the cut surface, and endeavour to heal it by the first intention, but if not, by suppuration. See Lizars' Practical Surgery, Part II., page 99.

exceedingly thin, the corpus mucosum very thick and moist, and the cutis vera affording origin to the papillæ. On the upper surface, or dorsum, is seen a longitudinal line, named linea mediana, or middle groove, marked D, in Fig. 3 of Plate LXXVI., at the commencement of which, near the root, is perceived a foramen, marked *h*, in Fig. 1 of Plate LXXIII., and in Fig. 3 of Plate LXXVI., named the foramen cœcum of Morgagni, and there are observed a multiplicity of small glandular papillæ, which are arranged into three series, according to their magnitude. The largest series are observed to extend on each side from the foramen cœcum, *h*, so as to form nearly a right angle, the apex pointing to the root, and the part of the root of the tongue posterior to this aperture to be studded over with them. In Fig. 1 of Plate LXXIII., this angle approaches to the acute, while in Fig. 3 of Plate LXXVI., it approximates an obtuse angle. This largest series of glands are of a lenticular form, are situated in shallow fossulæ, and have distinct little foramina in the centre of their apices. It is these glands which form the walls of the little foramen cœcum, together with some excretory ducts. This order of papillæ are denominated lenticulares, maximæ capitatæ, or villosæ. Besides these papillæ lentriculares at the root of the tongue, there are a number of mucous lacunæ, or follicles. The second series of papillæ, less in size than the preceding, but larger than the next, are observed scattered over the dorsum at irregular intervals or distances, between the largest series and the apex. These are somewhat of a cylindrical figure, and are named papillæ semi-lenticulares, mediæ, or fungiformes. The third or smallest series of papillæ are observed to be interspersed all over the dorsal surface, are very minute conical points, and are named papillæ minimæ, conicæ, or villosæ.

The nerves which supply the tongue, are the glosso-pharyngeal, the gustatory branches of the inferior maxillary, and the lingual nerves. The glosso-pharyngeal nerve, marked 13, in Figs. 3 and 4 of Plate LXXVI., and also in Plate XV., is described in page 51. The gustatory or lingual branch of the inferior maxillary nerve, marked 32, in the same figures and plates, is also described in page 52. The lingual nerve, marked 3, in the same figures and plates, is likewise described in page 51.

The arteries which supply the tongue are the lingual and facial, described in page 47; and are delineated in Plates LXXVI., LXXVII., and LXXVIII., the lingual being marked *b*, and the fascial *c*.

Fig. 2 of Plate LXXVI., is a vertical section of the tongue, illustrating its delicate glandular and muscular structure.*

Before describing the ear, I cannot but regret the very little attention which is usually paid by medical men to this most important organ; and the reason assigned by them for this neglect is, that its mechanism is extremely complicated and little known, its physiology, and consequently its diseases, still less so, and that even if these latter were known, nothing could be done for their removal, at least in diseases situated in the internal ear. All this may be very true, but instead of deterring us from the study, I think that it ought to be a most powerful incentive to its prosecution. Had physicians, from the complicated structure of the heart, been satisfied that the circulation of the blood should never be discovered, most assuredly it never would; for great discoveries in physiology are never made by chance, but only by patient and persevering investigation can we ever expect to arrive at the truth. If such, then, is the case, and if we are so defective in the physiology of the ear, the importance of the subject should surely stimulate us to a minute and careful study of its anatomy, as the only means by which its physiology and its diseases can be thoroughly understood.

As yet, certainly, we are unacquainted with any means of cure, when the disease is situated in the internal ear; investigation, however, I am convinced, may do much even here; but although it never should, still the knowledge of the anatomy and physiology of the whole will enable us to determine, with great certainty, the exact part of the organ which is diseased.

Having made these few introductory remarks, I shall proceed at once to describe what is known of its anatomy.

This organ of sense is divided into three portions, the

---

* The lips, the gums, the cheeks, and the tongue, from their glandular structure, are very subject to malignant ulceration, to warty excrescences, to various kinds of tumours, and to cancer. The lower lip is more subject to cancer and warty excrescences than the upper lip; and when either of these occur, it should be removed, together with a portion of the lip, in order to have healthy surfaces to unite, and to prevent a return of the disease. The best form of incision is that of the letter v, the apex pointing towards the chin; the part to be removed should be held firm with the fingers of the left hand, and excised with the bistoury, making an incision first on the one side and then on the other. When the part is excised, the coronary arteries bleed freely, but are immediately stemmed by approximating the raw edges by common needles, thrust first through one side of the lip and then the other; and when the needle has transfixed both sides of the wound, a long thick ligature of four threads is to be twined round both ends of the needle, in the form of the figure of 8. From two to three needles are required, according to the extent of the wound, and when they have all been inserted, the ligature may be entwined several times, in order to keep the edges perfectly approximated. Small pieces of lint should be put between the ends of the needles and the skin, to prevent them pricking the skin. The same steps are pursued when operating for hare-lip. The needles should be withdrawn on the third or fourth day. The common sewing needle, as it is much smaller in circumference, is a preferable instrument to the hare-lip pin. See Lizars' Practical Surgery, Part II., page 110.

When tumours are seated on the gums, they frequently affect the bone, so as to require a portion of the latter to be removed. This is easily accomplished on the lower jaw-bone, from its narrowness and more insulated nature, but with more difficulty on the upper maxillary bone. The inferior is oftener the seat of tumours than the superior maxillary bone. When any bleeding occurs, it must be stemmed by the actual cautery. Few or more of the teeth commonly require to be extracted.

Tumours of the cheeks, warty excrescences, and cancerous ulcerations, are very common affections, and one and all of them should be early removed with the knife, as they lay the foundation of loathsome incurable diseases. I have witnessed the smallest warty excrescence imaginable involve the whole face in deep painful cancerous ulceration, rendering the life of the individual most miserable for two or three years, when a little boldness on the part of the surgeon, and fortitude on that of the patient, would have eradicated the evil in a few seconds. In all operations of the face, we have to endeavour to avoid the parotid duct. (See Plate XVIII., letter x.)

The tongue is subject to tumours, to enlargement from mercury, and to cancerous ulceration. When tumours are present, they may be either removed by ligature or the knife. When the tongue is so enlarged as to prevent deglutition, or to threaten suffocation, which sometimes happens from the imprudent use of mercury, and occasionally in small-pox, free longitudinal incisions should be made; and when mercury is the cause, the medicine should be discontinued, and the patient exposed to change of air, have purgative glysters administered, and blood abstracted from the arm, if the incisions in the tongue do not bleed enough. In cancerous ulceration, either the ulcerated surface or the tongue should be ligatured. See Lizars' Practical Surgery, Part II., p. 122.

external, the middle, and the internal; all the views of which are represented in Plates LXXVII. and LXXVIII., Fig. 16 of Plate LXXVII. being an enlarged view of Fig. 6 of the same plate; Figs. 2, 4, 6, 8, 10, 13, and 17, of Plate LXXVIII., being enlarged views of Figs. 1, 3, 5, 7, 9, and 12 of Plate LXXVIII. The enlarged views are only marked.

The external portion, or external ear, consists of cartilage, ligaments, muscles, sebaceous glands, adipose substance, and integuments.

The cartilage, marked A, is named the pinna, and forms the greater part of this external portion, as seen in Fig. 16 of Plate LXXVIII., where the lower pendulous fatty substance has been removed, which is represented in Figs. 1, 2, 3, 4, and 5 of Plate LXXVII., marked B, and termed the lobulus.

The pinna has several elevations and depressions, which are better understood in the perfect ear than in Fig. 16 of Plate LXXVIII., where nothing but this cartilage is present. The elevations are the helix, marked *a*, in Figs. 1, 2, 3, 4, and 5 of Plate LXXVII., and in Fig. 16 of Plate LXXVIII., the antihelix, c, in Figs 1, 2, and 5 of Plate LXXVII., and in Fig. 16 of Plate LXXVIII., the tragus, *e*, and the antitragus, *o*, represented in the same figures.

The helix, letters *a*, in Figs. 1, 2, 3, 4, and 5 of Plate LXXVII., and in Fig. 16 of Plate LXXVIII., forms the boundary of the pinna, running in an arched form, and being turned over, or partially overlapping the general pinna; it begins at the lobulus, B, and runs round from behind forwards, descending into the cavity, named the concha, C, which it partially divides into two. Within the concavity of this helix, there is naturally formed a groove or fossa, named fossa innominata, marked with the letters *i*, in Figs. 1, 2, and 5 of Plates LXXVII., and in Fig. 16 of Plate LXXVIII., and which also begins at the lobulus, and runs around, descending into the concha, C.

Within the circle of the helix, the antihelix, marked c, is situated, which forms the brim or margin of the concha, C, and commences near the antitragus, *o*, ascending and dividing into two crura, marked *c*, *c*, in its course onwards to the fossa innominata, *i*; the lower crus continuing to form the margin of the concha, C. Between the crura, *c*, *c*, of the antihelix, there is formed a depression, marked *n*, named fossa navicularis, or scapha, which communicates with the fossa innominata.

The tragus, marked *e*, is that triangular-looking portion of the pinna, situated anterior or glabellad to the concha, C, which, from being studded with bristly hairs in advanced life, has got its appellation. It is partially separated from the helix by a fissure, marked x, and forms the exterior commencement of the cartilaginous portion of the auditory tube.

The antitragus, *o*, is the triangular portion of the cartilaginous pinna, opposed to the tragus, *e*, and is immediately above the lobulus, B, forming the inferior margin of the concha, C. A fissure, marked w, in Fig. 16 of Plate LXXVIII., is observed to separate this from the helix, *a*.

The concha, marked C, in Figs. 1, 2, and 5 of Plate LXXVII., and in Fig. 16 of Plate LXXVIII., is the large irregularly shaped cavity, bounded by the tragus, *e*, anteriorly, the antitragus, *o*, inferiorly, the antihelix, c, with its inferior crus, *c*, posteriorly and superiorly, and also by the termination of the helix, *a*. The floor of this cup is formed by the general cartilage, as observed in Fig. 4 of Plate LXXVII., which is an outer or posterior view of the external ear. The concha, C, leads directly to the meatus auditorius externus, *m*, or the cartilaginous portion of the tube, which tubular portion, marked *p*, in Fig. 5 of Plate LXXVII., is laid open to show its extent, from the external aperture down to the membrana tympani, *r*. This cartilaginous portion, *p*, is seen to be of some length, to have an oblique direction downwards and forwards, or basilad and glabellad, and to be fixed on the scabrous auditory process of the temporal bone, the osseous continuation of which is here also laid open downwards to the membrana tympani. This tubular portion of the ear has a number of ceruminous glands situated within it, and is also studded with delicate hairs.*

On looking at the outer or posterior aspect of the pinna, we observe several fossæ, as delineated in Fig. 4 of Plate LXXVII., which are evidently the depressions formed by the elevations on the anterior aspect. The fissures between the portions of the pinna are, one between the helix, *a*, and tragus, *e*, as delineated in Fig. 16 of Plate LXXVIII., marked T, another between the helix, *a*, and the antitragus, *o*, marked w, and a third at the base of the tragus, marked x. Across these fissures there extend remarkably delicate ligaments, so delicate that they are scarcely capable of representation.

The muscles which operate on this cartilage are very numerous.

The levator vel attollens aurem,† delineated in Plate XVIII., marked r; also in Figs. 1 and 2 of Pl. LXXVII., is situated on the lateral aspect of the cranium, immediately beneath the integuments, with which it is very liable to be lifted up when displaying it. This muscle consists of a delicate assemblage of scattered muscular fibres, which originate from the expansive tendon of the occipito-frontalis muscle, q, and descend to be inserted in the upper or coronal aspect of the back or dorsum of the cartilage, which forms the fossa navicularis, the fibres ascending upwards to the dorsum of the helix. The function of this muscle is to elevate the cartilage or pinna, upwards and forwards, or coronad and glabellad; and also to operate on the fossa navicularis.

The anterior auris muscle,‡ marked D, in Figs. 1 and 2 of Plate LXXVII., situated between the cheek-bone and the external cartilage of the ear, derives its origin from the zygomatic process, W, of the temporal bone, and after a short course, is inserted in a small eminence, marked *d*, in Fig. 16 of Plate LXXVIII., on the dorsum, or back part of the helix. Its function is to pull forwards or

---

* Its oblique direction and length should be well considered with regard to syringing the ear, when clogged up with hardened wax or in a state of suppuration, and also when affected with polypus. When the last affection is present, the tumour should be laid hold of with a small hook, and gently elongated, and then a pair of delicate blunt-pointed scissors are to be glided along the tumour to its pedicle or root, with which it is to be divided. Little or no bleeding follows, and to prevent or stunt the growth of the polypus, it should be touched with the nitrate of silver, for several days successively. See Lizars' Practical Surgery, Part II., p. 133.

† Syn. Auriculæ primus. Primus propriorum auriculæ. Portio musculi frontalis supra crotaphitam ad aurem producti. Attollens auriculæ. Attollens auriculam. Superior auriculæ. Le premier de l'oreille. Le premier et le second mitoyen. Le muscle supérieur de l'oreille. Temporo-auriculaire. Temporo-conchinien.

‡ Syn. Auriculæ musculus anterior. L'antérieur de l'oreille. Musculus novus conchæ proprius. Prior auriculæ. Zigomato-oriculaire. Zigomato-conchinien.

glabellad, and a little upwards or coronad, the external cartilage of the ear, and to widen or expand the fossa innominata.

The retrahens vel retrahentes auris muscle,* marked with the letters R, in Fig. 3 of Plate LXXVII., situated behind the external cartilage of the ear, consists of two or more fleshy slips, which originate from the mastoid process of the temporal bone, superficially to the tendinous insertion of the sterno-cleido-mastoideus, and the origin of the posterior fleshy belly of the occipito-frontalis, and extend nearly horizontally, converging to a point, to be inserted in the dorsum of the cartilage forming the concha. Its function is to pull backwards or iniad the external cartilage, and to widen or expand the concha.

The helicis major muscle,† marked H, in Fig. 2 of Plate LXXVII., situated on the convex margin of the helix, where it runs round and down into the concha, is an extremely small muscle, which derives its origin from the helix within the concha, and ascends on its acute convex edge, nearly to the highest aspect, where it is lost. Its function is to depress that portion of the helix, in which it is inserted, and by this to dilate the fossa innominata. It may also elevate that portion of the helix, from which it arises, and hence also dilate the fossa innominata.

The helicis minor muscle,‡ marked *h*, in Fig. 2 of Plate LXXVII., is situated nearer the antihelix than the major, and derives its origin from nearly the acute margin of the helix within the concha, and ascends a shorter way along the flat exterior surface of the helix, on which its fibres are lost. Its function is to assist the helicis major.

The tragicus muscle,§ marked T, in Fig. 2 of Plate LXXVII., is situated on the anterior and outer surface of the tragus, *e*, from the root of which it arises, and ascends to be inserted in its apex. Its function is to pull the tragus forwards, and to widen or expand the concha, C, in that direction.

The antitragicus muscle, ‖ marked *t*, in Fig. 2 of Plate LXXVII., situated on the antitragus, *o*, derives its origin from the commencement of the antihelix, c, and runs along the antitragus, *o*, to its apex. Its function is to pull the antitragus backwards or iniad, so as to widen or expand the concha, C, in that direction. It may also pull the antihelix to the antitragus, so as to raise up that portion of the margin of the concha.

The transversus auris muscle, ¶ marked U, in Fig. 4 of Plate LXXVII., situated on the dorsum of the external cartilage of the ear, is a scattered assemblage of muscular fibres, deriving their origin from the superior or coronal aspect of that portion which forms the concha, and passing across the fossa made by the antihelix, they are inserted in the dorsum of the helix. Its function is to pull backwards and downwards the helix and antihelix, and thus to dilate and expand the fossa innominata and navicularis. It will also raise the acute margin of the helix, so as to open the fossa innominata.

* Syn. Secundus auriculæ. Secundus propriorum auriculæ. Proprius auris externæ. Le second de l'oreille. Retrahens auriculam. Posteriores auriculæ. Posteriores auriculæ et postici corrugatores. Tres retrahentes auriculæ. Le postérieur de l'oreille. Mastoïdo-oriculaire. Mastoïdo-conchinien.

† Syn. Helicis musculus. Major helicis. Helix.

‡ Syn. Fibræ musculares in plana helicis facie. Minor helicis. Concho-helix.

§ Syn. Musculus tragi. Concho-tragique.

‖ Syn. Musculus antitragi. Antheli-tragique.

¶ Syn. Sunt fibræ transversæ in gibbo auriculæ. Fibræ, quæ in convexa conchæ parte. Transversus auriculæ. Concho-anthelix.

This external cartilage, with its muscles, has a number of sebaceous glands imbedded in the integuments investing it, the secretion of which is best exemplified in the fossa innominata, where from inattention it frequently becomes vitiated.

After the description of the external, I shall proceed to that of the middle portion of the ear, which consists of the tympanum, mastoid cells, and Eustachian tube, the tympanic cavity being represented in Figs. 6, 9, and 16 of Plate LXXVII., marked t, the mastoid cells m, and the Eustachian tube Z, in Fig. 5 of the same plate. Fig. 16 is an enlarged view of Fig. 6.

The tympanic cavity, t, Figs. 6 and 16 of Plate LXXVII., of an irregular circular figure, is bounded outwardly or peripherad by the membrana tympani, *r*, Fig. 5 of Plate LXXVII., and in Figs. 1, 2, 3, and 4 of Plate LXXVIII. It is bounded inwards or centrad by an osseous partition between it and the vestibular cavity, which is seen in Figs. 6 and 16 of Plate LXXVII., having the foramen ovale, o, and the foramen rotundum, r, formed in it, which in the recent state, are filled up by the extension of delicate membranes, and are then named fenestræ; it is bounded on its anterior or glabello-basilar aspect, with bone, but having a free communication with the posterior aperture of the nares and pharynx, through the medium of the Eustachian tube, z, in Fig. 5 of Plate LXXVII.; and it is bounded on its posterior or inial aspect also by bone, having a free communication with the mastoid cells, m, Fig. 6 of Plate LXXVII. This tympanic cavity is invested with a delicate mucous membrane, which may be said to be a continuation of that of the nares and pharynx, extending along the Eustachian tube, and in this cavity are contained the ossicula auditus, as represented in Fig. 7 of Plate LXXVII., and in Figs. 1, 2, 3, 4, 5, and 6 of Plate LXXVIII.

The membrana tympani, *r*, Figs. 5 and 8 of Plate LXXVII., and Figs. 1, 2, 3, and 4 of Plate LXXVIII., situated obliquely at the bottom of the auditory tube, and forming the outer or peripheral wall of the tympanic cavity, adheres to a delicate projecting ring of the bone, of an oval circular shape, marked *a*, in Fig. 8 of Plate LXXVII., and consists of two laminæ, or membranes, the one being an extension of the cuticle from the auditory tube, the other an extension of the mucous membrane or periosteum, which invests the tympanic cavity. In early life it is beautifully radiated and very vascular, as represented in Fig. 8 of Plate LXXVII.; and in the fetal condition, there is an adventitious membrane exterior to the membrana tympani, named membrana mucosa, which on investigation is found to consist of two layers united at their margins, so as to constitute a membranous pouch, containing a whitish-coloured flaky fluid. To the membrana tympani, the handle, 5, of the malleus is attached. Figs. 8 and 7 of Plate LXXVII. are interior or central views, and therefore the handle is marked, while Fig. 5 of Plate LXXVII., and Figs. 1, 2, 3, and 4 of Plate LXXVIII. are exterior or peripheral views of the membrane, where the handle of the bone only shines through, and is therefore not marked. The other long process seen running parallel with the handle of the malleus, in some of these figures, is the long crus of the incus, which does not adhere to the membrane, and is consequently more faintly drawn.*

* The situation, connexion, and obliquity of the membrani tympani, require to be considered by the operator, as it is sometimes requisite to

The anterior or glabello-basilar wall is extremely short or low, and has the Eustachian tube, z, opening into it. This tube is partly osseous and partly cartilaginous, as best illustrated in Figs. 1 and 2 of Plate LXXVIII., the small Roman z being placed on the cartilaginous portion, while the Roman capital Z is placed on the osseous, the outer wall of which is necessarily broken up. The same Roman capital is used in the mere osseous preparations of Figs. 6 and 7 of Plate LXXVII. This tube begins small in the tympanum, and gradually swells in diameter, till its termination at the posterior aperture of the nares, as seen in Fig. 1 of Plate LXXIV.; and in this course is attached to the basilar surface of the petrous portion of the temporal bone. The cartilaginous portion is very delicate in some points; and the whole tube is lined with a mucous membrane, which may be said to be the continuation of that of the nares and pharynx.* In the osseous state, there is another tube opening into the tympanic cavity, viz. the semi-osseous canal of the tensor tympani muscle, marked 1**, in Figs. 6 and 16. This tube is also indicated by the bristle marked 1, in Fig. 6 of Plate LXXVII., and is distinguished from that of the Eustachian tube, by being a degree smaller in calibre, and more centrad and coronad, or internal. On looking along the petrous portion into the tympanum, at these two canals, we observe only a delicate osseous lamina, partially separating them, for they communicate superiorly and laterally, or corono-laterad, the bone forming one arch over the two. In the recent state, the tensor tympani muscle, marked q, in Figs. 1 and 2 of Plate LXXVIII., at once indicates it.

The posterior wall of this tympanic cavity is equally as short or low as the anterior, and has a large aperture, which leads directly to the mastoid cells, m. In Fig. 6 of Plate LXXVII., the small osseous bridge, which forms this aperture, is left, while in Fig. 7 of the same plate, it is removed, the mastoid cells and tympanic cavity being thrown into one. These cells vary very much in different crania, some being large and few in number, while others are small and numerous: the latter of which is the case in Fig. 1 of Plate LXXVIII. They are lined with the mucous membrane common to the tympanic cavity and Eustachian tube.†

In the osseous state, there are many objects on the central or inner wall, or bottom of the tympanic cavity; the foramen ovale, marked o, in Fig. 6 and 16 of Plate LXXVII., situated nearly in the centre, leads directly into the vestibular cavity; but in the recent state it is filled up with a membrane, an extension of the vascular periosteum, or mucous membrane of the cavity, and to the tympanic aspect of this membrane, now named fenestra, the base, *w*, of the stapes, one of the ossicula auditus, is fixed. This bone is represented *in situ*, in Fig. 9 of Plate LXXVII., and in Figs. 9 and 10 of Pl. LXXVIII.

The foramen rotundum, r, which leads from the tympanum into the tympanic scala of the cochlea, is situated immediately beneath or basilad, and nearer the entrance to the mastoid cells, as represented in Figs. 6 and 16 of Plate LXXVII., and in Figs. 9, 10, 12, and 13 of Plate LXXVIII. This, like the foramen ovale, has an extension of the vascular periosteum, or mucous membrane of the tympanum, stretched to its margin, so as to form a fenestra.

Close to the inial or posterior elliptical margin of the foramen ovale, and nearer the mastoid cells than the latter, the osseous hollow pyramid, marked p, in Figs. 6, 9, and 16 of Plate LXXVII., and in Figs. 7, 8, 9, and 10 of Plate LXXVIII., is situated. This gives exit to the stapedius muscle, marked s, in Figs. 9 and 10 of Plate LXXVIII., and to the chorda tympani nerve, marked 33, in Figs. 7, 8, 5, and 6 of Plate LXXVIII. In Fig. 6 of Plate LXXVII., a bristle, marked 2, is inserted in the Fallopian aqueduct, A, and brought out at the osseous pyramid, p, to show the manner in which the facial nerve runs this length, and gives origin to the chorda tympani twig. This Fallopian aqueduct, or canal, A, in its course exterior to the central wall of the tympanum, makes a slight elevation immediately above, or coronad of the foramen ovale; and as this canal lodges the facial nerve, its course and manner of elevation are better understood by comparing Figs. 6 and 16 of Plate LXXVII. with Figs. 9 and 10 of Plate LXXVIII., where the facial nerve is marked 44. In Fig. 16 of Plate LXXVII., a bristle, marked 2, is inserted in this aqueduct, at the foramen stylo-mastoideum, and two dotted lines are drawn in continuation; the one, marked 33, proceeds to the pyramid, p, while the other, marked A, indicates the course of the facial nerve. Precisely above, or coronad and somewhat iniad, near the beginning of the passage to the mastoid cells, a small protuberance, marked *c*, in Fig. 16 of Plate LXXVII., is seen, which is made by the external or horizontal semicircular canal. This elevation will be better understood by comparing Fig. 16 of Plate LXXVII. with Figs. 9 and 10 of Plate LXXVIII., where *c* indicates the canal.

Between the foramen ovale and rotundum, there is an elevation observable, named the promontory, marked *a*, in Fig. 16 of Plate LXXVII., which is caused by the vestibular cavity and the commencement of the cochlea. This elevation will be more easily comprehended by comparing this figure of Plate LXXVII. with Fig. 12 of Plate LXXVIII., where C indicates the cochlea and V the vestibule.

Within this tympanic cavity are contained the ossicula auditus, the malleus, the incus, and the stapes. These are represented *in situ*, in Figs. 7 and 8 of Plate LXXVII., and in Figs. 1, 2, 3, 4, 5, 6, and 15 of Plate LXXVIII., and separately in Plate LXXVII., where Figs. 11 and 12 indicate the malleus, 13 and 14 the incus, and 15 the stapes.

---

pierce it for deafness. This can only be requisite when the membrane is exceedingly thickened from disease, or the Eustachian tube obstructed by disease, or when both occur. This little delicate operation may be performed, either simply, with a stilet, curved to the shape of the auditory tube, or with a trocar and canula of the same shape; the latter is the preferable instrument, and should be cautiously introduced, having the trocar sheathed in the canula, till the latter meets with resistance from the membrane, which is known by the yielding springing resistance felt, and then the trocar is to be pushed along the canula to puncture the membrane. The loud sound felt by the patient informs the operator that he has succeeded. See Lizars' Practical Surgery, Part II., page 136.

* When the Eustachian tube is inflamed, it should be treated by inhaling the vapour of hot water, or by inserting a tube along the nares, into its aperture in the pharynx, and having fitted a syringe to this tube, by injecting warm water into the Eustachian trumpet. The same means should be employed when this tube is obstructed; or a probe may be introduced from the nares along it. See Lizars' Practical Surgery, Part II., page 137.

† The mucous membrane of the mastoid cells is subject to inflammation and suppuration, particularly in early life; and when an abscess is ascertained, the matter must be evacuated, by making a crucial incision over the mastoid process, applying a small trephine, and giving exit to the matter.

The malleus (Figs. 11 and 12 of Plate LXXVII., Fig. 11 being an internal or central view, and 12 an external or peripheral view, and both being bones belonging to the right side) is situated in the tympanic cavity, having some faint resemblance to a hammer, and is described as having a head, marked 1*, a cervix, 2, a long slender process, 3, a short process, 4, and a handle, 5. The head has a double articulating surface, with a slight depression or groove dividing it, by which it is joined to the body, 6*, of the incus. In the cervix, near the short process, the laxator tympani minor muscle, marked l, in Figs. 3 and 4 of Plate LXXVIII., is inserted. The long slender process, 3, rests in the fissure of Glasserus, and in it is inserted the laxator tympani major muscle, marked L, in Figs. 1 and 2 of Plate LXXVIII. In the handle of the bone, near this long slender process, is inserted the tensor tympani muscle, marked q, in Figs. 1, 2, 3, 4, and 15 of Plate LXXVIII. The short process itself adheres to the membrana tympani. The handle, 5, of the malleus, adheres to the membrana tympani, *r*, as represented in Fig. 8 of Plate LXXVII., and in Figs. 1, 2, 3, 4, and 16 of Plate LXXVIII. The malleus is hollow, like the long cylindrical bones.

The incus, Figs. 13 and 14 of Plate LXXVII., the former being an internal or central view, and the latter, or 14, an external or peripheral view, and belonging to the right ear, is situated within the tympanic cavity, and consists of a body, 6*, a long crus, 8, and a short crus, 7*. The body has an articular surface to correspond with that of the head of the malleus, with which it is connected by a delicate capsular ligament. The short crus, 7*, rests in the aperture leading to the mastoid cells, as represented in Figs. 7 and 8 of Plate LXXVII., and in Figs. 3, 4, 5, 6, and 15 of Plate LXXVIII., and its long crus, 8, runs somewhat parallel to the handle of the malleus, downwards and inwards, or basilad and centrad, in the tympanic cavity, as delineated in Figs. 3, 4, 5, and 6 of Plate LXXVIII., its extremity giving rest to the apex, 17, of the stapes, as seen in Fig. 8 of Plate LXXVII.

This end or small projection of the long crus of the incus, is considered by some anatomists as a distinct bone, and named os orbiculare. The incus is hollow internally.

The stapes, Fig. 15 in Plate LXXVII., situated in the cavity of the tympanum, consists of a base, marked *w*, which corresponds in shape with the foramen ovale, the upper or coronal edge or margin being semicircular, while the lower or basilar is nearly straight, and is attached to the fenestra ovalis, as represented in Fig. 9 of Plate LXXVII., and in Figs. 9 and 10 of Plate LXXVIII.; it consists of two crura, a long one, 10, looking backwards to the mastoid cells, and more curved than the short one, 9, which looks forwards to the Eustachian tube. Both the crura and the base are slightly grooved to receive a delicate membrane, named the membrane of the stapes, which is attached within their arch, as represented in Fig. 15 of Plate LXXVII., marked 18. This bone also consists of an apex or head, 17, resting on the extremity of the long crus of the incus, as depicted in Fig. 8 of Plate LXXVII. To either the long posterior crus or the apex, the stapedius muscle, s, is attached, as delineated in Figs. 9 and 10 of Plate LXXVIII. The manner in which these ossicula auditus are joined or articulated to each other, is best represented in Fig. 8 of Plate LXXVII., this being a drawing of the fetal temporal bone.*

To enable these little bones to perform their motions, there are four muscles attached to them, viz. the tensor tympani, the laxator tympani major, the laxator tympani minor, and the stapedius.

The tensor tympani muscle,† marked q, in Figs. 1, 2, 3, 4, 7, 8, and 15 of Plate LXXVIII., situated partly without and partly within the tympanic cavity, derives a broad and fleshy origin from the styloid process of the sphenoid bone, where the spinous artery of the dura mater enters, from the superior border of the cartilaginous extremity of the Eustachian tube, and runs backwards or iniad along the osseous portion of the tube, and in its own semi-osseous canal, where, becoming tendinous, it enters the tympanic cavity, running backwards to be inserted internally or centrad in the handle of the malleus, and on the aspect opposite to the membrana tympani, near its long process. When the muscle leaves its semi-osseous canal, marked 1**, in Figs. 1 and 2 of Plate LXXVIII., it makes a turn backwards into the tympanum: its course and insertion are distinctly seen in Figs. 7 and 8 of Plate LXXVIII., where the malleus and incus are thrown outwards and downwards, or peripherad and basilad. Its function is to pull the malleus and membrana tympani inwards or centrad, and thus render its external or peripheral surface concave. It pushes the stapes against the membrana fenestræ ovalis, diminishes the vestibular cavity, and thus tenses all the membranes of the labyrinth.

The laxator tympani major‡ muscle, marked L, in Figs. 1, 2, and 16 of Plate LXXVIII., situated partly without and partly within the tympanic cavity, derives a fleshy origin from the styloid process of the sphenoid bone, and runs backwards, and becoming tendinous, it enters the tympanum at the fissure of Glasserus, to be inserted in the long slender process of the malleus, where the latter rests in this fissure. Its function is to pull the handle of the malleus forwards, upwards, and inwards, or glabellad, coronad, and centrad, and by this to tense the membrana tympani in these directions; and also to tense the other membranes inwards and forwards.

The laxator tympani minor§ muscle, marked l, in Figs. 3 and 4 of Plate LXXVIII., situated at the superior or coronal aspect of the membrana tympani, lying in a fine duplicature of the periosteum of the tympanum, derives its origin from the superior, posterior, or coronoinial margin of the meatus auditorius externus, where the membrana tympani adheres to it, and descends forwards and outwards, or glabellad and peripherad, to be inserted in the neck of the malleus near its short process. Its function is to pull the handle of the malleus backwards, upwards, and inwards, or iniad, coronad, and centrad, and thus to tense the membrana tympani in these directions,

* The ossicula auditus are occasionally discharged in suppuration of the mucous membrane lining the tympanic cavity, accompanied with ulceration of the membrana tympani.

† Syn. Musculus ossiculi malleo comparati. Musculus malleum ad incudem movens. Auris internæ secundus, qui ab osse cuneiformi prognatus. Alter internus et in concha latitans. Musculus internus auris. Internus mallei. Le second de ceux qui apartiennent au marteau, et l'externe. Musculus majoris processus. Le monogastrique. Le muscle interne de marteau. Salpingo-malléen. Auris membranarum tensor.

‡ Syn. Auris internæ externus. Externus mallei. Externus auris vel laxator externus. Musculus processus minoris mallei. Le muscle externe ou supérieur du marteau. Acoustico-malléen. Auris membranarum in anteriora et interiora tendens.

§ Syn. Auris membranarum in posteriora et interiora tendens.

and also to tense all the membranes backwards and inwards, or iniad and centrad.

The stapedius muscle,* marked s, in Figs. 9 and 10 of Plate LXXVIII., situated in the posterior aspect of the tympanic cavity, arises by two origins, the one within the Fallopian aqueduct, the other from the hollow osseous pyramid of the tympanum; these uniting, run forwards and outwards, or glabellad and peripherad, to be inserted in the posterior or inial aspect of the apex or head of the stapes, and sometimes in the posterior crus of this bone. Its function is to pull the apex or head of the stapes outwards and backwards, or peripherad and iniad, and thus to relax the membrana tympani, and membrana fenestræ ovalis, and also to enlarge the vestibular cavity, and relax all the membranes of the labyrinth.

I shall now proceed to the description of the proper internal portion of the ear, or what is named the labyrinth, which is divided into the vestibulum, the three semicircular canals, and the cochlea. These three portions are represented *in situ*, in Fig. 7 of Plate LXXVII., and in connexion with each other, but removed from the temporal bone in Fig. 10 of the same plate; and also in Figs. 12, 13, and 15 of Plate LXXVIII., the cochlea being marked C, the vestibule v, and the three semicircular canals *c*, *p*, *o*.

We observe in Fig. 6 of Plate LXXVII., in the dry osseous state, when the stapes is removed, that the foramen ovale, o, leads directly into the vestibular cavity. The same is represented in Fig. 10 of the same plate, the letter v indicating the foramen ovale, which leads directly into the vestibule. When the stapes is left *in situ*, its base, *w*, shuts up this foramen, as represented in Fig. 9 of Plate LXXVII., and in Figs. 9 and 10 of Plate LXXVIII. When the partition between the tympanic and vestibular cavities, in which this foramen ovale is situated, is removed, and the vestibule laid open, as in Figs. 12, 13, and 17 of Plate LXXVIII., marked v, it is observed to be somewhat of an oval circular form, having several foramina opening into it. In these figures, particularly 13 and 17 of Plate LXXVIII., it is larger than in nature. This cavity is invested with its periosteum, within which is found a delicate pulpy membrane, a watery fluid, and the expansion of part of the auditory nerve. At the posterior or central wall, this nerve enters by a number of delicate filaments, which makes the dried bone have a sieve-like appearance, when held between the eye and the light, and therefore named macula cribrosa. The internal auditory foramen, by which the nerve enters, is immediately behind. This macula cribrosa is subdivided into two surfaces, which are named from their shape cavitas semi-ovalis, marked *s*, in Fig. 17 of Plate LXXVIII., and cavitas hemispherica, marked *h*, in the same figure. A third cavitas is described by authors, named sulciformis, marked *f*, in the same figure, which is merely the commencement of the aqueduct of the vestibule, that is situated near the tubulus osseus communis, marked *p-o*, of the superior and posterior semicircular canals. This aqueduct of the vestibule proceeds through the bone, and opens about half an inch behind or iniad to the foramen auditorium internum in the adult, in a small pouch between the dura mater and the bone. The external aperture is marked K, in Fig. 14 of Plate LXXVIII Contiguous to the cavitas semi-ovalis, *s*, a small projection is seen, marked G, which is named the osseous pyramid of the vestibule. The cochlea communicates with the anterior aspect of the vestibule, by a large aperture, as represented in Figs. 12 and 13 of Plate LXXVIII., marked *w**, and the three semicircular canals open or terminate by five apertures in the posterior aspect of the vestibule, as delineated in the same figures.

The three semicircular canals, marked *p*, *c*, and *o*, in Figs. 7 and 10 of Plate LXXVII., and in Figs. 3, 4, 5, 6, 7, 8, 9, 10, 12, 13, and 15 of Plate LXXVIII., are situated posteriorly or iniad to the vestibule, each forming nearly three-fourths of a circle, being remarkably equal in their circumference, having a gently waving or undulating appearance, and so placed as to catch every direction of sound; thus one of them, marked *p*, is placed superiorly or vertically, or across the petrous portion, its convexity constituting the most elevated point of this part of the bone, its edge being turned forwards, and is termed the superior or vertical canal; the one aperture is more expanded than the other, which expansion or dilatation is named the ampulla, marked P, in Fig. 13 of Plate LXXVIII.; its other or central extremity, or aperture, joins or communicates with the superior or coronal one of the ends of the posterior or oblique canal, *o*, forming the tubulus osseus communis, marked *p-o*, in the same figure. Another of these semicircular canals, *o*, is placed perpendicularly oblique, so that its side is turned forwards, its one or superior extremity joining the vertical canal, *p*, to form the tubulus osseus communis, *p-o*, its other extremity being dilated to form its ampulla, marked o, in Fig. 13 of Plate LXXVIII.: this is styled the oblique or internal canal. The third canal, *c*, is placed horizontally, and is named the horizontal or external, having its ampulla at its superior aperture, marked c, in Fig. 13 of Plate LXXVIII. This last is the least of the three semicircular canals. These semicircular canals are invested in the fresh state with their periosteum, within which is contained the same watery fluid as in the vestibule, and a delicate pulpy membrane, on which is expanded part of the auditory nerve.

The cochlea, marked C, in Figs. 7 and 10 of Plate LXXVII., and in Figs. 3, 4, 5, 6, 7, 8, 9, 10, 11, 12, 13, and 15 of Plate LXXVIII., is situated anteriorly or glabellad to the vestibule, v, having its base looking inwardly or centrad towards the foramen auditorium internum, which it touches, and its apex looking outwardly or peripherad towards the tympanum and Eustachian tube; it is a spiral volute of two gyri, or turns, and a half, formed by the petrous portion, and divided partially by a delicate semi-osseous lamina, that winds round a central pillar, as satisfactorily illustrated in Fig. 11 of Plate LXXVIII. In this figure, which is a magnified view, the letters C indicate the petrous portion forming the walls of this elegant little figure, which are observed to run towards the modiolus, or central pillar, *m*, so as to constitute the osseous septum, which consists of two laminæ, and divides the gyri; those having an asterisk * after the C, point particularly to this septum The letters *m* point out the central pillar, or modiolus, which extends from the base upwards to the middle of the second turn, and which consists of two thin laminæ, or plates, that are hollow and foraminular, in order to allow the delicate threads of the auditory nerve to pass through. The hollow tube of the modiolus is named the tractus foraminu-

* Syn. Le muscle de l'étrier. Musculus stapidis. Stapedis musculus. Stapidæus vel musculus stapedis. Le second muscle de l'oreille interne que nous appellons petit. Pyramido-stapidien. Auris membranarum laxator.

losus. Around this modiolus, *m*, winds the delicate lamina spiralis, or septum scalarum, *l*, which commences at the base, and terminates at the apex, in a small hook-like point, named the hamulus laminæ spiralis, *g*. This lamina, which is foraminular, and consists of two plates, divides the gyri, or turns, into two open tubes or scalæ, and therefore does not touch the sides or walls, C, of the cochlea, in the dried state; but in the fresh state this partition is completed, by an extension of a delicate pulpy membrane from this lamina, *l*, to the walls, C, of the cochlea, which is termed the zona mollis, and upon it, as also the lamina spiralis, the delicate threads of the auditory nerve are expanded. These two tubes, or scalæ, the one of which commences at the foramen rotundum, r, in Fig. 12 of Plate LXXVIII., is named the external, or tympanic; the other, termed the internal or vestibular, begins in the vestibule, as delineated in Fig. 13, marked *w**, and they both wind round the modiolus, *m*, to the apex, where they communicate freely, through the medium of a small aperture under the hamulus, *g*, styled the canalis scalarum communis, marked *h*. These scalæ are therefore of a conical shape. At the apex there is a small cavity, marked *i*, in Fig. 11, named the infundibulum, the base of which is formed by part of the walls of the cochlea, marked *a*, and termed the cupola, while the apex points to the apex of the modiolus. The foramen rotundum, like the ovale, has a membrane stretched across it, converting it into a fenestra. The cochlea is invested with its periosteum, and a delicate pulpy membrane. Within the tympanic scala, at its commencement, and near the foramen rotundum, a small fossa is perceived, named the sinus fenestræ rotundæ, marked t, in Fig. 17 of Plate LXXVIII., at the bottom of which is the internal opening of the aqueduct of the cochlea, which descends and opens within the cranium, immediately below the meatus auditorius internus. The external aperture is marked *k*, in Fig. 14 of Plate LXXVIII.

The internal auditory foramen, or meatus, is delineated in Fig. 14 of Plate LXXVIII., marked M, m, *b*, being a representation of it in the temporal bone of the right side. At the bottom of this meatus, an osseous ridge, *b*, is observed to divide it in two portions or recesses. The inferior, M, when viewed between the eye and the light, is minutely cribriform, and is opposite the base of the cochlea and the vestibule, or actually forms the floor or base of the cochlea, and nearly the whole of the interior or posterior or central wall of the vestibule; here the auditory nerve enters, by dividing into numerous delicate and minute soft threads, the anterior fasciculus of which are distributed throughout the cochlea, by piercing the anterior or glabellar portion of the cribriform lamina, at the bottom of the meatus auditorius internus, and by ascending the hollow modiolus, or tractus foraminulosus, onwards to the pulpy membrane investing the infundibulum, and in this course piercing the minute foraminular structure, or canaliculi of the modiolis, and between the laminæ constituting the osseous septum, which divides the gyri, and also those of the lamina spiralis, to be distributed over the pulpy membrane investing the lamina spiralis, the cribriform structure of which enables them to be extensively distributed both over it and the zona mollis, and also over all the pulpy membrane investing the sides or walls of the scalæ. Plexiform expansions are formed over the lamina spiralis, and zona mollis. A delicate branch of this fasciculus proceeds laterally from the cochlea to the vestibule. Other threads of this nerve enter the vestibule through the foraminular plate, or maculæ cribrosæ of the cavitas semi-ovalis and sulciformis, to be distributed on the pulpy membranes of the vestibule and the three semicircular canals. These last threads constitute the posterior fasciculus which divides into three branches; the largest presents a gangliform swelling, pierces the macula cribrosa of the cavitas semi-ovalis, and supplies the posterior or central portion of the pulpy membrane investing the vestibule, which is named the alveus communis of the semicircularis canals; this portion also supplies the vertical and horizontal semicircular canals. The middle portion pierces the macula cribrosa of the cavitas hemispherica, to be distributed on the pulpy membrane of the vestibule. The smallest branch pierces the posterior part of the internal auditory foramen, and is distributed on the pulpy membrane investing the oblique canal. The origin of the auditory nerve is described in page 138.

I have here deeply to regret the impossibility of procuring an ear fresh enough to give a representation of the beautiful distribution of the auditory nerve.

The superior recess, m, of the internal auditory meatus, has a distinct round foramen, which is the commencement of the Fallopian aqueduct, that gives passage to the facial nerve. Part of the course of this aqueduct is represented in Fig. 12 of Plate LXXVIII., marked A, and another part in Figs. 6 and 16 of Plate LXXVII., also marked A, and in both of which is inserted a bristle, marked 2. The facial nerve itself, however, is displayed in Figs. 9, 10, 8, 7, 4, 3, 2, and 1 of Plate LXXVIII., marked 44. In Figs. 9 and 10, it is observed running in its aqueduct between the vertical canal, *p*, and the cochlea, C, then between the horizontal canal, *c*, and the stapes, *w*, around the posterior or central wall of the tympanum, downwards in the bone, to emerge at the foramen stylomastoideum, the remainder or continuation of this nerve being described in page 52. In the Fallopian aqueduct, the facial nerve is joined by the petrosal twig, p, of the vidian nerve, *v*, as represented in Figs. 1 and 2 of Plate LXXVIII. This petrosal twig, p, is also observed, in Figs. 1 and 2, to give origin to small threads, which supply one of the tympanic muscles, the tensor tympani, q. As the facial nerve runs round the posterior wall of the tympanic cavity, it gives origin to a small twig, which is distributed to the tensor tympani muscle, another to the stapedius muscle, and lastly to the chorda tympani, marked 33, in Figs. 5, 6, 7, and 8 of Plate LXXVIII., which emerges at the hollow osseous pyramid, p, of the tympanum, runs between the long crus, 8, of the incus, and the handle, 5, of the malleus, across the cavity, and emerges at the fissura Glasseri, and after a short course joins the gustatory branch, 32, of the inferior maxillary nerve, as described in page 52, and represented in Plate XV. In this course the chorda tympani sends off a twig to the laxator tympani major muscle, L, in Figs. 1 and 2 of Plate LXXVIII.

ORGANS OF SENSE.

THE EYE.

In Plates LXXIX., LXXX., and LXXXI., this important organ is delineated. In order to simplify its description, the eye is divided into several departments, as the bones which compose the orbit, the external appendages, the eye-ball, the muscles, the nerves, and the blood-vessels. The orbits are of a conical figure, with their apices looking centrad, or towards the brain, their bases peripherad, or outwards, their internal or mesial sides running nearly parallel with each other, and their external or lateral sides divaricating.

The bones composing the orbit in which the eye and its appendages are contained, are the frontal, the lacrymal, the ethmoid, the superior maxillary, the malar, the sphenoid, and the palatine, making in all seven in number, as represented in Fig. 1 of Plate IV. The orbit is invested with the periosteum, here named periorbita, which is continuous with the periosteum of the bones of the face, and with the dura mater that lines the interior of the bones of the cranium. The various foramina, as the optic, the anterior rugged or sphenoidal, the spheno-maxillary, and the anterior and posterior internal orbitary, which give entrance to the different nerves and blood-vessels that supply the eye, are situated at the bottom of the orbit, as represented in Fig. 1 of Plate IV.

The external appendages of the eye are, the supercilium, with its corrugator; the palpebræ, which consists of the common integuments, with very delicate cellular tissue, the orbicularis palpebrarum, the tarsi, with their ligaments, and the tunica conjunctiva palpebrarum; the cilia; the glandulæ ciliares; the glandula lachrymalis; the caruncula lachrymalis; the lacus lachrymalis; the plica semilunaris; the puncta lachrymalia; the canaliculi lachrymales; the saccus lachrymalis, and the ductus lachrymalis.

The supercilium or eye-brow, marked S, in Fig. 1 of Plate LXXIX., is that elegant arrangement of hairs, situated on the integuments which cover the superciliary ridge of the frontal bone, forming an arch above the eye, and giving much expression to the countenance. These hairs are short and consist of two series, the inferior of which runs upwards and outwards, while the superior downwards and outwards. Beneath the integuments there is a considerable quantity of adipose tissue; and beneath this are the united fibres of the occipito-frontalis and orbicularis palpebrarum muscles; while underneath all, close to the pericranium, is the muscle which moves this arrangement of hairs, named corrugator supercilii.

The corrugator supercilii * muscle, represented in Fig. 2 of Plate LXXIX. marked *s*, situated on the superciliary ridge of the frontal bone, derives a fleshy origin from the inner or mesial aspect, near the internal angular process, and extends along the ridge nearly two-thirds, when the fibres mingle with those of the orbicularis palpebrarum, w, and the occipito-frontalis, q, muscles, so as to constitute its insertion. The function of this muscle is indicated by its name; it is employed in knitting or corrugating the eye-brows.

The palpebræ or eye-lids are each of a crescentic figure, or resemble the segment of a circle, the straight line of which forms the edge, so that when they are gently shut they form a complete circle. They are slightly convex outwardly, and gently concave inwardly, and are so adapted as to shut the anterior entrance of the orbit. Each palpebra consists of the common integuments, which are remarkably thin; of a little delicate cellular membrane, there being little or no adipose tissue; of the fibres of the orbicularis palpebrarum muscle; of an oblong cartilage, named tarsus, which constitutes its chief portion; of cilia or eye-lashes; of ciliary glands; and of the tunica conjunctiva palpebræ.

The orbicularis palpebrarum has been already described in page 158, and is delineated in Plate XVIII., marked w.

The tarsi are thin fibro-cartilaginous bodies, firm and elastic, of an oblong shape, broader in the centre than at the extremities, and thicker at their margins where they look to each other, being so constructed that their exterior or peripheral edges meet, while their interior or central edges are so far apart as to leave a triangular canal when the eye-lids are shut, and even when open an angular fossa at the margin of the lower eye-lid to conduct the tears. The tarsus forms the chief portion and strength of each eye-lid, on which the skin, the muscular fibres, and tunica conjunctiva, are stretched. The tarsus of the upper eye-lid, marked T, in Fig. 1 of Plate LXXIX., is larger and broader than that of the lower one, marked t, in the same figure, both being invested, however, with the tunica conjunctiva, in consequence of their being everted. The inferior tarsus is not only narrower to correspond with its eye-lid, but is nearly of the same breadth throughout.* The tarsus of the upper eye-lid is supported in its situation by a ligamentous production, formed by the union of the periorbita and pericranium, which is attached

* Syn. Est qui sub cute supercilii. An pertinet ad supercilii musculum. Corrugator. Musculus frontalis verus, seu corrugator. Surcillier. Fronto-surcillier. Cutaneo-surcillier.

* The shape of the tarsi should be thoroughly investigated, as the eye-lids are subject to many diseases, and require many operations. There are inversion or entropeon, eversion or ectropeon, and various tumours situated on the eye-lids, all of which generally demand an operation.

to its orbital edge; while that of the lower eye-lid is supported by a similar production, formed by the union of the periorbita and periosteum, covering the superior maxillary and malar bones, and attached also to its orbital margin. These are named by some the broad ligaments of the tarsi, and are strongest at the outer or temporal canthus of the orbit. The two tarsi also have a ligament common to them, of a round shape, marked *t*, in Fig. 2 of Plate LXXIX., extending from their inner or mesial extremities to the nasal process, B, of the superior maxillary bone.*

The cilia or eye-lashes are an elegant arrangement of stiff hairs, of a semicircular or arched shape, projecting from the outer edges of the margins of the eye-lids; those of the superior curving downwards and upwards, having their convexity looking downwards; while those of the inferior curve also downwards, but have their convexity pointing upwards, so that when asleep they interlace each other. The cilia of the upper eye-lid differ from those of the lower in being longer and stronger, and in the central ones being also longer and stronger than those of the eye. Each eye-lash originates by a slender root from the integuments, becomes gradually thicker in the middle, and then tapers to a very fine point. †

The apertures of the ciliary glands, ‡ or rather the ducts of these glands, which are placed on the inner surface of the tarsi, and covered by the tunica conjunctiva, are observable immediately within or centrad to the eye-lashes. The glands themselves are arranged transversely on the tarsi, as represented in Fig. 1 of Plate LXXIX., running in longitudinal parallel rows, or rather clusters, of a yellowish colour. When examined with a magnifying glass, each tube or row consists of a congeries of very minute roundish shaped glands, each of which pours out its unctuous secreted fluid into its excretory tube, which runs in the centre of these small glands, and terminates by the open aperture at the ciliary margin of the eye-lid. The apertures are named the ciliary ducts. It is calculated that there are between thirty and forty rows of these small glands in the upper, and a few less in the lower eye-lid: in the former they are longer than in the latter. §

The glandula lachrymalis, marked *q*, in Figs. 2, 3, and 4 of Plate LXXIX., and in Fig. 1 of Plate LXXX., situated at the outer and upper aspect of the orbit, near or within the external angular process of the frontal bone, adhering to the periorbita (the depression being marked *k* in Fig. 2 of Plate V.), is a conglomerate gland of a somewhat oval shape, of a firm texture, and of a grayish ruddy colour, so that it is easily distinguished from the delicate soft adipose substance which abounds so plentifully in the orbit. Seven or eight short excretory ducts, leading from this gland, open like small lacunæ through the tunica conjunctiva palpebræ, and from which a few tears can be pressed when the eye is recent. ‖ By some authors this gland is described as double, and named glandula lachrymalis superior seu innominata Galeni, and glandula lachrymalis inferior.

The caruncula lachrymalis, marked C, in Fig. 1 of Plate LXXIX., situated at the inner angle of the eye, between the eye-lids, is a small conglomerate gland, of a reddish colour and prominent appearance, studded with short bristly hairs, and is more distinctly seen in the living than in the dead state. When examined in the latter state, it is found to be a congeries of glandular bodies, similar in structure to the ciliary glands. *

The lacus lachrymalis is a delicate channel or fossa, situated around the caruncle.

The plica semilunaris, † marked P, in Fig. 1 of Plate LXXIX., is a delicate crescentic-shaped mucous membrane, situated a little nearer the eye-ball than the caruncula, the cornua pointing upwards and downwards, the convexity towards the caruncle, and the concavity towards the cornea; it resembles the membrana nictitans in birds. ‡

A small aperture, marked *p*, in Fig. 1 of Plate LXXIX., named the punctum lachrymale, is observable near the caruncula lachrymalis, on the margin of each eye-lid, at the extremity of the tarsus, with a slight elevation around, which is termed the papilla lachrymalis. Each punctum is the outer commencement of a slender little mucous tube, named canaliculus lachrymalis, § which leads into the lacrymal sac; and in Fig. 2 of Plate LXXIX., the bristles marked 1, 2, are inserted in these tubes, and seen converging and emerging from the sac, G. The two canaliculi enter conjointly into the sac, or have a common inner opening, a tubulus communis, immediately beneath the ligament of the tarsi. Rosenmuller describes a little valvular fold covering this termination of the canals; but this I never could observe. The superior canaliculus runs more perpendicularly than the inferior, and both on a very gentle declivity, which, however, is modified by position, and each is about a quarter of an inch in length. The superior runs downwards and inwards, but the inferior is described by authors as running upwards and inwards.

The lacrymal sac, G, situated at the nasal angle of the eye, and attached to the nasal process of the superior maxillary and lacrymal bones (see Fig. 1 of Plate IV.), is a fibro-ligamentous pouch, of an oval shape, about the size of a small horse-bean, lined with a pulpy mucous membrane, containing numerous small mucous cryptæ, and giving entrance to the canaliculi lachrymales, and forming the beginning of the lacrymal or nasal duct. It is rounder superiorly than inferiorly, from its contracting to form the nasal duct, there being a slight constriction where the duct begins. This duct is formed of the lacrymal, superior maxillary, and inferior spongy bones, as described in page 14, and delineated in Fig. 1 of Plate IV. and in Figs. 17, 16, 27, and 28 of Plate VI., and is lined with a pulpy mucous membrane, continuous with the Schnei-

* Syn. Ligamentum palpebrale. The relation of this ligament to the lacrymal sac, G, should be considered by the surgeon when operating for fistula lachrymalis.

† The eye-lashes frequently take a different direction, curving inwards, and require an operation to be performed on the eye-lids; their natural course, therefore, should be well understood.

‡ Syn. Meibomian glands. Glandulæ sebaceæ palpebrarum.

§ The ciliary glands are frequently diseased, and also lay the foundation of diseases of the contiguous organs; they are involved in ophthalmia of the conjunctiva palpebrarum, in psorophthalmy, in lippitudo, in hordeolum, in inflammation of the canaliculi lachrymales, of the lacrymal sac, and also in fistula lachrymalis.

‖ The lacrymal gland is seldom diseased; it is subject to inflammation, particularly the chronic, which occasionally terminates in schirrus and cancer; also occasionally to acute inflammation and suppuration, and to encysted lacrymal swelling, and to watery vesicle of the gland. It is likewise subject to other sarcomatous tumours.

* The caruncula lachrymalis is subject to inflammation, suppuration, abscess, encanthis, and pterygium.

† Syn. Troisième paupière.

‡ The plica semilunaris is involved in the same diseases as the caruncula lachrymalis.

§ Syn. Cornua limacum.

derian membrane of the nares, and with the tunica conjunctiva of the eye, and like the former containing numerous small mucous cryptæ; the mucous membrane lining the canaliculi and their puncta being, however, more compact and thinner. There is thus a connexion established between the eye and the nose by continuity of mucous surface through the medium of these lacrymal passages. In Fig. 3 of Plate LXXIV., and Figs. 1 and 2 of Plate LXXV., the course of this duct is developed. The bristle marked 3 in these figures is inserted in this duct, and from these it is observed that the tube runs obliquely downwards and backwards. This duct is fully half an inch long, and sufficient to admit a bougie a little larger than a crow quill. Fig. 3 of Plate LXXIV. exhibits an anterior section of the right naris, the digits 23 indicating the inferior spongy bone, which in Fig. 1 of Plate LXXV. is partially removed, and in Fig. 2 of the same plate it is cut up towards the narrow part of the duct. This nasal duct, therefore, is a narrow tube, having two large terminations; the superior the lacrymal sac, and the inferior this dilatation, where it ends in the naris.* About the middle of the duct, a loose fold of the mucous membrane is described by Soemmering as occurring in many subjects, but this appears to be the result of disease. †

After the investigation of the appendages, I shall examine the tunics of the eye, which are divided into the proper and the accessory; the former consisting of the sclerotic, choroid, and retina, and the latter of the conjunctiva, cornea, and iris. I shall begin with the accessory; and in the first place, with the tunica conjunctiva.

The tunica conjunctiva ‡ is the semi-pellucid mucous membrane, with a polished surface, which invests the eye-lids and anterior surface of the ball of the eye. This membrane consists of all that surface of the eye which is exposed in Fig. 1 of Plate LXXIX.; the eye-lids being everted. It commences at the margins of the eye-lids, T, t, being a continuation of the skin; invests both eye-lids, running over the ciliary glands: and is reflected over the anterior aspect of the eye-ball, the caruncula lachrymalis, and plica semilunaris, so as to form a continuous or uninterrupted surface. Its adhesion to these objects is cellular. Where it begins to be reflected from the eye-lids over the eye-ball, or *vice versa*, there is a doubling or loose fold or angle, which can be unfolded, so as to exhibit one extended smooth surface, by everting the ball of the eye out from the eye-lids. That portion of this membrane which invests the eye-lids is named tunica conjunctiva palpebrarum vel palpebralis, while that which covers the anterior aspect of the eye is termed tunica conjunctiva oculi, this latter being divided into conjunctiva corneæ and conjunctiva scleroticæ. Where the conjunctiva begins, it is pierced by the ciliary ducts; and where it passes over the caruncula lachrymalis, it is pierced by its ducts and hairs. By the majority of writers, the conjunctiva is considered as terminating round the outer margin of the cornea or transparent membrane of the eye; but its extension over the cornea is established by its being

* The lacrymal passages, or the canaliculi, saccus, et ductus lachrymales, are subject to inflammation, to increased mucous secretion or blenorrhœa, vitiated secretion, stricture, fistula, hernia, and absolute obstruction; thus resembling the urethra in its diseases.

† Where the lacrymal duct terminates in the nostril, stricture is said to occur most frequently.

‡ Syn. Tunica albuginea. Tunica adnata.

capable of being separated when the eye is a little putrescent,—by its acute sensibility, in which it differs from the cornea,—by the blood-vessels of the conjunctiva sclerotica extending over the cornea,*—and by analogy with the lower animals, the serpent tribe, for example, shedding the conjunctiva corneæ at the same time with the epidermis. The conjunctiva which covers the cornea is perfectly transparent; no vessels can be seen on it; it is thinner than the sclerotica, and adheres most intimately to the external surface of the corner. The conjunctiva sclerotica is thick and pulpy, of a white colour, has few or no red vessels on its surface, and adheres by loose cellular substance to the sclerotic coat, so as to enable the ball of the eye to move in all directions. †

The conjunctiva palpebrarum ‡ is semi-transparent, extremely vascular, § and of a reddish colour; it is thinner than the sclerotic portion, but thicker than the coroneal; and it adheres loosely to the tarsus, where it leaves the sclerotica, but more and more firmly onwards to the ciliary margin, where they become consolidated.

The cornea ‖ is the anterior transparent tunic of the eye, marked *f*, in Figs. 1, 3, 5, 6, 8, and 10 of Plate LXXXI., Figs. 3 and 5 being magnified views of Figs. 2 and 4; it is a thick convex tunic, resembling the convex glass of a very small watch, and, with the sclerotic, *s*, it forms the exterior case or stratum of the eye-ball. The eye-ball is not perfectly spherical, the line forming the visual axis exceeding its transverse diameter. It consists of several laminæ, loosely connected together, which can be developed by squeezing the cornea between the finger and thumb, or by incising the cornea, and separating the laminæ with the forceps, each lamina being found to consist of a fibro-cartilaginous structure. ¶ The cornea is covered with the tunica conjunctiva, and is considered invested on its internal concave surface with the membrane of the aqueous humour. The cornea forms a pretty regular portion of a sphere, and is of equal thickness throughout, its refractive power being found to be greater than that of water.

The iris, marked *i*, in Figs. 3, 5, 6, and 7 of Plate LXXXI., extending from the letters *f* onwards to the black circle in the centre, is that beautiful circular membrane stretched across the eye, which produces such diversity of expression in each countenance, according to the difference of its colour. It extends from the ciliary circle or ligament, ** which is the circle of union of the

* This should be considered with reference to inflammation of the conjunctiva palpebralis and sclerotica, and also with respect to pterygia.

† The folds of the conjunctiva are sometimes the seat of serous effusion in inflammation of this membrane of the eye.

‡ Conjunctiva palpebralis.

§ The high vascularity should be kept in view in inflammation of this membrane.

‖ Syn. Cornea lucida. Cornea pellucida.

¶ The thickness of the cornea, and its consisting of layers thus adhering and sliding on each other, should be kept in view by the operator, otherwise he will have no conception of its structure when he comes to perform either anterior reclination of the lens, keratonyxis, or extraction of the lens. We cannot lacerate the cornea either with the fingers or the forceps.

** Syn. Annulus gangliformis tunicæ choroidæ. Annulus ligamentosus. Orbiculus ciliaris. Plexus ciliaris. Commissure de la choroïde. It is of considerable importance in operative surgery to be aware, that at this point where the cornea and sclerotic coat are united, the ciliary processes and iris also are connected, and likewise that the ciliary processes adhere to the vitreous humour and capsule of the crystalline lens. This connexion is clearly displayed in Figs. 4 and 5, the latter being an enlarged view of the former.

cornea, *f*, sclerotic coat, *s*, and ciliary folds, across or centrad in the aqueous humour, in which it floats, having an aperture nearly in its centre, named the pupil, marked *p* in Figs. 3, 5, and 7, which varies in magnitude in the living state, according to the comparative intensity of the light. It is slightly convex anteriorly or peripherad, and concave posteriorly or centrad, otherwise it would touch the lens in its multifarious movements. The iris appears a congeries of blood-vessels, and is supposed to be muscular; its anterior surface presents a beautiful stellated appearance, or representation of some wicker-work, and varies in colour in different individuals; while its posterior or central surface is said to consist of a circular arrangement of fibres; but this appears incorrect. In Fig. 7 of Plate LXXXI., which is a posterior view of the iris, its arrangement is also radiated. The colour of this surface is always a uniform dark brown; it is a thick stratum of the pigmentum nigrum, and is named uvea. The outer circular margin, which adheres to the ciliary circle, is named its ciliary; and the border of its central aperture is termed its pupillary margin, which is thin and sharply defined, and always of a dark colour, being covered with pigmentum nigrum, or by the uvea. The pupil is not precisely in the centre of the iris, the nasal being narrower than the temporal side. In the fetus, it is filled up with a delicate vascular opaque membrane, termed the membrana pupillaris, which begins to disappear about the seventh month.

The tunica sclerotica,* marked *s*, in Figs. 1, 3, 5, 6, 8, and 10 of Plate LXXXI., is the hard thick and bluish-white coat which forms the greater portion of the external stratum of the eye-ball, extending from the cornea to the optic nerve, 2, the latter of which pierces it in minute filaments, so as to form small foramina. This tunic is also pierced by the ciliary nerves, *c*, arteria centralis retinæ, *k*, with its concomitant vein, *z*, the ciliary arteries, *d*, and the ciliary veins, *h*, as represented in Figs. 1, 5, 8, and 10. The sclerotic can only be separated from the cornea by long maceration. It is so firm in its texture, which is fibrous, that it retains its figure when the humours are evacuated or removed, and we cannot lacerate it with the fingers or forceps. It is somewhat thinner anteriorly than posteriorly, and its external surface is rough and cellular, affording insertion to the muscles of the eye-ball, while its internal surface is smooth and glistening, being lined by the choroid coat.

The choroid coat,† marked *b*, in Figs. 5, 8, 7, 9, 10, and 11 of Plate LXXXI., is the soft thin delicate vascular membrane immediately interior or centrad to the sclerotic coat, which it invests, extending from the optic nerve, 2, onwards to the crystalline lens, *l*, in Figs. 4, 5, and 9. Its surface, which adheres to the sclerotic coat, as displayed in Fig. 8, is named pigmentum nigrum;‡ but this colouring matter pervades its whole structure, and is evidently an adventitious substance. The surface looking centrad or adhering to the retina, *r*, in Fig. 10, is termed, after Ruysch, tunica Ruyschiana; but in the human eye we cannot separate the choroid coat into two layers, as in the ox and many other animals. The whole texture of the choroid coat is a congeries of blood-vessels, as clearly exemplified in Fig. 8, with this brown adventitious pigment, for it is brown in man. Posteriorly, the choroid coat is pierced by the filaments of the optic nerve, the arteria centralis retinæ, with its accompanying vein, and some of the ciliary arteries. On tracing the inner or central surface of the choroid coat from the optic nerve onwards to the crystalline lens, as displayed in Figs. 4, 5, 7, and 9, we observe, that at some distance before arriving at the lens, it forms a number of parallel loose folds, radiating around the lens, which are marked *m*, and which constitute what is named the ciliary zone;* the small apices or points of which, that adhere to the capsule of the lens and project into the posterior chamber of the aqueous humour as represented in Fig. 6, and marked *n*, are termed the ciliary processes.† In Figs. 4 and 5, the choroid coat is invested with the retina.

These ciliary folds or plicæ, *m*, as seen in these figures, are observed to constitute nearly one-fourth of the choroid coat; and in Fig. 4, a peculiar dark ring or areola is perceived immediately before these plicæ begin to be formed. The processes, where they project into the anterior chamber, are also darker. The print or impression of these plicæ on the vitreous humour is delineated in Fig. 12, the humour being marked *o*, and the impression, with which always some of the plicæ remain, is marked *m*. These folds consist of the same structure as the rest of the choroid coat, being fully more vascular and more plentifully supplied with nerves.

The retina, *r*, Figs. 10, 11, 4, and 5 of Plate LXXXI., is the delicate medullary expanse of the optic nerve, which lines the choroid coat, being situated between it and the vitreous humour. In Figs. 4 and 5, which are vertical sections of the eye, Fig. 5 being a magnified view of Fig. 4, we observe the optic nerve, 2, becoming singularly constricted, reduced nearly to one-third, piercing the cribriform spot of the sclerotic, *s*, and choroid, *b*, coats, and expanding in a delicate pulp-like mucilage over the choroid coat and ciliary zone, *m*, dipping between the plicæ so as to invest the whole, onwards to the capsule of the lens, *l*, where it terminates. By most authors it is allowed to consist of two substances or two layers, a medullary expansion of the nerve, and a vascular membrane supporting it; but some consider this vascular layer to be internal or central to the medullary, while others hold the reverse. Dr. Jacob of Dublin has lately attempted to demonstrate a third layer, which he considers a distinct membrane of the eye, alleging, "that the retina is covered on its external surface by a delicate transparent membrane, united to it by cellular substance and vessels." But this appears to be nothing more or less than the membrane described by Monro secundus, who in his description of the retina observes, "The whole or retina appears to be composed of a uniform pulpy matter, on the outer side of which chiefly vessels are dispersed, supported, I suppose, by a *membrane* the same, or analogous to the pia mater." The retina adheres by extremely delicate cellular substance both to the choroid coat and to the vitreous humour. In Fig. 10, delicate blood-vessels are seen ramified on the exterior or choroid surface of the retina; and in Figs. 4 and 5 the arteria centralis retinæ, *k*, with its vein, *z*, is observed running in the centre of the section of the optic nerve, 2, and entering at what is termed the porus opticus. In Fig. 11 the artery is seen radiating

* Syn. Cornea opaca, seu tunica albuginea.

† Syn. Tunica vasculosa oculi.

‡ Syn. Pigmentum fuscum.

* Syn. Corpus ciliare. Tunica ciliaris.

† Syn. Corona ciliaris. Ciliary ligament. Rayons sous-iriens. "In regard to the names appropriated to this part of the eye," says Sir C. Bell, "there is more confusion than it is possible to believe."

over the internal surface of the retina, or that which adheres to the vitreous humour. In this last figure also a delicate conical papilla, or process, or fold, is observable, marked S, with the foramen * and delicate zone of Soemmering, of a pinkish colour around. By Soemmering the latter is said to be yellow. This process or fold is supposed by Sir E. Home to be the production of art, which appears correct; for when we cautiously make a horizontal section of the eye, leaving as much as possible of the vitreous humour, we do not see this process. Meckel contends that it is more palpable in the fetus than in the adult; but remarks, however, that he has observed no foramen here, but only a spot almost entirely deprived of medullary substance, of an oval figure, and which is surrounded with a free border neatly cut; and that this spot is not very apparent unless we compress the vitreous humour, so as to repress the process around or without, and to efface it. The retina is transparent in the living, but opaque in the dead state.

The optic nerve does not enter in the centre of the sphere, but a little towards the inner or mesial or nasal aspect, as is best illustrated in Fig. 1 of Plate LXXX. This nerve is invested with a production of the dura and pia mater. The former terminates at the sclerotic, to which it intimately adheres, but does not form the sclerotic, as described according to some authors; the latter or sclerotic being formed as early as the dura mater in the fetus, is remarkably thick and strong, while the envelope of the nerve is exceedingly delicate. The pia mater envelopes the nerve also to the eye-ball, where it likewise ceases, and does not form the choroid, nor any other membrane. Monro describes it as entering with the nerve, and forming the membranous expanse between the choroid and retina. But this mania of making one part form another, appears truly absurd, when we consider, that in the early fetus, vessels are distributed to every organ, and to every texture of the body, in order to secrete them; so that the heart and arteries, modified by the nerves, are the only sources of formation.

I shall now proceed to describe the humours of the eye, which are three in number; the aqueous, the crystalline, and the vitreous.

The aqueous humour is situated between the cornea, *f*, and the crystalline lens, *l*, as will be easily understood by examining the enlarged view of the eye, Fig. 5, Plate LXXXI., which is a vertical section, wherein the lens has been left entire. It is divided into two chambers; that marked B, which is situated between the concavity of the cornea, *f*, and the anterior surface of the iris, *i*, is named the anterior chamber, and is the larger of the two; while that marked P, which is contained between the posterior surface of the iris, *i*, and the anterior surface of the capsule of the lens, *l*, together with the ciliary processes, *n*, is termed the posterior chamber of the aqueous humour and is so small that the iris appears to be in contact with the lens. † The fluid undulates freely from the one chamber to the other through the medium of the pupil. This humour consists of only four or five drops of a watery fluid, possessing powerful solvent qualities, supposed to be secreted by a membrane which invests the cornea, the iris, the ciliary processes, and the capsule of the crystalline lens, constituting a serous pouch. This membrane, I have already stated, can be seen on the cornea, but not on the other surfaces.

The crystalline humour or lens, marked *l*, in Figs. 4, 5, 6, 9, 12, 13, and 14 of Plate LXXXI., is situated immediately behind the posterior chamber, P, of the aqueous humour, and anterior to the vitreous, *o*, in a recess of the latter of which it is imbedded, and surrounded by the ciliary processes, *n*, and its own peculiar capsule. In Fig. 12, the lens, *l*, together with the vitreous humour, *o*, having the impression of the ciliary folds, *m*, is removed from the case formed by the tunics of the eye, which figure compared with Figs. 4 and 5, vertical sections of the eye, in which the lens has been left entire, enables us to have a clear conception of the lens. In Figs 4 and 5 it is also seen to be immediately behind the iris, *i*, and its pupil, *p*, there being little or no interval space between these. * The lens is an oblate spheroid—seen by examining Figs. 13 and 14, figure 13 being an anterior, and figure 14 a posterior view, the latter of which is much more convex than the former, and is entirely imbedded in the vitreous humour. This difference is better exemplified in Figs. 4 and 5. The lens is remarkably transparent in the healthy eye; the exterior portion is soft like jelly, and may be removed by gently squeezing the lens between the fingers, leaving a central nucleus, of the consistence of slightly softened wax. In its transparent condition no fibres are observed; but when opaque, it exhibits a fibrous structure, having a radiated appearance, which is supposed to be muscular. The radiations on each side of the lens are, according to Dr. Young, ten in number.

The crystalline lens, *l*, is surrounded with a transparent film, named tunica crystalloidea, or capsule of the lens, which is very tough, firm, compact, and elastic, its anterior portion being more so than its posterior, and requiring some force to lacerate it. † The posterior portion adheres so intimately to the membrane surrounding the vitreous humour, that they are inseparable, thus rendering it even doubtful if both exist, and give rise to the opinion, that the whole capsule of the lens is a production or continuation of the membrana vitrea or hyaloidea; but these membranes are so dissimilar in their structures, that they seem quite different. In the fetus two membranes are observable behind the lens. The lens adheres to its capsule in two or three points, either by delicate nerves, blood-vessels, or cellular web.

A small quantity of watery fluid, named, after Morgagni, aqua, or aquula Morgagni, is situated between the capsule and the lens; and exterior to the capsule of the lens at its marginal circumference, a small canal is per-

* Syn. Foramen centrale.

† This part should be kept in view in inflammation of the eye, so as to account for the adhesion which so frequently occurs between these parts; and also with regard to some of the operations, as depression and reclination of the lens.

* The precise situation and relation of the lens to the contiguous objects, should be thoroughly understood by the operator. These are most faithfully delineated in Fig. 4, having compared this representation more than once with nature, in order to be certain of its accuracy. The iris does not extend so as to form a plain or flat surface across the aqueous humour, but is slightly convex anteriorly or peripherad where it looks to the cornea, and concave posteriorly or centrad when it looks to the lens. In consequence of the anterior convex surface of the lens projecting beyond the level of the vitreous humour and ciliary processes, this is of necessity the case, otherwise the uveal or posterior surface of the iris with its papillary margin would touch the lens in all its multifarious movements. This configuration of the iris ought to be kept in view by the operator in performing the operation of extraction of the lens.

† The toughness and firmness of the capsule of the lens should be kept in view by the operator.

ceptible, formed between this tunic and the membrana vitrea, which is named after Petit. Dr. Young, in the Bakerian lecture published in the Phil. Trans. for 1801, describes a thin glandular zone, filling up the marginal part of the capsule of the crystalline lens, which, he says, "may possibly secrete the liquid of the crystalline." He observed this glandular zone in the lower animals, particularly the partridge, but not in the human eye; from analogy, however, and from the spotted appearance of the image of a lucid point observable in one of his experiments, he infers the existence of something similar in the eye of man.

The vitreous humour, *o*, in Figs. 12, 4, and 5 of Plate LXXXI., is a tremulous transparent jelly, situated posterior to the crystalline lens, and surrounded by the retina, occupying therefore the greater portion of the sphere or case of the eye formed by the sclerotic coat, and forming four-fifths of the whole globe of the eye. It consists of a clear watery fluid, contained in transparent cellular cysts, and enveloped in an equally pellucid membrane, named vitrea or hyaloidea; so that by removing the cornea, iris, and lens, we can press out this humour entire from the retina, choroid, and sclerotica, like a mass of clear glass, as exemplified in Fig. 12: for it is not until we prick or cut this gelatinous mass, that the watery fluid, somewhat like the albumen of an egg, escapes or exudes. On the anterior or peripheral aspect of the vitreous humour, there is a concavity which receives the posterior convex surface of the crystalline lens (which can be easily comprehended by examining Figs. 12, 4, and 5); and to this concave surface and its brim, the tunica crystalloidea is attached. In Fig. 12, the radiated zone, *m*, is the print of the ciliary plicæ, a few of which remain, in consequence of their adhesion to the retina, and the adhesion of this latter to the vitreous humour. Some of the blood-vessels of the retina are also observable on this vitreous humour, *o*.

I shall now proceed to the description of the muscles which move the eye and its appendages; and of these, the orbicularis palpebrarum and the corrugator supercilii have been already described. The superior eye-lid has one peculiar to itself, named levator palpebræ superioris; and the eye-ball has four straight, and two oblique muscles. All these muscles, with the exception of the inferior oblique, derive their origin from the margin of the optic foramen of the sphenoid bone, *i*, *s*, the levator palpebræ superioris, the superior oblique, and the four straight muscles.

The levator palpebræ superioris muscle,* marked *l*, in Figs. 2, 3, and 4 of Plate LXXIX., in Figs. 15 and 16 of Plate LXXXI., is situated immediately beneath the roof of the orbit and periorbita; in order, therefore, to display this and the other muscles and objects under description, it is necessary to break up the roof of the orbit, by removing, partly with a saw, but chiefly with a cartilage knife, or chisel and hammer, the orbitary plate of the frontal bone, and the transverse spinous process of the sphenoid bone, which enters into the formation of the foramen opticum, and foramen lacerum anterius, preserving carefully the foramina orbitaria interna, and the depression which gives attachment to the cartilaginous pulley of the superior oblique muscle. This will be readily understood on examining Fig. 3 of Plate LXXIX. When the bone has been thus broken up, if the object be to display both the nerves and the muscles, the dissector must proceed in removing the periorbita with great care, as many of the nerves adhere intimately to this membrane. He must be also prepared to encounter a considerable quantity of delicate soft adipose tissue, interspersed between the muscles, nerves, and blood-vessels, that surround and supply the eye-ball, and which render the display of these objects difficult and tedious. The dissector should display on the one eye the muscles, arteries, and veins, and on the other, the nerves; or he may examine, in the first eye, the muscles, blood-vessels, and nerves generally, and in the second eye, these organs minutely.

The levator palpebræ superioris derives its origin, partly fleshy and partly tendinous, from the superior or coronal margin of the optic foramen of the sphenoid bone, becomes soon entirely fleshy, and advances immediately beneath the roof of the orbit to its margin, where it spreads on the upper surface of the tarsus, running onwards to its outer edge, and is lost in a delicate tendinous expanse or insertion. Mr. Crampton, in his Essay on Entropeon, says, that this muscle "is not inserted into the tarsus, but merely connected with it by means of the attachment of this last to the conjunctiva and to the integuments." Mr. Guthrie, in his able work on the Operative Surgery of the Eye, says, that "it would have been more correct to have said that the muscle is inserted into the conjunctiva, and into the process of the epicranium or broad ligament suspending the tarsal cartilage, to the upper edge of which the ligament is affixed." The function of this muscle is indicated by its name.

The rectus superior, or attollens oculi muscle,* marked A, in Fig. 4 of Plate LXXIX., in Fig. 1 of Plate LXXX., and in Figs. 15 and 16 of Plate LXXXI., is situated on the upper or coronal aspect of the eye-ball, immediately beneath or basilad to the levator palpebræ superioris, L, to which it adheres: derives a tendinous origin from the upper or coronal aspect of the optic foramen of the sphenoid bone, soon becomes fleshy, and advances with longitudinal fibres to the eye-ball, on which it extends, running superficially or coronad to the tendon, o*, of the obliquus superior, to be inserted by a tendinous expanse in the sclerotic coat near its middle, or near the circumference of the eye, the tendinous striæ advancing onwards to the margin of the cornea, and being intimately connected with the sclerotic. This tendinous expanse, together with that of the other three straight muscles, is remarkably white, and appears to contribute to the formation of what is named in popular language the white of the eye. The function of this muscle is to elevate or roll the ball of the eye upwards, as its name indicates.

The obliquus superior oculi muscle,† marked O, in

* Syn. Palpebrarum secundus, oculum aperiens. Musculus parvus et tenuis palpebram attollens. Rectus. Palpebræ superioris primus. Superiorem palpebram attollens. Apertor oculi, attollens palpebram superiorem. Pyramidalis. Aperiens palpebram rectus. Le releveur propre. Orbito-palpebral. Orbitosus-palpebral.

* Syn. Tertius oculum movens. Unus ex quatuor oblongis musculis. Unus ex quatuor qui rectis motibus præfecti. Ex iis qui rectis famulantur montibus. Rectus superior. Qui a physiognomicis superbus dicatur. Attollens sive superbus. Primus attollens. Superbus. Rectus attollens oculi. Elevator oculi. Elevator. Le releveur. Levator oculi. Sous-optico-spheni-scleroticien. Elevateur de l'œil.

† Syn. Tertius palpebrarum. Duorum in gyrum flectentium prior Obliquus ille qui per trochleam ducitur. Trochleæ musculus. Trochlearis. Alter ex obliquis superior, seu major. Sextus, obliquorum secundus, circumagens interior, aut superior, vel etiam major. Obliquo-

Figs. 3, 4, and 2 of Plate LXXIX., in Fig. 1 of Plate LXXX., and in Figs. 15 and 16 of Plate LXXXI., is situated on the inner and upper aspect of the orbit, close to the periorbita; derives a tendinous origin from the same aspect of the foramen opticum of the sphenoid bone, on the inner aspect of the origin of the levator palpebræ superioris, and advances on the inner and upper aspect of the orbit, becoming fleshy in its course onwards towards its cartilaginous pulley, *c;* where it again becomes tendinous; runs in a membranous sheath, marked *o*, in Fig. 2 of Plate LXXIX., and through the pulley, *c;* and afterwards extends outwards and downwards to the ball of the eye, beneath the attollens oculi, A, where it expands, to be inserted in the sclerotic coat. The action of this muscle is to rotate the eye-ball inwards and downwards, or mesiad and basilad.

Rectus internus or adductor oculi muscle,* marked a in Fig. 4 of Plate LXXIX., in Figs. 1 and 2 of Plate LXXX., and in Fig. 16 of Plate LXXXI., situated on the inner or mesial aspect of the eye-ball, between it and the inner wall of the orbit, derives a tendinous origin, in common with the depressor and abductor muscles, from the inner or mesial margin of the optic foramen of the sphenoid bone; soon becoming fleshy, it advances to the ball of the eye, along which it extends; and again becoming tendinous and expanding, is inserted in the sclerotic coat like the preceding, adhering onwards to the cornea. Its function is to adduct or to revolve the eye inwards or mesiad.

The rectus externus or abductor oculi muscle,† marked *a* in Fig 4 of Plate LXXIX., in Figs. 1 and 2 of Plate LXXX., and in Fig. 16 of Plate LXXXI., situated on the outer aspect of the eye-ball, between it and the outer wall of the orbit, derives a tendinous origin in common with the adductor and depressor muscles, from the outer or temporal aspect of the optic foramen of the sphenoid bone; soon becoming fleshy, it advances between the orbit and the eye-ball, adhering to the latter, in the sclerotic coat of which it is inserted onwards to the cornea. Its function is to abduct, or to revolve the eye outwards or temporad.

The obliquus inferior oculi muscle,‡ marked *i*, in Fig. 2 of Plate LXXIX., and *o*, in Fig. 2 of Plate LXXX., situated between the ball of the eye and the floor of the orbit, derives a tendinous origin from the margin of the orbitary process of the superior maxillary bone (see Plate VI., Fig. 15, letter *r*); ascends to the outer and under surface of the ball of the eye, running superficial or basilar to the depressor, and is inserted by a tendinous expanse in the sclerotic coat. Its action is the reverse of the superior, being its antagonist rotator, rotating the eye-ball outwards and upwards, or temporad and coronad.

Rectus inferior or depressor oculi muscle,* marked *d*, in Fig. 2 of Plate LXXIX., situated between the ball of the eye and the floor of the orbit, derives a tendinous origin, in common with the abductor and adductor muscles, from the inferior or basilar aspect of the optic foramen of the sphenoid bone; becoming immediately fleshy, it advances beneath the eye-ball, to which it adheres, when becoming again tendinous and spreading, it is inserted, like the attollens, in the sclerotic coat onwards as far as the cornea. It runs between the inferior oblique and the eye-ball. The action of this muscle is to depress, or to roll or revolve the eye-ball downwards, being the antagonist of the attollens.

These four recti muscles send their tendinous expansions over the anterior aspect of the sclerotic coat, from about the middle onwards to the cornea, meeting with each other so as to form an even layer, which, as already mentioned, contributes chiefly to form what is named in popular language the white of the eye.

The musculus lachrymalis,† lately discovered by Dr. Horner‡ of Philadelphia, marked l in Fig. 3 of Plate LXXX., where the eye-lids, U, *u*, are turned outwards and forwards, is situated at the inner angle of the orbit, behind or centrad to the lacrymal sac and canals, to which it adheres. It is of an oblong shape, derives its origin from the posterior surface of the os lachrymale, near the plane surface of the ethmoid bone (see Plate IV. Fig. 1, dig. 17), by a vertical arrangement of fibres, which, adhering to the lacrymal sac, advance in a parallel order outwards or temporad, dividing into two fasciculi at the angle of junction of the eye-lids, each bundle of fibres proceeding along one of the canaliculi lachrymales outwards to its punctum, where it terminates or is inserted. The superior fasciculus of fibres is blended with the orbicularis palpebrarum. The function of this muscle, according to Horner, is " to draw in the puncta and to keep the edges of the eye-lids properly adjusted to the ball of the eye," &c.; while, according to Trasmondi,§ who has discovered the nerves which influence this muscle, its function is to act upon the lacrymal sac and canals, to compress the caruncula lachrymalis, so as to favour the excretion of the matter secreted by its glandular cryptæ, also to render tense or relax the membrane of the lacrymal sac, so as to augment or diminish the bottom of the sac, and hence to press the tears down into the nasal duct. My own opinion is, that it performs all these actions, and also directs the tears into the puncta, and presses the lacrymal canals, so as to conduct and direct the tears into the sac.

The eye, with its appendages, is almost exclusively supplied with blood by the ophthalmic artery, which is a branch of the internal carotid, as described in page 139 and seen in Plate LXV., marked *o*. This artery, seen

---

rum, qui major est. Obliquus superior, vel trochlearis. Obliquus superior. L'oblique superieur. An gracillimus est rectus quintus, vel musculus trochlearis. Obliquus superior oculi, eu trochlearis. Optico-trochlei-scleroticien. Grand rotateur de l'œil.

* Syn. Primus oculum movens. Unus ex quatuor oblongis musculis. Unus ex quatuor qui rectis motibus præfecti. Ex iis qui rectis famulantur motibus. Rectus interior. Qui barbaris bibitorius appellatur. Adducens sive bibitorius. Tertius adducens. Bibitorius. Rectus adducens oculi. Adductor. L'adducteur. Orbito-intus-scleroticien. L'adducteur de l'œil.

† Syn. Secundus oculum movens. Unus ex quatuor oblongis musculis. Unus ex quatuor qui rectis motibus præfecti. Ex iis qui rectis famulantur motibus. Rectus exterior. Quem indignatorium appellant. Abducens, sive indignatorius. Quartus abducens. Iracundus. Rectus abducens oculi. Abductor. L'abducteur. Orbito-extus-scleroticien. L'abducteur de l'œil.

‡ Syn. Quintus oculi. Sextus oculi. Obliquus alter brevis. Obliquus inferius. Inferior seu minor obliquus. Obliquus minor. L'oblique inferieur. Petit rotateur de l'œil.

* Syn. Quartus oculum movens. Unus ex quatuor oblongis musculis. Unus ex quatuor qui rectis motibus præfecti. Ex iis qui rectis famulantur motibus. Rectus inferior. Qui humulis vocatur. Deprimens sive humulis. Rectus deprimens oculi. Secundus sive depressor. Humilis. Depressor. Deprimens. L'abaisseur. Sous-opti-spheno-scleroticien. L'abaisseur de l'œil.

† Syn. Tensor tarsi.

‡ London Medical Repository, vol. xviii. p. 32.

§ Mélanges de Chirurgie étrangère. Génève, 1824, p. 415.

also in Plate LXXXI., Figs. 15 and 16, marked *o*, is observed to derive its origin from the internal carotid, 19, and to enter the orbit with the optic nerve, 2,* at the optic foramen, enveloped in a sheath of the dura mater; it then runs tortuously around the optic nerve from beneath upwards, and over it to the mesial or inner wall of the orbit onwards to the nose, emerging between the cartilaginous pulley, *c*, of the superior oblique muscle, and the ligament common to the tarsi, where it inosculates with the facial artery, *c*, as delineated in Plate XVIII., and with the infra-orbitary artery. In this course the ophthalmic artery gives origin to a number of branches, as the lacrymal, the central artery of the retina, the supra-orbital, the ciliary, the muscular, the ethmoidal, the palpebral, the frontal, and the nasal. This artery does not always run in the first instance beneath the optic nerve, for it proceeds at once above or coronad to it.

The lacrymal branch, 7, is one of the first and largest given off, and proceeds along the abductor muscle, *a*, to the lacrymal gland, *q*, which it supplies, sending twigs also to the upper and lower eye-lids, which inosculate with the palpebral arteries. In this course the lacrymal sends branches to the abductor muscle and the os malæ, the latter of which they pierce, and inosculate with the deep temporal arteries. This lacrymal branch is sometimes double, and occasionally the meningeal of the internal maxillary sends a branch to the gland through the foramen lacerum anterius.

The central artery of the retina, marked *k* in Fig. 5 of Plate LXXXI., is a very small branch, which is early sent off from the ophthalmic artery, and soon pierces the optic nerve, running in its centre onwards through the porus opticus to the interior or central surface of the retina, where it divides into a number of minute twigs, connected by a very fine cellular web, as illustrated in Fig. 11. One of its minute twigs enters the substance of the vitreous humour, supplies the tunica hyaloidea, and afterwards advances to the capsule of the crystalline lens. In birds and fishes, a blood-vessel is seen entering the vertex of the radiation of the lens. This central artery of the retina is occasionally a subordinate, not a direct branch from the ophthalmic.

The supra-orbital or frontal branch, marked 91 in Fig. 15 of Plate LXXXI., and in Plate XVIII., derives its origin from the outer or temporal aspect of the ophthalmic artery in its course along the mesial or inner wall of the orbit, and at once ascends to the periorbita, and runs between it and the levator palpebræ superioris muscle, L, in company with the frontal nerve, onwards to the superciliary foramen, where it mounts and runs backwards on the forehead, still in company with the nerve, as delineated in Plate XVIII., and is distributed on the frontal bone, the orbicularis palpebrarum, the corrugator supercilii, the occipito-frontalis, and integuments, and inosculates with the temporal artery, *g*. This is generally the largest branch of the ophthalmic artery, and in this course supplies the attollens oculi, A, a, the levator palpebræ superioris, L, the trochlea, *c*, of the superior oblique muscle, O, the objects at the inner canthus of the orbit, and the superior eye-lid. These latter twigs inosculate with the facial artery of the external carotid.

The ciliary arteries, marked *d*, in Figs. 16, 1, 8, and 10 of Plate LXXXI., derive their origin both from the trunk of the ophthalmic artery and from some of its branches, as the muscular, the supra-orbital, and ethmoidal; they are very small, numerous, and irregular in number; they vary from 6 to 12 in number; encircle the optic nerve in a tortuous spiral manner, inosculating and separating from each other; and on their arrival at the sclerotic coat, they are increased in number to 20 or 30. They pierce the sclerotic coat a few lines anterior or dermal to the optic nerve, and the greater number are at once distributed on the choroid coat, and are named the short ciliary arteries;* while one or two of each side, as exemplified in Fig. 8, run onwards between the sclerotic, *s*, and choroid, *b*, coats to the ciliary zone, which they supply, and afterwards pierce the ciliary ligament, subdivide and form a beautiful plexus of vessels, like that of the superior mesenteric artery on the small intestines, around the ciliary margin of the iris; where they inosculate with other small arteries sent off from the muscular branches of the ophthalmic, which pierce the sclerotic a line or two behind the cornea, as represented in Fig. 1, marked 8. From this circular plexus of arteries others arise, which inosculate and subdivide in the same manner, forming smaller and smaller circles around the iris on its uveal aspect onwards near to the pupillary margin. These anterior arteries send also branches to the ciliary folds. These long branches, which run between the sclerotic and choroid coats, are termed the long ciliary arteries;† and those which pierce the sclerotic near the cornea, are styled the anterior ciliary arteries. The long ciliary arteries are more regular in their origin from the trunk of the ophthalmic, and pierce the sclerotic coat further from the optic nerve than the short ciliary arteries.

The muscular branches are very irregular both in their origin and number; I have already mentioned, that the supra-orbital artery supplies the attollens oculi and levator palpebræ muscles, and the lacrymal artery the abductor oculi muscle. A small branch in general accompanies one of the divisions of the third pair of nerves to the muscles, and there is usually a long inferior branch which supplies the depressor and inferior oblique muscles. These muscular branches supply the adipose substance.

The ethmoidal branch, marked 9 in Figs. 15 and 16 of Plate LXXXI., derives its origin from the mesial or inner aspect of the ophthalmic artery; enters the nares at the foramen orbitarium internum posterius, to be distributed on the mucous membrane of the ethmoidal cells, and that of the nares, inosculating with the nasal branches of the internal maxillary artery, as described in page 48, also in page 163. Another ethmoidal branch, marked 10 in Figs. 15 and 16 of Plate LXXX., is given off by the ophthalmic artery, which enters the nares at the foramen orbitarium internum anterius, and also supplies the mucous membrane of the ethmoidal cells, and that of the nares, (see page 163).

The palpebral branches are small arteries, deriving their origin where the ophthalmic emerges between the pulley of the superior oblique and the ligament common to the tarsi, and proceed to supply the palpebræ and tarsi, forming arches across the margins of the eye-lids, and sending branches to the ciliary glands, the conjunctiva, the caruncula lachrymalis, saccus lachrymalis, musculus lachry-

* The close proximity of the optic nerve to the internal carotid and ophthalmic arteries should be kept in view in diseases of the eye, as amaurosis, &c.

* Syn. Les artères ciliaires courtes, ou postérieures, uveales.

† Syn. Les artères ciliaires longues, iriennes.

malis, and orbicularis palpebrarum; inosculating with the supra-orbital, infra-orbitary, facial, and temporal arteries.

The frontal branch emerges from the orbit between the pulley of the superior oblique and ligament common to the tarsi, and ascends on the forehead, dividing into small twigs that supply the corrugator supercilii and occipito-frontalis muscles, inosculating with the supra-orbital artery.

The nasal branch is the continuation of the ophthalmic, and has therefore been already described onwards to the nose, along the side of which it descends to inosculate with the facial artery, as delineated in Plate XVIII.; and in this course supplies the lacrymal sac, the musculus lachrymalis, and the lower eye-lid.

Although I have described these minute branches of the ophthalmic artery in this manner, the student must not expect regularity of origin, or even of distribution; it appears sufficient to find the course of the trunk, and branches supplying the parts in its progress. Dr. Barclay describes only the course of the trunk, mentioning the parts which its branches supply.

The blood which is circulated by the ophthalmic artery and its branches, is returned to the cranium by the ophthalmic vein, the branches of which are nearly the same as those of the artery, and have almost a similar distribution.

The frontal vein, which returns the blood of the frontal, nasal, and supra-orbital arteries, and part of that circulated by the palpebral branches, has been already described in page 49, and is marked *z*, in Plate XVIII. A free communication is established between this vein and the beginning of the ophthalmic vein, marked V, in Figs. 15 and 16 of Plate LXXXI., which commences at the inner angle of the eye, between the pulley of the superior oblique and the ligament common to the tarsi, and accompanies the ophthalmic artery, *o*, running backwards or centrad along the inner or mesial wall of the orbit across the optic nerve, between it and the attollens oculi muscle to the outer or temporal aspect of the latter, and between it and the abductor oculi, to enter the cranium at the foramen lacerum anterius, there joining the cavernous sinus; the coats of the ophthalmic vein, or sinus, as it is frequently named, forming the anterior commencement of the cavernous sinus. In this course the ophthalmic vein, V, receives the ethmoidal veins, *w*, several muscular veins, *x*, the lacrymal vein, *y*, the ciliary veins, *h*, and the vena centralis retinæ, *z*.

The ethmoidal, the muscular, and the lacrymal are the simple venæ comites of their respective arteries, but the ciliary veins have a peculiar course. These begin on the uveal aspect of the iris, near the pupillary margin, running in a radiating manner backwards to the ciliary ligament, which they pierce, so as to arrive on the sclerotic aspect of the choroid coat, where they terminate in that beautiful arrangement of small veins named the venulæ, or vasa vorticosa, marked *h*, in Fig. 8 of Plate LXXXI. These venulæ vorticosæ collect the blood from the iris, the ciliary plicæ, and the whole of the choroid coat, and emerge piercing the sclerotic coat in two or more trunks, which proceed backwards, or centrad, to terminate in the ophthalmic vein.

Other veins are described accompanying the ciliary arteries, and named the long ciliary veins, while others again are described accompanying the anterior ciliary arteries, and termed the anterior ciliary veins; neither of these last, however, were injected in the eyes from which these diagrams were taken, and consequently are not delineated.

The venula centralis retinæ, marked *z*, in Figs. 4 and 5, begins near the termination of the retina, collecting the blood circulated by its artery, inosculating with the ciliary veins and its own branches, and congregating its branches, returns to the porus opticus, to enter the nerve in company with its artery, along which it runs for some length, and then emerges and joins either the ophthalmic vein, or runs backwards between the abductor and depressor muscles, entering the cranium at the foramen lacerum anterius, to terminate in the cavernous sinus.

The nerves which proceed to the eye and its appendages, are the optic, the moter oculi, the pathetic, the ophthalmic branch of the trigeminus, and the abducens.

I shall describe these nerves in the order in which they present themselves in dissection. When the roof of the orbit is broken up, as in Fig. 3 of Plate LXXIX., the nerves which appear nearly on a level, are the pathetic, 4, the twigs, *n*, *f*, *l*, of the ophthalmic branch, 1, of the trigeminus, 5, with the motor oculi, 3. These, with the exception of the motor, 3, adhere so intimately with the dura mater, D, within the cranium, and with the periorbita in the orbit without the cranium, that it requires great care and much patience to preserve them. A great quantity of delicate soft adipose tissue is also found giving support to these nerves, which likewise renders their dissection difficult and tedious.

The first nerve to be investigated is the fourth, or pathetic, 4,* the origin of which has been already described in page 138, and represented in Fig. 7 of Plate LXI., in Plates LXIV. and LXV., and in Fig. 2 of Plate LXVI.; it enters the fold of the tentorium, passes through the cavernous sinus, adhering closely to the dura mater; emerges at the foramen lacerum anterius, (see Plate V., Figs. 9, and 10,) forming a junction with the ophthalmic branch, 1, of the trigeminus, 5, as seen in Fig. 3 of Plate LXXIX., and almost immediately separates and runs towards the inner or mesial wall of the orbit, to be distributed on the superior oblique muscle, O.

The first or ophthalmic branch, 1, of the trigeminus, 5, ought to be next investigated. The origin and course of the trigeminal nerve, 5, to the cavernous sinus, has been already described in page 138, and delineated in Fig. 7 of Plate LXI., and in Plates LXIV. and LXV., marked 5. In the cavernous sinus, the fifth or trigeminal nerve, 5, sends small threads to unite with the great sympathetic nerve, and forms a peculiar plexus or ganglion, named Casserian,† marked G in Fig. 3 of Plate LXXIX., and then divides into its three branches, marked with the digits 1, 2*, 3*. These nerves adhere intimately to the dura mater. The first or ophthalmic branch, 1, the smallest of the three, originates from the upper or coronal aspect of the ganglion, and proceeds to the foramen lacerum anterius of the sphenoid bone (marked 2 in Fig. 10 of Plate V.), forms a junction with the fourth, or pathetic nerve, 4, on the outer or temporal aspect of which it runs, and also on the outer and upper, or temporal and coronal aspect, with regard to the third pair, marked 3; and then entering the orbit, it divides into three conspicu-

* Syn. Nervus oculo-muscularis superior, seu minimus, seu musculi oculi superioris, seu par celebrale quartum. Le nerve supérieur ou interne. Nerf moteur interne, nerf oculo-musculaire interne.

† Syn. Ganglion semilunare. Plexus gangliformis. Intumescentia ganglio affinis. Plexus retiformis. Tænia nervosa. Intumescentia semilunaris. Agger-lunatus. Armilla.

ous twigs, marked *n*, f, *l*, the nasal, frontal, and lacrymal. Sometimes it divides only into two twigs, in which case the frontal gives origin to the lacrymal.

The frontal nerve,* marked f, is the largest of the three, proceeds, united at first with the pathetic, 4, and adhering to the periorbita, superficially to the levator palpebræ superioris muscle, L, onwards to the superciliary foramen, dividing in this course into the supra-trochlear twig, *p*, and the proper frontal twig, f. Before this division of the frontal nerve, it not unfrequently gives origin to a small filament, which unites with the infra-trochlear twig of the nasal branch, and enters the frontal sinus. The supra-trochlear twig, *p*, proceeds along the inner or mesial wall of the orbit, to the cartilaginous pulley, *c*, in Fig. 4, superior or coronad to which it advances out of the orbit, and is then named internal frontal twig, and is distributed on the corrugator supercilii, the orbicularis palpebrarum, the occipito-frontalis, and the skin, and also unites with the threads of the infra-trochlearis and the proper frontal nerve. The proper frontal branch, f,† proceeds out of the orbit at the superciliary foramen, sometimes single, but more commonly in two or more filaments, which ascend over the superciliary ridge on the forehead to supply the skin of the eye-brow and the occipito-frontalis muscle, as delineated in Plate XVIII., seen accompanying the frontal artery, marked 91, where it ascends to the vertex, forming in its course junctions with the facial nerve. As this nerve emerges from the orbit, it sends twigs to the orbicularis palpebrarum muscle, and some of its threads do not pass through the foramen.

The lacrymal nerve, marked *l* in Figs. 3 and 4 of Plate LXXIX., and in Fig. 1 of Plate LXXX., the smallest of the three branches, proceeds outwards or temporad, adhering to the periorbita, and running on the abductor oculi muscle, *a*, and delicate adipose substance, onwards to the lacrymal gland, *q*, dividing in its course into two or three twigs. The interior or mesial twig enters the gland, subdividing into many filaments to supply its substance; but others emerge from the gland, and are distributed on the integuments of the upper eye-lid and forehead, forming junctions with the facial and frontal nerve. The exterior or temporal twig proceeds through the gland, and unites with a subcutaneous twig of the superior maxillary nerve, which enters the orbit at the spheno-maxillary fissure, and unites with a twig of the deep temporal branch of the inferior maxillary nerve. This nerve supplies the internal aspect of the superior tarsus.

The nasal nerve,‡ marked *n*, in Figs. 3 and 4 of Plate LXXIX., and in Fig. 1 of Plate LXXX., intermediate in size to the other two branches, is situated internal or mesial to these, running across the orbit to its mesial or inner wall. It begins, as seen in Fig. 1 of Plate LXXX., immediately where the ophthalmic nerve, 1, enters the orbit, proceeds beneath the levator palpebræ superioris, L, and attollens oculi, A, muscles, and superior or coronal to the optic nerve, 2; then ascends between the attollens, A, and adductor, a, muscles, as delineated in Fig. 4 of Plate LXXIX., running across the latter, and beneath the superior oblique muscle, O, as in Fig. 3 of Plate LXXIX., to the foramen orbitarium internum anterius (see Plate IV., Fig. 1). At this aperture the nerve enters the cranial cavity, runs along the cribriform lamella, *a*, of the ethmoid bone, emerging out of one of its anterior foramina, and descending into the nares along the cartilaginous septum onwards to the apex of the nose, where it anastomoses with twigs of the superior maxillary and facial nerves.

In this course the nasal nerve gives origin to several twigs. Almost at its very commencement it sends off a twig, named by some ramus ciliaris, which contributes to form the lenticular ganglion, marked *g*, in Fig. 1 of Plate LXXX. This twig is occasionally double. In its progress onwards, it not unfrequently gives origin to one or more distinct ciliary nerves, and even before sending off the twig to form the lenticular ganglion, it gives origin to one or two threads which unite with the third pair, 3. As the nerve proceeds towards the internal anterior orbitary foramen, it gives origin to a twig which advances along the inner wall of the orbit, beneath the obliquus superior and adductor muscles, to the pulley, *c*, in Fig. 4 of Plate LXXIX., and in Fig. 1 of Plate LXXX., which is named the nervus infra-trochlearis. This nerve, after sending twigs to the pulley and to the musculus lachrymalis, emerges out of the orbit, supplying the conjunctiva, the caruncula lachrymalis, saccus lachrymalis, orbicularis palpebrarum, occipito-frontalis, and the skin of the nose; anastomosing with the supra-orbital, the facial, and the infra-orbitary nerves. In the nares, the nasal nerve supplies the frontal sinus, and the Schneiderian membrane investing the ethmoid bone; and on the exterior of the nares it sends twigs to the ala nasi. This nasal nerve, in very rare instances, receives its origin from the sixth pair of nerves; and in nearly equally rare instances, it has not contributed to the formation of the lenticular ganglion.

The third pair of nerves, or motores oculorum,* marked 3, in Fig. 7 of Plate LXI., in Plates LXIV. and LXV., in Figs. 3 and 4 of Plate LXXIX., and in Figs. 1 and 2 of Plate LXXX., have been already described in page 138, from their origin to their entrance in the cavernous sinus. In this sinus or vein, the motor oculi nerve proceeds exterior or lateral to the internal carotid artery, 19, emerges at the foramen lacerum anterius, lying beneath and internal, or mesial and basilar to the pathetic, 4, and the ophthalmic branch, 1, of the trigeminal nerve, 5, and enters the orbit between the attollens, A, and abductor oculi, *a*, muscles, on the outer or temporal aspect of the optic nerve, 2, and almost immediately divides into two conspicuous branches, a superior and an inferior. The superior, which is the smaller of the two, as represented in Fig. 1 of Plate LXXX., runs superficially or coronad of the nasal branch, *n*, of the ophthalmic division of the fifth pair, and soon divides into two twigs, marked ⅠI and *z*, the former, ⅠI, proceeding to be distributed on the levator palpebræ superioris muscle, L, and the latter, *z*, to be ramified on the attollens oculi muscle, A. From an inadvertency, the twig, ⅠI, is marked with the digits 20, in Fig. 4 of Plate LXXIX. This superior branch generally forms a junction with the nasal nerve, *n*, and not unfrequently pierces the attollens oculi to arrive at the levator palpebræ.

The inferior branch, the larger of the two, runs first on the outer or temporal aspect of the optic nerve, 2, and

* Syn. Le nerve palpebro-frontal.

† Syn. External frontal nerve.

‡ Syn. Naso-ocularis. Nasalis internus. Ophthalmicus. Ethmoidalis. Naso-lobaire.

* Syn. Nervus oculo-muscularis inferior, seu medius, seu oculo-motorius, seu par tertium. Le nerf moteur commun. Moteur oculaire commun. Le nerf oculo-musculaire commun.

then beneath or basilad to it, and divides into three twigs marked a, d, o, in Fig. 2 of Plate LXXX. In this figure the optic nerve is turned forwards and outwards together with the eye-ball, in order to bring these nerves into view. In Fig. 1 of the same plate these objects are in their natural position and relation to each other. The twig marked a proceeds basilad or beneath the optic nerve, 2, to the inner aspect of the orbit, and is distributed on the adductor oculi muscle, a. The middle twig, d, d, consisting of two filaments, proceeds straight forwards to be ramified on the depressor oculi muscle, *d*. The external twig, o, runs along the outer or temporal aspect of the optic nerve, 2, and a little beneath or basilad, onwards to the obliquus inferior oculi muscle, *o*, on which it is distributed. In its course, this last twig, o, gives origin to a very short filament, which contributes to form the lenticular ganglion, *g*, as represented in Fig. 1 of Plate LXXX.

This lenticular ganglion then is generally formed by this long slender branch, o, of the third pair, and the nasal branch, *n*, of the ophthalmic nerve of the fifth pair; the former of which is observed to send a very short nerve, which frequently consists of several filaments; while the latter sends a long slender twig, as represented in Fig. 1 of Plate LXXX. It rests on the outer or temporal aspect of the optic nerve, 2, between the attollens, A, and the abductor oculi, *a*, muscles, as represented in Fig. 4 of Plate LXXIX.; is of a reddish tinge, and is so encompassed with delicate soft adipose substance, that it is very liable to be removed in dissection. The ciliary nerves, varying in number and in arrangement, proceed from this ganglion; sometimes they run individually, as in Fig. 4 of Plate LXXIX., and in Figs. 1 and 2 of Plate LXXX.; at other times they form two or three fasciculi: when two, the superior fasciculus adhering to the optic nerve consists sometimes of three and sometimes of six twigs; the inferior fasciculus, which is generally the larger, consists sometimes of six, and sometimes of from eight to ten twigs, and does not adhere to the optic nerve, but descends downwards and outwards. These twelve or sixteen, and occasionally twenty ciliary nerves, marked *c*, in Fig. 8 of Plate LXXXI., proceed individually along the optic nerve to the sclerotic coat, which they pierce near the optic nerve, 2, or between this and the middle of the eye-ball, and between this tunic and the choroid coat onwards to the iris. These nervous filaments seldom or ever unite in their course to the iris, and on their arrival at the ciliary ligament they generally divide into two threads, which describe an acute angle, and advance to the anterior surface of the iris, where they run in a radiated manner onwards to the pupil, having trifling enlargements in their course, which are supposed to be ganglia.

Some authors describe these ciliary nerves as not affording any threads to the choroid coat in their progress; but this appears fallacious, for when we lift gently up any of these ciliary nerves, we find delicate threads adhering and piercing the choroid coat; besides, it is contrary to the nature of nerves to run along any organ or membrane without affording to it branches. The lenticular ganglion is said to receive nervous threads from the great sympathetic nerve. The ciliary nerve which proceeds direct from the nasal nerve, enters the eye-ball about the middle of the sclerotic coat, and unites with these ciliary nerves just described, and advances together with them onwards to the iris.

The abducens or sixth nerve,* marked with the digit 6, in Fig. 7 of Plate LXI., Plates LXIV. and LXV., and Fig. 2 of Plate LXVI., is described in page 138, from its origin to its entrance in the cavernous sinus. This nerve is also represented in Figs. 3 and 4 of Plate LXXIX., and in Figs. 1 and 2 of Plate LXXX., likewise marked 6. In Fig. 1 of Plate LXXX., it is observed to run beneath or basilad to the tentorium, *d*, and to pierce the dura mater, where it invests the cuneiform process of the occipital bone, from thence to ascend and enter the cavernous sinus, running between the motor oculi, 3, and the ophthalmic branch, 1, of the trigeminal nerve, and adhering to the outer or lateral aspect of the internal carotid artery, 19, onwards to the foramen lacerum anterius. At this fissure it emerges from the cranium, and enters the orbit between the attollens, A, and the abductor oculi, *a*, muscles, to be ultimately ramified on the latter of these two. In its course through the cavernous sinus, where it first touches the internal carotid artery, 19, two or more soft filaments are given off, which descend along the artery to unite with the twig of the vidian nerve, marked I in Fig. 3 of Plate LXXVIII., to form the great sympathetic nerve. In this last figure, the manner of union of these nerves is distinctly delineated. In some rare instances, the abducens nerve gives origin to the nasal nerve, and not unfrequently sends a filament to the lenticular ganglion.

The second or optic nerve, represented in Fig. 7 of Plate LXI., in Plates LXIV. and LXV., in Fig. 5 of Plate LXVI., and in Plate LXVII., marked 2, has been already described in page 137, onwards to its emergence at the optic foramen of the sphenoid bone, and is observed in Plate LXIV., to emerge with the ophthalmic artery, *o*. In Figs. 3 and 4 of Plate LXXIX., and in Fig. 1 of Plate LXXX., it is seen after its entrance in the orbit, to run beneath or basilad to the pathetic, 4, the twigs, *n*, f, *l*, of the ophthalmic branch, 1, of the trigeminus, 5, the motor oculi, 3, and the abducens, 6, and surrounded by the recti muscles, A, a, *a*, *d*, together with the levator palpebræ superioris, L, and obliquus superior, O, muscles, and also by the ciliary nerves, *c*, sent off from the lenticular ganglion, *g*. The nerve advances enveloped in a strong sheath formed by the dura and pia mater, to enter the eye-ball a little towards the mesial or nasal or inner aspect, as minutely described in pages 177 and 176, in order to form the retina.

The superior maillary nerve,† the second branch of the fifth pair, should have been described formerly as expressed in page 163. In Figs. 3 and 4 of Plate LXXIX., and in Fig. 1 of Plate LXXX., the trigeminal nerve is observed dividing into its three branches, the ophthalmic, 1, the superior maxillary 2*, and the inferior maxillary, 3*, as already described in page 181. The superior maxillary nerve, 2*, intermediate in size to the other two branches, descends forwards beneath the dura mater, to which it adheres, onwards to the foramen rotundum, at which it emerges from the cranium, when it immediately divides into two or more branches. The first is a small nerve named the malar, or subcutaneous of the cheek, marked *c*, in Fig. 4 of Plate LXXV., which enters the orbit at the spheno-maxillary fissure, runs exterior or temporal to the abductor oculi muscle, uniting with the

* Syn. Nervous oculo-muscularis externus, seu posterior. Le nerf moteur externe. Le nerf moteur oculaire externe.

† Syn. Nervus medius quinti paris.

temporal twig of the lacrymal nerve, described in page 182, and advances adhering to the periorbita, onwards to the middle of the os malæ, through a foramen of which it emerges on the cheek, to supply the orbicularis palpebrarum muscle, and integuments of the cheek, anastomosing with the facial and the infra-orbitary nerves, as delineated in Fig. 4 of Plate LXXV. This malar nerve frequently divides in its course, as seen in this figure; and occasionally sends filaments direct to the lacrymal gland. The superior maxillary nerve then divides into two large branches, the infra-orbitary, 2, and the pterygo-palatine, the latter of which afterwards subdivides into the palatine, P, and the vidian, *v*, as delineated in Figs. 4 and 5 of Plate LXXV.

The infra-orbitary nerve, marked 2, in Figs 4 and 5 of Plate LXXV., and Plate XVII., and partially described in page 53, ascends in the spheno-maxillary fissure, in order to enter the infra-orbitary canal in the floor of the orbit, in which it runs, and emerges at the infra-orbitary foramen to be distributed on the face. Before entering the infra-orbitary canal, this nerve gives origin to one or two branches named dental,* and marked *d*, in Fig. 4 of Plate LXXV. This dental nerve, *d*, is observed to send off almost immediately from its anterior aspect a long slender filament, named its anterior branch, which proceeds to be distributed on the buccinator muscle; the trunk of the nerve, *d*, named the posterior branch, then continues to descend on the exterior wall of the antrum maxillare, or superior maxillary bone, giving origin to filaments that supply the mucous membrane which invests that cavity, to filaments which supply the bone, the three posterior molar teeth, the gums, and the pterygoid and buccinator muscles, some of these threads uniting with the nerve that supplies the anterior teeth.

In its course along the infra-orbitary canal, the infra-orbitary nerve, 2, is observed in Fig. 5 of Plate LXXV. to send off a small filament, marked *a*, which is named the anterior dental nerve, to distinguish it from the preceding, named in this case the posterior dental nerve. In many instances there are more than one anterior dental nerve. This nerve, *a*, pierces the superior maxillary bone, and sends filaments to the mucous menbrane of the nose, the mucous membrane of the antrum maxillare, and descends to supply the gums, the incisive, the canine, and anterior molar teeth, forming a junction with the preceding or posterior dental nerve, *d*.

The infra-orbitary nerve, 2, then emerges at the infra-orbitary foramen, as described in page 53.

The pterygo-palatine nerve,† or the trunk common to the pterygoid, *v*, and palatine, P, nerves, is described by Meckel to form before its division a round triangular or cordiform ganglion, termed ganglion Meckelii,‡ or ganglion spheno-palatinum. This pterygo-palatine nerve almost immediately divides into the two nerves, the pterygoid, *v*, and the palatine, P.

The palatine nerve, P,§ descends in the palato-maxillary canal to the palate, and emerges at the posterior palatine foramen, running horizontally by the side of the teeth onwards to the anterior palatine foramen, as delineated in Fig. 1 of Plate LXXVI., and anastomosing with the nasal twig of the same nerve, which descends to the palate by the incisive or anterior palatine foramen. In this course the palatine nerve gives origin to several branches, an external palatine nerve, marked *p*, in Fig. 4 of Plate LXXV., which not unfrequently arises by more than one branch,* that descends behind the bulbous process of the superior maxillary bone to the velum palati, onwards to the uvula, *f*, supplying in this progress the gums, the pterygoid muscles, the levator and tensor palati and azygos uvulæ muscles, and also the glandular and mucous structures of the velum and tonsils.

The palatine nerve is also observed in Figs. 4 and 5 to give origin to small filaments near the letter P, which enter the nares at the spheno-palatine aperture (marked *o*, in Fig. 4 of Plate IV.). The greater number of these are distributed on the mucous membrane which invests the mouth of the Eustachian tube, the sphenoid and palatine cells, and the bones of the nares, and are termed the superior posterior nasal nerves. One of these nerves descends along the septum narium to the foramen incisivum, which it perforates, and meets with the nerve of the opposite side, and also the termination of the trunk of the palatine nerve, forming sometimes a small ganglion in the incisive canal, named ganglion naso-palatinum.

The palatine nerve, P, in Fig. 5 of Plate LXXV., is observed to give origin to three other filaments immediately beneath the letter P, which pierce the nasal lamella of the palatine bone, to be distributed on the mucous membrane investing the inferior spongy bone and floor of the nares. These are named the inferior posterior nasal nerves.

These nasal nerves form junctions with the olfactory nerves.

The trunk of the palatine nerve, P, in Fig. 4 of Plate LXXV., is also seen to give origin to one or two other nerves that are descending to supply the pterygoid muscles and velum palati.

In the palate, the palatine nerve, P, divides into a number of filaments, as represented in Fig. 1 of Plate LXXVI., which supply the gums and the soft palate, and anastomose with the threads of the nerve of the opposite side.

The pterygoid or vidian nerve,† marked *v*, in Figs. 4 and 5 of Plate LXXV., and in Fig. 3 of Plate LXXVIII., reflected from the trunk common to this and the palatine, P, enters the vidian canal of the sphenoid bone, along which it runs, and re-enters the cranium, dividing into its petrosal twig, p, described in page 171, and its intercostal twig, I, the latter of which proceeds on the outer or lateral aspect of the internal carotid artery, marked 19 in Fig. 3 of Plate LXXVIII., dividing and uniting with the reflected twigs of the abducens nerve, 6, in order to form the great intercostal nerve, 7, described in page 50. In general this branch unites also with the trigeminal nerve. Before the pterygoid or vidian nerve enters the vidian canal, it sends off small filaments, some of which enter the spheno-palatine aperture to be distributed on the mucous membrane of the nares, anastomosing with the olfactory nerve, and are named the posterior superior nasal nerves; others of which pierce the internal pterygoid plate of the sphenoid bone, and descend to be ramified on the velum palati.

---

* Syn. Nervus alveolaris posterior superior. Nervi alveolares sive dentales priores.

† Syn. Spheno-palatine nerve.

‡ Memoires de Berlin, 1749, page 84.

§ Syn. Nervus naso-palatinus.

* Syn. Nervi palatini minores. Nervus palati minor posterior et nervus palatinus minimus exterior.

† Syn. Nervus quinti recurrens, seu anastomoticus.

ORGAN OF TOUCH.

I SHALL now proceed to the organ of touch, although, in a physiological order, it should have preceded the other senses, all of them being ultimately dependent on touch in the performance of their functions.

The immediate organ of touch consists of the whole superficies of the body, which is formed of the epidermis, the corpus mucosum, the cutis vera, the corpus cellulosum, and the corpus adiposum; together with the delicate termination of the extremes of the nerves, blood-vessels, exhalants, and commencements of the lymphatics.

The first pellicle which presents itself is named the epidermis, * and is best exemplified on the hand or foot, being there thickest. In Plate LXXXII. are four views of the hand, Figs. 1 and 2 illustrating the epidermis. The epidermis covers the whole surface of the body, and even enters the mucous passages, as the eye, the nose, the mouth, the ear, the urethra, the vagina, and the anus; but so modified in these, that it is not easily detected, except at there commencements. The skin is therefore said to form a sac reverted upon itself, which surrounds all the organs of the body. The epidermis is a white, semi-transparent, insensible, membranous expansion, arranged in the laminæ or squamæ, according to its thickness. In the negro it is of a clear grayish or cineritious colour, rather thicker, and scarcely semi-tranparent. In delicate parts of the body, as the face, or glans penis, it consists of one lamina, is exceedingly thin, and even transparent; while in the palms of the hands and soles of the feet it consists of squamæ, is remarkably thick, hard, and opaque, even in the fetus. The outer or peripheral aspect of the epidermis is rougher than the inner or central, the latter being smooth and glistening, in consequence of the moisture of the corpus mucosum. On both aspects or surfaces there are a number of rugæ, lines or wrinkles, from its receiving the impression of the various irregularities of the cutis, to which it intimately adheres; and on the interior or central, there are a number of delicate processes, which are the sheaths formed by the epidermis for the hairs that are transmitted; there are other processes, but shorter and more delicate, which are merely the points of adhesion between the epidermis and cutis vera. These are represented in Fig. 1, where the epidermis resembles a glove. Bichat is of opinion that these latter are the extremities of the exhalants and absorbents. Besides the hairs being transmitted through this membrane, there are small apertures or pores for the exudation of the exhalants, the excretory ducts of the glands of the skin, and for the commencements of the lymphatics. Lewenhoeck and Bichat contend that such apertures or pores exist, while Meckel and Humboldt deny their existence. These processes and foramina are best seen in a hand or foot which has been macerated for the purpose, by cautiously removing the epidermis. In Fig. 2, which is a view of the back of the epidermis that covers the hand, a number of foramina are observable.

The nails are those elegant appendages of the epidermis situated at the tips of the fingers, as represented in Figs. 1 and 2 of Plate LXXXII. They are of an oblong shape, consisting of a root, body, sides, and a free distal margin, and formed of plates or laminæ, their outer or peripheral aspect being smooth and convex, while their inner or central is concave and grooved, as delineated in Fig. 1 of Plate LXXXII. Even on the outer aspect there is a linear appearance. Their root and sides are firmly imbedded, wedged, or indented, in the cutis vera, as may be understood by examining Fig. 3; thus the epidermis is reflected so as to adhere to their outer surface, excepting at their anterior free margins, where it is attached to their inner aspect; and their inner surface adheres securely, through the medium of its grooved structure, also to the cutis vera. The nails are thus perfectly secured in order to prevent all motion.

The straight margin of the root of a nail is thinner than the rest, and is slightly serrated, apparently the more effectually to prevent mobility; and as the root shoots beyond the epidermis to become the body, there is a white semilunar spot, which is termed the lunula, but this is not invariably lunated, being in some rare cases pyramidical, the apex pointing distad. This root diminishes in size from the thumb to the little finger, and varies in magnitude in different individuals. The body of the nail is situated beyond, or distad to the lunula, and has a delicate pinkish tinge; and where it projects beyond the tip of the finger, it has a free distal margin, of a whitish colour, and thicker than elsewhere. When well formed, the margin is slightly arched; but from fashion or custom the nails are variously shaped, and of different lengths. If allowed to grow, they curve towards the palm of the hand.

The nails of the toes differ from those of the hand in being squarer, with the exception of that of the great toe, and in having generally no lunula. This last appearance, or lunula, depends on the cutis vera beneath, and so also does the delicate pink tinge distad to it.

The nails, like the epidermis, are totally destitute of sensation or vitality.

By maceration or putrefaction, we are enabled to separate the epidermis, and then we arrive at a mucous stratum of fluid between it and the cutis vera, termed the corpus mucosum. * The corpus mucosum is a homogeneous mucous semi-fluid substance, lodged between the papillæ of the cutis vera, and is described by some to consist of three or more strata or beds. Gualtier describes an external and an internal white stratum or tunic, and an intermediate one, which he denominates the brown substance in the negro; and that the external stratum is the thinnest, while the internal is the thickest. Cruickshanks found four strata in a patient who died of small-pox. But from the fluid nature of the corpus mucosum, it is very difficult to distinguish any layers even in the negro.

The cutis vera is situated beneath or centrad to the epidermis and corpus mucosum, and is represented in Figs. 3 and 4 of Plate LXXXII. This is subdivided by some anatomists into a vascular web or membrane, a papillary tissue, and a derma or dermis; which subdivision, however, appears unnecessary.

The cutis vera, like the epidermis, extends all over the surface of the body, and into the mucous passages; it constitutes the chief portion of the skin, as represented in Fig. 3, where, at the place of section, the integuments above the wrist-joint are everted: it is of a white colour, and solid elastic consistence; is formed of laminæ of a

* Syn. Cuticle. Skarf-skin.

* Syn. Rete vel reticulum Malpighi. Rete mucosum. Le réseau muqueux ou vasculaire.

somewhat fibrous structure, the fibres running obliquely from within outwards, and being more open in its texture within or centrad than without or peripherad, the latter of which is very dense and firm. This openness of the central aspect of the texture of the cutis, enables the nerves and arteries to enter freely its structure. This fibrous structure is most apparent on the back and the soles of the feet, where it resembles very much the fibrous cellular tissue beneath, which it evidently becomes. The cutis is thickest in the soles of the feet, the palms of the hands, and the back; thinnest in the eye-lids, the scrotum, the penis, and the labia of the female; it is thinner in the upper than in the lower extremities; and much thinner in the face than in the scalp. The cutis beneath the nails is red and vascular; is very thick, soft, and having no layers, but an appearance of longitudinal fibres to correspond with the grooves on the central surface of the nails. There are small regular spiral ridges, with corresponding grooves in the palms of the hands, as represented in Fig. 4, in the soles of the feet and margins of the lips; and there are a number of small elevations, named textus papillaris, or papillary tissue, * which seem to be the termination of the nerves and arteries, and commencement of the veins and absorbents,† at the tips of the fingers and the back of the hand, as delineated in Figs. 3 and 4, and also in the face. Each papilla is found to consist of two smaller papillæ, which are most conspicuous on the lips, the mamma of the female, the palmar aspect of the fingers, the plantar aspect of the toes, and the glans penis: on the lips and glans penis these papillæ are named villi, and are extremely numerous. This papillary structure, together with the whole external or peripheral surface of the cutis, is described by Mr. Baynham to be covered with a very delicate vascular web, composed of a multitude of central points united by a number of anastomosing vessels, disposed with great regularity. This, however, is unquestionably only the vascular papillæ.

In several parts of the body, as for example at the articulations, particularly the joints of the fingers, the cutis is thrown into loose folds; also on the forehead, the scrotum, and some other parts.

In various parts of the body, as the eye-lids, the extremity of the nose, the external cartilage and meatus of the ear, the nipple of the mamma, the vagina and the anus, there are a number of sebaceous glands ‡ imbedded in the cutis. They are mucous follicles or cryptæ, which open external to the epidermis with open mouths, like small black dots, and terminate in the cutis with culs-de-sac.

On investigating the integuments still deeper, we find immediately under or centrad to the cutis vera, the cellular substance,§ supporting in its cells the adipose substance, ‖ and serous fluid, as delineated in Fig. 3 of Plate LXXXII., at the place of section above the wrist-joint, where the integuments are everted.

The cellular substance forms an envelope to the muscles, and pervades the whole body, forming the foundation or matrix of all the other organs. According to Bordeu, Meckel, Prochaska, and others, it is a coherent, homogeneous, viscous substance, scarcely solidified, and divested of form; it is the coagulable fluid in the state of coagulation, and technically named the mucous tissue. Several very interesting facts and ingenious arguments are brought forward to support this theory; but what completely overturns it is, that when we take any quantity, however small, and immerse in water hot enough to melt and remove the oleaginous matter, there remains a membranous film. On the other hand, according to Haller, Bichat, Beclard, and others, this cellular substance is correctly described to consist of an assemblage of lamellæ of soft white fibrils, the arrangement of which varies to infinity, and which forms cells varying in figure and differing in magnitude, and communicating freely with each other, in such a manner that the whole cellular tissue forms only one cavity subdivided to infinity. The cellular substance is very elastic, but possesses little or no sensibility or mobility.

The cellular tissue varies in quantity in various parts of the body: thus, for example, it is very abundant under the skin in some regions, as at the mamma, the nates, and mons veneris in the female, also in the axillæ, the groins, and soles of the feet of both sexes; and is still more abundant in the pelvis. It abounds in the abdomen, as in the regions of the kidney and mesentery: in the thorax between the lamellæ of the mediastinum, and around the great vessels of the heart; and in the neck, about the carotids and lymphatic glands. In the superior extremities it is found in the course of the vessels, and between the muscles; and so also in the lower extremities, particularly around the popliteal vessels. There is very little cellular substance found about the eye-lids, penis, or scrotum; extremely little within the spinal canal; and little or none within the cranial cavity.

In the living body, the adipose matter is partly fluid and partly solid, and in some regions it is entirely the one or the other; it is of a yellowish colour, found in masses of various forms contained in the cells of the cellular tissue; these masses being smallest immediately beneath the cutis vera, and becoming larger and larger centrad; nevertheless there are small ones mingled with the large.

The serous fluid, or serosity, is found throughout the cellular tissue, but occasionally exists without the adipose matter, as, for example, in the eye-lids and scrotum.

In the subcutaneous adipose substance a profusion of blood-vessels, chiefly veins, are seen, which are named vasa subcutanea.

The hairs are situated all over the skin or external surface of the body, with the exception of the palms of the hands and soles of the feet; but are more numerous in some places than in others, in general where the cutaneous joins the mucous structure, as at the eye-lids, the nostrils, the mouth, the external auditory tube, the anus, and the vagina. The hairs are also numerous on the scalp, the eye-brows, the axillæ, the groins, the pubes, and abdomen in both sexes, and on the breast and back of the male. The hairs in many of these places do not appear until puberty, as on the chin, the pubes, and the axillæ.

The hairs on the cheek and the forehead are the furthest separated from each other; 2dly, those in the nose, around the anus, and the extremities, are less so; 3dly, those on the pubes, axillæ, breast, abdomen, eye-brows, and eye-

* Syn. Papillæ. Papillæ nervosæ. Papillæ pyramidales.

† Fodera has revived the ancient doctrine, that exhalation and absorption depend upon the capillary state of the tissues; and Jourdan and Breschet deny the existence of inhaling or exhaling vessels on the skin.

‡ Syn. Miliary glands. Mucous cryptæ.

§ Syn. Tela seu textus cellulosus, cribrosus, mucosus. Membrana cellularis. Reticular substance. Tissu cellulaire. Le système muqueux.

‖ Syn. Corpus adiposum. Adeps. Pinguedo. Panniculus adiposus.

lashes; 4thly, those on the chin, or the beard; and lastly, those of the scalp, which are also the longest, and most numerous.

The hardest and stiffest hairs are at the external aperture of the nares, while the softest are those of the face, with the exception of the beard.

The hairs on the pubes are the thickest in diameter, next those of the axillæ, then those of the scalp, and lastly those of the eye-brows and eye-lashes.

The hairs consist of a root or bulb, a body, and a point or apex, and gradually taper from the bulb to the apex, and are slender according to their length. The bulb is soft and thick, consists of several filaments, apparently vascular, united by cellular tissue, and surrounded or enveloped by a cellular sheath, between and around which is an oleaginous fluid named the medulla of the hair. The bulb is imbedded in the cellular tissue beneath the cutis vera, with which it is connected through the medium of blood-vessels and nerves, at least this is the source of origin of the long hairs. The delicate short hairs may grow from the cutis. With respect to nerves being distributed on the roots of the hairs, Rudolphi has traced them into the bulbs of the mustaches of the seal. As the hair advances through the cutis, it acquires a sheath of epidermis, which is supposed by Albinus and others to extend to its apex; this sheath is of a whitish colour and transparent, and at the bulb consists of several laminæ.

THE ORGANS

OF

MASTICATION AND DEGLUTITION.

The organs in the thoracic cavity have been already described from page 35 to 39; the reader, therefore, has only to apply the letters and digits therein marked to Plates LXXXIII. and LXXXIV., to enable him to understand their application to these figures, and also to Plates IX., X., XI., XII.; but should he find any difficulty or obscurity, he must consult at the same time the index of the letters of reference to Plates LXXXIII. and LXXXIV.

Before proceeding to the examination of the abdominal viscera, it is requisite to advert to the organs of mastication and deglutition, the description of the greater number of which has been given in pages 17, 153, and 164, as the mouth, the teeth, the gums, the mucous membrane of the mouth, the labial, the buccal, and the palatine glands, the fauces, and the pharynx, together with their various muscles; only the larger series of salivary glands,* therefore, remain to be described, as the parotid, the submaxillary, the sublingual, and the molar.

The parotid gland, † the largest of the salivary glands, is situated immediately anterior or glabellar to the external cartilage of the ear, extending from the zygoma downwards, a little beyond the angle of the inferior maxillary bone, and across the face, nearly one-third from the tragus to the angle of the mouth, or ala of the nose, resting on the masseter muscle, and converging to a point, from which its duct, x, proceeds imbedded in the adipose substance of the cheek, to pierce the buccinator muscle and mucous membrane of the mouth, in an oblique manner, opposite the second molar tooth of the upper jaw. The parotid gland is represented in Plate XVIII., marked s, its duct being indicated with the letter x. This gland, enveloped by a strong fascia, resembling that which invests the muscles and vessels of the neck, and appearing continuous with it, is partially covered by the platysma myoides muscle, F; it is a conglomerate gland, or consists of a number of lesser glands, or lobules, of a pale reddish colour, agglutinated together by cellular tissue, from which proceed the smaller ducts that concentrate to form the larger duct, x. ‡ In the substance of this gland are imbedded the facial nerve, the temporal artery and vein. § The parotid duct is a large excretory tube of a bluish white colour, remarkably thick in its substance, which is cellular, thus reducing the calibre of the canal, whose investment is serous. Where the duct pierces the mucous membrane of the mouth, it runs obliquely so as to act as a valve. In the living state, a small elevation of a ruddy colour is observable where the duct enters the mouth. The parotid gland should be examined by the student when dissecting the blood-vessels, nerves, and muscles of the face.

Occasionally one or two smaller salivary glands are found, either at the commencement or in the course of the parotid duct, the ducts of which join the parotid. These glands are named socia parotidis, or glandulæ accessoriæ. Lymphatic glands are always found in the vicinity of the parotid gland. *

The submaxillary or inferior maxillary gland, one of the conglomerate class, delineated in Plate XVII., marked with the letters *n*, is situated under, or centrad and basilad of the angle of the inferior maxillary bone, having the facial artery, *c*, imbedded in or surrounded by its lobes, of which there are two or more. This gland is obscured completely by the platysma myoides muscle, and rests on the digastric and stylo-hyoideus muscle, w. From its lobes small ducts proceed to form a larger one, † which runs between the mylo-hyoideus muscle, *m*, and the lining mucous membrane of the mouth, apparently piercing the sublingual gland, marked 80, in Plate XV., and entering the mouth by piercing its mucous membrane close to the side of the frænum linguæ, where a small papilla is observable, and where the entrance of the duct of the opposite side touches the papilla. The submaxillary duct does not pierce the sublingual gland, but runs between the gland and the side of the tongue, in a slightly waved manner, and is indicated by a bristle inserted in it, in Plate XV. This duct is much more delicate and capacious than the parotid, being with difficulty distinguished from a vein which accompanies it; it is of a grayish colour, and consists externally of cellular fibres, and internally of a mucous membrane. ‡

* Syn. Glandulæ salivares orales.

† Syn. Superior maxillary gland.

‡ Syn. Steno's duct. Ductus superior.

§ The relations of this gland to these important blood-vessels and nerves should be considered by the general practitioner, and also the operator. The parotid, like other glands, is subject to inflammation, constituting cynanche parotidea, to scirrhus, cancer, and the various modifications of sarcoma, some of which require the knife to eradicate them. See Lizars' Practical Surgery, Part II., page 143.

* These lymphatic glands frequently involve the parotid in their diseased actions.

† Syn. Ductus inferior. Ductus Whartoni.

‡ The relation of the submaxillary gland and its duct to the contiguous objects should be well considered by the general practitioner and the operator, as this gland, like the parotid, is subject to the same diseases, and the lymphatic glands in its vicinity not unfrequently so involve the submaxillary, that the one cannot be removed by the knife without the other, a circumstance which has occurred to myself. The submaxillary duct is subject to obstruction and over-distension with its

One or more lymphatic glands are generally situated near the submaxillary gland.

The sublingual, another conglomerate gland, of an oblong figure, marked 80 in Plate XV., is situated beneath the tongue, between the mylo-hyoideus muscle, *m*, and the inferior surface or base of the tongue, with its extremities pointing to the apex and root of this organ, and having a considerable extent of its surface invested with the lining mucous membrane of the mouth. It is the smallest of the preceding salivary glands, and consists of more lobules, which are also softer. Several short ducts proceed from this gland, which pierce the mucous membrane of the mouth in the contiguity of the submaxillary duct, and are best exemplified in the living state, appearing then small papillæ. A distinct duct is described by some authors to proceed from this gland, and to join the submaxillary duct; but this I have never observed.

A molar gland, intermediate in size to these larger glands and the smaller described in page 164, is described as being situated between the anterior margin of the masseter muscle and the outer aspect of the buccinator muscle, opposite the dentes molares of the upper jaw, but I have never found any glandular body situated here; several small glandular bodies are found between the buccinator muscle and the mucous membrane of the mouth, opposite this region; but these are, strictly speaking, the buccal glands.

The labial, the buccal, the lingual, the palatine, and the pharyngeal glands, which have been already described, are conglobate glands, having single ducts or lacunæ piercing the mucous membrane of the mouth.

VISCERA OF THE ABDOMEN.

The abdominal viscera are represented in their natural situation in Plate IX., and Plates LXXXIII. and LXXXIV.; Plate IX. illustrating an anterior or sternal view, Plate LXXXIII. a lateral one, and Plate LXXXIV. a posterior or dorsal view.

The abdominal cavity is bounded superiorly or atlantad by the diaphragm, marked B in Plate IX. and Plates LXXXIII. and LXXXIV.; inferiorly or sacrad by the brim of the pelvis, delineated in Plate III. letter *y*, or by the *cul-de-sac* formed by the peritoneum, a, extending between the bladder, m, and the rectum, I, as represented in Plate LXXXIII. assisted by these viscera, together with the levator ani muscle, and the bones forming the outlet of the pelvis, according as the pelvic cavity is considered excluded or included in the abdominal muscles, as the recti and pyramidales, together with the tendinous expansions of the three lateral, as depicted in Plates XXIX., XXX., and XXXI.; posteriorly or dorsad by the spinal column, together with the crura of the diaphragm, the psoæ and quadrati lumborum muscles, as represented in Plate XXXII.; and laterally by the false ribs, the ossa ilium, and lateral muscles of the abdomen and integuments, as delineated in Plates XXIX., XXX., and XXXI.

The interior of this extensive surface is invested with a serous membrane, named the peritoneum, which is also reflected on all the abdominal viscera in a similar manner to the pleura, so that these organs are equivocally said to be without this membrane. It forms a perfect sac in the male, but is continuous with the mucous membrane of the Fallopian tubes in the female. The simplest method of investigating the peritoneum is to make first a transverse division of the abdominal parietes a little below the umbilicus, and then a perpendicular one in the linea alba from the centre of this transverse one to the symphysis pubis, and reflect these two flaps outwards. The small intestines must now be held upwards towards the diaphragm, and the peritoneum, a, may then be traced from the region of the umbilicus, sinistrad, laterad, and dorsad, to the sigmoid flexure, *z*, of the colon, over which intestine it next glides to the brim of the pelvis, extending around dorsad and dextrad to the caput cœcum coli, M, over which portion of the same intestine it runs, to ascend on the abdominal parietes onwards to the region of the umbilicus, from whence we commenced. The peritoneum thus forms a continuous glazed serous surface, never passing behind any of the viscera; and will be easily comprehended, by supposing the simple experiment of making a small puncture in the abdominal parietes of a sound abdomen, and pouring or injecting into the cavity a mixture of Paris plaister and water, which is to be immediately removed. On opening this abdominal cavity, we should find every point of its surface, whether parietes or viscera, coated with the white pigment, which would precisely resemble the peritoneum.

Having investigated and understood this course of the peritoneum, we should next examine its structure, deferring the manipulation of its productions or processes until we come to investigate the viscera to which they belong. The flaps may be selected for the minute structure; and as the peritoneum in this region is concerned in hernia, and the securing of the external iliac artery, it ought to be carefully examined. The surface, which looks centrad or towards the cavity, is serous; while that which adheres to the abdominal muscles is cellular, the latter of which is best elucidated by tearing with the fingers the membrane from these muscles. In doing this, we should attend to where it adheres firmly, which will be found to be particularly the case from the angle of the flap down to the line, immediately opposite Poupart's ligament. It adheres intimately to the linea alba and the tendon of the transversalis, and loosely to the fleshy fibres of this muscle. In thus tearing the peritoneum from its connexions, it appears in some points much stronger than in others, in general where it admits of any extension, as near the urinary bladder; for according as this viscus is distended with urine, does it carry the peritoneum along with it; hence it is a very extensible membrane. The peritoneum is supplied with nerves from the various nerves in its contiguity, as the phrenic, the lumbar, and the great sympathetic; but it does not appear to be peculiarly sensitive in the living state while in health, although it becomes exceedingly so in disease. This membrane is also supplied by numerous arteries, as the phrenic, the lumbar, the cœliac, the superior and inferior mesenteric; it is not apparently very vascular in the living state during health, but becomes remarkably so in inflammation.

Properly speaking, before investigating the peritoneum even in the most superficial manner, we ought to examine the natural and relative situation of the abdominal viscera, in order to make ourselves acquainted with their situation when diseased. To facilitate this, the abdominal cavity is divided into the following regions, the epigastric, the umbilical, and the hypogastric or pubic,

---

salivary fluid, constituting ramula; and calcareous concretions are not unfrequently deposited in this duct, requiring extirpation.

with their respective lateral ones; thus the epigastric has its hypochondriac regions, the umbilical its renal or lumbar regions, and the hypogastric its iliac or inguinal regions. To define the three chief regions, two parallel straight lines are drawn from the anterior superior spinous processes of the ossa ilium upwards on each side until they meet with one drawn at right angles, across from the upper or atlantal point of the ensiform cartilage, which space is divided by drawing other two straight lines at right angles to the preceding two, the one intermediate between the sacral apex of the ensiform cartilage and the umbilicus, which limits the epigastric region; the other extending across at equal distances between the umbilicus and the symphysis pubis, in order to indicate the umbilical and hypogastric regions; the former of which is, therefore, situated at equal distances between the ensiform cartilage and the symphysis pubis between the middle lines, and the latter between the lower or pubic of these two lines of the symphysis pubis. Those portions of the abdominal cavity which are on each side of the epigastric, are named the hypochondriac regions, and are bounded by carrying the straight line between the ensiform cartilage and the umbilicus completely around to the spinous processes of the spinal column, also the one from the atlantal point of the ensiform cartilage across to the same processes of the spine. In a similar manner the two lateral regions of the umbilical are defined, and are named the renal or lumbar regions; and so also with the iliac or inguinal in regard to the hypogastric. Another method, which is probably the simpler, is to draw in the first instance the transverse lines from the ensiform cartilage,—from the intermediate point between this and the umbilicus,—from the intermediate point between the latter and the symphysis pubis,—and from the crista of the os pubis round to the spinal column, thus defining the three chief regions with their respective lateral ones at once; and then to subdivide each of these three into other three, by drawing the longitudinal straight lines from the spinous processes of the ossa ilium upwards, at right angles to the transverse lines. The space immediately centrad to the ensiform cartilage is termed the scrobiculus cordis. Monro primus, feeling the want of definite perspicuity in these regions, makes a tenth, which he names the lumbar, and defines,—" is the posterior part of the abdomen, and comprehends all that space which reaches from the lowest ribs on each side, and the last vertebra of the back, to the os sacrum and neighbouring parts of the ossa ilium. The lateral parts of this region are termed the loins." It must be confessed, that even with all these divisions, a great difficulty exists, particularly in morbid anatomy, to describe with accuracy the precise situation of any viscus. Thus, for example, the natural situation of the spleen is in the left hypochondriac region, and in morbid states it occasionally projects into the epigastric, the umbilical, the left renal, and left iliac regions; but these not having been hitherto so definitely marked, a difficulty existed of telling exactly what was epigastric, renal, or iliac region. I have been led to make these remarks, and to point out with more perspicuity these regions than has been hitherto done, from a judicious suggestion of Dr. Duncan, Professor of Materia Medica in the University of Edinburgh.

When the anterior abdominal parietes are reflected aside, as in Plate IX. (in doing which, the student must attend to the preservation of the round ligament of the liver, g, by making his incision on the left side of the linea alba from the umbilicus to the ensiform cartilage), we observe the omentum majus, h, obscuring nearly all the other viscera, which is the case when it is healthy; we, however, always perceive a portion of the stomach, b, situated atlantad to it, with part of the liver, i, still more atlantad and dextro-laterad, projecting from under the ribs; and inferiorly or sacro-pubic to the omentum, h, the uterus, k, and the urinary bladder, m; the latter organs, however, are only seen in some female subjects, for in the majority of females they are covered by the omentum, and the same is the case in males with regard to the urinary bladder. On cautiously reflecting the omentum majus upwards on the stomach, liver, and ribs, we bring into view one of the large intestines, the colon, marked M, O, P, in Plate XII., and T in Plate LXXXIII., encircling the greater proportion of the small intestines, marked K and L, the letter K indicating the jejunum and L the ileum.

On elevating the margin of the liver, i, we see the omentum minus, stretched between the stomach, b, and the liver, marked i, with the gall bladder, e, on the concave aspect of the latter; on raising gently the stomach, b, we perceive the spleen, F, and the duodenum, c; on feeling beneath or dorsad to the omentum minus, or rather on feeling through this delicate web, we touch the pancreas, marked D, in Plate XII.; on feeling beneath or dorsad to the colon, immediately sacrad to the liver, i, we find the kidneys, marked Y, in Plate XIII. and in Plate LXXXIV. These are the different viscera found in the abdominal cavity, which are divided into the floating and fixed, or the chylopoietic and assistant chylopoietic viscera. In the abdominal cavity then are contained, the peritoneum, with its productions, the floating and fixed viscera, with their appendages, blood-vessels, nerves, and absorbents. The productions of the peritoneum are the omentum majus, the omentum minus, the mesentery, the mesocolon, the mesorectum, the ligaments of the liver and of the spleen. Uuder the floating viscera are comprehended the stomach, the small and large intestines; and under the fixed viscera, the liver, with the gall bladder, the pancreas, the spleen, and the kidneys. When we apply the term chylopoietic, we comprehend the stomach, the small and large intestines, together with the omentum majus and minus, the mesentery, mesocolon, and mesorectum. Under the assistant chylopoietic viscera, are comprehended the liver, the pancreas, and the spleen. The kidneys, in this latter arrangement, come under the organs of urine. I have intentionally left out the pelvic viscera, for the sake of simplicity. The nerves and blood-vessels have been already considered.

I shall now proceed to the description of the individual viscera, which I shall give in a connected order, and not in that which the student should adopt. *

* The student should proceed as follows: first, he ought to inflate the colon from the ileum, within six inches or so of the former; secondly, inflate the stomach and duodenum from the jejunum, within two or three inches of the duodenum, attending carefully to the course of the duodenum during his inflation; thirdly, inflate the jejunum and ileum either from where the aperture was made to inflate the stomach, or from that to distend the colon. Having made himself master of all the connexions of these viscera, and their natural and relative positions, together with the mesentery and mesocolon, he should examine the omentum majus and minus; next collapse the jejunum and ileum, and investigate the superior and inferior mesenteric arteries, with the nervous mesh on these vessels; thirdly, he ought to manipulate the colon, gradually and progressively removing it, by beginning at the caput cœcum, taking along with it the few inches of ileum, and cutting close to the intestine,

The omentum minus and majus are productions of the peritoneum. On tracing with the fingers the glazed concave surface of the liver, i, in Plate IX., to the gastric, p, and hepatic, q, vessels, we find this glazing, which is the peritoneal tunic of the liver, become a loose web, apparently cribriform, and stretching to the duodenum and the concave lesser arch of the stomach, b. This loose delicate web is joined by another lamina from the dorsal aspect of the liver, as will be readily comprehended by examining Plate LXXXIV., which also advances to the concave lesser arch of the stomach, and this double cribriform web constitutes the omentum minus.* The omentum minus is thus bounded by the concave aspect of the liver, by the ducts and vessels extending between the latter and the duodenum, by that portion of the duodenum between these ducts and vessels and the stomach, and by the concave arch of the stomach and the œsophagus to the diaphragm.

The peritoneal tunic now embraces the stomach, b, and contiguous portion of the duodenum, so as to invest both their surfaces, their sternal and dorsal, advancing to the greater convex arch of the stomach, and contiguous portion of the duodenum, where the two portions meet and become again a loose floating web, marked h, named the omentum majus,* which extends to the uterus, k, where it is reflected inwards and backwards, or centrad and dorsad, and upwards or atlantad to the transverse arch of the colon, marked P, in Plate LXXXIII., where the two laminæ again separate to encircle this portion of the colon, and meet to constitute the mesocolon, the superior or atlantal layer of which advances upwards on the pancreas, D, in Plate XII., to the root of the liver, i, and diaphragm, B, thus forming a complete pouch,† the only aperture to which, termed the foramen of Winslow,‡ is dextrad and beneath or dorsad to the cystic and hepatic ducts and vessels. This aperture will be readily understood on comparing Plate IX. with Plate LXXXV. The finger can be easily inserted dextrad and dorsad of the ducts, *e*, *f*, M, of the vein, N, and the artery, q, in Plate LXXXV., when it will be perceived that it raises the omentum minus, as delineated in Plate IX. The finger passes atlantad of the duodenum, c, between the latter and the liver, i. The inferior or sacral layer of the mesocolon descends to form the mesentery, and also the mesocolon of the ascending and descending portions of the colon. This peritoneal or omental pouch is also shut up on the left side by the peritoneum investing the spleen, F, as will be comprehended by comparing Plates IX. and XII. with Plates LXXXIII., LXXXIV., and LXXXV. From this description it will be at once understood, that that portion of the omentum majus, marked h in Plate IX., which floats on the small intestines, is quadruple, being formed of the two laminæ from the stomach, and the two layers from the transverse arch of the colon. No viscus in the abdomen is completely surrounded with peritoneum like an orange with its rind, but one and all are merely so enveloped as to be well supported, and in such a manner as to enable this membrane to glide onwards to the contiguous viscus. In Plate IX. the nerves and blood-vessels of this organ are represented, and their description already given. If the omentum be very healthy and fat, in a young subject, we may succeed in inflating the omental pouch, by inserting a large blow-pipe, wrapped with cotton, in the foramen of Winslow; but in general it is either so thin and delicate, or so diseased, as to be incapable of this. When matted, there is a difficulty in separating the portion formed by the laminæ of the stomach, from that formed by those of the colon, the latter being closely connected to the greater convex arch of the stomach. If healthy, we can easily make an incision between the stomach and colon, and comprehend the general pouch. In some subjects the omentum majus extends to the ascending portion of the colon, near the caput cœcum, and is then named the omentum dextrum, or omentum cœci; some authors describe an omentum sinistrum; but we might with equal propriety make an omentum lienis; see Plate LXXXIII.

I shall now proceed to the description of the alimentary canal, which extends from the mouth to the anus. The mouth, fauces, and pharynx, have been already described. In page 153, I have mentioned that the pharynx becomes the œsophagus immediately sacrad to the cricoid cartilage of the larynx, between the latter of which and

so as to leave the mesocolon, and ending at the rectum. The structure of the colon, with its valve, &c. require to be deliberately investigated. Let him again return to the other viscera in the abdominal cavity, and proceed with the examination of the jejunum and ileum, the nerves, arteries, and veins of which having seen, and rudely traced, let him detach these intestines in the same way as he did the colon, cutting the mesentery close to the intestine, at which period he will comprehend the manner of the reflection of the peritoneal tunic over the intestine better than any other, also the course of the arteries, veins, and lymphatics, the last of which, however, are seldom discernible. When he has removed these intestines, he must examine most carefully their structure He should now return to the abdominal cavity, and commence the minute examination of the liver and gall bladder, with their ducts, the duodenum, the stomach, the pancreas, and the spleen, together with the nervous mesh distributed on their blood-vessels, and these vessels themselves; also the formation of the vena portæ, by the gastric, the superior mesenteric, the inferior mesenteric, and splenic veins; and having satisfied himself of their situation, connexion, and relation to each other, let him remove, in a mass, the liver, the duodenum, the pancreas, the spleen, together with the veins forming the vena portæ, but leaving their respective arteries as long as possible. When insulating the liver, he must remove a portion of the vena cava ascendens, by dividing it immediately atlantad to the renal veins, and also atlantad to the liver itself, thus taking away that part of it which is connected with the liver. Having detached these viscera, which is rather a difficult task, he should investigate them most minutely. The stomach has been left, in order to witness the distribution of the nervi vagi, which will have been by this time traced by the gentleman occupied in dissecting the neck and thorax. If this has been done, the stomach should be also removed, and be likewise thoroughly investigated, having previously, however, examined the arteries proceeding to it, as also the veins returning from it; this mode of proceeding should invariably be attended to, for when once the viscera are removed, the blood-vessels are with difficulty understood. The student should now proceed to trace the distribution of the splanchnic nerves, and the trunks of the great intercostals, which, by this period, will have been dissected by the young gentleman engaged in investigating the neck and thorax. After the examination of the nervous system, he should proceed with that of the arterial, and having advanced to the renal artery, he should manipulate the kidney with its duct, the ureter, the latter of which he ought to inflate a few inches from the kidney, both upwards to see the relation of the pelvis to the blood-vessels, and downwards to witness its connexion with the urinary bladder. He may now remove the kidney, with its artery, vein, and ureter of some length, and investigate it minutely. The remaining arteries of the abdomen may now be examined, next the veins, and lastly, he should proceed to the pelvic viscera. I have been thus minute from having witnessed students much perplexed in what manner to proceed in their examination of the abdominal viscera.

* Syn. Omentum hepatico-gastricum. Membrana macilentior mesogastrium.

* Syn. Omentum colico-gastricum. Epiploon.

† Syn. Marsupium omenti.

‡ Syn. Porta omenti.

its continuation the trachea, and the spinal column, the œsophagus descends, enters the thoracic cavity, running in the posterior cavity of the mediastinum, dextrad of the arch of the aorta, and dextrad and sternad to its thoracic portion, downwards or sacrad to the diaphragm, at the central or right aperture of which it emerges from the thoracic and enters the abdominal cavity, when it almost immediately dilates to form the stomach. This course of the œsophagus is delineated in Plates IX., XII., XVI., XXXII., LXX., LXXI., LXXII., LXXIII., LXXIV., LXXXIV., LXXXV., and LXXXVI., marked with the letter I.

The stomach, marked b, in Plate IX., and in Plates LXXXIII., LXXXIV., LXXXV., LXXXVI., Figs. 1, is situated partly in the left hypochondriac, but chiefly in the epigastric region, and contracts as it extends towards the right hypochondriac region to become the duodenum, c, the first portion of the small intestines.* The duodenum, marked also c, in Plate XII., descends dorsad in the right hypochondriac region, between the transverse portion of the colon, P, and the concave aspect of the liver, i, towards the right kidney in the renal region, then runs across in the umbilical region, beneath or dorsad to the transverse arch of the colon, P, the mesocolon, Q, the mesentery, the superior mesenteric vessels, V, U, and emerges to become the jejunum, K.

The jejunum, K, bridled down by the mesentery, occupies the umbilical, the right renal, the right iliac, and hypogastric regions, and not unfrequently descends into the pelvis. This intestine imperceptibly becomes the ileum, L, there being nothing to indicate their line of demarcation; the extent of intestine from the duodenum to the colon being commonly divided into five parts; the two contiguous to the duodenum constituting the jejunum, and the three contiguous to the colon constituting the ileum.

The ileum, L, bridled down like the jejunum by the mesentery, is situated in the umbilical, hypogastric, pelvic, and right iliac regions, and becomes or joins the colon in the last of these divisions.

The colon, marked M, O, P, *z*, in these Plates, and also in Plate XIII., and in Figs. 2 and 3 of Plate LXXXVII., begins in the right iliac region, ascends in the right renal and hypochondriac regions, then extends across in the umbilical (close to the epigastric) to the left hypochondriac, where it descends in the left renal and iliac to the hypogastric region, and becomes the rectum, I, which descends along the sacrum and coccyx in the pelvis, and terminates externally at the anus, I**.

Having described the course of the alimentary canal in this general manner, I shall now proceed with its structure. When formerly investigating the pharynx, I described only three tunics, a cellular, a muscular, and a mucous; and the same number and kind will be found to constitute the œsophagus. The alimentary tube, however, when it enters the abdominal cavity, acquires an additional coat, the peritoneal; but it may then be said to lose the cellular, for this becomes so attenuated as to be scarcely visible.—I should say, therefore, that the stomach, the small and the large intestines, consisted of a peritoneal, a muscular, and a mucous tunic. Some authors describe a nervous or vascular coat to be situated between the muscular and the villous; but this is nothing more or less than the cellular tissue which unites the muscular and villous tunics. On the same principle, we should follow the arrangement of other authors, and make the cellular tissue forming the bond of union between the peritoneal and the muscular, a distinct tunic. As these tunics vary considerably on the different viscera, I shall defer entering more minutely at present, until I come to their individual description, and therefore proceed with the œsophagus.

The œsophagus, marked I, in Plates IX., XII., XVI., XXXII., LXX., LXXI., LXXII., LXXIII., LXXIV., LXXXIV., LXXXV., and LXXXVI., I have described to be a continuation of the pharynx, beginning opposite the inferior or sacral margin of the cricoid cartilage, where there is a contraction of the tube at this point, as stated in page 192. The exterior cellular investment of the œsophagus is very loose, and abounds in greater quantity in some parts than in others; more so in the neck than in the thoracic cavity, where the œsophagus runs in the posterior cavity of the mediastinum, and still less so where its lateral parietes are in contact with the pleura. Its muscular fibres are chiefly spiral, a few only being either circular or longitudinal; the circular are situated at its commencement near the pharynx; the longitudinal at its junction with the stomach; and the spiral intermediate. Its mucous coat resembles that of the pharynx, of which it is evidently a continuation, but is of a white colour, and there appear fewer glandular bodies interspersed upon it, with the exception of that portion contiguous to the stomach; lacunæ or cryptæ are, however, very distinct. The extension of the cuticle is now lost to dissection, but by maceration it may be observed. After the œsophagus has entered the abdominal cavity, it acquires a coating from the peritoneum, reflected from the diaphragm, which, however, is extremely short, for the œsophagus almost immediately dilates to become the stomach. The extension of the peritoneum on each side has, however, been named ligamentum phrenico-gastricum, dextrum et sinistrum; that on the right side being continuous with the omentum minus; while that on the left side, with the omentum majus, or the ligamentum lienis suspensorium. In the ordinary state of the body, the œsophagus is collapsed.*

The situation of the stomach,† marked b in Plate IX., and in Plates LXXXIII., LXXXIV., LXXXV., and LXXXVI., Figs. 1, has been already described; it consists of two apertures, an entrance named the cardiac, or œsophageal orifice,‡ marked A, in Fig. 1 of Plates LXXXV. and LXXXVI., and an exit named the pyloric or duodenal orifice,§ marked T in the same figures; of a

* Syn. Intestinum tenue. L'intestine grêle.

* The œsophagus is subject to polypi, to fungous and lobulated excrescences, to scirrhus and cancer, some of which are accompanied with stricture or constriction of the canal, and even total obstruction. It is also sometimes affected with spasmodic or permanent constrictions or stricture, producing dysphagia and dilatation, and occasionally with a protrusion of the mucous membrane through a rent of the muscular; and even both of these tunics have been protruded through a gap in the cellular envelope, so as to resemble hernia. When inflammation attacks the œsophagus, it occasionally terminates in ulceration, which sometimes extends to the lungs, to the aorta, to the trachea, and to the skin, forming, in the last case, a fistula. These diseases occur at the extremities of the canal, and more frequently at the pharyngeal than at the ventricular.

† Syn. Ventriculus.

‡ Syn. Cardia. Os ventriculi. Upper orifice. Ostium ventriculi sinistrum.

§ Syn. Pylorus. Right or inferior orifice. Ostium ventriculi dextrum seu janitor. L'orifice intestinal.

lesser concave arch, D,* and of a greater convex arch, *b*;† of an anterior or sternal surface, b, in Fig. 1 of Plate LXXXV., and of an opposite, or posterior, or dorsal surface, both of which, however, vary according as the stomach is collapsed or distended; when it is fully distended, the sternal becomes the atlantal, and the dorsal the sacral; the stomach also consists of a larger extremity or *cul-de-sac*, X, ‡ and of a smaller, marked *x*. § Its size naturally varies according to its distension; in the natural healthy state, when not filled with food, the stomach is collapsed. Its peritoneal tunic has been already described as proceeding from the omentum minus to the lesser concave arch, and extending along its two surfaces, its sternal and dorsal, where it again meets at its greater convex arch to form the omentum majus. It also receives a part of its peritoneal investment from the diaphragm along the œsophagus, and may be likewise said to receive a portion from the duodenum, c. This peritoneal membrane is represented reflected off from the muscular tunic, in Fig. 1 of Plate LXXXV., and is marked a; and, in Fig. 1 of Plate LXXXVI., where the stomach is laid open, this tunic, a, is displayed throughout.

Some authors describe the peritoneum as forming various ligaments in this region; but these are so delicate and indistinct, as not to be worthy of investigation. Thus, for example, there are vinculum œsophagi; vinculum inter œsophagum et lienem: ligamentum dextrum ventriculi; ligamentum phrenico-gastricum; ligamentum gastro-splenicum.

Its muscular tunic consists of a longitudinal and transverse, or circular arrangement of fibres, the greater number being circular. This tunic is displayed in Figs. 1 of Plates LXXXV. and LXXXVI., and is marked B. In Fig. 1 of Plate LXXXV., the longitudinal fibres of the œsophagus, I, appear to form many of both the longitudinal and circular fibres, particularly the former; and both of these fibres seem to form those of the duodenum, c. At the pyloric orifice the circular fibres form a constriction, so as to enable this to act as a valve. ‖

The longitudinal fibres are most numerous on the lesser concave arch, D. The circular fibres appear to begin at the larger extremity, X, and to extend to the pyloric orifice, where they become strongest, interlacing with each other throughout this extent, as if they were only semicircular; some of them, however, have an oblique or transverse direction. Some authors describe a third layer of muscular fibres, to be situated beneath or centrad to these two last, and to be a continuation of the fibres of the œsophagus, running longitudinally, and interlacing with the oblique fibres.

In Fig. 1 of Plate LXXXVI., the stomach is laid open from the cardiac, A, to the pyloric, T, orifice, in order to display the mucous coat, *m*, which is loose, villous, and glandular, and has a reticular appearance. The mucous tunic is of a reddish rosy colour, which, however, diminishes towards the pylorus. When the stomach is empty, the mucous coat has the appearance of rugæ or plicæ, which vary in size, and run in an irregular waving transverse direction; but at the œsophageal aperture they run more longitudinally, blending with the folds of the œsophagus, of which they appear to be the continuation, and forming a stellated or radiated appearance. The epidermis investing the œsophagus cannot be traced into the stomach, for we fail to trace it further than around the cardiac orifice. At the cardiac orifice, A, the lesser arch, D, and the pyloric orifice, T, the glands are most numerous, but most so at the pyloric orifice;* and at the pyloric orifice, T, the mucous tunic is very pendulous, projecting inwards or centrad, in order to contribute to the formation of the valvular aperture, T, † which, contrasted with the cardiac, A, is remarkably small.

The stomach is larger, wider, and shorter in man than in woman, and its muscular coat is stronger in the former than in the latter. The nervous and vascular distributions to the stomach have been formerly described. ‡

The duodenum, § marked c in Plates IX. and XII., and in Figs. 2 of Plates LXXXV. and LXXXVI., the course of which has been already described in page 193, is the shortest and largest in diameter of the small intestines; that portion of its surface which adheres by very loose cellular substance to the vena cava ascendens, the right psoas magnus muscle, the abdominal aorta, and the spinal column, is not covered with peritoneum. The extension of the peritoneum from the duodenum to the right kidney, is named by some authors, ligamentum vel plica duodeno renalis; and these authors also describe a ligamentum duodeno-hepaticum, vel hepato-duodenale.

The muscular tunic of this intestine consists chiefly of circular fibres, which are very strong and distinct.

The mucous tunic, of a white colour, consists of a number of loose plicæ or folds, some of which are of a circular, while others are of a semilunar shape, and are arranged transversely or circularly; some being smaller or narrower than others. They are named valvulæ conniventes, ‖ where the duodenum, c, is laid open for a considerable extent, downwards from the pyloric orifice, T, of the stomach, b, and are displayed in Fig. 2 of Plate LXXXVI. The smaller valvulæ conniventes are named by some villi, or villosities; but these villi are distinct conical prolongations of the villous tunic, situated between the valvulæ conniventes, and from which this membrane has got its name. These villi are even situated on the valvulæ conniventes, and are so numerous as to be estimated at 4000 on each square inch of the villous tunic. When examined with the microscope, they presented a granulated appearance, with a number of open mouths, and are formed of lacteals and blood-vessels, connected with a cellular tissue. They have been named the ampullulæ of Leiberkuhn. Over all the surface of the duodenum, a multiplicity of

* Syn. La courbure supérieure. Petite courbure. Bord diaphragmatique.

† Syn. La grande courbure. Bord colique.

‡ Syn. Left extremity. Base. Fundus seu saccus cœcus. Le bas-fond, tubercle, ou grand cul-de-sac de l'estomac. Extremité splenique.

§ Syn. Right extremity. Antrum pylori. Petit cul-de-sac.

‖ Syn. Sphincter pylori.

* The glandular structure of these parts of the stomach, particularly at the pyloric, are those which become affected in scirrhus and cancer of this viscus. The pyloric aperture is also the most subject to constriction or stricture.

† Syn. Valvula pylori.

‡ The nervous, the vascular, the glandular, and mucous structures of the stomach should be carefully investigated, in order to comprehend its diseases. These are dyspepsia, spasm, gastritis, umbilical hernia, scirrhus, cancer, fungous excrescences, fatty tumours, tubercles, polypi, constrictions, so as to divide it into two pouches, ulcers, erosions, spontaneous perforations, softening and destruction of the mucous membrane, small pouches giving lodgement to foreign substances, and hematemasis, and it is involved in cholera and fever, particularly typhus and yellow fever. In the living body, the stomach presents no contraction in its middle.

§ Syn. Intestinum digitale. Intestinum rectum brevissimum. Ventriculus succenturiatus.

‖ Syn. Valvulæ Keckringii.

mucous glands or lacunæ are found.* Between these valvulæ conniventes, a number of small glands are situated, which are named after Brunner. † They present a round lenticular appearance, and open with distinct mouths, and are delineated in Fig. 2 of Plate LXXXVI.

In Figs. 2 of Plates LXXXV. and LXXXVI., we perceive the ductus communis choledochus, M, together with the pancreatic duct, P, piercing the walls of the duodenum. In Plate LXXXVI., where the intestine is laid open, we observe the open mouth, M*, of these conjoint ducts, M and P, with a papillary elongation of the mucous coat around, for in the majority of instances the pancreatic duct joins the ductus communis choledochus before its termination in the duodenum; the latter of which runs first between the peritoneal and muscular, and then between the latter and mucous tunics of the intestine, in order to act as a valve. In Plate LXXXV. the duct, M, enters the duodenum on its dorsal aspect, near the termination of the first turn, between three and four inches from the pyloric orifice, T, of the stomach.

The situation and course of the jejunum, K, have been described in page 193. It, together with the ileum, is held in situation by the mesentery, marked Q in Fig. 2 of Plate LXXXV., and in Fig. 1 of Plate LXXXVIII. This process or duplicature of the peritoneum, Q, extends along the abdominal portion of the aorta and the bodies of the lumbar vertebræ, to which it adheres by cellular substance, its two laminæ enclosing the superior mesenteric artery, R, and accompanying vein, U, with their numerous branches, together with the lacteal vessels and their lymphatic glands, the superior mesenteric plexus of nerves, a quantity of cellular and adipose substances, and expanding more and more into loose folds as they advance along these vessels to surround the long convoluted extent of the jejunum and ileum. This production of the peritoneum is one of the most beautiful and wonderful productions of Nature. The small portion of root, ‡ with the prodigious extent of ramification, is admirably arranged. The easiest manner for the student to comprehend this tortuous expanse of the peritoneum, is to return to that portion of this membrane already described in page 190, and to examine attentively and minutely the formation of the mesocolon, for the mesentery is formed identically in the same manner. Let him then trace the peritoneum a little atlantad to the brim of the pelvis, keeping the jejunum and the greater portion of the ileum out of his way, and merely allowing enough of this latter intestine to come within his examination, in order to enable him to comprehend how the peritoneum encircles and braces it down. Where the ileum joins the colon, it is very closely braced down by the peritoneum, there being very little mesentery. After this, he may trace the peritoneum across the abdomen, so as to traverse the middle of the mesentery; and he will then clearly and perfectly understand that the latter is formed by the peritoneum from both sides of the cavity, uniting on the aorta and spinal column, descending obliquely from left to right, from the second lumbar vertebra to the right sacro-iliac-synchondrosis, and extending along the superior mesenteric artery and vein onwards to the jejunum, K, and ileum, L, both of which it also invests, so as to remain a continuous surface, being continuous, atlantad, dextrad, and sinistrad with the mesocolon, and sacrad with the mesorectum and peritoneum investing the pelvis; for, as formerly remarked, the viscera are equivocally said to be without the peritoneum.*

The jejunum, K, is thus almost entirely surrounded with a peritoneal coat, as illustrated in Fig. 1 of Plate LXXXVIII., where the one lamina, a, is dissected from the other and the vessels forming the mesentary, Q, and left pendulous on the intestine. When the jejunum is fully distended, we observe a distinct arrangement of muscular fibres extending along its convex arch; and precisely in the centre of these a whitish line is described to be visible, and named its ligamentary band; this, however, is so delicate and indistinct in general, as not to be worthy of such an appellation.—It is merely the mucous coat shining through. The circular arrangement of fibres is very distinct, as exemplified in Fig. 1 of Plate LXXXVIII.; and the muscularity of the jejunum, although less than that of the duodenum, forms a striking contrast with the ileum, rendering the former much fleshier and redder in colour than the latter. The mucous coat of the jejunum so precisely resembles that of the duodenum, next the jejunum, that I considered it superfluous to give a delineation of it. It is of a whitish colour, and there are fully more valvulæ conniventes in the beginning of the jejunum, but rather fewer solitary glands; the glandular bodies being in oblong clusters, and named plexus glandulosi Peyeri. The villi are also more loose and pendulous. The mucous glands or lacunæ are the same.

The ileum, L, constituting the remaining three-fifths of the small intestine from the beginning of the jejunum, has been so far described in page 193. It differs from the jejunum in being much thinner in its muscular and mucous coats, as exemplified in Fig. 1 of Plate LXXXVII. Its peritoneal tunic has been already described, together with that of the jejunum.

Both the longitudinal and circular plane of muscular fibres are very indistinct. The colour of the mucous tunic becomes paler, and the valvulæ conniventes become more and more indistinct in the ileum as we advance towards the colon; and, as delineated in Fig. 1 of Pl. LXXXVII., there are none in that portion of the ileum: here they are considered by some to run longitudinally. The villi of the ileum are longer, thinner, and more conical than those of the jejunum or duodenum, and are also more remote or apart from each other. The mucous glands or lacunæ are the same. The larger series of glands resemble those of the jejunum, being arranged in clusters, and also named after Peyer; and near the colon they are most numerous, and frequently of considerable extent, as represented in Fig. 1 of Plate LXXXVII., where, on the mucous tunic, *m*, they form irregularly shaped patches. These are found almost exclusively on the sides of the ileum, and not on the convex or concave arches. The nervous and vascular distributions to the small intestines have been formerly described. †

* Syn. Criptæ minimæ. † Syn. Glandulæ solitariæ.
‡ Radix Mesenterii.

* In ascites or dropsy of the abdomen, the serous fluid is contained in the pouch of the peritoneum, between its anterior or sternal portion, investing the abdominal parietes, and that which invests the small and large intestines; and hence these viscera are dorsad to the fluid.

† The nervous, vascular, glandular, and mucous structures of the small intestines, should be carefully examined in order to comprehend their diseases, as spasm, volvulus, diarrhœa, cholera, constipatio, enteritis, ulceration, mortification, scirrhus and cancer, tabes mesenterica, tubercles, fungous excrescences, fatty tumours, perforations, adhesion to each other, ossification, and hernia. A peculiar malformation occa-

The colon,* marked M, O, P, *z*, in Plates XII. and XIII., and in Plates LXXXIII., LXXXIV., and LXXXVII., has been described, as far as regards its situation, in p. 193. It is divided into its caput cœcum, M, its ascending portion, O, † its transverse portion, P, ‡ and its descending portion or sigmoid flexure, *z*, § with its appendix vermiformis, 29. The caput cœcum is the commencement, or that portion which is sacrad or rather distad to the ileum, L, and will be best understood by examining Fig. 3 of Plate LXXXVII., where all that is to the right of L and *v* in reference to the observer, is the caput cœcum. The ascending portion, O, beginning above or atlantad to the caput cœcum, and the junction of the ileum, ends where the intestine advances to the liver, i. The colon now begins to extend across, becoming then the transverse portion, P, which terminates near the spleen, F, where the colon begins to descend and form the sigmoid flexure, *z*, which ends in the rectum, I. Some authors make a still more minute division of the colon, as, for example, caput; cœcum; ascending part of the arch; transverse part of the arch; descending part; and sigmoid flexure. The colon is held in this extensive course by the omentum majus and mesocolon, the latter of which is marked Q, in Plate XII., and part of which has been described in page 190, viz. that portion which binds down the sigmoid flexure, *z*. In some subjects the peritoneum here does not encircle the colon so as to form a mesentery, but only invests that portion of the intestine which is free, a considerable part in such a case adhering by loose cellular substance to the iliacus internus and psoas magnus muscles. ‖ At the caput cœcum, and the commencement of its ascending portion, this deficiency of peritoneal covering and extensive loose adhesion to the muscles is still more frequently the case. Near the right kidney the mesocolon is named the right ligament of the colon, and near the left kidney the left ligament of the colon. The mesocolon is loose and free where it supports the transverse portion, and it is here that it contributes to form the large omental pouch.

That portion of the mesocolon which binds down or supports the ascending portion of the colon is named by some, *le mesocolon lombaire droit;* the transverse portion, mesocolon transversum, and the descending, *le mesocolon descendant.* The mesocolon, as already mentioned, is, like the mesentery, a process of the peritoneum, and, like it, consists of two layers. In Plate XII. we observe it, marked Q, joining the mesentery on its sinistral aspect, and confining the duodenum, c, the course of which is indicated by dotted lines, and from thence extending dextral along the ilio-colica, *t*, and colica dextra, *u*, arteries, onwards to the ascending portion of the colon, O. This part of the mesocolon adheres firmly to the vena cava ascendens, the psoas magnus and iliacus internus muscles, and admits of no latitude of motion. We perceive also the mesocolon ascending along the colica media artery, V, uniting with its opposite lamina, which descends along the pancreas, D, to support the transverse portion, P, of the colon. This part of the mesocolon is remarkably loose and free. On the transverse and beginning of the descending portions of the colon, or, in other words, on those portions of the colon which are loose and free, small peritoneal prolongations filled with adipose substance project, which are termed appendices epiploica.* These, however, are only observable in fat subjects, for in emaciated ones little or no trace of them is to be found. In Fig. 2 of Plate LXXXVII. there is a process of the peritoneum, marked *l*, extending between the ileum, L, and the caput cœcum, M, connecting these together, and also giving support to the appendix vermiformis, 29.

The colon has, besides its three tunics, like the other intestines, three longitudinal muscular bands, marked T, in Figs. 2 and 3 of Plate LXXXVII., which extend along its walls at equal distances, one of them being hid by the laminæ of the mesocolon. These muscular bands are the longitudinal muscular fibres of this intestine congregated in this peculiar manner; still, however, we can perceive some insulated longitudinal muscular fibres here and there between these three bands. They commence or unite at the appendix vermiformis, 29, and terminate in forming the longitudinal fibres of the rectum. These bands purse the colon into these peculiar pouches or cells † so characteristic of this intestine; for when these bands are dissected off, the colon expands to double its natural size, and becomes regularly and uniformly cylindrical. The circular muscular fibres of this intestine are very sparse and thin, being more so than those of the small intestines.‡

The mucous tunic, of a very pale white colour, presents a number of depressions and elevations, which make it appear at first sight that this membrane is loose and free; the depressions have a reticular or honeycomb appearance, somewhat similar to that of the stomach; and the little elevations which separate these, occupy the greater space, and resemble the villi of the small intestines. We observe a multiplicity of mucous glands studding this mucous tunic, as delineated in Fig. 3 of Plate LXXXVII. §

In Fig. 3 of Plate LXXXVII., the valve of the colon,‖ marked with the letters *v*, is displayed, which is formed by the ileum extending into the colon, the two productions or folds, *v*, *v*, consisting of the mucous and muscular coats of both the ileum and colon, those of the latter being reflected inwards; but only the circular muscular fibres of the ileum are concerned, the longitudinal fibres with the peritoneal coat running on the colon. These folds, *v*, *v*, are of a semilunar shape, like the valvulæ conniventes, are extremely loose and floating, and run sternad and dorsad, or forwards and backwards, meeting with each other so

---

sionally exists in the course of the ileum, a conical projection or elongation like the finger of a glove originating from its convex arch, named diverticulum; I have seen these four inches long, and they are by no means uncommon. Syn. Diverticule ilial. The tænia, the lumbrica, and the trichuris, species of worms, are found in these intestines.

* Syn. Intestinum crassum.

† Syn. Intestinum colon dextrum seu ascendens.

‡ Syn. Colon transversum.

§ Syn. Intestinum colon descendens. Flexura sigmoidea seu iliaca, seu S romanum.

‖ I have been thus particular in describing this portion of the peritoneum, in consequence of this part of the colon, and its caput cœcum, being occasionally forced out in hernia without having a peritoneal herniary sac. When the peritoneum is forced out so as to form a herniary sac, it becomes, on some occasions, greatly elongated, sometimes rendered thicker by an acquisition of cellular tissue, and sometimes thinner by over distension.

* Syn. Omentula intestini crassi.

† Syn. Cellulæ seu haustra.

‡ The colon, particularly its sigmoid flexure, is very subject to constrictions or stricture.

§ The sigmoid flexure, of all the portions of the colon, is the most subject to scirrhus, and cancerous ulceration, accompanied with stricture, and even total obstruction, producing great dilatation in the upper portion of the intestine.

‖ Syn. Valvula vidi vidii. Valvula Bauhini. Valvula ileo-colica.

as to form two commissures. The atlantad or superior is narrower than the sacral or inferior, situated nearly horizontal, and forms almost a right angle with the ascending portion of the colon. The inferior or sacral is larger, and describes a more acute angle with this portion of the colon. These folds, *v*, overlap each other, and, when separate, they form an elliptic aperture of considerable magnitude, fully the size of the ileum. *

The appendix vermiformis, marked 29, in Plate XII., and in Figs. 2 and 3 of Plate LXXXVII., is a peculiar funnel shaped prolongation of the colon at its caput cœcum, generally about three inches long, and is therefore the shortest and narrowest portion of the alimentary tube. In the connected state, it is generally hid by the caput cœcum and ileum, and has a short narrow mesocolic production which binds it down, and gives it a tortuous appearance. It possesses peritoneal, muscular, and mucous tunics, like the rest of the alimentary canal. Its muscular coat is formed by the termination, or commencement of the three longitudinal muscular bands of the colon. It commences by an open mouth, at the beginning of the caput cœcum, as represented in Fig. 3 of Plate LXXXVII., where there is a number of mucous glands, which are still more numerous on the mucous tunic of this appendix. Morgagni describes a sort of transverse fold or species of valve being found at the mouth of this appendix, but this I have never observed.

The nervous and vascular distributions to the colon have been formerly described. †

The course of the rectum, the widest in diameter of the intestines, has been already generally described in page 193, and marked I, in Plates XIII., XIV., XXII., LXXXIII., and LXXXIV., in the last of which the I has an asterisk * after it, and in Plates XCIII. and XCIV. In the female subject, it is observed to descend behind, or sacrad to the uterus, k, and the vagina, D, adhering intimately to the latter, but in no degree with the former; ‡ and leaving the vagina where the perineum, E, Plate XCI., intervenes, this space being occupied by the sphincter vaginæ, N, sphincter ani, r, and levator ani, s, muscles, as represented in Plate XCII., together with the integuments, and cellular and adipose substances. In this course the rectum adheres by cellular substance to the os sacrum, B, and os coccygis, being in its extent from the promontory of the sacrum to that part where it is not invested with the peritoneum, a little sinistrad from the mesial line; but from the part uncovered with the peritoneum to its forming the anus, as that marked I* in Plate XCIII., it runs precisely in the mesial line.

As delineated in Plate XCIV., the peritoneum, *a*, is observed to extend along the rectum, I, encircling it for some extent a little beyond or coccygead to the os uteri, R, when it stops, and from thence re-ascends to be reflected on the sacral aspect of the uterus, k. The lateral folds of this inflection or cul-de-sac, which run somewhat longitudinally, are named plicæ semi-lunares. At the promontory of the sacrum, and for a little extent downwards in the pelvis, the rectum is so encircled with the peritoneum, that there is a mesentery here formed, named mesorectum; a short distance, however, before the peritoneum is reflected on the os uteri, this membrane only clothes the anterior or pubic aspect of the rectum; coccygead to this, the rectum, marked I*, is totally divested of a peritoneal tunic.

The muscular fibres of the rectum are remarkably numerous and strong, are arranged longitudinally, being the continuation of those fibres forming the longitudinal muscular bands of the colon, and are represented in Plates XCIII. and XCIV.; there are also circular muscular fibres, * situated beneath or centrad to these longitudinal ones.

In the male, the course of the peritoneum is different; it does not encircle the rectum so far coccygead, but invests only its pubic aspect, as represented by the white line extending between the rectum, I, and bladder, m, in Plate XXII.; and from the rectum, I, it is reflected on the urinary bladder, m, and ascends to its fundus; this fold or doubling of the peritoneum being named the cul-de-sac. †

The rectum proceeds along the coccyx, covered by the levator ani muscle, r, and projecting beyond the coccyx, is covered and supported by the sphincter ani muscle, s, and terminates in forming the anus, I**, the mucous membrane here uniting with, or running into the cutaneous. ‡ The mucous membrane, of a whitish colour near the colon, becomes slightly rosy near the anus, is loose, and studded with simple mucous glands, § which, however, are not very numerous.

I shall now proceed to the description of the fixed viscera, beginning with the liver.

The liver, || marked with the letters i in Plates IX., XII., LXXXIII., LXXXIV., LXXXV., and LXXXVI., is the largest conglomerate gland in the body, is situated in the right hypochondriac, the epigastric, and in the left hypochondriac regions; and is observed to extend more into the left hypochondriac region in woman than in man. In the fetus, the liver bears a considerably larger proportion to the other viscera, than in the adult. The liver descends much lower or sacrad on the right than on the left side; its right extremity rests on the right kidney, its left on the stomach near its cardiac orifice, while its free margin floats on the stomach, duodenum, and colon, extending outwards or periphero-sacrad nearly to the sacral margins of the cartilages of the last true and all the false ribs of the right side. It is held in this situation by duplicatures of the peritoneum, which are named the liga-

* The attachments and configuration of these folds, together with the direction of this aperture, should be considered with regard to overcoming the obstacle offered by them, when employing enemata in volvulus.

† The extent of the cœcum, which is about an inch and a half from the ileum, together with the cells of the colon, should be carefully examined in their relation to the lodgement of scybalæ, to constipation, cholera, and dysentery. And the nervous, vascular, and mucous structures of the colon should be examined, in reference to these diseases, and also to diarrhœa, spasm, enteritis, tubercles, and hemorrhage. Calcareous concretions are sometimes formed in the colon.

‡ In extirpation of the uterus, the non-connexion of the uterus with the rectum should be kept in view.

* The rectum, from its muscularity, is subject to both spasmodic and permanent stricture.

† This inflection of the peritoneum should be duly considered by the operator in puncturing the urinary bladder, and in the recto-vesical operation for calculus in the bladder.

‡ Children are not unfrequently born with an imperforate anus, in which case the rectum terminates in the male one or more inches from the site of the anus, sometimes joining the urinary bladder, at others the urethra; and in the female, in the vagina, or within an inch or two of the anus. The accoucheur should, therefore, be on his guard for such malformations, and both he and the operator ought to make themselves perfectly masters of the pelvic viscera and their blood-vessels.

§ These glands are very subject to disease, viz. to inflammation and suppuration, to tubercles, to stricture, to scirrhus, and cancer.

|| Syn. Hepar. Jecur.

ments of the liver. In early age onwards to the meridian of life, the colour of the liver is a reddish-brown; but after this period, it progressively becomes darker in colour. The peritoneum, a, a, after investing the diaphragm, B, B, as delineated in Fig. 2 of Plate LXXXV., unites in the mesial line of the body, beneath or centrad to the linea alba, from the umbilicus onwards near to the middle of the diaphragm, to form the suspensory ligament,* A, of the liver, which is further strengthened at its free margin by the round ligament, † C. These descend centrad or dorsad in the liver between its two great lobes, I, i; the suspensory ligament, A, again expanding on the convex aspect of the liver to become the peritoneal envelope of this organ. The round ligament, C, which was the umbilical vein in the fetus, is also surrrounded with the peritoneum, begins at the umbilicus, and descends between the two great lobes, I, i, to become incorporated likewise with the peritoneal investment of the liver. When we reflect downwards or sacrad the sternal margins of the two lobes, I, i, of the liver, so as to remove them a little from the diaphragm, B, we find the peritoneum, a, proceeding from the one organ to the other; and this angular fold, or angle of inflection of the peritoneum, is termed the coronary ligament of the liver. A considerable portion, therefore, of the liver adheres to the diaphragm through the medium of cellular substance; hence this viscus, like the intestines, is not entirely surrounded with the peritoneum. At the left extremity of the liver, where it projects into the left hypochondriac region, the peritoneum forms a loose doubling like the suspensory ligament, which extends between the left lobe of the liver, i, and the diaphragm, B, and is denominated the left lateral ligament of the liver,‡ and is marked E. A similar ligamentous production extends between the right lobe, I, and the diaphragm, B, which is named the right lateral ligament. § Other ligaments are described by authors, as the ligamentum hepato-colicum, which is a production of the peritoneum, extending from the gall bladder along its duct, and the duodenum to the colon: this, however, is the result of disease. A ligamentum hepato vel hepatico-renale, or plica hepatico-renalis, which connects the root of the right lobe of the liver to the right kidney, is also described; but this portion of the peritoneum is flat and adherent, and not entitled to the appellation of ligament. The peritoneum invests all the surface of the liver, with the exception of those points already described, and where the gall bladder, e, rests, and also where the liver rests on the vertebral column, or rather on the crura of the diaphragm, and likewise where the vena cava runs, as will be understood by examining Plate LXXXIV.

The liver consists of a convex surface pointing towards the diaphragm, B, and of a concave surface, I, i, towards the other abdominal viscera; of a free thin margin, which points sternad and peripherad, and of a fixed thick margin pointing dorsad; of a right and a left extremity; of two distinct lobes, a right one marked I, and a left i, with an accessory one to the right termed the lobulus Spigelii, and marked k. Authors, however, describe a lobulus caudatus, ‖ which is merely the connecting isthmus between the right lobe, I, and the lobulus Spigelii, k, and is marked Y, in Fig. 2 of Plate LXXXVI.; and a lobulus quadratus vel anonymus,* which is the gentle elevation between the gall bladder, e, and the pons hepatis, H, and is marked G in Fig. 2 of Plate LXXXV.

The right lobe, I, situated dextrad of the round ligament, C, lies in the right hypochondriac region, is much the largest, being nearly four times larger than the left, forming all the lesser lobes, and occasionally almost the whole bulk of the liver. Between the right, I, and left, i, lobes, or, if we make a quadratus, between the quadratus, G, and the left lobe, i, there is a small square portion of the liver, marked H, named the pons hepatis,† extending over the sulcus between the right and left lobes, which sulcus, marked V in Fig. 2 of Plate LXXXV., lodges the round ligament, C, that was the umbilical vein in the fetus, and hence termed fossa umbilicalis.‡ The continuation of this umbilical fossa downwards between the lobulus Spigelii and the left lobe, is named fossa ductus venosi, § from lodging this vein, one of the continuations of the umbilical vein in the fetus; while the whole extent of this sulcus, or both of these just enumerated, is named by some, fossa longitudinalis sinistra. The pons hepatis is frequently deficient.

The lobulus Spigelii, k, ‖ is merely a projection of the right lobe, and with the quadratus, G, forms what is named the porta, which gives entrance to the vena portæ, N, together with the hepatic artery, q, and exit to the hepatic duct, *f*. The hepatic plexus of nerves and lymphatic vessels also pass and repass here. The space bounded by the lobulus Spigelii, k, and quadratus, G, which are opposite each other, and by the diagonal points, the caudatus, Y, and contiguous projection of the left lobe, ¶ and all of which surround these vessels and ducts, is denominated the sinus of the vena portæ.**

On the dorsal aspect of the right lobe, between it and the lobulus Spigelii, as represented in Fig. 2 of Plate LXXXVI., a conspicuous depression or sulcus is observable, which is occupied by the vena cava ascendens, that frequently is imbedded in the substance of the liver at this part, and is termed fissura venæ cavæ.†† In Plate LXXXIV., which is a posterior view of the thoracic and abdominal viscera, the vena cava, *i*, is seen running imbedded in the substance of the liver marked i; there is, therefore, here no peritoneal investment. The vena cava is joined, during its passage along the liver, by the venæ hepaticæ, which open generally with eight mouths, as described in page 41. A little sinistrad of this last sulcus, on the dorsal aspect between the right and left lobes, a very gentle depression is observable, made by the spinal column, but from the diaphragm intervening, this depression is always very slight; there is here also no peritoneal covering.

The only other depression is that made by the gall bladder, e, on the concave aspect of the right lobe, dextrad

* Syn. Ligamentum latum. Ligamentum suspensorium. Ligamentum falciforme. Suspensorium hepatis. Middle ligament of liver.

† Syn. Ligamentum teres. Umbilical ligament.

‡ Syn. Le ligament triangulaire gauche.

§ Syn. Le ligament triangulaire droit.

‖ Syn. Processus caudatus.

* Syn. Lobulus accessorius. Lobulus anterior.

† Syn. Isthmus hepatis.

‡ Syn. The great fissure. Horizontal fissure. Fossa anterior, longa, longitudinalis. The great scissure. Fovea pro vena umbilicali, seu ligamento terete.

§ Syn. Sulcus ductus venosi. Left fissure. Posterior fissure.

‖ Syn. Lobulus posterior. Lobulus papillatus.

¶ This projection of the left lobe is named, by some authors, lobulus lobi sinistri.

** Syn. Sinus portarum. Sulcus transversus. Principal fissure. Sulcus intermedius seu transversus.

†† Syn. Fossa venæ cavæ.

of the lobulus quadratus, G, as delineated in Fig. 2 of Plate LXXXV. In Plate LXXXVI. the gall bladder is removed from its depression, which is marked W,* and is not invested with peritoneum, this membrane gliding from the liver over the exposed surface of the gall bladder, in order to retain the latter in its situation. In the fetus, the gall bladder projects more out from the liver than in the adult. The right kidney generally makes a slight indentation on the right lobe.

The vena portæ, marked N, n, *n*, in Plate XII., and in Figs. 2 of Plates LXXXV. and LXXXVI., has been already described in page 41, and so also have the hepatic veins in the same page, and the hepatic artery, q, in page 40. In page 41, the vena portæ, N, is described onwards to its division in the substance of the liver. In a successful injection, its minute branches are found to consist of two series, a smaller and a larger; the larger is subdivided ultimately into vessels about a line in diameter, which communicate directly with the commencements of the hepatic veins, already described in page 41. The smaller and much more delicate branches can be traced to the pori biliarii, or the commencements of the hepatic ducts, which do not inosculate with them. These terminations of the vena portæ are named penicilli. Some of these delicate branches proceed to the cortical substance of the liver.

On making a section of the liver, or in tracing the vessels and ducts into its substance, as delineated in Fig. 2 of Plate LXXXV., besides the ramifications of the vena portæ, the hepatic artery, the hepatic veins, the hepatic nerves, lymphatics, and the hepatic duct, together with a quantity of cellular substance, we perceive that it consists of two textures mingled together, the one alternating with the other. At first sight they appear to consist of undulating bands about half a line in thickness, but on more minute investigation, the yellowish coloured texture forms a coherent mass interspersed throughout, and producing a multitude of elevations and depressions, at the same time that there occurs a number of interruptions, thus forming a very complicated structure. This is compared to the medullary structure of the brain or kidney, and if more minutely examined, consists of small points or grains. In these intervals or gaps, which are scarcely a line in diameter, and of a polygonal starry shape, a much softer and less transparent texture is found, which is compared to the cortical structure of the brain or kidney. The smallest collections of these two textures are named lobuli, or acini.

The hepatic duct, † *f*, in Plate XII., and in Figs. 2 of Plates LXXXV. and LXXXVI., is observed to be formed in the last of these plates by a multiplicity of smaller ducts, which accompany the subordinate branches of the vena portæ, and concentrate in the first instance into two large branches, and secondly into one trunk. The one branch proceeds from the right, and the other from the left lobe of the liver. The minute commencements of these smaller biliary or hepatic ducts are named pori biliarii, and seem to begin where the medullary and cortical substances unite; for they are never found to originate from the surface, but always from the interior of the liver.

* Syn. Fovea fellis. Vallicula vesiculæ felleæ. Fossa pro vesicula fellea. By some the depression of the gall bladder, and that for the vena cava, is considered as one fossa, and named fossa longitudinalis dextra.

† Syn. Ductus excretorius hepatis.

The hepatic duct, *f*, emerges from the liver at the sinus portarum, and after a short course is joined by the cystic duct, *e*, the union of which constitutes the ductus communis choledochus, M,* that proceeds sacrad and dorsad of the duodenum, c, the coats of which it pierces between three and four inches from the pyloric orifice, T, of the stomach, as described at page 195. The ductus communis choledochus, M, together with a portion of the cystic, *e*, and hepatic, *f*, ducts, the vena portæ, N, the hepatic artery, q, the hepatic plexus of nerves, and the lymphatics of the liver, are all enveloped in a production of the peritoneum, which unites them together. That which more immediately surrounds the vena portæ, the hepatic artery, and hepatic duct, and accompanies them into the substance of the liver, is named the capsule of Glisson, which has been already described in page 41.

The cystic duct, *e*, is observed in Figs. 2 of Plates LXXXV. and LXXXVI. to be the excretory tube of the gall bladder, e, the latter of which is situated in a depression, w, on the concave surface of the right lobe, I, of the liver. The gall bladder,† of a pyriform shape, consisting of a fundus or its larger round bulbous extremity, a body or middle, a cervix or its narrow contracted extremity, and a mouth contiguous to this latter, is thus imbedded in the liver, and retained by the peritoneum gliding from the right lobe, I, over the gall bladder, e, to the lobulus quadratus, G, as illustrated in Fig. 2 of Plate LXXXV. It has thus a partial peritoneal coat. Beneath or centrad to this there is a delicate muscular tunic, the peripheral or outer surface of which is of a whitish colour, and throughout which a number of blood-vessels are found distributed. Underneath this muscular tunic there is a mucous coat, presenting an elegant reticular appearance, the figures of which are irregular pentagons, resembling that of the stomach. Small apertures are perceptible over this mucous surface, which are the mouths of glandular lacunæ or small mucous glands. Transverse folds are described by some authors as being found at the neck of the gall bladder, and in the cystic duct, having their free edges pointing to the gall bladder; but these seem to be merely the free folds of the cells accumulated, and have a longitudinal or spiral more than a transverse direction. Neither the cystic nor the hepatic duct appear to possess muscular tunics. Both of them have a peritoneal, a condensed cellular analogous to a muscular, and a mucous coat. In the interior of the liver the hepatic duct has merely the condensed cellular and mucous coats. Both the hepatic and common choledoch ducts have smoother mucous tunics than the cystic, and have numerous mucous lacunæ opening into them. ‡

The spleen, marked F, in Plates IX., XII., LXXXIII.,

* Syn. Common duct. Ductus choledochus. Ductus hepatico-cysticus.

† Syn. Cystis. Vesicula fellea. Chole-cystis. Cystis fellis. Vesicula.

‡ The relative situation and the structure of the liver, together with its circulation and secretion, should be carefully investigated and considered by the practitioner, as it is subject to many diseases. It is involved more or less in all the affections of the stomach, and in every variety of fever. Its function of secretion is affected by every kind of diet, and every variation of the weather. It is concerned in icterus, and very easily ruptured by a fall or a blow; it is subject to hepatitis, acute and chronic, to hepatocele, abscess, ulceration, scirrhus, cancer, tubercles, hypertrophy, induration, softening, conversion into adipose tissue, and to ossification of its investment. Its ducts are subject to spasmodic and permanent stricture, to obstruction, and to calculi. The gall-bladder is occasionally deficient, and in some instances a double gall bladder has been found.

and LXXXIV., and in Fig. 2 of Plate LXXXV., is an oblong shaped viscus, of a dark purple colour, situated in the left hypochondriac region, between the left extremity of the stomach and the diaphragm, and held in this situation by the peritoneum reflected from the diaphragm, from the pancreas along the vessels of the spleen, from the stomach and colon through the medium of the omentum majus and vasa brevia, and also from the left kidney. In some cases the omentum majus extends from the œsophagus along the great arch of the stomach to the spleen, and this portion has been named, by some authors, vinculum inter œsophagum et lienem. The extension of the peritoneum from the spleen to the kidney is also termed by some, plica renalis et capsularis. But sometimes we find these productions of the peritoneum remarkably delicate, while at others of some strength, but on no occasions so strong as to entitle them to the appellation of ligaments. The spleen is thus invested with a peritoneal tunic, and beneath or central to it is a fibrous coat, with which it is so intimately united as to be incapable of separation, excepting at the fissure where the blood-vessels enter its substance, and even there only for a very trifling extent. The surface of the spleen which is opposed to the diaphragm is convex, while that which rests on the left extremity of the stomach is concave, an acute margin forming the limits of these two surfaces. This margin is sometimes notched, as in Fig. 2 of Plate LXXXV. On the concave aspect we observe a fissure, by which the blood-vessels enter, surrounded with a quantity of cellular and adipose substances. The splenic artery, r, and its accompanying vein, *s*, have been already described in page 40, onwards to their entering this viscus; and in Fig. 3 of Plate LXXXV. these vessels are developed onwards to their distribution into the substance of this organ. The artery divides into a number of ramifications, which terminate in the most delicate twigs, grouped like the hair of a paint-brush, without inosculating. The veins are arranged around these arterial bundles, anastomose frequently with one another, and with those in their contiguity.

Its texture is remarkably soft and delicate, and appears to be entirely formed of blood-vessels; there is, however, a multitude of lamellæ and delicate fibrous prolongations proceeding from its fibrous investment, interwoven in a variety of ways, leaving irregular intervals for the distribution of the blood-vessels. There are also a multiplicity of white round soft corpuscles, plentifully supplied with the blood-vessels. The nerves distributed on the spleen have been already described. It has also a number of lymphatics. *

The pancreas, marked D, in Plates XII., LXXXIV., and in Fig. 2 of Plate LXXXV., is an oblong shaped flattish conglomerate gland, situated in the epigastric and left hypochondriac regions, and extending transversely across the spinal column, having the stomach on its sternal and the second last dorsal vertebra on its dorsal aspect, and the liver on its dextral, and the spleen on its sinistral aspect, and encircled by the convolutions of the duodenum. It has been compared in shape to the tongue of the dog, the root being its right or duodenal extremity, and the apex its left or splenic extremity; having also an anterior or sternal surface compared to the dorsum of the tongue, and a posterior or dorsal surface compared to the inferior surface of the tongue; likewise two sides or margins, an upper or atlantal, and a lower or sacral; and lastly, a body or central portion. Its sternal or anterior surface is invested with the peritoneum, while its posterior or dorsal aspect adheres by cellular substance to the duodenum, the vena portæ, the superior mesenteric artery and vein, the splenic artery and vein, the aorta, the crura of the diaphragm, and the atlantal extremity of the left kidney. It has, therefore, only a partial peritoneal tunic, but a complete cellular one, the cellular membrane running beneath the peritoneal tunic. By some it is compared to the figure of a hammer, and is described as being situated between the folds or laminæ of the mesocolon, but this is evidently incorrect.

The pancreas is of a yellowish brown colour, and precisely resembles the parotid and other salivary glands. On first examination, it is of a pretty firm consistence; but its lobes may be divided into grains, or granulæ, or acini of extreme tenuity, which are only held together by a very loose cellular tissue.

On making a longitudinal section of the pancreas, as delineated in Fig. 2 of Plate LXXXV., a long white duct * is displayed running throughout its whole length, beginning at its sinistral extremity, by several smaller ducts uniting at an acute angle, and being joined in its progress by a multiplicity of other small branches at a right angle; it terminates in the duodenum, c, either by one or two tubes, or joins the ductus communis choledochus, M, immediately at its termination in the duodenum; the latter of which is the more common occurrence, as described in page 195. Some are of opinion that the large pancreatic duct never enters the common choledoch duct, but runs on its left side separately, onwards to the duodenum, passing, like the biliary duct, between its coats. This duct joins occasionally the duodenum, nearly ten inches distant from the pylorus. The pancreatic duct has been found occasionally double throughout. Near its termination in the duodenum, it generally receives one or two conspicuous branches from that portion of the gland attached to the duodenum, which is named by some authors the head of the gland, and by others, the pancreas minus. These smaller ducts, however, occasionally terminate separately in the duodenum. When we trace the small ducts which feed the large one, we find them originating at the small grains. † The nerves and blood-vessels of the pancreas have already been described in pages 40, 41, and 43.

The kidney, marked Y, in Plates XIII., LXXXIV., and in Figs. 2 and 3 of Plate LXXXVIII., is a large conglomerate gland of the shape of the French bean (phaseolus), situated in the renal or lumbar region, between the last or twelfth rib and the crista of the os ilium, the right kidney being placed a degree lower or more sacral than the left, in consequence of the situation of the liver. It is situated dorsad, or behind the peritoneum, between it and the psoas magnus and quadratus lumborum muscles, adhering to all of them by loose cellular substance. The

* The delicate structure of the spleen should be considered by the practitioner, as it is easily ruptured in falls or by blows. It is involved in all affections of the stomach and liver; is subject to hypertrophy, splenitis, splenocele, scirrhus, tubercles, induration, and to ossification of its membranes. Appendages of the spleen, named accessory, not unfrequently exist, and are situated on its concave aspect, near its inferior or sacral extremity.

* Syn. Ductus pancreaticus. Ductus Wirsungianus.

† The pancreas is involved in scirrhus and cancer of the stomach, occasionally in diseases of the liver and spleen, and is subject to hypertrophy, induration, scirrhus, and cancer. Calcareous concretions have been found in its duct.

of the lobulus quadratus, G, as delineated in Fig. 2 of Plate LXXXV. In Plate LXXXVI. the gall bladder is removed from its depression, which is marked W,* and is not invested with peritoneum, this membrane gliding from the liver over the exposed surface of the gall bladder, in order to retain the latter in its situation. In the fetus, the gall bladder projects more out from the liver than in the adult. The right kidney generally makes a slight indentation on the right lobe.

The vena portæ, marked N, n, *n*, in Plate XII., and in Figs. 2 of Plates LXXXV. and LXXXVI., has been already described in page 41, and so also have the hepatic veins in the same page, and the hepatic artery, q, in page 40. In page 41, the vena portæ, N, is described onwards to its division in the substance of the liver. In a successful injection, its minute branches are found to consist of two series, a smaller and a larger; the larger is subdivided ultimately into vessels about a line in diameter, which communicate directly with the commencements of the hepatic veins, already described in page 41. The smaller and much more delicate branches can be traced to the pori biliarii, or the commencements of the hepatic ducts, which do not inosculate with them. These terminations of the vena portæ are named penicilli. Some of these delicate branches proceed to the cortical substance of the liver.

On making a section of the liver, or in tracing the vessels and ducts into its substance, as delineated in Fig. 2 of Plate LXXXV., besides the ramifications of the vena portæ, the hepatic artery, the hepatic veins, the hepatic nerves, lymphatics, and the hepatic duct, together with a quantity of cellular substance, we perceive that it consists of two textures mingled together, the one alternating with the other. At first sight they appear to consist of undulating bands about half a line in thickness, but on more minute investigation, the yellowish coloured texture forms a coherent mass interspersed throughout, and producing a multitude of elevations and depressions, at the same time that there occurs a number of interruptions, thus forming a very complicated structure. This is compared to the medullary structure of the brain or kidney, and if more minutely examined, consists of small points or grains. In these intervals or gaps, which are scarcely a line in diameter, and of a polygonal starry shape, a much softer and less transparent texture is found, which is compared to the cortical structure of the brain or kidney. The smallest collections of these two textures are named lobuli, or acini.

The hepatic duct,† *f*, in Plate XII., and in Figs. 2 of Plates LXXXV. and LXXXVI., is observed to be formed in the last of these plates by a multiplicity of smaller ducts, which accompany the subordinate branches of the vena portæ, and concentrate in the first instance into two large branches, and secondly into one trunk. The one branch proceeds from the right, and the other from the left lobe of the liver. The minute commencements of these smaller biliary or hepatic ducts are named pori biliarii, and seem to begin where the medullary and cortical substances unite; for they are never found to originate from the surface, but always from the interior of the liver.

* Syn. Fovea fellis. Vallicula vesiculæ felleæ. Fossa pro vesicula fellea. By some the depression of the gall bladder, and that for the vena cava, is considered as one fossa, and named fossa longitudinalis dextra.

† Syn. Ductus excretorius hepatis.

The hepatic duct, *f*, emerges from the liver at the sinus portarum, and after a short course is joined by the cystic duct, *e*, the union of which constitutes the ductus communis choledochus, M,* that proceeds sacrad and dorsad of the duodenum, c, the coats of which it pierces between three and four inches from the pyloric orifice, T, of the stomach, as described at page 195. The ductus communis choledochus, M, together with a portion of the cystic, *e*, and hepatic, *f*, ducts, the vena portæ, N, the hepatic artery, q, the hepatic plexus of nerves, and the lymphatics of the liver, are all enveloped in a production of the peritoneum, which unites them together. That which more immediately surrounds the vena portæ, the hepatic artery, and hepatic duct, and accompanies them into the substance of the liver, is named the capsule of Glisson, which has been already described in page 41.

The cystic duct, *e*, is observed in Figs. 2 of Plates LXXXV. and LXXXVI. to be the excretory tube of the gall bladder, e, the latter of which is situated in a depression, w, on the concave surface of the right lobe, I, of the liver. The gall bladder,† of a pyriform shape, consisting of a fundus or its larger round bulbous extremity, a body or middle, a cervix or its narrow contracted extremity, and a mouth contiguous to this latter, is thus imbedded in the liver, and retained by the peritoneum gliding from the right lobe, I, over the gall bladder, e, to the lobulus quadratus, G, as illustrated in Fig. 2 of Plate LXXXV. It has thus a partial peritoneal coat. Beneath or centrad to this there is a delicate muscular tunic, the peripheral or outer surface of which is of a whitish colour, and throughout which a number of blood-vessels are found distributed. Underneath this muscular tunic there is a mucous coat, presenting an elegant reticular appearance, the figures of which are irregular pentagons, resembling that of the stomach. Small apertures are perceptible over this mucous surface, which are the mouths of glandular lacunæ or small mucous glands. Transverse folds are described by some authors as being found at the neck of the gall bladder, and in the cystic duct, having their free edges pointing to the gall bladder; but these seem to be merely the free folds of the cells accumulated, and have a longitudinal or spiral more than a transverse direction. Neither the cystic nor the hepatic duct appear to possess muscular tunics. Both of them have a peritoneal, a condensed cellular analogous to a muscular, and a mucous coat. In the interior of the liver the hepatic duct has merely the condensed cellular and mucous coats. Both the hepatic and common choledoch ducts have smoother mucous tunics than the cystic, and have numerous mucous lacunæ opening into them.‡

The spleen, marked F, in Plates IX., XII., LXXXIII.,

* Syn. Common duct. Ductus choledochus. Ductus hepatico-cysticus.

† Syn. Cystis. Vesicula fellea. Chole-cystis. Cystis fellis. Vesicula.

‡ The relative situation and the structure of the liver, together with its circulation and secretion, should be carefully investigated and considered by the practitioner, as it is subject to many diseases. It is involved more or less in all the affections of the stomach, and in every variety of fever. Its function of secretion is affected by every kind of diet, and every variation of the weather. It is concerned in icterus, and very easily ruptured by a fall or a blow; it is subject to hepatitis, acute and chronic, to hepatocele, abscess, ulceration, scirrhus, cancer, tubercles, hypertrophy, induration, softening, conversion into adipose tissue, and to ossification of its investment. Its ducts are subject to spasmodic and permanent stricture, to obstruction, and to calculi. The gall-bladder is occasionally deficient, and in some instances a double gall bladder has been found.

heres to its surface. This organ is of a tolerably firm lobulated texture like the parotid gland, of a yellowish brown externally, and of a reddish brown internally. The external yellowish brown texture is firmer, and consists of fibres arranged perpendicularly from without inwards; while the internal reddish brown texture is softer, and forms the parietes of a small triangular cavity, which is supposed by some not to exist until after death, and that then it is the result of a spontaneous decomposition of the internal texture; but I may remark, that it is more easily discovered in the fresh than in the putrid state. The renal capsule is an imperfect gland, having no excretory duct.

The blood-vessels of the renal capsule have been described in page 41.*

The pelvis of the kidney, marked P, in Figs. 2 and 3 of Plate LXXXVIII., I have already stated, diminishes in its calibre as it emerges from the concave fissure of the kidney to form the ureter, w. The ureter, marked w, in Figs. 2 and 3 of Plates LXXXVIII., LXXXIV., and LXXXIII., and in Plates LXXXIX., XC., XCIII., XCIV., XXII., and XIII., in the last of which it is inadvertently marked f, descends behind or dorsad to the peritoneum, obliquely across the psoæ muscles, M, K, dorsad to the spermatic plexus, *g*, and sternad to the common iliac artery, P, and then enters the pelvic cavity, running parallel with the internal iliac artery, V, towards the body of the urinary bladder, m, along which it extends near to its cervix, where it runs between its muscular and mucous tunics, and terminates by an orifice smaller in diameter than itself. In its course in the pelvis of the female it runs by the side of the uterus, k, and in that of the male it passes outwards or laterad to the vas deferens, v. The precise termination of the ureter in the male is displayed in Plates XXII., LXXXIX., and XC., and in the female, in Plates XCIII. and XCIV., whalebone probes, marked s, being inserted in the termination of the ureters in Plates XC. and XCIV.

The ureter is formed of three tunics, a cellular which is very loose, a muscular which appears condensed, fibrous, cellular substance, and a mucous that is thin and loose, and continuous with that investing the papillæ of the kidney, and with that of the urinary bladder.†

VISCERA OF THE PELVIS,

TOGETHER WITH

THE ORGANS OF GENERATION IN THE MALE AND FEMALE.

In the description of the viscera of the pelvis, I shall pursue the same connected arrangement as I have adopted with regard to those of the abdomen, and not in the order which the student should follow.‡ In the male pelvis there are situated the urinary bladder and rectum, with the ureters, the vasa deferentia, the vesiculæ seminales, and the prostate gland, with various nerves, blood-vessels, lymphatics, and muscles. In the female pelvis there are the urinary bladder, the ureters, the rectum, the uterus with its appendages, the vagina, and several nerves, blood-vessels, lymphatics, and muscles.

The urinary bladder, marked m, in Plates IX., XIII., XIV., XXII., LXXXIII., XC., LXXXIX., XCIII., and XCIV., is situated in the pelvic cavity, close to the ossa pubis, supported by the peritoneum, a, and loose cellular tissue, by its anterior ligaments, by the umbilical arteries, which are ligamentous cords in the adult, and are marked *n* in Plate XIV. and Fig. 6 of Plate X., and by the ura-

---

* There is sometimes an increase of the renal capsule, so as to make it resemble more than one. It is besides subject to hypertrophy.

† The ureter is sometimes deficient, occasionally terminates in the abdominal parietes between the umbilicus and symphysis pubis, frequently double on one side. It is subject to constriction, stricture, dilatation, and to calculus.

‡ The student, when investigating the pelvic viscera and organs of generation of the male, should first examine the inflections of the peritoneum, particularly as they relate to puncturing the bladder above the pubes or from the rectum, and to the high operation or the recto-vesical or lateral operation of lithotomy; next the structure of the scrotum and testes, tracing the course of the vasa deferentia to the sides of the urinary bladder; thirdly, the external nerves, blood-vessels, and muscles of the perineum, and particularly as they relate to lithotomy; fourthly, the component parts of the penis from the glans onwards to the urinary bladder, deliberately studying the relation of these and the contiguous parts to lithotomy, to stricture of the urethra and fistulæ in perinæo; fifthly, the relation of the rectum to the prostate gland, urinary bladder, and *cul-de-sac* of the peritoneum, as regards the recto-vesical operation and the lateral operation of lithotomy, and also for puncturing the bladder; sixthly, let him trace the blood-vessels distributed to these organs within the pelvis, from the inferior mesenteric and from the internal iliac arteries; seventhly, let him detach the one-half of the pelvis, together with one of the extremities, as in Plate XXII. (the left side is the preferable to remove), paying great attention at the time to the strength and course of the levator ani muscle while dividing it; he ought now to trace the vasa deferentia round the bladder to the vesiculæ seminales, and onwards to the prostate gland, and examine deliberately the relation of these organs to lithotomy and the different operations specified; lastly, let him remove, in a mass, the urinary bladder, rectum, and penis, dividing the vasa deferentia near the inguinal canals. Having removed these important organs, he should again examine their connexion and relation to each other, and then proceed to investigate minutely their structures, beginning with the urinary bladder; next, the urethra; thirdly, the vasa deferentia, the vesiculæ seminales, and prostate gland; fourthly, the corpora cavernosa, &c. Before beginning the examination of these viscera, the student should insert again and again the catheter or sound in the urethra, and feel along the urethra from the glans penis to the anus, and also introduce the fingers of his left hand into the anus. When exploring these viscera and organs in the female, a similar order should be pursued:—First, the inflections of the peritoneum are to be traced as they relate to the supporting of the uterus and its appendages, to puncturing the urinary bladder above the pubes, and to extirpating the uterus or ovaria; secondly, the nature, relations, and course of the external parts and the anus, examining carefully the relation of the clitoris to the meatus urinarius, the situation of the circulus membranosus, the os uteri, and the perineum; thirdly, the external nerves, blood-vessels, and muscles of the perineum; fourthly, the arteries and veins and nerves distributed to the urinary bladder, uterus, and rectum; fifthly, let him remove in a mass, the bladder, uterus, and rectum, examining, during their removal, the course of the levator ani, and the course of the blood-vessels and ureters. When these organs have been removed, he should investigate their relations and connexions more deliberately, and afterwards manipulate their minute structure. He should particularly attend to the structure of the clitoris, to the extent of the urethra, to the connexion between the urinary bladder and the vagina, to the extent and structure of the perineum, to the structure of the uterus and its appendages, and to the connexion between all of them.

kidney occasionally extends on the left side so high as the eleventh or even the tenth rib, but on the right seldom higher than the eleventh.

The kidney has a convex lateral and a concave mesial margin, with a concavity or fissure at the latter;* an upper or atlantal, and a lower or sacral extremity; an anterior or sternal, and a posterior or dorsal surface. At its atlantal extremity there is a glandular tissue, marked *y*, in Plate LXXXIV., named capsula renalis;† and at its concave mesial margin the renal artery, C, with its accompanying vein, and the ureter, W, enter and emerge, and there is a quantity of adipose and loose cellular tissues found here. The peritoneum merely glides over the sternal surface of the kidney, there being interposed a quantity of adipose tissue; a profusion of loose cellular tissue surrounds the whole of the kidney, constituting its cellular tunic;‡ and beneath or centrad to this is a white fibrous membrane, rough on both its surfaces, closely investing also the whole of the gland which is named its tunica propria. By some authors this membrane is not allowed to be sensibly fibrous, but only to be very solid, and approach very closely to fibrous membranes.

The kidney consists of two textures, a cortical,§ marked B, in Figs. 2 and 3 of Plate LXXXVIII., and a medullary,‖ marked *p**, in the same figures. The cortical substance, B, completely encircles the medullary, *p**, and even sends prolongations between the various papillæ, *p**, which constitute the medullary structure, to the concavity of the gland. The cortical is of a lighter red than the medullary, of a softer consistence, and consists almost entirely of blood-vessels and glandular corpuscles,¶ which are the commencements of the tubuli uriniferi.

The arterial vessels are exceedingly delicate,—they encircle and penetrate the glandular corpuscles, which are of various figures, being either round, quadrangular, pentagonal, or hexagonal; and the commencements of the tubuli uriniferi here begin, being connected with the blood-vessels by a soft whitish cellular tissue. These tubuli** are small, of a whitish colour, and very flexuous, forming a diversity of figures, inosculating freely with each other, and running for the most part insulated, but sometimes united in pairs.

The medullary texture, marked with the letters *p**, consists of a number of conical or pyramidal bodies, varying from seven to twenty in number, with their bases pointing peripherad, and their apices centrad, towards the pelvis, P, of the kidney; the latter, or apices, *p*, being named papillæ uriniferæ.†† These medullary cones, *p**, nearly approximate each other, space being merely left for the blood-vessels to proceed to the cortical substance. This medullary substance is darker in colour, firmer, and harder than the cortical; it has fewer blood-vessels, consisting chiefly of straight uriniferous tubuli,‡‡ the continuation of the flexuous tubes in the cortical substance, which are now more concentrated, and consequently larger, and which run parallel with each other onwards to the papillæ, *p*, where they terminate by small apertures, either in a depression in the centre of the papillæ, *p*, or around these projections, from which, in a recent kidney, the urine may be with facility pressed out. In the majority of cases, the small depression is observable in the centre of the papillæ, in which the foramina, the mouths of the tubuli uriniferi are perceptible. Sometimes these cones are quite distinct at their bases, but are united at their apices.

The papillæ uriniferæ, *p*, are encircled by a large common membranous pouch, marked P, named the pelvis of the kidney, which is laid open in Fig. 3, bringing into view the manner in which these papillæ project into the cavity of the pelvis, and how each is surrounded with a loose fold of this membrane, termed its calyx, and the prolongation of which, towards the pelvis, together with the calyx, is styled infundibulum. These views are from the kidney of a subject about ten years old, and in which the infundibuli are not so well developed as in the adult. The pelvis, also, is not just so broad. The papillæ themselves have a very delicate extension of the membrane constituting the calyx spread over them. The pelvis, which is simply the accumulation of the infundibuli, or an enlargement of the ureter, W, immediately on its emergence from the concavity of the kidney, contracts to form the ureter, W; the course of which I shall defer tracing until I have described the vessels and capsula renalis. The renal plexus of nerves has been described in page 43, and the renal artery in page 41, onwards to the concave aspect of the kidney, where it divides into branches which run around and exterior to the pelvis, P, and proceed between the medullary cones, *p**, outwards to the cortical substance, B, where they subdivide and form arches turned towards each other, encircling and disposed in rays of most minute vessels around the glandular corpuscles, which they appear to form. The arterial branches, in their progress between the medullary cones, and even after they have formed the arches, do not inosculate. It is only the minute filaments disposed around the corpuscles which anastomose.*

The capsula renalis,† marked *y*, in Plate LXXXIV., situated on the upper or atlantal extremity of the kidney, Y, to which it adheres by cellular substance, is a triangular body, flattened anteriorly or sternad, and posteriorly or dorsad, having its apex pointing upwards or atlantad. The capsula renalis of the left side is less, and rises higher or atlantad, than that of the right side. Its anterior or sternal surface is invested with the peritoneum, and presents some furrows where the blood-vessels enter and emerge from its substance. It is surrounded or enveloped with a very thin serous membrane, which intimately ad-

* Syn. Hilus renalis. Scissure du rein. Bosom of the kidney. Fissure of the kidney. Sinus of the kidney.

† Syn. Glandula atrabiliaris.

‡ Syn. Membrana seu capsula renum adiposa.

§ Syn. Substantia corticalis, seu glandulosa, seu secernalis.

‖ Syn. Substantia medullaris, seu tubulosa, seu fibrosa, seu sulcata, seu striata, seu urinifera. La substance cannelle, ou sillonnée.

¶ Syn. Corpora globosa. Acini. Globuli arteriarum termini.

** Syn. Canales corticales. Conduits de Ferrein.

†† Syn. Papillæ renales. Substantia papillaris. Processus mammillaris. La substance mammelonnée.

‡‡ Syn. Ductus seu tubuli Belliana, seu renales.

* One or both kidneys are sometimes deficient; both have been found in the pelvic cavity; one of them is often much larger than the other; both are occasionally considerably larger than nature, being particularly elongated; and they are not unfrequently united into one by a bond of union, extending between their inferior or sacral extremities across the aorta and vena cava, having a semilunar shape. They sometimes present a lobulated appearance, like that of the cow. Two pelves and two ureters sometimes exist. The kidneys are subject to hypertrophy and to atrophy, in the latter of which cases they sometimes diminish greatly in volume, but what remains is solid, while at other times they preserve their size, but are converted into a very thin sac. They are subject to nephritis, abscess, scirrhus, cancer, tubercles, hydatids, and to calcareous depositions; also to Bright's yellow deposit.

† Syn. Ren succenturiatus. Capsula seu glandula supra-renalis seu atrabiliaris.

heres to its surface. This organ is of a tolerably firm lobulated texture like the parotid gland, of a yellowish brown externally, and of a reddish brown internally. The external yellowish brown texture is firmer, and consists of fibres arranged perpendicularly from without inwards; while the internal reddish brown texture is softer, and forms the parietes of a small triangular cavity, which is supposed by some not to exist until after death, and that then it is the result of a spontaneous decomposition of the internal texture; but I may remark, that it is more easily discovered in the fresh than in the putrid state. The renal capsule is an imperfect gland, having no excretory duct.

The blood-vessels of the renal capsule have been described in page 41.*

The pelvis of the kidney, marked P, in Figs. 2 and 3 of Plate LXXXVIII., I have already stated, diminishes in its calibre as it emerges from the concave fissure of the kidney to form the ureter, w. The ureter, marked w, in Figs. 2 and 3 of Plates LXXXVIII., LXXXIV., and LXXXIII., and in Plates LXXXIX., XC., XCIII., XCIV., XXII., and XIII., in the last of which it is inadvertently marked f, descends behind or dorsad to the peritoneum, obliquely across the psoæ muscles, M, K, dorsad to the spermatic plexus, *g*, and sternad to the common iliac artery, P, and then enters the pelvic cavity, running parallel with the internal iliac artery, V, towards the body of the urinary bladder, m, along which it extends near to its cervix, where it runs between its muscular and mucous tunics, and terminates by an orifice smaller in diameter than itself. In its course in the pelvis of the female it runs by the side of the uterus, k, and in that of the male it passes outwards or laterad to the vas deferens, v. The precise termination of the ureter in the male is displayed in Plates XXII., LXXXIX., and XC., and in the female, in Plates XCIII. and XCIV., whalebone probes, marked s, being inserted in the termination of the ureters in Plates XC. and XCIV.

The ureter is formed of three tunics, a cellular which is very loose, a muscular which appears condensed, fibrous, cellular substance, and a mucous that is thin and loose, and continuous with that investing the papillæ of the kidney, and with that of the urinary bladder.†

VISCERA OF THE PELVIS,

TOGETHER WITH

THE ORGANS OF GENERATION IN THE MALE AND FEMALE.

In the description of the viscera of the pelvis, I shall pursue the same connected arrangement as I have adopted with regard to those of the abdomen, and not in the order which the student should follow.‡ In the male pelvis there are situated the urinary bladder and rectum, with the ureters, the vasa deferentia, the vesiculæ seminales, and the prostate gland, with various nerves, blood-vessels, lymphatics, and muscles. In the female pelvis there are the urinary bladder, the ureters, the rectum, the uterus with its appendages, the vagina, and several nerves, blood-vessels, lymphatics, and muscles.

The urinary bladder, marked m, in Plates IX., XIII., XIV., XXII., LXXXIII., XC., LXXXIX., XCIII., and XCIV., is situated in the pelvic cavity, close to the ossa pubis, supported by the peritoneum, a, and loose cellular tissue, by its anterior ligaments, by the umbilical arteries, which are ligamentous cords in the adult, and are marked *n* in Plate XIV. and Fig. 6 of Plate X., and by the ura-

---

* There is sometimes an increase of the renal capsule, so as to make it resemble more than one. It is besides subject to hypertrophy.

† The ureter is sometimes deficient, occasionally terminates in the abdominal parietes between the umbilicus and symphysis pubis, frequently double on one side. It is subject to constriction, stricture, dilatation, and to calculus.

‡ The student, when investigating the pelvic viscera and organs of generation of the male, should first examine the inflections of the peritoneum, particularly as they relate to puncturing the bladder above the pubes or from the rectum, and to the high operation or the recto-vesical or lateral operation of lithotomy; next the structure of the scrotum and testes, tracing the course of the vasa deferentia to the sides of the urinary bladder; thirdly, the external nerves, blood-vessels, and muscles of the perineum, and particularly as they relate to lithotomy; fourthly, the component parts of the penis from the glans onwards to the urinary bladder, deliberately studying the relation of these and the contiguous parts to lithotomy, to stricture of the urethra and fistulæ in perinæo; fifthly, the relation of the rectum to the prostate gland, urinary bladder, and *cul-de-sac* of the peritoneum, as regards the recto-vesical operation and the lateral operation of lithotomy, and also for puncturing the bladder; sixthly, let him trace the blood-vessels distributed to these organs within the pelvis, from the inferior mesenteric and from the internal iliac arteries; seventhly, let him detach the one-half of the pelvis, together with one of the extremities, as in Plate XXII. (the left side is the preferable to remove), paying great attention at the time to the strength and course of the levator ani muscle while dividing it; he ought now to trace the vasa deferentia round the bladder to the vesiculæ seminales, and onwards to the prostate gland, and examine deliberately the relation of these organs to lithotomy and the different operations specified; lastly, let him remove, in a mass, the urinary bladder, rectum, and penis, dividing the vasa deferentia near the inguinal canals. Having removed these important organs, he should again examine their connexion and relation to each other, and then proceed to investigate minutely their structures, beginning with the urinary bladder; next, the urethra; thirdly, the vasa deferentia, the vesiculæ seminales, and prostate gland; fourthly, the corpora cavernosa, &c. Before beginning the examination of these viscera, the student should insert again and again the catheter or sound in the urethra, and feel along the urethra from the glans penis to the anus, and also introduce the fingers of his left hand into the anus. When exploring these viscera and organs in the female, a similar order should be pursued:—First, the inflections of the peritoneum are to be traced as they relate to the supporting of the uterus and its appendages, to puncturing the urinary bladder above the pubes, and to extirpating the uterus or ovaria; secondly, the nature, relations, and course of the external parts and the anus, examining carefully the relation of the clitoris to the meatus urinarius, the situation of the circulus membranosus, the os uteri, and the perineum; thirdly, the external nerves, blood-vessels, and muscles of the perineum; fourthly, the arteries and veins and nerves distributed to the urinary bladder, uterus, and rectum; fifthly, let him remove in a mass, the bladder, uterus, and rectum, examining, during their removal, the course of the levator ani, and the course of the blood-vessels and ureters. When these organs have been removed, he should investigate their relations and connexions more deliberately, and afterwards manipulate their minute structure. He should particularly attend to the structure of the clitoris, to the extent of the urethra, to the connexion between the urinary bladder and the vagina, to the extent and structure of the perineum, to the structure of the uterus and its appendages, and to the connexion between all of them.

chus, seen also in the last mentioned figure; it is of a pyramidal figure, being longer than it is broad, the base pointing atlantad, and the apex to the outlet of the pelvis; a slight difference, however, exists between the male and the female, the shape of the latter being rounder or more spherical, and a degree larger; the base is termed the fundus, the middle portion its body, the apex or inferior part its cervix, and the commencement of the urethra its mouth; it consists of one partial and three entire tunics, the former being the peritoneum, and the latter a cellular, a muscular, and a mucous. The peritoneum in the male, as illustrated in Plates XXII., LXXXIII., and LXXXIX., marked a, is reflected from the rectum, I, to what is termed the fundus of the bladder, to which adhering, it extends towards the symphysis pubis, A, where it leaves the bladder and invests the recti, pyramidales, and transverse muscles of the abdomen. In Plate LXXXIX., the precise extent of adhesion of the peritoneum, *a*, to the bladder is delineated, particularly as relates to puncturing the bladder from the rectum, or performing the recto-vesical operation of lithotomy. The triangular space, marked D, adheres intimately and closely to the rectum, the cellular substance here being short, and admitting of no motion or separation of the viscera. In the female, the peritoneum, *a*, covers the same extent of the urinary bladder, m, as in the male, as depicted in Plate XCIII.; but the uterus, k, and vagina, D, intervening between the urinary bladder, m, and the rectum, I, the peritoneum, a, is reflected from the bladder, m, on to the pubic aspect of the uterus, k.

The urinary bladder, in the female, adheres intimately to the vagina, D, on which it rests. The anterior ligaments are merely the fascia which invests the anterior or pelvic surface of the levator ani muscle, and which, leaving the muscle, ascends on each side of the body of the bladder, to which it adheres. At the arch of the pubes, a number of foramina are observable, which give passage to the veins of the penis. The foramina are termed the labyrinth. The umbilical arteries, described in page 45, become ligamentous cords soon after birth, and from their adhering to the urinary bladder in their course from the internal iliac artery to the umbilicus, assist in supporting this organ. The urachus is a ligamentous chord which extends from the pubic aspect of the fundus of the urinary bladder, and is apparently a continuation of its muscular fibres, upwards, or sternad, between the recti muscles, and between the latter and the peritoneum, and is lost near the umbilicus, occasionally advancing to this region.

In Plates XC. and XCIII., the cellular tunic, marked P, is partially displayed, being situated immediately beneath the peritoneal, *a*. In Plate XCIII., the portion marked P, is at no time covered by the peritoneum, *a*. The cellular tunic encircles completely the urinary bladdes, and is very loose, and loaded with adipose substance.

The muscular tunic, which is represented in Plates LXXXIX., XC., and XCIV., and in Plate XXII., marked m, also invests the urinary bladder, but is thicker and bolder in some places than in others; more so on its pubic, atlantal, sacral, and coccygeal, than on its lateral aspects. The fibres run in such a manner as to make it a very complicated task to unravel them; they consist of an external and an internal arrangement, the former, or external, which are the thicker and stronger, run chiefly longitudinally, from the pubic to the sacral, and from the sacral to the pubic aspects, mingling with each other on the fundus; the posterior arrangement also extend downwards to the neck, and afterwards ascend to meet and mingle with those in the pubic aspect. From this disposition of the longitudinal fibres, the sides of the bladder are almost entirely divested of them. The internal arrangement of muscular fibres are chiefly oblique, and run opposed to one another in such a manner, as to frequently interlace with each other, and thus to thicken the muscular tunic. Around the neck of the bladder, they run transversely, and very close to each other, in order to form what is termed the sphincter of the bladder.* Some bundles of these fibres also encircle the termination of each ureter, and accompany them onwards to the mucous coat. Beneath or centrad to this internal arrangement of fibres, there are perceptible in several places, particularly on its rectal aspect, thin muscular fibres running longitudinally, or from cervix to fundus. When the bladder is fully distended, we can perceive the mucous coat between the fibres of the muscular, particularly on the sides of the viscus. †

The mucous tunic, marked Q, in Plates XC. and XCIV., is situated within or centrad to the muscular, and is the last of its coats, being in contact with the urine in the living state. In Plates XC. and XCIV. this coat is depicted, the urinary bladder being laid open. It is loose, and is furnished with delicate villi and mucous glands, having a number of folds, apparently caused by the internal arrangement of muscular fibres, the latter of which are most numerous in the region of the neck of the bladder. ‡

Within the bladder there are three apertures, two of them marked w* w*, being the entrance of the ureters, and the third, U, the mouth of the bladder, or beginning of the urethra. § In Plates X. and XIV., where the urinary bladder is represented laid open, and whalebone probes, s, are inserted in the ureters, w, w, the entrances or apertures of these ducts are delineated; and a small papillary eminence, w*, is observable, which, as already remarked, is partly formed by the internal muscular fibres of the bladder accompanying the ureter, and also partly by the union of the mucous tunic of the ureter with that of the urinary bladder. The space between the ureters, w*, w*, and the commencement, U, of the urethra, is named trigonus Lieutaudi; ‖ and by some authors a projection is described at the apex of this triangle, named the uvula vesicæ, or la luette.

From the termination of the ureters, onwards to the commencement of the urethra, two fleshy bundles extend, which are named the corpora carnea Morgagni.

The nerves and blood-vessels to the urinary bladder have been already described.

I shall now describe the urethra of the male, and then the remaining organs of generation peculiar to this sex;

---

* Syn. Musculus sphincter vesicæ urinariæ.

† The muscular tunic should be thoroughly understood by the general practitioner and the operator, to enable them to comprehend its powers with regard to retention of urine, and grasping calculi during the operation of lithotomy, also with regard to sacculating or encysting calculi, and to contraction and thickening from either calculi, diseased prostate gland, stricture of the urethra, or fistulæ in perinæo, likewise in fasciculated bladder.

‡ The structure of the mucous tunic should be investigated to comprehend its diseases, as inflammation, suppuration, ulceration, catarrh, ischuria, hæmaturia, calculus, loose and encysted tubercles, fasciculated bladder, scirrhus, and cancer.

§ Vesical orifice. Orificium vesicale.

‖ Syn. Trigone vésical.

and afterwards those of the female, as the organs of the one differ so materially from those of the other.

In Plate XC., the urethra, marked U, is delineated extending from the urinary bladder to the glans penis, K, an extent of eight or nine inches in the adult. This is a cylindrical mucous tube, a continuation of the mucous tunic, Q, of the bladder, but much thinner in texture, very sensitive, highly vascular, and contractile; presenting a number of longitudinal folds in its collapsed state, and being of a reddish colour. Throughout its whole extent there are observable a number of mucous lacunæ, or small culs-de-sac, represented by small shaded spots, and which have thin apertures or mouths, pointing to the glans penis, K. These are named the glans of Littre, or canaliculi Morgagni, and are said to be only found on the inferior aspect of the circumference of the urethra, which however is incorrect. They are more numerous near the glans than the bladder; and one of them, from its magnitude, is named lacuna magna. This mucous membranous tube, the urethra, is surrounded in its course in the penis by several objects which divide the canal into portions, and on which these objects confer appellations. Immediately as the urethra, U, commences, or even the neck of the bladder itself, it is surrounded by the prostate gland, t, and this is named the prostatic portion of the urethra. The situation of this gland is also seen in Pl. LXXXIX. As the urethra, U, advances, it is encompassed with dense strong spongy cellular tissue, E, together with the triangular ligament of the penis, or deep perineal fascia,* marked M, in Plate LXXXIII., and this is improperly termed the membranous portion.† Beyond the membranous portion, E, Plate XC., onwards to the glans penis, K, the urethra is developed with the corpus spongiosum, G; the bulbous portion of which is marked F, and the glans K, being merely enlargements of this spongy substance. The external aperture, or termination, or commencement of the urethra, marked H, is termed the meatus urinarius externus, or the orificium cutaneum, from the mucous membrane joining or becoming cutaneous.

Many authors have described most minutely the variations of the canal of the urethra in its different portions, but these seem much exaggerated, for in a healthy well-formed penis, with the exception of the prostatic portion and the meatus externus, it is pretty equal in its diameter or calibre throughout. The calibre of this canal, like that of the pharynx and œsophagus, no doubt, differs in relative magnitude in individuals; but with the exception of the portions already mentioned, it will be found to be pretty equal throughout. It is described to be large where it is surrounded with the prostate gland; to be considerably contracted about an inch anterior to this, which is styled the isthmus urethræ, or membranous portion; to be dilated again where the corpus spongiosum begins to encircle it, or at the bulb; to be again contracted anterior to this, and to retain the same calibre onwards to the glans, where it becomes again dilated, and forms what is termed the fossa navicularis, the meatus urinarius itself being a little contracted. Other authors, as Amussat,* contend that there is no enlargement of the canal within the glans, that the diameter insensibly enlarges from the meatus externus to the bulb, where it contracts, and that it then slightly expands at the membranous portion, thus representing a cone, the base of which is towards the urinary bladder. The urethra is very sensitive, also elastic, both in its longitudinal and transverse direction.†

Where the prostate gland, t, in Plates LXXXIX. and XC., surrounds the urethra, U, there is a small projection seen in Plate XC., marked T, which is named veru montanum,‡ and around this a number of smaller foramina, indicated by black dots, are perceivable. The latter foramina are the openings of the ducts of the prostate gland, and the veru montanum is the opening of the vasa deferentia.

The prostate gland, t, in Plates LXXXIX. and XC., is a conglobate gland of the size and shape of a chestnut, or of a triangle, being a little more than an inch in width, one in length, and half an inch in thickness, and weighing about five drachms, situated at the rectal aspect of the neck of the urinary bladder, and commencement of the urethra, both of which it nearly surrounds, but particularly the latter: it also gives lodgement to the vasa deferentia, V. Its base is towards the urinary bladder, and its apex towards the membranous portion, E, of the urethra, with its body resting upon and adhering to the rectum. The prostate is a remarkably firm fleshy gland,§ of a greyish red colour, surrounded with a strong fibrous membrane, having several excretory ducts, from eight to twelve in number, opening into the urethra by small follicular apertures, around the veru montanum, T, in Plate XC., by piercing its mucous membrane.‖ Some authors describe a third lobe belonging to this gland, the two bulbous expansions on the sides of the neck of the bladder forming the other two lateral lobes; but this condition is only observable in the diseased state. This third or middle lobe, when present, is situated between the two lateral lobes, the urinary bladder and the veru montanum, projecting into the urethra or neck of the urinary bladder.¶

The membranous portion of the urethra, marked E, in Plates LXXXIX. and XC., is surrounded with strong, dense, spongy cellular substance, together with the triangular ligament of the penis,** the latter of which is

* This fascia closes the pubic arch, but leaves an aperture for the urethra. It is connected on each side to the rami of the pubes and ischia; anteriorly to the inferior pubic ligament; and posteriorly to the superficial perineal fascia and central tendon, behind which it passes upon each side of the rectum and becomes thin and cellular.

† This is unquestionably the toughest, and sometimes the hardest portion of the urethra, the ligamentous substance being fibrous or even cartilaginous, so that the lithotomist should be prepared, on laying open the urethra at this part, to encounter strong tough hard substance, not delicate membrane, as the name would indicate.

* Remarques sur l'Uretère de l'Homme et de la Femme, dans Archives Gén. de Médecine, tom iv.

† The urethra is subject to acute specific inflammation, and increased vitiated mucous secretion, constituting gonorrhœa; to chronic inflammation with increased mucous secretion, constituting gleet; to spasmodic and permanent stricture; and to fistula. It is also occasionally malformed, the meatus opening at the inferior aspect of the urethra, sometimes in the perineum; in others, the canal is situated superiorly between the corpora cavernosa, and consisting of an open groove or fossa; the whole canal is at other times remarkably small in diameter, scarcely two lines in diameter throughout.

‡ Syn. Caput gallinaginis, vel gallinaceum. Colliculus seminalis.

§ The structure, particularly the consistence of the prostate gland, should be considered by the lithotomist.

‖ The prostate gland is subject to inflammation and suppuration, to scrofulous enlargement, to many of the sarcomatous swellings, and to cancer; is concerned in puncturing the urinary bladder, and in the lateral and recto-vesical operation of lithotomy: calculi are sometimes sacculated in the prostate gland.

¶ This diseased projection into the urethra often becomes an obstacle to the introduction of the cathete

** Syn. Interosseous ligament.

marked M, in Plate LXXXIII., and descends from the symphysis pubis, A*, to encircle and support this part of the canal.

The remainder of the urethra, U, is supported by the corpus spongiosum, marked F, G, K in Plates LXXXIX. and XC., the commencement of which is named the bulb, F, and the termination of the glans penis, K. This spongy body, of considerable length, forming one of the three objects entering into the composition of the penis, being situated in the inferior fossa formed by the corpora cavernosa, is of a cellular structure, encased in condensed cellular substance, and swells out at its extremities; the cells when injected are found to be formed of a net-work of arteries and veins, the latter being the more numerous, and considerably dilated. The bulb, F, is merely an enlargement of this spongy cellular tissue, the calibre of the urinary canal being in no degree increased; therefore the term bulb of the urethra is very liable to deceive us.* The glans, K, is of a round triangular shape, appearing cleft in two at its inferior aspect, having its apex terminating the member, where the meatus urinarius, H, is situated, and its base towards the body of the penis having an abrupt acute circular edge, which is termed the corona glandis. At the root of the glans, where the penis is less in diameter, or contracted, it is denominated the cervix. The glans is invested with a mucous membrane, which is continuous with that of the prepuce, marked L in Plate LXXXIX. This membrane adheres intimately with the cellular web that invests the corpus spongiosum throughout.

The other two bodies which, with the corpus spongiosum urethræ, G, constitute the penis, are the corpora cavernosa, marked X, X, in Plates LXXXIX. and XC. In the former of these plates the corpus cavernosum of the right side is seen extending from the crus ischii, to which it intimately adheres, onwards to the glans, K; the precise origin is, strictly speaking, where the crus of the os ischii unites with that of the os pubis: the termination of the corpus cavernosum is more distinctly seen in Plate XC. These corpora cavernosa advancing from the rami of the bones of the ischia, unite with each other at the bulb of the corpus spongiosum, forming by their junction a fossa situated on their inferior aspect for this latter object, and another on their superior aspect for the vena magna Galeni, and advance, forming the sides and upper part of the penis, onwards to the glans, K; they are enveloped with a strong fibrous membrane, which dips between them, extending from the fossa that lodges the corpus spongiosum, to that on the upper aspect, which lodges the vena magna penis. This septum, named pectiniforme, is imperfect, in order to allow the blood-vessels to communicate with freedom; see page 63. These bodies are cellular, like the corpus spongiosum, as delineated in Plate XC.; but the cells are rather larger, and consist almost entirely of dilated veins. The corpora cavernosa, together with the corpus spongiosum, are surrounded with the common integuments, which adhere by a very loose cellular tissue to these bodies,† there being no adipose tissue. At the neck of the glans they become loose and pendulous, projecting forwards in order to form a covering for the glans, which is named the prepuce, and is marked L in Plate LXXXIX. At the distal extremity of the prepuce a circular aperture is left, in order to allow the urine to be voided, and the glans to be denuded.* The surface towards the glans is mucous,† being formed by a reflected inversion of the cutis vera and epidermis, which extends along the cervix and body of the glans, to the meatus urinarius. The prepuce, L, is still further connected with the glans, K, by means of the frenum,‡ marked N in Plate LXXXIX., which is situated at the inferior aspect of the member, and consists of a perpendicular fold of the mucous membrane, which extends between the glans near the meatus urethræ to the prepuce, thus rendering this membrane tight in this region, but slack and pendulous above or on the upper aspect of the glans. On each side of the frenum, N, and all around the neck of the glans, K, and root of the prepuce, L, are observable a number of small mucous glandular bodies, which are marked M in Plate LXXXIX., and are termed glandulæ Tysonianæ.§

The integuments from the inguinal regions, and the root of the penis, become loose and pendulous, of a brown colour, and at its anal aspect extending to the perineum, in order to form the scrotum, marked Z in Plates XXII. and XXIII., which is larger inferiorly, or at its most depending point, than at its origin, or upper aspect. This is a musculo-cutaneous pouch, containing the testes. The cutaneous part is very thin and delicate, although the epidermis is thick and solid, having a number of transverse circular rugæ, or wrinkles, running downwards from the root of the penis, to the central line which extends from the inferior aspect of the root of the penis along the scrotum to the perineum, and even to the anus, which central or mesial line is a condensation of the integuments, and is named the raphe. A number of long stiff hairs grow from the scrotum, which are interspersed here and there, but which on the pubes are much more thickly set. A number of sebaceous glands are also distributed over the integuments of the scrotum.‖

Centrad to or within the cutaneous pouch, an arrangement of circular muscular fibres are observable, named the dartos,¶ which are denied by some to possess muscularity. A multiplicity of small blood-vessels, particularly veins, are present, which give it a reddish appearance. Between the cutaneous and the muscular tunics a quantity of delicate loose cellular tissue without any adipose matter is found; and within the muscular layer, there is still more loose cellular tissue in immediate contact with the tunica vaginalis testes and the root of the penis.** The cellular

* The precise situation of the bulb is in the perineum, between the root of the scrotum and the anus.

† The loose adhesion of these integuments should be investigated, to enable us to understand how the matter in chancres sometimes burrows between the skin and corpora cavernosa for a considerable extent.

* When the circular aperture of the prepuce is too small to permit the prepuce to be drawn behind the glans, a very common malformation, it is termed phymosis, and when with such a malformation, or from inflammation and thickening, the prepuce is pulled behind the glans and cannot be brought forwards, the affection is styled paraphymosis.

† This mucous structure of prepuce and glans should be considered with regard to spurious gonorrhœa.

‡ Syn. Frenulum glandis.

§ These small glands become the seat of chancres.

‖ These glands become occasionally affected with primary syphilitic ulcer, and with that peculiar ulceration named chimney-sweeper's cancer.

¶ Syn. Tunica carnea.

** The cellular tissue here should be carefully considered with regard to the effusion of urine in fistula of the urethra, and calculi arrested here in their progress from the urinary bladder to the glans penis. The circumstance of the whole cellular tissue of the scrotum being easily inflated with air, or distended with fluids, is a strong argument in favour of the dartos not being muscular, and there being no muscular septum; yet we have only to consider the nature of a muscle, to reconcile this event to our minds.

tissue which descends from the inguinal regions and symphysis pubis, is thicker and stronger than that round the testis. This cellular tissue, together with the muscular fibres of the dartos, extends from opposite the raphe to the root of the penis, so as to divide the scrotum into two smaller pouches, which partition is named the mediastinum or septum scroti.

The testis,* marked b, in Plate XXIII., of an oblong roundish or oval figure, is contained in one of these smaller sacs of the scrotum, z, being separated from the other testis by the mediastinum, and enveloped in its two tunics, the tunica vaginalis and the tunica albuginea, and also partially by the fibres of the cremaster muscle, a, the latter of which, together with the spermatic cord, suspends this organ.

The cremaster muscle,† marked a in Plate XXIII., and formerly described, derives its origin from the internal oblique muscle, emerges at the external aperture of the inguinal canal, and descends on the spermatic cord, which it nearly encircles, downwards to the tunica vaginalis testis, b, on which its fibres, becoming gradually more and more separated, are lost, and thus answer the purpose of a tunic to the testis. Although the fibres of the cremaster nearly encircle the cord, they are much more distinct on its anterior aspect. The action of this muscle is to elevate the testis, particularly during coition.

Beneath or centrad to the fibres of the cremaster muscle, a loose cellular envelope surrounds the spermatic cord, which also binds or connects the vessels and duct composing this cord, and is named the immediate sheath of the spermatic cord. At its root we find this cellular envelope, forming a loose firm tunic for the testis, enclosing the body of the gland, its appendix or epididymis, and the root of the spermatic cord, and having an internal serous surface. It is named the tunica vaginalis testis, ‡ is marked b in Plates XXIII. and LXXXIX., and adheres intimately to the posterior aspect of the testis and epididymis, § where it is reflected over the testis and epididymis, becoming very thin at this part, and hence, like the peritoneum, forms a perfect sac. It thus leaves a space for blood-vessels, ducts, &c. to enter and emerge from the testis. The exterior layer of the tunica vaginalis is strong and fibrous. That portion of this tunic which immediately invests the gland itself, has been named conjunctiva. || The tunica vaginalis communicates or mingles with the cellular envelope of the spermatic cord, and is not a production of the peritoneum, as is clearly and satisfactorily explained by Monro primus, in the fifth volume of the Medical Essays and Observations.

Within the tunica vaginalis, or from its serous surface, a halitus or serous fluid is secreted.

The testis, r, with its epididymis, *r*, and root of the spermatic cord, is situated within the tunica vaginalis, marked b in Plates XXIII. and LXXXIX. The testis, r, of an oblong roundish or oval figure, flattened in some degree, so as to have two sides and two edges, the posterior of the latter of which adheres to the tunica vaginalis, and gives entrance to the blood-vessels; also two extremities, an inferior and an upper, the latter of which gives rest to the epididymis, is invested with its proper tunic, named albuginea,* as represented in the section of the gland in Plate LXXXIX. This immediately invests the glandular substance, is of a silvery colour, thick, and fibrous, being covered outwardly with the tunica vaginalis, and being pierced superiorly by the seminiferous ducts, and posteriorly by the spermatic vessels. Within the tunica albuginea, the gland or the testicle itself is contained, which consists of blood-vessels and seminiferous ducts arranged in lobules or fasciculi, separated from each other by very delicate cellular membranaceous septa,† extending longitudinally and divaricating from each other. These adhere in a concentrated bundle at the posterior edge of the testis, which is named corpus Highmorianum or nucleus‡ of the testicle, and from this they divaricate to the opposite edge, where they also adhere to the tunica albuginea. This subdivision of the testis into compartments, is attempted to be represented in the section of the gland in Plate LXXXIX. The seminiferous ducts,§ separated by these septa, are exceedingly small and convoluted (as represented in Fig. 2 of Plate XC., where the letter v is placed on the concentration of them, there named vas deferens, and the letter y on the membranous septa, the drawing being taken from a preparation wherein the vas deferens has been injected with mercury), running towards the corpus Highmorianum, and there uniting || and concentrating, and advancing to the superior extremity, where they still further reunite, become larger, and pierce the tunica albuginea to constitute the epididymis. From their commencement to their piercing the albuginea, they are estimated to be 5,000 feet in length. In their course between the membranaceous septa, they do not inosculate. When we bisect a testis, we find it remarkably soft and delicate, of a brownish tinge, and on laying hold of any portion with the dissecting forceps, we elevate and elongate several of these delicate convoluted seminiferous ducts.

The epididymis,¶ marked *r* in Plates XXIV. and LXXXIX., is that appendix to the testis situated on its upper and posterior extremity, resembling the capitol of a cucurbit. It is invested, in precisely the same manner as the body of the testis, with the tunica vaginalis and albuginea, the latter of which is much thinner where it is interposed between it and the body of the testis. The lower margin of the epididymis hangs freely over, and around the upper extremity of the testis. The most elevated point of the epididymis is termed the globus major, or head of this appendix.

Where the seminiferous ducts pierce the tunica albuginea, and form the epididymis, they are much larger, as may be understood by examining Fig. 2 of Plate XC.; they are about twenty in number, connected together by delicate cellular substance, and are termed vasa efferentia.** These concentrating form a flexuous tube,

* Syn. Didymus. Geminus.

† Syn. Tunica carnea seu erythroides.

‡ Syn. Tunica vaginalis testis propria.

§ This adhesion of the tunica vaginalis to the testis should be understood with regard to hydrocele, to enable us to comprehend the situation of the testis in this dropsical affection. Hæmatocele sometimes results after the operation of tapping for hydrocele. The tunica vaginalis is subject to ossification.

|| Syn. Tunica vaginalis reflexa. External lamina of the tunica albuginea.

* Syn. Tunica anonyma. Tunica fibrosa.

† Syn. Sepimenta. Septulæ.

‡ Syn. Firmamentum.

§ Syn. Vascula serpentina. Canaliculi seminales. Tubi vel tubuli seminiferi. Tubuli testis. Vasa recta. Vasa seminalia.

|| Syn. Rete testis.

¶ Syn. Testis accessorius. Tête du testicule.

** Syn. Vasa excretoria. Vascular cones.

marked with the digit 1 in Plate XXIV., and with the letter v in Plate LXXXIX., which descends along the posterior edge of the testis, r, to its inferior extremity, where it assumes the name of vas deferens, and again ascends, loosely connected to the testis, to its upper extremity, where it contributes to form a portion of the spermatic cord, along which it ascends posterior to the nervous and vascular plexus, to the inguinal canal, and enters the abdominal cavity.

Where the vasa efferentia of the epididymis have formed one duct, and are emerging from this appendix, the elongated conical portion is named its cauda.* The length of the ducts constituting the epididymis, until it becomes the vas deferens, is calculated to measure about thirty feet.

A vas aberrans is described by some authors to pass off from the vas deferens, and terminate in a cul-de-sac; while another duct is described arising from the one end of the epididymis and running into the other.

The vas deferens, marked v in Plates XXII., LXXXIII., and LXXXIX., after its entrance into the abdominal cavity by the inguinal canal, proceeds dorsad of the peritoneum, a, obliquely across the epigastric and the external iliac arteries, and the external iliac vein, and almost immediately separates at an acute angle from the nervous and vascular plexus, *g**, forming the rest of the spermatic cord, in order to enter the pelvic cavity, where it descends still exterior to the peritoneum, by the side of the body of the urinary bladder, m, to which it adheres, running between the bladder and the ureter, w, down towards the cervix vesicæ, where it communicates with the vesicula seminalis, u, and meets the duct, v, of the opposite side, to pierce the substance of the prostate gland, t, and the urethra, U. The two vasa deferentia unite immediately before their termination at an acute angle, but do not communicate; they form the papilla named the veru montanum, which is marked T, in Fig. 1 of Plate XC. The vas deferens adheres to the peritoneum, until it runs between the ureter and the urinary bladder, but is exterior to it throughout its course, and only very partially covered by this membrane. Near where the vas deferens runs between the ureter and urinary bladder, it becomes a trifle larger, and continues so almost to its termination, when it again contracts, but does not increase in thickness.

The vas deferens is a canal remarkably small in its calibre, its two tunics being exceedingly thick, particularly the exterior, which is very hard and solid, and of a brownish yellow colour. Lewenhoeck perceived longitudinal fibres running along it, and Meckel has seen circular fibres. Its interior or central tunic, of a whitish colour, is much thinner, united to the exterior by loose cellular substance, and is continuous with the mucous membrane of the urethra.†

The vesicula seminalis,‡ marked u in Plates XXII., LXXXIII., and LXXXIX., is a convoluted tube of an oblong oval shape, situated on the sacro-lateral aspect of the neck of the urinary bladder, enveloped with tough cellular substance, and interspersed with a profusion of veins, and apparently a continuation of the vas deferens. The peritoneum does not invest it, and it consists of the same tunics as the vas deferens, with this difference, that the mucous has a number of short loose folds projecting inwards, forming a cellular structure resembling the interior of the gall-bladder. The vesicula seminalis communicates freely with the vas deferens, so as to be considered a continuation of it.*

That portion of the vas deferens which extends from the vesicula to the urethra, is named by some authors ductus ejaculatorius. It has the same structure as the vesicula seminalis. The veru montanum, marked T in Fig. 1 of Plate XC., is a small soft eminence formed by the mucous membrane of the urethra, in which the two vasa deferentia enter the urethra. When we use a blowpipe to this eminence, we inflate a small lacuna or pouch, formed by a loose floating circular membrane, which surrounds these openings of the ducts. The lacuna is named sinus pocularis, or sinus Morgagni.

The description of the nervous and vascular distributions to the male organs of generation have already been partly given.

In page 64, the spermatic artery is traced to its entering the testes at its posterior margin, where the tunica vaginalis begins to be reflected over the gland. The spermatic artery here pierces with several branches the tunica albuginea, both where this membrane envelopes the testis, as also the epididymis. It generally consists of two fasciculi of branches, the one larger and somewhat anterior, which is distributed to the testes itself; the other smaller and rather posterior, distributed to the epididymis. The fasciculus to the testes divides into still more minute ramifications, which run in a serpentine manner, and accompany the multiplied convolutions of the seminiferous ducts.

Within the glandular structure of the testicle, a still greater number of veins originate, which accompany the arteries, and emerge piercing the tunica albuginea; they then ascend along the spermatic cord, anterior to the vas deferens, concentrating and running in a convoluted manner, frequently crossing the arteries upwards to the inguinal canal, by which they enter the abdominal cavity, and accompany the spermatic artery, as described in page 42. These spermatic veins, in their course along the cord, have numerous valves.† Where the spermatic veins emerge from the gland of the testis, they resemble the tendrils of a vine, and are named corpus pampiniforme, or corpus pyramidale, from their pyramidal appearance. The vascular plexus formed by the veins and arteries in their course along the cord, has also been termed vasa pampiniformia.

The formation of the spermatic plexus of nerves has been described in page 43 and delineated in Plate XIII., in which it is seen to accompany the artery, *g*, to the ovarium. In the male it also accompanies the spermatic artery, with which it emerges at the inguinal canal, and descends along the spermatic cord, as represented in Plate XXIV., to the testicle, which it enters by the most minute filaments, together with the artery. In this course the spermatic plexus unites with the spermatic twig of the first lumbar nerve, marked with the digit 1, in Plate

* Syn. Globus minor.

† The vas deferens is subject to malformation, terminating in a cul-de-sac, and also to stricture.

‡ Syn. Paraprostatæ.

* The vesiculæ seminales are sometimes deficient. They sometimes adhere to the neighbouring parts from inflammation, and are occasionally scirrhous. Calculi have been found in their tubes.

† The spermatic veins, as also those of the scrotum, particularly the former, are very subject to become varicose, constituting the disease named varicocele, or circocele. The spermatic cord is subject to dropsy, to scrofulous enlargement, to scirrhus, and to hæmatocele.

XXIII., and also with filaments of the internal pudic nerve.

In the fetus in utero, prior to the sixth month of utero-gestation, the testis is situated partly in the renal and partly in the iliac region, dorsad to the peritoneum, immediately sacrad to the kidney, resting on the psoas magnus muscle, which satisfactorily accounts for the origin of the spermatic plexus of nerves, and the spermatic artery, and also the termination of the spermatic vein. Between the seventh and eighth months of utero-gestation, the testis begins to descend, behind or dorsad to the peritoneum, to the inguinal canal, where it emerges from the abdominal cavity, and descends into the scrotum, but without dragging down the peritoneum in its progress to form the tunica vaginalis, but only cellular substance, of which this tunic is formed, as has been already explained. In thus deviating from the description of modern authors, I am following Nature, and the clear simple account given by Monro primus, in the fifth volume of the Edinburgh Medical Essays and Observations. In the early period of the fetus, while the testis is in the abdomen, a ligamentous-looking cord, of a triangular shape, named gubernaculum,* is reflected from the inguinal canal into the abdominal cavity, and attached by its base to the body of the testis. As the testis advances to the inguinal canal, this ligamentous cord becomes blended with the fibres of the cremaster muscle.†

Two or three small glands, named after Cowper, are sometimes, but not always, found between the bulb of the urethra, O, and the prostate gland, t, as delineated in Plate LXXXIII., and one of which is marked N. When three are present, one is found on the one side of the urethra and two on the other, and the anterior of the two latter is named the antiprostate gland. They are small conglomerate glands, of a round or oblong shape, and of a yellowish colour, enveloped in a strong cellular fascia, with long distinct ducts, which, piercing the corpus spongiosum, enter the mucous membrane of the urethra.

I shall now proceed to the description of the muscles of the perineum in the male, which are delineated in Plate XXII.

The superficial perineal fascia extends across the perineum, from ischium to ischium, and from scrotum to anus, immediately beneath the integuments. It is composed of condensed cellular tissue, and is continuous with the dartos of the scrotum; laterally, it is connected with the rami of the pubes and ischia, and to the tuberosities of the latter; in its middle, with the anus; and posteriorly with the dorsal and superficial fasciæ of the hips and thighs. A central tendon is described, formed by the interlacement of aponeurotic fibres from different muscles, in the centre of the perineum, a little in front of the anus.

The accelerator urinæ * muscle, marked o in Plate XXII., is situated beneath the integuments and a strong fascia, covering the proximal or perineal half of the corpus spongiosum urethræ. It derives a very delicate fleshy origin from the ramus of the os pubis, glides obliquely over the corpus cavernosum, X, and the insertion of the erector penis, p, from both of which objects it also either originates, or is attached for two or three inches downwards opposite the bulb of the urethra. The delicate fibres descend obliquely across the corpus spongiosum, and unite with those of the opposite muscle on the centre of this body, forming a delicate white tendinous line; the muscles adhering in their course to the exterior cellular envelope of the corpus spongiosum, from their union superiorly down to the membranous portion. The inferior fibres unite also with those of the levator ani, s, the transversus perinæi, q, and the sphincter ani, r, muscles. The function of this muscle is to propel the urine or semen in their course along the urethra. †

The transversus perinæi ‡ muscle, marked q in Plate XXII., and situated between the tuberosity of the os ischium and bulb of the urethra, is sometimes single and sometimes double, more generally single. When double, as was the case in this subject, the deeper muscle to be immediately described, is named transversus perinæi alter. This muscle, marked q, is remarkably delicate, and sometimes consists of more than one fasciculus of carneous fibres, which derive their origin from the strong fascia covering the tuberosity of the os ischium, G, and proceed either directly or obliquely across to the bond of union of these perineal fibres, those of this muscle mingling with the fibres of the accelerator urinæ, o, the levator ani, s, and the sphincter ani, r, muscles. The function of the transversi perinæi muscles is to keep the urethra and rectum, or anus, in the mesial plane, and to compress the urethra during the evacuation of the urine and seminal fluid; hence assisting the preceding muscles in their action. § This transversus perinæi is frequently deficient. The transversus perinæi alter ‖ is much more generally found than the preceding. I may state, that I have never found it deficient. It is situated immediately deeper or centrad of the former, and is a stronger fasciculus of fibres,

* Syn. Vagina. Cylindrus. Basis.

† The testes are irregular in their descent from the abdominal cavity; sometimes they begin so early as the fifth month, sometimes the one descends before the other, while at others not until after birth, and occasionally never, one or both remaining in the abdomen for life. In some, each testis has a separate scrotum. In some rare instances three testes have been found, two on the one side and one on the other; an example of which I witnessed lately in a gentleman who consulted me about it, and who mistook it for hernia. The testicle is subject to many diseases, as, for example, inflammation constituting hernia humoralis, suppuration, fistulous or sinuous ulcers, scirrhus, cancer, scrofulous enlargement, cartilaginous enlargement, sarcomatous enlargement, hydrosarcocele, fungous excrescences, one of which is named lipoma, and to ossification. One or both are occasionally entirely wasted away in hernia humoralis, consequent on gonorrhœa occurring in early life.

* Syn. Primus penis musculus. Inferior sive urethram trahens. Musculus urethræ seu accelerator. Dilatator urethræ, sive accelerator seminis et urinæ. Urethram dilatans. Accelerator. Le bulbo-caverneux. Accelerator urinæ seu ejaculator seminis. Bulbo-urethral. Bulbo-syndesmo-caverneux.

† When dissecting the accelerator urinæ muscle, the student must proceed with great caution, as it is very thin, and liable to be removed. He should make an oblique incision in the perineum, parallel with the fibres of the muscle near its middle, and proceed cautiously deeper and deeper, by removing the loose cellular tissue, or superficial perineal fascia, until he arrives at the condensed cellular envelope, which being also carefully removed, the fleshy fibres will be displayed, and are to be exposed by dissecting upwards and downwards, parallel with their arrangement.

‡ Syn. Levator ani parvus, seu externus. Transversus seu transversalis. Transversalis penis. Le dilatateur qui part, de la parte interieure de la tuberosité sciatique. Penis seu urethræ musculus transversus. Le transverse du périné. Ischio-perinéal. Ischio-pubi-prostatique.

§ In order to display the transversus perinæi muscle, a transverse incision of the integuments ought to be made from the region of the bulb of the urethra to the tuberosity of the os ischium, and the cellular tissue, which is very thready or fibrous here, should be carefully removed by incisions made parallel with that through the skin, or the fibres of the muscle.

‖ Syn. Urethræ elevator seu ejaculator. Ischio-prostatique.

of a triangular shape, the base of which is towards the ramus of the os ischii, and the apex towards the bulb of the urethra, deriving its origin from the ramus of the os ischii, and extending directly across, with short fleshy fibres, which are inserted in the accelerator urinæ muscle, o, opposite the bulb of the urethra. In Plate XXII., this muscle should fill up the dark triangular space formed by the transverse perinæi, q, the accelerator urinæ, o, and the erector penis, p, muscles. Its function is the same as that of the preceding muscle.

The erector penis* muscle, marked p in Plate XXII., and situated along the ramus of the os ischium and os pubis, is a strong muscle, deriving its origin from the mesial aspect of the ramus of the os ischii, close to its tuberosity, and ascending along the ramus and corpus cavernosum penis, on the tendinous fascia of the latter of which its fibres are lost. This muscle sometimes originates with fleshy fibres, and at other times with tendinous ones; and sometimes its middle fibres are tendinous, and at other carneous; so that it always presents a variegated appearance of alternate carneous and tendinous fibres. Its fibres nearly encircle the corpus cavernosum, and adhere to those of the accelerator urinæ muscle; and the terminating fibres on the corpus cavernosum run beneath those of the accelerator urinæ muscle. The function of this pair of muscles is to draw the corpora cavernosa backwards and downwards, or dorsad and sacrad, compressing them at the same time; and by the one muscle opposing the other in the lateral directions, they prevent these bodies from moving either dextrad or sinistrad. The action of these muscles is still more evident when the corpora cavernosa are distended, and these muscles may assist in their distension.†

The sphincter ani muscle, marked with the letters r in Plate XXII., and situated around the anus, I, is a delicate arrangement of scattered carneous fibres, which derive their origin from the apex of the os coccygis, C, and run in an elliptical manner on each side of the termination of the rectum, I, or the anus, and are blended at the perineum with the fibres of the accelerator urinæ, o, the transversus perinæi, q, and the levator ani, s, muscles. The fibres of this muscle are sometimes very pale and delicate, and interspersed with adipose substance, while at others they are strong, fleshy, and united to each other; occasionally they form a mass of considerable breadth surrounding the rectum; so much so, as to make some anatomists consider there are two sphincter muscles, an external and an internal.‡ The function of the sphincter ani muscle is to keep the anus closed, until the desire to evacuate the feces overcomes it, when it then also assists in expelling them; and after their expulsion, it again acts as a janitor. This muscle likewise assists indirectly, through the medium of the levator ani, in propelling the urine along the urethra.*

The levator ani† muscle, marked s in Plates XXII. and LXXXIX., is a circular or conical arrangement of strong carneous fibres, situated partly within and partly without the pelvic cavity surrounding the neck of the bladder, and the termination of the rectum. It originates within the pelvis from the tendinous fascia, investing the obturatores interni muscles, the ligamentous fascia described in page 203, and from the central aspects of the symphysis pubis, and the os coccygis. From this circular origin, the fibres descend in a funnel-like shape, surrounding the neck of the bladder, the vesiculæ seminales, the prostate gland, the membranous portion of the urethra, and the termination of the rectum, to be inserted around the anus, the fibres running beneath those of the sphincter ani muscle, r. The function of this muscle is to resist the peristaltic action of the intestines, particularly the rectum, until the desire to expel the feces calls it into action, when it then, in the first place, becomes quiescent; and, in the second, assists the rectum in their expulsion, by compressing it. This muscle also assists indirectly in expelling the urine, by pulling the sphincter ani upwards and forwards, or atlantad and sternad, which stretches the fibres of the acceleratores urinæ, and presses the bulb against the arch of the pubes, and shortens or contracts the membranous portion of the urethra. This muscle likewise aids indirectly the erectores penis, through the medium of the sphincter ani muscle, and assists in the expulsion of the seminal fluid, in the same manner as it does that of the urine, also by compressing the vesiculæ seminales.‡

ORGANS OF GENERATION

IN

THE FEMALE.

The organs of generation in the female are partly situated within the pelvis, and partly at the outlet of that cavity, and hence are divided, for the sake of simplicity and perspicuity, into the external parts or organs, and into the internal organs of generation; thus we observe a difference between those of the male and those of the female,

* Syn. Tertius et quartus penis musculus. Posterior penis musculus. Erector. Collateralis, sive penem erigens. L'ischio-caverneux. Ischio-uréthral.

† This muscle is readily discovered, and with facility displayed. The student should attend to the close connexion its fibres have with those of the accelerator urinæ, neither of whose fibres should be cut in the lateral operation of lithotomy.

‡ Synonyms of sphincter externus ani muscle.—Musculus orbiculatim intestino obductus. Musculus orbicularis recti intestini, sphincter dictus. Sphincter primus et externus, carnosus. Constrictor ani. Sphincter ani. Les sphincter cutanés. Pars per perinæum procurrens, videtur esse levator ani sextus gracilis et acuminatus. Est l'un des muscles dilatateurs de l'urethre. Urethræ dilatator posticus. Penis musculus triangularis. Urethræ virilis, dilatator posticus, sive triangularis. Coccygio-anal. Coccygio-cutané sphincter.

Synonyms of sphincter internus ani muscle.—An est musculus cutaneous et circularis in extrema sedis ora collocatus. Sphincter cutaneus. Sphincter cutaneus ac superficialis. Sphincter internus. Le sphincter intestinal ou orbiculaire.

* The sphincter ani requires great care in its dissection, as its fibres are sometimes very pale and delicate. A slight semicircular incision should be made on each side, close to the verge of the anus, through the integuments, where they become the mucous membrane of the gut, and the fleshy fibres will appear, which are to be displayed by carefully dissecting in their course, and removing only the skin, for the fatty substance which generally lies between the fasciculi is liable to mislead the student. The sphincter ani muscle should be studied with regard to fistula in ano, and the recto-vesical operation of lithotomy.

† Syn. Musculus sedem attollens. Latus ani. Major levator ani. Levator. Levator magnus seu internus. Le releveur de l'anus. Sous-pubio-coccygien. Pubio-coccygien-annulaire.

‡ The levator ani muscle is difficult to dissect, in consequence of its depth from the surface of the body. After the student has displayed the sphincter ani, r, and the transversus perinæi, q, muscles, he should remove with freedom a considerable portion of the adipose substance situated between the tuberosity of the os ischii and the rectum, proceeding cautiously near the latter, when he will perceive an arrangement of fleshy muscular fibres, descending obliquely from within the

the former being situated more without than within the pelvic cavity. These organs are delineated in Plates XCI., XCII., XCIII., and XCIV., and also in Plates IX., XIII., and XIV.

The external organs, or those of copulation (organa copulationis), are the vagina, with its appendages, which are the mons veneris, the labia externa, the clitoris with its prepuce, the nymphæ, the meatus urinarius, and the hymen.

The hymen is considered the membrane which divides the external from the internal organs. Authors, in their description of the external parts, differ greatly in what are the limits of the vagina, some making the whole canal, from the external aperture to the os uteri, the vagina, which, in my opinion, is the simplest and most correct; while others define it to be that portion of the tube from the meatus urinarius to the os uteri; while others, again, only that part from the hymen to the os uteri. There can be no difference of opinion with respect to the function of these parts, although some authors consider that portion which is external to the hymen as only performing the function of copulation, while that internal to this membrane is regarded only as performing that of generation.

The mons veneris is that cushion of cellular and adipose tissues, covered with integuments, thickly studded with long thick hairs, situated on the symphysis and bodies of the bones of the pubes, and delineated in Plates XCI., and XCIII., marked A. It is supported by a strong cellular prolongation of fascia, marked 70 in Plate XCII., which is partly continuous with the fascia superficialis, and partly originating from the external oblique muscles, and may be named the ligamentum suspensiorum, being analogous to that of the penis in the male.

The labia externa, * marked B in Plates XCI., XCII., and XCIII., are those large tumid oblong bodies which descend from the mons veneris, A, on each side of the vagina, D, downwards to the perineum, E, thus meeting both superiorly and inferiorly, forming the entrance of the vagina, † and forming two acute angles, the upper of which is named the superior commissure, ‡ marked C, and the lower the inferior commissure, § marked d*, the latter of which has a delicate transverse fold within the vagina, which unites the two labia externa, and is named frenulum pudendi; || and the space between this frenulum and the inferior commissure, which is exceedingly small, is termed fossa navicularis. Some authors describe this fossa to be formed between the frenulum and the circulus membranosus, L; indeed both the frenulum and this fossa are so indistinct, that they exist more in the mind of the anatomist than in nature. Each external labium, B, consists of the common integuments, which on their dermal or peripheral aspect are cutaneous, while on their mesial aspect they are mucous, the one structure running into the other. Within their cutaneous envelope a considerable quantity of cellular and adipose tissues is found, and on the mucous surface a number of mucous follicles are observable.* The same aponeurotic web, marked 70 in Plate XCII., which descends from the fascia superficialis and external oblique muscle to support the mons veneris, continues to run into the cellular tissue forming these bodies, in order to support them, and may be termed also ligamentum suspensorium labiorum externorum.

The space between the inferior commissure, d*, and the anus, I**, is named the perineum, † and is marked E in Plate XCI. This consists of the integuments, of the union of the sphincter vaginæ, N, and sphincter ani, I, muscles, together with cellular and adipose substances, as delineated in Plates XCI. and XCII. ‡ On the surface of the integuments, a projecting line extends from the vagina to the anus, named the raphe, which is also indicated by the letter E in Plate XCI.

Immediately within or sacrad to the superior commissure, C, the præputium clitoridis, H, is situated, which is a loose triangular elongation of the skin, that descends around and on each side of the glans clitoridis, G, downwards to the nymphæ, F, F, in a similar manner to the prepuce of the penis in the male. The prepuce is thin, soft, and moist on both its surfaces, particularly the internal, which is mucous; and a number of sebaceous glands § are situated in the angular fold formed between it and the glans clitoridis.

The glans clitoridis, || marked G in Plates XCI., XCII., XCIII., and XCIV., is the termination of the union of the two bodies, named crura clitoridis, one of which is delineated in Plates XCIII. and XCIV., marked g. The situation of the clitoris, therefore, is immediately beneath, or sacrad or coccygead, to the superior commissure, C, or the arch of the pubes, and is surrounded with its prepuce, H. It is an oblong round body, formed by these two crura, g, each of which is attached to the point of union of the crura ischii et pubis, from which they ascend towards the arch of the pubes, where they unite at an obtuse angle to form this oblong body, that protrudes peripherad, covered by its præputium, H, and terminates at the glans, G. The crura and body of the clitoris have

---

pelvic cavity towards the anus. He then must dissect from the anus towards the pelvis, and dissect cleanly all the fibres of this muscle, which in fat subjects are generally interspersed with adipose substance. This is a muscle of great importance to the lithotomist when performing the lateral operation, for until its fibres are freely divided, he cannot arrive at the membranous and prostatic portions of the urethra. Still less can he extract a calculus of common magnitude, without tearing and lacerating its fibres. It is from bruising, and lacerating, and protracting this operation, that so many die of it. Free incisions do no harm: while small incisions lead to contusion, and laceration, and inflammation, with fatal results. The great quantity of cellular and adipose tissues, in this triangular space, should be kept in view by the lithotomist, and by the practitioner, with regard to abscesses in this quarter, to fistula in ano, and in perinæo.

* Syn. Labia pudendi magna Alæ pudendi majores.

† Syn. Vestibule. Vulva. Fossa magna. The vestibulum is defined by some authors to be formed by the nymphæ and perineum.

‡ Syn. Commissura anterior.

§ Syn. Commissura posterior.

|| Syn. Furcula. Fourchette.

* The mucous surface of the labia externa is the seat of syphilitic ulcers and warty excrescences. The labia, when inflamed, sometimes shut up the vagina, and prevent the evacuation of the urine; and when attacked with phagedenic ulceration or hospital gangrene, they sphacelate with prodigious rapidity. They occasionally acquire a considerable magnitude from protracted leucorrhœa, or chronic inflammatory determination to them, rendering them affected with solid œdema, and requiring extirpation. See Lizars' Practical Surgery, Part II., p. 310. In inguinal hernia, the viscera are liable to descend into the external labium. The labia externa are sometimes deficient, and are sometimes united together, forming an imperforated vagina; while occasionally the one is larger than the other.

† Syn. Perinæum anterius.

‡ The perineum is an object of much interest to the accoucheur from its being very liable to be lacerated during parturition, unless supported during the efforts of nature at this period. See Lizars' Practical Surgery, Part II., p. 309.

§ Syn. Glandulæ odoriferæ.

|| Synonyms of the clitoris.—Membrum muliebre. Coles fœminarum. Nympha. Mentula muliebris.

a production of the fascia, common to the mons veneris and labia externa, expanded over them, which is named ligamentum suspensorium clitoridis.

The crura clitoridis,* g, consists of a spongy structure, enveloped with a strong fibrous sheath, as delineated in Plates XCIII. and XCIV., particularly in Fig. 2 of the latter. From the point where the two crura unite to form the body of the clitoris onwards to the glans, they, or it, is encircled with the same fibrous envelope, which also sends a cribriform partition perpendicularly across to divide the clitoris, precisely in the same manner as that of the corpora cavernosa penis. Where the body of the clitoris becomes as it were the glans, the latter can be separated from the former, being only held together by cellular substance, nerves, and blood-vessels; and the end of the body of the clitoris has a concave surface, which receives the glans. The glans consists of the same spongy texture as the crura, which in all of them is found to be formed by large veins, frequently anastomosing. The glans has no septum, and is invested with a thin mucous membrane, covered with a thick soft epidermis.†

The nymphæ, or labia interna,‡ marked F in Plates XCI., XCIII., and XCIV., descend on each side of the vagina, D, from the clitoris, G, to the inferior commissure, where they are blended together. They are thin loose prolongations of the mucous membrane of the vagina, of an oblong shape, and reddish colour, somewhat similar to the wattles of the domestic cock. They consist of a very delicate spongy texture,§ which is continuous with that of the glans clitoridis, but much finer, and enveloped with the mucous membrane of the vagina, the central surface being continuous with this, and the peripheral with that investing the external labium.‖ A number of subaceous or mucous lacunæ are found on the nymphæ. In some, the nymphæ do not descend beyond the middle of the side of the vagina.

Centrad, or deeper in the vagina than the nymphæ, F, F, and about an inch from the glans clitoridis, G, under the arch of the pubes, the meatus urinarius, K, is situated.¶ The loose projection at its inferior or perineal aspect consists of a vascular spongy texture, and is named by some corpus glandulosum;** and around the circumference of this orifice a number of mucous follicles are situated.†† The meatus urinarius, K, is the outer aperture of the urethra, marked T in Plate XCIII. and U in Plate XCIV., which is observed to be much shorter and wider in the female than in the male, being only about two inches in length, and a little more than a quarter of an inch in diameter. It extends from the meatus urinarius, K, under the arch of the pubes, A*, to the urinary bladder, m; and consists, like that of the male, of a mucous tunic, marked U in Plate XCIV., with a spongy muscular tissue around.

Still deeper in the vagina than the meatus urinarius, K, the circulus membranosus, or hymen,* marked L in Plate XCI., is situated, which is a circular or oval duplicature of the mucous membrane of the vagina, with an aperture in its centre; it is formed by an extension of that continuous with the mucous membrane of the nymphæ, and that continuous with the mucous membrane deeper than the hymen, united by cellular substance. This membranous circle is seldom complete, and its aperture is rarely in the middle, and always irregular. The broadest part of this membrane is generally towards the perineum. In the adult, particularly in the married female, instead of this membranous circle, there are merely short prolongations on each side of the vagina, as represented in Plates XCIII. and XCIV., also marked L, and then named carunculæ myrtiformes. The circulus membranosus may be said to separate the external from the internal organs of generation,† and is considered by some authors to form the orificium vaginæ, the space between the external labia and the circulus membranosus being termed the vestibulum.‡ Between the meatus urinarius and the circulus membranosus, a number of mucous lacunæ are found extending around this portion of the canal.

The internal organs of generation or formation (organa generationis seu formantia) are considered to be the remainder of the vagina, with the uterus and its appendages; but this is more arbitrary than if the whole of the vagina is included under the external organs of copulation, and the uterus, with its appendages, made the organs of generation.

The continuation of the vagina, D, is a circular or oval mucous tube, about four inches in length and one in diameter, situated between the urinary bladder, m, and the rectum, I, and running in the direction of the axis of the pelvis, beginning at the circulus membranosus, L, and terminating in a cul-de-sac,§ around the os uteri, R, as delineated in Plates XCI., XCIII., and XCIV. Its commencement at the circular membranosus, which is the narrower of the two extremities, is named the orifice of the vagina.‖ The canal is more capacious at its upper or vesical region than at its lower or rectal region, and is longer in the latter or rectal than in the vesical direction. The vagina consists of two structures, an external marked V, in Plates XCIII. and XCIV., which appears partly

* Syn. Corpora cavernosa clitoridis. Corpora spongiosa clitoridis.

† The situation of the clitoris should be well understood by the practitioner, as it is the guide of the meatus urinarius or opening of the urethra, when drawing off the urine with the catheter in the living body. It is liable to become the subject of operation, from being morbidly enlarged or scirrhous; is subject to malformation, being then also so enlarged as occasionally to deceive the parents with regard to the sex of the child. It is this which constitutes hermaphrodism; and in this case the prepuce and glans are well formed, and there is a fissure at the extremity of the glans. The malformation is easily ascertained by attentive examination. See Lizars' Practical Surgery, Part II., page 314.

‡ Syn. Labia pudendi minores. Alæ minores.

§ Syn. Corpus cavernosum nymphæ.

‖ The nymphæ are found of very great magnitude in the race of the Boschismans, protruding beyond the external labia: and are also occasionally morbidly increased in size in Europeans. Sometimes they are deficient, and at others are found adhering, either from malformation or inflammation.

¶ The student should make himself master of the situation and structure of the meatus, together with the course of the urethra, in order to be able to remove the urine with the catheter in the living body, when requisite.

** Syn. Glandulæ prostatæ mulierum.

†† Syn. Prostata Bartholiniana.

* Syn. Valvula vaginæ.

† The circulus membranosus is not unfrequently imperforated, in which case it is generally thicker and firmer, so that when the catamenia are secreted, they accumulate behind it, and excite violent pain, so as to require this membrane to be crucially divided. It must be prevented reuniting by sponge tent. See Lizars' Practical Surgery, Part II., page 313.

‡ The whole extent of mucous surface, from the external labia to the circulus membranosus, is the seat of primary syphilitic ulcers and warty excrescences.

§ Syn. Fundus vaginæ.

‖ Syn. Aditus vaginæ. Os externum uteri. The orifice of the vagina is described by some to be that portion of the canal between the meatus urinarius and the circulus membranosus.

muscular and partly vascular; and an internal, marked D, in the same plates, which is mucous, being only covered for a small extent at its lower or sacral aspect, where it separates the uterus from the rectum, by the peritoneum, as seen in Fig. 1 of Plate XCIV., the peritoneal membrane being marked *a*.* The external and internal layers or tunics are connected together with tolerable closeness; the external, V, is thick, solid, of a reddish colour, and appears continuous with the fibrous texture, *b*, of the uterus. This external layer, V, adheres intimately to the urinary bladder, m, on its upper or pubic aspect, and also to the rectum, I, on its sacral or coccygeal aspect, there being very little cellular tissue forming this bond of adhesion; and hence we may discard a cellular tunic as belonging to the vagina, described by some authors. The internal or mucous tunic, D, of a reddish colour in the living, but bluish white in the dead state, has a number of semicircular rugæ,† as delineated in Plates XCIII. and XCIV., which run transversely across the direction of the canal, meeting with one another on each side at a longitudinal white line,‡ as represented in Fig. 1 of Plate XCIV. These transverse rugæ, most conspicuous in the virgin, and some of which are oblique, appear continuous with those in the cervix uteri, marked *e* in Fig. 1 of Plate XCIV.; and are largest and most numerous near the circulus membranosus, as delineated in Plate XCIII. The mucous membrane of the vagina is continuous with that of the uterus. Throughout this mucous membrane, but particularly on its upper aspect, a number of mucous glands are situated, and between this mucous membrane, D, and the external tissue, V, a multiplicity of blood-vessels, especially veins, are found, some of which form a vascular plexus,§ near the circulus membranosus, as represented in Fig. 2 of Plate XCIV., marked *f*. The nervous and vascular distributions to these external organs have been formerly described.‖

The muscles which operate on these external organs of generation in the female, are the sphincteres vaginæ, the erectores clitoridis, the transversi perinæi, the levator ani, and sphincter ani; all of which are developed in Plate XCII.

The sphincter vaginæ,¶ marked N in Plate XCII., and situated exterior to the mucous membrane investing the external labium and contiguous portion of the vagina, is a broad fleshy muscle, which derives a scattered origin from the union of fibres belonging to the sphincter ani, r, the transversus perinæi, q, and the levator ani, s, muscles, and ascends on the side of the mucous membrane of the vagina, and is lost near the superior commissure, C, on the ligament which supports the crura clitoridis, the fibres running under the ligamentum suspensorium labii externi, 70, and over those of the erector clitoridis, P. The function of this muscle is indicated by its name.

The erector clitoridis,* marked P in Plate XCII., situated on the rami of the ossa ischii et pubis, derives its origin from the ramus of the os ischii, near its tuberosity, ascends on its ramus, and that of the os pubis, and the crus clitoridis, on which it is lost. Its function is to compress the crus of the clitoris, to draw it dorsad and sacrad, and thus facilitate the flow of blood into it; and by the one muscle opposing the other, they prevent the clitoris from moving to either side.

In Plate XCII., we observe that the other muscles, the transversus perinæi, q, and the transversus perinæi alter, q*, the sphincter ani, r, and the levator ani, s,† have the same origin, course, and insertion as in the male, which are described in page 208.

The levator ani descends on each side of the vagina, so as to embrace it, and is partially inserted in its inferior extremity. The transversus perinæi alter, q*, is inserted in the labium externum and sphincter vaginæ. These muscles of the female, like those of the male, require considerable care in their dissection, in consequence of their delicate structure. As their delineation is very distinct in Plate XCII., where the skin, marked M, is also left, in order to show the manner in which they should be dissected, it seems unnecessary to describe them further.

The proper organs of generation are the uterus and its appendages, the latter of which are the two round ligaments of the uterus, the two broad ligaments, the Fallopian tubes, the corpora fimbriata, the ovaria, and the ligaments of the ovaria.

The uterus,‡ marked k in Plates IX., XIII., XIV. and in Plates XCIII. and XCIV., is situated in the pelvic cavity, between the urinary bladder, m, and the rectum, I, and kept in this situation by the two broad, *k*, *k*, and the two round, *l*, *l*, ligaments. It is of a pyramidal figure, about two inches in length in the virgin, resembling a small flask or caoutchouk bottle, a little flattened on its pubic and sacral aspects, having a fundus, k, a body, *p*, a cervix, *e*,§ and an os, R, as represented in Fig. 1 of Plate XCIV. It consists of a peritoneal investment, *a*, a fibrous structure, *b*, and a mucous lining, *p*, as delineated in the same figure.

The peritoneal tunic or investment of the uterus forms also the broad and round ligaments, and all these run so much into one another, that I shall describe them at once. The peritoneum, *a*, in Plate XCIII., is observed expanded over the fundus of the bladder, m, and to glide between its posterior or sacral aspect, and the anterior or pubic aspect of the uterus, *k*, where it ascends to the fundus of the

---

* Hernia sometimes takes place here between the uterus and the rectum, and the water in ascites makes a pouch occasionally, so as to enable it to be drawn off here. See Lizars' Practical Surgery, Part II.

† Syn. Columna rugarum anterior et posterior.

‡ Syn. Raphe.

§ Syn. Plexus retiformis. Corpus cavernosum vaginæ.

‖ The vagina is sometimes so inflamed as to terminate in adhesion, and produce more or less contraction or stricture. It is occasionally involved in scirrhus uteri, and also in cancerous ulceration extending from that of the uterus, in which case it sometimes forms a communication either with the urinary bladder or the rectum. The vagina is also liable to be inverted or everted in prolapsus uteri. In a few instances, polypi have been found growing from the vagina, in the contiguity of the os uteri. The canal is occasionally malformed, being either very narrow in its transverse diameter, or very short in its length: sometimes it is imperforated, while at others it is deficient, there being nothing but loose cellular tissue in its place, and on some rare occasions a double vagina has been found, there being a longitudinal septum extending from without to the os uteri, and even two hymens present.

¶ Syn. Orbicularis musculus sinum muliebrem undequaque obvolvens. Clitoridis inferior latus et planus. Portio carnosa in externa parte vaginæ. Alius musculorum paris, quod clitoridi a plerisque adscribitur. Vaginæ musculi constrictorii. Eadem sphincteris vaginæ. Constrictor cunni. The second muscle belonging to the clitoris. L'autre muscle du clitoris. Périnéo-clitorien. Anulo-syndesmo-clitorien.

* Syn. Clitoridis musculus. Clitoridis musculus tensioni dicatus Superior rotundus. Musculus qui ab osse coxendicis oritur. The first muscle belonging to the clitoris. Ischio-caverneux. Ischio-sous-clitorien. Ischio-clitoridien.

† The levator ani in the female should be carefully examined by the accoucheur, as it is concerned in parturition.

‡ Syn. Matrix. Womb.

§ Syn. Collum uteri.

uterus, spreading out into loose folds on each side, marked *k*. After the peritoneum has arrived at the fundus, k, of the uterus, and the round-looking cord, k*, *k**, which are the Fallopian tubes, it begins to descend in a similar manner on the sacral aspect of the uterus, s, and these broad expansions, *k*, *k*, as delineated in Fig. 1 of Plate XCIV.,* downwards between the cervix uteri and the rectum, I*, on the latter of which it ascends, and spreads around the sides of the pelvis. In Plate XCIV., the peritoneum, *a*, is observed to extend between the rectum and uterus, even a little beyond or peripherad to the os uteri, so as to invest a very small portion of this sacral aspect of the vagina, D. The fold of the peritoneum which extends upwards on each side from this point, and is lost on the sides of the pelvic cavity, is named, as already mentioned in page 197, plica semilunaris.† On the pubic or anterior aspect of the uterus, the peritoneum does not extend so far between the bladder and uterus, beyond or peripherad of the os uteri, but is reflected from the one viscus to the other, within half an inch of the os uteri in the adult.‡ This duplicature of the peritoneum is named by some authors ligamentum uteri inferius anterius.

The broad ligaments of the uterus,§ marked *k*, *k*, in Plates XCIII. and XCIV., I have already described to be formed by a union of the anterior and posterior peritoneal investments of the uterus, extended transversely towards the sides of the pelvic cavity, so as to divide the pelvis into two halves, as illustrated in Plate XCIII. This division, however, is only apparent when these ligaments are thrown on the stretch by elevating the fundus uteri. These two laminæ of the peritoneum are intimately connected by cellular substance, and admit of no aperture, with the exception of the ovarian one, *k***, of the Fallopian tube. Besides the cellular tissue connecting these laminæ of the peritoneum which form the broad ligament, it is stated by some authors that there are muscular fibres which originate from the sides of the uterus, and extend outwards, becoming gradually lost as they extend between these layers of the peritoneum. There are several arteries, veins, and nerves running between these laminæ, as formerly described. Each of those broad ligaments, *k*, in its extension from the side and fundus of the uterus, embraces the Fallopian tube, marked *k**, the corpus fimbriatum, s, a production apparently of the peritoneum, the ovarium, N, with its ligamentous cord, *n*, and the round ligament, *l*.

* In Fig. 1 of Plate XCIV., the uterus, k, with its broad ligaments, are turned round, so as to give a full view of their sacral or posterior aspect.

† Syn. Ligamentum uteri inferius posterius.

‡ The uterus is sometimes absent, and at other times only one of its sides is present; occasionally, it is exceedingly small in size, with very thin parietes: a few instances have occurred where it has been divided into two lateral halves, and even where it has been divided by a longitudinal partition, so as to constitute two uteri, which partition has also in one or two cases extended to the external parts. It is subject to prolapsus, to retroversion, to inversion, to hernia, to laceration in the pregnant state, to inflammation, suppuration, ulceration, and obliteration; to polypi, which grow from its mucous membrane, investing either the fundus, body, or neck: to scirrhus and cancer, to sarcomatous tumours growing from its surface, to hypertrophy, to conversion into a fibro-cartilaginous mass, to ossification, or deposition of calcareous matter in its muscular texture, to a deposition of fat and hairs in its texture, to a deposition of teeth on its internal surface, and in its cavity. Scirrhus and cancer more frequently commence at the os and cervix than elsewhere; and the os is also subject to warty excrescences.

§ Syn. Ligamenta laterali uteri. Ala vespertilionum.

The round ligaments,* marked *l*, also two in number, extend from the fundus, k, of the uterus to the inguinal canal, as delineated in Plates LXXXIX. and XCIII. Each round ligament is involved in the peritoneal envelope, forming the broad ligament, and consists of the peritoneum, investing a tissue of blood-vessels and cellular substance, extending from the fundus uteri to the inguinal region. This round ligament proceeds from the fundus uteri exterior or sacrad to the peritoneum, ascends to the side of the pelvis, crosses obliquely the external iliac vein and artery, and like the spermatic cord in the male, emerges from the abdomen on the iliac and atlantal aspect of the epigastric artery at the inguinal canal, and exterior in the inguinal region, divides into several fasciculi, which are lost in the adipose substance of the mons veneris and external labium.† See Plates LXXXIX. and XCIII. Besides the blood-vessels and cellular tissue which enter into a formation of the round ligament, it is supposed there are longitudinal muscular fibres, which originate from the muscular substance of the uterus. The peritoneum does not surround entirely the round ligament, but merely invests it in the same manner as it does any of the small intestines, as, for example, the jejunum. When the uterus, together with its ligaments, is insulated, the round ligament is very partially covered with the peritoneum, and is with difficulty distinguished. Having described these productions of the peritoneum, I shall return to the description of the uterus.

I have mentioned that all the uterus, with the exception of its mouth, is invested with the peritoneum. The os uteri, R, projects into the fundus or upper opening of the vagina, and is surrounded by the latter; it consists of two swollen projecting labia, about an inch in extent in the virgin, arranged transversely with a horizontal aperture, and from its resemblance to the mouth of the ray or skate, is named also os tincæ.‡ The cervix is nearly cylindrical, and narrower than the os, being about six-eighths of an inch in diameter. The corpus or body swells out from the cervix, being about an inch and a half in breadth, and flattened on the pubic and sacral aspects, more so on the former than the latter, and having round edges or sides, and altogether a triangular appearance. The fundus is slightly arched.

Beneath or centrad to the peritoneal investment, there is the thick fleshy stratum, marked *b* in Fig. 1 of Plate XCIV., nearly half an inch thick at the body of the uterus. This consists of several longitudinal muscular strata of a brownish red colour, between which are transverse or circular whitish bands, all intimately interlaced, and between which a number of extremely flexuous blood-vessels run, frequently inosculating together. The longitudinal fibres run from the fundus on the pubic and sacral aspects towards the cervix, where they disappear, some of them taking an oblique, and some even a transverse direction. The transverse fibres run in a circular direction, intimately interlacing with the longitudinal and oblique. The muscular substance is thickest at the fundus, there being very little at the cervix.

The internal aspect or cavity of the uterus, which corresponds somewhat in shape with the external, is lined

* Syn. Ligamentum uteri teres.

† The practitioner should carefully attend to this vascular connexion between the groin and the uterus, in reference to the application of leeches in suppression of the catamenia, and in hysteritis.

‡ Syn. Os uterinum. Orificium uteri externum.

with a reddish flocculent mucous membrane, marked *p* in Fig. 1 of Plate XCIV., which communicates with the vagina through the medium of the os uteri, and with the peritoneum by the Fallopian tubes. This mucous tunic adheres intimately to the muscular or fibrous substance, and can be only separated by maceration; hence some authors have denied its existence, and considered there are only exhalent vessels situated here. At the cervix there are two longitudinal projecting lines on the pubic and sacral aspects, the former of which is represented in Fig. 1 of Plate XCIV., and from these, oblique lines with corresponding furrows extend upwards on each side towards the sides of the cervix. In this cervical region there are also a number of mucous glands or follicles,* situated chiefly on the inferior part.

The internal cavity of the uterus is extremely small, the pubic and sacral sides nearly touching each other; it communicates with the vagina by the mouth, which is rather larger than the cervix, and the latter of which becomes even narrower towards the body, where it is named ostium uteri internum. From this contraction the cavity swells out laterad but not pubic and sacrad, to the fundus, where it extends to the commencement of the Fallopian tubes, the same mucous structure running along them. At the fundus, and especially where the Fallopian tubes begin, the parietes of the uterus are thinnest. The cavity of the uterus, where it begins to form these tubes, has a funnel-like shape.

The Fallopian tubes,† marked *k** in Plates XCIII. and XCIV., form the highest or most atlantal free margins of the broad ligaments, k, in which they are enveloped, and extend from the fundus uteri laterad towards the ovaria, N, N; they are flexuous tubes, between three and five inches long, small in calibre, but having thick fleshy parietes: and I have already mentioned, that they are encircled with the peritoneum, which forms at their ovarian extremities, in conjunction with their internal or mucous tunic, the elegant fringed web marked s, named corpus fimbriatum,‡ which surrounds the ovarian aperture, *k***. Beneath or centrad to the peritoneal investment there is a layer of longitudinal muscular fibres, within which are also circular ones; and interior to this muscular layer is the mucous coat, arranged in longitudinal folds, extending from the corner of the fundus uteri to the corpus fimbriatum, the latter of which, as above mentioned, it contributes to form. The calibre of the Fallopian tube is exceedingly small at the uterus, being about half a line, and scarcely capable of admitting a hog's bristle; but from this it gradually enlarges towards its ovarian aperture,* so as to admit the common brass blowpipe of the dissecting case, which is about four lines in diameter. The aperture at the fundus uteri is termed ostium uterinum.†

The ovarium,‡ marked N in Plate XIII., and in Plates XCIII. and XCIV., is an oval-shaped glandular-looking body, situated on the posterior or sacral aspect of the broad ligament, *k*, of the uterus, being also held in this situation by a ligament proper to itself, marked *n* in Plates XCIII. and XCIV., and named ligamentum ovarii § This ligament, *n*, is a production or duplicature of the peritoneum, together with cellular substance, which extends from the fundus uteri to the one extremity of the ovarium, N. The ovarium is invested with a peritoneal envelope, continuous with the posterior or sacral lamina of the broad ligament of the uterus; it is about an inch and a half long, and about half an inch in diameter, being nearly of the same breadth and thickness; and its inferior or coccygeal margin is described as being more straight than the superior or atlantal, and having a slight concavity.‖

Beneath its peritoneal investment there is a white fibrous membrane, named tunica albuginea, both of which are intimately adherent; and this white tunic is pierced at the lower border of the ovarium with the blood-vessels which go to and from this body. On making a section of the ovarium, N*, as delineated in Fig. 1 of Plate XCIV. we perceive a number of vesicles, which vary from eight to twenty in number, imbedded in a brownish red substance, tolerably solid and firm, and plentifully supplied with blood-vessels.

The vesicles of the ovarium¶ vary in size, the largest being about three lines in diameter, and they are found more abundant on the surface than in the centre of the ovarium. They consist of a clear limpid fluid, encased in a thin serous membrane, which adheres to the substance of the ovarium.**

The nerves and blood-vessels to the female organs of generation have been formerly described.

* Syn. Ovula Nabothiana. Ovarium secundarium.

† Syn. Meatus seminarii.

‡ Syn. Morsus diaboli. Pavillon de la trompe. Morceau frangé.

* Syn. Ostium abdominale.

† The uterine aperture of the Fallopian tube is sometimes obliterated; calcareous concretions are occasionally found in the Fallopian tube; and a fetus is sometimes developed in it, constituting a tubal conception.

‡ Syn. Testis muliebre.

§ Syn. Ligamentum rotundum ovarii.

‖ Syn. Hilus. Scissure vasculaire.

¶ Syn. Ovula Graafiana.

** The ovaria are subject both to misplacement and to disease; they are occasionally found at birth exterior to the inguinal canals, forming herniæ, in which case they are sometimes mistaken for testes; and if the clitoris be very large, with the urethra immediately at its root, and the vagina small or the sides adherent, the combination is liable to be considered hermaphrodism. The ovaria are sometimes very small, and sometimes one or both are deficient. The vesiculæ are occasionally absent. The ovaria are subject to inflammation, suppuration, and ulceration, to hypertrophy, dropsy, an albuminous collection, sarcoma in all its forms, a deposition of teeth and hairs, and to ovarian conception.

GRAVID UTERUS.

The description of the uterus in the gravid or impregnated state naturally follows that of the organ in the virgin state, and I shall therefore proceed to describe the gravid uterus at the ninth month, or full period of utero-gestation, and afterwards the fetus at the same age.

At the ninth month of utero-gestation, as represented by Plates XCV. and XCVI., the uterus, K, has risen out of the pelvic cavity, and rests on the pubes, A; has elevated the floating viscera, particularly the jejunum and ileum, L, near the diaphragm, and even raised the liver and spleen a little atlantad, so that all of them press on this muscular partition, and reduce the cavity of the thorax. The jejunum and ileum are also pressed laterad of the uterus. The anterior parietes of the uterus, K, are in immediate contact with the peritoneum, *a*, investing the anterior and lateral parietes of the abdominal cavity.*

The uterus has by this time acquired a great magnitude, is entirely changed in its shape and appearance, being of an oval figure; its cervix, E, is now obliterated by the distension; and its fleshy parietes are considerably increased in thickness, as represented in Plate XCVI., the section being marked *b*. The Fallopian tubes, *k**, have also become shorter, thicker, and more fleshy; the peritoneum has increased with the uterus, and, in only very few instances, has been found elongated and somewhat thinner than elsewhere; the spermatic and uterine arteries, with their corresponding veins, are enormously enlarged; the hypogastric plexus, and the abdominal muscular twigs of the lumbar nerves, are augmented; and the lymphatics are likewise increased greatly in magnitude.

On making a section of the parietes of the uterus, as exemplified in Plate XCVI., we perceive them (marked with the letters *b*) remarkably thick and fleshy, and interspersed with numerous large foramina, which are the bisected blood-vessels, now enormously enlarged, we observe them invested with three membranes, marked *f*, *d*, *c*; and interior to the last, the fetus and placenta, *p*, with their medium of connexion, the umbilical cord, marked *n*, *n*, g. The membranes† are the decidua, *f*, the chorion, *d*, and the amnion, *c*.

The decidua,‡ marked *f* in Plate XCVI., and in Figs. 1 and 9 of Plate XCVII., invests the inner or concave surface of the uterus, *b*, and the outer or convex surface of the chorion, *d*, forming a complete sac, somewhat similar to the peritoneum, excepting at the os uteri, where the uterine lamina does not extend across this aperture, but here ceases, the os uteri being shut up by a glutinous substance. These two laminæ unite round the margin of the placenta, *p*. That portion investing the uterus, is named the decidua externa or vera; while that which invests the chorion, is called the decidua interna or reflexa.* The surfaces of these laminæ, looking to each other, are serous, whereas the surfaces which adhere to the uterus and to the chorion, may be said to be cellular. That portion adhering to the uterus has a number of flocculent processes, which seem to be the blood-vessels that supply it, being derived from the uterine vessels, and entering this membrane in an oblique direction, running in beautiful serpentine convolutions; while that which adheres to the chorion requires some degree of putrefaction in order to separate it. The decidua is of a yellowish colour resembling coagulable lymph, is soft and spongy, having in some places a cribriform appearance, particularly where it invests the chorion opposite the os uteri.

The chorion,† marked *d* in Plate XCVI., and in Figs. 2, 3, 4, 7, 8, and 9 of Plate XCVII., is situated immediately internal or central to the decidua, *f*, which it invests, and exterior or peripheral to the amnion, *c*, to which it also adheres. It is a thin pellucid membrane, having delicate villous prolongations on its two surfaces, especially on the outer, as represented in Fig. 8 of Plate XCVII., which are blood-vessels derived from the umbilical vessels. Where it invests the placenta, it is thicker, affording a coating to its blood-vessels, and extends along the umbilical cord, onwards to the fetus, where it is lost in the integuments. Some authors describe the chorion to consist of two laminæ, between which run small blood-vessels.

The amnion,‡ marked *c* in Plate XCVI., and in Figs. 1, 2, 4, and 9 of Plate XCVII., is situated immediately within or centrad of the chorion, *d*, to which it adheres by delicate gelatinous substance, analogous to cellular tissue, and at the placenta it extends along the umbilical cord onwards to the fetus, where it blends with the integuments, particularly the epidermis. It is a thin transparent membrane, but tougher in its texture than either the chorion or decidua, and has an internal serous surface towards the fetus.

Within the amnion is contained a clear limpid fluid, named the liquor amnii, which is generally about eight ounces in quantity at parturition, and is then more or less

* The close connexion of the anterior parietes of the abdomen with the uterus should be kept in view in the cæsarian operation. At the sixth month the small intestines have been found between the interior parietes and the uterus, but never at the ninth month.

† Syn. Secundæ Secundines. Involucra. Membranæ. Les enveloppes. Délivre.

‡ Syn. Membrana caduca. Tunica exterior ovi. Membrana Hunteri. Membrana cribrosa. Epichorion.

* Syn. Chorion fungosum.

† Syn. Chorion pellucidum. Membrana vasculosa. Membrana extima.

‡ Syn. Tunica ovi intima. Amnios.

muddy and flocculent. Its situation may be comprehended by examining Figs. 7 and 9 of Plate XCVII., where, in the latter, the decidua, *f*, and chorion, *d*, are laid open, and the amnion, *c*, containing its liquid, left entire; while in Fig. 7 both amnion and chorion, *d*, are left sound.*

The placenta, marked with the letters *p* in Pl. XCVI., and in Figs. 1 and 9 of Plate XCVII., is situated generally at the superior and posterior part of the fundus of the uterus, a little towards the right side, adhering to the inner surface of the uterus, through the medium of the decidua.†

In Fig. 1 of Plate XCVII., which is a view of this body the full size of life, we observe that it is a soft flat mass, of a roundish oval figure,‡ about eight inches in length, and from six to seven in breadth, and one in thickness, being thickest in its centre, and becoming gradually thinner towards its circumference; it is invested on this surface, which looks to the fetus, with the amnion, chorion, and decidua; and on its uterine surface, simply with the latter. On the uterine aspect, however, it is rough and irregular, from the decidua being generally detached at parturition. It consists of a profusion of blood-vessels, the divisions of the two umbilical arteries, *n*, *n*, and the umbilical vein, g, distributed in a delicate parenchymatous substance, which is subdivided by productions of the decidua from both surfaces, so as to give it a lobulated appearance; each tissue of veins and arteries forming a lobulus,§ the veins being much more numerous than the arteries. These lobules, of an irregular round shape, are very distinct on its uterine aspect, and vary very much in size. Besides the decidua on its uterine surface, there is another soft stratum, termed the parenchymatous substance, resembling it very much, which is situated between the decidua and these lobules, and which extends from lobule to lobule, and penetrates between them. By some authors the placenta is divided into a uterine and fetal portion, with the intervention of a cellular structure, like that of the corpora cavernosa penis; but this is evidently incorrect, for, not until the mass is very putrid, can we in the least separate it into two portions; and as even Dr. Hunter himself observes, "In a placenta of nine months, I have never been able to separate the two constituent parts otherwise than by some degree of putrefaction, and gentle rubbing and washing; but this operation always destroys the uterine portion, which is more tender, and melts down by putrefaction sooner than the other."

From experiments performed by Dr. Lauth,‖ vessels have been discovered between the interior surface of the uterus and the decidua, which he considers to be lymphatic. "On examining with care," says he, "a placenta still covered by the deciduous membrane, it will be seen that these two parts are united with each other by a multitude of small transparent vessels which proceed from the one towards the other. These vessels can be injected neither by those of the placenta, nor by those of the membrana decidua; but a very fine tube inserted into either, allows at one time the vessels of the decidua, at another those of the placenta, to be injected. From this it follows, 1st, That the vessels are of two orders, the one belonging to the decidua, and consequently to the uterus, and the other to the placenta; 2dly, That these are not blood-vessels; and, 3dly, That these terminate, the one in the blood-vessels of the membrana decidua, and the other in those of the placenta, by orifices provided with valves, which impede their being injected from behind."* It is probable, from the observations of Uttini,† Michaelis,‡ and Lauth, that lymphatics exist in the placenta.

The umbilical cord,§ marked g, *n*, *n* in Plate XCVI., and in Fig. 1 of Plate XCVII., is situated within the amnion, *c*, floating in its liquid, and extends generally from near the centre‖ of the placenta, *p*, to the umbilicus of the fetus, twining round the neck of the latter, and varying from fifteen to twenty-four inches in length.¶ It consists of the two umbilical arteries, *n*, *n*, and the umbilical vein, g, beautifully entwining around each other, and invested with the amnion** and chorion, which are here transparent and gelatinous. Beneath the chorion and amnion there is a still greater quantity of this gelatinous substance,†† varying very much in quantity in different individuals. The umbilical vein, g, begins by small branches in the placenta, which communicate with the vascular system of the mother, by means of lymphatics, as formerly explained, and probably also by venous absorption, through the medium of the multiplied radicles of the veins; these veins progressively become larger, unite freely with each other, and ultimately congregate to form that marked g, which proceeds along the umbilical cord, generally in its centre, the arteries twining round it,‡‡ to the umbilicus of the fetus, where it enters and proceeds between the anterior muscles of the abdomen, in the line of the linea alba, and in the duplicature of the peritoneum which forms the suspensory ligament of the liver, to the umbilical fissure, where it divides into several branches, from fifteen to twenty in number, one of which runs downwards in the fissure to join the vena cava

* The amnion is occasionally separated from the chorion in the early months of gestation, by a deposition of fluid, which is named the false water of the amnion. This, however, generally disappears between the second and third month.

† The placenta sometimes adheres to the uterus so near the cervix, as to impede the advancement of the fetus at birth, and produce hemorrhage, which may prove fatal both to the mother and fetus.

‡ The placenta is sometimes very oblong, and at others triangular, and even very irregular, being like two united by an isthmus, or having one or two small lobes appended to it.

§ Syn. Cotyledone. Lobe.

‖ Repertoire d'Anatomie et de Physiologie Pathologiques.

* The decidua which invests the uterine surface of the placenta, and the umbilical arteries in its neighbourhood, frequently becomes cartilaginous, or has calcareous depositions in it at parturition; the placenta also becomes occasionally scirrhous, points of consideration for the accoucheur; and hydatiform vesicles are occasionally found throughout the substance of the placenta.

† Uttini Memoria dell Instituto Nationale Italiano.

‡ Michaelis Observat. circa placentæ ac funiculi umbilici vasa absorbentia.

§ Syn. Funis vel funiculus umbilicalis.

‖ Great irregularity exists in the point of origin of the umbilical cord from the placenta; sometimes it originates precisely in the centre, but more commonly a little to the one side, sometimes at the very edge, at other times at the one end, and at others, again, not for some distance from the edge—the vessels, in this latter case, not having concentrated to form the cord until they have run along the convex aspect of the membranes between the decidua and the chorion. In these cases the vessels form several centres.

¶ The umbilical cord is subject to great irregularity in its course about the fetus, and hence the circulation is frequently stopped for such a length of time during parturition, as to prove fatal to the fetus. The funis is also occasionally twisted, so as to form a perfect knot, which likewise sometimes proves fatal to the fetus during parturition. It likewise varies very much in its length, and frequently has nodosities here and there.

** Syn. Vagina umbilicalis.

†† Syn. Gelatina Whartoniana.

‡‡ The vein sometimes encircles the arteries, and sometimes the three vessels encircle one another.

ascendens, *i*, as delineated in Fig. 6 of Plate X., and is named ductus venosus;* the other branches enter the liver, with the exception of one that joins the vena portæ. No valves exist in the course of the umbilical vein, but one is found where it divides at the liver of the fetus, and another where the ductus venosus joins the vena cava. No inosculation takes place between the umbilical vein and the arteries in their progress along the cord. The smaller veins in the placenta intermingle with the arteries, the one crossing and encircling the other in a beautiful manner.

The umbilical arteries, *n*, *n*, originate from the internal iliac arteries of the fetus, as represented in Fig. 6 of Pl. X., and described in page 45. They ascend behind the peritoneum, along the parietes of the pelvis, and the sides of the urinary bladder, to the anterior walls of the abdomen, where they still run peripheral or exterior to the peritoneum, atlantad or upwards to the umbilicus, at which aperture they emerge, and run along the umbilical cord, twining round the vein, g, as delineated in Plate XCVI., and in Fig. 1 of Plate XCVII., onwards to the placenta, *p*, where they branch out into several vessels, many of them inosculating, and the ultimate divisions terminating in the commencements of the umbilical vein. These two umbilical arteries generally anastomose very freely just where they begin to branch out on the placenta.

According to the interesting investigations of that indefatigable philosopher, Sir Everard Home, † nerves have been discovered supplying the placenta and umbilical cord. Those of the latter run in the gelatinous substance between the blood-vessels. They have been also seen by Chaussier and Ribes to proceed from the great intercostal nerve of the fetus, along the umbilical cord to the placenta. ‡ Lymphatic vessels have been found on the umbilical cord by some anatomists, but they are denied by others.

I shall now proceed to describe the condition of the fetus at its full developement, or at the ninth month.

Its osseous, muscular, vascular, and nervous systems have been already described in the pages wherein these subjects are treated of.

The umbilical aperture is merely a foramen in the linea alba, which becomes closed when respiration takes place at birth, throwing into action the abdominal muscles. The tendinous fibres, however, of the lateral muscles, especially those of the external oblique, cross each other around this aperture, as described in page 74, the more effectually to shut it up after birth.

The fetus, enveloped by the membranes, is situated in the uterus, being immediately surrounded by the amnion and its fluid; and in the last month of gestation, near the period of parturition, it has an oblique position, its back towards the left side of the mother, its head towards the os uteri, resting on the pubes, the chin touching the breast; its upper extremities also resting on the breast, and gently bent; its lower extremities gently bent, the patellar aspect of the thighs touching the abdomen, and the heels the popliteal aspect of the thighs, with its feet towards the placenta, and crossing each other in order to occupy the smallest possible space, and to conform to the shape of the uterus, being, like it, of an oval figure, as represented in Plate XCVI. This is the natural position of the fetus immediately prior to parturition, but a great variety exists, constituting the many different cases of labour, as those of the face, breech, and foot.

It is commonly about twenty-two inches long, and weighs from eight to fifteen pounds. The skin is of a bluish violet colour, and covered with a white sebaceous substance, particularly the head, back, axillæ, and groins.

The thoracic cavity is much smaller, relatively speaking, than in the adult, in consequence of the lungs being collapsed; and the diaphragm is loose and flaccid. The thymus gland, a large glandular mass, consisting of two oblong lobes, united at their sacral aspect, but free at their atlantal aspects, where they extend on the sides of the trachea, is situated in the anterior cavity of the mediastinum, as described in page 38, and extends also upwards or atlantad in the neck, towards the thyroid gland. It rests in some degree on the pericardium and large blood-vessels of the heart, and also on the left subclavian vein; it is of a whitish yellow colour, and consists of a number of small vesicles, containing a milky-coloured fluid, surrounded and connected together with a tolerably thick and strong cellular tissue. A number of small blood-vessels are distributed to this gland, but no excretory ducts have been traced from it.

The lungs are collapsed and solid, and of a purplish colour, none of the blood in the fetus having been yet oxygenated. The foramen ovale exists in the septum auriculorum of the heart, as described in page 35; and in page 36, the pulmonary artery is described to have a central branch, named the ductus arteriosus, which extends to the arch of the aorta. The pulmonary veins are collapsed, and to appearance much smaller than natural.

The head bears a greater proportion to the rest of the fetus than in the adult.

The abdomen is also larger and more prominent in proportion, chiefly in consequence of the magnitude of the liver. The liver bears a considerably larger proportion to the other viscera than it does in the adult, and particularly the left lobe, which is even larger than the right, and extends into the left hypochondriac region; the free margin of the liver descending almost to the umbilicus. Its texture, which is of a deep red colour, is exceedingly soft and pulpy. In the earlier stage of the fetus, there is merely a mucous fluid found in the gall bladder, and not until a short period before birth is there any biliary fluid secreted. The course of the umbilical vein, and its branches which enter into the substance of the liver, have been described.

In the intestinal canal there is a peculiar glairy substance, of a greenish colour in the small, and blackish in the large intestines, which is termed meconium.* The supra-renal glands are considerably larger in the fetus than in the adult. The urinary bladder rises more into the abdominal cavity than in the adult, in consequence of the shallowness of the pelvis. The urachus is more conspicuous; and the umbilical arteries, as already described, are the largest branches of the internal iliacs. These are the chief peculiarities in the fetus at the full period of gestation, the rest having been described in treating on the other viscera of the adult.

* The ductus venosus sometimes joins the venæ hepaticæ.

† Phil. Trans. for 1825, Part I.

‡ Experiences Nouvelles sur le Digestion, et Remarques à ce Sujet dans Journ. Univ. des Sciences Med. t. i. p. 233.

* The colour of this substance should be attended to when operating on a child born with an imperforated anus.

LYMPHATIC OR ABSORBENT SYSTEM.

THE lymphatic system consists of an elaborate set of vessels, being more numerous than either the arterial or venous, and of a number of glands distributed in various parts in the course of these vessels.

The lymphatics consist of a superficial and a deep set of vessels, throughout not only the head and extremities, but even all the viscera of the thorax, abdomen, and pelvis. Some of them, almost as soon as they originate, at once join the veins in the capillary tissue, others join the veins in the lymphatic glands, while others again concentrate to form the thoracic duct, which ultimately also joins the venous system. Every venous or arterial trunk is generally accompanied with several lymphatics, commonly ten in number; and all the lymphatic vessels have valves somewhat similar to those of the veins.

The lymphatics situated on the alimentary canal are named lacteals,* and both these and the other lymphatics are also termed absorbents.

The lacteals are those lymphatics or absorbents situated on the intestinal canal, being named so from the commencement of the duodenum to the termination of the rectum. But there are other absorbents which carry the lymph from the tissue of the intestines, and which are simply named lymphatics, although they take the same course. They are subdivided into lactea primi generis, and lactea secundi generis. The lactea primi generis are those which extend from the intestines to the lymphatic glands situated in the folds of the mesentery; and the lactea secundi generis are those which extend from the lymphatic glands to the thoracic duct.

In order to give a connected description, I shall begin with the lymphatics of the stomach. These arrange themselves into three fasciculi, those of the left side, those of the lesser curvature, and those of the greater arch. The lymphatics of the left side originate at the larger extremity or cul-de-sac of the stomach, where they are joined by some of those of the omentum majus, accompany the vasa brevia of the splenic artery to its trunk, where they terminate in the lymphatics of the spleen. The lymphatics of the right side or greater arch originate from this region of the stomach and the omentum majus, accompany the arteria gastro-epiploica dextra, running through several small lymphatic glands in their course, to the dorsal aspect of the pancreas, where they unite between the cœliac and superior mesenteric arteries with the lacteals of the intestines, in order to form one of the principal branches of the thoracic duct. These lymphatics of the greater arch also inosculate in their course with those of the lesser arch. The lymphatics of the lesser arch originate near the pyloric orifice of the stomach, where they anastomose with those of the greater arch; accompany the gastric artery to the cardiac orifice, running through several lymphatic glands; and concentrating, they descend to the root of the liver, where they join the lymphatics of this organ, and terminate in the thoracic duct. These lymphatics of the stomach will be found chiefly to accompany the arteries of the stomach, and, before concentrating, to run both superficially and deep-seated; the superficial arising between the peritoneal and muscular coats, and forming numerous inosculations; the deep-seated originating between the muscular and villous tunics, and uniting with each other, and also with the superficial set. In this course, these lymphatics communicate or run through several lymphatic glands,* some of which are situated on the lesser concave arch in the course of the gastric artery, others on the greater convex arch in the course of the arteria gastro-epiploica dextra et sinistra, also in the course of the vasa brevia. These glands are small and few in number, being seldom more than five or six on each arch.

The lymphatics or lacteals of the small intestines are very numerous, more so than those of the stomach or the large intestines, and abound more in the duodenum than in the jejunum or ileum, and more in the jejunum than in the ileum. They consist of a superficial and deep-seated set; the deep-seated originating from the mucous coat, from the villi or radicles which absorb the chyle, described in page 194. They run between the mucous and muscular tunics, around the intestine in a circular manner, some of them piercing the muscular coat and uniting with the superficial set in this region, while others run between the peritoneal folds, forming the mesentery, and there unite with the superficial. The latter set derive their origin between the muscular and peritoneal coats, where, as already observed, they form inosculations with the deep-seated lacteals, and extend first in a longitudinal manner along the intestinal canal, as delineated in Plate XCVIII., marked with the digits 12, uniting with each other in various directions, and ultimately joining the deep-seated set in the folds of the mesentery. The two sets unite and concentrate, and run in the course of the superior mesenteric artery, marked R in Plate XCVIII., piercing or communicating with the mesenteric glands, marked with the digits 3. In their course along the trunk of the superior mesenteric artery, R, these are joined by the lymphatics of the ascending, O, and transverse, P, portions of the colon, marked with the digits 13, which vessels arise and run in a similar manner to those of the small intestines, being only much less numerous. The whole are now generally concentrated into two, three, or four vessels, which accompany the superior mesenteric artery to the pancreas, where they inosculate with the lymphatics of the pancreas, liver, and spleen, and form one of the chief branches constituting the thoracic duct, marked with the digit 1. The lymphatics of the sigmoid flexure, *z*, of the colon, and the rectum, 1*, take a different course; those of the colon join the lymphatic glands in the sacral and lumbar regions, and those of the rectum, the lymphatics in the sacral and iliac regions, both of them ultimately terminating in the lymphatic trunks of the lower extremities which contribute to form the thoracic duct.

These lymphatic vessels, in their course from the small and large intestines, pass through or communicate with a

* Syn.. Vasa chylifera.

* Syn. Glandulæ ventriculi superiores et inferiores. Glandulæ stomacho-epiploicæ. Les glandes gastro-epiploïques.

number of lymphatic glands, which are named mesenteric and mesocolic, from their situation. The mesenteric, marked with the digits 3, are chiefly situated on the sinistral aspect of the superior mesenteric artery, R, and are much more numerous and larger than the mesocolic, marked with the digits 2, being estimated by some authors to be upwards of a hundred in number. The glands communicating with the lymphatics of the jejunum, K, are better developed than those of the ileum; and those near the intestine are smaller and more apart than those near the trunk of the artery. *

The lymphatics of the liver, I, i, are extremely numerous, small, and have less perfect valves, so that they can be injected from their trunks, and arrange themselves into deep and superficial sets. The superficial set of lymphatics is distributed on the convex and concave aspects; those on the convex surface arrange themselves into three fasciculi, a right, a left, and a middle. The right fasciculus extends over the convex surface of the right lobe, I, runs towards the right lateral ligament, where it pierces the diaphragm, and enters the thoracic cavity, some of the branches joining the thoracic duct, 1, others inosculating with the inferior lymphatics of the diaphragm, while others again advance sternad to unite with the middle fasciculus after its entrance into the thorax. The left fasciculus occupies the greater extent of the convex surface of the left lobe, i, of the liver, runs towards the left lateral ligament, and joins the lymphatics of the lesser concave arch of the stomach, as described in page 218. The middle fasciculus derives its origin partly from the left and partly from the right lobe of the liver, runs along the suspensory ligament, and pierces the diaphragm near the sternum; having entered the thoracic cavity, its vessels, about six in number, inosculate with the lymphatics in this region of the diaphragm, and concentrate in forming two or more trunks, which run in the folds of the mediastinum, uniting with the lymphatics of the pericardium and pleura sternalis, onwards to the thoracic duct near its termination. Sometimes a few vessels of this fasciculus run on the left of the suspensory ligament towards the coronary ligament, and join other lymphatics of the liver between the left lobe and diaphragm, which descend to the thoracic duct in the abdomen.

The superficial lymphatics on the concave surface of the liver, marked with the digits 14, in Plate XCVIII., are not so numerous as those on the convex aspect, with which they inosculate. They run along the concave surface, i; those on the right lobe uniting with those on the left, i, and also with the deep lymphatics towards the vena portæ, along which they extend, and unite with the lymphatics of the intestines. Some of these latter lymphatics of the liver at once pierce the glandular substance, and unite with the deep-seated set.

The deep-seated lymphatics of the liver, much more numerous than the superficial, accompany the divisions of the vena portæ, hepatic artery, and hepatic duct, and emerge at the fossa of the vena portæ, accompanying this vessel to the root of the mesentery, where they unite with the lymphatics of the intestines, to form one of the chief sources of the thoracic duct; and forming in this course inosculations with the lymphatics of the lesser arch of the stomach, and those of the pancreas and spleen. These lymphatics pass through or communicate with several lymphatic glands situated in their course along the trunk of the vena portæ. *

The lymphatics of the spleen consist of a superficial and deep set, the former of which being very small, originating from and encircling its convex surface, descend towards the entrance of the splenic artery, where they are joined by the deep-seated lymphatics of considerable magnitude, and from thence both proceed along and around the artery. In their progress along the splenic artery, they are joined by the superficial and deep-seated lymphatics of the pancreas, and then proceed to join the lymphatics of the intestines, inosculating with those of the stomach, as described in page 218.

The thoracic duct, † marked with the digit 1 in Plate LXXXIV., and in Plate XCVIII., is formed by this concentration of the lymphatics of the stomach, intestines, liver, spleen, and pancreas, together with the two trunks of the lymphatics of the lower extremities and the other viscera of the abdomen and pelvis, and is generally first observable in the region of the first, second, or third lumbar vertebra, between the fleshy pillars of the diaphragm, dorsad of the aorta, and atlantad of the right renal artery. Here, or a little atlantad, it commonly becomes a little enlarged, and has been named the receptaculum chyli; ‡ but more frequently there is merely a sort of varicose appearance. From this region the thoracic duct, 1, ascends behind the aorta a little dextrad, and enters the thoracic cavity between the aorta and the right crus of the diaphragm; then ascends in the posterior cavity of the mediastinum, between the aorta and vena azygos, 5*, to the fifth dorsal vertebra, where it runs sinistrad obliquely behind or dorsad to the œsophagus, I, the descending aorta, E, and its arch, to the root or origin of the left carotid artery, P, dorsad to which, and sinistrad of the œsophagus, it ascends to the second or first dorsal vertebra, where it mounts to the left internal jugular vein, forming a circular turn. Here it generally splits into two branches, which, after proceeding a very short distance, again unite and run dorsad to this vein to the sinistral aspect of its termination, where the duct joins the left subclavian vein, by entering its atlanto-dorsal or superior posterior aspect; the internal serous tunic of the vein forming a semilunar valve, which covers two-thirds of the orifice of the duct. In this course, the thoracic duct having few valves, occasionally divides and unites again more than once, particularly where it crosses from right to left in the thoracic cavity, and in this course it is also joined by several branches, the lymphatics of the pleura, intercostal spaces, and the lymphatics of the lungs, the lymphatics of the heart, and the lymphatics of the left superior extremity, and left side of the head.

The lymphatics of the pleura arrange themselves into anterior and posterior. The anterior § commence upon the thoracic aspect of the diaphragm, where they are joined by the lymphatics on the atlantal and sternal aspects of the integuments and muscles of the abdomen, which pierce the diaphragm at the ensiform cartilage; from this they ascend on each side of the sternum, in

* The mesenteric lymphatic glands are subject to inflammation, suppuration, scrofulous enlargement, scirrhus, cancer, osseous concretions, earthy concretions, and the various species of sarcoma.

* These lymphatic glands are sometimes so tumefied, that they obstruct the course of the biliary fluid along the ducts, and produce icterus.

† Syn. Left thoracic canal. Le canal thoracique, proprement dit.

‡ Syn. Cysterna chyli. Reservoir of Pecquet. Saccus lacteus of Van Horne.

§ Syn. Internal mammary lymphatics.

company with the internal mammary artery, those of the left side concentrating in one or two trunks, and continuing to ascend before or sternad to the left subclavian vein, where it joins the thoracic duct, or terminates at once in the vein itself. In this course they are joined by lymphatic vessels between the intercostal spaces,* and run through several lymphatic glands in their course, especially those situated in the lower or sacral region of the neck. The lymphatics on the right side of the sternum take the same course, in company with the internal mammary artery of that side, and are joined by the intercostals of the same side; but they either terminate in the venous system, at the junction of the right internal jugular and right subclavian veins, or unite with the lymphatics of the right upper extremity and right side of the head.

The posterior set of lymphatics, marked with the digits 4 in Plate XCVIII., accompanies the intercostal arteries,† receiving, in its course towards the spinal column, several lymphatic vessels from the pleura and intercostal muscles. They run between the ribs, and terminate in the thoracic duct, during its progress in the thoracic cavity, inosculating in their course with each other, especially round the aorta, with the lymphatics of the spinal canal, and running through several lymphatic glands, and also communicating with the lymphatic glands of the lungs.

The lymphatics of the lungs are arranged into superficial and deep-seated. The superficial set, marked 18, in Fig. 1 of Plate XCIX., originates on the pleura pulmonalis, and forms a complicated plexus, which runs between the lobes, inosculating with the deep set, and on the mesial aspect towards the bronchial glands, marked b. The deep-seated lymphatics derive their origin from the interlobular substance, where they inosculate with the superficial, and accompany the branches of the pulmonary vessels, and the ramifications of the trachea, and run through the bronchial glands.‡ At the first division of the trachea, K, the lymphatics of the left side, which are more numerous than those of the right, ascend along the left subclavian vein, *v*, to the left internal jugular, M, and either terminate in one of these veins, or in the thoracic duct, or in the lymphatic trunks of the left side of the neck or upper extremity. In this course these lymphatics are joined by those of the pericardium, and run through several lymphatic glands, situated on the trachea.

The lymphatics of the right lungs, fewer in number than those of the left, after passing through the glands or the trachea, concentrate into one, which is joined by the lymphatics of the pericardium, anterior mediastinum, and heart, and ascend to terminate in the right internal jugular or subclavian vein.

The lymphatics of the pericardium are few, and run between the laminæ of the mediastinum to join those of the lungs. In the fetus, the lymphatics of the thymus gland have the same course and termination.

The lymphatics of the heart, marked with the digits 20 in Plate XCVIII., are divided into superficial and deep-seated. The superficial accompany the coronary arteries, *r*, *s*, and in their progress are joined by the deep-seated lymphatics. Those which accompany the left coronary artery, *s*, are more numerous, and ascend on the aorta, E, inosculating with those of the right side, and join the thoracic duct, 1. The lymphatics accompanying the right coronary artery, *r*, proceed to the pulmonary lymphatic trunk which terminates in the right subclavian vein. In this course these lymphatics of the heart run through lymphatic glands situated on the aorta.

Besides the lymphatic glands already described in the thoracic cavity, there are some situated between the intercostal muscles; in the course of the internal mammary artery; between the laminæ of the anterior mediastinum; in the posterior cavity of the mediastinum; in the course of the œsophagus and aorta; and in the substance of the lungs, as described in page 37.

The lymphatics of the upper extremity are arranged, like the preceding, into superficial and deep-seated. The superficial may be divided into the palmar and anconal The anconal or posterior set commences on the back, or anconal aspect of the fingers, runs on their radial and ulnar margins, uniting in the course upwards or proximad along the cutaneous veins of the back of the hand, with the lymphatics on the palmar aspect. As they ascend proximad, they encircle the fore arm on each side, and run on the palmar aspect at the bend of the arm, where they unite with the superficial palmar set. This latter set of lymphatics, marked with the digits 21, in Fig. 2 of Plate XCIX., begin on the palmar aspect of the fingers, run along the ulnar and radial margins, uniting with those on the anconal aspect, concentrate at the palm of the hand into three or four vessels, which continue to ascend proximad on the palmar aspect, several of them running on the cephalic, r, and median, s, veins, to the bend of the arm, where they unite with the anconal set, run through the lymphatic glands in this region, marked 2, and then ascend chiefly in company with the brachial vein, u, and artery, h, to the axillary glands, marked with the digits 3. Some accompany the cephalic vein, r, throughout its course, to its termination in the axillary vein, *u*, and then join either the axillary, 3, or the inferior cervical glands, 4. From the axillary glands, 3, the lymphatics, reduced in number to four or five, run along the subclavian vein, *v*, and artery, H, and either enter the subclavian vein, or join the lymphatics of the neck, or the thoracic duct, 1.

The deep-seated lymphatics accompany the arterial distribution, beginning from the digital branches, and extending to the volar, the ulnar, the interosseal, the radial, the brachial, and the axillary arteries, and terminating in the axillary glands, 3. In this course they inosculate frequently with the superficial, and receive the lymphatics, 5, from the sternal aspect of the thorax, the mamma, and the pectoral muscles. These latter lymphatics are marked 5 in Fig. 1 of Plate XCIX.

The superficial lymphatics, from the sternal and lateral aspects of the thorax, originate as high up or atlantad as the sacral, or lower part of the neck, and as low down or sacrad as the umbilicus. The atlantal set runs along the greater pectoral muscle to the axillary glands; the sacral set ascends, and some of them pierce the rectus muscle, and join the lymphatics of the thorax. The lateral set ascends on the external oblique and serratus magnus muscles, to the axillary glands, and some of them pierce these and the intercostal muscles, in order to join the intercostal lymphatics.

The lymphatics of the right upper extremity terminate either in the right subclavian vein, or in the internal jugular of the same side, and are frequently joined by the

* Syn. Anterior intercostal lymphatics.

† Syn. Posterior intercostal lymphatics.

‡ The bronchial glands, particularly those near the bifurcation of the trachea, are subject to scrofulous enlargement, to inflammation and suppuration, constituting phthisis pulmonalis, to calcareous concretions, to osseous depositions, and to scirrhus.

lymphatics of the right side of the head, and those of the right lungs, so as to form a right thoracic duct. This, however, is of very short extent, being seldom more than an inch in length.

Besides the lymphatics of the upper extremity and those of the mamma, joining the axillary glands, there are all the superficial lymphatics of the back, from the nape of the neck to the lumbar vertebræ. Those in the cervical region descend on the trapezius muscle, pierce the deltoid muscle, and join the axillary glands, receiving in their course the lymphatics of the shoulder. The lymphatics situated in the lumbar and dorsal regions ascend on the trapezius muscle, which they pierce to get to the axillary glands.

Besides the glands already described, there are generally from five to eight lymphatic glands (marked with the digits 22 in Fig. 1 of Plate XCIX.) situated in the course of the brachial artery. The lymphatic axillary glands, 3, vary from eight to twelve in number, and are much larger than the preceding. They are closely connected by cellular substance with the axillary vein, *u*, and artery, *h*, being plentifully supplied by their branches,* and they extend upwards or proximad beneath the pectoral muscles and clavicle to the inferior cervical glands, 4.

The lymphatics of the head and neck are arranged also into superficial and deep-seated sets.

The superficial lymphatics of the head originate on the coronal aspect of the cranium, and accompany the frontal, 91, the temporal, *g*, and occipital, *d*, arteries, as delineated in Plate C. Those marked 23, which accompany the frontal artery, 91, with its vein, *z*, descend to the inner angle of the orbit, where they accompany the facial artery, *c*, with its vein, z, to the base of the inferior maxillary bone, and unite with those which accompany the temporal artery. In this course they inosculate with the lymphatics, 24, of the temporal artery, *g*, and are joined by several lymphatic vessels from the integuments of the face; they also run through or communicate with the lymphatic glands, marked 25, situated on the buccinator muscle, and those at the base of the lower jaw-bone, marked with the digits 7.

The lymphatics marked 24, accompanying the temporal artery, *g*, originate on the coronal aspect of the cranium, where they inosculate with those, 23, which accompany the frontal, 91, and the occipital, *d*, arteries, and then descend to the zygoma, where they communicate with some superficial lymphatic glands, marked 8, and afterwards accompany the artery to the angle of the inferior maxillary bone, where they unite with those of the face, the occiput, and nape of the neck, and join the superficial cervical glands, marked 9. From these glands, some of them descend on the external jugular vein, *d*, and terminate in the inferior cervical glands, marked 4. Some of these lymphatics run superficially or dermad to the parotid gland, s, where they inosculate freely with those of the face. The lymphatics of the occiput, marked 26, originate on the coronal aspect of the cranium, where they inosculate with those, 24, accompanying the temporal artery, *g*, and descend behind the ear in company with the occipital artery, *d*, to the insertion of the sterno-cleido-mastoideus muscle, E, where they leave the artery, running superficially to this muscle towards the lobe of the ear, where they join some of the superficial lymphatic glands of the neck, marked 10, and inosculate with the temporal lymphatics and those of the nape of the neck; some of them afterwards descend along the sterno-cleido-mastoideus muscle, E, to its clavicular origin, where they terminate in the inferior cervical glands, marked 4.

The deep-seated lymphatics of the face derive their origin from the muscles of the face, the nose, and the mouth, and descend to the deep superior cervical glands,* marked 6 in Fig. 1 of Plate XCIX., where they are joined by the lymphatics of the nares, the mouth, the tongue, the palate, the pharynx, and the larynx. The lymphatics of the nares accompany the internal maxillary artery to these lymphatic glands.† The deep-seated of the cranium, or rather those of the brain, have never been seen but when this organ was in a diseased state, and effusion on its surface had taken place; in which case lymphatic vessels are seen on the dura mater, arachnoid coat, and pia mater; they accompany the primary divisions of the internal carotid and vertebral arteries (for no lymphatics have been discovered in the substance of the brain), back to their origin out of the cranium, where some of them terminate in the deep superior cervical glands, 6, in Fig. 1 of Plate XCIX., or descend to the inferior cervical glands, 4, inosculating on their emergence from the cranium with the superficial cranial and facial lymphatics. Some of these lymphatics accompany the internal jugular vein. The united lymphatics, from the surface of the head and its interior, descend along the internal jugular vein, M, in Fig. 1 of Plate XCIX., and cellular web, covering the muscles posterior or dorsal to it, receiving in their course the lymphatics from the trachea, K, the thyroid gland, Z, the œsophagus, and muscles and integuments of the neck, and inosculating freely with each other, downwards to the inferior cervical glands, 4, where they emerge in one or more trunks, which terminate either in the thoracic duct, 1, or in the internal jugular vein, M, or in the subclavian vein, *v*, but most frequently in the internal jugular vein. In many instances, these lymphatics of the head and neck unite immediately before their termination with those of the upper extremity, and even those from the lungs; on the right side this is almost invariably the case, as described in page 220.‡ Besides the lymphatic glands already enumerated, some are found behind or centrad of the parotid gland, others along the course of the common carotid artery, and internal jugular vein, M, some of the latter of which are marked 11 in Fig. 1 of Plate XCIX.

The lymphatics of the lower extremities are divided into a superficial and deep set, like the rest of the system. The superficial lymphatics, marked with the digits 27, in Figs. 1 and 2 of Plate CI., run between the integuments and the fascia lata, K. They begin on the patellar aspect on each side of the toes, accompanying the branches of

* As the axillary glands are very subject to inflammation, suppuration, scirrhus, and cancer, particularly when the last disease affects the mamma, the student should make himself thoroughly master of their situation and relative connexion.

* Syn. Glandulæ jugulares. Glandulæ concatenatæ.

† The relative situation of these glands to the nerves and blood-vessels in this region should be thoroughly understood, as they are subject to scirrhus and cancer; they are also subject to inflammation, suppuration, and all the species of sarcoma.

‡ The course of the lymphatic vessels to the glands should be understood, to enable us to comprehend how these glands in the neck become affected, when, for example, the disease is in the nose or mouth. The lymphatic glands in the region of the parotid and submaxillary glands are frequently affected with disease, and may afterwards involve these salivary glands.

the saphena major vein, marked *b* in Fig. 2, along which they chiefly ascend on the leg to the tibial aspect of the knee-joint, where they are joined by another set of lymphatic vessels, which originate from the outside or fibular aspect of the sole of the foot, and accompany the saphena minor vein upwards or proximad to the poples, where, as already observed, they join the preceding, or the deep lymphatics accompanying the popliteal artery. Both of these fasciculi of superficial lymphatic vessels frequently inosculate in their progress. In their course along the patellar aspect of the inner malleolus, *s*, the first series of lymphatics, 27, is joined by some which originate on the sole of the foot. The lymphatic vessels formed by the union of these two fasciculi, ascend on the tibio-patellar aspect of the thigh, as represented in Fig. 2 of Plate CI., where they still chiefly accompany the saphena major vein, *b*, upwards or proximad to the inferior superficial lymphatic glands,* marked with the letters *a*. In this course along the thigh, these are joined by several lymphatics of the integuments from the outer or fibular, and the posterior or popliteal aspects; and throughout their whole extent, they frequently unite with the deep-seated.

The deep-seated lymphatics accompany the respective deep arteries of the leg, as the anterior tibial, the posterior tibial, and the fibular, uniting with each other at the poples, where they enter the popliteal lymphatic glands, and also inosculating frequently with the superficial lymphatic vessels. From their emergence at the popliteal glands, there are generally from four to six large trunks which accompany the popliteal and superficial femoral arteries, upwards or proximad to the groin, where some of them join the inferior superficial inguinal glands, marked *a* in Fig. 1 of Plate CI.; others join the deep-seated inguinal glands, marked 15 in Plate XCVIII.; while others again run by the side of these glands, receiving in their course those of the superficial lymphatic vessels which have emerged from the inferior superficial inguinal glands, *a*, and enter the abdominal cavity with the crural artery, t, T, and its vein, U, and terminate in the external iliac glands, 16. The other deep lymphatics of the thigh accompany either the obturator artery, the ischiadic artery, or the gluteal artery, and join the sacral and hypogastric lymphatic glands. So also do the lymphatics of the perineum accompany the internal pudic artery, and join the hypogastric glands.

The superficial lymphatic vessels of the abdomen, beneath or sacrad to the umbilicus, marked 28, in the regions of the loins, 30, the nates, 31, the penis, 32, the scrotum, 33, and the perineum, inosculate frequently with each other, and ultimately join the superior superficial inguinal lymphatic glands, marked 17 † in Fig. 1 of Plate CI. From these superior glands, 17, the lymphatic vessels, reduced in number, descend to the inferior inguinal glands, *a*. The superficial lymphatic vessels of the inferior half of the abdomen inosculate with those of the superior half, where they originate or commence. The superficial lymphatics of the penis and scrotum often inosculate with the superficial lymphatics of the thigh, as seen in Fig. 1 of Plate CI. Those of the penis, marked 32 in Fig. 1 of Plate CI., are generally three in number, and begin at the prepuce, from which they extend to the root of the member inosculating with each other, and ultimately separating into two sets, one of which runs to the glands on the one side, and the other set to the series of glands on the opposite side. The lymphatics of the scrotum, 33, inosculate with those of the testis, b. Those of the clitoris and external labia in the female also inosculate with those of the thigh, and terminate in the superior superficial lymphatic glands.* The deep lymphatic vessels of the penis accompany the internal pudic artery to the hypogastric glands. The deep lymphatic vessels of the clitoris take the same course. The lymphatics of the lower portion of the vagina ascend to the external aperture of the inguinal canal, enter the abdominal cavity, and run along the round ligaments to the uterus, where they join the lymphatics of that organ. Besides the lymphatic glands of the lower extremity, already described, there are some others. One or two is occasionally found in the course of the anterior tibial artery, near the knee-joint, and is named glandula tibialis antica. The popliteal glands are small, commonly about three in number, and are in close contact with the popliteal blood-vessels.

In the pelvis a number of lymphatic vessels originates from the viscera in this cavity; in the male, from the urinary bladder, the prostate gland, and vesiculæ seminales; and in the female, from the urinary bladder, uterus, and its appendages. In the male, those of the bladder, prostate gland, and vesiculæ seminales, inosculate with each other, and ascend to enter the external iliac, 16, the hypogastric, or internal iliac, 19, and sacral lymphatic glands. In the female, those of the bladder take the same course. Those of the vagina, and os et cervix uteri, accompany the uterine arteries to the hypogastric glands; those of the body and fundus of the uterus accompany the spermatic arteries, being joined in their course by the lymphatics of the ovaria, and enter the lumbar glands. The lymphatics of the ureters partly join those of the urinary bladder, and partly ascend along the ureters, to enter the lumbar glands, inosculating with the lymphatics of the kidneys. Independently of these in the cavity of the pelvis, there are several lymphatic vessels around its parietes; thus, some originate from the central aspect of the symphysis pubis, where they are joined by lymphatics of the pyramidalis and levator ani muscles, and proceed to join the external and internal iliac glands; while others derive their origin from the concave aspect of the sacrum and coccyx, from the sacro-ischiadic plexus of nerves, where they are joined by those which accompanied the gluteal, ischiadic, and internal pudic arteries from without the pelvis, and terminate in the hypogastric glands.

The lymphatics of the testicle, marked 34 in Plate XCVIII., are exceedingly numerous, and consist of a superficial and deep set, the former deriving its origin from the tunica vaginalis, and the latter from the substance of the gland, r, *r*. From this they ascend in company with the spermatic artery, *g*, to the inguinal canal, enter the abdominal cavity, and extend along the artery to the lumbar glands, where they inosculate with the renal lymphatics. At their origin they are joined by some of the lymphatics of the scrotum.

The external iliac glands, about eight or ten in number, extend along the course of the artery of the same name; and the internal iliac or hypogastric glands, about twelve

* It is this lower or distal series of lymphatic glands which becomes affected in the first instance, in wounds and diseases of the leg, distal to them; as, for example, in ulcers.

† It is these superior inguinal lymphatic glands which become affected with bubo, supervening to gonorrhœa, or syphilitic ulcer, on the glans, prepuce, or scrotum.

* This chain of connexion should be kept in view in syphilitic chancres occurring in the female.

in number, also extend along their artery. The sacral glands, small and numerous, extend between the hypogastric glands of each side, being situated between the rectum and the sacrum, and mingling with the mesocolic glands. The lumbar glands, extremely numerous and large, are situated around the vena cava ascendens, and abdominal aorta, from its bifurcation into the two common iliacs upwards or atlantad to the renal arteries, on the latter of which they extend laterad, and also on the sides of the bodies, and transverse processes of the lumbar vertebræ.

The lymphatics of the kidneys consist of a superficial and deep set; the former run over the surface, inosculating with the lymphatics of the supra-renal glands, onwards or mesiad to the concave fissure of the kidney, where they join the deep-seated lymphatics which come from the substance of the gland. From the concave fissure both of these lymphatics accompany the renal arteries, inosculating with those of the ureters and spermatic cord, and terminate either in the lumbar glands, or the thoracic duct itself.

The lymphatics of the supra-renal glands join either those of the kidney, or the liver, or the spleen, according to the side of the body to which they belong.

The lymphatics of the peritoneum and muscles, forming the parietes of the abdomen, accompany those arteries which are in their vicinity; thus, for example, those on the sternal aspect accompany the epigastric artery to its origin, and terminate in the external iliac glands. Those on the lateral aspect accompany the lumbar and the circumflex iliac arteries, the former joining the lumbar glands, where they generally run across to the lymphatics of the opposite side, to form the lumbar plexus. Those which accompany the circumflex iliac artery terminate in the external iliac glands.

The lymphatic vessels which have been described entering the lumbar glands, emerge from these in one or two trunks; that on the right side emerges and ascends dextrad of the aorta, to the right renal artery, a little atlantad to which it unites with that of the left side, which crosses from left to right, behind or sacrad to the aorta, and here both are joined by the concentrated lymphatic vessel from the intestines, which descends dextrad of the origin of the superior mesenteric artery and the aorta, to form the thoracic duct described in page 219.

Sr. Lippi of Florence has traced some lymphatic vessels from the lumbar glands, entering the vena cava ascendens, near the third lumbar vertebra. He has also discovered other lymphatics at once entering the venous system, as, for example, the lymphatics of the liver joining the vena portæ. In one of his experiments, having inserted a pipe in one of the left external iliac lymphatic vessels, and injected mercury, he perceived in the left lumbar region several lymphatic vessels enter the vena cava ascendens, some running sternad, others dorsad, of the aorta; also some ascending and joining the superior mesenteric and splenic veins. In another experiment, he found some lymphatic vessels at once enter the common iliac vein.

The structure of the lymphatic vessel is somewhat similar to that of a vein; only it has no distinctly visible muscular fibres, even in the largest trunk, the thoracic duct. It is presumptive, however, that it possesses either these fibres or others analogous, as it evidences sensibility and motion in its living action. The external tunic is partly fibrous.* The parietes of a lymphatic vessel are exceedingly thin, and consist of a distinct fibro-cellular and a serous tunic, both of which are very extensible, and the external possesses considerable strength. Throughout the system of lymphatic vessels, a number of valves are situated, which are reflections of the internal serous tunic, and are much less numerous in the thoracic duct than in the smaller branches. These valves are of a semilunar or parabolic figure, the convexity towards their origin, their concavity towards the venous system; they are generally arranged two and two, the one being a little larger than the other; sometimes there is only one, while at others there are three; the latter, however, is very rarely the case. The lymphatics have minute nerves, and vasa vasorum distributed on them.†

The lymphatic glands, which we have seen to be in general small, hard, roundish, and in some degree flattened bodies, are of the conglobate class, and of a reddish-gray colour. Their size and colour vary in different parts of the body; they are smallest on the serous membranes, and largest in the axillæ, at the root of the lungs, mesentery, pelvis, and groins; but the largest and smallest are found together in these regions. The smallest are clear, as those on the pleura and peritoneum; the subcutaneous are of the reddish-gray colour, while those at the root of the lungs and trachea are almost black. They also vary in size at the different periods of life; they are larger in early than in advanced age, and greater in size in the female than in the male.

They are enveloped in a condensed cellular tissue, and free from the contiguous structures; they seem on first aspect to be homogeneous, but when they are filled with air or mercury, they become knotted on their external surface; and in their interior, the lymphatic vessels which enter them, divide into a multitude of very delicate ramifications, accompanied with equally delicate arteries, veins, and nerves, the latter consisting of excessive tenuity, all connected together by a delicate cellular tissue. The arteries are extremely numerous. The lymphatic vessels which enter the lymphatic glands, are more numerous than those which emerge to proceed onwards to the thoracic duct. In the fetus no lymphatic glands exist, and there are in their stead merely simple plates, where the continuity of lymphatic vessels is quite apparent.

---

* Sœmmering and Schreger have seen transverse muscular fibres in the thoracic duct of man and the calf.

† The lymphatic vessels are subject to inflammation and suppuration.

PHYSIOLOGICAL AND PATHOLOGICAL OBSERVATIONS.

The pabulum of life, taken up by the absorbents, is conducted by the thoracic duct to the venous system, which it joins at the angle formed by the internal jugular and the subclavian veins of the left side. This subclavian vein, or vena anonyma, having the nutritious lymph blended with the blood returned from the left side of the head and the upper extremity, soon unites with the vena anonyma or subclavian vein of the right side, returning the blood of the arm and head of the same side, and forms the vena cava descendens, which is immediately joined by the vena azygos. The vena cava descendens, by its undulatory motion, propels the blood onwards to the right or pulmonic auricle,* where meeting with that returned by the vena cava ascendens, which is the trunk of the venous system of the lower extremities and the abdomen, and that returned by the coronary vein of the heart, the fleshy parietes of this auricle are distended, stimulated to action, and contracting, propel the blood through the tricuspid valve into the right or pulmonic ventricle; the blood being prevented flowing downwards into the inferior vena cava by the valve of Eustachius, and the accumulation of blood advancing to pursue the same course; and from flowing upwards by the current of blood, and the vis a tergo.

When the right ventricle is distended, its fleshy parietes are excited, which contracting propel the blood out of the cavity, at the mouth of the pulmonary artery; the blood being prevented regurgitating into the right auricle by the tricuspid valve stretching across the aperture, from the blood stimulating its columnæ carneæ to contraction; and in order that the ventricle may be thoroughly distended, the semilunar valves at the mouth of the pulmonary artery offer, in the commencement of the distention of the cavity, a resistance to the blood, in consequence of their being filled with this fluid when the pulmonary artery contracted to propel the blood which immediately preceded. Part of the tricuspid valve also assists in forming this obstacle to the flow of blood at the pulmonary artery, by its partly overlapping the opening into the artery.

The blood then enters the pulmonary artery, which being stimulated, contracts, and propels the fluid through its branches in the lungs, where giving off carbonaceous matter, and assuming a vermilion hue, it returns by the four pulmonary veins into the left or systemic auricle † of the heart; which being similarly excited, contracts, and propels the blood through the mitral valve into the left or systemic ventricle; which also similarly contracting, propels the blood into the aorta, the branches of which maintaining the like contractile motion, propel the blood over all the system, its gelatinous and fibrous part being retained in the cells of that vascular parenchyma, that forms the basis of the whole fabric.

While one portion flows to the brain to stimulate the source of the nervous system, other portions are entangled in the peculiarly formed labyrinths of the glands, in the excretory ducts, and the exhaling vessels, forming the various secretions and excretions. The remainder of the blood, impregnated with carbon, and of a dark red colour verging to purple, returns by the veins to undergo the same course.

The blood in the pulmonary artery is prevented returning into the right ventricle by the distention of the three semilunar valves at its mouth; and from the aorta into the left ventricle by the same arrangement. The mitral valve opposes a similar barrier to the blood regurgitating into the left auricle, that the tricuspid valve does between the right ventricle and its corresponding auricle. The mitral, like the tricuspid valve, also assists in preventing the blood, on its entrance into the ventricle, flowing out at the aorta. The mechanism of the tricuspid and mitral valves is such, that when the blood presses on them from behind, they all meet in the centre of the aperture, so as to effectually shut up the passage; and the flaps of the mitral valve even overlap each other. When the auricles act, the columnæ carneæ, and chordæ tendineæ, prevent the membranous valves falling into the auricles; and when the ventricles act, those fleshy columns contract and moderate the distance which the flaps might otherwise have, and prevent them also falling into the auricles.

On opening the thorax of a living animal, the blood is observed to flow from the veins into both the auricles at the same moment of time, so as to distend them; and they are no sooner filled than they contract, and propel the blood into the ventricles, which being also distended, contract by the apex approximating the centre of the cavity, and inject the blood into the arteries. Thus both the auricles and ventricles are filled and emptied, the auricles distending while the ventricles are contracting, and *vice versa;* and the auricles being no sooner emptied, than they are filled again from the veins. When the venæ cavæ and pulmonary veins are emptying themselves, the ventricles are also contracting; and while the auricles are propelling their blood into the ventricles, the pulmonary artery and aorta are at the same time contracting.

The cavity which first ceases to contract, at death, is the left ventricle; secondly, the left auricle; thirdly, the right ventricle; and lastly, the right auricle, which last continues longest to vibrate: hence, when the heart is laid open, very little blood is found in the left side, while it is accumulated on the right side. When the auricles contract, the veins become swollen, which appearance extends even to their ramifications, from the regurgitation or impediment to the flow of the blood which has been thus accumulating in its course onwards to enter the auricles. Thus we observe there are no effective valves at the entrance of the venæ cavæ, in order to allow the blood to regurgitate out of the heart when any impediment occurs. The auricles, from their structure, seem capable of expelling all their contents.

When the cavities of the heart are opened in a living

* Syn. Right sinus venosus. † Syn. Left sinus venosus.

animal, the septum ventriculorum and columnæ carneæ are observed shortening themselves, so as to propel their contents into the arteries; and during relaxation of the different cavities, the sides are in contact, or collapsed, and the heart expands or passes into the diastole, and remains in that state till the blood stimulates it to contract; and after death, the muscular parietes and columns possess little or no elasticity, so that the heart appears to have no power of distending itself; but the auricles become swollen by the blood poured into them by the veins, and the ventricles are distended by the blood propelled into them by the auricles, one and all of them contracting by the blood stimulating their muscular parietes through the medium of the nerves, the same as takes place in the alimentary canal from the stimulus of the food, or, as is evidenced in the lacteal vessels, from the stimulus of the lymph. The naturally collapsed state of the cavities, and their distention solely by the blood, will cause them to contract with more energy, and enable them to expel more completely all the blood; and hence the greater the quantity of the blood circulating in the viscus in a given time, the more forcible are its contractions, as is exemplified in running, or any other active exercise. *

At birth, the heart contracts from 130 to 140 in the minute; at one year old, 120; at two years old, 110; at three years, 90; at seven years, 85; at fifteen years, or puberty, 80; at mature age, from 65 to 75; and in old age, between 60 and 70;—all, however, varying considerably in different individuals. † The cause of a single sensation of a palpitation of the heart, is the contraction of the ventricles, arising from a change of the situation of the apex of the heart striking against the cartilages of the ribs; and at the same moment that the ventricles are contracting, the left auricle is filling, which cavity being placed posteriorly, or dorsad, will strike the vertebræ, so as to assist in producing this sensation. The exterior fibres are seen to curl themselves, the apex is attracted to the base, the heart becomes shorter and blunter, and is bent forwards and to the right, or sternad and dextrad. The curve in the apex of the heart is ascribed to the straightening of the aorta while it is filling. As each ventricle can hold between two and three ounces of blood after death, it is consistently supposed, that this quantity is ejected into the arteries at each time in life; and according to the most unexceptionable calculations, the quantity of blood in the body is estimated at thirty pounds, each pound being twelve ounces. About two ounces of blood, therefore, leave the heart at each contraction; and as there are seventy contractions occurring in the minute, the whole mass of blood circulates about twenty-three times in an hour, or once in two minutes and a half. ‡

The powers of the muscular structure of the heart have been estimated by Borelli, Hales, and Haller, but seemingly in a very defective manner. From the circumstances required to be taken into calculation, it appears to be extremely difficult; these are the area of the heart, the area of the aorta, the quantity of blood propelled, the velocity of the blood, the resistance, &c. all of which can scarcely be ascertained, and even if ascertained in one, there is so much variety in different individuals, that it is probable it would be of little advantage.

To direct the heart in its motions, to afford it liberty, and to prevent friction, the heart is provided with a capsule, named pericardium, the dimensions of which are a little larger than its greatest expansions, and from the surface of both of which a serous fluid is poured out. That the pericardium directs or limits the motions of the heart we are entitled to conclude, from its being found stronger in those animals that have no diaphragm, and also from its adhesion to the diaphragm being only found in man, and some of the simiæ who walk erect. The pericardium is firmly fixed to the diaphragm, which in expiration brings the upper part of it to the level of the fourth rib. The serous fluid, besides the uses already ascribed to it, also prevents adhesion of the heart to the pericardium: this fluid was observed by Spallanzani in living salamanders, so that it does not appear to be the condensation of a halitus after death. When coloured water is injected into the coronary arteries, it transudes by a multiplicity of pores from the surface of the heart, the large blood-vessels, and the pericardium. This fluid of the pericardium is generally about a drachm or teaspoonful in quantity, and is often of a yellowish colour, from bile. The analysis is, water 92, albumen 5, mucus 2, muriate of soda 5-10ths. *

The heart is present in all animals, with the exception of insects and zoophytes. It varies a little in its shape in quadrupeds, birds, and several fishes; in some of the latter it is short and thick, in other fishes it is cylindrical, in others semicircular, while in others again it is long and slender, and in others quadrilateral. In the mollusca, it is sometimes lobed, and sometimes semicircular. In man, we find it conical, and fixed by its large vessels at the right side and base, while its middle, left side, and apex are left free, the latter having an oblique direction to the left side, its flat surface resting on the diaphragm, with the intimate connexion of the pericardium to the latter. No animal which has veins is found destitute of auricles or sinus venosi, but they are absent in those animals whose hearts are long, and which viscus also constitutes the principal artery, and in whom the veins cannot be distinguished from the arteries.

Amphibious animals have the largest auricles, which may assist them in remaining long under water. There are two auricles in those warm-blooded animals that have two ventricles and four great vessels, and that propel the whole blood of the right ventricle through the lungs before it arrives at the left ventricle, as in mammalia and birds. One auricle is found where there is one ventricle, and where only a small portion of the blood runs through the lungs, as in cold-blooded animals, or in those whose blood is a trifle warmer than the circumambient water. One auricle is also only found in oviparous quadrupeds.

The mollusca differ materially in the parts of the heart; all of them have a left or systemic ventricle; many have a dilatation of the venæ cavæ compared to an auricle, and two lateral hearts or ventricles: the heart is sometimes

* These different motions of the heart have been witnessed in cold and warm-blooded animals by a number of experimenters, by Steno, Bartholinus, Peyer, Lewenhoeck, Willis, Caldesi, Harvey, Pecquet, Lancisius, Muraltus, Maitre Jean, Senac, Haller, and Spallanzani.

† These differences of the pulse should be carefully considered by the practitioner, that he may be able to calculate the aberration in disease.

‡ This rapidity of the circulation enables us to explain the quick discharge of fluids by the urine, when diuretics are given.

* Littre details the case of a woman who lived to fifty-four years of age without the pericardium. The heart was dry, rugged, and hard, and had little adipose substance. She is stated never to have enjoyed good health.

lobed, and sometimes semicircular. The seiches have two hearts separated, and the pulmonary is divided into two. The lingules have the systemic heart divided into two. The pectinibranches have two auricles. The acephalous mollusca have either two lateral hearts or ventricles, or one ventricle with one or two auricles; or only a simple systemic ventricle, as the acephalous tuncata. The larger crustacea have two ventricles. Fishes have only one auricle and one ventricle, the latter of which is placed at the commencement of the pulmonary artery. Reptiles have either two auricles and one ventricle, or one auricle and one ventricle.

In the fetus, the heart is larger in proportion than in the adult. It is larger in quadrupeds and birds of a small, than in those of large size. In birds, the heart is found larger than in quadrupeds; and the same relative proportion is stated by Haller to be found in ferocious animals, compared with tame animals; but Hales contradicts this, for he found timorous animals, as deer, asses, and hares, to have larger hearts than courageous ones. Male animals are stated to have larger hearts than females. The heart is smallest in fishes, and smaller in cold-blooded than in warm-blooded fishes. Valisnerus observes, that the columnæ carneæ are most numerous in swift running animals, as the stag or hare.

The heart being supplied with nerves, and being a muscular viscus, possesses the powers of contractility, or those of sensibility and motion, in a marked degree. The heart is sensible to numerous stimuli after death, and the more so the earlier it is experimented on; a drop of saliva, or any acid, or a particle of common salt, excites its contractions; so also does the stroke of a probe, the prick of a needle, the separation of the sides of the thorax, or the blowing of air into the large veins contiguous to the heart. Electricity and galvanism are powerful agents in restoring the motions of the heart after death; as also the inflation of the lungs, and stimuli to the brain.* Experiments on the heart are best elucidated on those animals which have the nervous system much diffused, as in the cold-blooded.

When air, water, vinegar, or a saline solution, is injected into the veins leading to the heart, its action is increased, and the more so according to the stimulus; from which we can account for salt or pungent provisions, or stimulating liquors, exciting an undue action in the heart, independent of their first operation on the nerves of the alimentary canal. Hales observes, that the force of the blood is very different, not only in animals of different species, but also in animals of the same kind, and even in the same animal, where it is continually varying according to the different kinds and quantities of food, the various distances of time after taking food, the more or less plethoric state of the system; also from exercise, rest, different states of vigour or vivacity of mind in the animal, likewise from climate, heat, cold, and evacuations, so as probably never to be exactly the same any two minutes during the whole life of the animal. Dr. Bostock analysed the serum of the blood of a young lady, who had been taking for some time the subcarbonate of soda, to the extent of three ounces daily, and found it much more strongly alkaline than ordinarily.

* In asphyxia these agents, as electricity, galvanism, the resuscitating bellows, stimuli to the head, as hot sinapisms, or pungent salts to the nostrils, should be employed. Stimuli into the stomach also excite the heart's motions.

The exposure of the heart to a moderate degree of cold, or to caloric, increases the number of its contractions; while an intense degree of cold suppresses them by impeding its motions, and a great degree of caloric arrests them by exhausting its motions. Alcohol and opium seem to have a similar mode of operation to caloric; they at first increase, but soon diminish the heart's motions by exhaustion. Opium has a more transient stimulation than alcohol.

Irritation, injury, or even destruction of various parts of the nervous system, generally increase the contractions of the heart for a time, which, however, are frequently very feeble; but compression of the nervous system impedes or suppresses these actions. These are exemplified in phrenitis caused by irritation of blood, and in compression of the brain from matter, water, blood, or depressed bone.* Almost every emotion of the mind influences the actions of the heart; thus this viscus acts more frequently in joy, more quickly and strongly in anger, more slowly and languidly in grief. The happy influence of joy, or mental exhilaration on the heart and general system, is admirably illustrated in the history of the siege of Breda, and in Colonel Stewart's interesting Sketches of the Highland Regiments in the West Indies. These, and other similar facts, prove that the heart is indirectly voluntary. Hales, by his experiments, proves that sighing increases the actions of the heart and arteries, consequently study or anxiety is injurious in pectoral complaints.

The external objects of nature operating on the organs of sense, influence the actions of the heart; thus different scenes in nature produce different effects, placid scenery tranquillizes them, wild picturesque scenery quickens them, and a parterre of roses accelerates them.

Certain sensations are also found to affect the actions of the heart, as various smells. The smell of the white lily has been known to produce immediate fainting, so also that of boiled beans, or that from the snuff of a candle. Pain likewise operates in a similar manner, as a blow on the knee or testis, or a surgical operation. The application of tobacco leaves over the region of the stomach diminishes the action of the heart, so also does this narcotic when administered per rectum. Any substance disturbing the functions of the alimentary canal influences the actions of the heart; thus the gas evolved in the stomach in dyspepsia, by exciting the expanse of the pneumo-gastric nerves, instantaneously produces palpitation and irregular action of the heart. Narcotics passing along the pharynx and œsophagus into the stomach, operate on the nervous expanse of these organs, and thus influence both directly and indirectly the motions of the heart; directly, through the medium of the pneumo-gastric to the heart, and indirectly, through the medium of the brain. The swallowing of ether and laudanum in combination is an excellent illustration. An infusion of tobacco, or the Prussic acid, when swallowed, instantaneously overpowers the nervous system, and then the actions of the heart. The metallic poisons irritate, and then destroy, the nerves of the stomach, and hence influence the actions of the heart. Diseases of the bowels produce, through the medium of the nerves, a quickened action of the heart.

* The experiments of Dr. Wilson Philip, and M. Le Gallois, throw much light on the effects of causes operating on the brain and spinal marrow, and ultimately on the heart; they, in my opinion, satisfactorily establish the most direct chain of connexion between these organs.

Substances, through the medium of the lungs, affect the motions of the heart; thus, the breathing of the fumes of alcohol, or nitrous oxide, increases them, while those of hydro-carbon, or pure carbonic acid gas, diminish them. The actions of the heart can also be influenced through the medium of the skin; thus cold or heat applied to the surface, either accelerates or lessens them, according to the time of duration.* All these effects are produced by these various agents operating through the medium of the nerves.

Besides the quality of the blood stimulating the heart, the quantity circulating in the viscus increases its contractions, and the greater the quantity of blood entering the heart in a given time, the more is the action increased, in consequence of the parietes having a natural tendency to collapse. This is satisfactorily proved in running, or any other active exercise. Such violent voluntary muscular actions at first increase the number and strength of the contractions of the heart, but when long continued, the number increases, although not the strength, the functions of the heart become exhausted, in consequence of the structure being unable to keep up for any length of time this forced action.

The muscular fibres of the heart themselves are sometimes acted on by the venous blood getting access to the coronary arteries, as in asphyxia, which diminishes the sensibility of the heart.

Blood-letting always diminishes the sensibility of the heart, by first removing a portion of the stimulus to the brain; and, secondly, by lessening the quantity of the stimulus to the heart itself. But this does not always occur in proportion to the quantity abstracted, for some faint from the abstraction of a very small quantity, while others are able to bear a large quantity removed; which effect seems to depend on the firmness of the fabric of the individual. Hence fat flabby people faint sooner than lean firm individuals. In the lean constitution, pressure seems to be kept up between the different structures of the system; while in the loose flabby frame, pressure or support is deficient, and thus it resembles the dropsical habit. Bleeding an individual, while in the erect posture, produces fainting sooner than when in the horizontal, and apparently on the same principles. When erect, the blood cannot be propelled so easily or so quickly to the brain; this organ, therefore, deprived of its wonted pressure or support, and also of its stimulus, is unable to perform its functions, and fainting, consequently is the result. But the stimulus of the blood to the brain does not account for this effect so well as pressure or support. The depriving of the organ, therefore, of its support, must be the first effect, which is corroborated by what occurs in paracentesis abdominis for dropsy of that cavity, by what takes place in leaping suddenly out of bed in the morning, or in raising a patient too quickly after fever, or any disease which has confined him long in the horizontal posture. The heart contracts or palpitates more quickly by twelve beats, in the erect than in the horizontal posture; but this varies in different constitutions, particularly in the native of a cold climate, who has resided long in a tropical one. In feeble people it is greater, and in all habits it is greater after eating or drinking, or exercise.

† It is from these effects that cold, warm, and vapour baths prove so valuable remedies in disease; the vapour in cutaneous diseases, the warm in fevers, and the cold for convalescents.

The inflammatory action greatly influences the motions of the heart; hence in inflammation of any degree, the heart always accompanies and constitutes part of the inflammatory fever. Sometimes the quickened action of the heart precedes the appearance of the inflammation, while at other times it follows: in the former, the increased circulation, from whatever cause, so excites the nerves and arteries, that they are unable to return to their wonted quiescence; in the latter, or when the quickened action of the heart follows the inflammation, the heart is excited by the diseased action of the nerves of the part being transmitted along the nerves to the heart.

The quantity of blood circulated by the heart may be increased, or diminished, or be the same as in health, while the motions of this viscus are disturbed. When the quantity is the same as in health, the pulse if more frequent will be feebler, and if slower, will be stronger; in the former, the heart will either never be filled, probably in consequence of increased sensibility, or never be emptied, in consequence of the debility of its muscular powers. The effect of this indicates a derangement in the nervous and muscular systems. If the quantity of blood circulated by the heart be diminished, the arteries will be contracted, until they become only capable of propelling the blood through the capillary vessels, with a proportionally smaller velocity. The veins will become distended, unless the muscular coat of the arteries can be sufficiently relaxed to afford a diminished tension, which is probably the case. In this state, the pulse is small and weak, and the arteries being partly exhausted, there will be a paleness and chilliness of the extremities, which is also partly produced by a derangement of the nervous system; until the blood that is accumulated in the veins has sufficient power to urge the heart to a greater action. A contrary state now arises, the quantity of blood circulated by the heart is increased, and the pulse is full and strong, the arteries continue to propel the blood easily into the veins, until a relaxation of their capillaries takes place, probably to such an extent, that another general derangement of the system is produced. The motion of the blood being accelerated, and the arteries emptied, so that the pulse may be small and weak, while the veins are overcharged, and the heart exhausted by violent and fruitless efforts to restore the equilibrium. When, on the contrary, the capillary vessels are contracted, the arteries are again distended.

From what has been stated in the preceding observations, it will be at once understood, how easily and readily the functions of the heart are deranged, that no disturbance of either the respiratory, the circulating, the alimentary, or the mental functions, or injury to any function or organ, can take place, without influencing or involving more or less the actions of this important organ. The envelope of the heart is subject to inflammation, and some of its terminations, as adhesion and dropsy, also to a peculiar hardened state, and to ossification.

The heart itself is subject to the following diseases:—to inflammation, and some of its terminations, as suppuration, ulceration, and gangrene; to a softened state, or mollescence, to hypertrophia, to atrophia, to aneurism, to rupture of its parietes, to the foramen ovale remaining open, to an aperture in the septum ventriculorum forming a communication between the ventricles, to a conversion into cartilage, and to ossification.

Pericarditis and carditis are the terms given to inflam-

mation of the pericardium and the heart, the former being a much more prevalent disease than the latter, and generally occurring in the rheumatic constitution, being frequently combined with pleuritis or pneumonia, and being with difficulty distinguished from the latter. The morbid appearances seen in pericarditis, are a layer of coagulable lymph on the interior surface of the pericardium, and also on the surface of the heart, occasionally so abundant, as to fill up the space between them, forming a delicate bond of adhesion. The exterior or pleural surface also sometimes displays marks of inflammation, in which case the affection is complicated with disease of the pleura. Instead of so great a quantity of lymph being deposited, there is at other times a more or less quantity of serum effused, which is occasionally tinged with blood. The symptoms of this disease are, acute pain in the region of the heart, aggravated on motion or on inspiration; violent palpitation of the heart, but small regular pulse, rendered irregular on motion; irregular, anxious respiration, slight cough, and a tendency to syncope on moving. There is also an anxious expression of countenance. The treatment consists in repeated bleedings, the application of blisters in the cardiac region, large doses of Hyosciamus and digitalis, brisk cathartics, enemata, rest, and low diet. There are two varieties of this as of most other diseases, namely, the acute, and the chronic, the latter of which is very ill defined in its symptoms.

When pericarditis does not prove fatal, it ends either in an abatement or resolution of the disease, in adhesion of the pericardium to the heart, or in effusion of serum constituting dropsy: when adhesion is the result, the morbid appearance is a greater or less extent of union, through the medium of coagulable lymph, between the pericardium and the heart, which is sometimes so extensive and connected, as to cause many believe that no pericardium existed, this membrane requiring to be patiently dissected off from the heart. The symptoms characteristic of this disease in life, are, a painful sensation of pulling or tugging in the region of the heart, respiration rendered laborious and frequent on the slightest motion, sudden flushings of the countenance, irregular pulse, particularly on moving, and syncope often occurring. There is no palpitation of the heart.

In dropsy of the pericardium, the serous effusion varies from seven ounces to eight pounds, and when it accumulates to this quantity, such pressure is made on the heart, large blood-vessels, and lungs, as to prove fatal. The colour of the fluid is more or less green, and quite transparent. The pericardium is always thickened, and has been found hardened like a dried bladder. The symptoms of this affection are, an oppressive weight in the region of the heart, occasionally attended with palpitations; difficulty of breathing, threatening suffocation in the horizontal posture, a painful anxiety, and frequent syncope; obscure and tumultuous pulsations felt over the region of the heart, and in different parts of the thorax, according to the quantity effused; when the patient stoops forward and inclines rather to the left side, an obscure pulsation felt low down or sacrad in the thoracic cavity, and a more forcible beat in the region of the heart; the pulse small, feeble, frequent, and sometimes irregular; and the face of a bloated violet colour, with blackish livid lips. The treatment consists in giving diuretics or cathartics, as in other dropsical affections, and if the constitution is capable of bearing it, the catharsis ought to be carried as far as possible, as the cure of dropsy is to be accomplished more by this excitement, which rouses the absorbents to greater action, than by diuresis. Riolanus recommends puncturing the pericardium in this dropsical affection, in which he is supported by Senac, and by Dessault, who performed what he conceived to be this operation; but after death, the effusion was found collected in a sac formed by the left lungs and the pericardium. It was done within these few years in Nottingham, but without success.

The pericardium has been found distended and hardened like a dried bullock's bladder, and also ossified in one part to a considerable extent.

Carditis, we have already observed, is with difficulty distinguished from pericarditis in the living, but with ease in the dead state: in the latter, the appearances are, an inflamed state of the pericardium, with more or less of a yellowish purulent matter; a deposition of lymph on the surface of the heart, the muscular structure of which is pale, flabby, and soft, being easily torn and separated into layers, in consequence of depositions of purulent matter in the cellular tissue; the blood-vessels enlarged, increased in their branches, and covered with pus; and the cavities filled with coagulable lymph, which extends even into the great vessels. The symptoms of this disease are merely an aggravation of those of pericarditis; and the treatment must consequently be the same, with a similar modification to answer the greater evil. The best marked cases of carditis which I have witnessed, have followed inflammation of a vein from blood-letting, and the throwing a ligature round a wounded vein, as, for instance, the axillary.

Carditis generally terminates in suppuration, the morbid appearances of which have been described. There are also instances where the pus has been confined to an abscess in the fleshy parietes of one of the cavities, and also in the cavities themselves. This state, we may presume to say, must always prove immediately fatal, so that if the treatment of the inflammatory stage prove ineffectual, there will be no symptoms of the suppurative stage except rigors, and no treatment required. Chronic inflammation of the heart sometimes ends in ulceration, which has been known to go on until the parietes have been eaten through, and then proves fatal by effusion of the blood.* If inflammation of the heart, before it ends in suppuration, proves fatal, this eventful result must occur before gangrene can take place. Storck, however, and Leroux, in Corvisart, detail cases of this termination having been visible, while Corvisart seems to doubt it.

In acute fever the heart is more or less affected, sometimes to the extent of being rendered softer and of a deep red colour, the latter, however, occasionally approaching to brown, and the muscular structure breaking down under the fingers. In patients who have fallen victims to typhus or hectic fever, the heart has been found equally soft and of a white or jaundiced yellow colour. Those who recover from such diseases are naturally very liable to be affected with aneurism of the heart, and hence the great care requisite to be bestowed in recruiting the strength of patients after fever. These softened states of the heart are occasionally the result of idiopathic affections, in which case the one resembles in its symptoms pericarditis or carditis, and the other chronic inflammation.

Chronic inflammation of the heart is extremely difficult

* See Morgagni and Marchettis.

of being ascertained before death, in consequence of the symptoms being generally referred to a distant part. Dropsy is a common concomitant, so also is cough, and more or less uneasiness or wandering pains in the thoracic cavity, accompanied with difficult and laborious breathing; but in some cases, the head is the chief part complained of, in others, the urinary bladder, in others again, dropsy of the abdomen, while in some others the uterine organs are affected. The pulse is generally small, weak, irregular, and sometimes intermitting. On applying the ear or stethescope over the region of the heart, this viscus will be found to be acting irregularly. The morbid appearances are, fewer or more adhesions between the pericardium and the heart, with occasionally coagulable lymph, and even pus, and more or less softness and paleness of the heart. The treatment consists in early small bleedings, in the repeated application of blisters or issues to the sternum, and in cathartics.

Chronic inflammation is frequently accompanied with dilatation of the heart, rendering the disease very complicated. The dilatation appears to go on with rapidity, is accompanied with fever, and an acute pain is felt sometimes in the epigastric, at others in the hypogastric region. The pulse is frequent, irregular, and jarring.

White spots are frequently found on the surface of the heart, similar to those on the surface of the liver, which appear to consist of depositions of coagulable lymph, but cannot be traced to any local inflammation, however trifling.

Hypertrophia * is a thickening of the parietes of the heart without dilatation, † the left ventricle being the cavity generally affected, and is characterized by the following symptoms: a confusion and struggling in the thoracic cavity, the palpitation being communicated to the region of the left clavicle, and when the ear is applied over the heart, it feels as it were repulsed by its pulsations. When the region of the heart is percussed, there is a dull obscure sound. When the stethescope is used, the pulsations appear very loud and strong, and can in some instances be heard at the back of the patient. There is an inexpressible anxiety and inquietude about the heart, together with a weak, irregular, fluttering, or vibrating pulse. The patient constantly apprehends instantaneous dissolution. Persons labouring under hypertrophy are often very fat. The treatment of this malady consists in small bleedings, issues to the sternum, active purges, low diet, reduction particularly of fluids, and quietness.

Hypertrophy is sometimes accompanied with dilatation or aneurism, ‡ in which case the pulse is strong, full, and vibrating; at other times with contraction of the cavity, § in which case the pulse is generally regular, full, and strong, but occasionally feeble. Hypertrophy of the right ventricle is distiuguished by the pulsations of the heart being felt at the inferior or sacral aspect of the sternum, and towards the right side, by bloody expectoration. That of the left ventricle, by the pulsations being felt between the fifth and sixth ribs of the left side, by the countenance being flushed of a vermilion tinge, by bleedings of the nose, by deafness and headache.

The heart is also subject to atrophy, or wasting of its muscular substance, which is frequently accompanied with general constitutional debility, particularly phthysis pulmonalis, and in these cases the pulse is small and frequent. The practitioner has to watch the pulmonary complaint, to prescribe moderate light diet, and to apply blisters to the sternum.

Aneurism of the heart consists in a dilatation of one or more of its cavities, that of the left ventricle being the most common when there is thickness of the parietes, while that of the right ventricle where the parietes are thin, and again that of all the cavities, is the most rare.

In some cases of aneurism, only one ventricle is affected, while in others only one auricle, the left auricle being the one most seldom affected. In aneurism of the right auricle, the tricuspid valve is so diseased by cartilaginous or osseous depositions, as to contract the aperture between the right auricle and right ventricle; in aneurism of the right ventricle, there is generally such a state of diseased lungs as to obstruct the circulation of the pulmonary artery, the semilunar valves of which vessel are rarely affected. In aneurism of the left auricle, the mitral valve is either cartilaginous or osseous, or both; and in aneurism of the left ventricle, the semilunar valves of the aorta are either cartilaginous or osseous. Although the preceding appearances are generally discovered in these various species of aneurism, and may be said to produce them, yet we occasionally find the cause very remote; thus a distorted course of the aorta from curved spine, has been found to produce aneurism of the right auricle and ventricle, particularly that of the former; so also has a contraction of the orifice of the aorta, and of the mitral valve. This dilatation is sometimes accompanied with hypertrophy of the parietes of the cavities.

Aneurism of either cavity, or all the cavities, with thickness or thinness of the parietes, is indicated in its commencement by pains in the region of the heart, palpitations, cough, and oppression of breathing, the latter of which is also short and high: the pulse at this period is little or at all affected. There is a feeling of hot flushings arising from the thorax to the face, which are very transient; the appetite is keen, and the digestion good, but attended with constipation. The patient is easily fatigued, and an oppressive breathlessness follows, which occurs most frequently on walking up a hill or up stairs. After the preceding symptoms have lasted for a few weeks, the palpitations become stronger and more frequent; the pulse is hard, vibrating, frequent, and sometimes contracted, when there is increased thickness of the parietes of the cavities; while it is soft, tolerably frequent, feeble, and easily compressed when there is simply dilatation; the respiration is now extremely difficult, and the patient is compelled to sit and bend the body forwards, resting the chest on the knees, for he cannot breathe in a horizontal posture; the cough is hard and frequent, and there is expectoration of viscid matter occasionally tinged with blood, the latter of which is somtimes spit up in a pure state. He feels a numbness which is sometimes followed by syncope, a constriction about the throat like the globus hystericus, and passes restless nights, being disturbed with frightful dreams. The appetite is still good, but the food excites pain and frequently vomiting, and the bowels become rather relaxed. The abdomen assumes the appearance of approaching ascites, the whole surface of the body looks pale and flaccid, but the face is bloated, the lips being of a violet colour. These symptoms are soon succeeded with more alarming ones, the pulsations of the heart are scarcely perceptible, and when felt are very

* Syn. L'irritation nutritive du cœur.
† Syn. L'hypertrophie simple.
‡ Syn. L'hypertrophie excentrique. L'aneurisme actif.
§ Syn. L'hypertrophie concentrique.

quick; the pulse is small, frequent, unequal, intermitting, and hardly perceptible; the veins in the neck are swollen; the respiration is extremely difficult, suffocation being threatened every moment; there is a dry convulsive cough, with viscid bloody expectoration, or pure coagulated blood; the expectoration is occasionally, however, purulent. There is great debility, and anxiety, and no hope of sleep, the patient being instantly awakened with delirium; the appetite is gone, and the stools are watery and frequent; there is universal anasarca, and ascites; and the patient either dies insensibly or in convulsions.

It will be readily acknowledged, that it must be exceedingly difficult to ascertain which cavity of the heart is affected with aneurism. Wherever there are the usual symptoms of aneurism of the heart, accompanied with expectoration of blood, a greater degree of breathlessness, more frequent faintings, a serous diathesis, the countenance of a violet colour, approaching to black, with fluctuation of the jugular veins, we may infer that the right cavities are those affected, all of which appearances are easily accounted for on the connexion subsisting between the right side of the heart and the lungs, and this side and the veins of the face and neck. When the left ventricle is aneurismal, the face is suffused with a lively deep red, and the pulse is more affected. But when the disease is well advanced, whatever be the species of aneurism, there is a general bloatedness of the countenance.

In simple dilatation, or aneurism of all the cavities, without either increase or diminution of the parietes, there is an oppression in the thoracic cavity, with the feeling of occasional suffocation; the pulse is full, slow, and soft, and the heart can be felt to contract sluggishly and equally in the thorax. These are generally attended with dropsical and dyspeptic symptoms. This affection is liable to be followed with chronic inflammation of the heart, or dropsy of the pericardium. In aneurism with hypertrophy of all the cavities, there is also oppression in the thorax, the pulse is strong, full, regular, and frequent, the heart pulsates hurriedly and violently, and the countenance is of a violet colour and somewhat livid. In both of these affections, rest, with abstemious diet, repeated small bleedings, issues in the region of the heart, and attention to the bowels, are all that can be done.

Aneurism of the heart is occasionally accompanied with enlargement of the aorta, and sometimes but rarely with a contracted state of this vessel; in the former case, the symptoms are nearly the same as when the aorta is about its natural size; but in the latter or contracted state of the aorta, there is difficulty of breathing, a tendency to fainting, with an unequal pulse, accompanying the symptoms already enumerated. Towards the termination of the disease, a pain is felt in the region of the diaphragm, accompanied with cough, a languid frequent pulse, and vomiting.

The treatment of aneurism is the same as that for hypertrophy, with which it is often complicated.

A few rare cases have occurred, where there has been found in the parietes of one of the ventricles of the heart, a dilated pouch, lined with strata of coagulated blood, so as to resemble aneurism of an artery, the symptoms and treatment of which are the same as for the preceding kind of aneurism. The parietes of the heart sometimes rupture, without any previous disease, the ventricles being more subject to it than the auricles, and the left more than the right ventricle. This arises from some violent exertion, a fit of passion, an epileptic paroxysm, or in *actu coitus*. This occurs, however, oftener in diseased states of the heart, as aneurism, ulceration, softening of the fleshy parietes, and violent contusions. Sometimes there is only a rupture or laceration of some of the columnæ carneæ of the ventricles, a case of which is detailed by Corvisart, where one of the large columnæ which form the mitral valve was lacerated from its base, so as to float loosely in the left ventricle.

An aperture being found in the septum ventriculorum, or the foramen ovale remaining pervious, is far from being an uncommon occurrence. Caillot mentions the case of a child eleven years old, where the foramen ovale remained open, and where there was also an aperture in the septum ventriculorum large enough to admit the fingers. In this affection, which is termed the blue disease, from the face having a bluish tint, the patient has difficulty of breathing, frequent fainting, convulsive motions, and diminution of vital heat.

The heart has been, in some instances, converted into cartilage, and even ossified to a great extent; Bordenave mentions one case where the heart was almost entirely ossified; Haller details a case where the inferior part of the right ventricle, the valves of the pulmonary artery, the aorta, and the more fleshy parts of the left auricle were ossified; Burns found both the ventricles mere calcareous moulds; Albertini observed the right auricle ossified; Renauldin, in the "*Journal de Medecine*" for January 1806, relates a case, where he found the heart extremely hard and weighty, the left ventricle appeared changed into a real petrifaction, presenting in some places a gravelly appearance, and in others that of a saline crystallization, the columnæ carneæ being enlarged, and resembling real stalactites. The symptoms of this derangement of structure, are strong and frequent palpitations of the heart on the slightest motion: the pulse, regular and full in the beginning of the disease, becomes gradually more feeble and intermitting, the breathing is extremely difficult, and attacks rather in paroxysms, obliging the individual to remain constantly in the semi-erect position, and there is great anxiety, much nausea, with frequent vomiting towards the conclusion of the disease. The patient is also occasionally tormented with pains in the abdomen and lower extremities, and there is more or less dropsical effusion.

As previously mentioned, the valvular structure is very subject to ossification; the semilunar valves of the aorta are most frequently affected; next to them the mitral valve; thirdly, the tricuspid; and lastly, the semilunar valves of the pulmonary artery. The semilunar valves of the aorta are sometimes so indurated as to remain touching each other, thus leaving the smallest aperture for the transmission of the blood; and the mitral valve, with its chordæ tendineæ and columnæ carneæ, have been found forming one continued osseous body, only permitting the smallest aperture possible between the auricle and ventricle. In those cases where the semilunar valves of the aorta are affected, the neighbouring portion of the artery is also involved. These states of the valves, as formerly mentioned, are almost always accompanied with aneurism of one or more cavities, so that the symptoms and treatment are the same. Besides these ossified conditions of the valves, they are often affected with a sort of fungous or warty excrescences, resembling cauliflower buds, complicated with other affections of the heart. When the semilunar valves of the aorta are ossified, strong and frequent palpitations take place, the pulse is irregular,

undulating, rustling, obscurely trembling, and is often augmented by the force and frequency of the palpitations, the left ventricle being easily filled, but with difficulty emptied.

Polypus in the cavities of the heart seems a very rare disease, for the coagula found in the cavities, and entangled among the valves, are evidently merely the coagulable lymph of the blood after death. Polypus is to be distinguished from these by possessing a more uniform structure, and being free of any red globules. The symptoms of this affection during life, are irregular action of the heart, irregular pulse, and difficulty of breathing; and they frequently resemble so nearly those of aneurism, as to be with difficulty distinguished. The treatment is almost the same.

Cancer, a tuberculated state, serous cysts, and vesicular worms, are described by a few authors to be found present in the heart. Cancer is peculiar to glandular structure, therefore its existence appears doubtful in muscular texture, unless soft cancer or medullary sarcoma is meant. Tubercles and serous cysts may exist, but it appears very doubtful if worms are ever present. Serous cysts are not uncommon.

The coronary arteries and vein are subject to the same diseases as blood-vessels in general; but ossification of the arteries, and a varicose state of the vein, may be considered the chief and most common affections which attack these vessels. The coronary arteries are sometimes so ossified, as scarcely to transmit enough of blood to nourish the muscular structure of the heart, one of them being obliterated, in which case the heart is unable to propel the blood freely and entirely out of its cavities, thus disposing it to hypertrophy, and even aneurism. The muscular structure of the heart appears pale and flabby in such cases, and is easily torn with the fingers. The symptoms are occasional palpitations, induced by passion, or by making any undue exertion, as ascending a hill or stairs; irregular pulse, sometimes full and strong, at other times weak and intermitting; violent pain in the region of the heart darting along the arms, even to the fingers, accompanied with difficulty of breathing, and a sense of suffocation when the paroxysm is severe. The patient cannot stretch himself so horizontally as in health. The treatment consists in avoiding every undue exertion, in abstracting small quantities of blood at intervals, in keeping the bowels gently open, and living on moderate diet. A varicose state of the coronary vein not unfrequently accompanies hypertrophy, or aneurism of one or more of the cavities of the heart.

Malformation of the heart, and of the origin of the large vessels from it, is far from being an uncommon occurrence.

In the beginning of these physiological observations, the blood is stated to have two courses from the heart, the one by the pulmonary artery through the lungs, the other by the aorta, throughout the whole system. That which is circulated by the pulmonary artery through the lungs is named the lesser circulation, and when present in the animal, constitutes the double circulation: I shall defer the consideration of this, till I have explained the greater circulation, or that performed by the aorta. All animals, excepting some insects and zoophytes, have arteries.

The aorta, consisting of its three tunics,* proceeds to the different extremities of the body, dividing, at different angles in its course, into innumerable branches, according to the organs which these are destined to supply. These branches or arteries branch off sometimes at an acute angle, sometimes at a right angle, and at other times at an obtuse angle: the majority being at an acute angle. Organs which are destined to perform their functions rapidly, as the heart, have their arteries branching off at an acute angle, while those that are designed to do their office slowly, as the testis, have their arteries branching off at an obtuse angle. The velocity of the blood is greater, the more acute the angle of ramification is, and the less flexuous the artery is in its course,* also the less that arteries anastomose in the common manner; but the reverse, when they anastomose like the vertebral arteries, to form the basilar artery on the basis of the brain. By this union of the vertebrals, the velocity of the blood is augmented, and apparently to prevent congestion or pressure. In the frog's foot, two currents are observed sometimes to meet in the middle, and hence lose a corresponding momentum, which anastomosis appears designed to prevent congestion, and to afford a freer communication between one part and another. The blood flows with less velocity in the branches than in the trunks of arteries, in consequence of the increasing area of the branches, compared with the trunk, the greater friction as it proceeds onwards, and the impinging against the angles of the ramifications; and with less velocity the nearer the angle is to an obtuse angle.

In the living body, when an artery is exposed, it is always seen filled with blood, and if punctured, the blood flows in an interrupted stream. But although the arteries thus appear already filled, yet at every contraction of the heart they receive a fresh quantity of blood, from two to three ounces being propelled at each contraction of the systemic ventricle. When we press an artery between the fingers, that part of the vessel next, or proximad the heart, becomes turgid, while that distad or most remote, is emptied and flaccid: but on removing the fingers, the blood rushes into the empty vessel. The course of the blood is beautifully seen by placing the web-foot of the frog, or the tail of a fish, or the punctum saliens of an incubated egg, in the focus of the microscope. An artery, when laid bare, is never found collapsed or corrugated, but

* In the opinion that the arteries consist of three coats, at least that they possess a muscular tunic, I am supported by Willis, Bidloo, Lancisius, Nicholls, Ludwic, Haller, Cuvier, Sir Everard Home, Dr. Young, Dr. W. Phillip, and Dr. Hastings. The cellular tunic is found to be proportionally greater in the larger than the smaller arteries, while the latter again exceed the former, in the proportion of their muscular tunic; the larger are therefore more elastic, while the smaller arteries are more muscular. Besides these three tunics, some arteries have an adventitious coat, thus the aorta within the cavity of the pericardium has the serous coat of the heart; without the cavity of the pericardium, some parts of the arch, and all the descending thoracic aorta, have the pleura, excepting that portion which adheres to the vertebræ. The abdominal aorta, and its division into the iliacs, are also similarly covered by the peritoneum. In the neck, the superior and inferior extremities, the arteries are enveloped, together with their accompanying veins, with a strong cellular sheath; the sheath in some places, as in the trunk of the external carotid and the popliteal arteries, being more delicate.

* Some arteries are very flexuous, as the coronary arteries of the lips, the arteries of the uterus, those of the testis, those of the large intestines, of the iris, the umbilical cord, the spleen, tongue, stomach, and also the bronchial, carotid, and vertebral arteries. In some of the lower animals, there are other arteries extremely flexuous; thus the sloths have the axillary and iliac arteries dividing into a number of equally sized cylinders, which are very tortuous, and occasionally anastomose with each other. The arteries, when empty, are almost straight, but become flexuous when distended with blood.

appears like a tense cord, thus resembling the collapse of the ventricles of the heart. Every fresh quantity of blood propelled into the aorta, gives an increased velocity to the blood in all the arteries of the body, which impulse is observed to occur at a period later, according to the distance of the artery from the heart. During the circulation, there is a dilatation of the arterial tube every where, in consequence of this regular increased quantity of blood from the heart, and this is greater in some arteries than in others; more so in those nearer the heart, than in those more distant. It is this which gives the sensation of pulsation felt by the finger. There is also a lateral dilatation or diastole of an artery, which dilating power gradually ceases from exposure to the air, the coats contracting and at last stopping the flow of blood. This dilatation does not take place in all the vessels at the same moment of time, as is verified at the neck, temple, and wrist; appearing later the greater the distance from the heart. After this partial dilatation, the artery returns to its former state, which constitutes the systole of the artery. Hence the arteries perform a diastole or dilatation, and a systole or contraction, the same as the heart. From what appears by the artery of an amputated stump, jutting forward at every contraction of the ventricles, or by the artery when tied in aneurism, an artery is supposed to be elongated from the systole or contraction of the heart. This, however only occurs when the artery is much insulated, so as to render the extreme point one of resistance, and to act as an obstacle to the flow of the blood; for this appearance is not evident when a small portion of an artery is laid bare.

The general cause of increased velocity is owing to the increased impulse given by the quantity of blood propelled into the arteries, which is exemplified in hydraulicks. The pulse is caused by the blood thrown into the aorta impelling all the rest of the fluid before it into the arteries, the same effect occurring with water in a leathern tube of a fire-engine, at each stroke of the double pump, and the parabola of the jet being thereby increased. This dilatation is satisfactorily accounted for, on the principle of the arteries being elastic tubes, and possessing greater elasticity in the longitudinal than in the transverse direction. The heart forces more blood into the arteries than it can give out at opposite extremities, therefore the arteries must dilate to make room for the increased quantity of blood; and the quicker the impelling power, the greater will be the dilatation. When the arteries again contract, their elasticity keeps up the flow of blood, till a new impulse is given by the heart, which results from these vessels tending to return to their former collapsed state, like the ventricles of the heart.

These two powers, the action of the heart, and the elasticity of the arteries, seem alone capable of carrying on the circulation; on the same principles as the fire-engine, where the impulse is given by working the pump, and continued by it and the elasticity of the tubes. But the arteries possess muscular contraction; they are capable of being stimulated, so as to evidence sensibility and motion. That they possess muscular fibres, may be demonstrated on the middle-sized arteries of man, and many other animals. This muscular tunic, I have already observed, is allowed by Willis, Bidloo, Lancisius, Nicholls, Ludwig, Haller, Sir E. Home, Drs. Young, W. Philip, and Hastings. Haller and Spallanzani found the circulation carried on for some minutes in many cold-blooded animals, in fishes, and in the incubated egg, after the destruction of the heart. In fishes, the blood describes three circles in the liver; and in all other parts, excepting the gills, it describes two circles, before returning to the heart. In cold-blooded animals, the circulation continues in the capillary arteries, after the heart no longer propels the blood.* In insects and zoophytes, where no heart exists, the vessels analogous to arteries circulate their fluids. In all the worms having red blood, and which have no hearts, the systole and diastole of the arteries is well marked. In the lumbricus terrestris, where there is no heart, the blood is solely propelled by the muscularity of the arteries. The lumbricus marinus has no ventricle, the blood being propelled by the blood-vessels of the organs of aeration; and in human monsters where no heart is present, the blood is propelled by the arteries.† When the aortic valves are ossified, the heart contracts sometimes twice for each pulsation of the arteries. Bordenave found the heart in one instance almost completely ossified; Burns found the ventricles mere calcareous moulds, and Renauldin found the left ventricle converted into a real petrifaction, the columnæ carneæ resembling stalactites. These physiologists also found that the circulation in the arteries varied in different parts of the system in many animals, as the palate, lungs, and mesentery. Haller found that the arteries circulated their fluid in a retrograde direction, when cold, fright, inflammation, or wounds occurred, which fact is corroborated by the experiments of Lewenhoeck and Spallanzani. Spallanzani found that the blood flowed in a retrograde direction along the aorta to the heart, when an incision was made into the latter, although the animal, a salamander, was placed perpendicularly, and hence the blood had to ascend. In the same animal he observed that the action of the heart and aorta was seldom synchronous. He found that the velocity of the circulation in the trunk of the pulmonary artery, compared with that in the ultimate branches, was as three to one; while he perceived no difference between the velocity of the blood, in the small vessels on the surface of the gall-bladder, and that in the large arteries. He observed that the large and middle-sized arteries propel the blood during the diastole of the heart. Haller, in his observations on the motion of the heart, says, "Is motus totus in contractione ponitur, qua eadem communis omnium musculorum functio absolvitur;" which, in my opinion, is equally applicable to the arteries. That the arteries possess sensibility, is proved by their being plentifully supplied with nerves, and consequently capable of being excited by stimuli, of which the blood is their natural stimulus.‡ In many cases of paralytic limbs, no pulse has been felt,§ shewing that the arteries, when deprived of their nervous influence, cannot contract to circulate their fluids, and that the heart alone is unable to perform the function of circulation. Sir Everard Home proves from his experiments, that the arteries, like other parts of the body, are totally dependent on the nerves for their capability to perform contractile

* Bichat, Recherches Phys. sur la Vie et la Mort.

† See Memoires de l'Academie des Sciences, 1720, par Mery; Memoires de l'Academie des Sciences, 1740, par Winslow; Com. Soc. R. Sc. Gotting. tom. 4, com. 4, Roederer; Trans. Roy. Soc. Edin. vol. 3, Monro; Phil. Transact. 1793, Clarke; Phil. Transact. 1767, Le Cat; Medico-Ch. Transact. vol. 1, Young; Phil. Transact. 1809, Brodie.

‡ The only exceptions to this are the umbilical and placentary arteries; both of which have lately been discovered to possess nerves, by that indefatigable physiologist, Sir Everard Home. Phil. Trans. for 1825, Part I.

§ See Storer in Trans. Soc. Med. Chir. Know. vol. iii.

motion, and hence, that the nerves which accompany the arteries regulate their actions.* That they possess muscular contraction, is proved by their having a muscular tunic; and where muscular fibres exist, they must be capable of action, because if we deny this in one place, we are equally entitled to do it in another. That they evidence sensibility and muscular contraction, is established not only by what I have already advanced, and the numerous other experiments performed by these physiologists and others, but by what may be observed in the face, arms, neck, and breast of the female in blushing, by the local determination of blood in suffusion of the eyes from sand, and by erection of the penis, either from direct irritation, or from the idea of a voluptuous woman in the mind. These latter actions take place in an instant of time, and they cannot be explained on the elasticity of the arteries, or the action of the heart, for the latter in many cases is not increased in its motions. The arteries in these actions must suddenly act, which can only be effected by muscular action. Besides these, there is the state of the arteries in the heads of those animals which shed their horns; the state of the uterine vessels during gestation; the state of the arteries in the secretion of milk, and the growth of tumours; and the state of the arteries leading to inflamed parts, as the carotid of the affected side in cynanche tonsillaris.

The middle coat of the arteries being muscular, enables us to comprehend how these fibres will assist the action of the heart, and the elasticity of the arteries, and thus render the extreme branches of these vessels less dependent on the heart; for at no period, and in no part of the arterial system, do we find all the fibres either in action, or in a state of relaxation, but some active in one quarter, and others relaxed in another. It is only in this way that we can satisfy ourselves respecting the sudden actions of insulated portions of the arterial system, and account for the occurrence of all those topical congestions and local palenesses: hence the velocity of the blood in some arteries is greater than in others. The arteries, besides nervous filaments, have lymphatics, and numerous vasa vasorum, or very small arteries and veins, on their tunics, two essential agents in muscular motion.

I formerly remarked that the arteries divided at different angles into numerous branches, which again subdivide into smaller arteries, named capillaries, the majority of which terminate in the veins; some, however, join the veins at an earlier period. This termination of the capillary arteries in veins, can be demonstrated on the pia mater of the human brain, on the tail of a fish, on the web-foot of the frog, and the gills of the salamander and frog. Not only in these, but in other animals, this termination or junction of arteries in veins, has been witnessed by many physiologists, among whom may be mentioned Harvey, Lewenhoeck, Bernouilli, Cowper, Malpighi, Hales, Haller, and Spallanzani.

A second termination of the capillary arteries is into exhalants. These either open into some cavity, as the ventricles of the brain, the nostrils, bag of the pleura, pericardium, mouth, stomach, intestines, gall-bladder, urinary bladder, uterus, vagina, pouch of the peritoneum, and tunica vaginalis testis; or the exhalation takes place in the skin, eye-lids, and tunica conjunctiva of the eye, and sometimes into tubes and true glands; or these vessels terminate by pores or very short channels or canals, as illustrated in the little cells of the cellular tissue, or in the aerial tubes of the lungs. Almost all the membranes of the body secrete an exhalation, as the dura mater, the pia mater, the pleura, pericardium, peritoneum, &c. The simple experiment of Haller, the insertion of an injecting pipe into one of the venæ cavæ, and the propelling of a coloured liquor, which flows into the heart and pulmonary artery, and escapes at the trachea, illustrates this kind of secretion. Another species of exhalation is by lacunæ and true glands.

A third termination of the capillary arteries is in excretory ducts, which carry a fluid different from the blood, and do not return it to the heart. Some carry their fluids into the aerial tubes of the lungs, some into the stomach, others into the kidneys, and others again out at the skin. Neither Lewenhoeck, nor any one else, excepting Bertin, has witnessed the arteries becoming excretory ducts. It is easy, however, by injecting water into the renal artery, to make it flow into the ureter.

The capillary arteries have been also found to communicate with the lymphatics, as described by Caspar Bartholinus, Borrichius, Nuck, Cowper, Walther, and Haller. These terminations and communications of the arteries have been particularly considered under secretion and absorption.

Arteries convey differently-coloured blood, not only in different animals, but even in the same animal; some insects, as the grasshopper, circulate green blood; some crustaceous animals, as the lobster, circulate white blood, while the vertebral animals circulate red blood. In man, and many animals, the small arteries of the crystalline lens, vitreous humour, and tunica conjunctiva and cornea of the eye, circulate colourless blood. Haller and Spallanzani talk of the red and yellow artery, the latter being merely a continuation of the former, and consequently smaller, and therefore containing less red blood, or having this colour less concentrated.

Arteries pervade every structure of the body, excepting the tunica arachnoidea of the brain and spinal cord, the epidermis, the nails, the hairs with the exception of their bulbous roots, and the membranes of the umbilical cord. It is presumptive, however, that both in the arachnoid coat, and in the membranes of the umbilical cord, arteries are present, but that they convey colourless blood, for these become inflamed, and undergo other diseased changes.

The arteries anastomose with each other from the crown of the head to the sole of the foot, and particularly about the joints,* but only with their small branches, excepting the vertebrals, which unite to form the basilar artery.

The various causes and agents which we have mentioned as influencing the heart, must also operate on the arteries, from the one being as it were a continuation of the other. The regular as well as the irregular actions of the heart are all indicated either by the motion of this organ felt immediately over its situation, or by the motion of the blood in one of the arteries, as at the wrist or temple, which motion is termed the pulse. This, when regular, beats the same as the heart, a scale of which from birth to old age is given in page 225, and should be well committed to memory. Although that scale may be considered as a standard to regulate generally our con-

* Phil. Trans. 1814.

* The free inosculation of arteries should be considered by the operating surgeon in aneurism.

duct, yet the pulse varies exceedingly in different individuals in health. In some persons at middle life the pulse is seldom higher than 40 in the sitting posture, while in others it is never below 96 or even 106; for it varies much according to our position. I am acquainted with a gentleman who enjoys good health, and who has been many years in a tropical climate, whose pulse while in bed in the morning is 90, but whenever he gets up, it rises to 120; and after breakfast it mounts to 140. Dr. Fordyce mentions the case of an old man whose pulse was naturally only 26 in the minute; and a patient in Guy's Hospital about sixty-five years of age had a pulse of only 16 in a minute: such is the discrepancy in the pulse.

The pulse, during any irregular action, as palpitation of the heart, is always increased in number. The pulse varies in size or fullness, according as the distension or diastole is greater in both the heart and arteries, which fullness or largeness is judged of by the impression conveyed to our fingers. It also varies in the time which is employed in the distension or diastole of the artery. When this takes place quickly, it is termed a strong pulse; and when slowly or gradually, a weak pulse. The pulse also varies in point of regularity, the intervals between the pulsations differing in length, which irregular pulse is divided into unequal and intermitting. It is said to be unequal, when for a number of pulsations the pulse beats quickly, and after a while, more slowly for another number of pulsations, forming a regular series, although neither of the series continue the same length of time. The pulse is named intermitting, when it beats in regular succession, but stops or intermits at times, one, two, three, or more pulsations. These two latter, the unequal and intermitting, are occasionally combined, nay all of these varieties are sometimes variously combined.

The quick pulse may depend on increased sensibility and motion of the heart, from any cause that increases the frequency of the contractions of the heart. It may also depend on the stimulant power of the blood; and likewise on an increase of the velocity of the flow of the blood in the veins.

The slow pulse is caused by moderate diminution of the sensibility and motion of the heart, by diminution of the stimulant power of blood, and by less velocity in the flow of the blood in the veins.

As the arteries themselves possess a structure similar to the heart, evidence similar phenomena, and are capable of being influenced by the same causes, they must assist in producing these effects, or, in other words, they must aid in rendering the pulse quicker or slower.

The varieties in fullness of the pulse is caused by a greater quantity of blood being present in the artery when distended, which may be produced by an increase in the quantity of the blood sent from the heart, or by a greater velocity being given to this blood. It may also arise from more blood being present in the artery, when a fresh supply is propelled from the heart; or when there is plethora in all the arterial system, which plethora, however, may be partial, and confined to particular parts. The pulse is rendered fuller by the same means that it is rendered quicker, namely, the increased action of the heart, the increased stimulant power of the blood, and an increase in the velocity of the blood in the veins. It may be also rendered fuller by any impediment to the flow of the blood in the arteries.

Small or slender pulse is necessarily caused by the reverse of what produces fullness of the pulse.

The varieties in strength and weakness of the pulse depend on the combined action of the heart and arteries; which varieties depend chiefly on the difference of time the arteries take in being filled, and less on the action of these vessels; and by ascertaining the time which the artery takes in being filled, we can calculate the quickness of action of the ventricles of the heart.

The intermitting pulse appears to be caused either by no blood, or so little being sent from the ventricles, that it produces no dilatation in the arteries to render a sensible impression on the fingers. This may depend either on no action, or too weak an action of the ventricles, or it may depend on a sudden spasm preventing their receiving any blood from the auricles, or upon such an obstruction between the auricles and ventricles, or between the ventricles and arteries, as to prevent their receiving a sufficient quantity of blood.* Polypus, or ossification of the tricuspid, mitral, or semilunar valves, or aneurism of the arch of the aorta, produces nearly the same effects.

Too small a quantity of blood leaving the heart, seems to be the most frequent cause of intermission of the pulse. This frequently occurs where the heart is quite healthy, as in those having weak stomachs, which are often disordered, and in nervous people. In the nervous habit, it must depend on too feeble action or spasm of the heart. Immediately after intermission, there generally takes place an increased effort of the heart, which causes a greater action.

The arteries seem to possess a power inherent in themselves of acting, without calling into action the heart, the contractions of which continue naturally the same; and in this independent action the veins participate. This independent action of the arteries is ascribable to the nerves, for all motion begins in the latter This phenomenon is beautifully elucidated in the eye, where the transparent, almost invisible vessels, on the tunica conjunctiva, become, from any exciting cause, red in a few seconds, by immediately enlarging. It is illustrated by the act of blushing in the young female, where the face, neck, bosom, and arms, become in a moment suffused; by the application of hot water, or a heated metal, to a small part of the face, instantaneously producing redness; and by the penis being injected immediately with blood, from local irritation, even in sleep. The application of cold produces a similar appearance; the nerves are chilled, causing a suspension of their action, at the same moment that the capillaries are constricted, thus increasing the resistance; so that the nerves are excited, and the arteries are immediately after overcharged. In these actions, the arteries are excited to contract with more vigour and celerity, and consequently propel the blood with more quickness, and in greater quantity, than ordinarily.

When this action lasts for any time, it is named a local determination of blood or hyperœmia;† but when pain accompanies it, it is styled inflammation. In the latter, the nerves are excited to greater action, and the contractility of the arteries is soon by over-action enfeebled, so

* In Medico-Chirurgical Transactions, Vol. I., Mr. Abernethy details two cases, where the communication between the left auricle and corresponding ventricle was so small, as to impede the flow of blood: the auricle was double its size, and the ventricle smaller than natural. The pulse was extremely small and frequent in both. I examined the heart of a middle-aged lady, where the same appearances were found, and where the pulse was during life also exceedingly small and frequent.

† A local determination of blood increases the bulk of the part, by depositing new substance.

that these vessels enlarge and circulate a greater quantity of blood. The blood, however, appears to flow with increased velocity, which is caused by that part of the artery immediately contiguous, or leading to the inflamed and dilated portion, being morbidly excited. The artery of an inflamed part, therefore, is at first smaller than during health, in consequence of the spasmodic action of the nerves, and the distention of the vasa vasorum, diminishing the calibre of the vessel, but very soon becomes enlarged, from the nerves being partially exhausted, and the vessel over distended with blood; while the portion leading to the inflamed part is contracted in diameter. The increased quantity of blood circulating in an inflamed part, is the cause of the redness, and partly the cause of the increased heat. Nearly the same effects take place, only in a less degree, in local determination of the blood, or what is sometimes styled congestion; for when the capillary arteries are partially constricted or obstructed, inflammation may supervene.

In inflammation of any degree, the heart and the whole circulating system are involved, and constitute inflammatory fever; sometimes the quickened pulse precedes the appearance of the inflamation, while at other times it follows. In the former, the increased circulation, from whatever cause, so excites the nerves and arteries, that they are incapable of returning to their wonted quiescence, and the inflammation may be either partial or general, according as there is any part of the body feebler than another. This is satisfactorily verified in those who have once had any local inflammation, having always that part attacked more readily than any other, in any increased action of the heart and arteries. In the latter or when the quickened pulse follows the inflammation, the heart and arteries are excited by the diseased action of the nerves of the part being transmitted along the nerves to the heart.

The treatment of local inflammation is by leeches, cupping, punctures with the lancet, or incisions with the bistoury, warm anodyne fomentations, and poultices:* applying the leeches in great numbers, and repeating the fomentations and poultices, as often as they become cool.†

The treatment of general inflammation is by general blood-letting, warm-bath, or warm sponging, mercurial and saline purges, antimonial solution, acidulated drinks, low diet, and perfect quietness in a darkened or dark chamber. The blood-letting, at the onset of the disease, should be carried to syncope, and repeated every four hours till the pain is removed, for this symptom is the most to be depended on, and is the best criterion of this case; the pulse and buffy blood‡ may almost be thrown out of consideration. The warm-bath, or sponging with warm water, should be repeated as often as the skin indicates preternatural dry heat. Salts ought to be given much diluted, and often enough to produce two motions in the twenty-four hours, while pain is present, and one daily when this is subdued. The acidulated drinks may be made of super-tartrate of potash, tamarinds, or green fruits. Low diet is vegetables plainly boiled, green fruits, and plain cold or toast-water. From what has been said, it will be at once understood, that the local inflammation may become general, and require the combination of these treatments.*

In inflammation of almost any degree, the capillary arteries are modified by the nerves, to secrete coagulable lymph, which generally favours the inflammatory action by moderating it. When this action is more violent, the capillaries are modified by the nerves, so as to form small papillæ, named suppurative, which secrete purulent matter†; and when the inflammatory action is extremely violent, the nerves, arteries, and contiguous textures, are so destroyed in their structure, the two former by inflammatory exhaustion, the last both by this and by being gorged with blood, which coagulates, in consequence of not being kept in motion: this constitutes gangrene, or mortification; sphacelus being the further stage, or separation of the gangrened part.‡ These are the common and general terminations of inflammation; the first, or the secretion of coagulable lymph, which generally accompanies a natural quiescence of the inflammatory action, is termed resolution, although resolution may take place without effusion of coagulable lymph. When coagulable lymph is thrown out, and becomes a bond of connexion, as in pleuritis, the termination is named adhesion; the capillaries shoot into the lymph, and render it an organised mass: and when lymph is effused into a recent wound, and becomes a similar bond of connexion, it is termed the adhesive inflammation or union by the first intention; the capillaries here performing the same part as in the former. The second termination, or the secretion of purulent matter, is named suppuration; and the third, or destruction of the different textures inflamed, is denominated mortification. Besides these, there are other terminations. When the suppurative papillæ are exposed by rupture and absorption of the integuments, the disease is named ulceration, of which there are many varieties, depending either on local circumstances or on constitutional causes. Ulceration may also take place in cavities, as in the thorax; in which case there are ulcerative papillæ, or the suppurative papillæ perform what is named the ulcerative absorption, i. e. the papillæ secrete pus, while the absorbents are excited to remove the contiguous structure, so that there is active absorption and secretion going on. When inflammation attacks the serous membranes, as the pleura or peritoneum, the exhalants are sometimes rendered so debilitated, that they secrete more than their natural quantity, and of a more watery consistence, which constitutes effusion or dropsy. This disease may also be caused by diminished absorption, or by both increased exhalation and diminished absorption. When this action attacks glandular structure, the arteries sometimes secrete a peculiar condensed cartilaginous structure, named schirrus, which, when accompanied with pain, forms carcinomatous sarcoma, or occult cancer. The capillaries in various parts of the body, and in various tissues, secrete differently diseased substances, forming a variety of tumours, as tubercles, the common vascular or organised sarcoma, the adipose sarcoma, the pancreatic sarcoma, the mammary sarcoma, the tubercu-

* Sir Everard Home's experiments on the influence of the nerves upon the arteries, incontestably prove the superiority of warm applications over cold, to inflamed surfaces.—Philos. Trans. 1814; see also Dr. Wilson Philip, in Philos. Trans. 1815; and Le Gallois sur la Principe de la Vie.

† See Lizars's Practical Surgery, Part I., page 15.

‡ Many a patient is made a victim by the practitioner giving too much weight to buffy and cupped blood. This appearance depends on increased absorption, therefore it is more exhibited at the last scene of life, than in the beginning of disease.

* See Lizars' Practical Surgery, Part I., p. 24.

† Ibid., Part I., p. 46. ‡ Ibid., Part I., p. 74.

lated sarcoma, and the medullary sarcoma, or fungus hæmatodes; also the different kinds of encysted tumours, as the atheroma, melliceris, and the steatoma. *

When suppuration follows active inflammation, and the matter is confined by the surrounding parts, it is named an acute abscess; a free incision should be made to evacuate the fluid, and the part afterwards treated with simple dressings. If the suppuration has been extensive, nourishing diet, and, as soon as possible, exposure of the patient to the open air, will be requisite.† When suppuration is slow in its progress, and preceded by chronic inflammation, which is merely a slow action of the inflamed vessels, in this case, a small opening should be made with a lancet, the wound either healed up, as directed in page 106, or allowed to remain open, and the parts properly supported by compresses and bandage. Nourishing diet, and exposure to the open air, are powerful auxiliaries in the cure.‡

In mortification, the application of simple warm poultices is far preferable to stimulants, for the gangrened part cannot be saved, but must sphacelate; so that our object is still to subdue the contiguous inflamed part, and thus prevent a further extension of the gangrene: consequently, the low diet, gentle laxatives, and acid drinks, should be continued, unless diarrhœa is present, when the latter should be given up, and astringents administered. When sphacelus is perfectly established, the part may be removed, but not too near the gangrened surface. In extensive gangrene, as that of a limb, arising from external injury, amputation is proved to be salutary. §

When any obstruction takes place in an artery, either from coagulated blood, pressure, or the application of a ligature, the limb does not die for want of blood, because the circulation is carried on, however feebly, by the anastomosing branches: the latter gradually enlarge, until the communication between the upper and lower parts of the limb is completed. The blood, in the first part of this process, stimulates these anastomosing branches, next gradually enlarges them, and lastly, by this increased determination, gives them proportionate strength. The vessels appear to be modelled to perform their new and more important task.‖ Sometimes, however, these anastomosing vessels are incapable of carrying on the circulation sufficiently, and the limb dies from mortification.

When an artery is secured by a ligature, the two internal, or the serous and muscular coats, are either partially or completely cut through, while the external or cellular coat remains sound; a moderate degree of inflammation is next excited, coagulable lymph effused, and union of the opposite sides of the artery effected by adhesion. Sometimes, however, instead of this healthy termination, the inflammatory action is too violent and ulceration occurs, which is followed by hemorrhage. The serous coat of an artery is the most easily inflamed, and the most subject to disease. When injecting a limb in the dissecting-room, great care is requisite to avoid rupturing the serous and muscular coats, and to prevent the injection flowing into the mesh of the cellular tunic, or into the cellular or muscular substance in the contiguity.

When an artery is obstructed by the internal or serous coat separating and plugging up the calibre of the vessel, or from coagulated blood, the vessel above this obstruction either dilates or ruptures, and produces aneurism.* In the case of the artery simply dilating, either from the preceding causes, debility of its coats, an undue impulsion, or any other cause, the disease is styled true aneurism;† which species is most frequently met with in the arch of the aorta, and occurs likewise in the thoracic and abdominal portions, at the division of the carotid and the iliac arteries, and also in the arteries of the brain. But this is not properly considered true aneurism, which is a disease consisting of a dilatation of the coats forming the sides of an artery; the present affection being a simple dilatation of an artery, and when it occurs in the ascending aorta, the coats are thickened and covered with atheromatous and calcareous depositions. The symptoms of this dilatation of the commencement of the aorta are the same as those of aneurism of this part, and so also is the treatment. But this is a species that seldom occurs, for the internal or serous coat, together with the muscular, rupture in consequence of their brittleness, or from inflammation and ulceration, or mortification, or partial dilatation; or absorption of these two tunics takes place, in consequence of some diseased spot, which appears of a blackish colour, and slightly inflamed,‡ while the external or cellular coat alone is dilated, constituting what is named by some writers true, and by others false aneurism

When the cellular coat of the artery is ruptured, the blood is then only confined by the loose cellular sheath of the artery, which also yields; the walls of the sac are then formed by the surrounding parts, which have been consolidated by the previous inflammatory action excited by the distention of the tumour. The sac, however, sometimes bursts before these adhesions are sufficiently strong, and the blood is injected among the surrounding soft parts. When the aneurism advances to the skin, the integuments slough and ulcerate, and the patient dies of hemorrhage; the same process takes place in the trachea, œsophagus, stomach, and other mucous structures; while, when an aneurism bursts through a serous membrane, as the pleura, the latter is lacerated. When an aneurism presses upon the bone, the latter becomes carious.

In the event of the cellular tunic of the artery rupturing, and the blood diffusing itself in the contiguous cellular tissue, the disease is denominated by some simply false aneurism, and by others diffused false aneurism, to distinguish it from the preceding, which is then named the circumscribed false aneurism. This false aneurism, or

* See Lizars' Practical Surgery, Part II. p. 1.

† Ibid., Part I., p. 47. ‡ Ibid., Part I., p. 81.

§ Mehee, Traité des Plaies d'Armes à Feu, Paris, 1799; Larrey, Memoires de Chirurgie Militaire, tome iii.; Lawrence, Medico-Chir. Trans., vol. vi.; A. C. Hutchinson's Practical Observations on Surgery; Mathews, in Edinburgh Medical and Surgical Journal, vol. xix. p. 205. See also Lizars's Practical Surgery, Part I., p. 74.

‖ Cases are detailed where the aorta has been obliterated, and yet the circulation carried on by the other vessels. See Stanzel's Dissertation de Steatomatibus Aortæ; Meckel, in the Memoirs of the Royal Academy of Berlin, for 1756; Stoerk, in Medical Annals, vol. ii.; Dessault's Medical Journal, a case by Paris, tome ii.; Medico-Chirurgical Transactions, vol. v., a case by Dr. Graham. Sir A. Cooper tied the aorta first in the dog, Medico-Chirurgical Transactions, vol. ii., and then in the human body; the man lived for several hours after, Surgical Essays, vol. i. See also a case by M. Crampton, surgeon-general at Dublin, in Dublin Hospital Reports, vol. ii.

* See Lizars' Practical Surgery, Part I., p. 89.

† Morgagni, Pelletan, and Larrey are of opinion that syphilis is a predisposing cause of aneurism.

‡ In many subjects brought into the dissecting-room, where an aneurism was present, these black spots or tubercles have been found in many arteries. They appear to be an effusion of blood from the vasa vasorum.

diffused extravasation of blood, is more generally produced by an artery being wounded by a sharp instrument, so that the blood escapes at once into the surrounding soft parts. *

The parts of the arterial system most subject to the second species of aneurism, or that wherein the serous and muscular coats are ruptured, and the cellular dilated, are the arch of the aorta, the external carotid artery, the axillary, the brachial, the femoral, and the popliteal arteries. The symptoms of this disease, when it attacks the arch of the aorta, are, difficult, frequent, laborious, and whistling respiration, the inspirations appearing never to be complete, thus resembling those in asthma, and also occurring in paroxysms, particularly when walking, on which occasion there is frequently a sense of suffocation; frequent cough, with occasional expectoration of mucus streaked with blood; pain at the sternum; intermitting pulse, which, however, is sometimes very variable, being occasionally soft, full, and frequent, and different at the two wrists; face more or less livid; the extremities ædematous; and the patient unable to lie on the back in the horizontal posture. When percussion is employed, the thorax does not sound on the middle and upper part of the left side; and when the hand is applied, a rustling and trembling is felt. This disease is often mistaken for an affection of the lungs; and I have seen it mistaken for hydrothorax. In some cases, the tumour presses outwards, and generally on the left side of the thorax; one instance of which occurred in a woman, representing the appearance of two mammæ on one side. I took a drawing of the case, and have preserved the preparation in my Museum. The treatment of this fatal malady can only be palliated by occasional bleedings, low diet, gentle exercise, and attention to the bowels.

A tangible aneurism, if I may use the expression, is characterized by a pulsating tumour in the region of an artery, with the pulsation of which it corresponds, attended with pain in the seat of the tumour; and when in the lower extremity, feebleness and pain in walking. When in bed, the patient is attacked with cramp, and sudden twitchings in the legs, which prevent him sleeping. The tumour, when examined, contains arterial blood, generally partly fluid, and partly in layers of coagula; it is only in those small true aneurisms, that the blood is entirely fluid. Patients are frequently affected with more than one aneurism, showing that there is a general affection of the arterial system. This species may be treated either by compression or an operation. For a detail of the operations to secure the different arteries, the reader is referred to the former part of the work, where each is minutely described.

Besides these diseases, arteries are subject to inflammation and its terminations, as adhesion, suppuration, and gangrene; and are also frequently involved in inflammation, and other diseases of contiguous structures. The internal or serous coat is sometimes found of a deep red colour, with a deposition of coagulable lymph, appearances which have been witnessed in the aorta in severe cases of pneumonia, carditis, and bronchitis. This state often induces gangrene of the limbs. In some cases, the cellular tissue connecting the coats of the aorta have been found distended with lymph. The application of a ligature to an artery in amputation, or for the cure of aneurism, has occasionally produced so great a degree of inflammation as to extend to the heart. The ligature on the umbilical cord sometimes excites inflammation along the hypogastric or umbilical arteries. The arteries are not unfrequently deeply tinged, of a red colour, from transudation of the blood; but when the internal or serous coat is detached, the muscular presents no unnatural colour, there is no deposition of lymph, and no thickening of the coats of the vessel. As this state of the arteries is a concomitant of other acute diseases, the practitioner is directed to their symptoms. Should he suspect inflammation of the artery, or arteries, the antiphlogistic treatment will require to be more vigorous.

In the vicinity of ulcerations, thickenings, or calcareous depositions of arteries, the vessel is generally inflamed, which must be considered chronic; the internal coat of the artery is of a deep red colour, and is softer and thickened. This condition of arteries occurs commonly in aneurismal subjects, whose diseased state of the arteries is complicated with syphilis. The effusion of coagulable lymph and the adhesive inflammation, have already been considered; but I may here observe, that Nature, with her infinite wisdom, has by this process preserved the lives of many for several days, as in phthisis pulmonalis, where, when the substance of the lungs is nearly entirely consumed, hemorrhage is prevented by the closure of the branches of the pulmonary artery, through the means of effusion of coagulable lymph, and the adhesive inflammation;* but where the ulceration is so rapid, as to prevent this adhesive process taking place, hemorrhage ensues, which becomes more or less serious, according to the magnitude of the artery.

Suppuration is seldom witnessed, in consequence of the matter being washed away by the blood; but ulceration is often met with in arteries affected with calcareous and atheromatous depositions. The condition of arteries frequently gives rise to aneurism, to apoplexy, hemoptysis, hematemesis, &c. This state often occurs in phagedenic ulcers.

Gangrene of a limb involves the arteries, together with the other textures, but inflammation of an artery seldom or never ends in gangrene.

The serous coat of arteries is sometimes converted into the cartilage, sometimes into a thickened pulpy structure, like steatoma, sometimes into an atheromatous substance, which is however deposited between the serous and muscular tunics.

Ossification of the arteries, or a deposition of calcareous matter, is a very common result in old age; sometimes, however, it occurs in very early life, even at fifteen months. All the old subjects which come into dissecting-rooms, have their arteries from the aorta to the arteries of the brain, arm, and leg, covered with calcareous depositions, which begin on the outer surface of the serous coat. This change of structure is the most common cause of spontaneous aneurism, and is a frequent cause of apoplexy, hemoptysis, and mortification of the inferior extremities. Calcareous depositions take place principally in the arteries of the trunk, in the branches of the carotid and iliac arteries, and more frequently in the second and third

* The opinion of the majority of surgical writers of the present day, is, that true aneurism consists of a rupture of the serous and muscular, with a distention of the cellular coat, and that this rupture takes place in the side of the artery. In aneurisms of some magnitude and continuance, however, I have seen the whole area of the artery involved, and the serous coat distributed in patches over the tumour.

* I possess a preparation where the left half of the lungs forms a complete pouch.

orders of arteries, than in their ramifications. The pulmonary artery and valves are seldom affected; and the upper extremities much more seldom than the lower. In maniacs, the arteries of the brain are generally ossified.*

Hemorrhage from a wounded artery is to be stemmed by various methods, which vary according to the magnitude and number of the vessels injured; but it may be laid down as a law in surgery, that wherever an artery is large enough to pour out such a quantity of blood, as to weaken in the least the patient, it should be secured by a ligature above and below the seat of the wound. Where a vascular surface is wounded, in which the blood-vessels are extremely small, where they are merely capillary, as, for example, the mucous membrane of the nares, styptics, with compression, and a bandage, where it can be applied, should be employed. The styptics used are cold water, vinegar and water, a solution of the sulphates of zinc, copper, or iron, the mineral acids diluted, alcohol, alcohol and sulphuric acid combined together. In all contused wounds, where arteries are injured, compression should be used, and if found ineffectual, the artery leading to the injured part should be secured by ligature, but never at the seat of the injury. This is well exemplified in the palm of the hand and the sole of the foot. Compression is produced by lint, dry sponge, sponge-tent, agaric, and bandage, and is the remedy employed in hemorrhage of the plantar or palmar arteries, the internal pudic artery in lithotomy, the intercostal arteries, the temporal artery, and the extreme branches of the internal maxillary artery, after the extraction of a tooth. The actual cautery is employed after the extraction of tumours from the antrum maxillare, the gums, palate, &c. When hemorrhage occurs in any of the large cavities, as the cranium, the thorax, and abdomen, the patient is treated with bleedings from the arm to produce syncope, with depressing narcotics, as digitalis and hyosciamus, together with gentle laxatives, low diet, and perfect rest. When the cranium is the seat of the hemorrhage, we often trephine in the region of the middle meningeal artery in the expectation that it is the source of the hemorrhage. When in the thorax, or abdomen, we can only have recourse to the general remedies mentioned.

Hemorrhage has proved fatal even from the gums, the nares, or the ears; when from the former, it has been after the extraction of a tooth, and then sponge-tent, wedged between the contiguous teeth, and the jaws firmly bound together by a roller, will stem the bleeding; when from the nares, the hemorrhage may be stemmed by plugging up the anterior and posterior apertures of the nostrils with lint; and when from the ear, by plugging the meatus with lint, and a compress and bandage externally: the securing the common carotid artery has been had recourse to by some, but has proved inefficient. Hemorrhage proves sometimes fatal in rapid ulceration involving large arteries.

The greater number of animals have veins, at least all those which possess a heart: veins, therefore, are only observed to be deficient in insects, as the erucæ, and in zoophytes, as the polypi. Veins are also sometimes found deficient in the human monster, when born without the heart.

In page 233 we remarked, that the capillary, and even some of the larger arteries, terminated in, or joined the veins; that this junction can be demonstrated on the pia mater of the human brain, the tail of a fish, the web-foot of the frog, and the gills of the salamander and frog; and that this inosculation had been witnessed not only in these animals, but in others, by several physiologists, as Harvey, Lewenhoeck, Bernouilli, Cowper, Malpighi, Hales, Haller, and Spallanzani. When cleaning out the arteries of a limb, or the head of a subject, with tepid water, previous to injecting it with coloured wax, the water returns by the veins; and when injecting the arteries of a limb, or the head, with the coloured wax, the veins are often found filled. If a ligature be applied to a vein, or if pressure be made, as in blood-letting, the distal parts become turgid, while the proximal, or those next the heart, are found empty; so that there can be no doubt, that the veins return the blood from the arteries to the heart, and that they circulate their blood from extremes, or branches, to trunks; this latter observation is applicable to all the veins, with the exception of the vena portæ, which when it approaches the liver, branches from a trunk like the arteries. That some veins commence by open mouths, and perform the function of absorbents, is still doubtful; for although there are many experiments related by Haller, Magendie, and others, which seem to substantiate this opinion, yet they can all be satisfactorily explained by the acknowledged fact, that the veins and lymphatics have a direct communication. Where the veins have been found to be absorbents, they may have received the fluid through the medium of the lymphatics, either in the living, or in making mercurial preparations in the dead state.

The veins begin by small branches continuous with the arteries, and have numerous inosculations as they advance and become larger, even in their largest trunks. The veins of the lower extremities and abdomen form the vena cava ascendens, which enters the right auricle, along with the vena cava descendens and the coronary vein, the former of which returns the blood from the head and upper extremities, while the latter returns it from the heart. The anastomoses of the veins differ from those of the arteries, the former taking place even in the larger trunks, the latter only in their smaller branches; and by the blood thus concentrating in the veins, it flows with more rapidity. The veins take various courses; some accompany the arteries, as the venæ satellites of the arteries of the extremities; others run between the skin and the muscles, as the cutaneous of the extremities; others abandon the arteries, the blood of which they return, as the sinuses of the brain: others again form several separate plexuses, without accompanying the arteries, as those of the neck, tonsils, spermatic cord, urinary bladder, and vagina. The veins vary in the thickness of their sides, those running immediately under the skin being the thickest, while those in the abdomen are the thinnest, with the exception of those in the sinuses of the head. This variety of thickness seems to depend on the pressure applied to the veins, those vessels being thickest where little or no pressure exists, as the subcutaneous. The veins, like the arteries, have three tunics, but considerably thinner, namely, a cellular, a muscular, and a serous; the first and last, like the arteries, are allowed by all, but the middle or muscular is doubted, and particularly its muscular contractility; flexile muscular fibres, however, can be demonstrated running longitudinally on the venæ cavæ in man, and many other animals, which fact is taken notice of by Lancisius, Borelli, Senac, and Haller; the last of whom observed these vessels pulsate and contract in propelling the blood into the right auricle, both in cold

* Marshall on Mania and Hydrophobia.

and warm blooded animals, which latter circumstance was also noticed by Lancisius, Senac, Steno, Lower, Cowper, and a number of anatomists. The fact that the blood circulates in worms of red blood, that have no heart, and that the umbilical vein of the fetus, both in the perfect fetus and in the monster without a heart, circulates its blood, satisfactorily prove that veins possess muscular contractility. They have nerves, lymphatics, arteries, and veins, the same as the arteries. The veins have no adscititious cellular covering, and although much thinner, yet they have greater density and strength than the arteries, being sometimes prodigiously dilated with blood, and afterwards returning to their wonted calibre. In the dead state, they are less easily ruptured by the distention of injections than the arteries. In old animals, however, the veins have less density and specific gravity than the arteries. In some parts of the body, as in the sinuses of the brain and in the bones, the veins consist only of their internal or serous tunic.

When a vein is opened, we observe the blood flow in jets, shewing that the impulse of the heart is even communicated, to a certain extent, in the venous system. Hales and Walæus observed the blood accelerated in the capillary veins, at each systole of the heart, in cold-blooded animals; but Haller found that this did not take place in warm-blooded animals. The increased flow of the blood into the veins appears consequent on the action of the heart, communicated through the medium of the column of blood in the arteries; but the blood is moved forwards in the veins, partly by the action of the heart, partly by the elastic and muscular powers of the arteries, and partly also by similar powers in the veins. These powers of elasticity and muscular contractility are much feebler in the veins than in the arteries, in consequence of their more delicate structure.

As certain portions of the body tend to induce congestion in the veins, as the action of the muscles in the extremities, Nature has placed a number of valves in these vessels, and these are consequently found most numerous in the veins of the extremities. Valves exist also in the veins of the neck and head, but they are deficient in the brain, those in the sinuses having merely little productions of the membrane stretching across; and they are also deficient in the vertebral veins, in the pulmonary veins, in the coronary vein of the heart, with the exception of a single valve at the termination of the latter in the viscus, in the veins of the portal system, in those of the urinary bladder, in those of the uterus, in those of the kidneys or supra-venal glands, in the placenta, or umbilical vein, though the latter has some rugæ. These valves, which are of a sigmoid shape, as represented in Fig. 3, Plate XI., vary from one to three in number, one being only found in the smaller, as in the veins of the hand, foot, spermatic cord, and vena azygos, and one at the termination of the vena cava inferior, named after Eustachius, and one at the coronary vein. Two valves are found in the majority of the veins and three where the larger veins unite, as at the junction of the crural veins, and that of the internal jugular with the subclavian vein. These valves are formed by a production of the internal or serous tunic, and have a shining and somewhat tendinous appearance, that portion adhering to the wall of the vein in some degree callous; and they have their free edges pointing to the heart, or proximad. They seldom form a complete partition, but oppose a considerable obstacle to the reflux of the blood.

The valves of veins seem to be designed to obviate pressure, and hence they are found in the veins of the extremities, and in those returning the blood from the testis and ovarium. These valves consequently prevent muscular contraction from retarding the flow of the blood, and by their directing the course of this fluid, the muscles rather increase than diminish, by their motions, the velocity of the blood. These valves evidently answer the same purpose in the subcutaneous veins, for there they are constantly exposed to the pressure of the skin. The blood is propelled in the veins of the mesentery, &c. by the action of the abdominal muscles, and in the lungs by the motion of respiration, hence no valves are requisite in these regions. Veins have their vasa vasorum and nervous twigs like arteries, and are much more sensitive. In some places the veins are more dilated than in others, as in the vena cava inferior sacrad to the diaphragm, the beginning of the internal jugular, and the popliteal vein between the condyles of the os femoris.

The blood is found to flow faster in the trunks than in the branches of the veins, which must depend partly on a law of hydraulicks, that a fluid flowing from a larger into a smaller tube, is augmented in velocity, and partly on the principle that it flows in larger vessels possessing stronger muscular fibres. Hence, when a small vein is opened, the blood flows very slowly, but more quickly from a larger vein, and with still more rapidity from a venous trunk. The flow of the blood in the veins is observed to be more rapid the greater the number of uniting branches, and the shorter these are, because they are less tortuous. The less veins anastomose, and the less the angle at which they meet in anastomosing, the more is venous congestion prevented: but these anastomoses of veins enable the blood, when impeded in one course, to flow by another onwards to the heart.

The blood in the veins flows quicker, the more rapidly the arterial blood flows; and it is agreed, that in vessels of the same size, the blood flows slower in a vein than in an artery, in consequence of the propelling powers being diminished by the friction of the blood against the sides of the vessels, and its adhesion to these sides; and also, in consequence of the feebler structure of the veins.

Veins are not only greater in diameter, but thrice as numerous as the arteries; the area of the whole venous system is found much greater than that of the arterial; that of the veins is calculated to be to that of the arteries as nine to four, which is easily comprehended by the great number of middle-sized veins, and by the excess of veins over the arteries, as, for example, in the upper extremity. Much greater variety occurs both in the division and in the origin of the branches of the veins than in the arteries.

When the body is exposed to caloric, the blood passes readily into the veins, apparently from the expansion of the capillaries, and the increased impetus given to the circulation of the heart; on the contrary, when exposed to cold, the capillary vessels are contracted, and the blood circulates more slowly.

When a ligature is thrown round a vein, its coats are merely applied to each other; they are not ruptured, like those of an artery, consequently more irritation is produced, and inflammation excited: and as the action or motion of veins is the reverse of that of arteries, being from extreme branches to the heart, and the blood flowing in the same direction, the inflammatory action frequently extends to the heart and proves fatal. It is now therefore

an axiom in operative surgery, never to apply a ligature to a vein, even in amputation, but to trust to compression. Dry sponge, with proper bandaging, is found capable of stemming the hemorrhage from the largest veins. However, those in the vicinity of the heart, as the external jugular, when wounded, demand a ligature to prevent the admission of air, from the suction-power of the heart, since numerous fatal cases are recorded where this has been omitted. *

If a fine or thin ligature be employed, the internal tunic is lacerated, inflammation produced, and if compression be applied, so as to retain the opposite sides of the vein in contact, adhesion takes place.

Veins are very prone to inflammation from wounds, as in blood-letting, particularly where there is any tendency to erysipelas, and in sultry weather, and especially in crowded and filthy hospitals. The inflammatory action extends along the vein onwards to the heart, and very frequently proves fatal. The vein, where punctured, is thickened in its coats, and for some extent onwards towards the heart; in some places the internal tunic is of a deep red colour, onwards to the right auricle; in other places it is lined with coagulable lymph, and in others again with pus. The vein is frequently found obliterated in places. The cellular tissue in the contiguity of the vein is often infiltrated with pus, so also occasionally is the pectoral muscle. The symptoms of this disease are pain in the wounded part, extending along the extremity with great tumefaction, severe pyrexia, small quick pulse, hot skin, difficult respiration, furred tongue, great prostration of strength, with pain in the head, back, and extremities. The treatment consists in active blood-letting from the system, warm bath, laxatives, low diet, and rest, accompanied with leeches, hot anodyne fomentations and poultices applied to the arm. Abscesses often occur in the course of the vein, and require to be early punctured. †

The crural veins have occasionally been found inflamed and filled with purulent matter, after accouchement; and the hypogastric and spermatic veins, onwards to the renal veins, have been found in the same state in puerperal fever, and after abortion. ‡ One or more veins in the body have been found in a similar condition in phthisis pulmonalis, in cancerous states of various organs, and in erysipelas. § Veins have been found inflamed from metastasis. ||

Ulceration occasionally begins in the interior coat of a vein, and ulcerates through the vessel, so as to give rise to hemorrhage. * Veins have been found ruptured without ulceration, or any morbid change, being easily torn when suddenly distended, as in cramps, † sudden action of the circulating system, as in the cold bath, ‡ in the cold state of intermittent fever, § and from blows, an instance of which I witnessed in the thigh of a man, who received a blow from a hammer, where the branches of the vein accompanying the arteria profunda femoris were ruptured. When slowly dilated, however, veins bear distention better than the arteries.

The veins are liable to be deranged in their functions from pressure, and from gravity; and those of the lower extremities, as also those returning the blood from the testicles and ovaria, seem most subject to be disturbed from such causes. When they become enlarged and tortuous, they are named varicose. The hemorrhoidal veins are also frequently varicose; likewise the superficial epigastric, and those at the bend of the arm, have been found in this state. ||

Morgagni observed the jugular veins dilated, ¶ and Portal the right subclavian vein dilated. ** The femoral vein immediately distad to Paupart's ligament has been found so dilated, as to be mistaken for hernia. Sometimes coagula of blood are deposited in varicose veins, and were formerly extracted by surgeons; †† but this practice, from its frequently producing violent constitutional irritation, is now abandoned; and for the same reason, the tying of veins with ligature is abandoned. They are now treated either with potass, or the twisted suture, which consists of needles and ligatures.

Pain and inflammation of the skin and cellular tissue frequently accompany dilatation of veins, the inflammation terminating either in abscesses or indolent ulcers round the veins. When the hemorrhoidal veins are varicose, they are named hemorrhoids, or piles; and besides being varicose, they frequently rupture and effuse their blood into the cellular tissue; which last state is that in which we find them when we apply the term hemorrhoids; for in a multiplicity of instances which I have examined after death, I have invariably found those tumours round the anus, consisting of effused coagulated venous blood, in the loose cellular web of that region; while the veins of the rectum leading to these tumours, were enlarged and tortuous. In life they should be freely laid open with a lancet, guarding against bleeding by compress and bandage, and afterwards poulticed till free of pain; then anointed with the ointment of nut-galls, or bathed with the decoction of oak-bark, and lastly discussed with the rectum bougie, introduced at bed-time, and left to remain as long as possible. When touched with the lancet, if they bleed much, a compress of lint, and the T bandage, or a couple of handkerchiefs applied after it, will be found to suppress it. Those of the spermatic cord in man are very frequently so affected, and begin sometimes very early in life. The female, in the advanced stages of gestation, is most subject to those of the leg; however, women unimpregnated are even affected; men are also occasionally affected with

* There are numerous cases on record of the fatal effects of tying veins; in Travers' Surgical Essays, Part I.; Carmichael, in Transactions of the Association of Fellows of the King and Queen's College of Physicians in Ireland, vol. ii.; Abernethy's Works; Loguet, Dissertation sur l'Inflammation des Veines, Paris, 1815; Hodgson on Diseases of Arteries and Veins; Hunter, in Transactions for Improvement of Medical and Surgical Knowledge, vol. i.; Breschet, Traité des Maladies des Artères et des Veines; Surgical Essays by Sir Astley Cooper and Travers. Meckel and Osiander detail cases where the tying the umbilical cord proved fatal. The same event I have witnessed myself, where the inflammation and suppuration extended onwards to the liver of the child.

† See Lizars' Practical Surgery, Part I., p. 39.

‡ Faits pour servir à l'Histoire des Inflammations Veineuses et Arterielles, Biblioth. Médic. tome xvi., Schwilgué; Medico-Chir. Trans. vol. iii., Travers and Wilson; Clarke's Practical Essays on the Management of Pregnancy.

§ Breschet, Traité des Maladies des Artères et des Veines.

|| Ibidem.

* Portal, Anatomie Médicale, tome iii.

† Hodgson on Diseases of the Arteries and Veins.

‡ Portal, Anatomie Médicale, tome iii.

§ Ibidem.

|| Petit, Traité des Maladies Chir., tome ii.; Hodgson's Treatise on the Diseases of the Arteries and Veins.

¶ Letter xviii. Art. 9, 10, 11.

** Cours d'Anat. Med., tome iii.

†† Petit, Traité des Mal. Chir., tome ii.

varicose veins of the legs, being consequent on collections of feces in the intestines, and tumours of the abdomen or pelvis. This varicose state sometimes arises in consequence of the circulation of the vein being obstructed, and even obliterated. In some instances, the vein ruptures, and hemorrhage takes place; an occurrence by no means uncommon in the saphena major of the leg. In the varicose state of the legs, bandaging and attention to the bowels generally dissipates them. A strong decoction of oak-bark is a powerful auxiliary. If not cured, they must be treated with potass or the twisted suture. In varix of the spermatic cord, the application of oak-bark decoction is still more indispensable, as no bandage can be applied; the actual cautery is sometimes necessary; the whole veins of the scrotum, as also those of the spermatic cords, are occasionally affected. The suspension of the testes by a bandage, and attention to the bowels, are requisite, together with the frequent application of cold water, and lying the greater portion of the twenty-four hours in the horizontal posture.

Varicose aneurism* is that species which is produced by a lancet, or any sharp-pointed instrument, transfixing a vein, and wounding an artery in its immediate vicinity, so as to establish a communication between them, and allow the arterial blood to flow directly into the vein Inflammation is excited at the wounded points of the vein, fascia of the biceps and the artery, so as to form a bond of adhesion between them, and a passage for the blood; for it sometimes happens, that the wound in the artery does not adhere to that of the fascia, and the blood escapes beneath the latter, and is diffused into the cellular tissue, forming false aneurism. A tumour is soon formed of a bluish colour, which communicates a tremulous motion and rustling noise to the touch and hearing; and the veins in the contiguity are more or less varicose. This species of aneurism occurs most frequently at the bend of the arm, but has been known to occur between the arch of the aorta and vena cava descendens, the abdominal aorta and vena cava ascendens, the subclavian artery and vein, the popliteal artery and vein, and the femoral artery and vein. This species is treated by compress and bandage, and if these fail to accomplish a cure, by securing the artery by operation. See the former part of this work, also Lizars' Practical Surgery, Part I., page 107.

Aneurism by anastomosis, first correctly and properly described by my able preceptor, the late Mr. John Bell, is that species where the small arteries and veins are so numerously collected at any part of the body, as to present a peculiar vascular appearance. This species is often first the simple nævus maternus, when the blood-vessels are generally so small, as not to prove troublesome or serious; at other times, it is at once a vascular tumour These, however, as the individual advances in life, increase in calibre, rupture in sultry weather, or in intense cold, producing hemorrhage, which each time becomes more momentous, until at last it proves fatal. This is particularly the case when it attacks a surface delicately covered with integuments, as the lips. In one or two cases of children, I have witnessed this disease involve the chest, neck, mouth, fauces, and pharynx. This disease sometimes follows an accident. Mr. J. Bell mentions that there are intermediate cells between the arteries and veins, which may be the structure in those cases depending on accidental violence; but in those I have had an opportunity of examining, and which appeared to be congenital, there was no cellular intervention. The veins in general have been found to form the greater portion of the tumour.

Aneurism by anastomosis, when insulated, may be removed by seton or operation, by extirpating the vessels and structure in the neighbourhood. The simple securing of the arteries leading to this vascular body, has been found ineffectual.*

Veins are very seldom converted into cartilage, or ossified, or covered with calcareous depositions; cases, however, are recorded by Morgagni,† Baillie,‡ Macartney, Hodgson,§ Beclard, Breschet,‖ and other authors. Loose calculi have also been found in veins, named phlebulites;¶ and tumours, resembling in appearance those in the contiguity, have been found growing from the lining coat of veins.** There are several instances on record of large veins being obliterated, as the vena cava inferior, and the circulation carried on by the vena azygos.†† I met with a preparation in the dissecting-room, where no trace of the vena cava inferior was to be found, and where the vena azygos carried on the circulation. Veins, like arteries, are frequently involved in inflammation, ulceration, mortification, &c. of contiguous structures.

* Syn. Aneurismal varix. Venous aneurism.

* See Lizars' Practical Surgery, Part I., p. 117.

† Morgagni, Letter lxiv. Art 9.

‡ Transactions of a Society for the Improvement of Medical and Chirurgical Knowledge, vol. i.

§ Hodgson on Diseases of the Arteries and Veins.

‖ Breschet, Traité des Maladies des Artères et des Veines.

¶ Ibid., and Hodgson on Diseases of the Arteries and Veins.

** Ibid.

†† Bartholinus Observat. Anat. Cent. ii. Hist..xxxv.; Haller, Opuscula Path. Obs. xx.; Transactions of a Society for the Improvement of Med. and Chir. Knowledge, vol. i. p. 127, and vol. iii. p. 70; Scarpa on Aneurism, Wishart's Translation, p. 20, note.

INDEX

TO

THE LETTERS OF REFERENCE

IN

THE PLATES OF THE BONES.

PLATE I.

a, Bones of trunk
b, Bones of head
c, Bones of upper extremity
d, Bones of lower extremity

PLATE II. Fig. 1.

a, True vertebræ
b, Foramina common to vertebræ, which transmit spinal nerves
c, Ribs
d, Cartilages
e, Sternum
f, Foramina in transverse processes of cervical vertebræ
g, Os sacrum
h, Ossa innominata
k, Scapula
o, Intervertebral cartilage
p, Clavicle
1, 1, Surface of attachment of trapezius muscle
2, 2, Attachment of sterno-cleido-mastoideus muscle
3, 3, Attachment of greater pectoral muscle
4, 4, Attachment of deltoid muscle

Fig. 2.—A Lumbar Vertebra.

a, Body
b, Ring
c, Articular processes
d, Transverse process
e, Spinous process

Fig. 3.—A Cervical Vertebra.

a, Body
b, Ring
c, Articular processes
d, Transverse processes
e, Spinous process
f, Foramina for vertebral arteries and veins

Fig. 4.—A Dorsal Vertebra.

a, Body
b, Ring
c, Articular processes
d, Transverse processes
e, Spinous process
g, Depressions for articulation with heads of the ribs
h, Depression for articulation with tubercle of rib

Fig. 5.—Atlas.

a, Body
b, Ring
c, Articular processes
d, Transverse processes
e, Spinous process
f, Foramina for vertebral arteries and veins
i, Indicating attachments of transverse ligament
k, Smooth surface on which processus dentatus revolves
m, Points of attachment for lateral ligaments

Fig. 6.—Vertebra Dentata.

a, Body
b, Ring
c, Articular processes
d, Transverse processes
e, Spinous process
f, Foramina for vertebral arteries and veins
n, Processus dentatus

Fig. 7.—Seventh Rib.

a, Sacral margin with groove for intercostal nerve, artery, and vein
b, Head
c, Point of articulation to transverse process of vertebra
d, Tubercle
e, Depression for mucilaginous glands
f, Angle
g, Sternal extremity

Fig. 8.—First Rib.

h, Tubercle for attachment of scalenus muscle
i, Depression made by subclavian artery
k, Head

PLATE III.

Fig. 1.—Female Pelvis.

H, Body of the os ischii
S, Crista of os ilium
U, Foramen obturatorium
Y, Promontory of os sacrum
a, Os sacrum
b, Os coccygis
c, Articular processes of os sacrum
f, Sacro-iliac-synchondrosis
h, Os ilium
n, Foramina for sacral nerves
r, Acetabulum
s, Anterior superior spinous process of os ilium
t, Anterior inferior spinous process of os ilium
x, Depression made by psoas magnus and iliacus internus muscles
y, Brim or inlet
ɾ, Spine of os pubis
ɡ, Surface for pectinalis muscle
ɦ, Body of os pubis
ɨ, Crista pubis
ɟ, Attachment of crus clitoridis
ɫ, Symphisis pubis
ɱ, Origin of gracilis muscle
ɲ, Linea-ileo-pectinea
1, Origin of erector clitoridis
2, Origin of adductor magnus muscle
7, Origin of quadratus femoris muscle
8, Spine of os ischii

Fig. 2.—Male Pelvis.

H, Body of os ischii
S, Crista of os ilium
U, Obturator foramen
Y, Promontory of os sacrum
a, Os sacrum
b, Os coccygis
c, Articular processes of os sacrum
f, Sacro-iliac-synchondrosis
h, Os ilium
n, Foramina for sacral nerves
r, Acetabulum
s, Anterior superior spinous process of os ilium
t, Anterior inferior spinous process of os ilium
x, Depression made by psoas and iliacus internus muscles
y, Brim or inlet
ɾ, Spine of os pubis
ɡ, Surface for pectinalis muscle
ɦ, Body of os pubis
ɨ, Crista pubis
ɟ, Attachment of crus penis
ɫ, Symphisis pubis
ɱ, Origin of gracilis muscle
ɲ, Linea-ileo-pectinea
1, Surface for erector penis
2, Surface for adductor magnus muscle
7, Surface for quadratus femoris muscle
8, Spine of os ischii

Fig. 3.—Fetal Pelvis.

H, Body of the os ischii
S, Crista of os ilium
U, Obturator foramen
a, Os sacrum
b, Os coccygis
c, Articular processes of os sacrum
f, Sacro-iliac-synchondrosis
h, Os ilium
n, Foramina for sacral nerves
o, Cartilage of acetabulum
r, Acetabulum
s, Anterior superior spinous process of os ilium
ɦ, Body of os pubis
ɫ, Symphisis pubis
ꝑ, Cartilaginous junction of crura of pubes and ischium

Fig. 4.—Os Coccygis.

a, Surface by which it is articulated to os sacrum
b, Bodies of the different portions
c, Articular processes
d, Shoulders
n, Notch for last spinal nerves

PLATE IV.

Fig. 1.—Front View of Skull.

A, Zygomatic process of os malæ
a, Zygomatic process of temporal bone
d, External angular process of os frontis
e, Temporal ridge
f, Mental foramen
n, Superciliary notch
1, Os frontis
3, Os parietale
7, Os temporis
9, Os sphenoides
11, Os ethmoides
15, Os maxillare superius
17, Os lachrymale
19, Os malæ
23, Os spongiosum inferius
24, Os vomeris
25, Os maxillare inferius

Fig. 2.—Basilar View of Skull.

A, Zygomatic process of os malæ
R, Spheno-maxillary aperture

V, Palatine plate of superior maxillary bone

a, Zygomatic process of temporal bone 7
a, Protuberance of occipital bone
b, Tubercle of zygomatic process of temporal bone
c, Inferior transverse ridge of occipital bone
d, Perpendicular ridge of occipital bone
e, Glenoid cavity
f, Foramen stylo-mastoideum
g, Cuneiform process of os occipitis
i, Condyles of os occipitis

l, Unciform process of sphenoid bone
m, Mastoid process of temporal bone
n, Groove for occipital artery
q, Styloid process
t, Canalis carotideus
w, Foramen lacerum posterius
x, Internal pterygoid process
z, External pterygoid process

ɦ, Superior transverse ridge of occipital bone

4, Foramen ovale
5, Foramen spinosum
7, Temporal bone
22, Palatine plate of os palati
24, Os vomeris

Fig. 3.—Internal Basilar View of Cranium.

b, Crista galli of os ethmoides
c, Transverse spinous process of os sphenoides
h, Orbitary plates of os frontis
i, Groove in os parietale made by lateral sinus
o, Foramen condyloideum posterius
p, Foramen condyloideum anterius
q, Superior portion of internal perpendicular ridge of os occipitis
r, Internal transverse ridge of os occipitis
s, Inferior portion of internal perpendicular ridge of os occipitis
t, Depressions in os occipitis for posterior lobes of cerebrum
u, Depressions in os occipitis for lobes of cerebellum
u, Internal auditory foramen
v, Petrosal ridge

w, Foramen lacerum posterius
y, Fossa in os occipitis for lateral sinus
z, Fossa in os occipitis for lateral sinus

1, Foramen opticum
2, Foramen lacerum anterius
3, Foramen rotundum
4, Foramen ovale
6, Foramen cœcum
7, Temporal bone
10, Anterior clinoid processes
11, Posterior clinoid processes
12, Cella turcica
14, Depression made by decussation of optic nerves
14, Foramen for auditory twig of Vidian nerve
16, Depressions for middle lobes of cerebrum
20, Depression for medulla oblongata

Fig. 4.—Vertical Section of Skull.

B, Nasal process of superior maxillary bone

d, Spinous process of os palati

b, Crista galli of os ethmoides
c, Nasal lamella of os ethmoides
d, Spinous process of os maxillare superius
d, Turbinated portion of os ethmoides
f, Frontal sinuses
f, Ethmoid cells
i, Fossa on parietal bone made by lateral sinus

n, Line of attachment of falx cerebri
o, Spheno-palatine foramen
q, Ridge of occipital bone, affording attachment to falx cerebri
r, Transverse ridge giving attachment to tentorium cerebelli
v, Petrosal ridge
x, Internal pterygoid process of os sphenoides
z, Fossa made by lateral sinus

9, Sphenoid cells
13, Os nasi
23, Os spongiosum inferius

Fig. 5.—Fetal Os Occipitis.

Fig. 6.—Fetal Skull.

a, Anterior fontanelle
b, Posterior fontanelle

1, Frontal bone
3, Parietal bone
7, Temporal bone

Fig. 7.—Vertical Section of a Vertebra.

Fig. 8.—Section of Patella.

Fig. 9.—Fetal Os Sphenoides.

Fig. 10.—Section of Os Femoris.

a, Indicating white line, originally cartilage
b, Indicating white line, originally cartilage

c, Indicating white line, originally cartilage
d, Dense shaft

PLATE V.

BONES OF CRANIUM.

Fig. 1.—External View of Os Frontis.

a, Nasal process
b, Internal angular process
c, Superciliary ridge
d, External angular process
e, Temporal ridge
f, Elevations made by frontal sinuses
g, Centres of ossification in the fetus

h, Orbitary depressions
l, Temporal depression
n, Superciliary foramen

2, Circular serrated edge, forming coronal suture
18, Circular serrated edge, forming coronal suture

Fig. 2.—Internal View of Os Frontis.

a, Nasal process
b, Internal angular process
c, Superciliary ridge
d, External angular process
e, Temporal ridge
h, Orbitary depressions
i, Depression for cartilaginous pulley of superior oblique muscle of eye
k, Depressions for lachrymal glands
m, Depressions assisting to form ethmoid cells

n, Superciliary foramina
o, Apertures of frontal sinuses
q, Ridge giving attachment to falx cerebri
x, Groove made by superior longitudinal sinus

2, Circular serrated edge, forming coronal suture
6, Foramen cœcum
18, Circular serrated edge, forming coronal suture

Fig. 3.—External View of Os Parietale.

a, Superior or coronal side
b, Anterior or glabellar side
c, Inferior or basilar side
d, Posterior or inial side
e, Temporal ridge
f, Anterior inferior angle, or spinous process
g, Superior posterior angle
k, Temporal depression

o, Foramen which transmits a vein that terminates in the superior longitudinal sinus

ɛ, Anterior superior angle
ɦ, Posterior inferior angle

4, Indicating division between squamous suture and its additamentum

Fig. 4.—Internal View of Os Parietale.

a, Superior or coronal side
b, Anterior or glabellar side
c, Inferior or basilar side
d, Posterior or inial side
f, Anterior inferior angle, or spinous process
g, Posterior superior angle

i, Impression made by lateral sinus
n, Groove formed by the superior longitudinal sinus

ɛ, Anterior superior angle
ɦ, Posterior inferior angle

Fig. 5.—External View of Os Occipitis.

a, Central protuberance
c, Inferior transverse ridge
d, Perpendicular ridge
e, Groove made by occipital artery
f, A ridge giving attachment to rectus lateralis muscle
g, Cuneiform process
i, Condyloid processes
k, Foramen magnum

m, Surface to which perpendicular ligament is attached
n, Surface to which lateral ligament is attached
o, Posterior condyloid foramina
p, Anterior condyloid foramina

ɦ, Superior transverse ridge
f, Ridge made by recti antici muscles

Fig. 6.—Internal View of Os Occipitis.

g, Cuneiform process
k, Foramen magnum
o, Posterior condyloid foramina
p, Anterior condyloid foramina
q, Perpendicular ridge giving attachment to falx cerebri
r, Transverse ridge giving attachment to tentorium
s, Perpendicular ridge giving attachment to falx cerebelli
t, Depressions for posterior lobes of cerebrum
u, Depressions for lobes of cerebellum

w, Portion of foramen lacerum posterius
x, Groove made by superior longitudinal sinus
y, Depression made by lateral sinus
z, Groove made by lateral sinus

1, 2, 3, } Serrated edge forming lambdoidal suture
20, Depression made by medulla oblongata

Fig. 7. External View of Os Temporis.

E, Depression which assists in forming glenoid cavity
T, Inner aperture of carotid canal

a, Zygomatic process
b, Oblong elevation, upon which the condyloid process of inferior maxillary bone moves
c, *c*, Squamous portion
d, Maxillary portion
e, Glenoid cavity
f, Stylo-mastoid foramen
g, Fissure of Glasserus
k, Temporal depression

m, Mamillary process
n, Fossa made by occipital artery
q, Styloid process
r, Vaginal process
t, Outer aperture of carotid canal
w, Foramen lacerum posterius
x, Auditory ring

ɦ, Fossa made by digastric muscle
I, Foramen auditorium externum

9, Foramen giving entrance to a vein which joins lateral sinus

Fig. 8.—Internal View of Os Temporis.

a, Zygomatic process
c, *c*, Squamous portion
d, Mamillary portion
q, Styloid process
r, Vaginal process
t, Outer aperture of carotid canal
u, Foramen auditorium internum
v, Petrosal ridge

w, Foramen lacerium posterius
y, *z*, } Fossa made by lateral sinus

j, Groove made by middle meningeal artery

9, Foramen which transmits a vein to join lateral sinus

Fig. 9.—External View of Os Sphenoides.

a, Body of the bone, or azygos process
b, Ethmoidal process
c, Transverse spinous processes
d, Spinous process
e, Styliform process
f, Temporal processes
h, Orbitary plates
i, Groove made by temporal twig of superior maxillary nerve
k, Temporal depressions
l, Unciform processes
m, Triangular processes
x, Internal pterygoid processes
z, External pterygoid processes

1, Foramina optica
2, Foramina lacera anteriora
3, Foramina rotunda
4, Foramina ovalia
5, Foramina spinosa
8, Foramina Vidiana
9, Apertures to sphenoidal cells

Fig. 10.—Internal View of Os Sphenoides.

b, Ethmoidal process
c, Transverse spinous processes
d, Spinous processes
e, Styliform processes
, Temporal processes
l, Unciform processes
x, Internal pterygoid processes
z, External pterygoid processes

g, Cuneiform process

1, Foramina optica
2, Foramina lacera anteriora
3, Foramina rotunda
4, Foramina ovalia
5, Foramina spinosa
8, Foramina Vidiana
10, Anterior clinoid processes
11, Posterior clinoid processes
12, Depression for pituatary gland
13, Fossæ made by carotid arteries
14, Groove made by optic nerve
16, Depressions which lodge middle lobes of cerebrum

Fig. 11.—Internal View of Os Ethmoides.

a, Cribriform lamella
b, Crista galli
e, Ossa plana

Fig. 12.

c, Nasal lamella
d, Turbinated portions
e, Ossa plana
f, Ethmoidal sinuses

PLATE VI.

BONES OF THE FACE.

Fig. 13.—External View of Os Nasi.

H, Superior edge
N, Inferior edge
b, Superior or glabellar extremity

Fig. 14.—Internal View of Os Nasi.

H, Superior edge
N, Inferior edge
b, Superior or glabellar extremity

Fig. 15.—External View of Superior Maxillary Bone.

B, Nasal process
D, Lachrymal depression
H, Orbitary process

d, Spinous process
g, Bulbous process
l, Malar process
n, Alveolar processes
o, Infra-orbitary foramen or canal
p, Origin of levator anguli oris
q, Origin of depressor labii superioris
r, Origin of inferior oblique muscle of the eye
t, Point where the ligament of the tarsi is fixed

Fig. 16.—Internal View of Superior Maxillary Bone.

A, Antrum maxillare
B, Nasal process
C, Point of connexion with orbitary process of os palati
D, Lachrymal depression
V, Palatine process

b, Incisive hole
d, Spinous process
e, Ridge which supports the inferior spongy bone
s, Fossa contributing to form palato-maxillary canal
x, Pterygoid depression for palate bone
z, Pterygoid depression for palate bone

Fig. 17.—Orbitary View of Lachrymal Bone.

E, Perpendicular ridge
F, Orbitary plate
G, Lachrymal depression

Fig. 18.—Nasal View of Lachrymal Bone.

Fig. 19.—External View of Os Malæ.

A, Zygomatic process
D, Superior orbitary process
K, Maxillary process
L, Inferior orbitary process

Fig. 20.—Internal View of Os Malæ.

A, Zygomatic process
D, Superior orbitary process
K, Maxillary process
L, Inferior orbitary process

b, Orbitary depression
k, Temporal depression

Fig. 21.—Internal or Nasal View of Os Palati.

E, Ridge that gives support to inferior spongy bone
P, Nasal lamella

d, Spinous ridge

a, Anterior or proper orbitary process
b, Posterior orbitary process
n, Palatine plate
o, Spheno-palatine foramen
x, Pterygoid portion

Fig. 22.—External View of Os Palati.

P, Nasal lamella

d, Spinous ridge

a, Anterior or proper orbitary process
b, Posterior orbitary process
n, Palatine plate
o, Spheno-palatine foramen
s, Palato-maxillary canal
x, Internal pterygoid depression
y, Middle pterygoid depression
z, External pterygoid depression

Fig. 23.—External or Antral View of Inferior Spongy Bone.

Fig. 24.—Vomer.

a, Depression that receives azygos process of sphenoid bone
b, Edge joined to cartilaginous septum
c, Edge joined to nasal lamella of ethmoid bone
d, Edge joined to spinous ridges of superior maxillary and palate bones

Fig. 25.—External View of Inferior Maxillary Bone.

M, Alveolar processes

a, Base
b, Condyles
c, Symphysis menti
d, Angle
e, Cervix
f, Mental foramen
g, Ridge for buccinator muscle
h, Point of origin of levator labii inferioris
i, Point of origin of depressor labii inferioris
k, Coronoid processes
o, Point of attachment of external pterygoid muscle

Fig. 26.—Internal View of Inferior Maxillary Bone.

b, Condyles
d, Angle
e, Cervix
k, Coronoid processes
m, Point of origin of anterior heads of digastric muscles
n, Point of origin of genio-hyoglossi muscles
o, Point of insertion of external pterygoid muscle
p, Ridge for mylo-hyoideus muscle
q, Rough surface for insertion to internal pterygoid muscle
r, Foramen that gives entrance to osseous branch of inferior maxillary nerve, &c.
s, Groove made by mylo-hyoideal twig of inferior maxillary nerve

Fig. 27 —Internal View of Superior Maxillary and Palate Bones joined.

A, Antrum maxillare
B, Nasal process
D, Lachrymal fossa
P, Nasal lamella of palate bone
V, Palatine plate of superior maxillary bone

d, Spinous ridge of palate bone

d, Spinous ridge of superior maxillary bone
n, Palatine plate of palate bone
x, Pterygoid depression of palate bone
z, Pterygoid depression of palate bone

16 Only indicates the superior maxillary bone, as
21 Points out the palate bone, and
23 Marks the inferior spongy bone

Fig. 28.—View of Deciduous and Permanent Teeth.

Fig. 29.—External View of Frontal, Ethmoidal, Sphenoidal, and Occipital Bones in connexion.

d, Turbinated portions of ethmoid bone
f, Ethmoid cells
k, Foramen magnum
2, Foramina lacera anteriora
3, Foramina rotunda
4, Foramina ovalia
5, Foramina spinosa
8, Foramina Vidiana

PLATE VII.

Fig. 1.—View of the Dorsum Scapulæ.

A, Surface of teres major muscle

a, Point of origin of long head of triceps muscle

a, Inferior costa
a, Surface of teres minor muscle
b, Superior costa
c, Base or insertion of rhomboidei muscles
d, Posterior superior angle
e, Anterior superior angle
f, Inferior angle
g, Infra-spinal fossa
h, Spine
o, Supra-scapular notch
r, Point of insertion of levator scapulæ muscle
g, Supra-spinal fossa

2, Cervix
3, Origin of long head of biceps muscle
5, Coracoid process
6, Acromion process
7, Point of attachment of proper anterior ligament of scapula
9, Point of attachment of conoid and trapezoid ligaments

Fig. 2.—View of the Venter Scapulæ.

a, Origin of long head of triceps muscle
b, Superior costa
d, Posterior superior angle
e, Anterior superior angle, or glenoid cavity
f, Inferior angle
i, Subscapular fossa
k, Base or line of insertion of serratus magnus muscle
o, Supra-scapular notch
2, Cervix
3, Point of origin of long head of biceps muscle
5, Coracoid process
6, Acromion process
8, Surface to which the clavicle is articulated
9, Point of attachment of conoid and trapezoid ligaments

Fig. 3.—Anterior or Palmar View of Os Brachii.

a, Shaft of the bone
b, Trochlear surface
c, Head
d, Trochlear surface on which radius moves
e, Cervix
f, Internal or ulnar tubercle
g, Radial or external tubercle
h, Bicipital fossa
i, Scabrous surface made by coraco-brachialis muscle
l, Internal or ulnar ridge affording origin to pronator and flexor muscles
m, Internal or ulnar ridge of bicipital groove
n, External or radial ridge of bicipital groove
o, Rough surface made by deltoid muscle
p, Internal or ulnar condyle
q, External or radial condyle
y, Lesser sigmoid cavity

Fig. 4.—Posterior or Anconal View of Os Brachii.

g, Point of attachment of teres minor muscle
y, Groove made by ulnar nerve
a, Shaft of the bone
b, Trochlear surface
c, Head
e, Cervix
k, External or radial ridge giving origin to supinators and extensors
l, Internal or ulnar ridge giving origin to pronator and flexor muscles
o, Surface into which is inserted the deltoid muscle
p, Inner or ulnar condyle
q, Outer or radial condyle
r, Ridge affording origin to second head of the triceps muscle
s, Ridge for third head of the triceps muscle
t, Channel made by spiral nerve
z, Greater sigmoid cavity

Fig. 5.—Anterior, or Palmar, or Thenal View of Ulna and Radius.

a, Body or shaft of radius
b, Tubercle of radius
c, Cervix of radius
d, Smooth surface around head of radius
e, Cup-like cavity of head of radius
f, Ridge giving insertion to supinator radii brevis
g, Surface affording insertion to pronator radii teres
h, Ulnar angle of radius to which interosseous ligament is attached
i, Foramen for nutritious artery
k, Surface for insertion of pronator quadratus
l, Surface for insertion of supinator radii longus
s, Styloid process
t, Greater sigmoid cavity
1, Body or shaft of ulna
2, Point affording insertion to triceps muscle
3, Coronoid process
4, Point of attachment of ulnar lateral ligament of elbow joint
5, Olecranon
6, Ancon
8, Greater sigmoid cavity
10, Radial angle giving attachment to interosseous ligament
11, Foramen for medullary vessels
14, Styloid process
16, Groove made by ulnar artery and nerve
17, Smooth surface opposed to cuneiform bone of wrist
18, Oblique ridge affording insertion to pronator quadratus

Fig. 6.—Posterior or Anconal View of Ulna and Radius.

a, Body of radius
c, Cervix
d, Smooth circular surface around head of radius
g, Scabrous surface into which pronator teres is inserted
h, Ulnar angle of radius to which interosseous ligament is attached
n, Tubercle on distal extremity of radius
o, Groove made by extensor secundi internodii pollicis
p, Groove made by extensor digitorum communis and indicator muscles
q, Depression made by radial extensors
r, Groove made by extensor ossis metacarpi and extensor primi internodii pollicis
s, Styloid process
z, Lesser sigmoid cavity of radius
1, Body or shaft of ulna
2, Insertion of triceps muscle
5, Olecranon
6, Ancon
7, Insertion of anconeus muscle
12, Attachment of flexor ulnaris muscle
13, Smooth surface opposed to lesser sigmoid cavity of radius
14, Styloid process
15, Groove made by extensor carpi ulnaris

Fig. 7.—View of the Back of the Hand.

a, Os scaphoides
b, Os lunare
c, Os cuneiforme
e, Os trapezium
f, Os trapezoides
g, Os magnum
h, Os unciforme
1, Metacarpal bone of thumb
2, Metacarpal bone of fore finger
3, Metacarpal bone of middle finger
4, Metacarpal bone of ring finger
5, Metacarpal bone of little finger
6, First bone of thumb
7, First bone of fore finger

Fig. 7. (Continued).

8, First bone of middle finger
9, First bone of ring finger
10, First bone of little finger
11, Second bone of fore finger
12, Second bone of middle finger
13, Second bone of ring finger
14, Second bone of little finger
15, Last bone of thumb
16, Third or last bone of fore finger
17, Third or last bone of middle finger
18, Third or last bone of ring finger
19, Third or last bone of little finger

Fig. 8.—View of the Palm of the Hand.

a, Os scaphoides
b, Os lunare
c, Os cuneiforme
d, Os pisiforme
e, Os trapezium
f, Os trapezoides
g, Os magnum
h, Os unciforme
1, Metacarpal bone of thumb
2, Metacarpal bone of fore finger
3, Metacarpal bone of middle finger
4, Metacarpal bone of ring finger
5, Metacarpal bone of little finger
6, First bone of thumb
7, First bone of fore finger
8, First bone of middle finger
9, First bone of ring finger
10, First bone of little finger
11, Second bone of fore finger
12, Second bone of middle finger
13, Second bone of ring finger
14, Second bone of little finger
15, Last bone of thumb
16, Last or third bone of fore finger
17, Last or third bone of middle finger
18, Last or third bone of ring finger
19, Last or third bone of little finger
20, Sesamoid bones on head of metacarpal bone of thumb
21, Lateral ridges affording attachment to vaginal ligaments of flexor muscles
22, Points of insertion of flexor digitorum sublimis
23, Points of insertion of flexor digitorum profundus

PLATE VIII.

Fig. 1—Posterior or Dorsal View of Os Sacrum.

a, Body
c, Articular processes
d, Sacro-iliac-synchondrosal surface
e, Spinous processes
g, Tubercle for sacro-ischiadic ligaments
l, Canal for cauda equina
n, Foramina for sacral nerves

Fig. 2.—External View of Os Innominatum.

H, Tuberosity of os ischii
R, Acetabulum
S, Crista of os ilium
U, Obturator foramen
ɥ, Body of os pubis
ʝ, Attachment of crus penis
q, Origin of adductor brevis muscle
w, Niche for passage of obturator vessels
a, Origin of gluteus maximus muscle
b, Origin of gluteus medius muscle
c, Origin of gluteus minimus muscle
d, Origin of tensor vaginæ femoris muscle
e, Attachment of capsular ligament of hip-joint
s, Anterior superior spinous process of os ilium
f, Posterior superior spinous process of os ilium
t, Inferior anterior spinous process of os ilium
v, Inferior posterior spinous process of os ilium
z, Arch of great sacro-ischiadic notch
1, Origin of erector penis
2, Origin of adductor magnus
3, Origin of biceps and semi-tendinosus muscles
4, Origin of semi-membranosus muscle
5, Origin of gemellus inferior muscle
6, Attachment of long or outer sacro-ischiadic ligament
8, Spine of os ischii
9, Sinuosity around which the obturator internus muscle plays
10, Deficiency of osseous brim of acetabulum
12, Highest margin of acetabulum

Fig. 3.—Anterior or Patellar View of Os Femoris.

a, Body or shaft
b, Head
c, Depression for attachment of ligamentum teres
d, Cervix
e, Trochanter major, where it gives attachment to gluteus minimus muscle
f, Trochanter minor
g, Ridge to which capsular ligament is attached
i, Rut at trochanter major, giving insertion to pyriformis, obturator externus and internus, with gemelii muscles
k, Point of insertion of triceps muscle
m, Trochlear surface opposed to patella
n, Trochlear surface opposed to patella
ɛ, Point of attachment of gluteus medius muscle

Fig. 4.—Posterior or Popliteal View of Os Femoris.

a, Superior tibial division of linea aspera, affording attachment to pectinalis muscle
e, Smooth surface made by gluteus maximus
a, Linea aspera
b, Head
d, Cervix
f, Trochanter minor
h, Ridge affording attachment to quadratus femoris muscle
i, Rut at the root of trochanter major, giving insertion to several muscles

Fig. 4. (Continued).

k, Point of insertion of triceps muscle
l, Smooth surface of linea aspera, made by superficial femoral artery and vein
m, Internal condyle
n, External condyle
p, Tubercle giving origin to fibular head of gastrocnemius externus muscle
r, Surface giving origin to tibial head of gastrocnemius externus muscle
s, Fossa giving origin to popliteus muscle
t, Cavity or notch, to which are attached crucial ligaments
a, Superior fibular division of linea aspera, affording attachment to gluteus maximus muscle
c, Point of attachment of gluteus medius muscle

Fig. 5.—External View of Patella.

a, Point of insertion of rectus and crureus muscles
b, Point of insertion of vastus internus muscle
c, Point of insertion of vastus externus muscle
d, Point of attachment of patellar ligament

Fig. 6.—Internal or Popliteal View of Patella.

d, Point of attachment of patellar ligament
e, Point of attachment of capsular ligament
m, Surface opposed to internal condyle of os femoris
n, Surface opposed to external condyle of os femoris

Fig. 7.—Anterior or Patellar View of Tibia and Fibula.

a, Body or shaft of tibia
d, Tubercle of tibia
e, Surface into which inner hamstring muscles are inserted
h, Surface to which fibula is articulated
q, Styloid process or malleolus internus of tibia
m, Fibular angle affording attachment to interosseous ligament
r, Smooth articular surface for astragalus
s, Rough depression affording attachment to fibula
1, Exterior angle of body or shaft of fibula
2, Proximal extremity of fibula
4, Tibial angle giving attachment to interosseous ligament
9, Distal extremity of fibula
10, Coronoid process or malleolus externus
11, Smooth surface opposed to astragalus

Fig. 8.—Posterior or Popliteal View of Tibia and Fibula.

b, Elevation on head of tibia, giving attachment to crucial ligaments
c, Smooth depressions on head of tibia
f, Point of insertion of semi-membranosus muscle
g, Point of attachment of posterior crucial ligament

Fig. 8 (Continued).

i, Smooth surface made by popliteus muscle
k, Oblique ridge made by gastrocnemius internus muscle
m, Fibular angle giving insertion to interosseous ligament
n, Foramen for nutritious vessels
n, Groove made by flexor longus digitorum pedis and tibialis posticus muscles
o, Posterior tibial angle made by tibialis posticus muscle, &c.
p, Groove made by flexor longus muscle
q, Styloid process or malleolus internus
1, Exterior angle of body or shaft of fibula
2, Proximal extremity of fibula
3, Foramen for nutritious vessels
4, Tibial angle giving attachment to interosseous ligament
6, Surface giving origin to fibular head of gastrocnemius internus muscle
9, Distal extremity of fibula
10, Coronoid process or malleolus externus
12, Cavity for mucilaginous glands
13, Groove made by peronei muscles

Fig. 9.—View of Upper Part of the Foot.

a, Surface opposed to fibula
a, Os astragalus
b, Os naviculare
c, Os calcis
d, Os cuneiforme internum
e, Os cuneiforme medium
f, Os cuneiforme externum
g, Os cuboides
k, Depression made by flexor longus pollicis pedis
m, Smooth projection of astragalus
n, Smooth surface of naviculare, where it joins cuboides
t, Projection of metatarsal bone of little toe, affording insertion to peroneus brevis muscle
c, Smooth surface of os calcis opposed to os cuboides, *g*
g, Fossa made by peroneus longus muscle
1, Situated on os naviculare, *b*, indicates surface opposed to os cuneiforme internum, *d*
1, Metatarsal bone of great toe
2, Situated on os naviculare, *b*, indicates surface opposed to os cuneiforme medium, *e*
2, Situated on os cuneiforme externum, *f*, indicates surface opposed to metatarsal bone, 2, of index toe
2, Metatarsal bone of index toe
3, Situated on os naviculare, *b*, indicates surface opposed to os cuneiforme externum, *f*
3, Situated on os cuneiforme externum, *f*, indicates surface opposed to metatarsal bone, 3, of middle toe
3, Metatarsal bone of middle toe
4, Situated on os cuneiforme externum, *f*, indicates surface opposed to metatarsal bone of ring toe, 4
4, Metatarsal bone of ring toe
5, Metatarsal bone of little toe
6, First bone of great toe
7, Last bone of great toe
8, First bone of index toe
9, Second bone of index toe
10, Third bone of index toe
11, First bone of middle toe
12, Second bone of middle toe
13, Third bone of middle toe
14, First bone of ring toe
15, Second bone of ring toe
16, Third bone of ring toe
17, First bone of little toe
18, Second bone of little toe
19, Third bone of little toe

INDEX

TO

THE LETTERS OF REFERENCE

IN

THE BLOOD-VESSELS AND NERVES OF THE HEAD AND TRUNK.

PLATE IX.

A, Ribs
B, Diaphragm
C, Pericardium
D, Right ventricle of the heart
E, Aorta
F, Pulmonary artery arising from right ventricle D of heart
F, Spleen
G, Lungs
H, Subclavian arteries
I, Œsophagus
K, Trachea
L, Scalenus anticus muscle
M, Internal jugular veins
N, Vertebral veins
O, Trunk of thyroideal veins
P, Carotid arteries
Q, Arteria innominata
R, Vertebral artery
S, Inferior thyroideal artery
T, External iliac artery
U, External iliac vein

a, Muscular parietes of abdomen
b, Stomach
c, Duodenum
d, Right auricle of heart
e, Gall bladder
f, Suspensory ligament of heart
g, Round ligament of liver
h, Great omentum
i, Liver
k, Uterus
m, Urinary bladder
p, Gastric artery
q, Hepatic artery
r, Splenic artery
s, Arteria gastro-epiploica dextra
w, Arteria gastro-epiploica sinistra
x, Epigastric artery

a, Peritoneum
d, Left auricle of heart
h, Vena cava superior
k, Broad ligament of uterus
l, Round ligament of uterus
r, Right coronary artery
s, Left coronary artery
t, Vena azygos
u, Right subclavian vein
v, Left subclavian vein
x, Epigastric vein

1, Nervus vagus
2, Left pulmonary veins
3, Twigs of cœliac plexus
6, Nervous threads of great intercostal nerve
7, Great intercostal nerve
8, Phrenic nerve
10, Recurrent twigs of par vagum
11, Cardiac nerve
14, Internal mammary arteries

PLATE X. Fig. 1.

D, Right ventricle
E, Aorta
F, Pulmonary artery

d, Right auricle
f, Right and left branches of pulmonary artery
g, Left ventricle

d, Auricular portion of left auricle
h, Vena cava descendens
i, Vena cava ascendens
k, Coronary vein and branches
r, Right coronary artery
s, Left coronary artery

1, Right pulmonic veins
2, Left pulmonic veins

Fig. 2.

D, Right ventricle
E, Aorta
O, Tricuspid valve

d, Auricular portion of right auricle
l, Fossa ovalis
m, Tuberculum Loweri

n, Eustachian valve
s, Left coronary artery

h, Vena cava descendens
i, Vena cava ascendens
k, Entrance of coronary vein and valve

Fig. 3.

D, Right ventricle
E, Aorta
F, Pulmonary artery

d, Right auricle
f, Branches of pulmonary artery

l, Foramen ovale
n, Eustachian valve

f, Ductus arteriosus
h, Vena cava descendens
i, Vena cava ascendens

PLATE X. Fig. 4.

E, Aorta
F, Pulmonary artery
O, Tricuspid valve

p, Columnæ carneæ

q, Semilunar valves of pulmonary artery

d, Left auricle
g, Left ventricle
s, Left coronary artery

Fig. 5.

E, Aorta
F, Pulmonary artery

d, Left auricle
g, Septum ventriculorum

p, Columnæ carneæ of mitral valve
q, Semilunar valves of aorta
o, Mitral valve

Fig. 6.

A, Ribs
D, Heart
E, Aorta
F, Pulmonary artery
G, Lungs
P, Common iliac arteries
T, External iliac arteries
Y, Kidney

d, Venæ hepaticæ
e, Aorta descendens

f, Branches of pulmonary artery
g, Umbilical vein
i, Liver
m, Urinary bladder

f, Ductus arteriosus
f, Ureter leading from kidney
h, Vena cava descendens
i, Vena cava ascendens
n, Umbilical arteries

PLATE XI. Fig. 1.

A, Musculo-ligamentous membrane of trachea
G, Lungs
K, Trachea

a, Muscular fibres of trachea
b, Bronchial glands
c, Vascular mucous membrane of trachea

f, Branches of pulmonary artery
k, Bronchi

k, Subdivision of bronchial tubes

1, Branches of pulmonary veins
2, Branches of pulmonary veins

Fig. 2.

B, Sterno-costalis muscle

e, Sternum

14, Internal mammary arteries

Fig. 3.

M, Internal jugular vein
V, Distal extremity of subclavian vein

a, Valves of veins
v, Proximal extremity of subclavian vein

Fig. 4.

a, Brachial artery
a, External or cellular coat of artery

a, Middle or muscular coat of artery

1, Internal or serous coat of artery

PLATE XII.

A, Ribs
B, Diaphragm
D, Pancreas
E, Thoracic aorta
F, Spleen
G, Lungs
H, Subclavian arteries
I, Œsophagus
K, Jejunum
L, Ileum
M, Caput cæcum coli
N, Vena portæ
O, Ascending portion of colon
P, Transverse arch of colon, continuation of ascending portion O
P, Carotid arteries arising from arch of aorta, E
Q, Arteria innominata arising from arch of aorta, E
Q, Mesentery
R, Superior mesenteric artery distributed on intestines
R, Left vertebral artery arising from subclavian artery, H
S, Ascending thyroideal artery
T, Dorsal vertebræ
U, Superior mesenteric vein

c, Duodenum
d, Hepatic veins
e, Gall bladder
h, Omentum majus
i, Liver
k, Lobulus Spigelii of liver
k, Left bronchial tube under arch of aorta, E
p, Gastric artery
q, Hepatic artery
r, Splenic artery
w, Arteria gastro-epiploica sinistra
z, Diaphragmatic artery

R, Mesentery

a, Œsophageal plexus of nerves
b, Œsophageal arteries
e, Ductus cysticus
f, Ductus hepaticus
g, Ductus communis coledochus
i, Vena cava ascendens
n, Branches of vena portæ
s, Splenic vein
t, Ileo-colic artery
u, Arteria colica dextra
v, Arteria colica media
y, Gastric vein

1, Nervus vagus
2, Pulmonic plexus of nerves
3, Bronchial arteries
4, Bronchial vein
5, Vena azygos
7, Great intercostal nerve
9, Individual intercostal nerves
10, Recurrent of nervus vagus
11, Cardiac twigs of sympathetic nerve
12, Intercostal arteries
14, Nervous twigs from great intercostal nerve contributing to form pulmonic plexus
15, Intercostal veins
16, Nervous thread from great intercostal nerve, joining œsophageal plexus
17, Twigs of great intercostal nerve, forming splanchnic nerve
29, Appendix vermiformis

PLATE XIII.

A, Ribs
B, Diaphragm
C, Renal artery
C, Quadratus lumborum muscle
E, Thoracic aorta
F, Ureter
G, Supra-renal gland
H, Inferior mesenteric vein
I, Œsophagus close to aorto, E
I, Rectum, continuation of colon, *z*
K, Psoas magnus muscle
L, Renal veins
M, Psoas parvus muscle
N, Ovaria
O, Common iliac veins
P, Common iliac arteries
R, Superior mesenteric artery
T, External iliac artery
U, External iliac vein
V, Internal iliac artery
W, Iliacus internus muscle
Y, Kidney

b, Inferior mesenteric artery
d, Hepatic vein
e, Abdominal aorta
f, Ureter
k, Uterus
m, Urinary bladder
p, Gastric artery
q, Hepatic artery
r, Splenic artery
x, Epigastric artery
y, Ilio-lumbar artery
z, Diaphragmatic artery

a, Arteria colica sinistra, branch of inferior mesenteric artery, b
a, Semilunar ganglia of splanchnic nerves, 17
b, Internal hemorrhoidal artery
c, Circumflex iliac artery
g, Spermatic arteries
i, Vena cava ascendens
k, Fallopian tubes
l, Round ligaments of uterus
s, Splenic vein
z, Sigmoid flexure of colon

1, Nervus vagus of right side
7, Trunk of intercostal nerve
8, Ganglia of solar plexus
9, Ganglion of left great intercostal nerve
17, Splanchnic nerve

PLATE XIV.

A, Symphysis pubis
B, Sacrum
C, Renal artery
D, Vagina
E, Thoracic aorta
F, Bodies of lumbar vertebræ
I, Rectum
K, Part of psoas magnus muscle
O, Common iliac vein
P, Common iliac arteries
R, Superior mesenteric artery
T, External iliac artery
U, External iliac vein
V, Internal iliac artery
W, Part of Iliacus internus muscle

b, Body of sacrum
b, Inferior mesenteric artery, branch of abdominal aorta, e
e, Abdominal aorta
k, Fundus of uterus
m, Urinary bladder
n, Cœliac artery
p, Gastric artery
q, Hepatic artery
r, Splenic artery
z, Diaphragmatic artery

a, Sacro-lateral arteries
c, Gluteal arteries
d, Obturator arteries
e, Uterine arteries
f, Ischiadic arteries
g, Spermatic arteries, deriving their origin from abdominal aorta, e

PLATE XIV. (Continued).

g, Middle hemorrhoidal artery, branch of internal iliac artery, V
h, Internal pudic arteries
i, Vena cava ascendens
n, Umbilical artery
p, Sacro-median artery
r, External hemorrhoidal artery
t, Lumbar arteries

3, Last dorsal nerve
6, Lumbar nerves
7, Trunk of great intercostal nerve
9, Ganglion on left common iliac artery
20, Great sacro-ischiadic nerve
21, Obturator nerve
22, Anterior crural nerve

PLATE XV.

A, Clavicle
G, External carotid artery
H, Right subclavian artery
K, Trachea
L, Scalenus anticus muscle
M, Internal jugular vein truncated
N, Cricoid cartilage
O, Inferior thyroideal veins
P, Common carotid artery
Q, Arteria innominata
S, Thyroid cartilage above cricoid cartilage, N
S, Inferior thyroideal artery near scalenus anticus muscle, L
X, Os hyoides
Y, Inferior constrictor muscle of pharynx

a, Crico-thyroideus muscle
p, Splenius capitis
v, Inferior maxillary branch of internal maxillary artery

Z, Thyroid gland

a, Superior thyroid artery
b, Lingual artery
c, Facial artery
f, Internal maxillary artery
g, Temporal artery
h, Ascending pharyngeal artery
i, Hyo-glossus muscle
k, Genio-hyo-glossus muscle
l, Genio-hyoideus muscle
q, Styloid process
r, Deep cervical artery

1, Nervus vagus
3, Lingual nerve
4, Nervus mandibulo-labialis
4, Cardiac twig of nervus vagus
5, Middle meningeal artery
6, Inferior maxillary nerve
7, Great intercostal nerve
8, Phrenic nerve
9, Axillary plexus of nerves
10, Recurrent of nervus vagus
11, Cardiac nerve of intercostal, 7
12, Accessory nerve of nervus vagus
13, Glosso-pharyngeal nerve
19, Internal carotid artery
21, First cervical nerve
22, Second cervical nerve
23, Third cervical nerve
24, Fourth cervical nerve
31, Nervous twig to mylo-hyoideus muscle
32, Lingual branch of inferior maxillary nerve
33, Chorda tympani nerve
40, Levator scapulæ muscle
50, Scalenus posticus muscle
51, Supra-scapular artery
52, Superficial cervical artery
55, Superior laryngeal nerve
60, Lingualis muscle
64, First rib
80, Sublingual gland

PLATE XVI.

A, Clavicle
B, Sterno-thyroideus muscle
D, External jugular vein
E, Sterno-cleido-mastoideus muscle
G, External carotid artery
H, Subclavian artery
I, Œsophagus
L, Scalenus anticus muscle
M, Internal jugular vein
P, Common carotid artery
S, Thyroid cartilage
T, Superior laryngeal veins
X, Os hyoides
Y, Constrictor pharyngis inferior muscle
Z, Thyro-hyoideus muscle

h, Buccinator muscle
k, Stylo-pharyngæus muscle
m, Stylo-glossus muscle
n, Internal pterygoid muscle
p, Splenius capitis muscle
t, External pterygoid muscle

a, Superior thyroid artery
b, Lingual artery
c, Facial artery
d, Occipital artery
e, Auricular artery
f, Internal maxillary artery
g, Temporal artery
h, Ascending pharyngeal artery
i, Hyo-glossus muscle
m, Mylo-hyoideus muscle
p, Pharynx
u, Subclavian vein

3, Lingual nerve
5, Descendens noni nerve
8, Phrenic nerve
9, Axillary plexus of nerves
12, Accessory nerve of nervus vagus
13, Glosso-pharyngeal nerve
19, Internal carotid artery
22, Second cervical nerve
23, Third cervical nerve
24, Fourth cervical nerve
25, Inferior maxillary bone
40, Levator scapulæ muscle
44, Facial nerve
51, Supra-scapular artery
52, Superficial cervical artery
55, Superior laryngeal nerve
64, First rib
80, Trapezius muscle

PLATE XVII.

A, Clavicle
C, Sterno-hyoideus muscle
D, External jugular vein
E, Sterno-cleido-mastoideus muscle
G, External carotid artery
H, Subclavian artery
M, Internal jugular vein
P, Common carotid artery
T, Laryngeal veins
U, Omo-hyoideus muscle
V, Lymphatic glands
W, Posterior head of digastric and stylo-hyoideus muscles
X, Os hyoides
Z, Facial vein

PLATE XVII. (Continued.)

a, Zygomaticus major muscle
h, Buccinator muscle
l, Masseter muscle
o, Levator anguli oris muscle
u, Temporal muscle
y, Temporal vein

a, Superior thyroid artery
c, Facial artery
d, Occipital artery
e, Auricular artery
f, Mental foramen
g, Temporal artery
m, Mylo-hyoideus muscle
n, Submaxillary gland
o, Infra-orbitary foramen
w, Anterior head of digastric muscle

2, Infra-orbitary nerve
3, Lingual nerve
4, Mental nerve
5, Descendens noni nerve
9, Axillary plexus of nerves
12, Accessory nerve of nervus vagus
20, Zygomatic process of temporal bone
22, Second cervical nerve
23, Twigs of third cervical nerve
40, Levator scapulæ muscle
44, Facial nerve
51, Supra-scapular artery
52, Superficial cervical artery
80, Trapezius muscle

PLATE XVIII.

A, Clavicle
E, Sterno-cleido-mastoideus muscle
F, Platysma myoides muscle

a, Zygomaticus major muscle
b, Depressor anguli oris muscle
e, Zygomaticus minor muscle
f, Orbicularis oris muscle
h, Buccinator muscle
i, Levator labii superioris alæque nasi
l, Masseter muscle
n, Compressor naris muscle
q, Occipito-frontalis muscle
r, Attollens aurem muscle
s, Parotid gland

w, Orbicularis palpebrarum muscle
x, Parotid duct
y, Temporal vein
z, Facial vein

c, Facial artery
d, Occipital artery
g, Temporal artery
z, Frontal branch of facial vein

2, Infra-orbitary nerve
23, Twigs of third cervical nerve
70, Depressor labii inferioris muscle
90, Occipital vein
91, Frontal branch of ophthalmic artery

INDEX

TO

THE LETTERS OF REFERENCE

IN THE

BLOOD-VESSELS AND NERVES OF THE UPPER AND LOWER EXTREMITIES.

PLATE XIX. Fig. 1.

A, Clavicle
B, Deltoid muscle
C, Greater pectoral muscle
D, Lesser pectoral muscle
E, Latissimus dorsi muscle
F, Teres major muscle
G, Long head of triceps muscle
H, Axillary artery
K, Coraco-brachialis muscle
L, Biceps muscle
O, Serratus magnus muscle

a, Thoracic arteries
c, Internal branch of subscapular artery
d, Posterior circumflex artery
e, Anterior circumflex artery
f, Profunda superior artery
g, Second head of triceps muscle
h, Brachial artery
k, Profunda inferior artery
m, Anastomoticus artery

q, Basilic vein
r, Cephalic vein
u, Brachial vein

a, Axillary glands
c, Scapular circumflex, branch of subscapular artery
g, Third head of triceps muscle
u, Axillary vein

1, Axillary plexus of nerves
2, Median nerve
3, External cutaneous nerve
4, Internal cutaneous nerve
5, Ulnar nerve
6, Spiral nerve
7, Thoracic nerves
9, Intercosto-humeral nerves, and cutaneous nerve of Wrisberg
14, Branches of internal mammary artery

Fig. 2.

I, Pronator radii teres muscle
N, Supinator radii longus muscle
P, Flexor carpi radialis muscle
Q, Palmaris longus muscle
R, Flexor digitorum sublimis muscle
S, Flexor carpi ulnaris muscle
T, Pisiform bone
V, Palmar aponeurosis
Y, Abductor pollicis muscle
Z, Flexor brevis pollicis muscle

h, Brachial artery
l, Tendinous expansion of biceps muscle
o, Radial artery
q, Basilic vein

r, Cephalic vein
s, Median vein
t, Median basilic vein
v, Median cephalic vein

h, Ulnar artery
x, Thenal branch of the radial artery

2, Median nerve
3, External cutaneous nerve
4, Internal cutaneous nerve
5, Ulnar nerve
16, Cutaneous twig of the spiral nerve
36, Thenal twig of the spiral nerve
46, Anconal twig of the spiral nerve

PLATE XX. Fig. 1.

A, The clavicle
B, Deltoid muscle
D, Acromion scapulæ
E, Latissimus dorsi muscle
F, Teres major muscle
G, Long head of triceps muscle
H, Axillary artery
L, Biceps muscle
M, Brachieus internus muscle
N, Supinator radii longus muscle

d, Posterior circumflex artery
f, Profunda superior artery
g, Second head of triceps muscle
i, Radial recurrent artery

a, Proper posterior ligament of scapula
c, Scapular circumflex branch of subscapular artery
u, Brachial vein

1, Axillary plexus
6, Spiral nerve
8, Supra-scapular nerve
51, Supra-scapular artery
66, Supra-spinatus muscle
80, Teres minor muscle
81, Infra-spinatus muscle

Fig. 2.

I, Pronator radii teres muscle
N, Supinator radii longus muscle
P, Flexor carpi radialis muscle
Q, Palmaris longus muscle
R, Flexor digitorum sublimis muscle
S, Flexor carpi ulnaris muscle
T, Pisiform bone
U, Annular ligament
W, Flexor digitorum profundus muscle
X, Flexor longus pollicis muscle
Z, Flexor brevis pollicis muscle

PLATE XX. Fig. 2, (Continued.)

h, Brachial artery
i, Radial recurrent artery
n, Ulnar recurrent artery
o, Radial artery
p, Interosseous artery

h, Ulnar artery, and superficial palmar arch
o, Deep palmar arch of radial artery
w, Adductor pollicis muscle

2, Median nerve

5, Ulnar nerve
6, Spiral nerve
12, Interosseal nerve
15, Dorsal, or anconal twig of ulnar nerve
16, Cutaneous twig of spiral nerve
26, Deep branch of spiral nerve
50, Pronator quadratus muscle
51, Abductor minimi digiti muscle
52, Near z, Flexor ossis metacarpi pollicis muscle
52, Near 51, Flexor parvus minimi digiti muscle

PLATE XXI.

B, Extensor carpi ulnaris muscle
D, Extensor digitorum communis muscle
U, Posterior portion of annular ligament

o, Radial artery
q, Basilic vein
r, Cephalic vein

a, Extensor ossis metacarpi pollicis muscle

b, Extensor primi internodii pollicis muscle
c, Extensor secundi internodii pollicis muscle
d, Arteria magna pollicis

15, Anconal twig of ulnar nerve
36, Thenal twig of spiral nerve
46, Anconal twig of spiral nerve

PLATE XXII.

A, Symphysis pubis
B, Sacrum
C, Coccyx
G, Tuberosity of ischium
I, Rectum and anus
X, Corpus cavernosum penis
Y, Gluteus maximus muscle
Z, Scrotum

m, Urinary bladder
o, Acceleratores urinæ muscles
p, Erector penis muscle
q, Transversus perinei muscle
r, Sphincter ani muscle
s, Levator ani muscle
t, Prostate gland

u, Vesiculæ seminales
v, Vas deferens
w, Ureter

b, Internal hemorrhoidal artery
g, Spermatic artery
h, Internal pudic artery
n, Catheter

1, Artery of corpus spongiosum penis
2, Artery of corpus cavernosum penis
3, Arteria dorsalis penis
4, Twig of sacral nerves
6, Cauda equina

PLATE XXIII.

A, Symphysis pubis
B, Paupart's ligament
C, Anterior superior spinous process of os ilium
D, Pubic portion of fascia lata
E, Sartorius muscle
K, Iliac portion of fascia lata
T, Femoral artery
U, Femoral vein
Y, Patella
Z, Scrotum

a, Cremaster muscle
b, Tunica vaginalis testis
f, Inguinal pudic artery
t, Superficial femoral artery

x, Epigastric artery

a, Inguinal glands
b, Saphena major vein
c, Circumflex iliac artery
d, Vein of integuments of abdomen
e, Vein of integuments of penis
f, Inguinal pudic veins
x, Spermatic branch of epigastric artery

1, Spermatic twig of first lumbar nerve
3, Third lumbar nerve
22, Anterior crural nerve
70, Suspensory ligament of penis

PLATE XXIV.

A, Symphysis pubis
B, Poupart's ligament
C, Anterior superior spinous process of os ilium
E, Sartorius muscle
F, Pectinalis muscle
G, Adductor magnus muscle
I, Rectus femoris muscle
K, Tensor vaginæ femoris muscle
L, Vastus internus muscle
N, Semi-membranosus muscle
O, Vastus externus muscle
P, Crureus muscle
Q, Gracilis muscle
T, Common femoral artery
U, Femoral vein
W, Psoas magnus and iliacus internus muscles
Y, Patella

c, Arteria profunda
d, Internal circumflex artery
e, External circumflex artery
g, Adductor longus muscle
r, Testis
t, Superficial femoral artery
x, Epigastric artery

a, Anastomoticus artery
b, Saphena vein
c, Circumflex iliac artery truncated
c, Profunda veins
g, Spermatic artery, running down to testis, *r*
g, Adductor brevis muscle, beneath adductor longus, g
r, Epidydymis

1, Vas deferens
3, Arteria dorsalis penis
21, Obturator nerve
22, Anterior crural nerve
60, Vena magna penis

PLATE XXV.

A, Pyriformis muscle
B, Sacrum
C, Coccyx
D, Great sacro-ischiadic notch
E, Sartorius muscle
F, Gluteus maximus muscle
G, Adductor magnus muscle
H, Long sacro-ischiadic ligament
I, Gluteus medius muscle
K, Quadratus femoris muscle
L, Long head of biceps muscle
M, Semi-tendinosus muscle
N, Semi-membranosus muscle
Q, Gracilis muscle
R, Gastrocnemius externus muscle
T, Popliteal artery
U, Popliteal vein
X, Obturator internus, with gemelli muscles
Z, Tuberosity of os ischium

b, Posterior superior spinous process of os ilium
l, Short head of biceps muscle

a, *a*, Arteriæ gastrocnemiæ
b, Saphena major vein
c, Gluteal artery emerging from great sacro-ischiadic notch, D
c, Continuation of profunda femoris artery, emerging at the ham
f, Ischiadic artery
h, Internal pudic artery
l, Insertion of biceps muscle
z, Saphena minor vein

1, Posterior cutaneous twig of great sacro-ischiadic nerve
2, Inferior posterior cutaneous twig of great sacro-ischiadic nerve
2, Posterior sacral nerves truncated
4, Nervus communicans tibiæ
5, Peroneus superficialis nerve
20, Great sacro-ischiadic nerve
23, Posterior tibial nerve
26, Fibular nerve
27, Trunk of nervus communicans tibiæ, and peroneus superficialis
28, Anterior tibial nerve

PLATE XXVI.

A, Tibialis anticus muscle
B, Extensor longus digitorum pedis muscle
C, Extensor pollicis pedis muscle
D, Annular ligament
E, Extensor brevis digitorum pedis muscle
F, Peroneus longus muscle
S, Malleolus externus

c, Malleolar arteries
e, Tarsal branches of anterior tibial artery

a, Spine of tibia
b, Saphena major vein
d, Recurrent branch of anterior tibial artery
f, Digital branch to great toe and index pedis
s, Malleolus internus
t, Anterior tibial artery
z, Saphena minor vein

4, Nervus communicans tibiæ
5, Peroneus superficialis nerve
28, Anterior tibial nerve

PLATE XXVII.

A, Flexor pollicis longus muscle
D, Os calcis
O, Flexor digitorum longus muscle
R, Gastrocnemius externus muscle
S, Malleolus externus
Y, Plantar fascia

a, Tibialis posticus muscle
r, Gastrocnemius internus, or soleus muscle
t, Posterior tibial artery

a, External plantar artery emerging from plantar fascia, Y

a, Arteriæ gastrocnemiæ ramified on gastrocnemius muscle, R
b, Saphena major vein
q, Inner angle of tibia
r, Tendo-achillis
s, Malleolus internus
z, Saphena minor vein

2, Posterior inferior cutaneous twig of great sacro-ischiadic nerve
4, Nervus communicans tibiæ
23, Posterior tibial nerve
24, External plantar nerve
25, Internal plantar nerve

PLATE XXVIII.

A, Flexor longus pollicis muscle
B, Abductor pollicis muscle
C, Flexor brevis digitorum muscle
D, Os calcis
E, Sartorius muscle
F, Abductor minimi digiti pedis muscle
L, Vastus internus muscle
M, Semi-tendinosus muscle
N, Semi-membranous muscle
O, Flexor longus digitorum muscle
Q, Gracilis muscle
R, Gastrocnemius externus muscle
T, Popliteal artery
U, Popliteal vein
V, Popliteus muscle
X, Flexor brevis pollicis muscle

a, Tibialis posticus muscle
r, Gastrocnemius internus, or soleus muscle
t, Posterior tibial artery
y, Fibular artery

a, External plantar artery
b, Saphena major vein
c, Internal plantar artery
r, Tendo-achillis
s, Malleolus internus
t, Anterior tibial artery

5, Peroneus superficialis nerve
23, Posterior tibial nerve
24, External plantar nerve
25, Internal plantar nerve
28, Anterior tibial nerve

INDEX

TO

THE LETTERS OF REFERENCE

IN

THE MUSCLES OF THE TRUNK.

PLATE XXIX.

B, Paupart's ligament
C, Situated near serratus magnus muscle, O, is the pectoralis major muscle
C, Situated near crista, S, of os ilium, is the anterior superior spinous process of os ilium
D, Pubic portion of fascia lata
E, Latissimus dorsi muscle
F, Origins of external oblique muscle of abdomen
K, Iliac portion of fascia lata
O, Serratus major anticus muscle
R, Rectus abdominis muscle
S, Crista of os ilium
T, Pyramidalis muscle
U, Umbilicus

a, Cremaster muscle
f, Linea semi-lunaris
r, Tendinous intersections of rectus muscle

b, Saphena major vein
f, Linea alba

1, Upper pillar of external aperture of inguinal canal
2, Lower pillar of external aperture of inguinal canal
70, Suspensory ligament of penis

PLATE XXX.

A, Ribs
C, Anterior superior spinous process of os ilium
D, Pubic portion of fascia lata
G, Internal oblique muscle
K, Iliac portion of fascia lata
R, Rectus abdominis muscle
S, Crista of os ilium
U, Umbilicus
X, Internal intercostal muscles
Z, External intercostal muscles

a, Cremaster muscle
f, Tendon of external oblique muscle
g, Anterior tendon of internal oblique muscle
x, Epigastric artery

a, Peritoneum
f, Linea alba
g, Posterior tendon of internal oblique muscle
x, Epigastric vein

ɛ, Spine of os pubis

3, Gimbernat's ligament
14, Internal mammary artery

PLATE XXXI.

A, Ribs
C, Anterior superior spinous process of os ilium
D, Pubic portion of fascia lata
G, Internal oblique muscle
I, Transversalis muscle
K, Iliac portion of fascia lata
S, Crista of os ilium
U, Umbilicus
V, Vas deferens
X, Internal intercostal muscles

a, Cremaster muscle
f, Tendon of external oblique muscle
g, Anterior tendon of internal oblique muscle
i, Tendon of transversalis muscle
x, Epigastric artery

a, Peritoneum
c, Circumflex iliac artery
f, Linea alba
g, Contiguous to letters i, is the posterior tendon of internal oblique muscle
g, Contiguous to v, is the spermatic cord
x, Epigastric vein

ɛ, Spine of os pubis
ꝑ, Linea-ilio-pectinea

PLATE XXXII.

A, Ribs
B, Diaphragm
C, Quadratus lumborum muscle
C, Renal arteries truncated
D, Ligamentum arcuatum
I, Œsophagus
K, Psoas magnus muscle
P, Common iliac artery
R, Superior mesenteric artery

b, Origins of crura of diaphragm
e, Aorta abdominalis
n, Cœliac artery

e, Sternum
i, Vena cava ascendens

PLATE XXXIII.

B, Deltoid muscle
C, Base of scapula
D, Acromion scapulæ
E, Contiguous to skull, is the sterno-cleido-mastoideus muscle
E, Situated in lower half of Plate, indicates latissimus dorsi muscle
F, Placed on scapula, is teres major muscle
F, Contiguous to crista, S, of os ilium, is external oblique muscle
G, Internal oblique muscle
H, Serratus posticus inferior muscle
O, Complexus muscle
S, Crista of os ilium
T, Rhomboideus major muscle
U, Omo-hyoideus muscle

d, Tendons of sacro-lumbalis muscle
g, Interspinous ligament
k, Tendons of longissimus dorsi muscle
p, Splenius capitis muscle
q, Occipito-frontalis muscle
t, Rhomboideus minor muscle

a, Protuberance of occipital bone
c, Base of scapula
e, Spinous process of vertebra
h, Spine of scapula
p, Splenius colli muscle

ꝑ, Superior transverse ridge of occipital bone
ɛ, Base of scapula

40, Levator scapulæ muscle
66, Supra-spinatus muscle
80, Trapezius muscle
81, Infra-spinatus muscle

PLATE XXXIV.

C, Quadratus lumborum muscle
D, Sacro-lumbalis muscle
E, Serratus superior posticus muscle
K, Longissimus dorsi muscle
L, Spinalis dorsi muscle
M, Semi-spinalis dorsi muscle
O, Contiguous to skull, indicates complexus muscle
O, Contiguous to left scapula, is serratus magnus muscle
Q, Multifidus spinæ muscle
S, Crista of os ilium
T, Insertion of rhomboideus major muscle
Z, External intercostal muscles

d, Tendons of sacro-lumbalis muscle
k, Tendons of longissimus dorsi muscle
p, Splenius capitis muscle
t, Insertion of rhomboideus minor muscle
z, Levator costæ muscle

a, Protuberance of occipital bone
d, Musculus accessorius ad sacro-lumbalem muscle
h, Intertransverse muscle
k, Insertion of longissimus dorsi muscle
m, Mastoid process of temporal bone
p, Splenius colli muscle

ꝑ, Superior transverse ridge of occipital bone
ꝑ, Cervicalis descendens muscle
ꝑ, Transversalis colli muscle

5, Occipital bone
9, Axillary plexus of nerves
40, Levator scapulæ muscle
50, Scalenus posticus muscle
52, Superficial cervical artery

PLATE XXXV.

A, Rectus capitis major muscle
B, Obliquus superior muscle
E, Obliquus inferior muscle
F, Trachelo-mastoideus muscle
H, Rectus capitis lateralis muscle
M, Semi-spinalis dorsi muscle
N, Semi-spinalis colli muscle
O, Complexus muscle
P, Rectus capitis minor muscle

d, Sacro-lumbalis muscle
g, Interspinalis muscle
k, Longissimus dorsi muscle

a, Protuberance of occipital bone
d, Transverse process of atlas
e, Spinous process of vertebra
l, Capsular ligament of tubercle of rib
m, Mastoid process of temporal bone

ꝑ, Superior transverse ridge of occipital bone
ꝑ, Cervicalis descendens muscle
ꝑ, Transversalis colli muscle

1, Intertransverse ligament
2, Internal ligament of neck of rib
5, Occipital bone
7, Temporal bone.

INDEX

TO

THE LETTERS OF REFERENCE

IN THE

SUPPLEMENT, AND MUSCLES OF THE UPPER AND LOWER EXTREMITIES.

PLATE XXXVI.

A, Symphysis pubis
B, Paupart's ligament
C, Anterior superior spinous process of os ilium
E, Sartorius muscle
G, Internal oblique muscle
I, Transversalis muscle
K, Iliac portion of fascia lata
P, Pectinalis muscle
S, Crista of os ilium
T, Common femoral artery
U, Common femoral vein
W, Iliacus internus muscle

a, Cremaster muscle
f, Tendinous expanse of external oblique muscle
g, Adductor longus muscle
i, Tendon of transversalis muscle
t, Superficial femoral artery

v, Vas deferens

a, Spermatic cord
b, Saphena major vein truncated
f, Linea alba
g, Adductor brevis muscle
g, Spermatic arteries
i, Iliac portion of fascia transversalis

ɡ, Spermatic vein
í, Pubic portion of fascia transversalis

1, Upper pillar of external aperture of inguinal canal
2, Lower pillar of external aperture of inguinal canal
3, Gimbernat's ligament
22, Anterior crural nerve

PLATE XXXVII.

A, Symphysis pubis
B, Os sacrum
C, Os coccygis
I, Transversalis muscle
O, Common iliac vein
P, Common iliac artery
R, Rectus muscle
T, External iliac artery
U, External iliac vein
V, Internal iliac artery
W, Fascia iliaca
X, Internal iliac vein
Y, Abdominal aspect of crural aperture

v, Vas deferens
x, Epigastric artery

a, Peritoneum
d, Obturator artery
g, Spermatic arteries
i, Iliac portion of fascia transversalis
x, Epigastric vein

ɒ, Obturator vein
ɡ, Spermatic veins
í, Pubic portion of fascia transversalis

1, Internal aperture of inguinal canal
2, Lumbar vertebræ
21, Obturator nerve

PLATE XXXVIII.

A, Clavicle
B, Deltoid muscle
C, Origin of pectoralis major muscle
D, Pectoralis minor muscle
E, Near A, indicating clavicle, is the sterno-cleido-mastoideus muscle
E, Near F, is latissimus dorsi muscle
F, Teres major muscle
G, Long head of triceps muscle
H, Axillary artery
I, Subscapularis muscle
K, Coraco-brachialis muscle
M, Subclavius muscle
O, Serratus magnus muscle
Z, External intercostal muscles

a, Ribs
b, Insertion of deltoid muscle
d, Posterior circumflex artery

c, Insertion of pectoralis major muscle
d, Insertion of pectoralis minor muscle
e, Sternum
l, Long head of biceps flexor cubiti muscle

ɛ, Capsular ligament of shoulder-joint
ɪ, Short head of biceps flexor cubiti muscle

1, Capsular ligament of sternal articulation of clavicle
2, Interarticular cartilage of sternal articulation of clavicle
3, Capsule of cartilage of rib
4, Ligamentous expanse between clavicle and scapula
5, Coracoid process of scapula

PLATE XXXIX. Fig. 1.

A, Clavicle
B, Origin of deltoid muscle
C, Clavicular origin of pectoralis major muscle
D, Acromion scapulæ
E, Insertion of latissimus dorsi and teres major muscles
I, Subscapularis muscle
K, Coraco-brachialis muscle
L, Biceps flexor cubiti muscle
M, Brachieus internus muscle
N, Supinator radii longus muscle
P, Flexor carpi radialis muscle

b, Insertion of deltoid muscle
g, Triceps muscle
i, Insertion of subscapularis muscle
l, Fascia of biceps muscle

a, Bursa mucosa beneath the deltoid muscle

c, Insertion of pectoralis major muscle
d, Insertion of pectoralis minor muscle
l, Long head of biceps muscle

ɪ, Short head of biceps muscle

λ, Tendinous insertion of biceps muscle

5, Coracoid process of scapula
6, Ligamentum proprium anticum scapulæ
8, Ligamentum trapezoideum
9, Scapulary articulation of clavicle
66, Supra-spinatus muscle
80, Insertion of trapezius muscle
81, Infra-spinatus muscle

Fig. 2.

A, Clavicle
B, Origin of deltoid muscle
D, Acromion scapulæ
E, Insertion of latissimus dorsi and teres major muscles
G, Long head of triceps muscle
K, Coraco-brachialis muscle
O, Insertion of serratus magnus muscle

b, Insertion of deltoid muscle
e, Supra-scapular artery
g, Second head of triceps muscle
i, Tendinous insertion of subscapularis muscle

a, Proper posterior ligament of scapula
b, Superior costa of scapula

c, Contiguous to b, indicates insertion of pectoralis major muscle, which compare with Fig. 1
c, Contiguous to ɛ, is head of os brachii
e, Glenoid cavity of scapula
i, Origin of subscapularis muscle
l, Long head of biceps muscle

ɛ, Capsular ligament of shoulder-joint

5, Coracoid process of scapula
6, Ligamentum proprium anticum scapulæ
8, Ligamentum trapezoideum
66, Insertion of supra-spinatus muscle

Fig. 3.

A, Clavicle
B, Sterno-thyroideus muscle
C, Sterno-hyoideus muscle

a, Ribs

e, Sternum

1, Capsular ligament of sternal articulation of clavicle
7, Inter-clavicular ligament
10, Rhomboid ligament

PLATE XL.

H, Extensor carpi radialis longior muscle
I, Pronator radii teres muscle
L, Biceps muscle
M, Brachieus internus muscle
N, Supinator radii longus muscle
P, Flexor carpi radialis muscle
Q, Palmaris longus muscle
R, Flexor digitorum sublimis muscle
S, Flexor carpi ulnaris muscle
T, Os pisiforme
U, Annular ligament

V, Fascia palmaris
W, Flexor digitorum profundus muscle
X, Flexor longus pollicis muscle
Y, Abductor pollicis muscle
Z, Flexor brevis pollicis muscle

m, Insertion of brachieus internus muscle
r, Tendons of flexor digitorum sublimis muscle
w, Tendons of flexor digitorum profundus muscle

PLATE XL. (Continued.)

a, Extensor ossis metacarpi pollicis muscle
b, Extensor primi internodii pollicis muscle
h, Extensor carpi radialis brevior muscle
r, Divided tendons of flexor digitorum sublimis muscle
w, Adductor pollicis muscle

ϖ, Lumbricales muscles

λ, Tendon of biceps muscle

2, Bursæ mucosæ of biceps muscle
6, Situated on thumb, indicates proximal phalanx of thumb
6, Near 16, indicates trunk of spiral nerve
15, Distal phalanx of thumb
16, Cutaneous branch of spiral nerve
26, Deep branch of spiral nerve
30, Vaginal ligaments of flexor tendons of fingers
50, Pronator quadratus muscle
51, Abductor minimi digiti muscle
52, Near 51, is flexor parvus minimi digiti muscle
52, Near Y, is flexor ossis metacarpi pollicis muscle
54, Palmaris brevis muscle
55, Near V, is adductor minimi digiti muscle
55, Near bursæ mucosæ 2, indicates supinator radii brevis muscle
70, Abductor indicis muscle

PLATE XLI. Fig. 1.

M, Brachieus internus muscle
N, Tendon of supinator radii longus muscle
P, Tendon of flexor carpi radialis muscle
S, Flexor carpi ulnaris muscle
T, Pisiform bone
U, Annular ligament of carpus
W, Flexor digitorum profundus muscle
X, Flexor longus pollicis muscle
Z, Flexor brevis pollicis muscle

m, Insertion of brachieus internus muscle
r, Tendons of flexor digitorum sublimis muscle
w, Tendons of flexor digitorum profundus muscle

b, Tubercle of radius
e, Os trapezium
h, Os unciforme
r, Divided tendons of flexor digitorum sublimis muscle
w, Adductor pollicis muscle
z, Inner head of flexor brevis pollicis muscle

ϑ, Tendinous insertion of triceps muscle
ϖ, Lumbricales muscles

6, Proximal phalanx of thumb
15, Distal phalanx of thumb
30, Vaginal ligaments of flexor tendons of fingers
34, Intertransverse ligaments of heads of metacarpal bones
50, Pronator quadratus muscle
51, Points of attachment of abductor minimi digiti muscle
52, Near T, Points of attachment of flexor parvus minimi digiti muscle
52, Near P, Flexor ossis metacarpi pollicis muscle
55, Near 51, Adductor minimi digiti muscle
55, Near *b*, Supinator radii brevis muscle
70, Abductor indicis muscle

Fig. 2.

P, Tendinous insertion of flexor carpi radialis muscle
T, Os pisiforme

m, Tendinous insertion of brachieus internus muscle

a, Radius
e, Os trapezium
g, Capsular ligament of articulation between os trapezium and metacarpal bone of thumb
h, Os unciforme
m, Capsular ligament of distal articulation of thumb
n, Lateral ligament of distal articulation of thumb
p, Near 40, is ulnar condyle of os brachii
p, Near ϰ, indicates prior indicis muscle
q, Near ϰ, is posterior indicis muscle
q, Near 45, is radial condyle of os brachii
s, Prior annularis muscle
t, Interosseous auricularis muscle
u, Prior medii muscle
w, Origin of adductor pollicis muscle
x, Posterior annularis

ϵ, Capsular ligaments of proximal articulations of fingers

λ, Tendinous insertion of biceps muscle

1, Near 61, Ulna
1, Near *g*, Metacarpal bone of thumb
2, Metacarpal bone of fore-finger
3, Metacarpal bone of middle-finger
3, Near m, Coronoid process of ulna
4, Metacarpal bone of ring-finger
5, Metacarpal bone of little-finger
6, Proximal phalanx of thumb
15, Distal phalanx of thumb
25, Ulnar intermuscular ligament
30, Vaginal ligaments of flexor tendons
35, Capsular ligament of elbow-joint
40, Ulnar lateral ligament of elbow-joint
45, Radial lateral ligament of elbow-joint
50, Pronator quadratus muscle
60, Oblique ligament
61, Interosseous ligament
62, Sacciform ligament around distal head of ulna
63, Capsular ligament of wrist-joint
64, Ulnar lateral ligament of wrist-joint
65, Radial lateral ligament of wrist-joint

Fig. 3.

a, Radius
d, Head of radius

λ, Tendinous insertion of biceps muscle

PLATE XLI. Fig. 3. (Continued.)

1, Ulna
3, Coronoid process of ulna
5, Coronary ligament of elbow-joint
35, Capsular ligament of elbow-joint
38, Synovial gland

Fig. 4.

T, Os pisiforme

a, Os scaphoides
b, Os lunare
c, Os cuneiforme
e, Os trapezium
g, Capsular ligament of articulation between trapezium and metacarpal bone of thumb
h, Os unciforme
i, Interarticular cartilage

1, Metacarpal bone of thumb
13, Distal head of ulna
62, Sacciform capsule
63, Capsular ligament of wrist-joint
65, Radial lateral ligament of wrist-joint

PLATE XLII. Fig. 1.

B, Extensor carpi ulnaris muscle
D, Extensor communis digitorum muscle
E, Anconeus muscle
H, Extensor carpi radialis longior muscle
N, Supinator radii longus muscle
S, Flexor carpi ulnaris muscle
U, Annular ligament of carpus

d, Tendons of extensor digitorum communis muscle
g, Triceps muscle

a, Extensor ossis metacarpi pollicis muscle
b, Extensor primi internodii pollicis muscle
c, Extensor secundi internodii pollicis muscle
d, Tendinous expanse of extensor digitorum communis muscle
h, Extensor carpi radialis brevior muscle
m, Prior medii muscle
n, Posterior medii muscle
o, Posterior annularis muscle
q, Radial condyle of os brachii
w, Adductor pollicis muscle

ϑ, Connecting tendons of extensor digitorum communis

2, Metacarpal bone of fore-finger
5, Metacarpal bone of little finger
6, First phalanx of thumb
7, First phalanx of fore-finger
8, First phalanx of middle finger
9, First phalanx of ring finger
10, First phalanx of little finger
12, Ulna
15, Last phalanx of thumb
16, Third phalanx of fore-finger
17, Third phalanx of middle finger
18, Third phalanx of ring finger
19, Third phalanx of little finger
25, Radial intermuscular ligament
70, Abductor indicis muscle

Fig. 2.

B, Extensor carpi ulnaris muscle
D, Origin of extensor digitorum communis muscle
E, Anconeus muscle
H, Points of attachment of extensor carpi radialis longior muscle
N, Origin of supinator radii longus muscle
S, Flexor carpi ulnaris muscle
U, Annular ligament of carpus

a, Extensor ossis metacarpi pollicis muscle
b, Extensor primi internodii pollicis muscle
c, Extensor secundi internodii pollicis muscle
f, Indicator muscle
h, Points of attachment of extensor carpi radialis brevior muscle
m, Prior medii muscle
n, Posterior medii muscle
o, Posterior annularis muscle

ϵ, Capsular ligaments of proximal joints of fingers

g, Insertion of triceps muscle
ϰ, Lateral ligaments of proximal joints of fingers

1, Metacarpal bone of thumb
2, Metacarpal bone of fore-finger
3, Metacarpal bone of middle finger
4, Metacarpal bone of ring finger
5, Metacarpal bone of little finger
6, Near g, is olecranon ulnæ
6, Proximal phalanx of thumb
7, Proximal phalanx of fore-finger
8, Proximal phalanx of middle finger
9, Proximal phalanx of ring finger
10, Proximal phalanx of little finger
15, Distal phalanx of thumb
25, Radial intermuscular ligament
35, Capsular ligament of elbow-joint
55, Supinator radii brevis muscle

** Intertransverse ligaments of carpal bones

PLATE XLIII.

B, Paupart's ligament
C, Anterior superior spinous process of os ilium
D, Part of pubic portion of fascia lata
E, Origin of sartorius muscle
G, Adductor magnus muscle
I, Contiguous to K and E, indicates gluteus medius muscle
I, Contiguous to P, indicates rectus femoris muscle
K, Near E, Tensor vaginæ femoris muscle
K, Near f, Psoas magnus muscle
L, Vastus internus muscle
P, Contiguous to D, indicates pectinalis muscle
P, Between I and L, indicates crureus muscle
Q, Pectinalis muscle
T, Common femoral artery

PLATE XLIII. (Continued.)

U, Near T or t, indicates femoral vein
U, At the top of the Plate, indicates umbilicus
w, Iliacus internus muscle

f, Tendon of external oblique muscle
g, Adductor longus muscle
t, Superficial femoral artery

f, Linea alba
g, Adductor brevis muscle

ꝛ, Spine of os pubis
ꝯ, Tendon of triceps muscle
ı, Crista pubis

1, Upper pillar of abdominal ring
2, Lower pillar of abdominal ring
3, Gimbernat's ligament

PLATE XLIV.

A, Capsular ligament of hip-joint
C, Anterior superior spinous process

D, Obturator externus muscle
E, Origin of sartorius muscle
G, Adductor magnus muscle

PLATE XLIV. (Continued.)

I, Contiguous to K and E, indicates gluteus medius muscle
I, Contiguous to A and L, indicates rectus femoris muscle
K, Insertion of psoas magnus muscle
L, Vastus internus muscle
N, Semi-membranosus muscle
P, P, Contiguous to g, g, indicate origin and insertion of pectinalis muscle
P, Between I and L, indicates crureus muscle
Q, Origin of gracilis muscle
U, Femoral vein
w, Insertion of iliacus internus muscle

d, Obturator vein

g, g, Origin and insertion of adductor longus muscle
t, Superficial femoral artery

d, Obturator artery
f, Trochanter minor
g, *g*, Origin and insertion of adductor brevis muscle
i, Part of origin of rectus femoris muscle
t, Anterior inferior spinous process of os ilium

ꝯ, Tendon of triceps muscle

1, Bursa mucosa of psoas magnum and iliacus internus muscles
21, Obturator nerve

INDEX

TO

THE LETTERS OF REFERENCE

IN THE

MUSCLES AND JOINTS OF THE LOWER EXTREMITY.

PLATE XLV.

F, The gluteus maximus muscle
I, The gluteus medius muscle
K, The tensor vaginæ femoris muscle
k, The fascia lata
f, The superior posterior spinous process of the os ilium

PLATE XLVI.

A, Pyriformis muscle
C, Gluteus minimus muscle
D, Obturator externus muscle
F, Origin of gluteus maximus muscle
G, Adductor magnus muscle
H, Long sacro-ischiadic ligament
I, Origin of gluteus medius muscle
K, Pubic to the gluteus medius muscle, I, indicates the tensor vaginæ femoris muscle, which is entire and on the stretch
K, Contiguous to Z, between it and e, indicates quadratus femoris muscle, which is cut across
L, Long head of biceps flexor cruris muscle
M, Semi-tendinosus muscle
X, Obturator internus muscle
Z, Tuberosity of os ischium
e, Trochanter major
f, Fleshy insertion of gluteus maximus muscle
i, Insertion of gluteus medius muscle
k, Fascia lata
s, Levator ani muscle
x, Gemellus superior muscle

c, Branch of gluteal artery
f, Bursa mucosa of gluteus maximus muscle
f, Posterior superior spinous process of os ilium
x, Gemellus inferior muscle

ɛ, Point of insertion of gluteus medius muscle

20, Great sacro-ischiadic nerve

PLATE XLVII. Fig. 1.

A, Contiguous to *g*, indicates pyriformis muscle emerging at greater sacro-ischiadic notch
A, Contiguous to *a*, capsular ligament of hip-joint
C, Anterior superior spinous process of os ilium
H, Long sacro-ischiadic ligament
I, Surface of origin of gluteus medius muscle
X, Origin and insertion of obturator internus muscle
Z, Tuberosity of os ilium

a, Insertion of pyriformis muscle
b, Os coccygis
c, Surface of origin of gluteus minimus muscle
d, Insertion of obturator externus muscle
e, Trochanter major of os femoris
f, Trochanter minor of os femoris
g, Tubercle of os sacrum, affording attachment to sacro-ischiadic ligaments
x, Origin of gemellus inferior muscle

c, Insertion of gluteus minimus muscle
h, Short sacro-ischiadic ligament
i, Insertion of gluteus medius muscle
x, Origin of gemellus superior muscle

a, Strong pubic fibres of capsular ligament
1, Bursa mucosa of obturator internus muscle

Fig 2.

A, Capsular ligament of hip-joint around acetabulum
B, Round ligament of hip-joint
C, Anterior superior spinous process of os ilium
D, Origin of obturator externus muscle
K, Origin of quadratus femoris muscle
R, Synovial gland of hip-joint

PLATE XLVII. Fig. 2. (Continued.)

s, Crista of os ilium
U, Obturator ligament

a, Capsular ligament of hip-joint attached to cervix of os femoris
d, Obturator vein
r, Acetabulum

a, Reflected portion of capsular ligament of hip-joint
b, Head of os femoris

c, Surface of origin of gluteus minimus muscle
d, Obturator artery
t, Anterior inferior spinous process of os ilium

ɒ, Neck of os femoris

1, Cartilaginous brim of acetabulum
10, Ligamento-cartilaginous brim of acetabulum
21, Obturator nerve

PLATE XLVIII. Fig. 1.

H, Long sacro-ischiadic ligament
s, Crista of os ilium
Z, Tuberosity of os ischium

b, Crucial ligaments of vertebræ
h, Short sacro-ischiadic ligament

q, Lacertus ligamentosus

b, Os coccygis
f, Sacro-iliac synchondrosis
h, Intertransverse muscle
i, Ligamenta vaga

Fig. 2.

H, Long sacro-ischiadic ligament
s, Crista of os ilium
Z, Tuberosity of os ischium

a, Ligamentous expanse of os coccygis
g, Interspinous ligament
h, Short sacro-ischiadic ligament
k, Ilio-lumbar and ilio-sacral ligaments

b, Os coccygis
g, Tubercle of os sacrum, affording attachment to sacro-ischiadic ligaments
i, Ligamenta vaga
f, Posterior superior spinous process of os ilium
z, Ilio-sacral ligaments

2, Capsular ligaments of articular processes of vertebræ

Fig. 3.

C, Capsule of head of rib

a, Common anterior ligament of vertebræ

PLATE XLIX. Fig. 1.

Y, Patella

d, Attachment of patellar ligament to tubercle of tibia

d, Apex of patella
l, Cellular envelope of vastus internus muscle, incorporated with fascia lata

o, Cellular envelope of vastus externus muscle, incorporated with fascia lata
y, Patellar ligament

ɒ, Bursa mucosa, under patellar ligament

3, External lateral ligament of knee-joint

Fig. 2.

M, Internal condyle of os femoris
N, External condyle of os femoris

m, Tibial surface of patella, opposed to *m* of os femoris

PLATE XLIX. Fig. 2. (Continued.)

n, Fibular surface of patella, opposed to *n* of os femoris

m, Trochlear surface opposed to patella
n, Trochlear surface opposed to patella

1, Bursa mucosa, beneath crureus and rectus muscles
3, External lateral ligament
4, Capsular ligament
5, Patella
7, Synovial gland
8, Mucous ligament
9, Synovial glandular tissue
10, Alar ligaments

PLATE L. Fig. 1.

A, Flexor longus pollicis pedis
D, Os calcis
E, Tendon of sartorius muscle
F, Peroneus longus muscle
I, Peroneus brevis muscle
K, Vaginal ligament of peronei muscles
M, Tendon of semi-tendinosus muscle
N, Tendon of semi-membranosus muscle
O, Flexor longus digitorum pedis muscle
Q, Tendon of gracilis muscle
R, Gastrocnemius externus muscle
U, Plantaris muscle
V, Popliteus muscle

a, Tibialis posticus muscle
o, Tendon of flexor longus digitorum pedis muscle

r, Gastrocnemius internus muscle
u, Tendon of plantaris muscle

e, Bursa mucosa, common to tendinous insertions of sartorius, gracilis, and semi-tendinosus muscles
l, Tendon of biceps flexor cruris muscle
m, Tibial condyle of os femoris
r, Tendo achillis
s, Malleolus internus

ã, Vaginal ligament of flexor longus pollicis pedis
o̧, Vaginal ligament of the flexor muscles of the toes

2, Internal lateral ligament of knee-joint
10, Popliteal ligament

Fig. 2.

M, Internal condyle of os femoris
N, External condyle of os femoris

a, Head of tibia
c, Depressions on head of tibia
y, Patellar ligament

4, Capsular ligament of knee-joint
9, Synovial tissue
11, Anterior crucial ligament
12, Posterior crucial ligament
13, Internal semilunar cartilage
14, External semilunar cartilage
15, Transverse ligament of semilunar cartilages

Fig. 3.

M, Internal condyle of os femoris
N, External condyle of os femoris

a, Head of tibia

4, Capsular ligament of knee-joint
9, Synovial tissue
11, Anterior crucial ligament
12, Posterior crucial ligament

PLATE LI. Fig. 1.

A, Flexor longus pollicis muscle
B, Origin of abductor pollicis muscle
C, Origin of flexor brevis digitorum muscle
D, Os calcis
F, Abductor minimi digiti pedis muscle
G, Musculus accessorius ad flexorem longum digitorum
H, Interosseous ligament
I, Peroneus brevis muscle
N, Flexor brevis minimi digiti pedis muscle
O, Flexor longus digitorum pedis muscle
R, Origin of internal head of gastrocnemius externus muscle
V, Popliteus muscle
X, Flexor brevis pollicis pedis muscle

a, Tibialis posticus muscle
b, Insertion of abductor pollicis muscle
k, Lumbricales muscles

o, Tendon of flexor longus digitorum muscle

a, Tendon of flexor longus pollicis pedis muscle
b, Os naviculare
c, Tendons of flexor brevis digitorum pedis muscle
n, Outer condyle of os femoris
o, Tendons of flexor longus digitorum pedis muscle
s, Malleolus internus

ã, Vaginal ligament of flexor longus pollicis muscle

1, Fibula
2, Internal lateral ligament of knee-joint
3, External lateral ligament of knee-joint
4, Vaginal ligaments of the flexor tendons of the toes
10, Popliteal ligament
60, Head of fibula

Fig. 2.

s, Malleolus externus

a, Trochlear surface of astragalus opposed to tibia and fibula

b, Os naviculare
e, Capsular ligament surrounding articulation of os calcis and os cuboides

PLATE LI. Fig. 2. (Continued.)

g, Os cuboides
m, Convex surface of os astragalus opposed to os naviculare
s, Malleolus internus
u, Intertransverse ligament between astragalus and os naviculare and os cuboides
v, Capsular ligament surrounding articulation of astragalus and naviculare

z, Transverse ligament between os calcis and os cuboides

10, Synovial gland
30, Capsular ligament of ankle-joint
31, Anterior fibular ligament of ankle-joint

Fig. 3.

i, Intertransverse ligaments between tarsal and metatarsal bones
m, Capsular ligament of proximal joint of great toe

b, Os naviculare
d, Os cuneiforme internum
e, Os cuneiforme medium
f, Os cuneiforme externum
g, Os cuboides
l, Capsular ligaments surrounding articulations between tarsal and metatarsal bones

t, Protuberance on proximal extremity of metatarsal bone of little toe
v, Capsular ligament surrounding articulation of os naviculare, and three cuneiform bones
z, Transverse ligaments of tarsal bones

2, Metatarsal bone of index toe
3, Metatarsal bone of middle toe
4, Metatarsal bone of ring toe
5, Metatarsal bone of little toe
6, Proximal phalanx of great toe
20, Metatarsal bone of great toe

PLATE LII. Fig. 1.

D, Os calcis
H, Interosseous ligament
I, Peroneus brevis muscle
L, Transversalis pedis muscle
P, Abductor tertii digiti pedis muscle
Q, Abductor minimi digiti pedis muscle
V, Origin of popliteus muscle

a, Tibialis posticus muscle
e, Transverse ligaments of heads of metatarsal bones

b, Os naviculare
d, Os cuneiforme internum
g, Adductor medii digiti pedis muscle
i, Indicates point of insertion of popliteus muscle

m, Internal condyle of os femoris
n, External condyle of os femoris
o, Tibia
q, Adductor pollicis muscle
s, Malleolus internus
w, Tibial plantar ligament
x, Transverse plantar ligaments
y, Fibular plantar ligament

1, Fibula
2, Internal lateral ligament of knee-joint
3, External lateral ligament of knee-joint
4, Vaginal ligaments of flexor tendons
10, Popliteal ligament
60, Head of fibula

Fig. 2.

D, Os calcis

a, Os astragalus
b, Os naviculare
g, Os cuboides

s, Malleolus internus
w, Internal plantar ligament
y, External plantar ligament

33, Deltoid ligament of ankle-joint

PLATE LIII.

A, Adductor indicis muscle
D, Os calcis
F, Peroneus longus muscle
H, Interosseous ligament
I, Peroneus brevis muscle
K, Vaginal ligament of peronei muscles
M, Abductor medii digiti pedis muscle
P, Abductor tertii digiti pedis muscle
Q, Abductor minimi digiti pedis muscle
T, Abductor indicis muscle

a, Insertion of tibialis posticus muscle
i, Tendon of peroneus brevis muscle
m, Capsular ligaments of proximal joints of toes
n, Lateral ligaments of proximal joints of toes
p, Capsular ligaments of medial and distal joints of toes
q, Lateral ligaments of medial joints of toes

b, Os naviculare
d, Os cuneiforme internum
g, Adductor medii digiti pedis muscle
i, Indicates points of insertion of popliteus muscle
m, Internal condyle of os femoris
n, External condyle of os femoris
o, Tibia
s, Malleolus internus
t, Adductor tertii digiti pedis muscle
w, Tibial plantar ligament
x, Transverse plantar ligaments
y, Fibular plantar ligament

1, Fibula
2, Internal lateral ligament of knee-joint
3, External lateral ligament of knee-joint
5, Transverse ligaments of head of fibula
6, Proximal phalanx of great toe
7, Distal phalanx of great toe
8, Proximal phalanx of index toe
9, Medial phalanx of index toe

PLATE LIII. (Continued.)

10, At top of plate, indicates popliteal ligament
0, Distal phalanx of index toe
1, Proximal phalanx of middle toe
12, Medial phalanx of middle toe
13, Distal phalanx of middle toe
14, Proximal phalanx of ring toe
15, Medial phalanx of ring toe
16, Distal phalanx of ring toe
17, Proximal phalanx of little toe
18, Medial phalanx of little toe
19, Distal phalanx of little toe
20, Metatarsal bone of great toe
60, Head of fibula

PLATE LIV. Fig. 1.

A, Tibialis anticus muscle
B, Flexor longus digitorum pedis muscle
C, Flexor longus pollicis pedis muscle
D, Adductor indicis muscle
F, Peroneus longus muscle
G, Abductor indicis muscle
H, Interosseous ligament
I, Peroneus brevis muscle
K, Adductor medii digiti muscle
L, Adductor tertii digiti muscle
S, Maleolus externus

i, Tendon of peroneus brevis muscle
m, Capsular ligaments of first or proximal joints of toes
n, Lateral ligaments of first or proximal joints of toes
p, Capsular ligaments of medial joints of toes
q, Lateral ligaments of medial joints of toes

b, Os naviculare
d, Os cuneiforme internum
o, Tibia
p, Transverse ligaments between tarsal and metatarsal bones
s, Malleolus internus
t, Prominence of base of metatarsal bone of little toe
z, Transverse ligaments of tarsus on patellar aspect

1, Fibula
2, Metatarsal bone of index toe
3, Metatarsal bone of middle toe
4, Metatarsal bone of ring toe
5, Metatarsal bone of little toe
6, Proximal phalanx of great toe
7, Distal phalanx of great toe
8, Proximal phalanx of index toe

PLATE LIV. Fig. 1. (Continued.)

9, Medial phalanx of index toe
10, Distal phalanx of index toe
11, Proximal phalanx of middle toe
12, Medial phalanx of middle toe
13, Distal phalanx of middle toe
14, Proximal phalanx of ring toe
15, Medial phalanx of ring toe
16, Distal phalanx of ring toe
17, Proximal phalanx of little toe
18, Medial phalanx of little toe
19, Distal phalanx of little toe
20, Metatarsal bone of great toe
30, Capsular ligament of ankle-joint
31, Anterior fibular ligament of ankle-joint
32, Perpendicular fibular ligament of ankle-joint
33, Deltoid ligament of ankle-joint
70, Transverse ligament connecting tibia and fibula

Fig. 2.

D, Os calcis
H, Interosseous ligament
S, Malleolus externus

a, Os astragalus
o, Tibia
s, Malleolus internus

1, Fibula
14, Posterior fibular ligament of ankle-joint
30, Capsular ligament of ankle-joint
32, Perpendicular fibular ligament of ankle-joint
33, Deltoid ligament of ankle-joint
70, Transverse ligament connecting tibia and fibula

Fig. 3.

H, Interosseous ligament
S, Malleolus externus

a, Os astragalus
o, Tibia
s, Malleolus internus

1, Fibula
10, Synovial gland
30, Capsular ligament of ankle-joint
32, Perpendicular fibular ligament of ankle-joint
70, Transverse ligament connecting fibula and tibia

INDEX

TO

THE LETTERS OF REFERENCE

IN

THE BRAIN, FIRST PORTION.

PLATE LV.

A, Hemispheres of the cerebrum
B, Hemispheres of the cerebellum
C, Spinal cord
D, Dura mater
d, Theca vertebralis

PLATE LVI.

A, Left hemisphere of the cerebrum
B, Left hemisphere of the cerebellum
C, Spinal cord
R, Vertebral artery
X, Cervical vertebræ
Y, Margin of the cranium

a, Anterior lobe of the cerebrum
d, Theca vertebralis

a, Middle lobe of the cerebrum
x, Superior longitudinal sinus
z, Lateral sinus
ã, Posterior lobe of the cerebrum

9, Lower cervical nerves, which form axillary plexus
11, Accessory nerve to nervus vagus
19, Internal carotid artery
21, First pair of cervical nerves
22, Second pair of cervical nerves
23, Third pair of cervical nerves
24, Fourth pair of cervical nerves

PLATE LVII.

A, Right hemisphere of the cerebrum
D, Dura mater
Y, Margin of the cranium
Z, The nose

g, Temporal artery
x, Superior longitudinal sinus
y, Temporal vein

1, Veins on the surface of the right hemisphere, running into superior longitudinal sinus
5, Middle meningeal artery

PLATE LVIII.

A, Left hemisphere of the cerebrum
E, Medullary matter of the right hemisphere
G, Inferior longitudinal sinus
Y, Margin of the cranium

g, Temporal artery
v, Artery of corpus callosum
w, Corpus callosum
x, Superior longitudinal sinus
y, Middle artery of the cerebrum
D, Falx cerebri

2, Veins forming a communication with superior and inferior longitudinal sinuses

PLATE LIX.

B, Hemispheres of cerebellum
C, Spinal cord
E, Centrum ovale Vieussenii
V, Valve of Vieussens

e, Corpora bigemina superiora vel nates
e, Corpora bigemina inferiora vel testes
o, Anterior arteries of cerebellum
r, Valve of Tarin or Reil

4, Fourth ventricle

PLATE LX.

A, Anterior cornu of lateral ventricle
D, Dura mater
E, Medullary matter of hemisphere
F, Thalamus nervi optici
G, Corpus striatum
I, Inferior cornu of lateral ventricle
K, Fornix
L, Septum lucidum
M, Foramen Monroianum
P, Posterior cornu of lateral ventricle

PLATE LX. (Continued.)

i, Choroid plexus
k, Hippocampus minor
r, Posterior artery of the cerebrum
t, Tænia semicircularis
v, Artery of corpus callosum
y, Middle artery of the cerebrum
ꝑ, Hippocampus major

PLATE LXI. Fig. 1.

F, Thalamus nervi optici
G, Corpus striatum
K, Fornix
L, Septum lucidum
i, Choroid plexus
t, Tænia semicircularis
w, Corpus callosum

5, Fifth ventricle

Fig. 2.

F, Thalamus nervi optici
G, Corpus striatum
K, Fornix

a, Foramen commune anterius
i, Vena magna Galeni
k, Anterior crus of fornix
i, Choroid plexus
i, i, *i*, Velum interpositum Halleri
t, Tænia semicircularis
w, Commencement of corpus callosum

Fig. 3.

F, Thalamus nervi optici
G, Corpus striatum
H, Pineal gland

a, Foramen commune anterius
e, Natis
f, Anterior tubercle of thalamus
k, Anterior crus of fornix
m, Commissura mollis
c, Anterior commissure
e, Testis
f, Corpus geniculatum internum
h, Peduncles of pineal gland
p, Posterior commissure
t, Tænia semicircularis
w, Beginning of corpus callosum

Fig. 4.

E, Tuber annulare
F, Thalamus nervi optici
H, Pineal gland
I, Iter ad infundibulum
P, Pituitary gland

e, Natis

c, Anterior commissure
e, Testis
h, Peduncles of pineal gland
i, Infundibulum
p, Posterior commissure
r, Posterior artery of the cerebrum

3, Third ventricle
19, Internal carotid artery

Fig. 5.

Section of the medulla oblongata

Fig. 6.

F, Corpus olivare
G, Corpus pyramidale

Fig. 7.

E, Tuber annulare
F, Thalamus nervi optici
O, Ophthalmic artery
R, Vertebral artery

q, Basilar artery

1, Olfactory nerve
2, Optic nerve
3, Motor oculi nerve
4, Pathetic nerve
5, Trigeminal nerve
6, Abducens nerve
7, Facial nerve
8, Auditory nerve
9, Glosso-pharyngeal nerve
9 *a*, Fifth cervical nerve
10, Nervus vagus, or pneumogastric nerve
11, Accessory nerve of Willis
12, Lingual nerve
19, Internal carotid artery
21, First cervical nerve
22, Second cervical nerve
23, Third cervical nerve
24, Fourth cervical nerve

INDEX

TO

THE LETTERS OF REFERENCE

IN

THE BRAIN, SECOND AND CONCLUDING PORTION.

PLATE LXII.

A, Anterior cornu of lateral ventricle
E, Medullary matter of hemispheres of cerebrum
F, Thalamus nervi optici
G, near *w*, Corpus striatum
G, near ɒ, Inferior longitudinal sinus
H, Pineal gland

a, Foramen commune anterius
e, Corpus bigeminum superius vel natis
f, Anterior tubercle of thalamus
i, Vena magna Galeni
k, k, Anterior pillars of fornix

a, Foramen commune posterius
d, Tentorium cerebelli
f, Corpus geniculatum internum
h, Peduncle of pineal gland
i, Choroid plexus
p, Posterior commissure
r, Posterior artery of cerebrum
t, Tænia semicircularis
v, Artery of corpus callosum
w, Corpus callosum

ɒ, Falx cerebri

IV, Fourth venous sinus

PLATE LXIII.

B, Cerebellum
E, Medullary matter of left hemisphere of cerebrum
F, Thalamus nervi optici
G, Corpus striatum
H, Pineal gland
I, Inferior cornu of lateral ventricle
Y, Section of cranium

a, Foramen commune anterius
e, Natis
f, Anterior tubercle of thalamus
k, k, Anterior pillars of fornix

a, Foramen commune posterius
c, Anterior commissure
e, Testis
h, Peduncle of pineal gland
i, Choroid plexus
p, Posterior commissure
r, Posterior artery of cerebrum
t, Tænia semicircularis
v, Artery of corpus callosum
w, Corpus callosum
x, Superior longitudinal sinus
y, Middle artery of cerebrum
z, Lateral sinus

ɒ, Hippocampus major

4, or IV, Fourth sinus

PLATE LXIV.

B, Hemisphere, or lobe of cerebellum
E, Tuber annulare
F, Corpus olivare
G, Corpus pyramidale
R, Vertebral artery
Y, Section of cranium

a, Anterior lobe of cerebrum

a, Middle lobe of cerebrum
e, Posterior artery of cerebellum
i, Infundibulum
o, Anterior artery of cerebellum
q, Basilar artery
r, Posterior artery of cerebrum
s, *s*, Corpora mamillaria
t, Lateral communicant artery
u, Anterior communicant artery
v, Artery of corpus callosum
y, Middle artery of cerebrum

1, Olfactory nerve
2, Optic nerve
3, Motor oculi nerve
4, Pathetic nerve
5, Trigeminal nerve
6, Abducens nerve
7, Facial nerve
8, Auditory nerve
9, Glosso-pharyngeal nerve
10, Nervus vagus
11, Accessory nerve to nervus vagus
12, Lingual nerve

PLATE LXV.

B, Transverse spinous process of sphenoid bone
C, Cavernous sinus
E, Dura mater, extended over sella turcica, to cover pituitary gland

PLATE LXV. (Continued.)

R, Vertebral artery
Y, Section of cranium
Z, The Nose

b, Crista galli
d, Tentorium cerebelli
i, Infundibulum
k, Foramen magnum
o, Ophthalmic artery
p, Petrosal sinus
u, Inferior depressions of occipital bone
x, Superior longitudinal sinus
z, Lateral sinus

ɒ, Falx cerebri

δ, Falx cerebelli

1, Olfactory nerve
2, Optic nerve
3, Motor oculi
4, Pathetic nerve
5, Trigeminal nerve
5*, Middle meningeal artery
6, Abducens nerve
7, Facial nerve
8, Auditory nerve
9, Glosso-pharyngeal nerve
10, Nervus vagus
11, Accessory nerve to nervus vagus
12, Lingual nerve
19, Internal carotid artery

IV, Fourth sinus

PLATE LXVI. Fig. 1.

C, Spinal cord

d, Theca vertebralis

e, Ligamentum denticulatum

Fig. 2.

E, Tuber annulare
F, Corpus olivare
G, Corpus pyramidale

e, Natis

e, Testis
l, Processus cerebelli ad testes
n, Processus cerebelli ad tuber annulare
o, Processus cerebelli ad medullam oblongatam

4, Pathetic nerve
5, Trigeminal nerve
6, Abducens nerve
7, Facial nerve
8, Auditory nerve
9, Glosso-pharyngeal nerve
10, Nervus vagus
11, Accessory nerve to nervus vagus
12, Lingual nerve

Fig. 3.

D, Corpus dentatum
E, Tuber annulare

F, Corpus olivare
G, Corpus pyramidale

Fig. 4.

B, Cerebellum
E, Tuber annulare
F, Thalamus nervi optici
G, Corpus pyramidale
G*, Corpus striatum
N, Corpus niger

e, Natis
g, Crus cerebri

e, Testis
s, Corpus mamillare

Fig. 5.

C, Spinal cord
E, Tuber annulare
F, Thalamus nervi optici

a, Anterior lobe of cerebrum
e, Natis
g, Crus cerebri

e, Testis
i, Infundibulum
s, *s*, Corpora mamillaria

1, Olfactory nerve
2, Optic nerve
2*, Optic tract

PLATE LXVI. Fig. 6.

A, Occipital bone
B, Atlas
C, Dentata
D, Spinous processes of cervical vertebra
R, Vertebral artery
X, Body of vertebra

d, Occipital artery

e, Branch of communication between vertebral and occipital artery
k, Foramen magnum

22, Second cervical nerve
23, Third cervical nerve

PLATE LXVII.

B, Hemisphere of cerebellum
E, Tuber annulare
F, Corpus olivare
G, Corpus pyramidale

a, Anterior lobe of cerebrum
g, Crus cerebri

a, Middle lobe of cerebrum
i, Infundibulum

n, Processus cerebelli ad tuber annulare
o, Processus cerebelli ad medullam oblongatam
s, *s*, Corpora mamillaria

𝔄, Posterior lobe of cerebrum

1, Olfactory nerve
2, Optic nerve
2*, Optic tract

PLATE LXVIII.

B, Cerebellum
C, near d, Spinal cord
E, Tuber annulare
F, Thalamus nervi optici
G, Corpus pyramidale
H, Pineal gland
K, Fornix
N, Corpus niger
R, Vertebral artery
V, Valve of Vieussens

d, Theca vertebralis
e, Natis
g, Crus cerebri
i, Vena magna Galeni
k, Anterior pillar of fornix

e, Testis
l, Processus cerebelli ad testes
m, Commissure of cerebellum

n, Processus cerebelli ad tuber annulare
o, Processus cerebelli ad medullam oblongatam
p, Posterior commissure
q, Basilar artery
r, Posterior artery of cerebrum
u, Artery of corpus callosum
w, Corpus callosum
x, Superior longitudinal sinus
z, Lateral sinus

3, Third ventricle
4, near *o* and *n*, Fourth ventricle
4, or IV, near *x* and *z*, Fourth sinus
5, Fifth ventricle
19, Internal carotid artery
- - - - -, Iter à tertio ad quartum ventriculum

PLATE LXIX.

A, Hemisphere of cerebrum
D, Dura mater

Y, Section of cranium

INDEX

TO

THE LETTERS OF REFERENCE

IN

THE MUSCLES OF THE HEAD AND NECK, TOGETHER WITH THE ORGANS OF SENSE.

PLATE LXX.

A, Ribs
B, Insertion of sterno-hyoideus muscle
C, Insertion of sterno-thyroideus muscle
E, Insertion of sterno-cleido-mastoideus muscle
F, Constrictor pharyngis medius muscle
G, Stylo-hyoideus muscle
I, Œsophagus
K, Trachea
L, Longus colli muscle
R, Rectus anticus major muscle
W, Posterior head of digastric muscle
X, Os hyoides
Y, Constrictor pharyngis inferior muscle

a, Crico-thyroideus muscle
l, Masseter muscle
m, Stylo-glossus muscle
p, Splenius capitis et colli muscle

a, Zygomatic process of temporal bone
c, Capsular ligament of articulation of inferior maxillary bone
d, Angle of inferior maxillary bone
e, Sternum
i, Hyo-glossus muscle
m, Mylo-hyoideus muscle
p, Pharynx
q, Styloid process of temporal bone
s, Lateral ligament of inferior maxillary bone
w, Anterior head of digastric muscle

25, Inferior maxillary bone
40, Levator scapulæ muscle

PLATE LXXI.

B, Rectus capitis posticus major muscle
E, Insertion of sterno-cleido-mastoideus muscle
F*, Insertion of trachelo-mastoideus muscle
F, Constrictor pharyngis medius muscle
G, Origin of stylo-hyoideus muscle
H, Rectus lateralis muscle
L, Longus colli muscle
R, Rectus capitis anticus major muscle
W, Origin of posterior head of digastric muscle
X, Os hyoides
Y, Constrictor pharyngis inferior muscle

b, Mucous coat of pharynx
d, Transverse processes of cervical vertebræ
k, Stylo-pharyngeus muscle
m, Stylo-glossus muscle
n, Internal pterygoid muscle
t, External pterygoid muscle
u, Temporal muscle

a, Zygomatic process of temporal bone
b, Condyle of inferior maxillary bone
d, Angle of inferior maxillary bone
e, Capsular ligament of articulation of inferior maxillary bone
f, Internal pterygoid muscle
h, Interarticular cartilage of inferior maxillary joint
k, Genio-hyo-glossus muscle
l, Genio-hyoideus muscle
q, Styloid process of temporal bone
s, Cornu of thyroid cartilage
y, Constrictor pharyngis superior muscle

25, Inferior maxillary bone

PLATE LXXII.

A, Atlas
B, Tubercle at root of zygomatic process of temporal bone
C, Section of inferior maxillary bone
D, Palato-pharyngeus muscle
E, Rima glottidis
F, Velum palati
G, The tongue
H, Rectus capitis lateralis muscle
K, Trachea
L, Levator palati muscle
N, Cricoid cartilage
Q, Epiglottis
R, Insertion of rectus capitis anticus major muscle
R*, Vertebral artery
S, Thyroid cartilage
T, Posterior aperture of the nares
Y, Constrictor pharyngis inferior muscle

a, Circumflexus palati muscle
b, Mucous coat of pharynx
k, Insertion of stylo-pharyngeus muscle
m, Insertion of stylo-glossus muscle

PLATE LXXII. (Continued.)

n, Origin of internal pterygoid muscle
r, Rectus capitis anticus minor muscle
t, External pterygoid muscle

a, Zygomatic process of temporal bone
b, Condyle of inferior maxillary bone
c, Insertion of capsular ligament of inferior maxillary bone
d, Transverse process of atlas
e, Glenoid cavity of temporal bone
f, Uvula
k, Genio-hyo-glossus muscle
l, Unciform process of sphenoid bone
s, Superior cornu of thyroid cartilage
y, Constrictor pharyngis superior muscle

ε, Inferior articular process of atlas

1, Transverse ligament of atlas

Fig. 2.

A, Atlas
C, Interarticular cartilage of vertebræ
D, Theca vertebralis
E, Ligamentum commune anticum vertebrarum
R, Vertebral artery

c, Capsules of articular processes of vertebræ
d, Vertebra dentata

a, Body of one of the vertebræ
b, Section of bony ring of vertebra
c, Articular process of vertebra
d, Transverse process of vertebra
i, Condyle of occipital bone
k, Foramen magnum
m, Anterior margin of foramen magnum
n, Tooth-like process of vertebra dentata
o, Vein joining lateral sinus

1, Transverse ligament of atlas
2, Lateral ligament of atlas
3, Perpendicular ligament
5, Occipital bone

PLATE LXXIII. Fig. 1.

A, Tip of the tongue
B, Tubercle at root of zygomatic process of temporal bone
F, Velum palati muscle
I, Œsophagus
K, Trachea
L, Levator palati muscle
N, Cricoid cartilage
Q, Epiglottis
S, Thyroid cartilage
T, Posterior aperture of the nares
V, Hard palate

a, Circumflexus palati muscle
b, Mucous coat of pharynx
s, Inferior cornu of thyroid cartilage

a, Zygomatic process of temporal bone
e, Glenoid cavity of temporal bone
f, Uvula
g, Thyro-arytenoideus muscle
h, Foramen cœcum of tongue
i, Condyle of occipital bone
k, Genio-hyo-glossus muscle
l, Unciform process of sphenoid bone
m, Crico-arytenoideus posticus muscle
n, Arytenoideus obliquus muscle
o, Foramen condyloideum posterius
p, Crico-arytenoideus lateralis muscle
q, Arytæno-epiglottideus muscle
r, Arytenoideus obliquus muscle
s, Superior cornu of thyroid cartilage
t, Arytenoideus transversus muscle
u, Azygos uvulæ muscle
x, Apex of arytenoid cartilage
z, External pterygoid process of sphenoid bone

1, Constrictor isthmi faucium muscle
3, Tonsil or amygdala

Fig. 2.

A, The glottis
K, The trachea
N, The cricoid cartilage
Q, The epiglottis
S, The thyroid cartilage
X, The os hyoides
V, Ventricle of glottis

a, Vocal chord
b, Ligamentous band between arytenoid cartilage and epiglottis
c, Arytenoid cartilage

PLATE LXXIII. Fig. 2. (Continued.)

d, Ligament supporting epiglottis
e, Ligamentous band extending between os hyoides and thyroid cartilage
r, Membrane extending between os hyoides and thyroid cartilage
s, Superior cornu of thyroid cartilage
x, Cornu of os hyoides

Fig. 3.

N, The nose
f, Frenum of lower lip
f, Frenum of upper lip
i, Levator labii inferioris muscle
l, Glandular structure of lower lip
s, Depressor labii superioris muscle
u, Labial glands

PLATE LXXIV. Fig. 1.

A, Antrum maxillare
D, Columna nasi
F, Velum pendulum palati
G, Root of tongue
P, Palatine cell
Q, Epiglottis
T, Posterior aperture of nares
X, Bodies of cervical vertebræ
Y, Section of occipital bone
Z, Aperture to Eustachian tube
b, Mucous membrane of pharynx
b, Crista galli
c, Nasal lamella
*c**, Arytenoid cartilage
*f**, Ethmoidal cells
*g**, Section of cuneiform process of occipital bone
g, Sphenoidal cell
g, Section of cuneiform process of sphenoid bone
1*, Section of frontal bone
2, Posterior arch of fauces
3, Tonsil

Fig. 2.

A, Perpendicular cartilage of nose
B, Lateral cartilage of nose
C, Ligamentous membrane of nose
D, Columna nasi
E, Anterior aperture of nares

Fig. 3.

A, Antrum maxillare
D, Columna nasi
E, Anterior aperture of nares
b, Crista galli
c, Nasal lamella
d, Superior spongy bone
g, Sphenoid cell
1*, Section of frontal bone
2, Probe passed from the nose up to frontal sinus
3, Probe passed from the nose up along the lachrymal duct
4, Probe passed from the nose into sphenoid cell
5, Probe passed from the nose into ethmoid cell

PLATE LXXV. Fig. 1.

D, Columna of the nose
E, Cavity of the nares
b, Crista galli of ethmoid bone
c, Nasal septum
g, Sphenoidal cell
1*, Section of frontal bone
2, Probe indicating communication of frontal sinus
3, Probe indicating course of lachrymal duct
4, Probe showing the communication between sphenoidal cells and nares
5, Probe introduced into ethmoidal cells
6, Probe introduced into antrum maxillare
7, Schneiderian membrane lining cavity of nares
23, Represents the surface where the inferior spongy bone has been detached

Fig. 2.

P, Palatine cell
f, Frontal sinus
*f**, Ethmoidal cells
g, Sphenoidal cell
3, Probe introduced into lachrymal duct
6, Foramen leading to antrum maxillare
23, Indicates the surface where the inferior spongy bone has been detached

Fig. 3.

A, Antrum maxillare.

Fig. 4.

P, Spheno-palatine branch of superior maxillary nerve
p, Palato-maxillary branch of superior maxillary nerve
c, Malar twig of superior maxillary nerve
d, Dental twigs of superior maxillary nerve
f, Uvula
l, Lachrymal twig of ophthalmic branch of fifth pair of nerves
v, Vidian branch of superior maxillary nerve
1, Ophthalmic branch of fifth pair of nerves
1*, Frontal twig of first branch of fifth pair of nerves
2, Infra-orbitary branch of superior maxillary nerve
2*, Superior maxillary branch of fifth pair of nerves
3, Inferior maxillary branch of fifth pair of nerves
5, Trunk of fifth pair of nerves

PLATE LXXV. Fig. 5.

A, Antrum maxillare
P, Spheno-palatine branch of superior maxillary nerve
a, Nervous twig distributed on antrum maxillare
v, Vidian branch of superior maxillary nerve
2, Infra-orbitary branch of superior maxillary nerve
2*, Superior maxillary nerve

PLATE LXXVI. Fig. 1.

F, Velum pendulum palati
P, Palatine branch of superior maxillary nerve
V, Hard palate
f, Uvula

Fig. 2.

A, Apex of tongue
D, Dorsum of tongue
K, First ring of trachea
N, Cricoid cartilage
Q, Epiglottis
S, Thyroid cartilage
X, Body of os hyoides
s, Inferior cornu of thyroid cartilage
e, Round-shaped ligament extending between superior cornu of thyroid cartilage and cornu of os hyoides
r, Membranous ligament extending between os hyoides and thyroid cartilage
s, Superior cornu of thyroid cartilage
x, Cornu of os hyoides

Fig. 3.

A, Apex of tongue
D, Mesial line on dorsum of tongue
Q, Epiglottis
S, Side of tongue
h, Foramen cœcum of Morgagni
13, Glosso-pharyngeal nerve

Fig. 4.

A, Apex of tongue
D, Dorsum of tongue
3, Lingual nerve
13, Glosso-pharyngeal nerve
32, Gustatory branch of inferior maxillary nerve

PLATE LXXVII. Fig. 1.

B, Lobulus
C, Concha
D, Anterior auris
H, Helicis major muscle
W, Zygomatic process of temporal bone
c, Antihelix
r, Attollens aurem muscle
s, Parotid gland
a, Helix
c, Crura of antihelix
e, Tragus
g, Temporal artery
h, Helicis minor muscle
i, Fossa innominata
m, Meatus auditorius externus
n, Fossa navicularis
o, Antitragus

Fig. 2.

B, Lobulus
C, Concha
D, Anterior auris
H, Helicis major muscle
T, Tragicus muscle
W, Zygomatic process of temporal bone
c, Antihelix
r, Attollens aurem muscle
s, Parotid gland
a, Antihelix
c, Crura of antihelix
e, Tragus
g, Temporal artery
h, Helicis minor muscle
i, Fossa innominata
m, Meatus auditorius externus
n, Fossa navicularis
o, Antitragus
t, Antitragicus muscle

Fig. 3.

B, Lobulus
R, Retrahentes auris muscle
a, Helix

Fig. 4.

B, Lobulus
U, Transversus auris muscle
a, Helix
p, Cartilaginous tube of external ear

Fig. 5.

B, Lobulus
C, Concha
W, Zygomatic process of temporal bone
c, Antihelix
Z, Eustachian tube
a, Helix
c, Crura of antihelix
e, Tragus
i, Fossa innominata
m, Meatus auditorius externus
*m**, Mastoid process
n, Fossa navicularis
o, Antitragus
p, Cartilaginous portion of auditory tube
q, Styloid process
r, Membrana tympani

PLATE LXXVII. Fig. 6.

A, Fallopian aqueduct
W, Zygomatic process of temporal bone
Z, Osseous portion of Eustachian tube

m*, Mastoid cells
O, Foramen ovale
P, Osseous pyramid of tympanum
R, Foramen rotundum
T, Tympanic cavity

a, Promontory of tympanum
c, Protuberance made by external semicircular canal

1**, Bristle indicating semi-osseous canal of tensor tympani muscle
2, Bristle indicating Fallopian aqueduct, and emergence of chorda tympani nerve

Fig. 7.

C, Cochlea
M, Inferior recess of meatus auditorius internus, which gives entrance to auditory nerve
V, Vestibule
Z, Osseous portion of Eustachian tube

m, Commencement of Fallopian aqueduct
m*, Mastoid cells

b, Ridge dividing meatus auditorius internus

c, External or horizontal semicircular canal
o, Oblique or posterior semicircular canal
p, Vertical or superior semicircular canal
p-o, Union or tubulus osseous communis

1*, Head of malleus
3, Long slender process of malleus
5, Handle of malleus
6*, Body of incus
7*, Short crus of incus

Fig. 8.

a, Auditory ring of temporal bone
r, Membrana tympani
w, Base of stapes

1*, Head of malleus
3, Long slender process of malleus
5, Handle of malleus

6*, Body of incus
7*, Short crus of incus
8, Long crus of incus
9, Short interior crus of stapes
10, Long posterior crus of stapes
17, Apex of stapes

Fig. 9.

P, Osseous pyramid of tympanum
R, Foramen rotundum

w, Base of stapes resting on foramen ovale

9, Short anterior crus of stapes
10, Long posterior crus of stapes
17, Apex of stapes

Fig. 10.

C, Cochlea
V, Vestibule

R, Foramen rotundum

c, External or horizontal semicircular canal
o, Oblique or posterior semicircular canal
p, Vertical or superior semicircular canal

Fig. 11. Malleus.

1*, Head of malleus
2, Cervix of malleus
3, Long slender process of malleus

4, Short process of malleus
5, Handle of malleus

Fig. 12. Malleus.

1*, Head of malleus
2, Cervix of malleus
3, Long slender process of malleus

4, Short process of malleus
5, Handle of malleus

Fig. 13. Incus.

6*, Body of incus
7*, Short crus of incus

8, Long crus of incus

Fig. 14. Incus.

6*, Body of incus
7*, Short crus of incus

8, Long crus of incus

Fig. 15. Stapes.

w, Base of stapes

9, Short anterior crus of stapes

10, Long posterior crus of stapes
17, Apex of stapes
18, Membrane of stapes

Fig. 16.

A, Fallopian aqueduct

O, Foramen ovale
P, Osseous pyramid of tympanum
R, Foramen rotundum

a, Promontory of tympanum
c, Elevation made by external semicircular canal

t, Boundary of tympanum

1**, Semi-osseous canal of tensor tympani muscle
2, Bristle inserted in Fallopian aqueduct
33, Dotted line, indicating course of chorda tympani nerve

PLATE LXXVIII. Fig. 1.

Z, Cartilaginous portion of Eustachian tube

44, Facial nerve

See Fig. 2.

Fig. 2.

L, Laxator tympani major muscle
P, Petrous portion of temporal bone, covered by dura mater
Z, Osseous portion of Eustachian tube

m*, Mastoid cells
p, Petrosal twig of vidian nerve
q, Tensor tympani muscle
q*, Tendon of tensor tympani muscle

Z, Cartilaginous portion of Eustachian tube

m, Meatus auditorius externus
r, Membrana tympani

1*, Head of malleus
1**, Semi-osseous canal of tensor tympani muscle
4, Foramen ovale
44, Facial nerve

Fig. 3.

D, Petrous portion covered with dura mater
I, Twig of vidian nerve assisting to form the great intercostal nerve

p, Petrosal twig of vidian nerve

v, Vidian nerve

g, Cuneiform process of sphenoid bone

1, Nervus vagus
6, Sixth pair of nerves
7, Great intercostal nerve
12, Accessory nerve of Willis
19, Internal carotid artery
44, Facial nerve

See Fig. 4.

Fig. 4.

C, Cochlea
D, Petrous portion covered with dura mater
I, Twig of vidian nerve assisting to form the great intercostal nerve

l, Laxator tympani minor muscle
m*, Mastoid cells
p, Petrosal twig of vidian nerve
q, Tensor tympani muscle
q* Tendon of tensor tympani muscle

c, External or horizontal semicircular canal
m, Meatus auditorius externus

p, Superior or vertical semicircular canal
r, Membrana tympani
v, Vidian nerve

g, Cuneiform process of sphenoid bone

1*, Head of malleus
1**, Semi-osseous canal of tensor tympani muscle
3, Long slender process of malleus
6*, Body of incus
7*, Short crus of incus
8, Long crus of incus
44, Facial nerve

Fig. 5.

See Fig. 6.

Fig. 6.

C, Cochlea
D, Petrous portion invested with dura mater

m*, Mastoid cells

c, External or horizontal semicircular canal
m, Meatus auditorius externus

p, Superior or vertical semicircular canal

1*, Head of malleus
3, Long slender process of malleus
5, Handle of malleus
6*, Body of incus
7*, Short crus of incus
8, Long crus of incus
33, Chorda tympani nerve

Fig. 7.

See Fig. 8.

Fig. 8.

C, Cochlea
D, Petrous portion invested with dura mater

p, Osseous pyramid of tympanum
q, Tensor tympani muscle
q*, Tendon of tensor tympani muscle

c, External or horizontal semicircular canal

p, Superior or vertical canal

1*, Head of malleus
3, Long process of malleus
6*, Body of incus
7*, Short crus of incus
8, Long crus of incus
33, Chorda tympani nerve
44, Facial nerve

Fig. 9.

See Fig. 10.

Fig. 10.

C, Cochlea
D, Petrous portion invested with dura mater

m*, Mastoid cells
p, Osseous pyramid of tympanum

R, Foramen rotundum
S, Stapedius muscle

c, External or horizontal semicircular canal
l, Lamina spiralis

PLATE LXXVIII. Fig. 10. (Continued.)

p, Superior or vertical semicircular canal
w, Base of stapes resting on fenestra ovalis
*w**, Vestibular scala of cochlea
9, Anterior crus of stapes
10, Posterior crus of stapes
17, Apex of stapes
19, Internal carotid artery
44, Facial nerve

Fig. 11.

C, Base of cochlea
C*, Septum scalarum
a, Cupola
g, Hamulus
h, Canalis scalarum communis
i, Infundibulum
l, Lamina spiralis
m, Modiolus

Fig. 12.

A, Aqueduct of Fallopius
C, Cochlea
V, Vestibule
r, Foramen rotundum
c, External or horizontal semicircular canal
l, Lamina spiralis
p, Vertical or superior semicircular canal
p-o, Tubulus osseus communis
*w**, Aperture leading from the vestibule to the cochlea

Fig. 13.

A, Aqueduct of Fallopius
C, Cochlea
V, Vestibule
r, Foramen rotundum
c, External or horizontal semicircular canal
l, Lamina spiralis
o, Oblique or posterior semicircular canal
p, Vertical or superior semicircular canal
p-o, Tubulus osseus communis
*w**, Aperture leading from the vestibule to the cochlea

Fig. 14.

K, External aperture of aqueduct of vestibule
M, Point of entrance for auditory nerve
m, Commencement of Fallopian aqueduct in meatus auditorius internus
b, Ridge dividing meatus auditorius internus
k, External aperture of aqueduct of cochlea

Fig. 15.

C, Cochlea
M, Meatus auditorius internus
V, Vestibule
q, Tensor tympani muscle
c, External or horizontal semicircular canal
o, Oblique or posterior semicircular canal
p, Vertical or superior semicircular canal
1*, Head of malleus
6*, Body of incus
7*, Short crus of incus

Fig. 16.

A, Pinna
C, Concha
L, Laxator tympani major muscle
T, Fissure between helix and tragus
W, Fissure between helix and antitragus
X, Fissure at base of tragus
c, Antihelix
a, Helix
c, Crura of antihelix
d, Process of helix
e, Tragus
i, Fossa innominata
n, Fossa navicularis
o, Antitragus
r, Membrana tympani

Fig. 17.

C, Cochlea
G, Pyramid of vestibule
H, Cavitas hemispherica
V, Vestibule
c, External or horizontal semicircular canal
f, Aqueduct of vestibule
p, Vertical or superior semicircular canal
p-o, Tubulus osseus communis
s, Cavitas sulciformis
t, Aqueduct of cochlea

PLATE LXXIX. Fig. 1.

C, Caruncula lachrymalis
P, Plica semilunaris
S, Supercilium
T, Superior tarsus
t, Inferior tarsus
p, Punctum lachrymale

Fig. 2.

B, Nasal process of superior maxillary bone
G, Cavity of lachrymal sac
L, Levator palpebræ superioris muscle
O, Tendon of superior oblique muscle
W, Orbicularis palpebrarum muscle
b, Internal angular process of frontal bone
c, Cartilaginous pulley of superior oblique muscle
i, Inferior oblique muscle
l, Lachrymal sac
o, Membranous sheath of superior oblique muscle
p, Punctum lachrymale
q, Lachrymal gland
s, Corrugator supercilii muscle
t, Ligament of the tarsi
1, Bristle inserted in inferior canaliculus lachrymalis
2, Bristle inserted in superior canaliculis lachrymalis
13, Os nasi

Fig. 3.

D, Dura mater
G, Ganglion of Glasserus
L, Levator palpebræ superioris muscle
O, Superior oblique muscle
T, Superior tarsus
f, Frontal twig of ophthalmic branch of the fifth pair of nerves
a, Cribriform lamella of ethmoid bone
b, Crista galli
f, Frontal sinus
g, Sphenoid cell
l, Lachrymal twig of ophthalmic branch of the fifth pair of nerves
n, Nasal twig of ophthalmic branch of the fifth pair of nerves
p, Twig of frontal nerve, which supplies cartilaginous pulley of superior oblique muscle and lachrymal muscle
q, Lachrymal gland
*, Bristle inserted into canal of communication between frontal sinus and the nose
1, First or ophthalmic branch of the fifth pair of nerves
2, Optic nerve
2*, Second or superior maxillary branch of the fifth pair of nerves
3*, Third or inferior maxillary branch of the fifth pair of nerves
3, One of the third pair of nerves, or motor oculi
4, One of the fourth pair of nerves, or pathetic nerve
5, One of the fifth pair of nerves, or trigeminal nerve
6, One of the sixth pair of nerves, or abducens nerve
19, Internal carotid artery

Fig. 4.

A, Attollens vel levator oculi muscle
D, Dura mater
L, Levator palpebræ superioris muscle
O, Superior oblique muscle
T, Superior tarsus
a, Adductor oculi muscle
f, Frontal twig of ophthalmic branch of the fifth pair of nerves
g, Lenticular ganglion
a, Abductor oculi muscle
b, Crista galli
c, Cartilaginous pulley of superior oblique muscle
l, Lachrymal twig of ophthalmic branch of the fifth pair of nerves
n, Nasal twig of ophthalmic branch of the fifth pair of nerves
q, Lachrymal gland
1, First or ophthalmic branch of the fifth pair of nerves
2, One of the second pair, or optic nerves
2*, Second or superior maxillary branch of the fifth pair of nerves
3, One of the third pair of nerves, or motor oculi
3*, Third or inferior maxillary branch of the fifth pair of nerves
5, One of the fifth, or trigeminal nerves
6, One of the sixth, or abducentes nerves
19, Internal carotid artery
20, Twig of the third pair of nerves distributed on levator palpebræ muscle

INDEX

TO THE

LETTERS OF REFERENCE

IN

THE EYE, AND THE SKIN.

PLATE LXXX. Fig. 1.

A, Levator oculi muscle
L, Levator palpebræ superioris muscle
O, Obliquus superior muscle
O*, Tendon of obliquus superior muscle
P, Pituitary gland
Y, Section of cranium

a, Adductor oculi muscle
f, Frontal twig of ophthalmic branch of fifth pair of nerves

a, Abductor oculi muscle
b, Crista galli
c, Cartilaginous pulley of superior oblique muscle
d, Tentorium
g, Lenticular ganglion
i, Infundibulum
l, Lachrymal twig of ophthalmic branch of fifth nerve
n, Nasal twig of ophthalmic branch of fifth pair of nerves
p, Supra-trochlear twig of ophthalmic branch of fifth pair of nerves
q, Lachrymal gland
z, Twig of third pair of nerves distributed on levator oculi muscle

a, Twig of third pair of nerves to adductor oculi muscle
l, Twig of third pair of nerves distributed on levator palpebræ muscle
o, Twig of third pair of nerves distributed on obliquus inferior muscle

1, Ophthalmic branch of fifth pair of nerves
2, Optic nerve
2*, Superior maxillary nerve
3, Motor oculi nerve
3*, Inferior maxillary nerve
5, Trigeminal nerve
6, Sixth, or abducens nerve
19, Internal carotid artery

Fig. 2.

D, Dura mater
Y, Section of cranium

a, Adductor oculi muscle

a, Abductor oculi muscle
b, Crista galli
c, Ciliary nerves
d, Depressor oculi muscle
o, Obliquus inferior muscle
r, Reflected twig of sixth pair of nerves
z, Filament of third pair of nerves distributed on levator oculi muscle

a, Twig of third pair of nerves to adductor oculi muscle
d, Threads of third pair of nerves to depressor oculi muscle
l, Twig of third pair of nerves distributed on levator palpebræ muscle
o, Filament of third pair of nerves to inferior oblique muscle

1, Ophthalmic branch of fifth pair of nerves
2, Optic nerve
3, Motor oculi nerve
3*, Inferior maxillary nerve
5, Trigeminal nerve
6, Abducens nerve
19, Internal carotid artery

Fig. 3.

U, Upper eye-lid
u, Lower eye-lid

l, Lachrymal muscle

PLATE LXXXI. Fig. 1.

c, Ciliary nerves
d, Posterior ciliary arteries
f, Cornea
h, Ciliary veins
s, Sclerotic coat

2, Optic nerve
8, Anterior ciliary arteries

Fig. 2.

Front view of the eye-ball.

Fig. 3.

Enlarged view of Fig. 2.

f, Cornea
i, Iris
p, Pupil
s, Sclerotic coat

Fig. 4.

Vertical section of the eye-ball, in which the crystalline lens is left entire.

PLATE LXXXI.

Enlarged view of Fig. 4.

B, Anterior chamber of aqueous humour
P, Posterior chamber of aqueous humour

b, Choroid coat
f, Cornea
i, Iris
k, Arteria centralis retinæ
l, Crystalline lens
m, Ciliary folds
n, Ciliary processes
o, Vitreous humour
p, Pupil
r, Retina
s, Sclerotic coat
z, Vena centralis retinæ

2, Optic nerve

Fig. 6.

f, Cornea
i, Iris
l, Crystalline lens
n, Ciliary processes
p, Pupil
s, Sclerotic coat

Fig. 7.

b, Choroid coat
i, Iris
m, Ciliary folds
n, Ciliary processes
p, Pupil
s, Sclerotic coat

Fig. 8.

b, Choroid coat
c, Ciliary nerves
d, Posterior ciliary arteries
f, Cornea
h, Ciliary veins
s, Sclerotic coat

2, Optic nerve

Fig. 9.

b, Choroid coat
l, Crystalline lens
m, Ciliary folds
n, Ciliary processes
r, Retina
s, Sclerotic coat

Fig. 10.

b, Choroid coat
c, Ciliary nerves
d, Posterior ciliary arteries
f, Cornea
r, Retina
s, Sclerotic coat

2, Optic nerve

Fig. 11.

S, Process of Sœmmering
b, Choroid coat
r, Retina
s, Sclerotic coat

Fig. 12.

l, Crystalline lens
m, Impression of the ciliary folds
o, Vitreous humour

Fig. 13.

View of anterior surface of crystalline lens.

Fig. 14.

View of posterior surface of crystalline lens.

Fig. 15.

A, Levator oculi muscle
E, Eye-ball
L, Levator palpebræ superioris muscle
O, Obliquus superior oculi muscle
V, Ophthalmic vein

c, Cartilaginous pulley of superior oblique muscle
o, Ophthalmic artery
q, Lachrymal gland
w, Ethmoidal vein
y, Lachrymal vein

1, Ophthalmic branch of fifth pair of nerves
2, Optic nerve
2*, Superior maxillary nerve
3*, Inferior maxillary nerve
5, Fifth or trigeminal nerve
7, Lachrymal artery
9, Ethmoidal artery
10, Ethmoidal artery
19, Internal carotid artery
91, Supra-orbital, or frontal artery
99, Ethmoidal vein

PLATE LXXXI. Fig. 16.

A, Levator oculi muscle
E, Eye-ball
L, Levator palpebræ superioris muscle
O, Obliquus superior oculi muscle
O*, Tendon of obliquus superior muscle
V, Ophthalmic vein

a, Adductor oculi muscle

a, Abductor oculi muscle
c, Cartilaginous pulley of superior oblique muscle
d, Posterior ciliary arteries
h, Ciliary veins
o, Ophthalmic artery
q, Lacrymal gland
w, Ethmoidal veins
x, Muscular veins
y, Lacrymal vein

1, Ophthalmic branch of fifth pair of nerves
2, Optic nerve
2*, Superior maxillary nerve
3*, Inferior maxillary nerve
5, Fifth or trigeminal nerve
7, Lacrymal artery
8, Anterior ciliary arteries
9, Ethmoidal artery
10, Ethmoidal artery
19, Internal carotid artery

PLATE LXXXII. Fig. 1.

Front view of the epidermis of the hand.

Fig. 2.

Back view of the epidermis of the hand.

Fig. 3.

Back view of the hand, exhibiting the cutis vera.

Fig. 4.

Front view of the hand, exhibiting the cutis vera.

PLATE LXXXIII.

A, Ribs
A*, Symphysis pubis
B, Diaphragm
B*, Os sacrum
C, Os coccygis
D, Right ventricle of the heart
F, Spleen
G, Lungs
H, Left subclavian artery
I, Rectum
I*, Anus
K, Jejunum
L, Ileum
M, Triangular ligament of urethra
N, Cowper's gland
O, Bulb of urethra
P, Transverse portion of colon
T, Longitudinal muscular band of colon
X, Corpus cavernosum penis
Z, Scrotum

a, Peritoneum
b, Stomach
h, Omentum majus
i, Liver
m, Urinary bladder
r, Sphincter ani muscle
s, Arteria gastro-epiploica dextra
t, Prostate gland
u, Vesiculæ seminales
v, Vas deferens
w, contiguous to F, Arteria gastro-epiploica sinistra
w, contiguous to *f*, Ureter

c, Gluteal artery
f, Ischiadic artery
g, Left ventricle of the heart
*g**, Spermatic artery
*g***, Middle hemorrhoidal artery
k, Vesical artery
n, Catheter
z, Sigmoid flexure of colon

8, Phrenic nerve
14, Internal mammary artery

PLATE LXXXIV.

A, Ribs
A*, Pyriformis muscle
B, Diaphragm
B*, Sacrum
C, Renal artery
C*, Gluteus minimus muscle
E, Thoracic aorta
F, Spleen
F*, Gluteus maximus muscle
G, Lungs
H, Long sacro-ischiadic ligament
I, Œsophagus
I*, Rectum
I**, Anus
I***, Gluteus medius muscle
M, Caput cœcum coli
O, Ascending portion of colon
O*, Common iliac vein
P, Common iliac artery
S, Crista of the os ilium
T, Dorsal vertebræ
X, Obturator internus muscle, with gemelli muscles
Y, Kidney
Z, Tuberosity of os ischium

a, Peritoneum
b, Stomach
e, Abdominal aorta
e*, Trochanter major
f, Left branch of pulmonary artery
h, Short sacro-ischiadic ligament
i, Liver
k, Right bronchus
s, Levator ani muscle
w, Ureter
z, Diaphragmatic artery

a, Œsophageal plexus of nerves
b, Internal hemorrhoidal artery
c, Gluteal artery
f, Ischiadic artery
g, Spermatic artery
h, Internal pudic artery
i, Vena cava ascendens
p, Sacro-median artery

PLATE LXXXIV. (Continued.)

t, Lumbar artery
z, Sigmoid flexure of colon

1, Thoracic duct
2, Pulmonic plexus of nerves
2*, Left pulmonic veins
5*, Vena azygos
12, Intercostal arteries
15, Intercostal veins
20, Great sacro-ischiadic nerve

PLATE LXXXV. Fig. 1.

A, Cardiac orifice of stomach
B, Muscular tunic of stomach
D, Lesser arch of stomach
I, Œsophagus
T, Pyloric orifice of stomach
X, Greater extremity of stomach

a, Peritoneal tunic of stomach
b, Anterior or sternal aspect of stomach
c, Duodenum
p, Gastric artery
s, Arteria gastro-epiploica dextra
w, Arteria gastro-epiploica sinistra

b, Greater arch of stomach
x, Lesser extremity of stomach

Fig. 2.

A, Suspensory ligament of liver
B, Diaphragm
C, Round ligament of liver
D, Pancreas
E, Left lateral ligament of liver
F, Spleen
G, Lobulus quadratus vel anonymus
H, Pons hepatis
I, Right lobe of the liver
K, Jejunum
L, Ileum
M, Ductus communis choledochus
N, Vena portæ
P, Pancreatic duct
Q, Mesentery
R, Superior mesenteric artery
T, Pyloric orifice of the stomach
U, Superior mesenteric vein
V, Fossa umbilicalis

a, Peritoneum
b, Stomach
c, Duodenum
e, Gall bladder
i, Left lobe of the liver
k, Lobulus Spigelii of liver
n, Right branch of vena portæ
q, Hepatic artery
r, Splenic artery
s, Arteria gastro-epiploica-dextra

e, Ductus cysticus
f, Ductus hepaticus
n, Left branch of vena portæ
s, Splenic vein

Fig. 3.

r, Splenic artery
s, Splenic vein

PLATE LXXXVI. Fig. 1.

A, Cardiac orifice of stomach
B, Muscular tunic of stomach
D, Lesser arch of stomach
I, Œsophagus
T, Pyloric orifice of stomach

a, Peritoneal tunic of stomach
c, Duodenum

b, Greater arch of stomach
m, Mucous tunic of stomach

Fig. 2.

I, Right lobe of liver
M, Ductus communis choledochus
M*, Opening of ductus communis coledochus in duodenum
N, Vena portæ
T, Pyloric orifice of stomach
U, Superior mesenteric vein
V, Fossa umbilicalis
W, Fossa of gall bladder
Y, Lobulus caudatus.

b, Stomach
c, Duodenum

e, Gall bladder
i, Left lobe of liver
k, Lobulus Spigelii
n, Right branch of vena portæ
p, Gastric artery
q, Hepatic artery
s, Arteria gastro-epiploica dextra

e, Ductus cysticus
f, Ductus hepaticus
i, Vena cava ascendens
n, Left branch of vena portæ
s, Splenic vein

PLATE LXXXVII. Fig. 1.

L, Ileum
Q, Mesentery

m, Mucous tunic of ileum

Fig. 2.

L, Ileum
M, Caput cœcum coli
O, Ascending portion of colon
T, Longitudinal muscular bands of colon

1, Ligament between ileum and colon
29, Appendix vermiformis

Fig. 3.

L, Ileum
T, Longitudinal muscular bands of colon

v, Valve of colon
29, Appendix vermiformis

m, Mucous tunic of colon

INDEX

TO

THE LETTERS OF REFERENCE

IN

THE VISCERA OF THE ABDOMEN AND PELVIS, AND THE ORGANS OF GENERATION.

PLATE LXXXVIII. Fig. 1.

B, B, B, The muscular coat developed
K, K, K, K, The jejunum
Q, The mesentery
a, The peritoneal coat of the jejunum partially dissected off

Fig. 2. Section of the Kidney.

B, B, The cortical structure
C, C, C, The renal arteries
L, The renal vein
P, Pelvis of kidney
W, Ureter
a, Calyces of the infundibula
p, p, p, p, p, p, The papillæ uriniferæ
p, p*, p**, The medullary structure

Fig. 3. Section of the Kidney.

B, B, B, Cortical substance
C, C, C, Renal arteries
L, Renal vein
P, Pelvis laid open
W, Ureter
a, a, a, Calyces or infundibula laid open
p, p, p, p, Apices of papillæ uriniferæ projecting into pelvis, and surrounded by infundibula or calyces, *a*
v, p*, p**, Medullary structure

PLATE LXXXIX.

A, Symphysis pubis
B, Section of os sacrum
C, Os coccygis
D, Triangular space of urinary bladder formed by vasa deferentia and peritoneum
E, Membranous portion of urethra
F, Bulb of urethra
G, Corpus spongiosum urethræ
H, Meatus urinarius
I, Rectum
K, Glans penis
L, Prepuce
M, Sebaceous glands on prepuce and glans
N, Frenum
O, Spermatic vein
R, Rectus muscle
X, Corpus cavernosum penis
Z, Scrotum
b, Tunica vaginalis testis
m, Muscular tunic of urinary bladder
r, Body of testis
s, Levator ani muscle
t, Prostate gland
u, Vesiculæ seminales
v, Vas deferens
w, Ureter
a, Peritoneal coat of urinary bladder
g, Spermatic artery
r, Epididymis

PLATE XC. Fig. 1.

E, Membranous portion of urethra
F, Bulb of the urethra laid open
G, Corpus spongiosum urethræ
K, Glans penis
K*, Glans penis laid open
M, Muscular coat of urinary bladder
P, Cellular tunic of urinary bladder
Q, Mucous coat of urinary bladder
S, Probe inserted in ureter
U, Urethra
h, Meatus urinarius
t, Prostate gland laid open
t, Caput galinaginis
w, Ureter
w*, Entrance of ureter in urinary bladder
x, Corpus cavernosum penis laid open

Fig. 2.

Y, Membranous septa of testis
v, Vas deferens

PLATE XCI.

A, Mons veneris
B, Labium externum
C, Superior commissure of vagina
D, Vagina
D*, Inferior commissure of vagina
E, Perineum
F, Nymphæ
G, Glans clitoridis

PLATE XCI. (Continued.)

H, Preputium clitoridis
I, Anus
K, Meatus urinarius
L, Hymen
d, Vagina

PLATE XCII.

B, External labium
G, Glans clitoridis
H, Preputium clitoridis
I*, Anus
M, The skin held out by hooks
N, Sphincter vaginæ muscle
Q, Fascia lata
Y, Gluteus maximus muscle
p, Erector clitoridis muscle
q, Transversus perinæi muscle
q*, Transversus perinæi alter muscle
r, Sphincter ani muscle
s, Levator ani muscle
70, Ligamentum suspensorium labiorum

PLATE XCIII.

A, Mons veneris
A*, Symphysis pubis
B, Labium externum
C, Superior commissure
D, Mucous tunic of vagina
F, Nymphæ
G, Glans clitoridis
I, Rectum
I*, Anus
K, Meatus urinarius
L, Carunculæ myrtiformes
N, Ovarium
P, Cellular tunic of the urinary bladder
R, Os uteri
S, Corpus fimbriatum
T, Corpus spongiosum urethræ
v, Spongy structure of vagina
b*, Sacro-iliac synchondrosis
g, Crus clitoridis
k, Fundus uteri
k**, Ovarian aperture of Fallopian tube
l, Round ligament of uterus
m, Fundus of urinary bladder
r, Sphincter ani
w, Ureter
a, Peritoneum
k, Broad ligament of uterus
*k**, Fallopian tube
n, Proper ligament of ovarium
z, Sigmoid flexure of colon

PLATE XCIV. Fig. 1.

A, Mons veneris
B, Labium externum
C, Superior commissure of vagina
D, Mucous tunic of vagina
D*, Inferior commissure of vagina
E, Perineum
F, Nymphæ
G, Glans clitoridis
H, Preputium clitoridis
I, Rectum
I*, Rectum
I**, Anus
K, Meatus urinarius
L, Carunculæ myrtiformes
N, Ovarium
N*, Ovarium laid open
P, Cellular tunic of urinary bladder
Q, Mucous tunic of urinary bladder
R, Os uteri
S, Corpus fimbriatum
s*, Whalebone probe inserted in ureter
U, Urethra
v, Spongy structure of vagina
g, Crus clitoridis
k, Fundus uteri
m, Muscular tunic of urinary bladder
a, Peritoneum
b, Fleshy structure of uterus
e, Transverse lines of cervix uteri
g, Longitudinal ridge of cervix uteri
k, Broad ligament of uterus
*k**, Fallopian tube
*k***, Ovarian aperture of Fallopian tube
n, Proper ligament of ovarium
p, Mucous tunic of uterus

Fig. 2.

B, External labium
G, Glans clitoridis
H, Preputium clitoridis
g, Crus clitoridis
d, External aspect of mucous tunic of vagina
f, Vascular plexus of vagina

INDEX

TO

THE LETTERS OF REFERENCE

IN

GRAVID UTERUS, AND THE LYMPHATIC SYSTEM.

PLATE XCV.

A, Mons veneris
E, Cervix uteri
K, Body of uterus
L, Ileum
M, Caput cœcum coli
N, Ovarium
O, Ascending portion of colon
P, Transverse arch of colon
S, Corpus fimbriatum

h, Omentum majus
k, Fundus uteri

a, Peritoneum investing flaps of abdominal parietes
*k**, Fallopian tube
*k***, Ovarian aperture of Fallopian tube
z, Sigmoid flexure of colon

PLATE XCVI.

A, Mons veneris
E, Cervix uteri
K, Body of uterus
L, Ileum
M, Caput cœcum coli
N, Ovarium
O, Ascending portion of colon
P, Transverse portion of colon
S, Corpus fimbriatum

g, Umbilical vein
h, Omentum majus

a, Peritoneum investing flaps of abdominal parietes
b, Section of uterus
c, Amnion
d, Chorion
f, Decidua
*k**, Fallopian tube
*k***, Ovarian aperture of Fallopian tube
n, Umbilical artery
p, Placenta
z, Sigmoid flexure of colon

PLATE XCVII. Fig. 1.

g, Umbilical vein

c, Amnion

d, Chorion
f, Decidua
p, Placenta

Fig. 2.—An Ovum, 20 days old, laid open

c, Amnion

d, Chorion

Fig. 3.—An Ovum, 40 days old.

d, Chorion

Fig. 4.—An Ovum, 40 days old, laid open.

c, Amnion
d, Chorion

e, Fetus
h, Vesicula umbilicalis

Fig. 5.—A Fetus, 50 days old.

h, Vesicula umbilicalis

Fig. 6.—A Fetus, 60 days old.

u, Umbilical cord

Fig. 7.—An Ovum, 60 days old.

d, Chorion

PLATE XCVII. Fig. 8.—An Ovum, 60 days old.

d, Chorion

Fig. 9.—An Ovum, 90 days old.

g, Umbilical vein

c, Amnion

d, Chorion
f, Decidua

PLATE XCVIII.

A, Ribs
A*, Suspensory ligament of liver
D, Right ventricle of heart
E, Aorta
F, Pulmonary artery
H, Left subclavian artery
I, Right lobe of liver
I*, Rectum
K, Jejunum
L, Ileum
M, Left internal jugular vein
M*, Caput cœcum coli
O, Ascending portion of colon
P, Transverse arch of colon
P*, Left carotid artery
Q, Arteria innominata
R, Superior mesenteric artery
T, External iliac artery
U, Femoral vein
X, Penis

d, Right auricle of heart
e, Gall-bladder
f, Left branch of pulmonary artery
g, Left ventricle of heart
i, Left lobe of liver

r, Testis
t, Superficial femoral artery

d, Left auricle of heart
g, Spermatic artery
h, Vena cava descendens
r, Right coronary artery
r, Epididymis
s, Left coronary artery
v, Left subclavian vein
z, Sigmoid flexure of colon

1, Thoracic duct
2, Mesocolic glands
3, Mesenteric glands
4, Intercostal lymphatics
12, Lacteals of the jejunum and ileum
13, Lacteals of the colon
14, Lymphatics of the liver
15, Deep-seated inguinal glands
16, External iliac glands
19, Internal iliac or hypogastric glands
20, Lymphatics of the heart
29, Appendix vermiformis
34, Lymphatics of the testis

PLATE XCIX. Fig. 1.

A, Ribs
A*, Clavicle
B, Deltoid muscle
G, Lungs
K, Trachea
M, Internal jugular vein
P, Left carotid artery

b, Bronchial glands
h, Brachial artery
k, Bronchus
q, Basilic vein
r, Cephalic vein
s, Parotid gland
s*, Median vein
u, Brachial vein

Z, Thyroid gland

h, Vena cava descendens
u, Axillary vein

v, Subclavian vein

1, Thoracic duct
2, Lymphatic glands at elbow-joint
3, Axillary glands
4, Deep inferior cervical lymphatic glands
5, Truncated pectoral lymphatics
6, Deep superior cervical lymphatic glands
7, Lymphatic glands at base of inferior maxilla
10, Superficial lymphatic glands behind the ear
11, Lymphatic glands accompanying the internal jugular vein
18, Lymphatics of lungs
21, Lymphatics of fore-arm
22, Brachial lymphatic glands

PLATE XCIX. Fig. 2.

v, Fascia palmaris

q, Basilic vein
r, Cephalic vein

s, Median vein

2, Lymphatic glands at elbow-joint

PLATE C.

A, Clavicle
B, Lateral nasal cartilage
C, Sterno-hyoideus muscle
D, External jugular vein
E, Sterno-cleido-mastoideus muscle
G, External carotid artery
U, Sterno-thyroideus muscle

a, Zygomaticus major muscle
b, Depressor anguli oris muscle
e, Zygomaticus minor muscle
f, Orbicularis oris muscle
i, Levator labii superioris alæque nasi muscle
l, Masseter muscle
n, Compressor naris muscle
q, Occipito-frontalis muscle
r, Attollens aurem muscle
s, Parotid gland
w, Orbicularis palpebrarum muscle

y, Temporal vein
z, Facial vein

c, Facial artery
d, Occipital artery
g, Temporal artery
m, Mylo-hyoideus muscle
w, Anterior belly of digastric muscle
z, Frontal vein

4, Inferior cervical lymphatic glands
7, Lymphatic glands at the base of inferior maxilla
8, Temporal lymphatic glands
9, Superficial cervical lymphatic glands
10, Superficial lymphatic glands behind the ear

PLATE C. (Continued).

23, Facial lymphatics
24, Temporal lymphatics
25, Lymphatic glands on buccinator muscle
26, Occipital lymphatics

70, Depressor labii inferioris muscle
90, Occipital vein
91, Frontal artery

PLATE CI. Fig. 1.

K, Fascia lata
Z, Scrotum

b, Tunica vaginalis testis

a, Inferior superficial inguinal glands
b, Saphena major vein

17, Superior superficial inguinal glands

27, Superficial lymphatics of the thigh
28, Superficial lymphatics of abdomen
30, Superficial lymphatics of the loins
31, Superficial lymphatics of the nates
32, Superficial lymphatics of the penis
33, Superficial lymphatics of the scrotum

Fig. 2.

K, Fascia lata

b, Vena saphena major

s, Malleolus internus

27, Superficial lymphatics of the leg

FINIS.

EDINBURGH:
PRINTED BY W. H. LIZARS.

PLATE I.

Engraved by W. H. Lizars.

PLATE II.

Fig. 1.

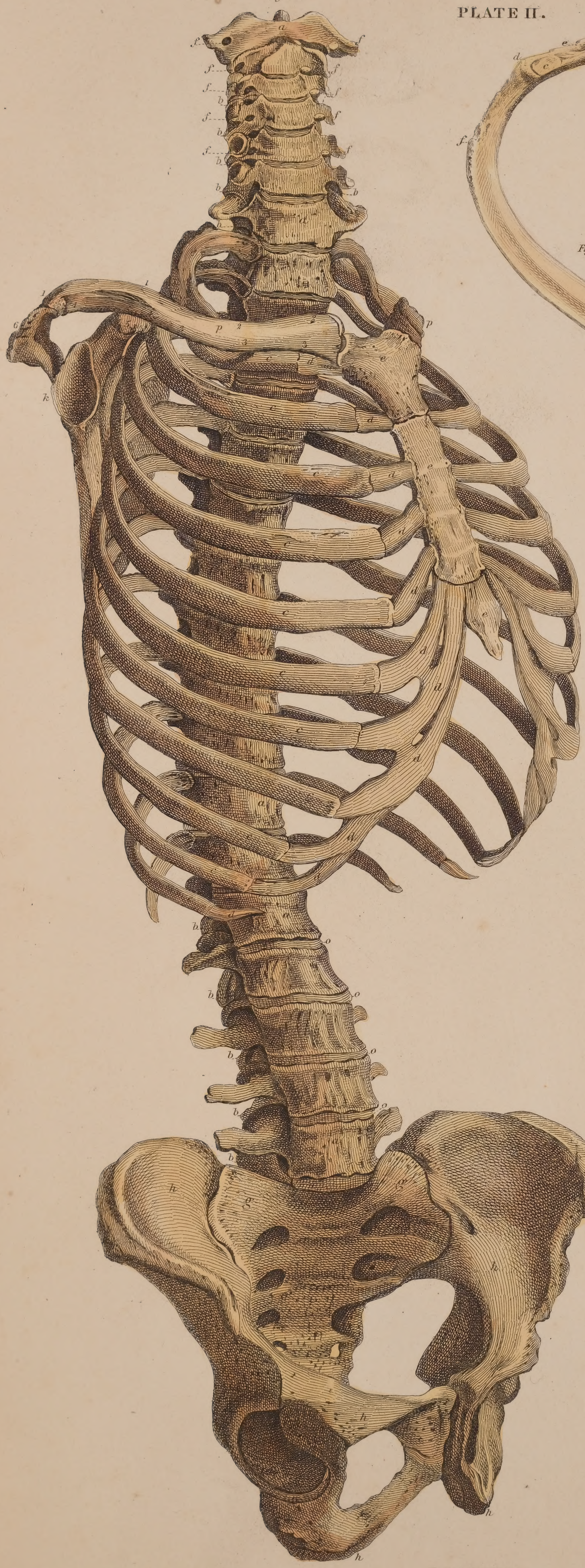

Fig. 7.

Fig. 8.

Fig. 5.

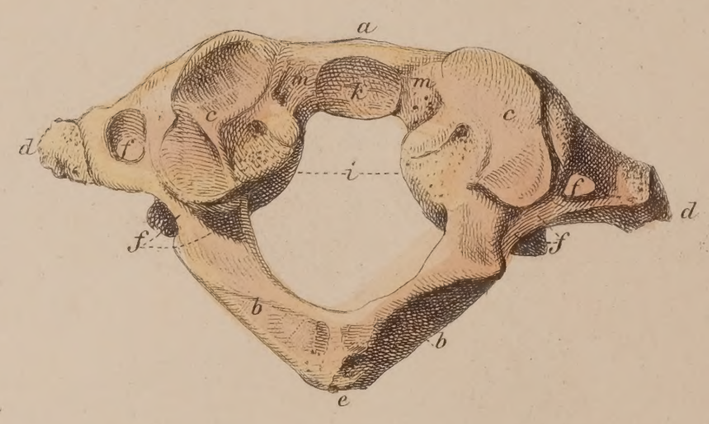

Fig. 6.

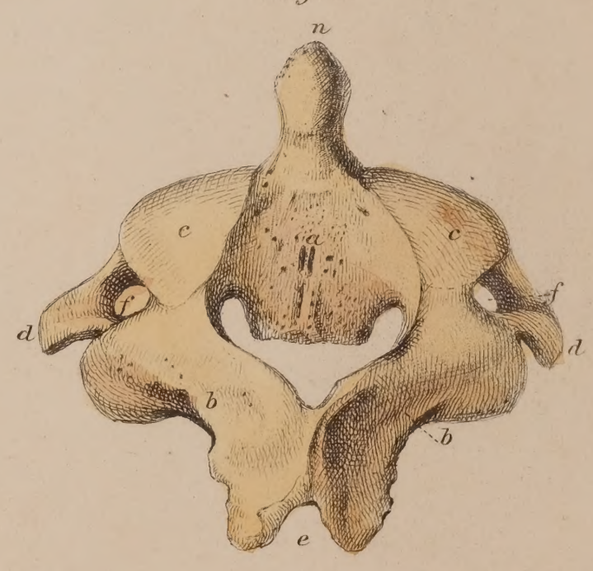

Fig. 3.

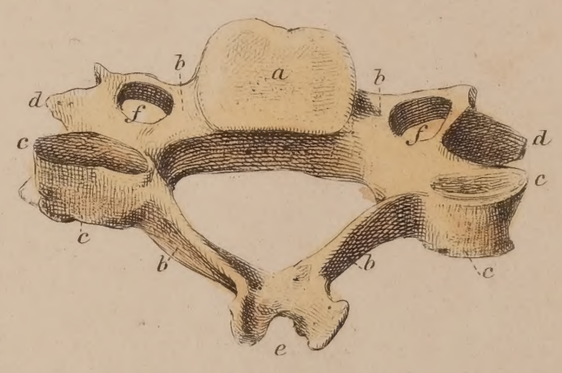

Fig. 4.

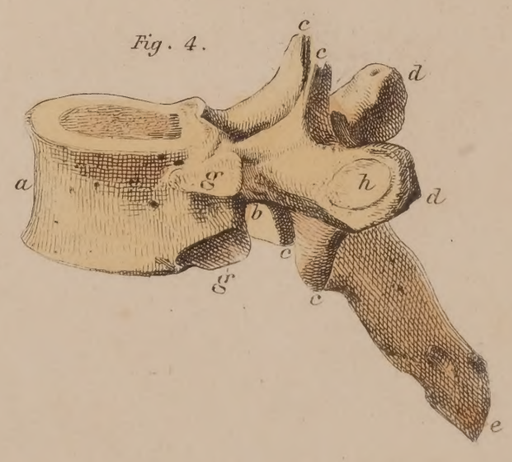

Fig. 2.

Engraved by W. H. Lizars.

PLATE III.

Fig. 1.

Fig. 2.

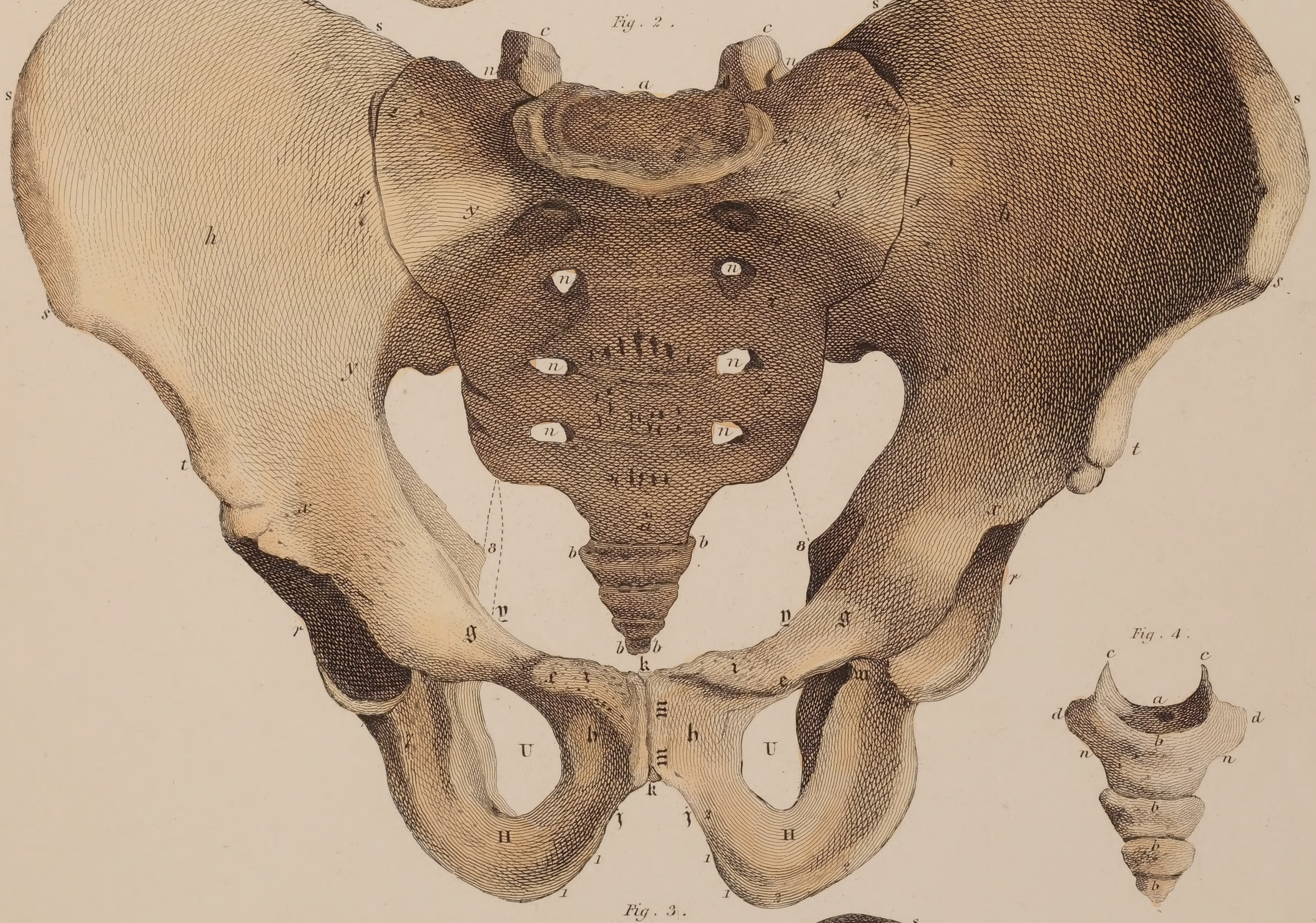

Fig. 4.

Fig. 3.

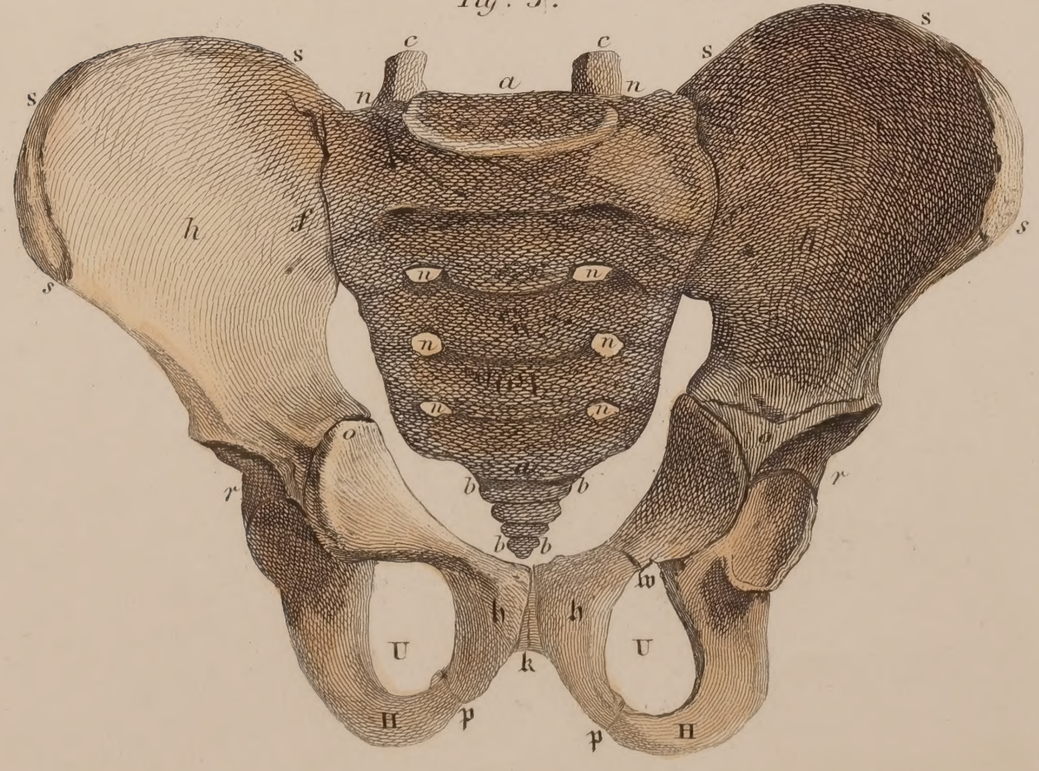

Engraved by W. H. Lizars.

PLATE IV.

Fig. 1.

Fig. 2.

Fig. 3.

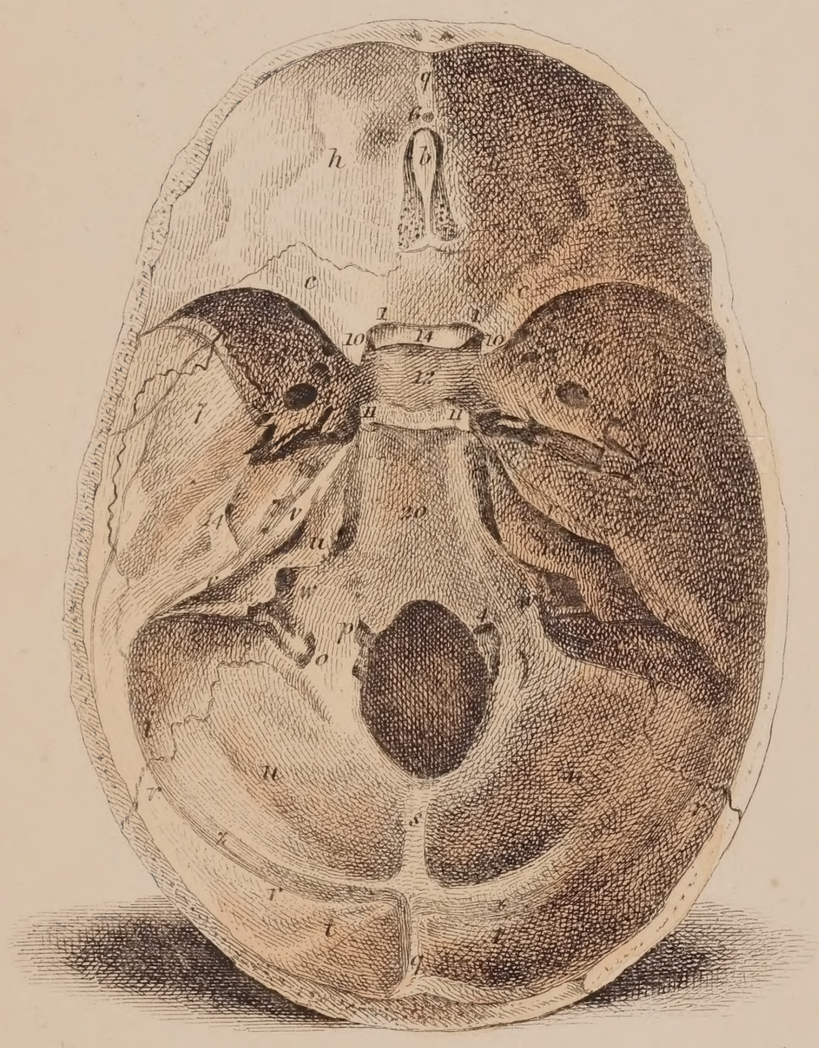

Fig. 4.

Fig. 5.

Fig. 7.

Fig. 6.

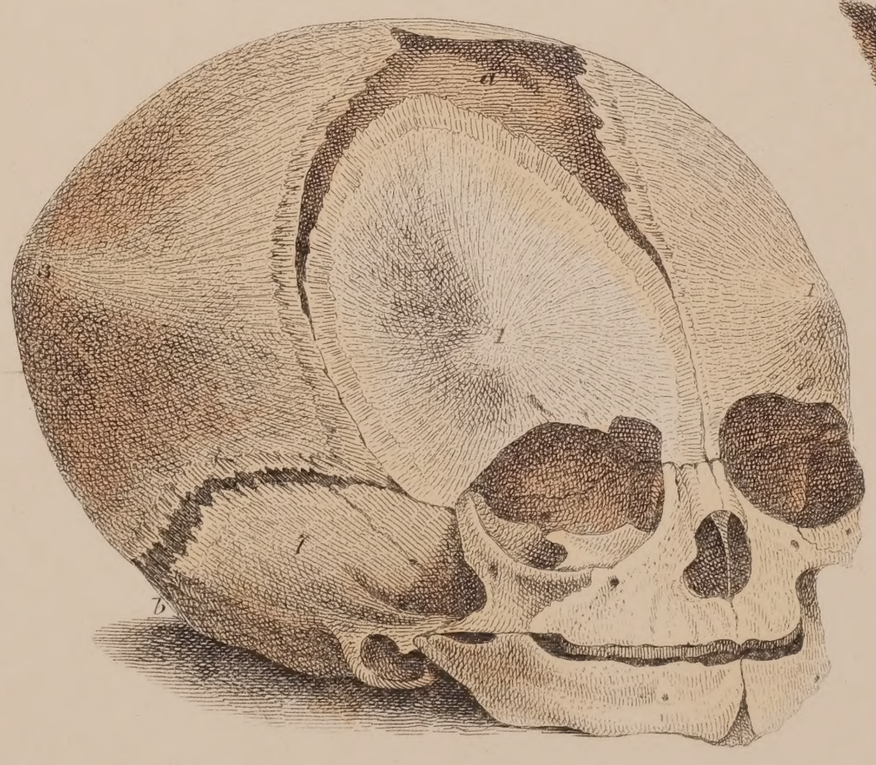

Fig. 9.

Fig. 8.

Fig. 10.

Engraved by W. H. Lizars.

PLATE V.

Fig. 1.

Fig. 12.

Fig. 2.

Fig. 11.

Fig. 3.

Fig. 4.

Fig. 7.

Fig. 5.

Fig. 6.

Fig. 8.

Fig. 9.

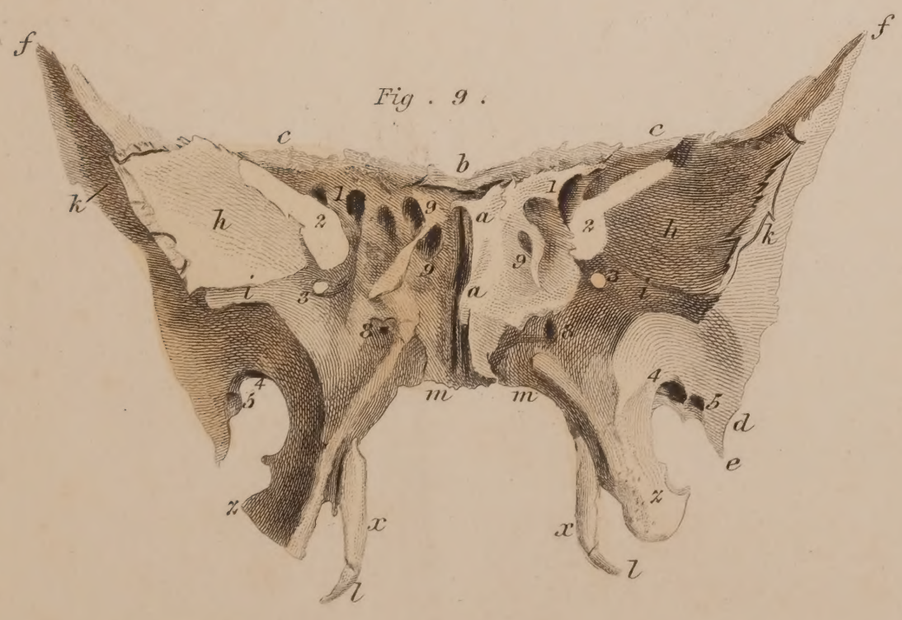

Fig. 10.

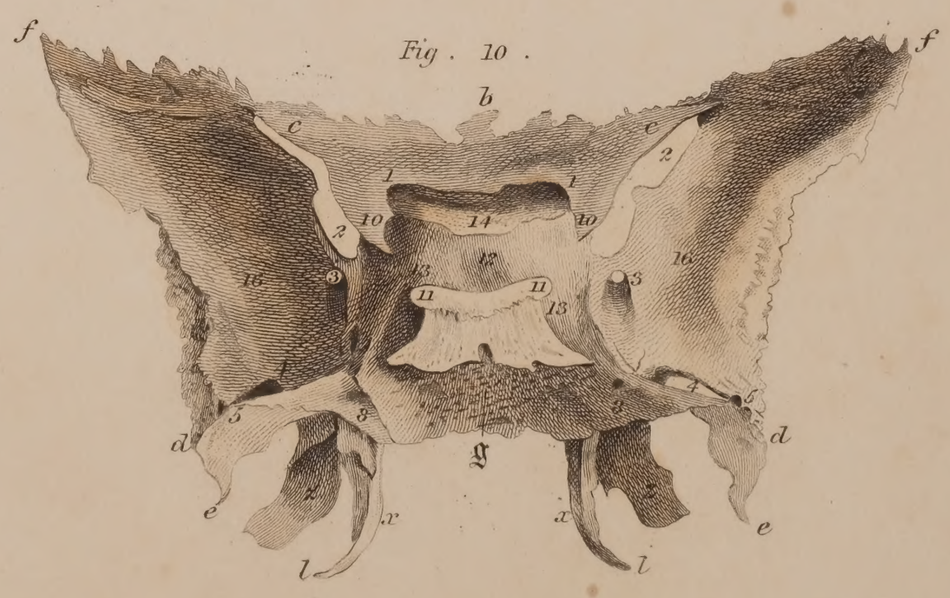

Engraved by W. H. Lizars

PLATE VI.

Fig. 16.

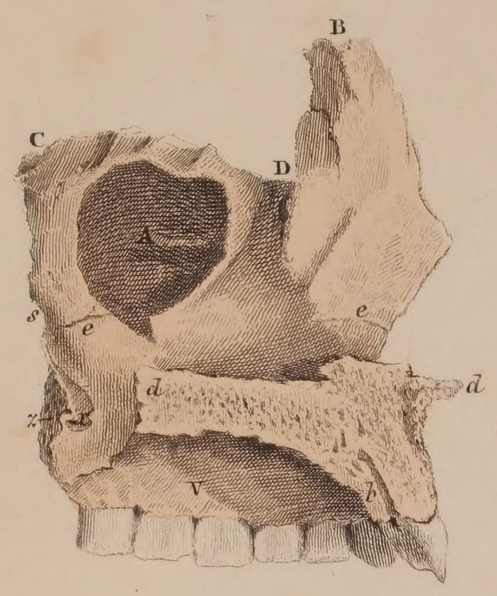

Fig. 27.

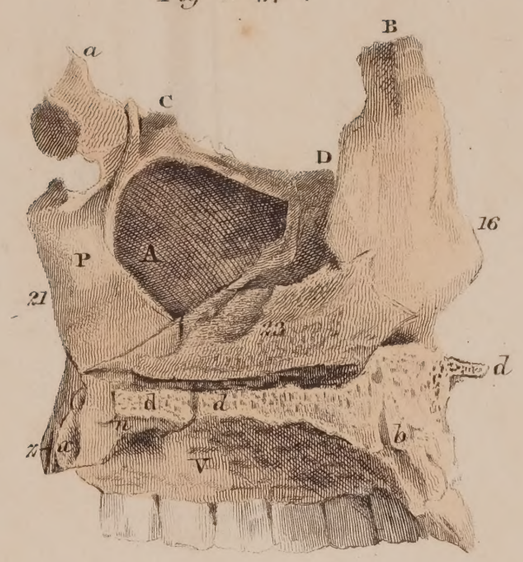

Fig. 15.

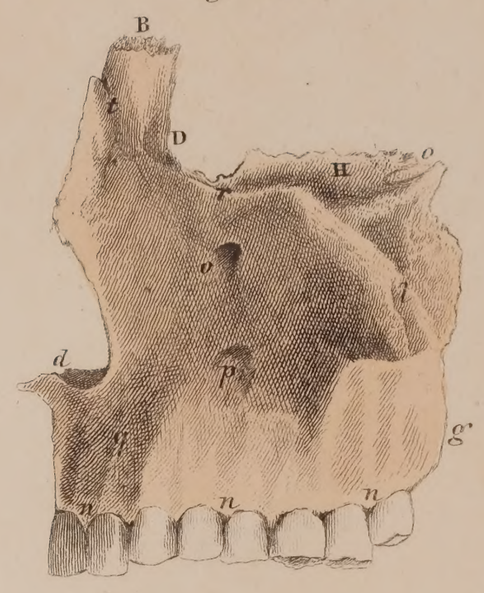

Fig. 28.

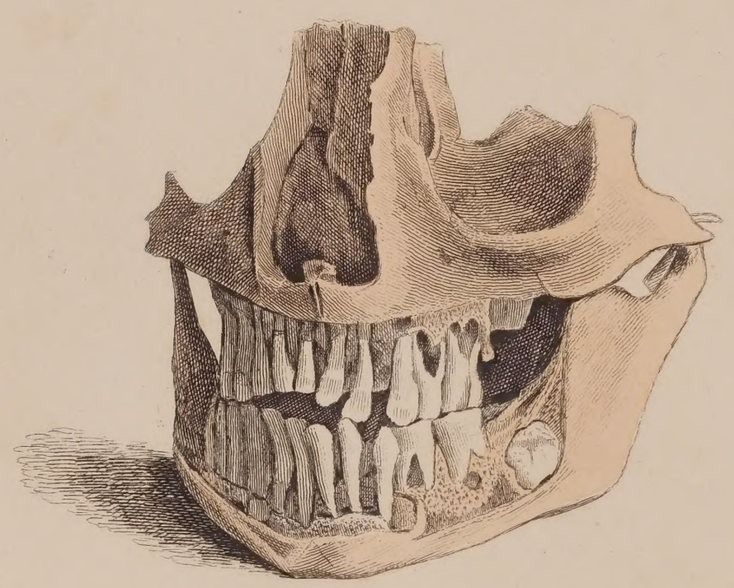

Fig. 24.

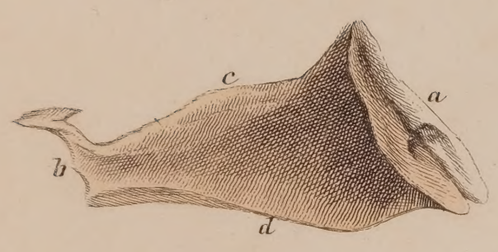

Fig. 23.

Fig. 25.

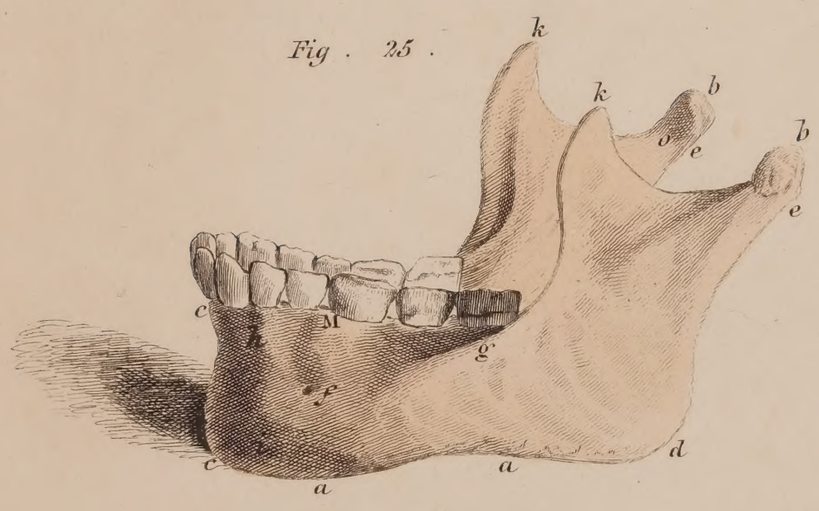

Fig. 26.

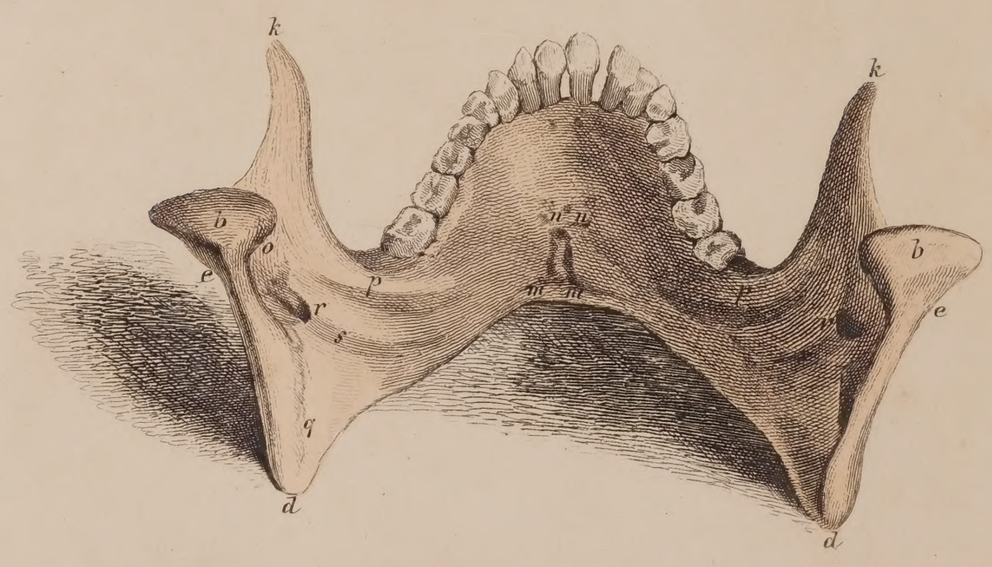

Fig. 18.

Fig. 20.

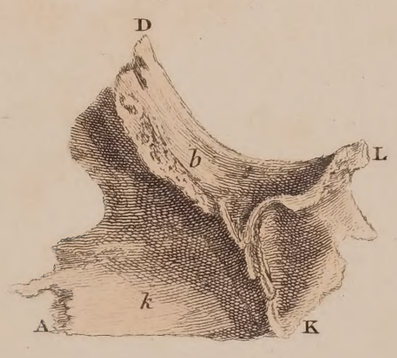

Fig. 19.

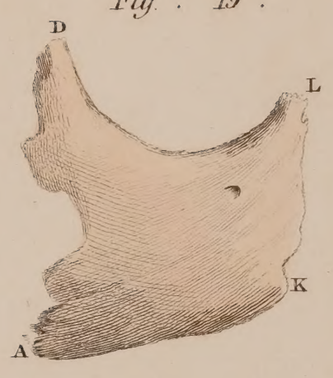

Fig. 17.

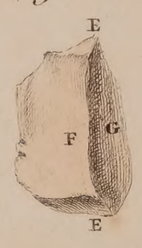

Fig. 13.

Fig. 29.

Fig. 14.

Fig. 21.

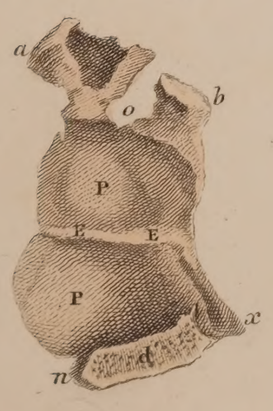

Fig. 22.

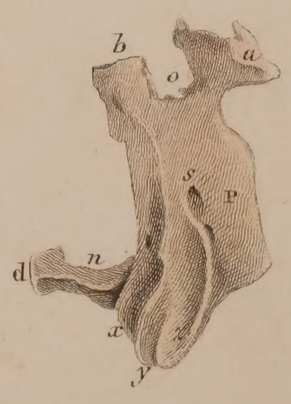

Engraved by W. H. Lizars

PLATE VII.

Fig. 7.

Fig. 8.

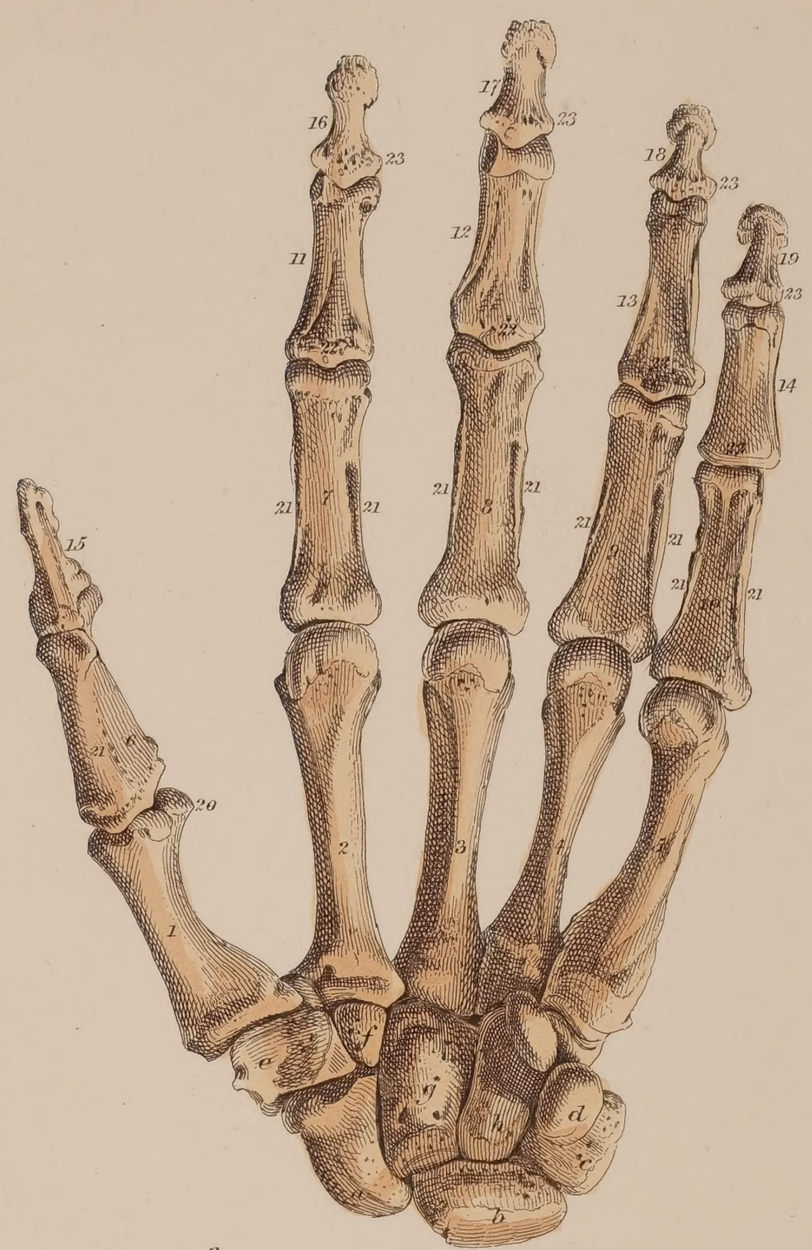

Fig. 1.

Fig. 2.

Fig. 5.

Fig. 3.

Fig. 6.

Fig. 4.

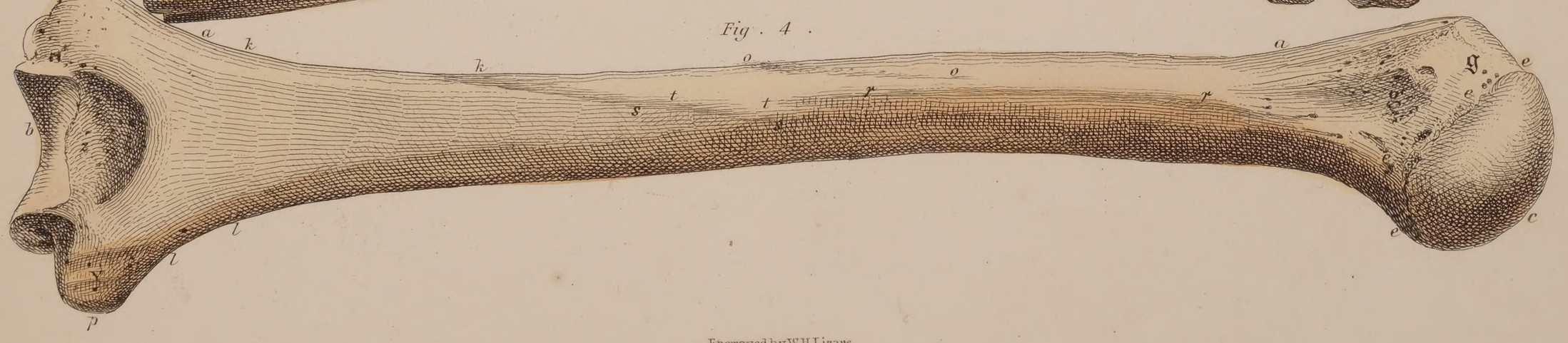

Engraved by W. H. Lizars.

PLATE VIII.

Fig. 1.

Fig. 2.

Fig. 5.

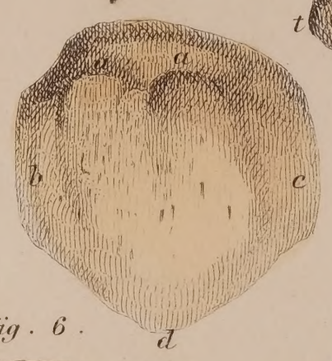

Fig. 6.

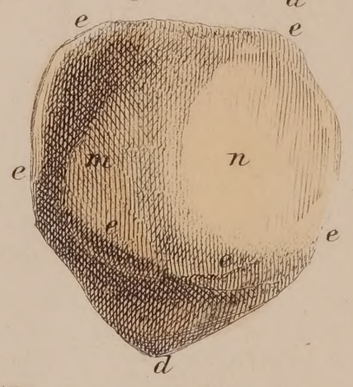

Fig. 9.

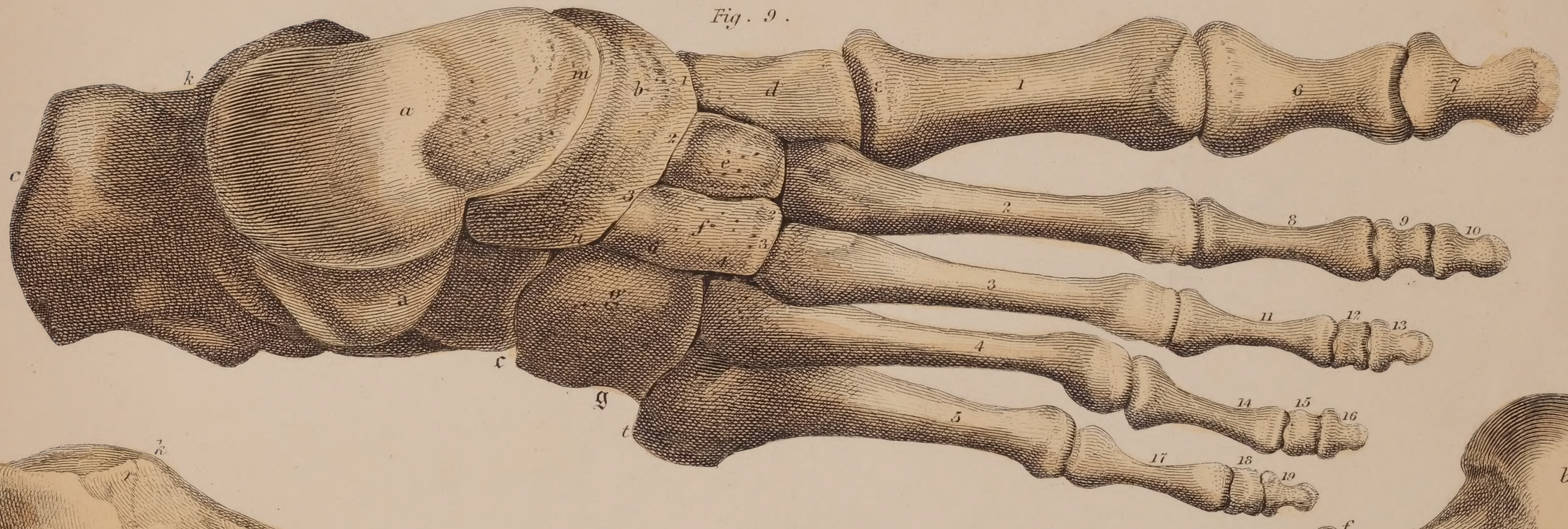

Fig. 4.



Fig. 3.

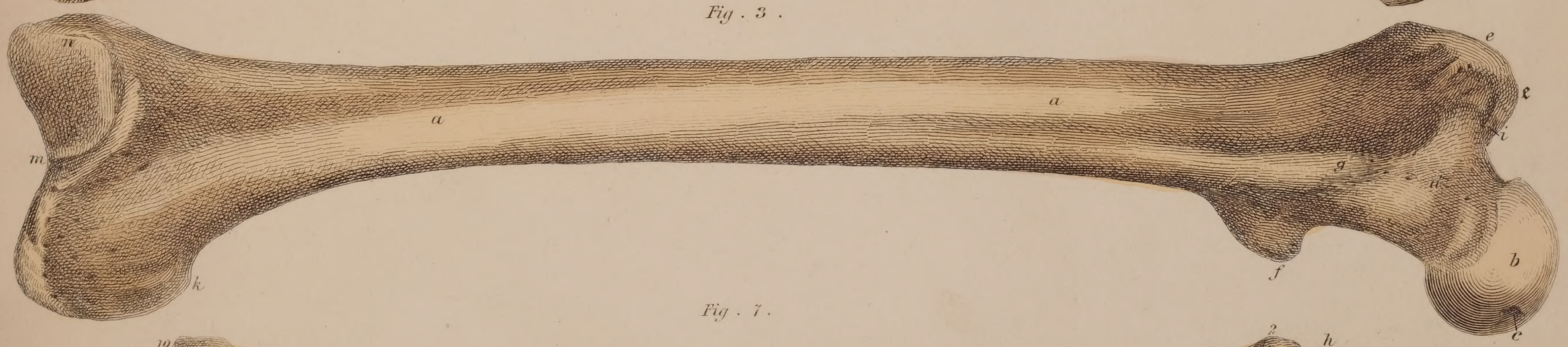

Fig. 7.



Fig. 8.

Engraved by W.H. Lizars.

PLATE IX.*

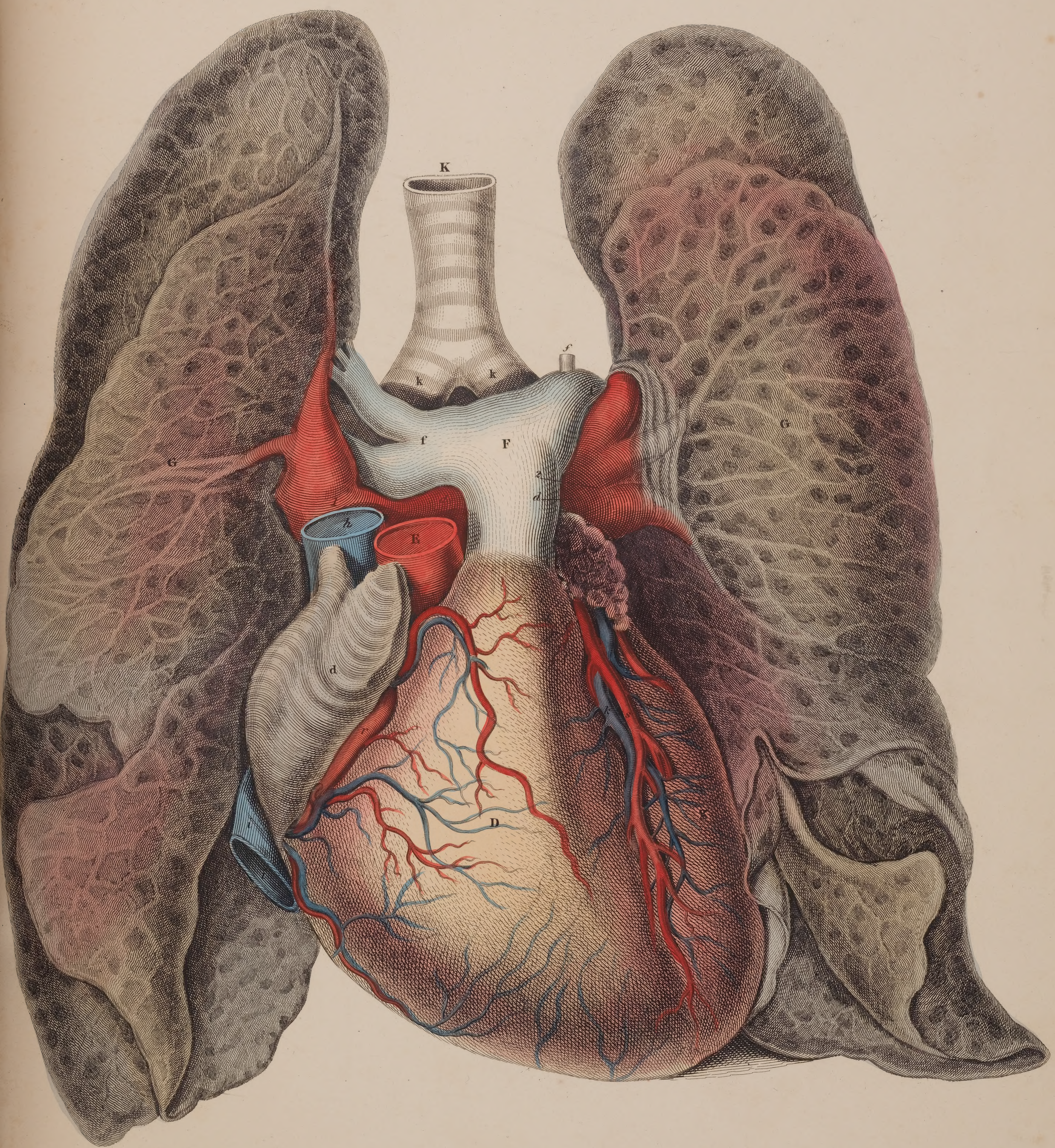

Engraved by W.H. Lizars.

PLATE IX.

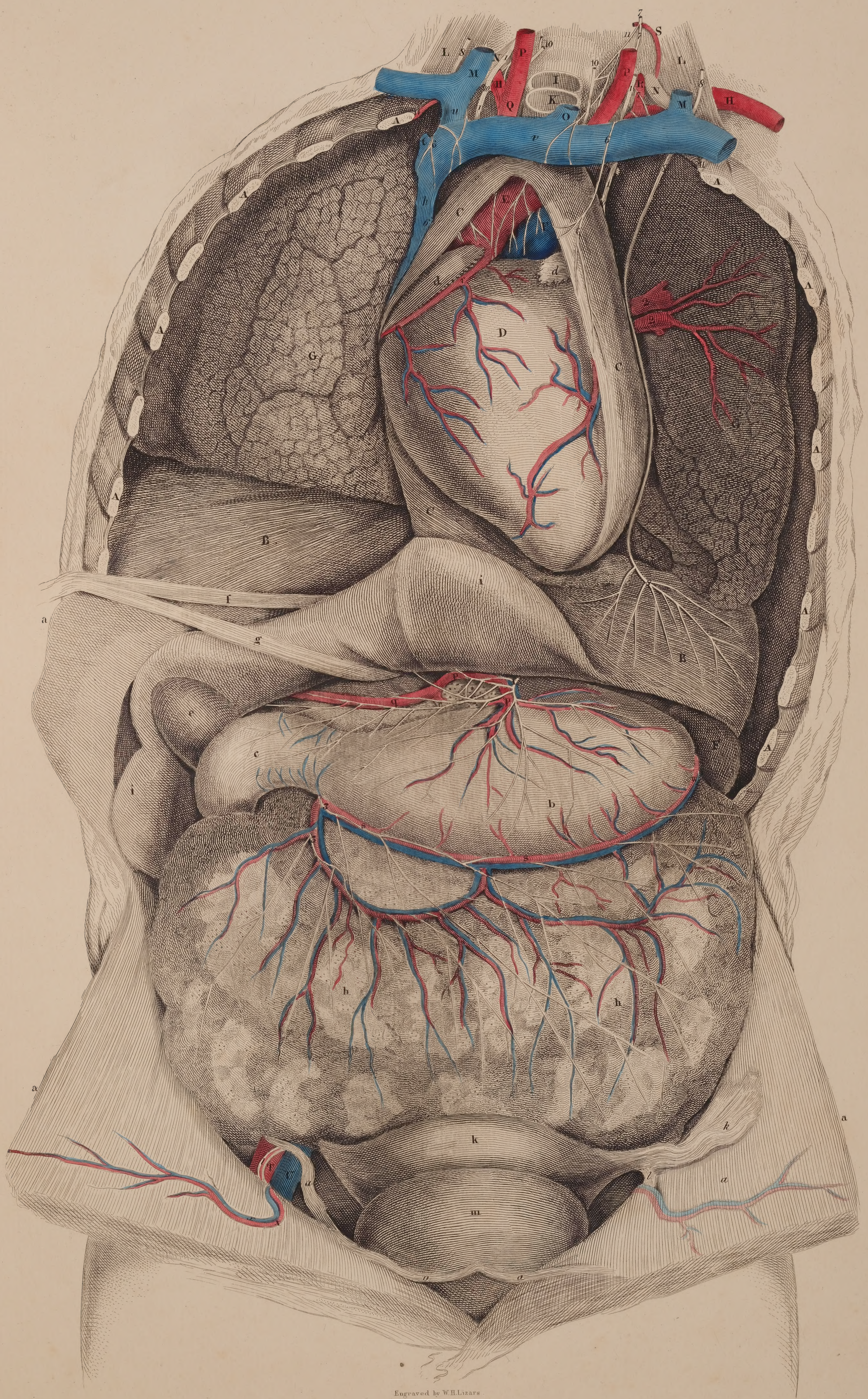

Engraved by W.H.Lizars

PLATE X.

Fig. 1.

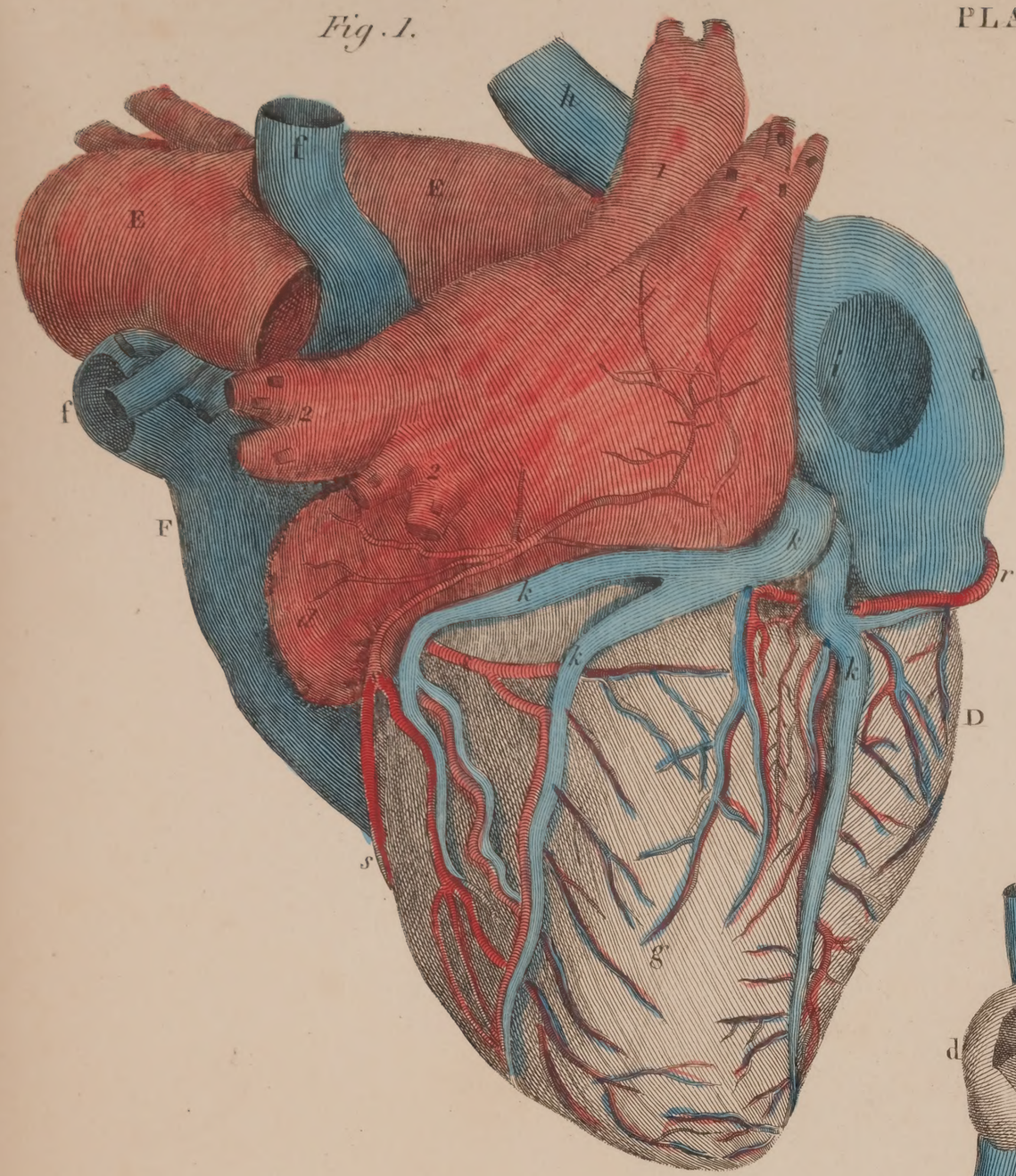

Fig. 2.

Fig. 3.

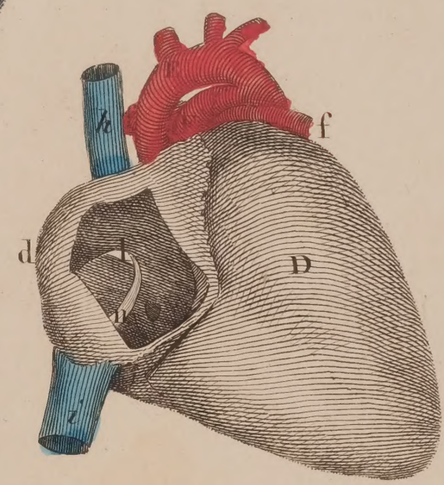

Fig. 4.

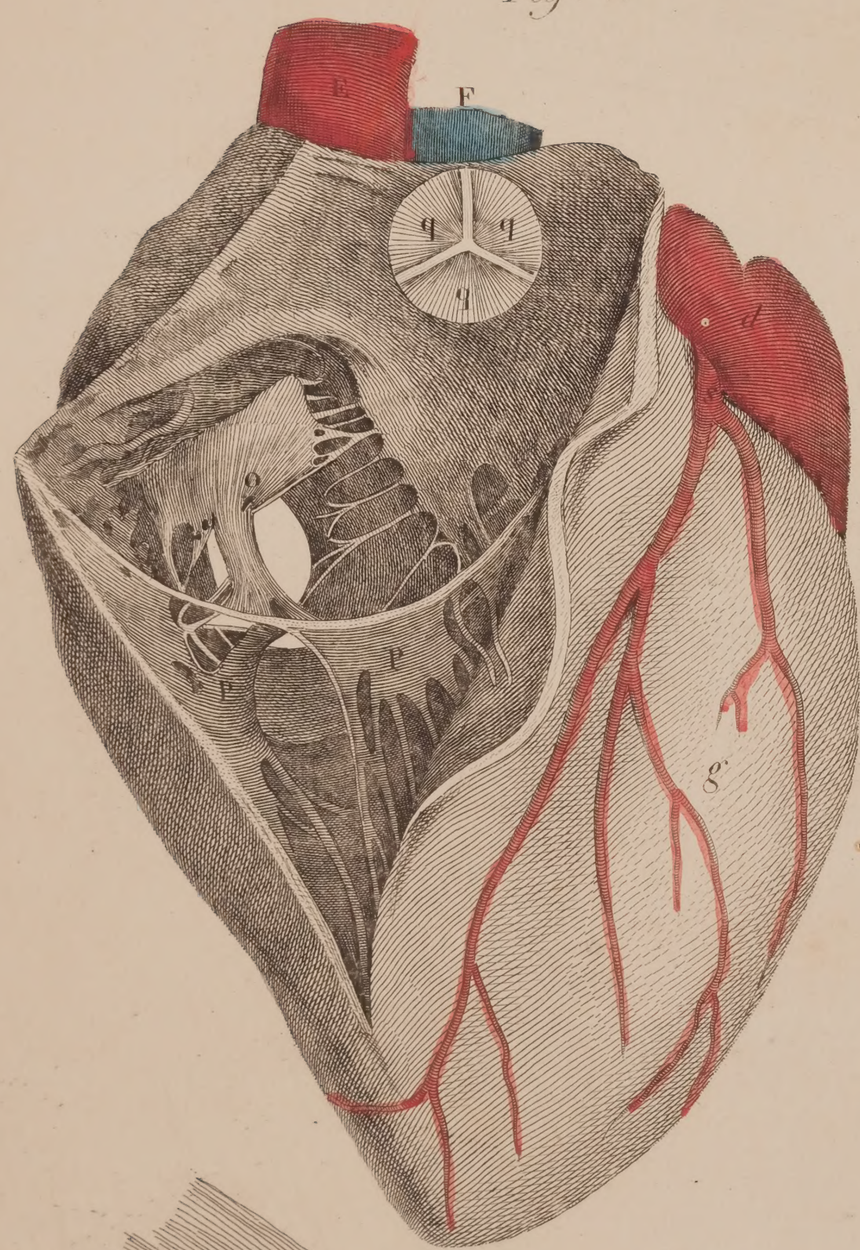

Fig. 5.

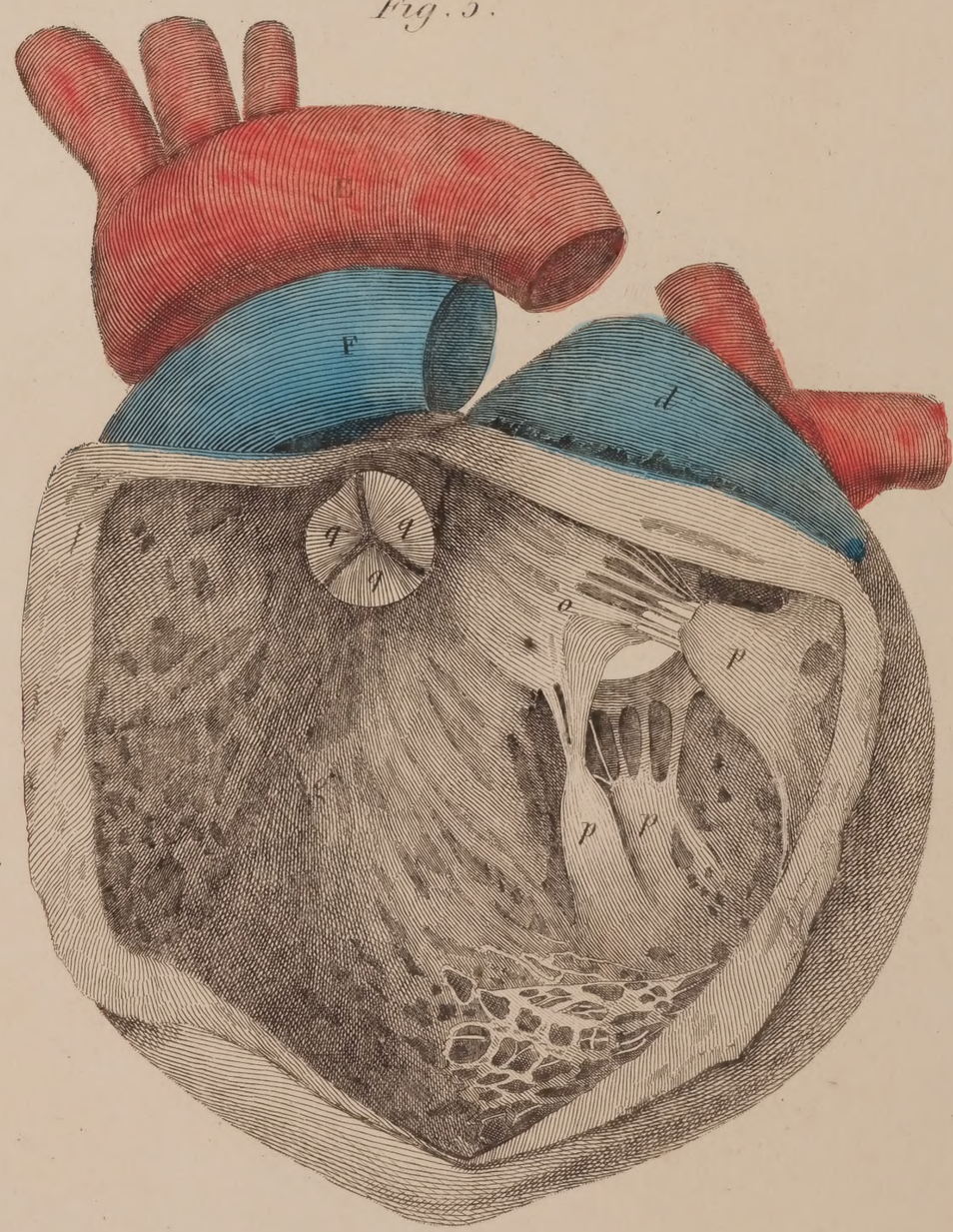

Fig. 6.

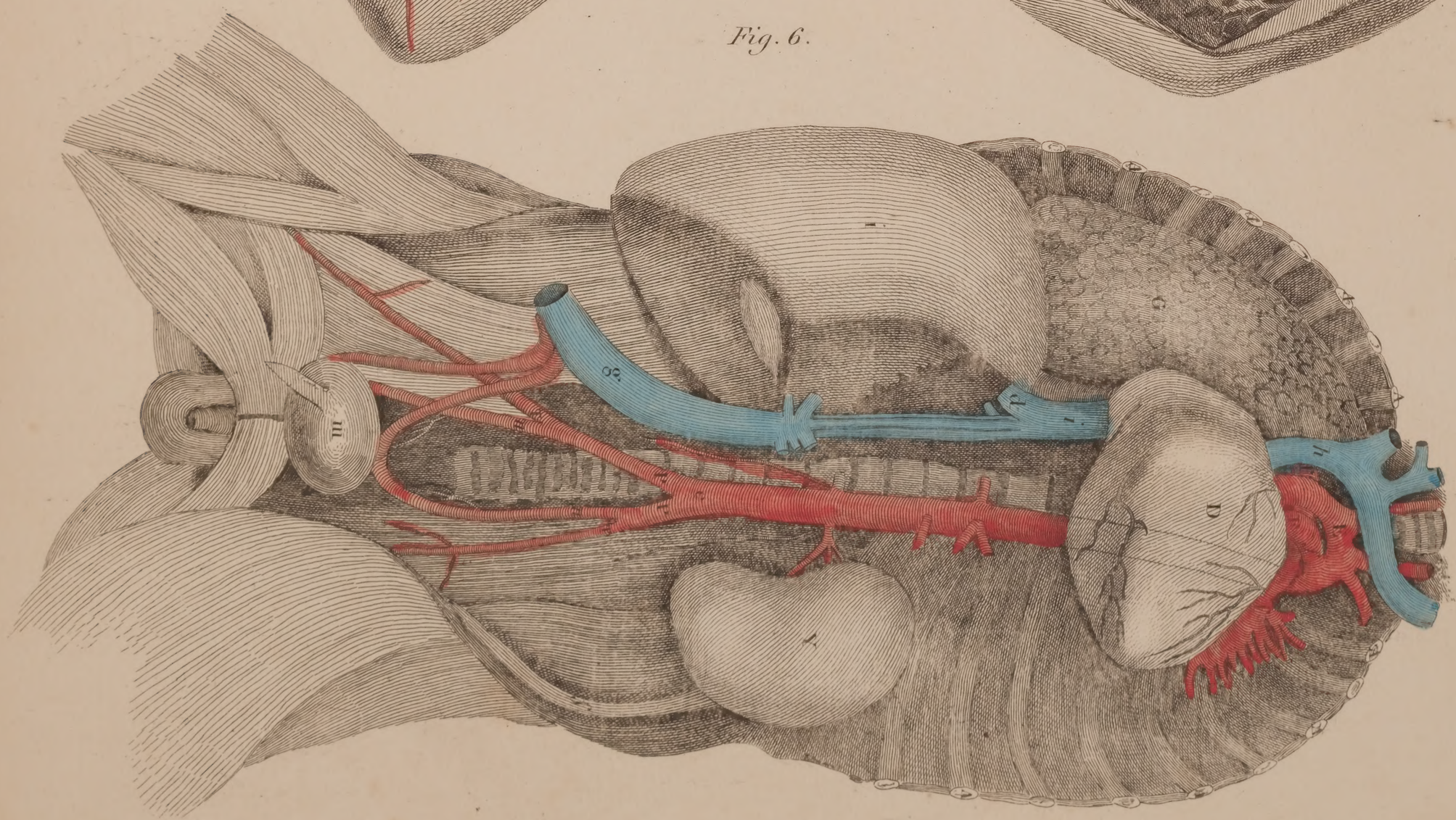

Engraved by W. H. Lizars

Fig. 2.

Fig. 3

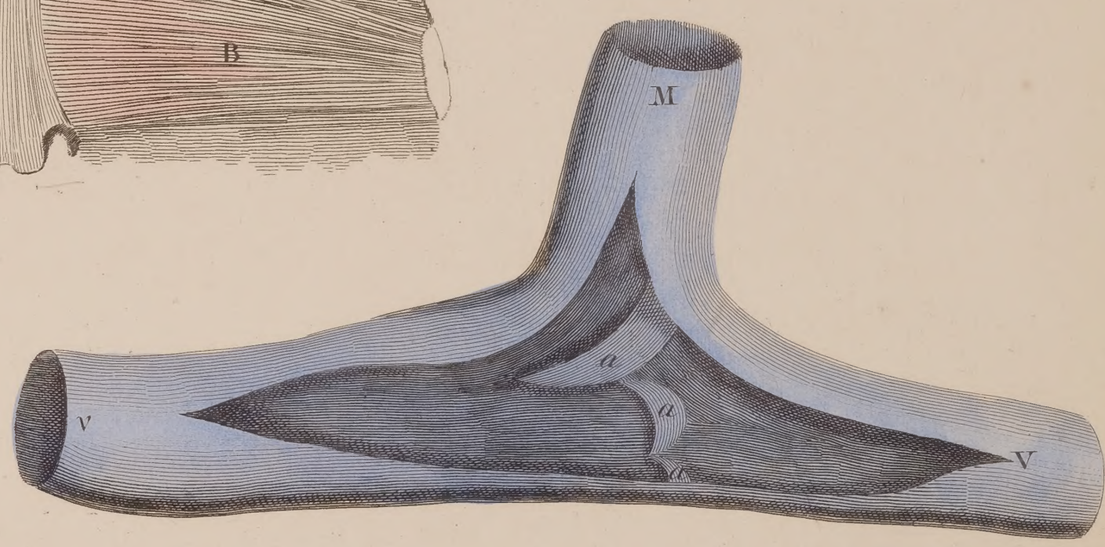

Fig. 4.

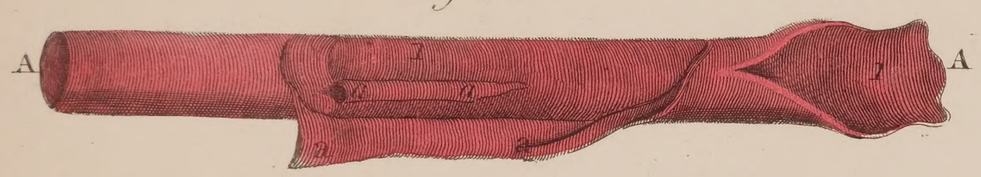

Fig. 1.

Engraved by W.H.Lizars

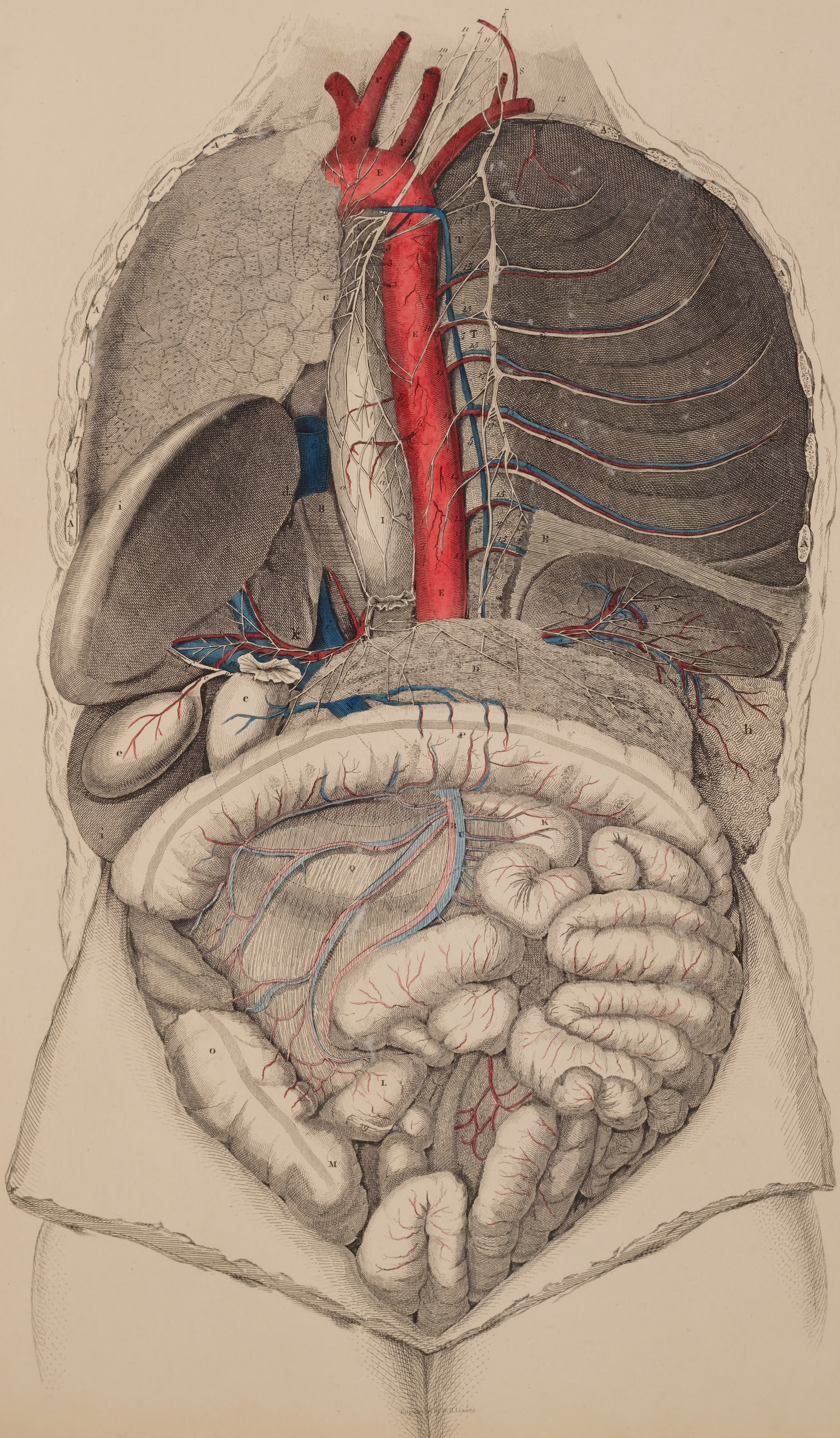
A
A
A
A
A
A
C
E
E
E
T
T
B
B
I
i
K
D
c
e
h
P
K
Q
O
L
M

PLATE XIII.

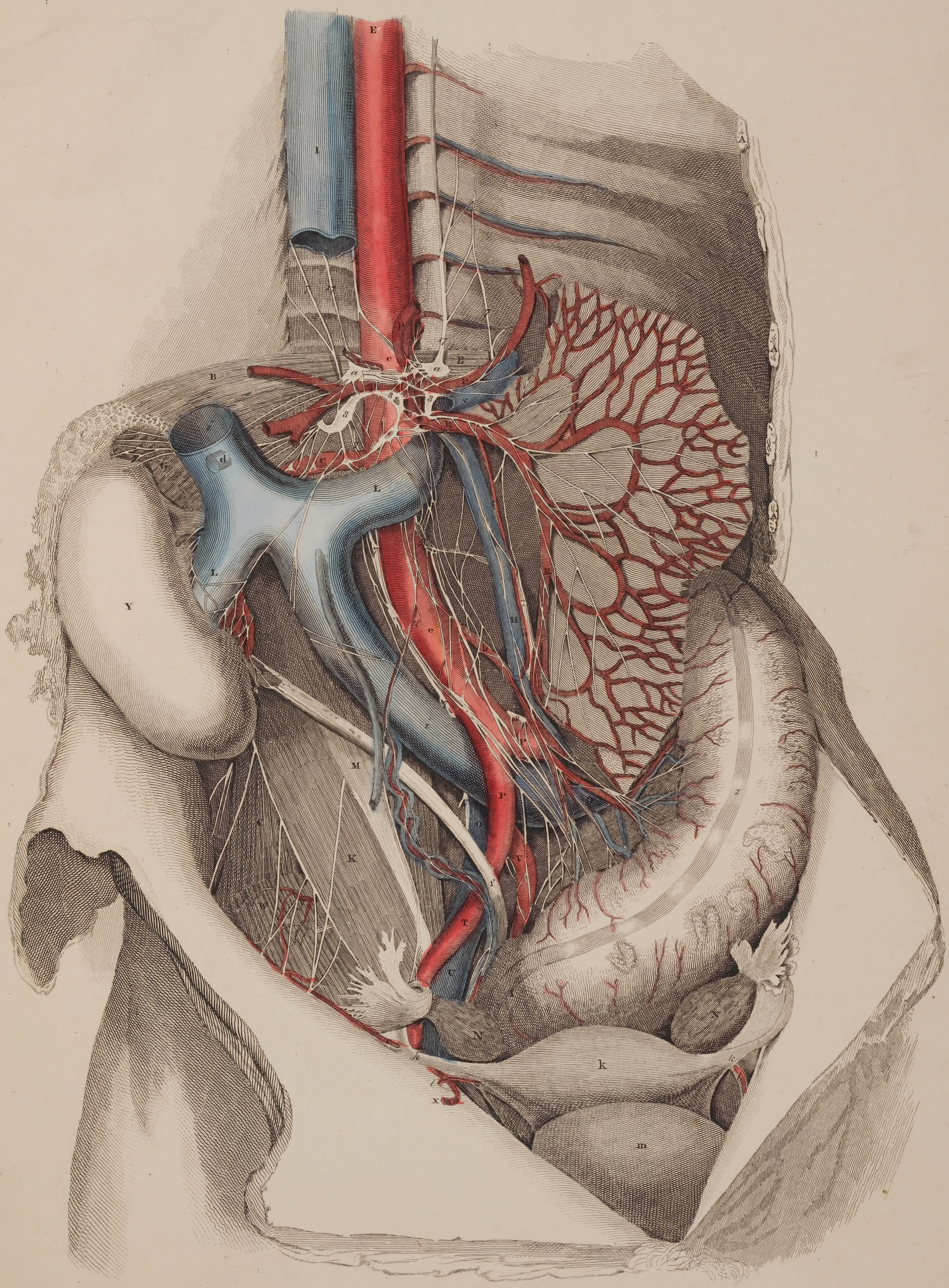

Engraved by W. H. Lizars.

PLATE XIV.

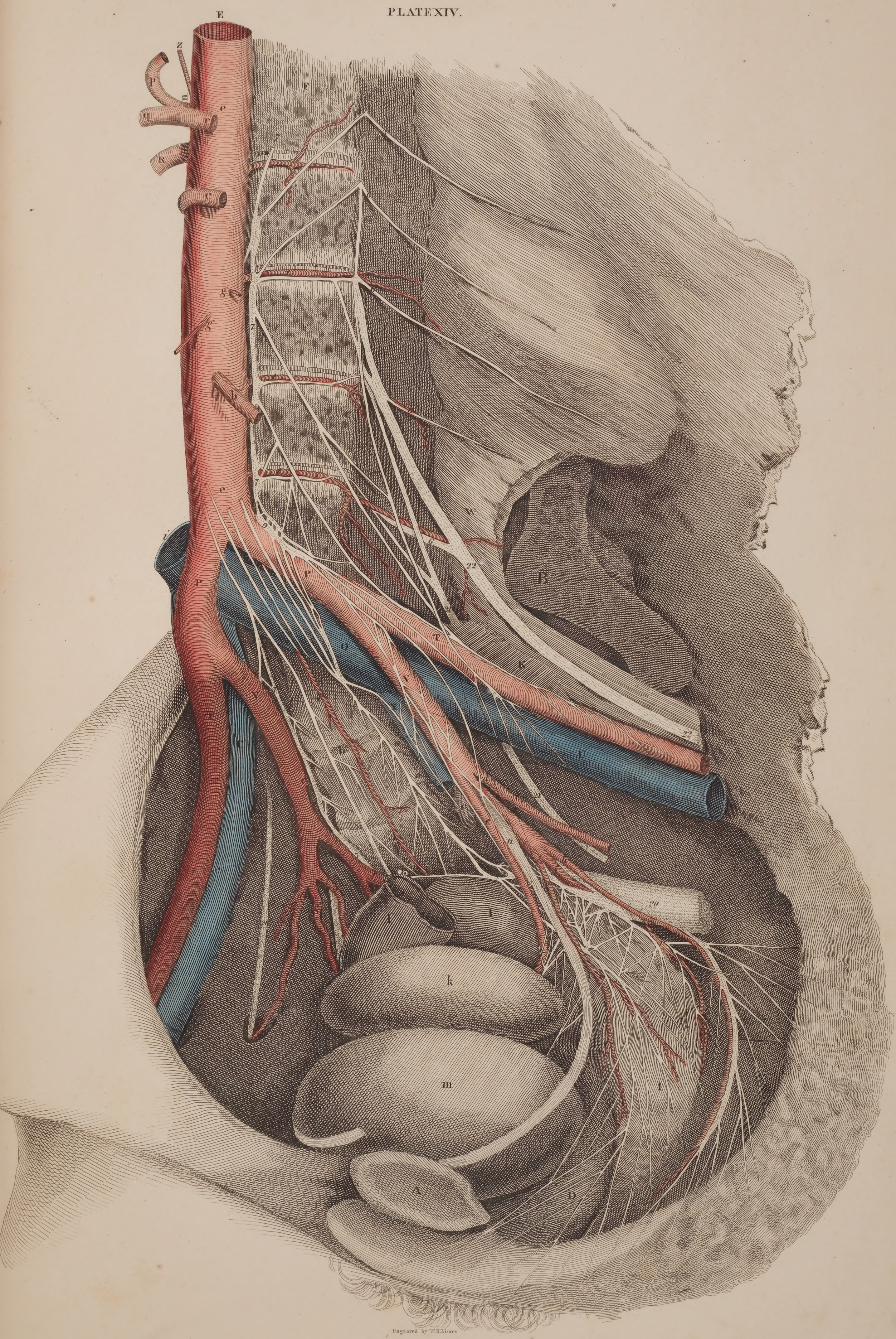

Engraved by W.H.Lizars

PLATE XV.

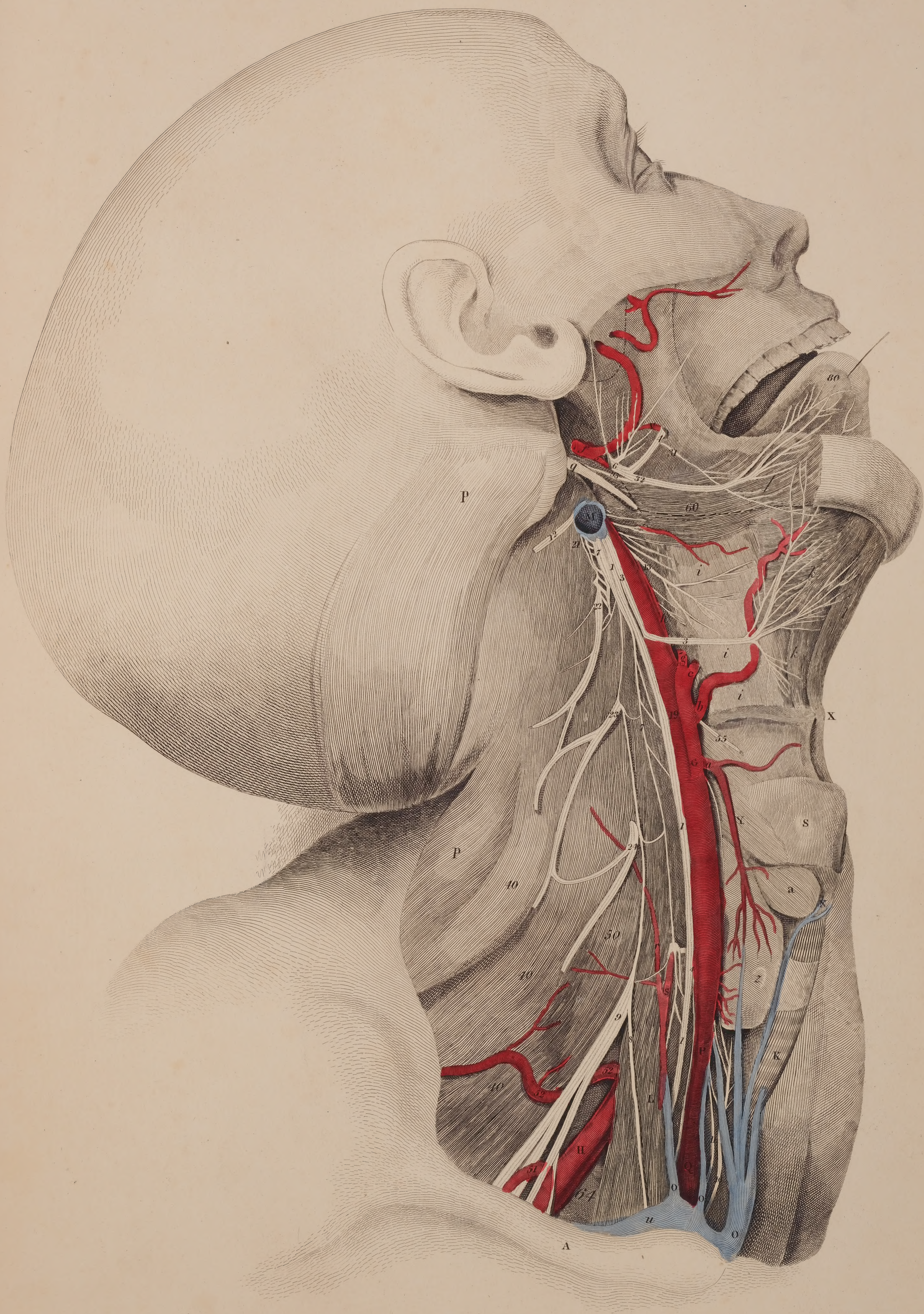

Engraved by W.H. Lizars

PLATE XVI.

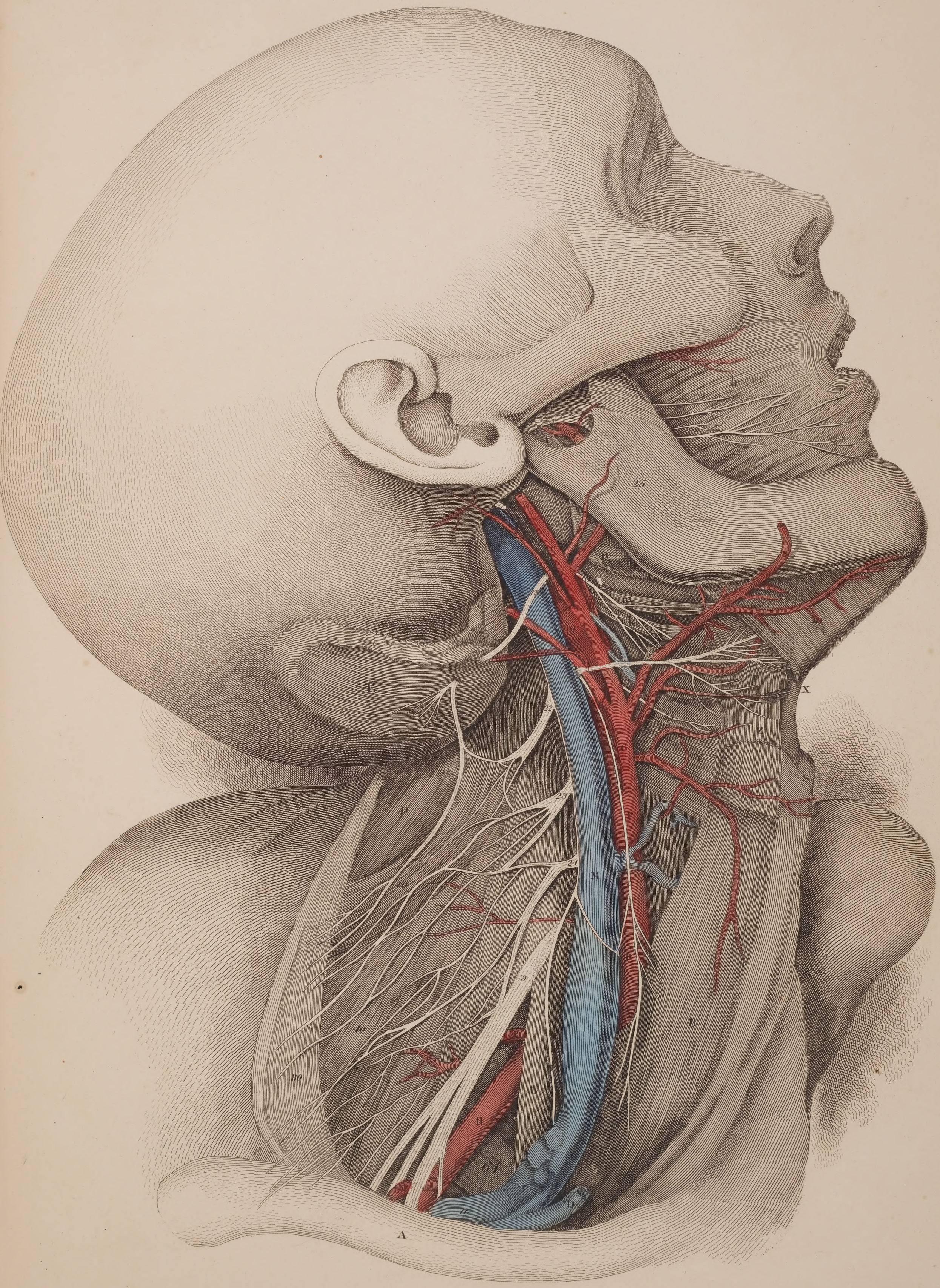

Engraved by W H Lizars

PLATE XVII.

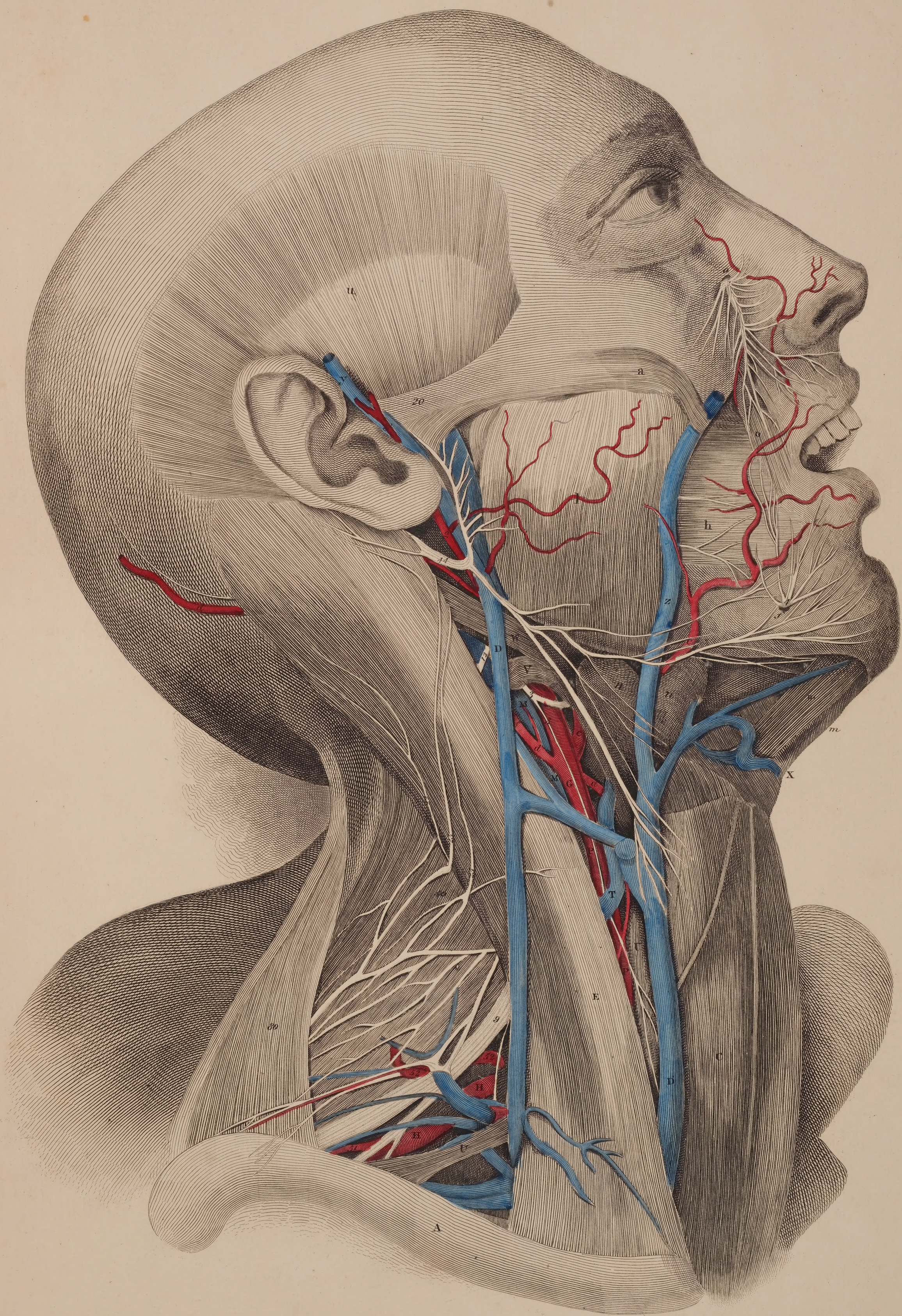

Engraved by W H Lizars

PLATE XVIII.

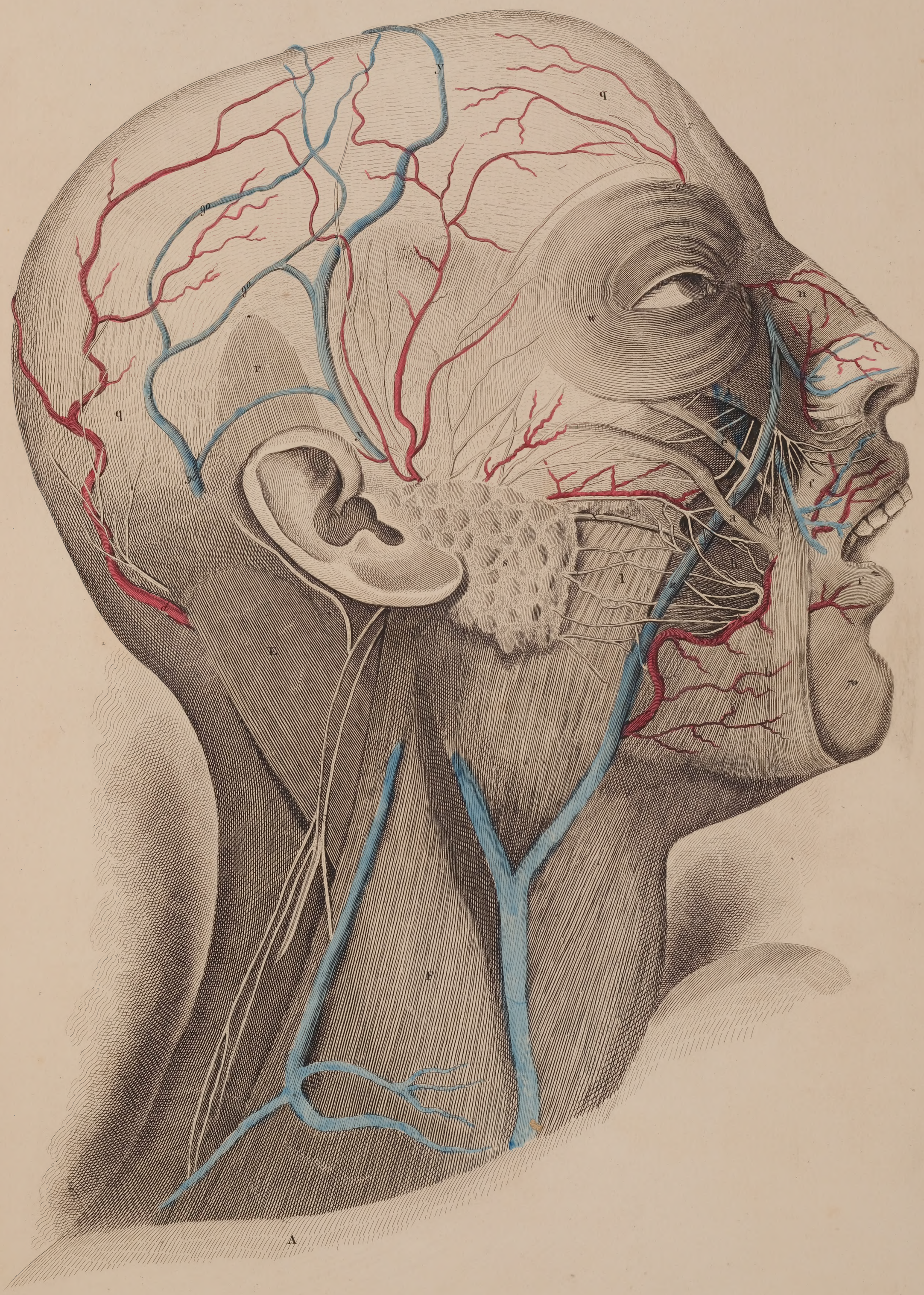

Engd. by W. H. Lizars

PLATE XIX.

PLATE XX.

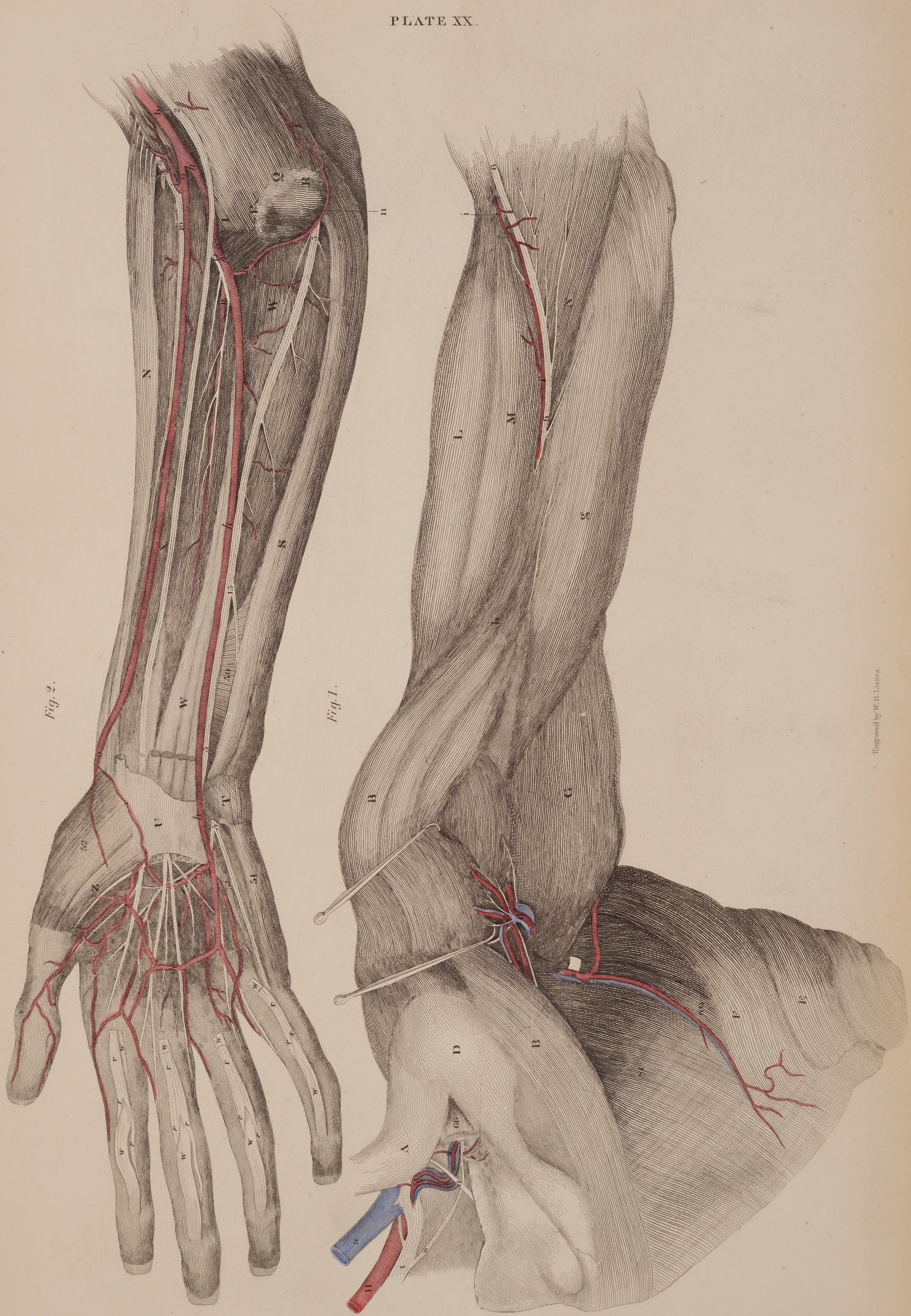

PLATE XXI.

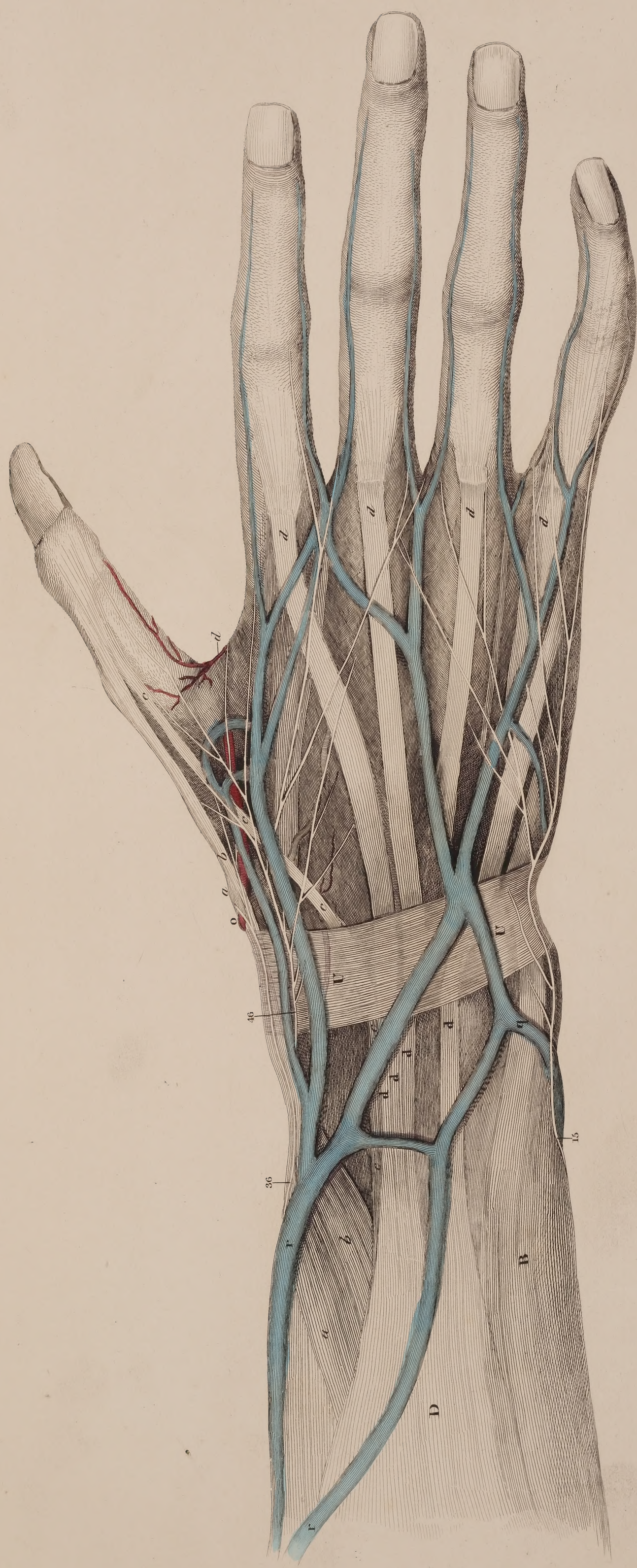
46
36
15
U
U
B
D
d
d
d

PLATE XXII.

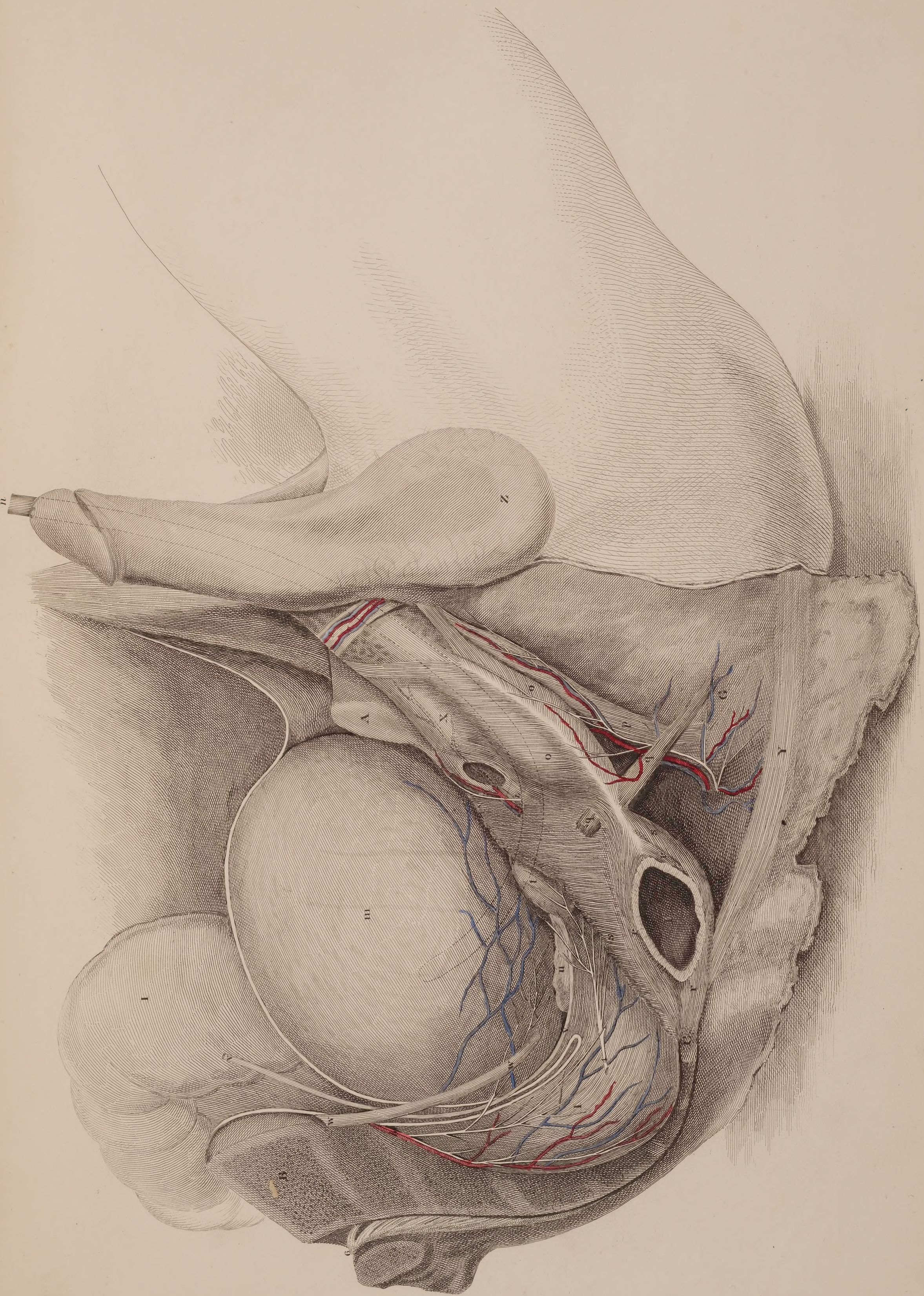

Engraved by W.H.Lizars

PLATE XXIII.

Engd by W.H. Lizars

PLATE XXIV

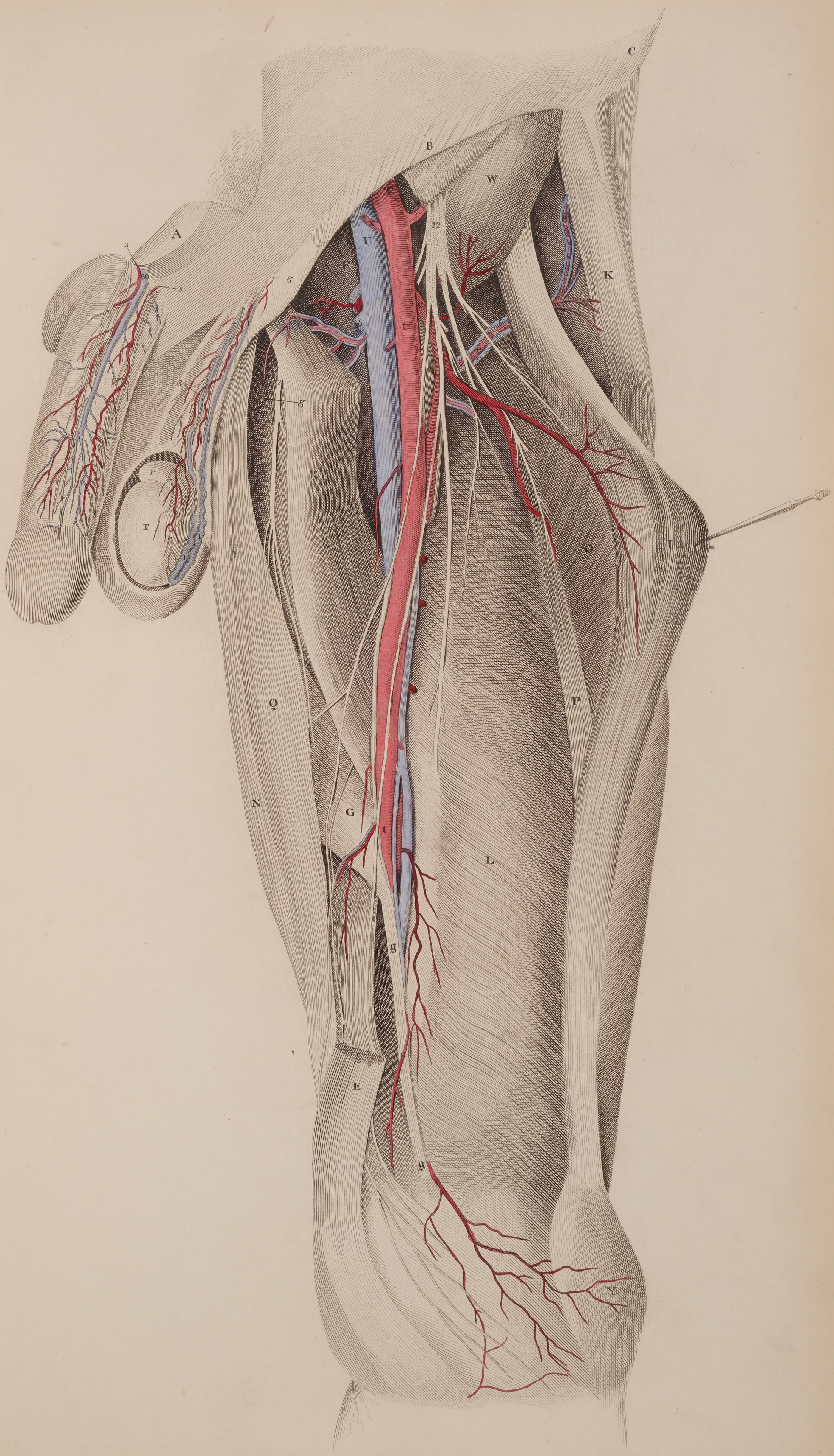

Engraved by W.H. Lizars

PLATE XXV.

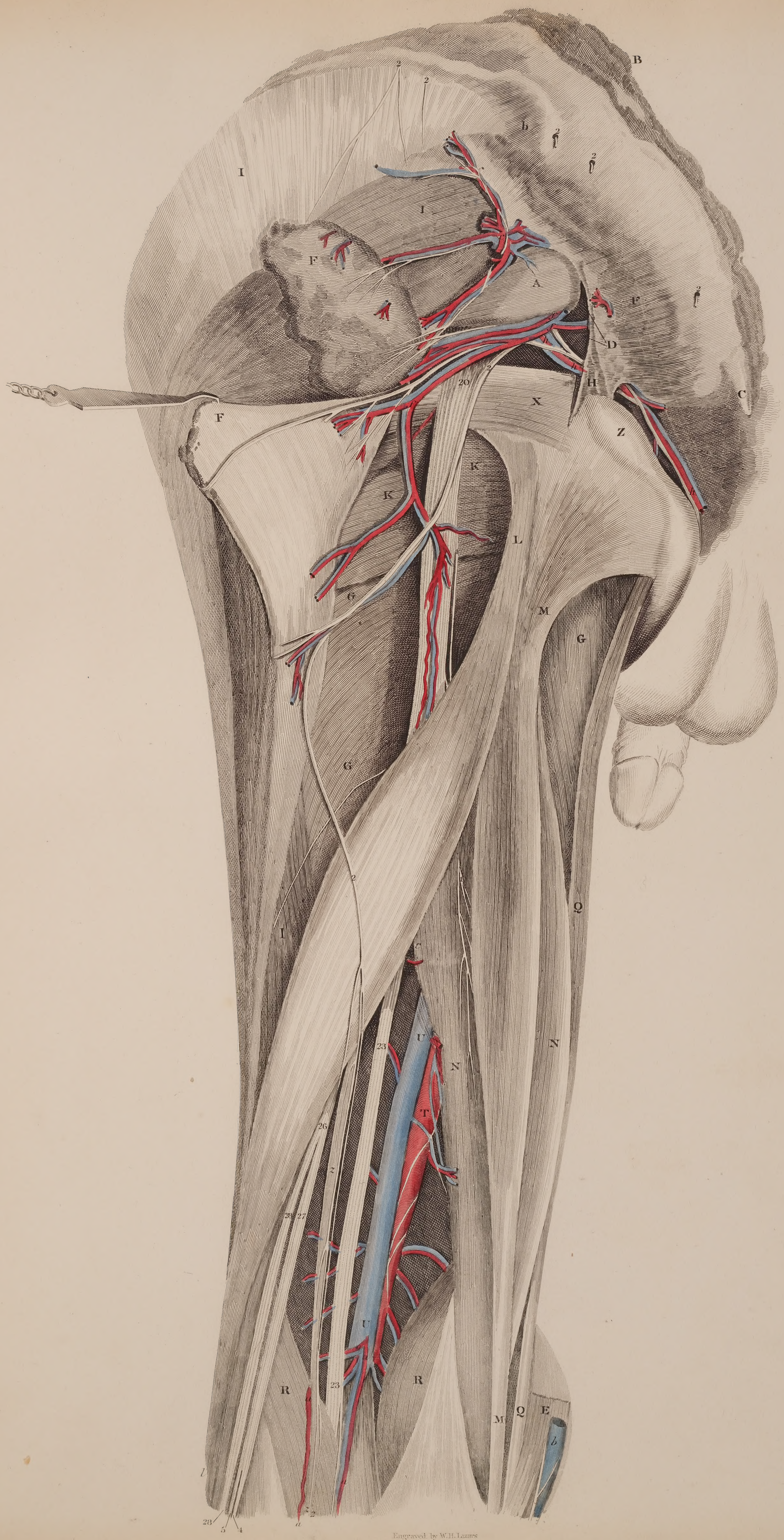

Engraved by W.H. Lizars

PLATE XXVI.

Engraved by W. H. Lizars

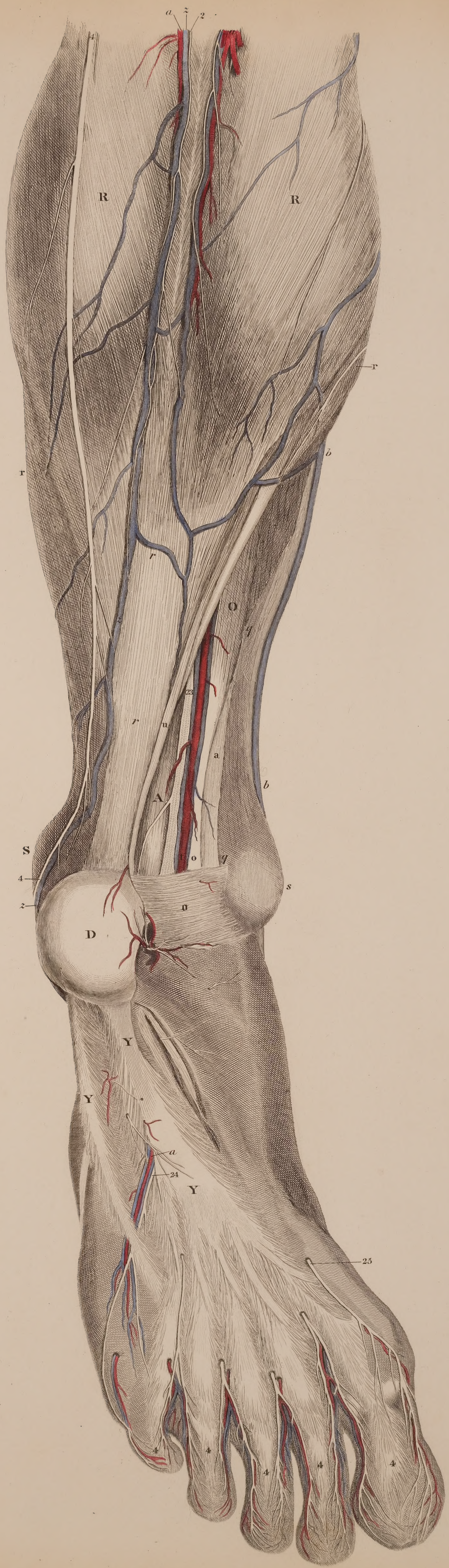

Engraved by W.H. Lizars

PLATE XXVIII.

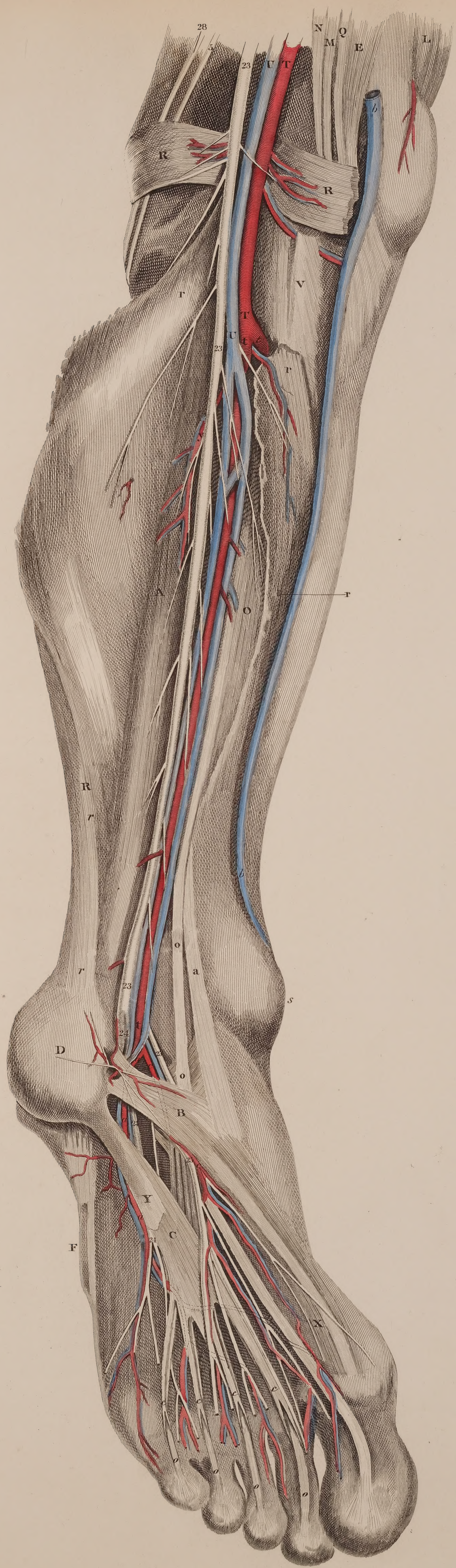

Engraved by W. H. Lizars

PLATE XXIX.

Engd. by W.H. Lizars

PLATE XXX.

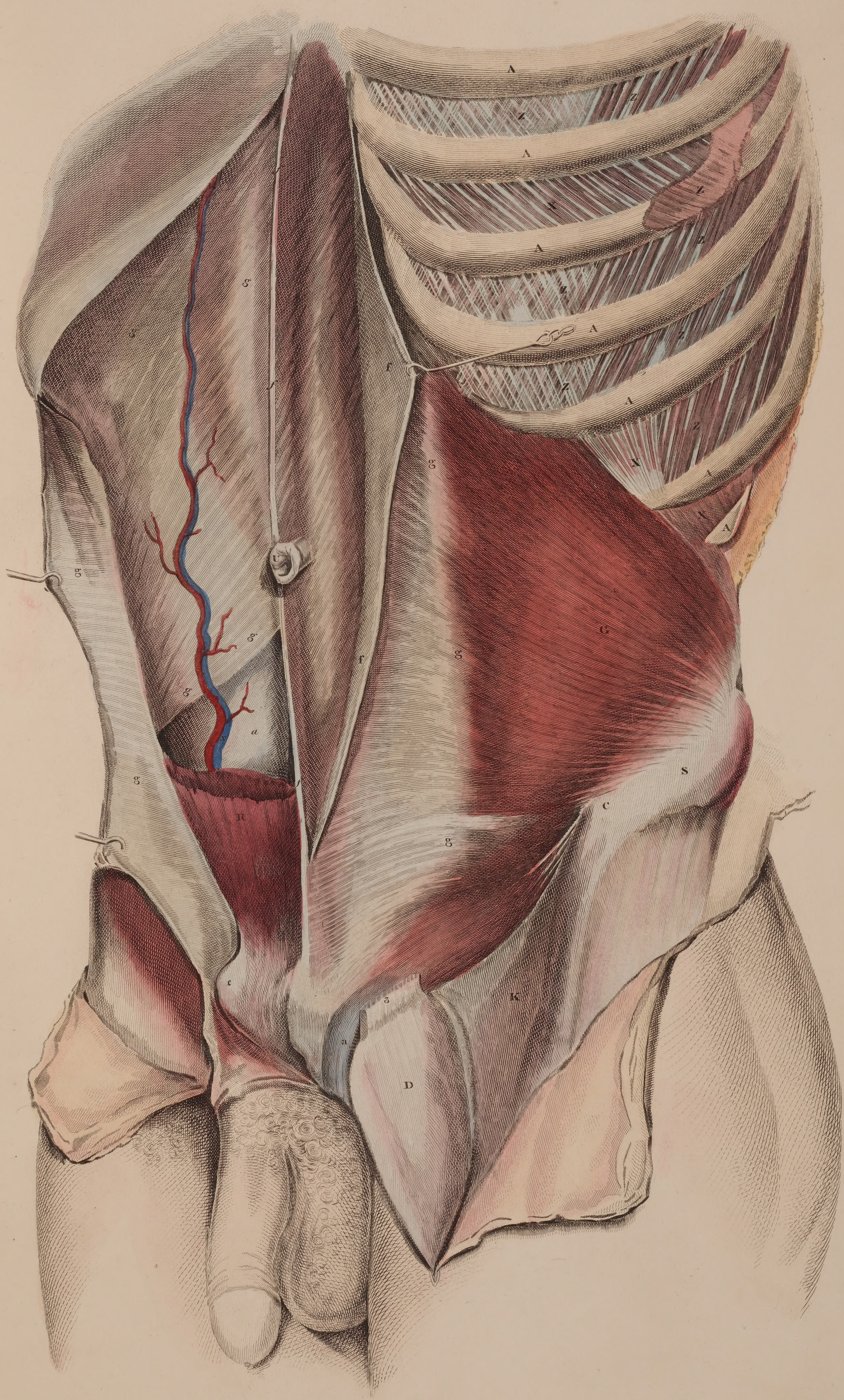

Engd by W. H. Lizars

PLATE XXXI.

Engd by W. H. Lizars

PLATE XXXII.

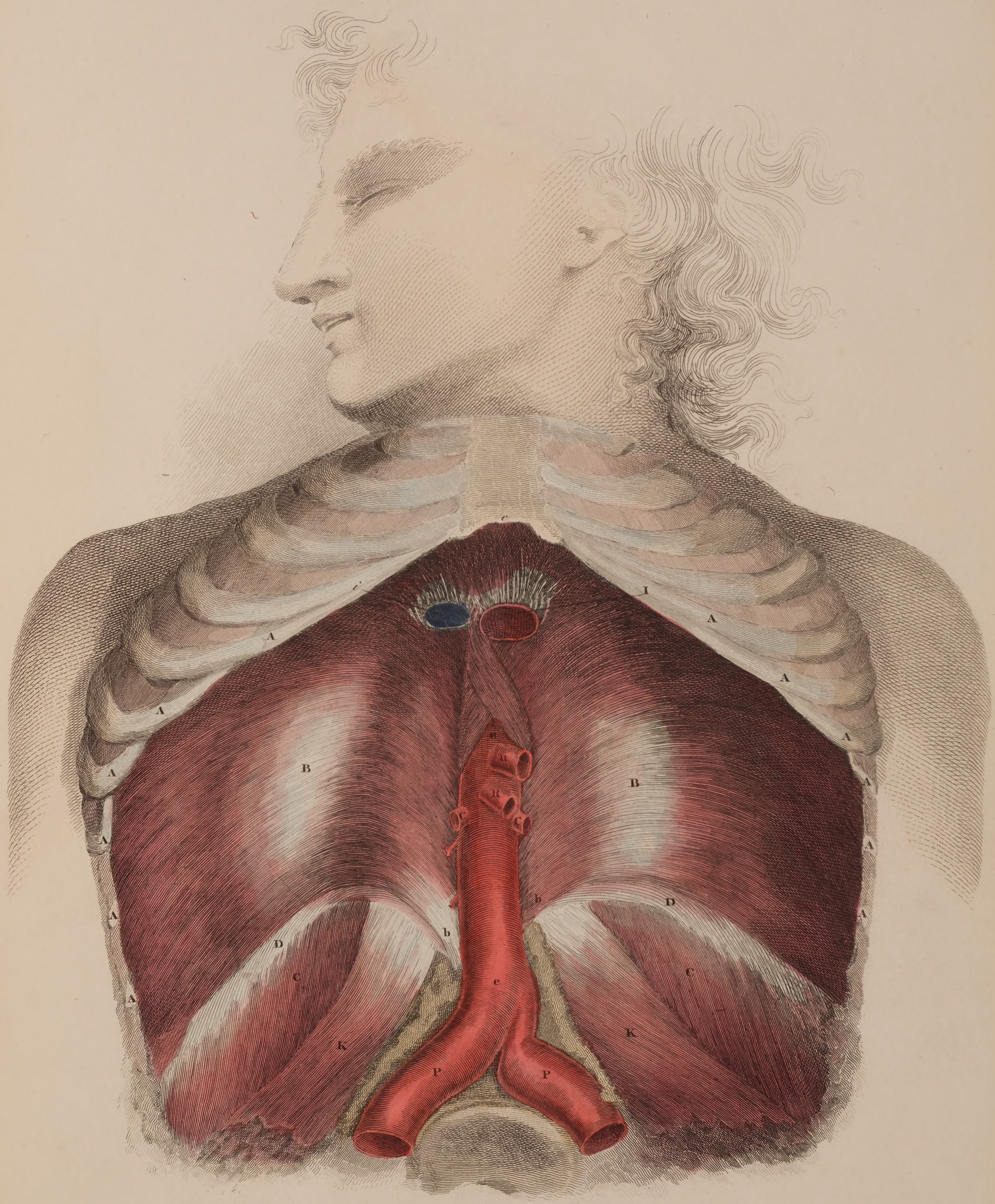

Engd by W.H. Lizars

PLATE XXXII.*

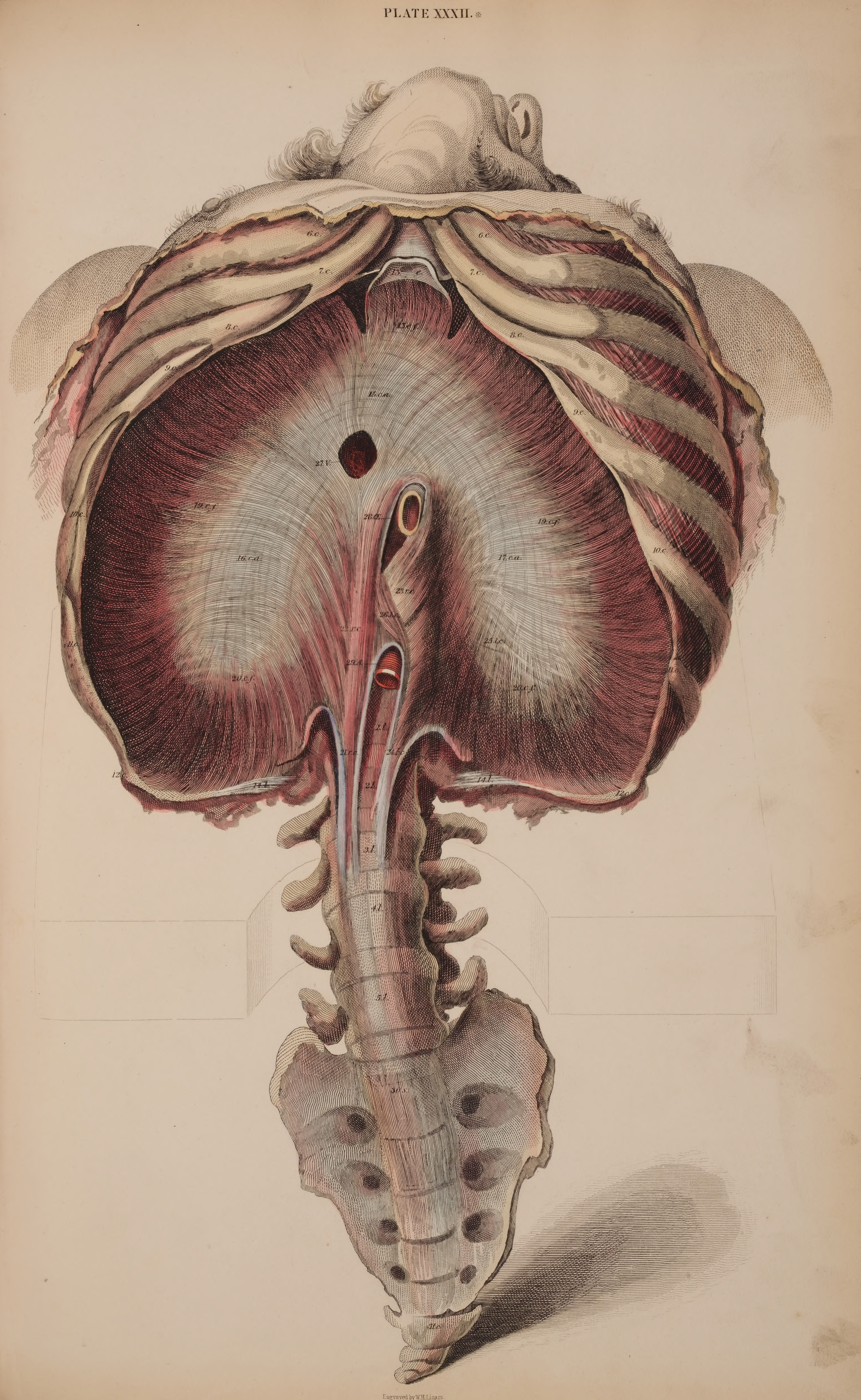

Engraved by W.H. Lizars.

PLATE XXXIII.

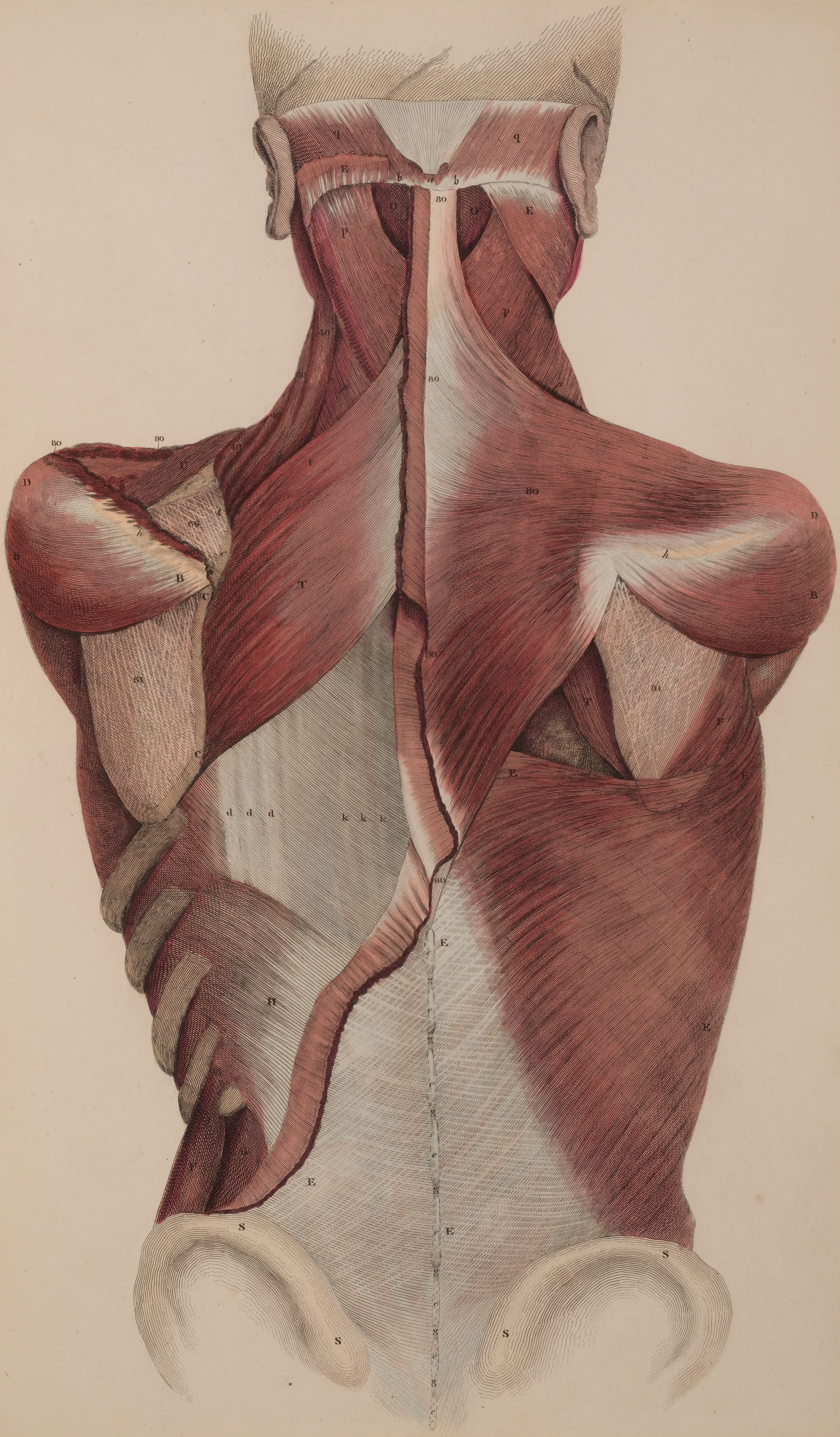

Engd. by W.H. Lizars

PLATE XXXIV.

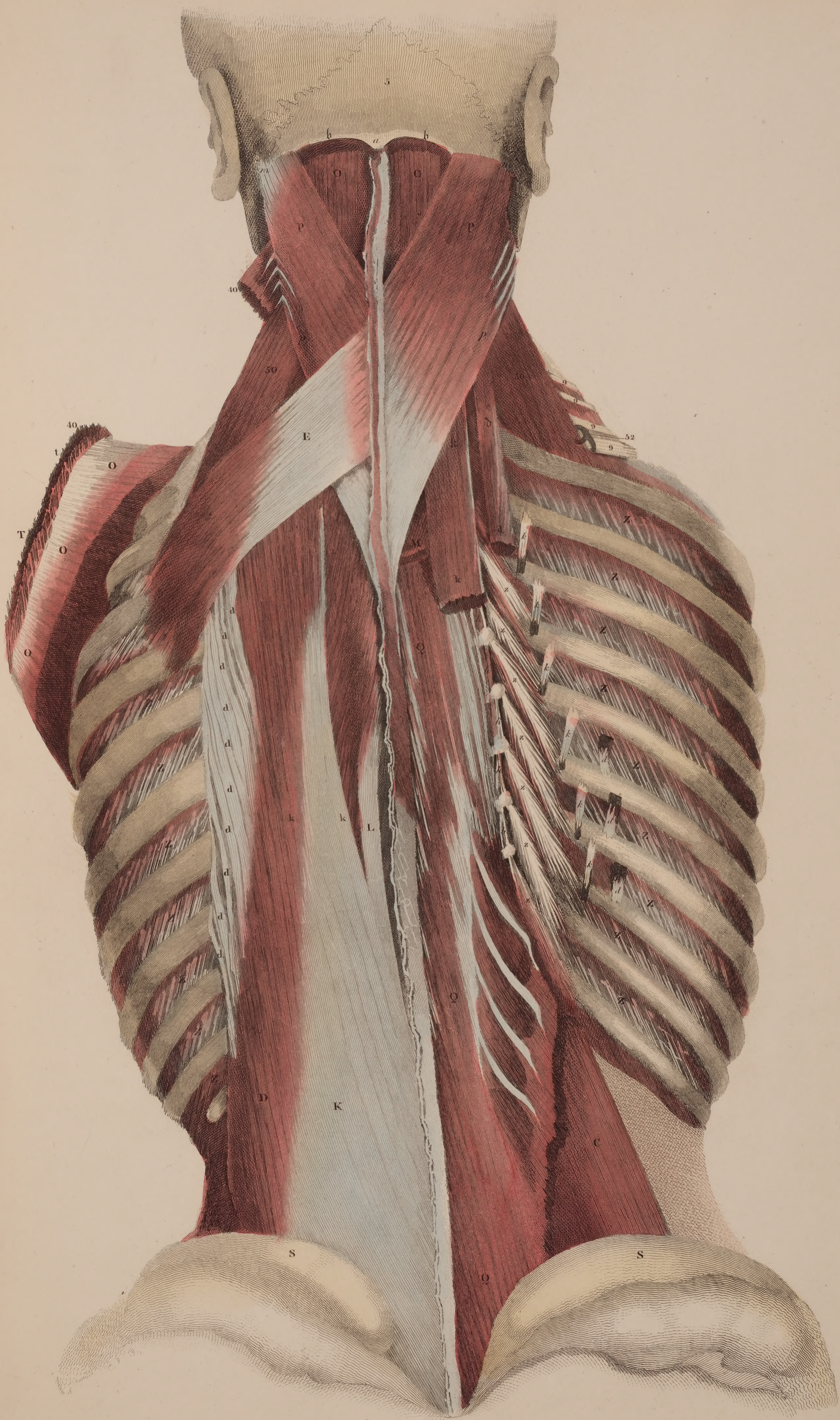
5
b
a
b
m
O
O
P
P
40
P
P
50
50
9
9
9
52
9
40
t
O
E
T
O
O
Z
Z
Z

PLATE XXXV.

Engd by W. H. Lizars

PLATE XXXVI.

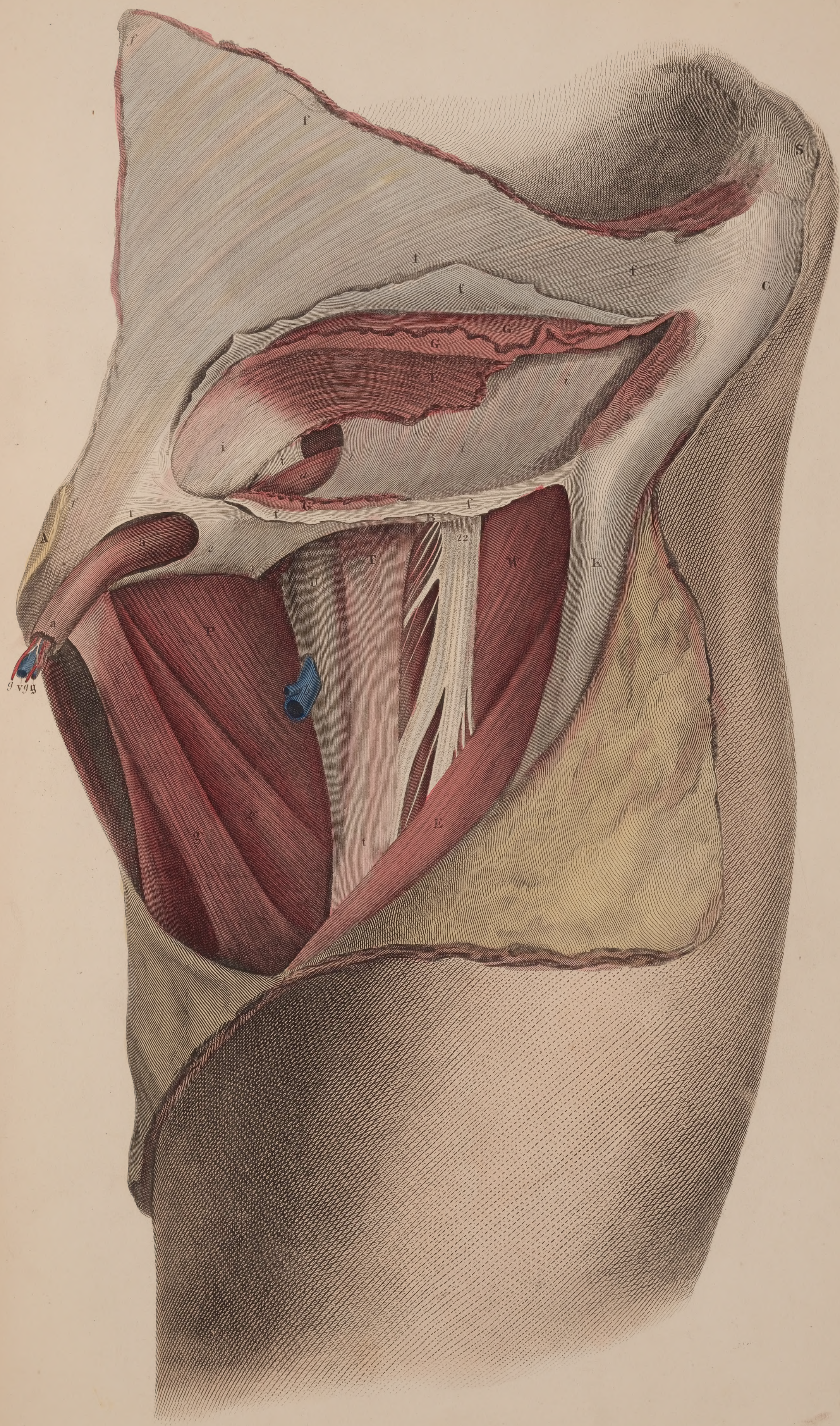

Engraved from a Dissection made by the hands of Sir Astley Cooper, kindly presented by him to the Author, and now preserved in his Museum at Edinburgh.

Engraved by W.H. Lizars

PLATE XXXVII.

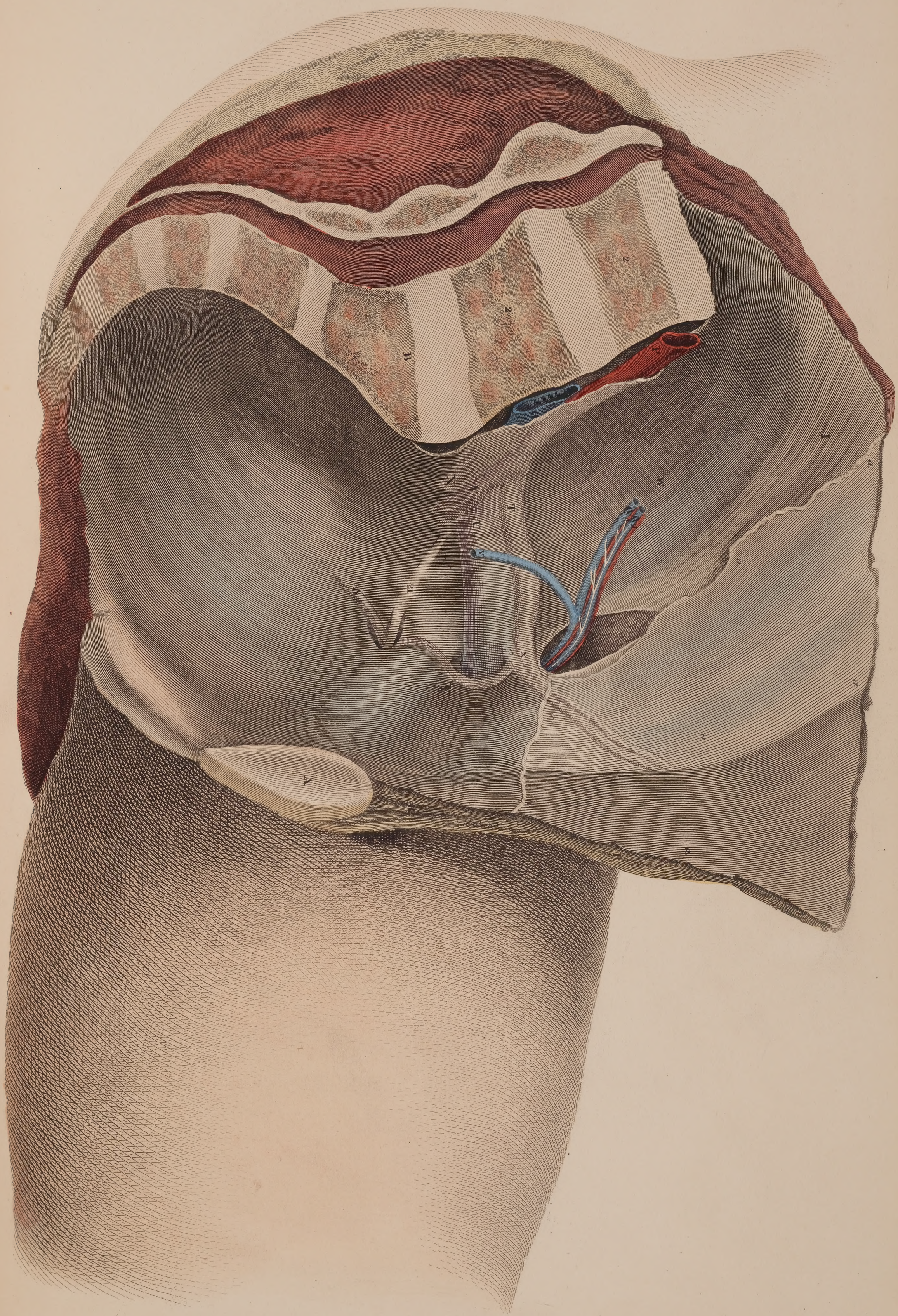

Engraved by W.H. Lizars

PLATE XXXVIII.

PLATE XXXIX.

Engraved by W. H. Lizars.

PLATE XL.

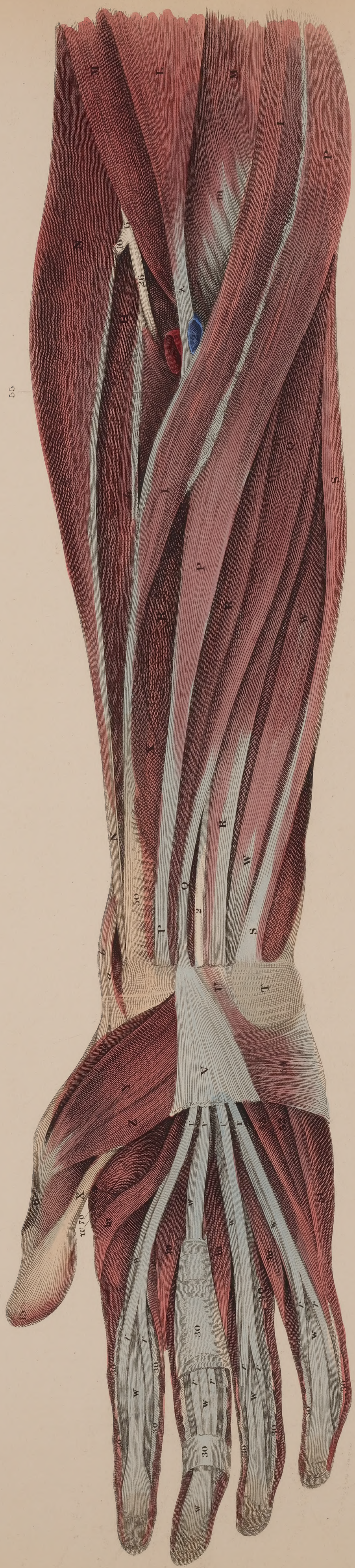

Engraved by W.H. Lizars

PLATE XLI.

Fig. 1.

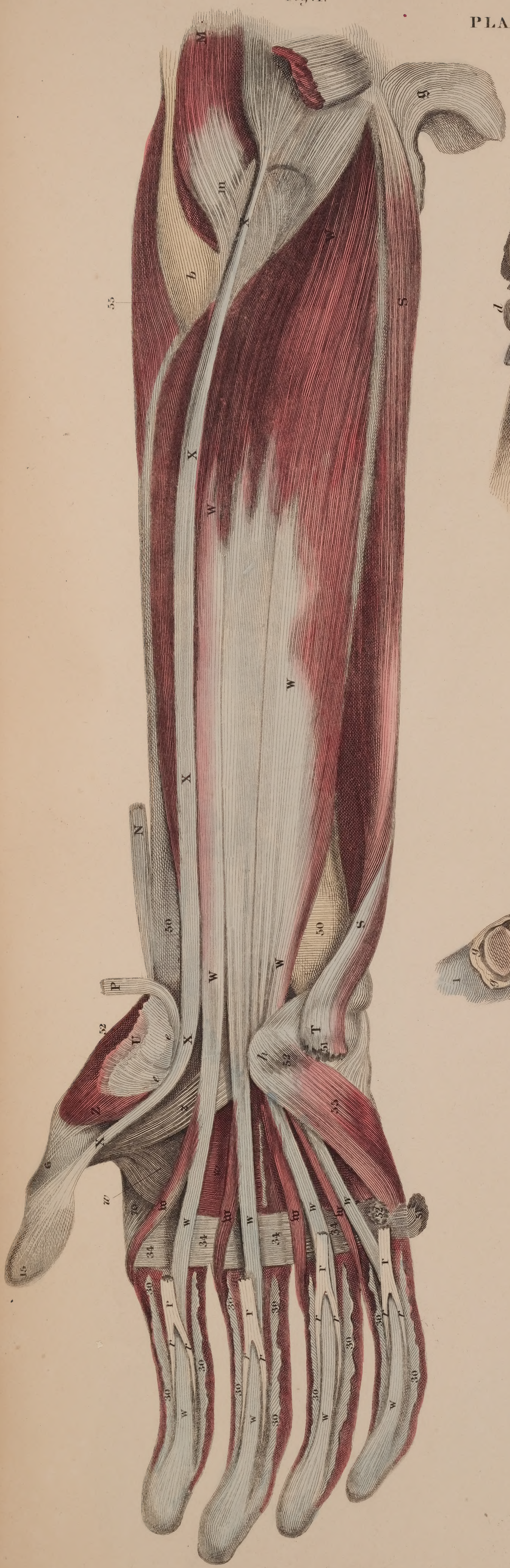

Fig. 2.

Fig. 3.

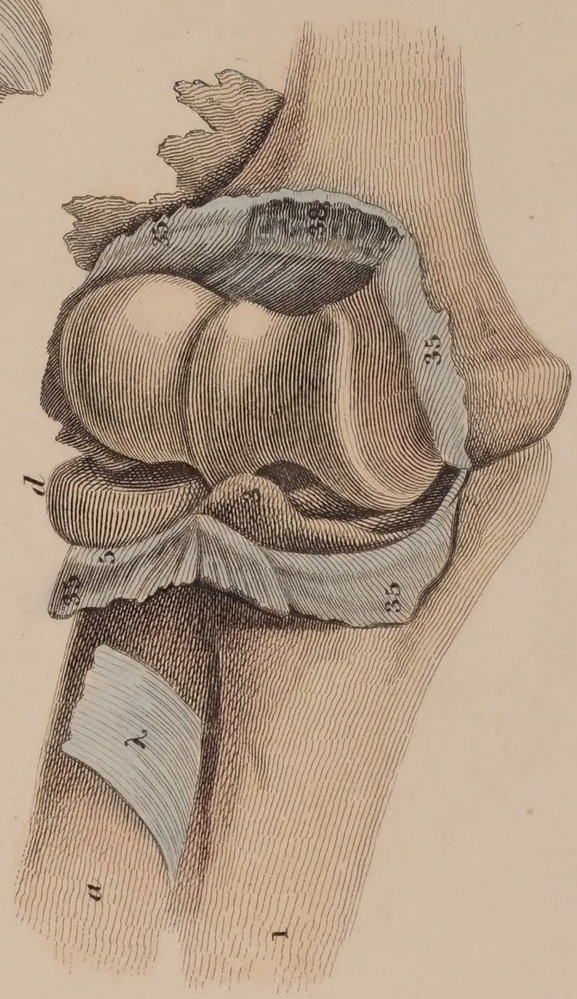

Fig. 4.

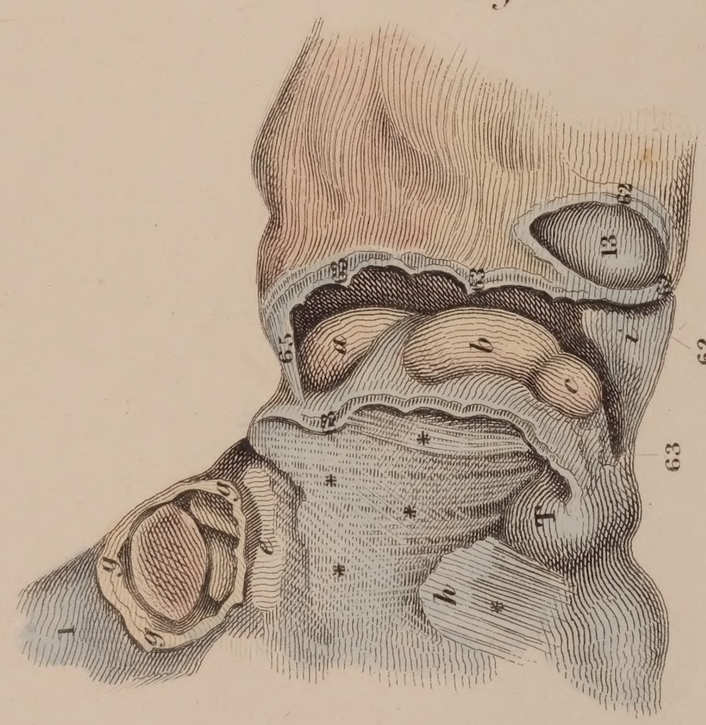

Engraved by W.H. Lizars.

PLATE XLIII.

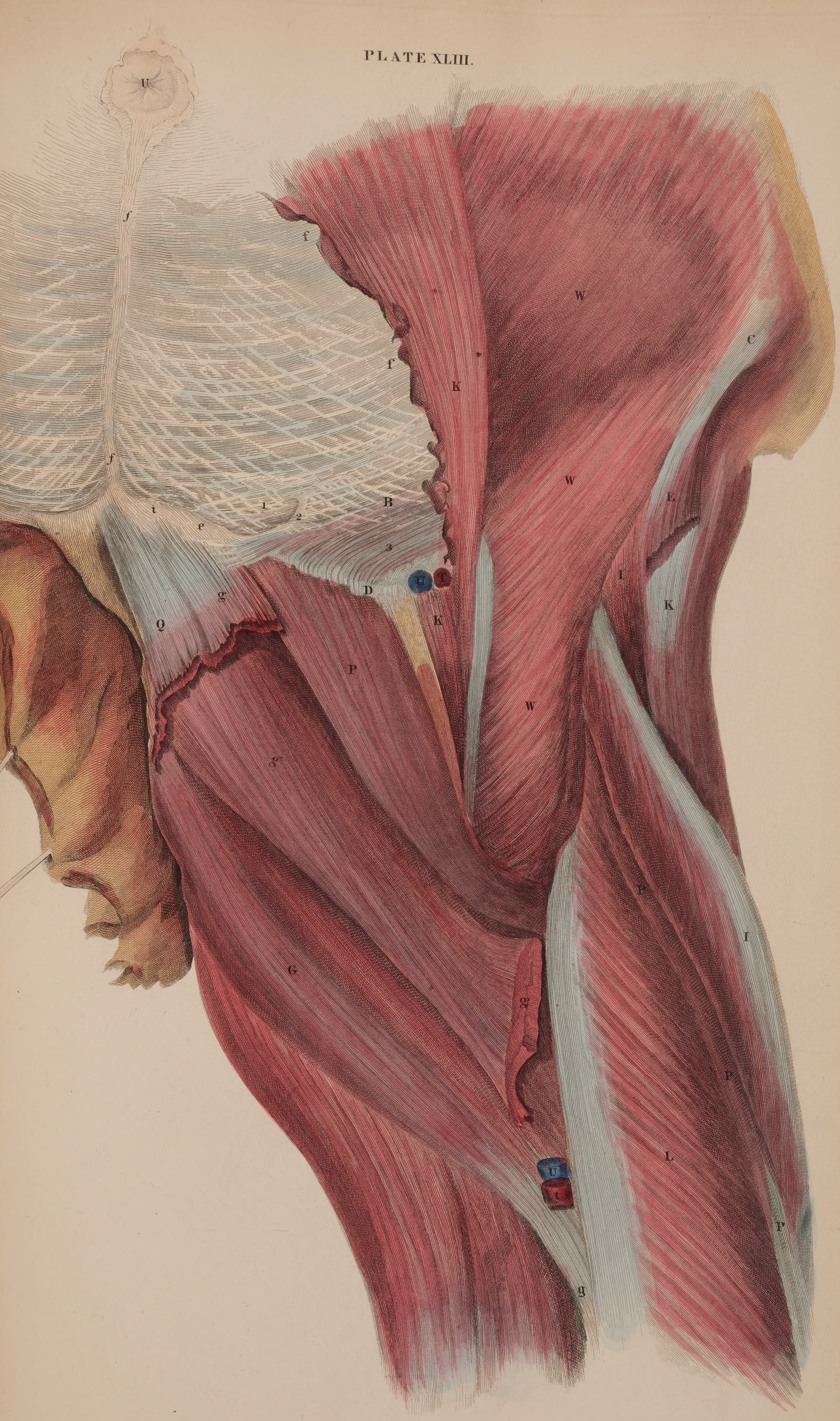

Engraved by W.H. Lizars.

PLATE XLIV.

Engraved by W.H. Lizars

PLATE XLV.

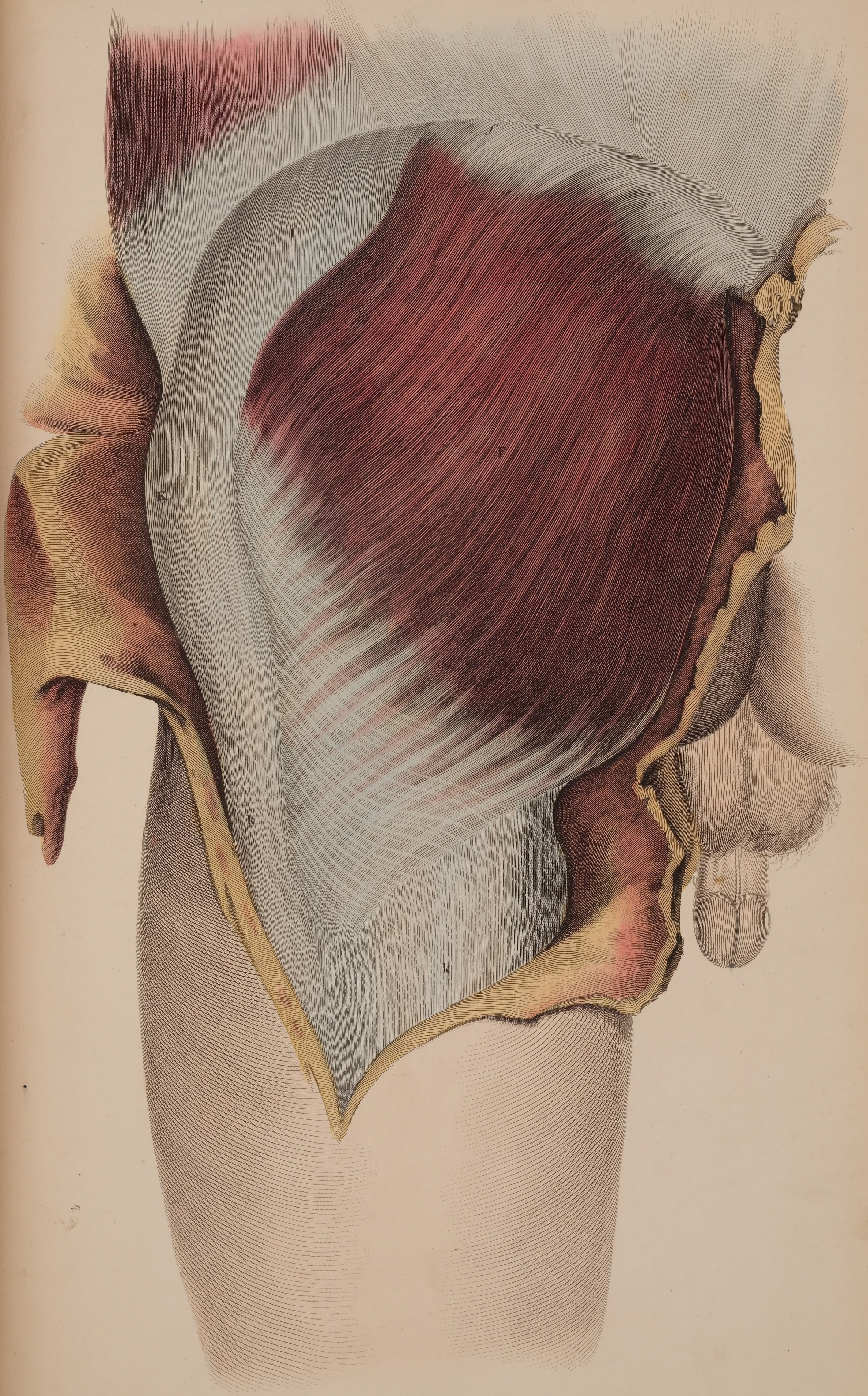

Engraved by W.H. Lizars.

PLATE XLVI.

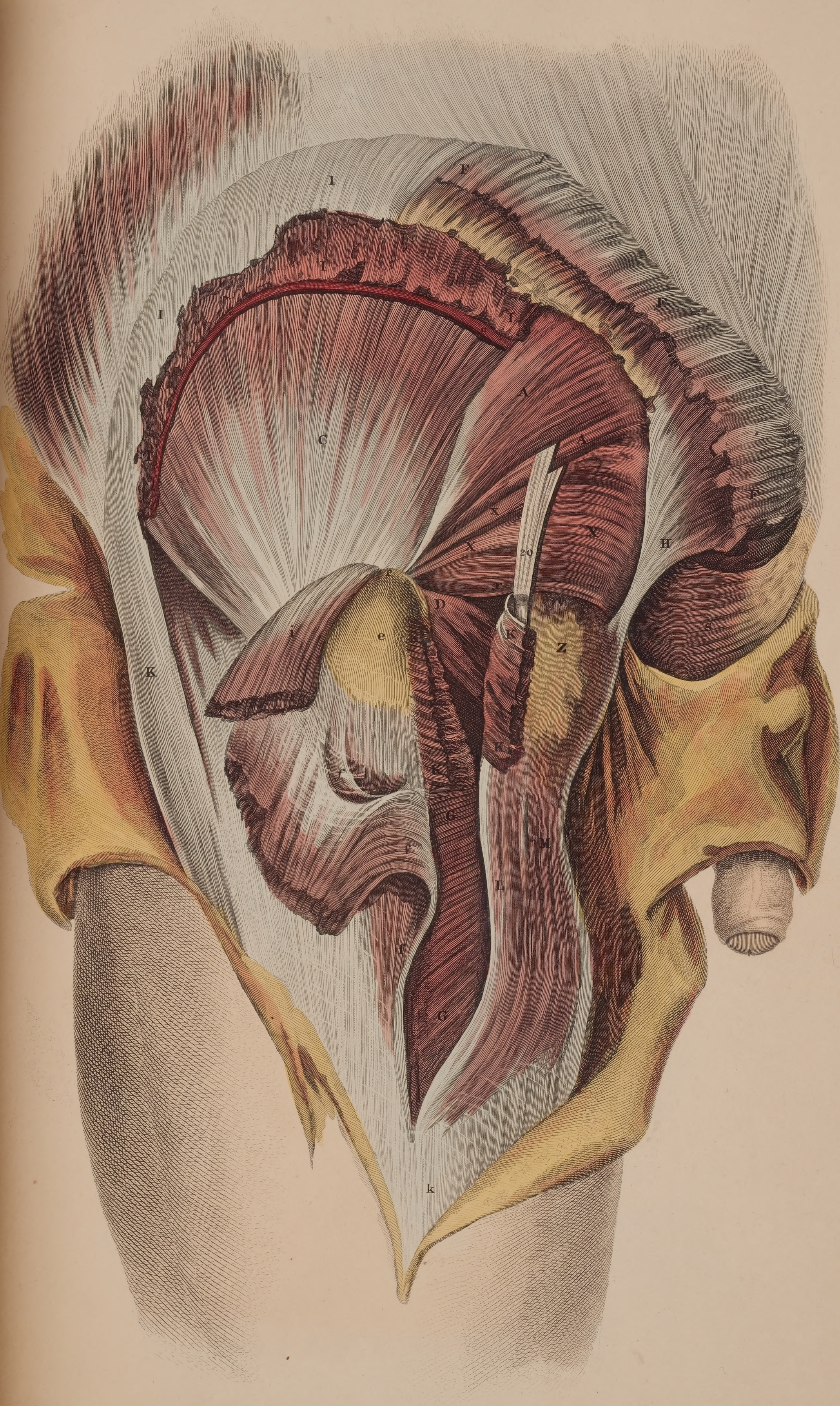

Engraved by W.H.Lizars.

PLATE XLVII.

Fig. 1.

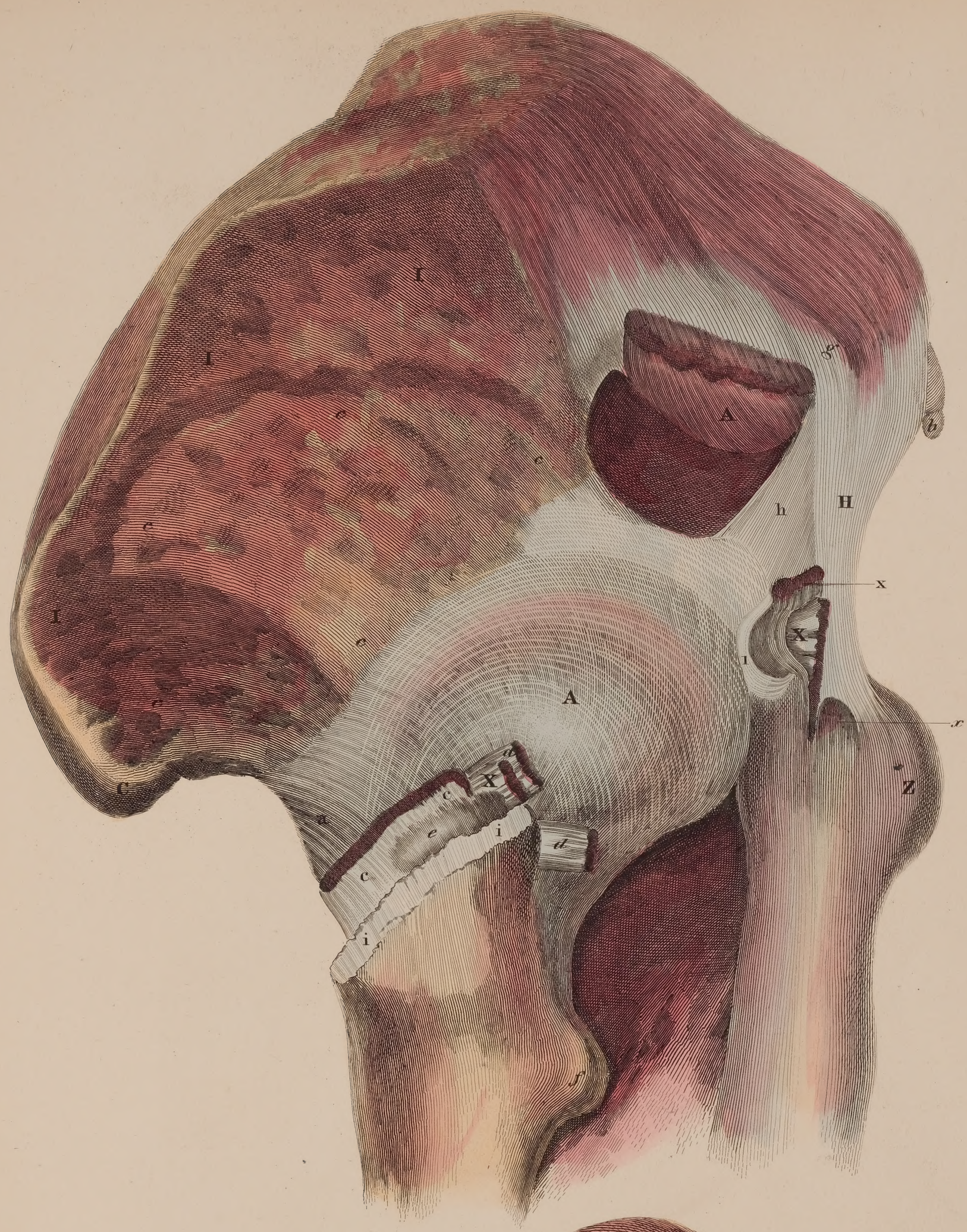

Fig. 2.

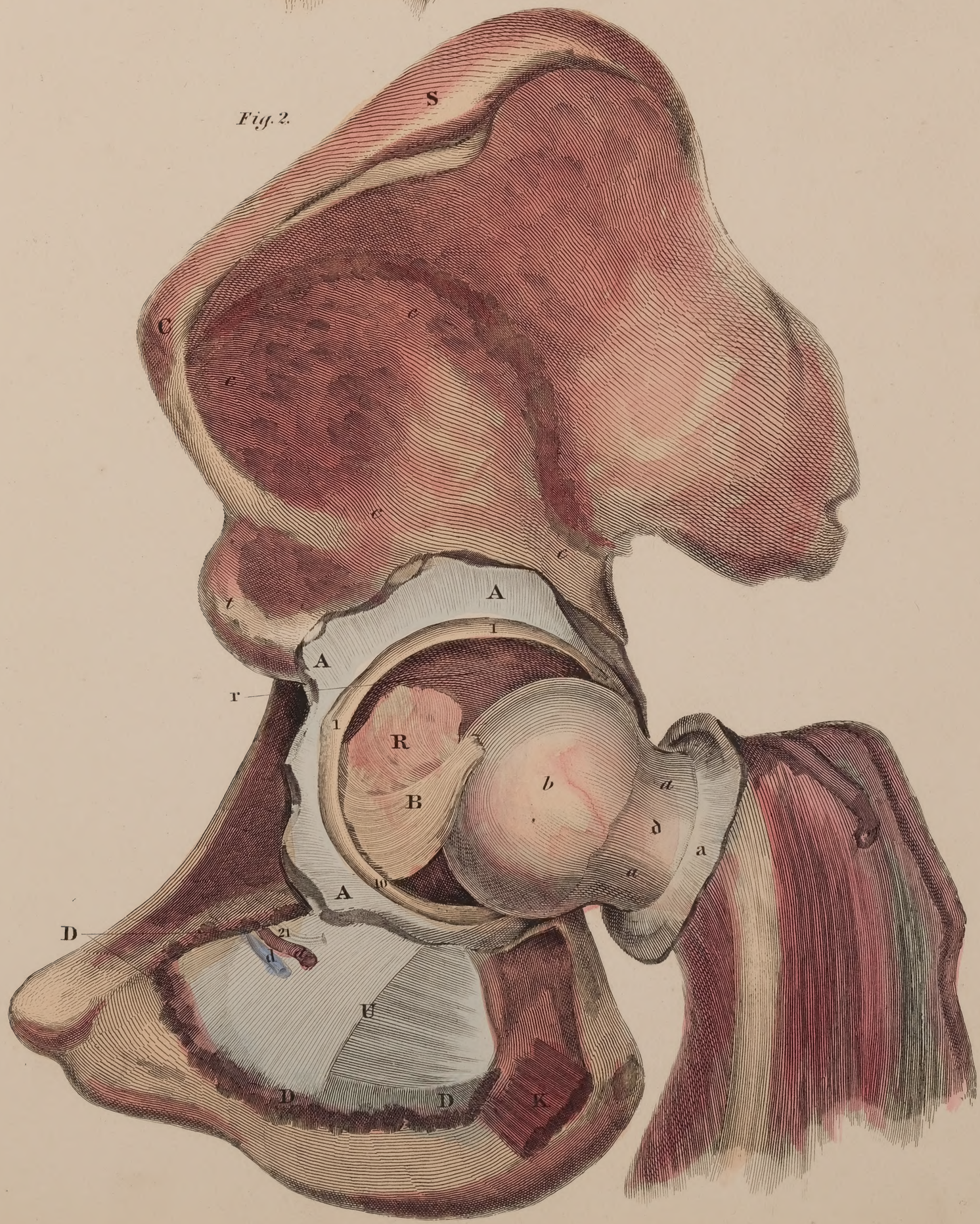

Engraved by W. H. Lizars.

PLATE XLVIII.

Fig. 1.

Fig. 2.

Fig. 3.

Engraved by W.H. Lizars.

Fig. 1.

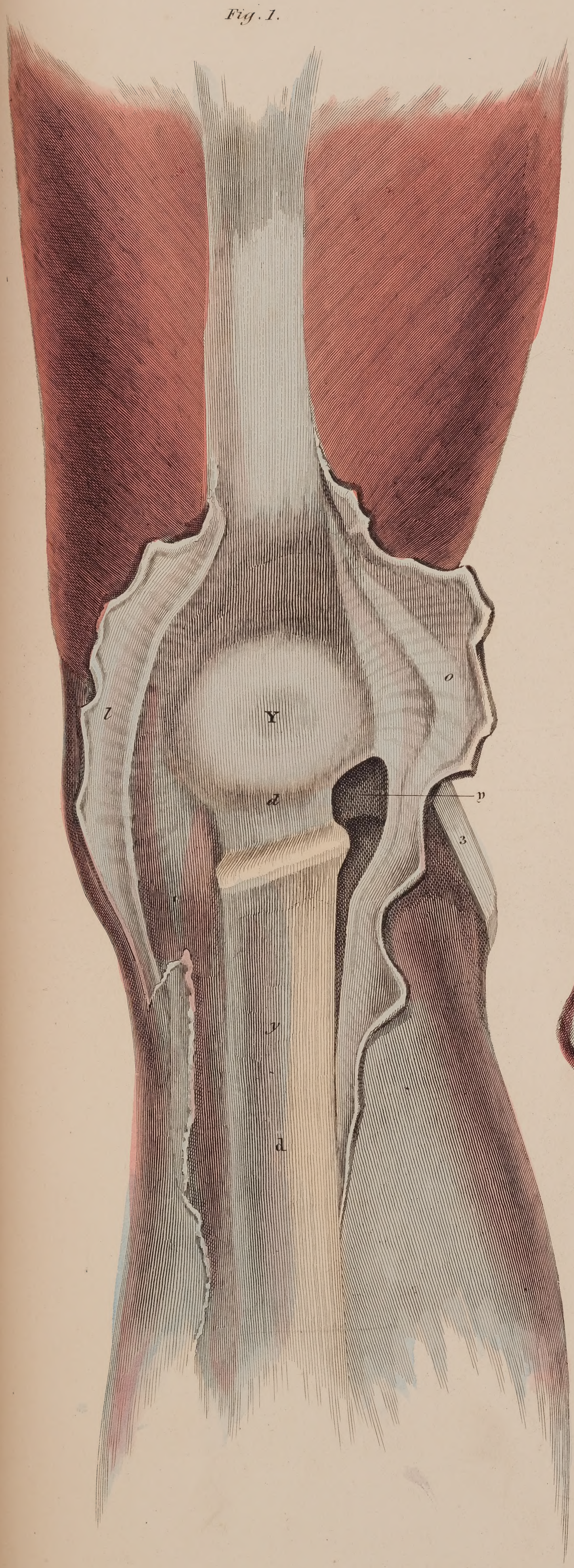

Fig. 2.

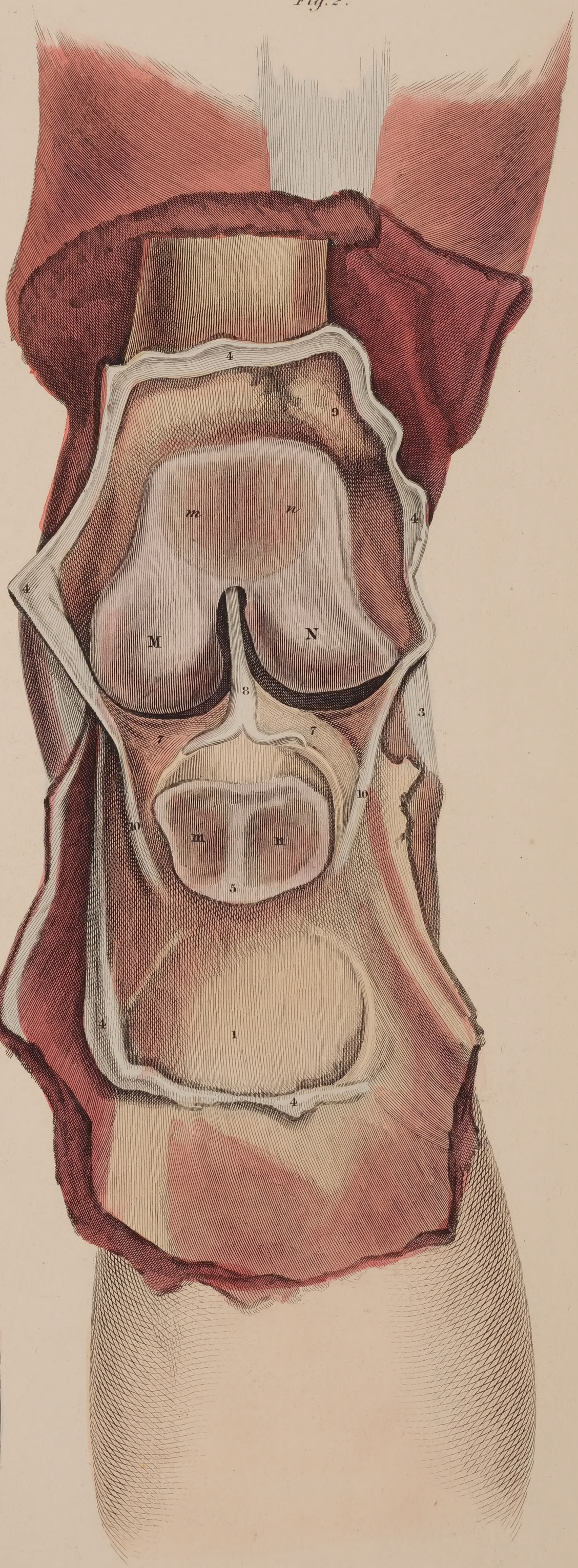

Engraved by W.H.Lizars.

PLATE L.

Fig. 1.

Fig. 2.

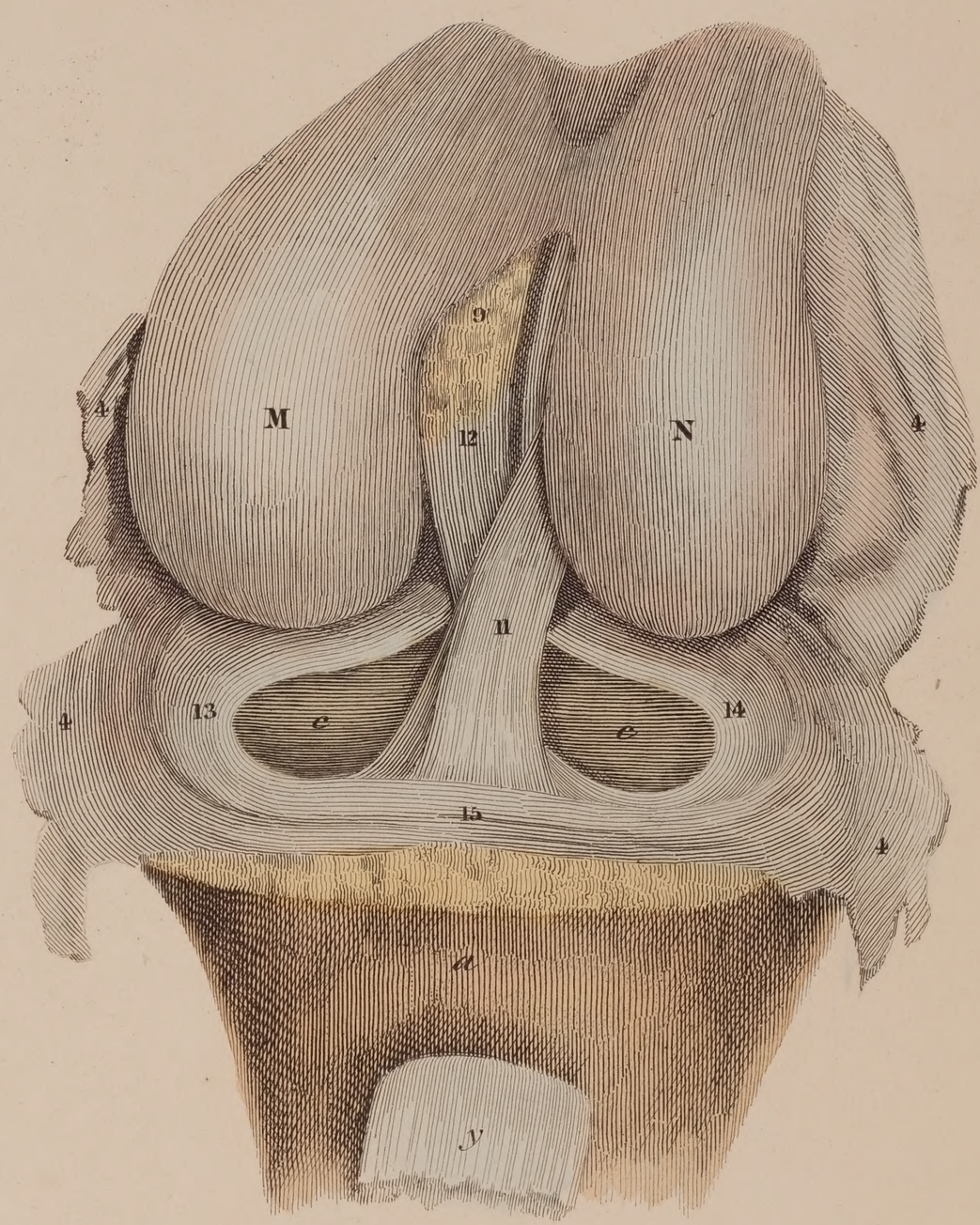

Fig. 3.

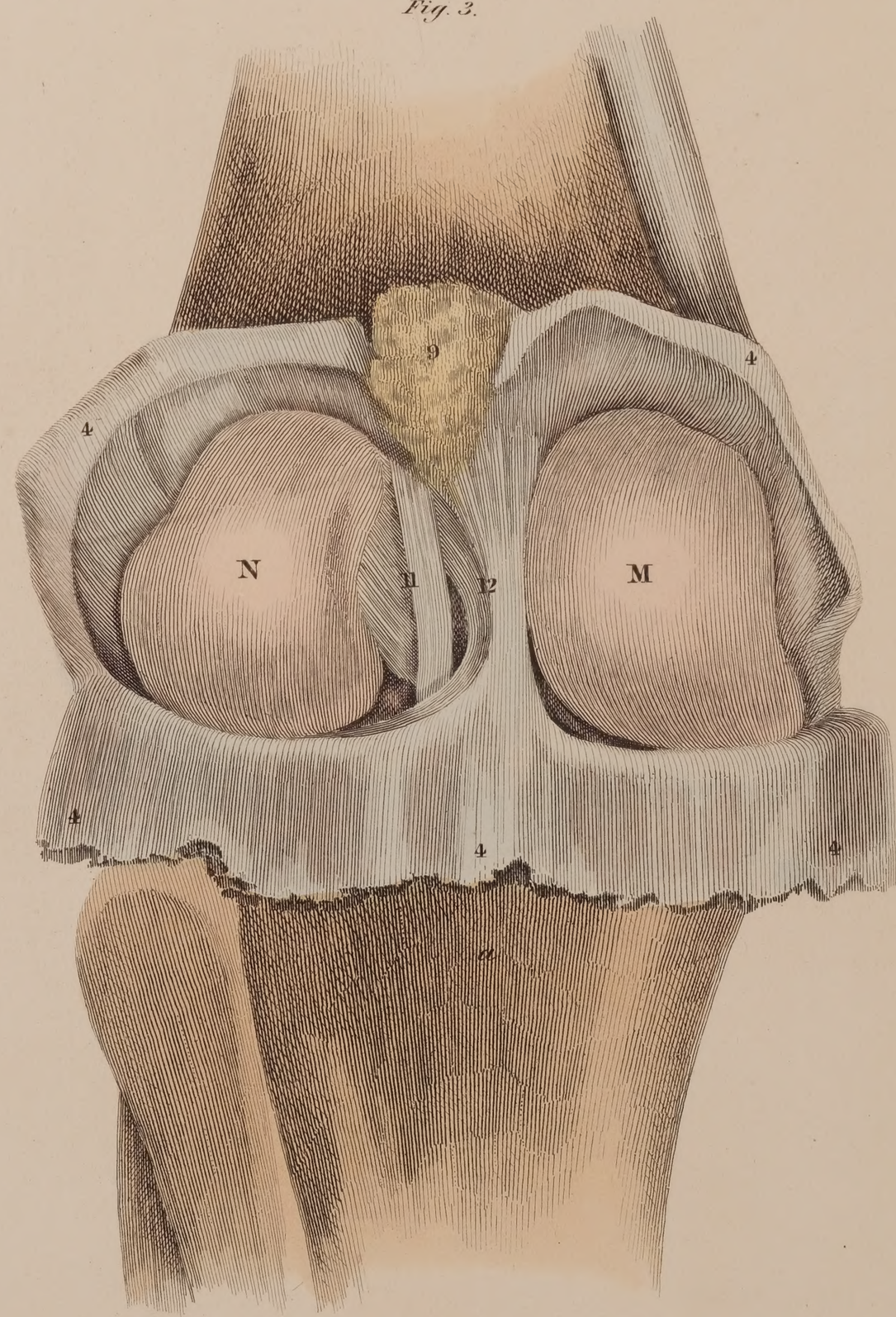

Engraved by W.H.Lizars

PLATE LI.

Fig. 1.

Fig. 2.

Fig. 3.

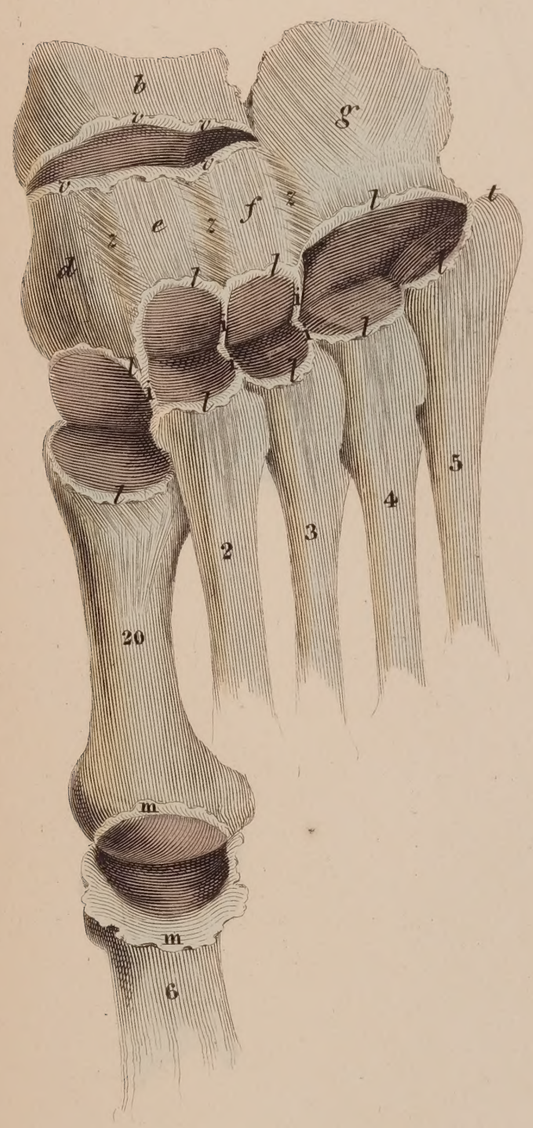

Engraved by W.H. Lizars.

PLATE LII.

Engraved by W.H. Lizars.

PLATE LIII.

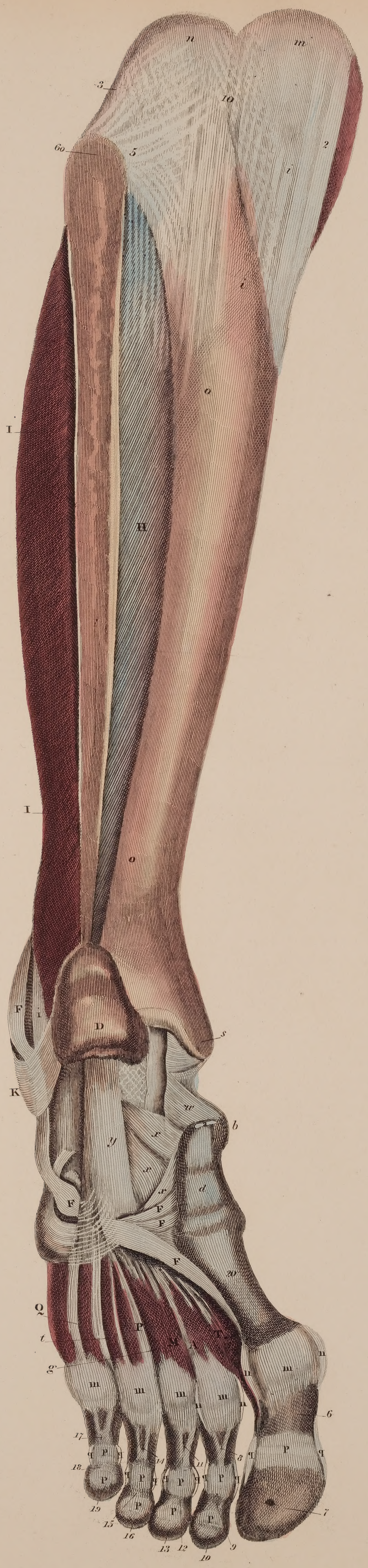

Engraved by W. H. Lizars.

PLATE LIV.

Fig. 1.

Fig. 2.

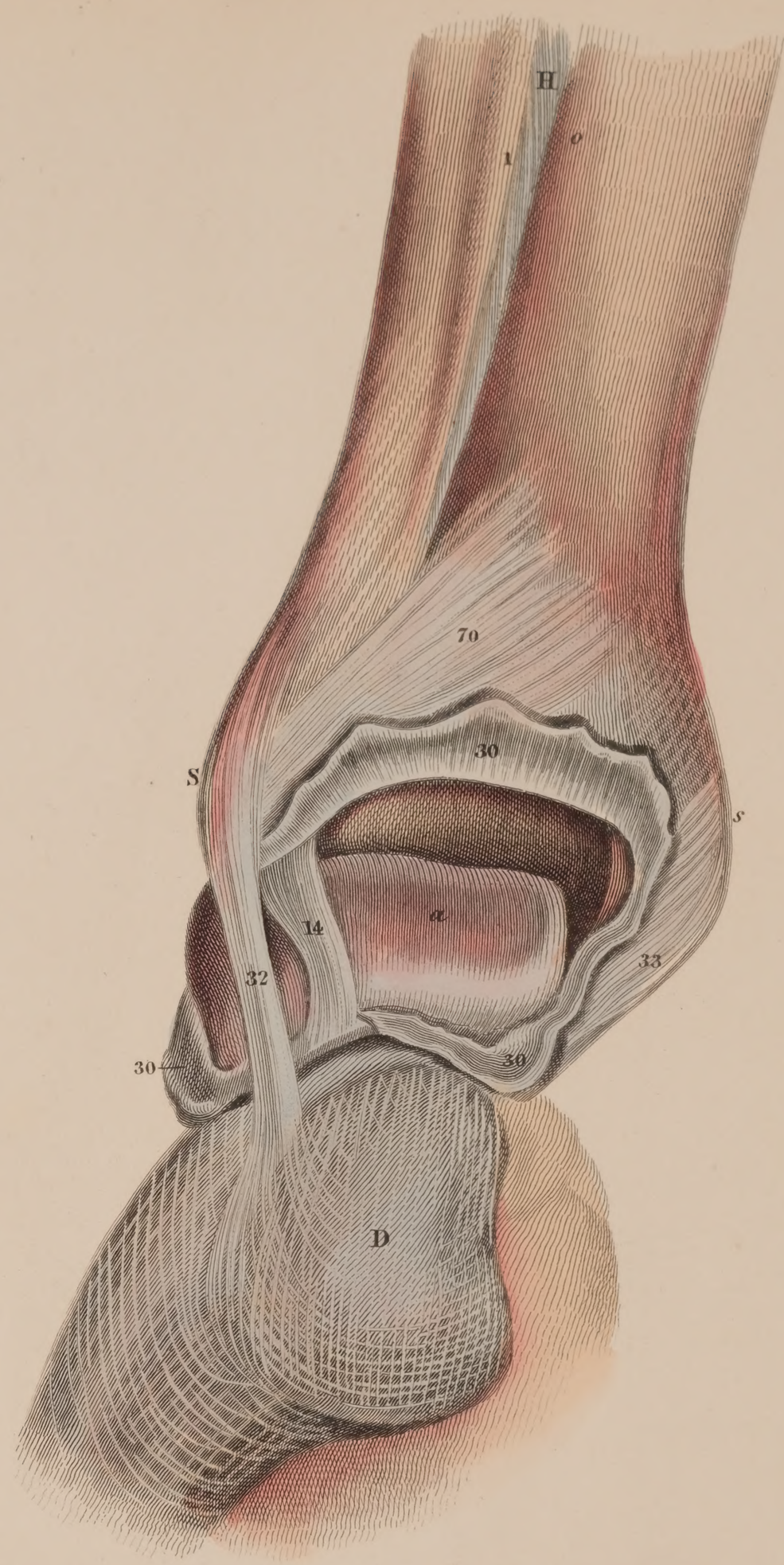

Fig. 3.

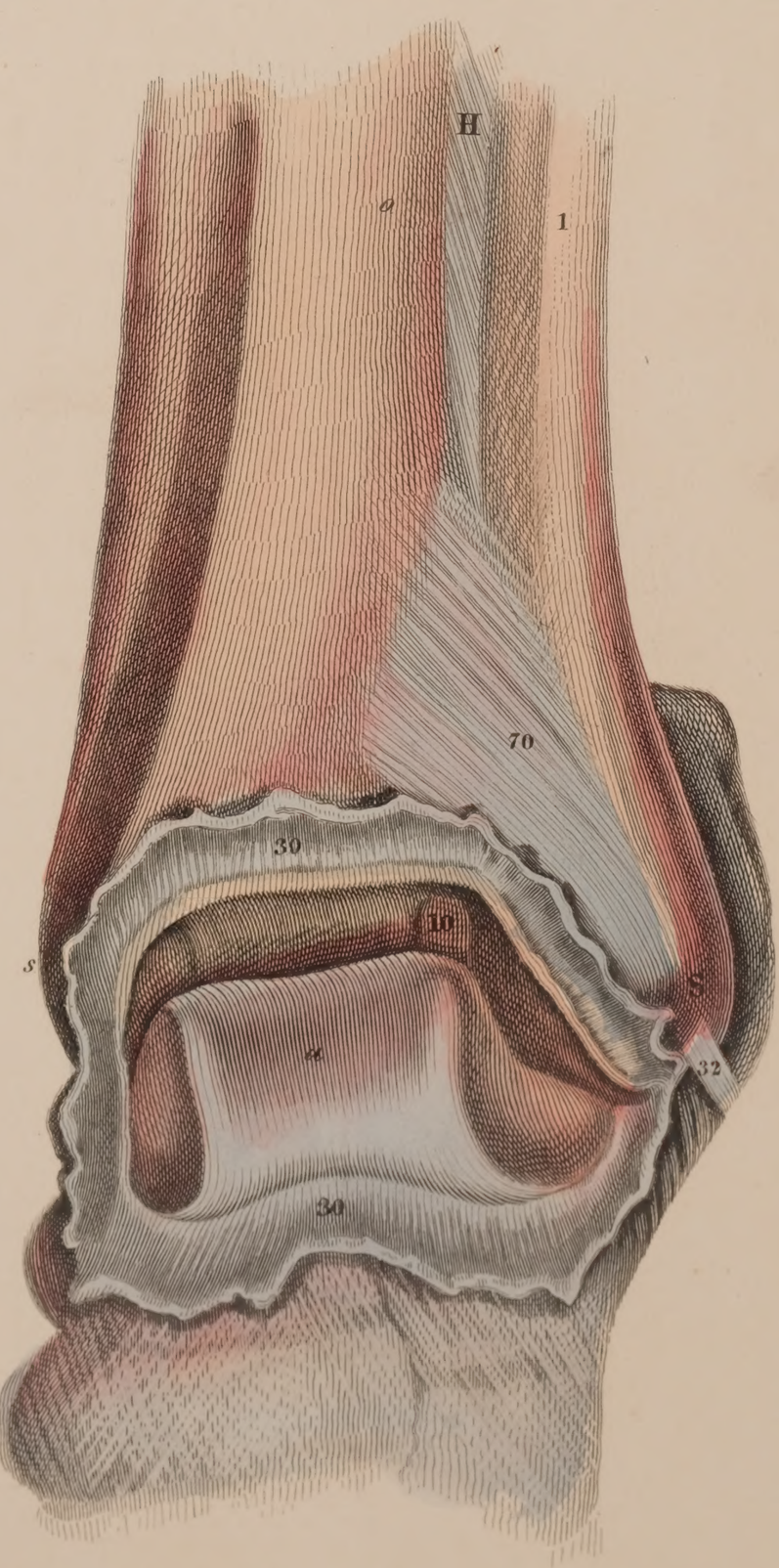

Engd. by W.H. Lizars.

PLATE LV.

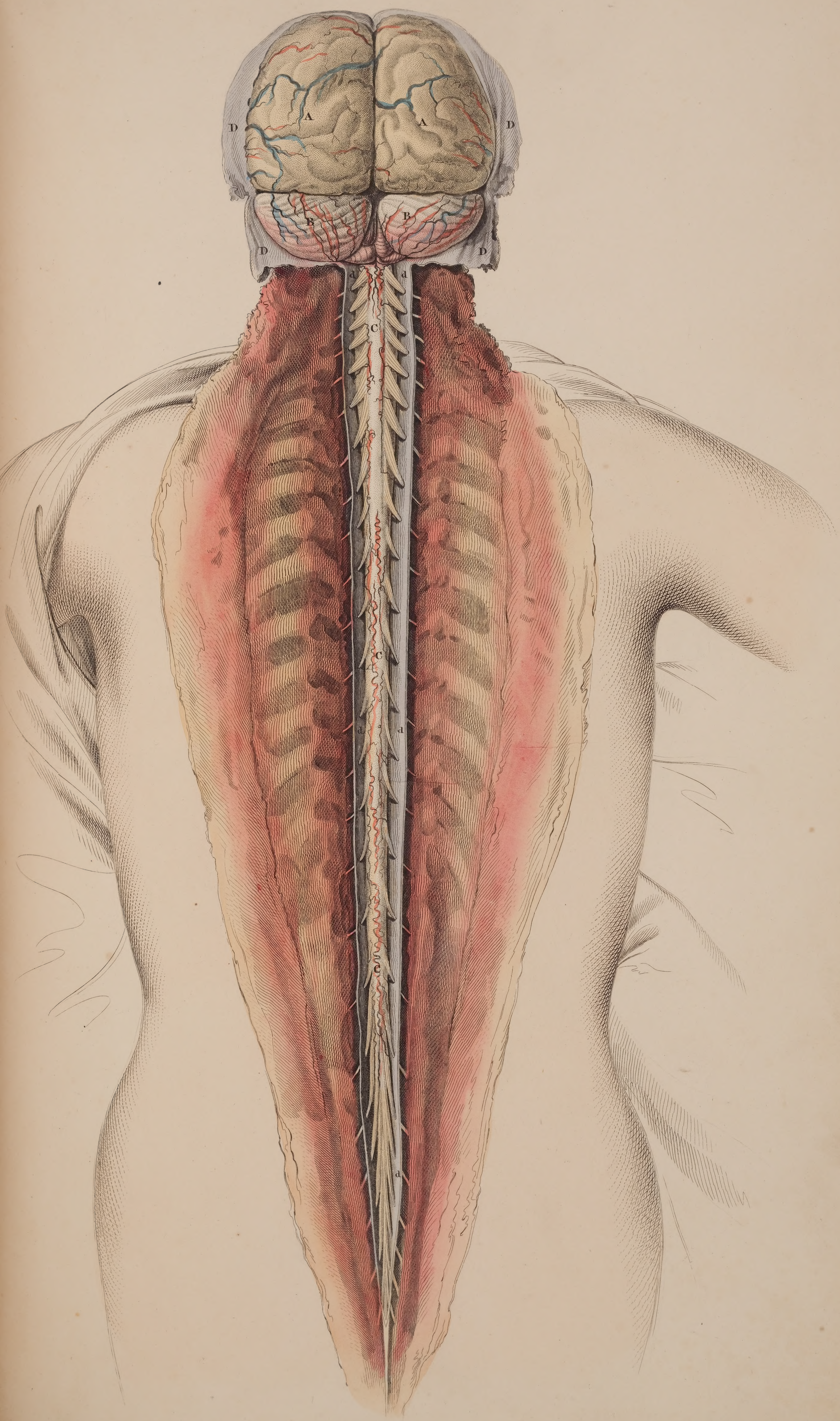

Engraved by W.H. Lizars.

PLATE LVI.

Engraved by W.H.Lizars.

PLATE LVII.

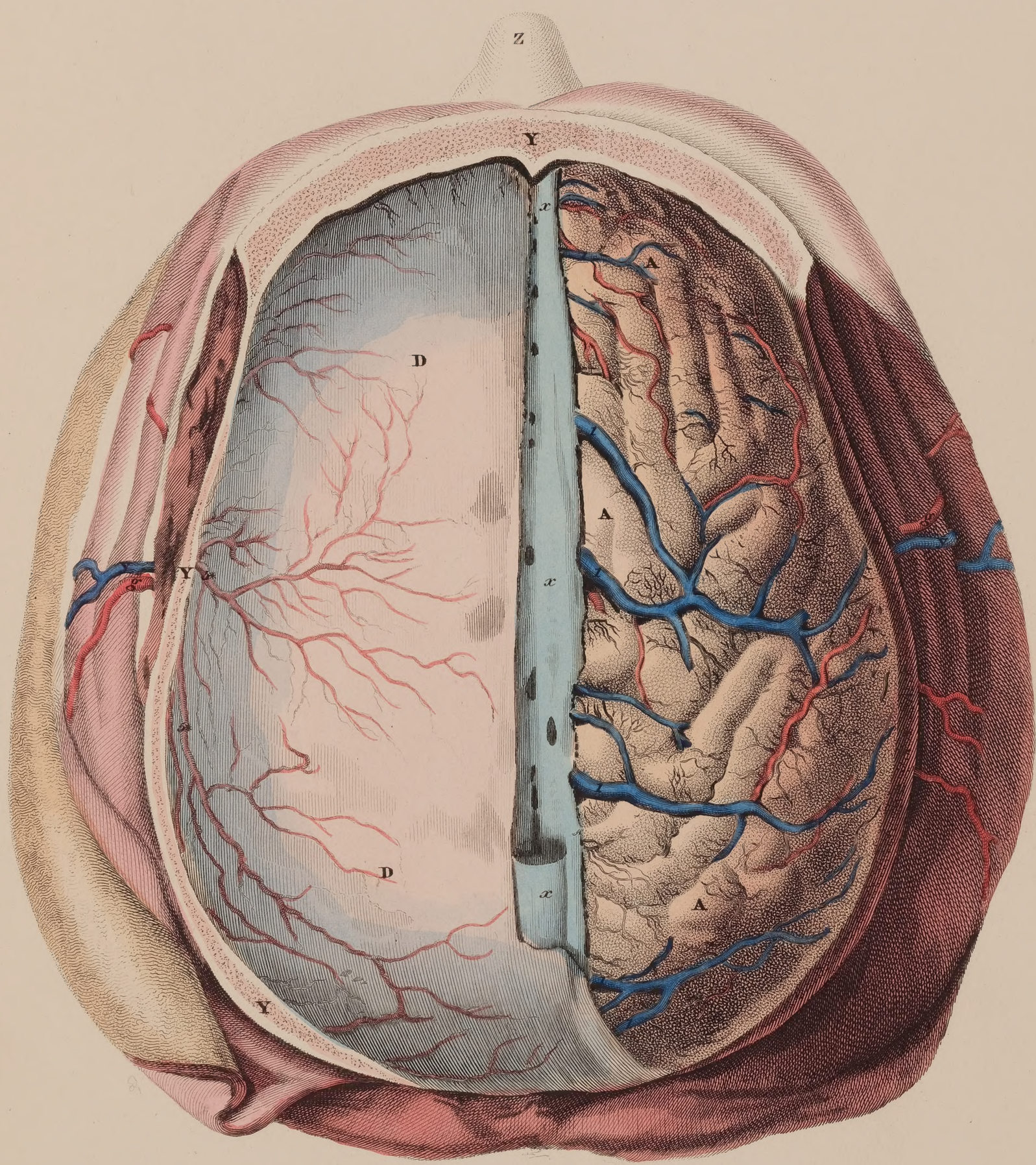

X. Superior Longitudinal Sinus
5 Middle Meningeal Artery

Engd by W.H. Lizars.

PLATE LVIII.

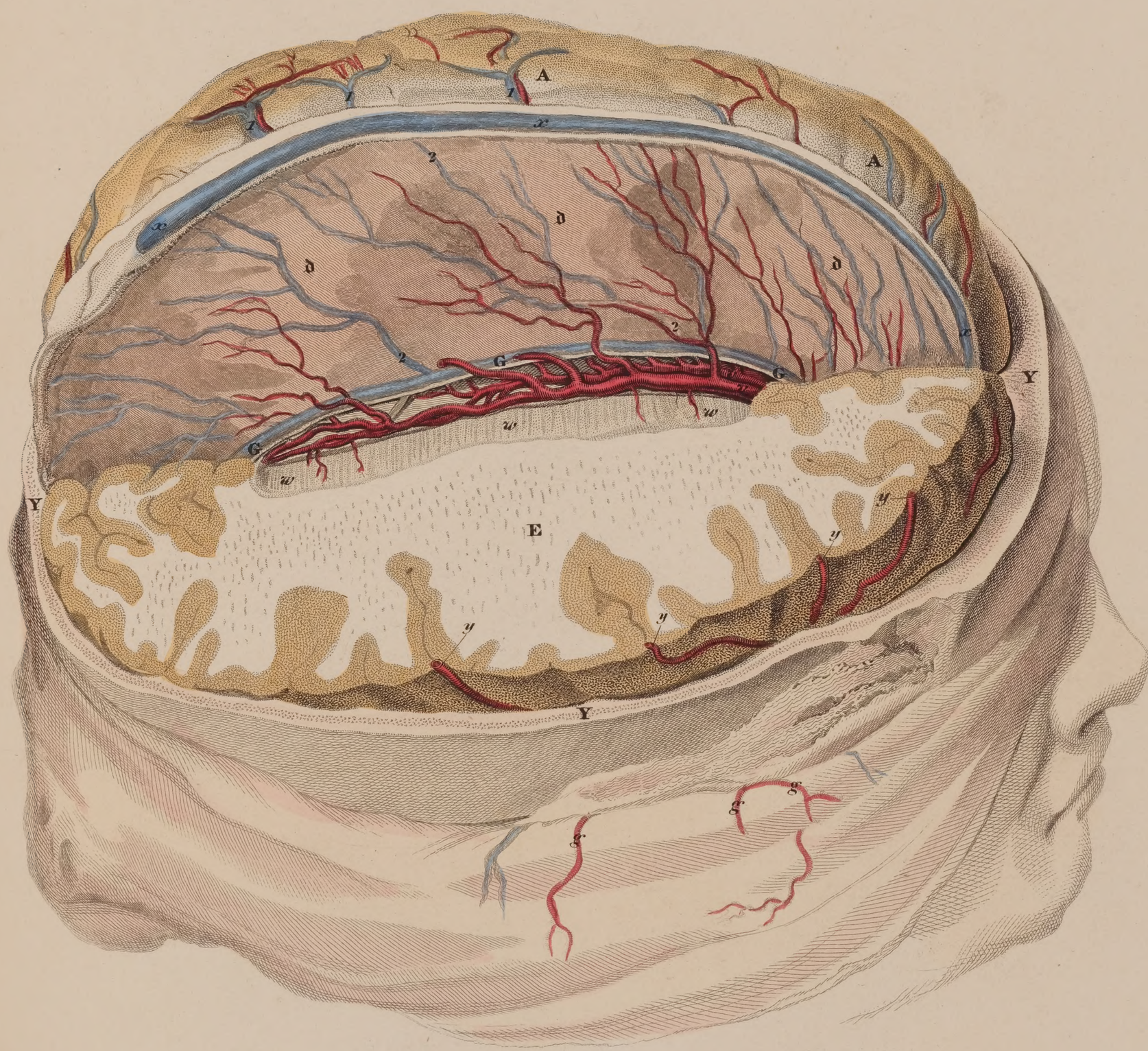

x. superior Longitudinal Sinus
G Inferior do do
v Artery of Corpus Callosum
w Corpus Callosum
y Middle Cerbral Artery
g Temporal Artery
E Medullary Matter

Engd by W.H. Lizars.

PLATE LIX.

E Centrum Ovale
V Valve of Vieussens
B Hemispheres of Cerebellum
C Spinal Cord
4 Fourth Ventricle
e e Nates
e e Testes
r r Valve of Reil
o o Anterior Cerebellar Arteries

Engd by W. H. Lizars.

PLATE LX.

A Anterior Cornu of lateral Ventricle
D Dura Mater
E Medullary Matter of Hemispheres
F Optic Thalamus
G Corpus Striatum
I Inferior Cornu of lateral Ventricle
K Fornix
L Septum Lucidum
M Foramen of Monro
P Posterior Cornu of lateral Ventricle

i Choroid Plexus
k Hippocampus Minor

Engd by W.H. Lizars.

PLATE LXI.

Fig. 1.

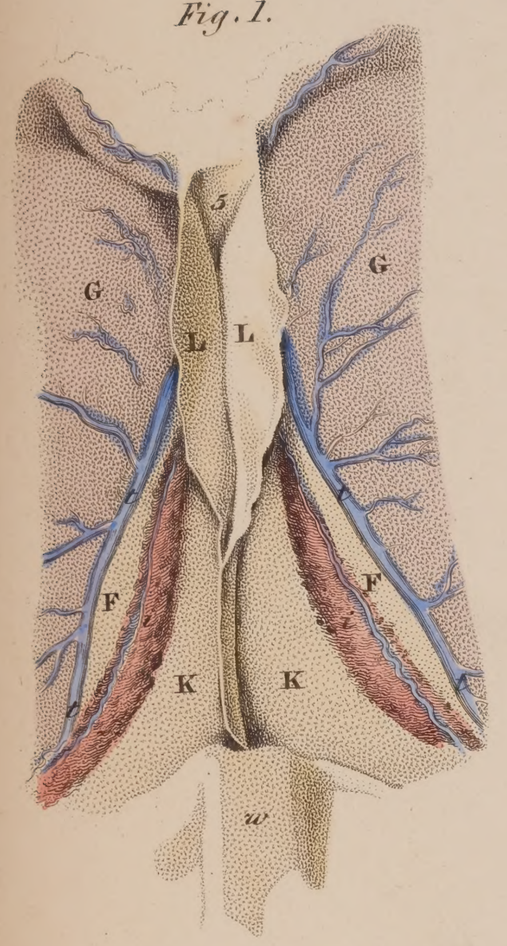

Fig. 2.

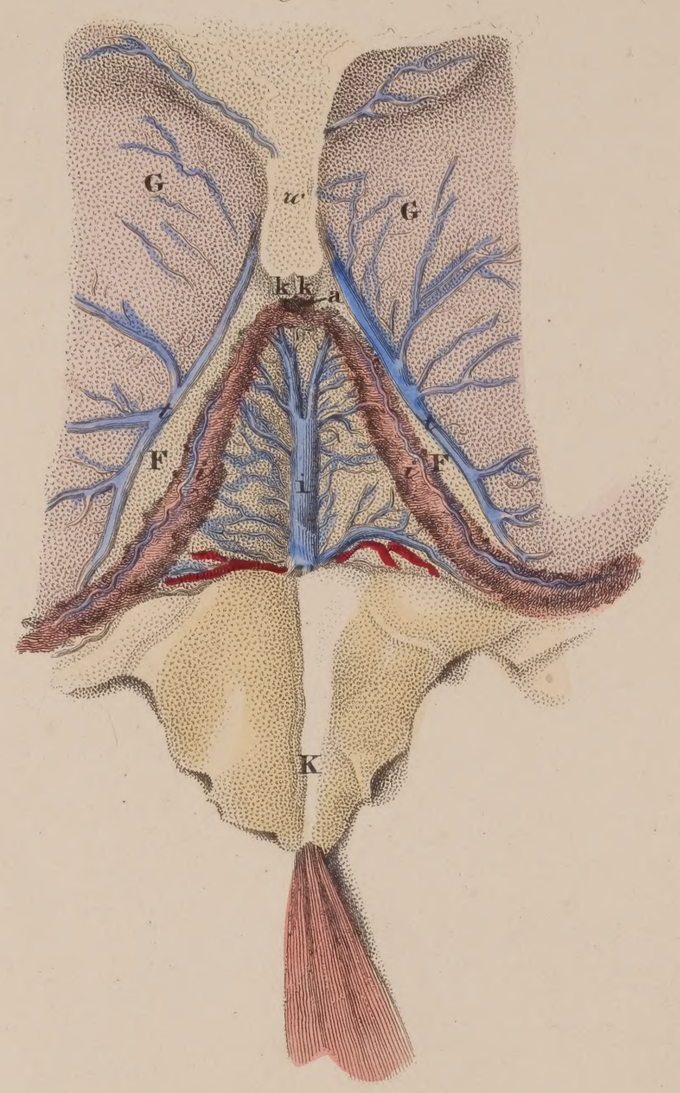

Fig. 3.

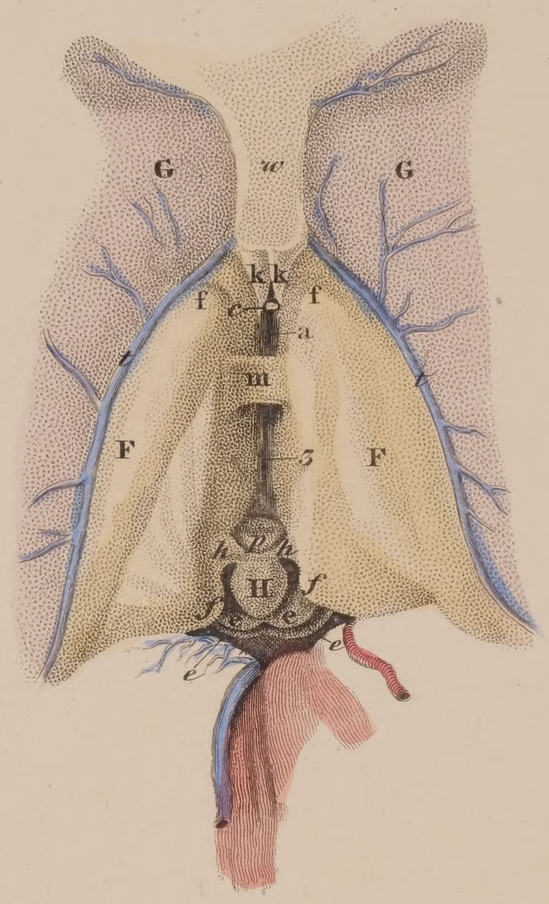

Fig. 4.

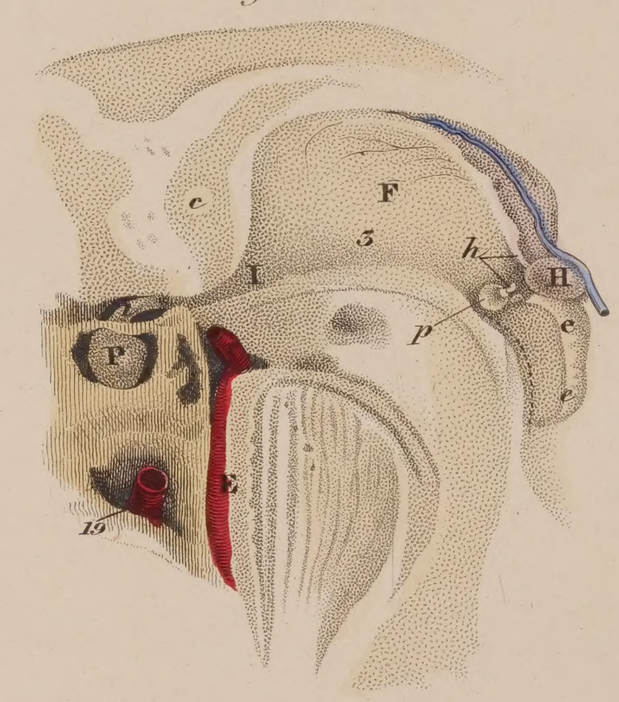

Fig. 5.

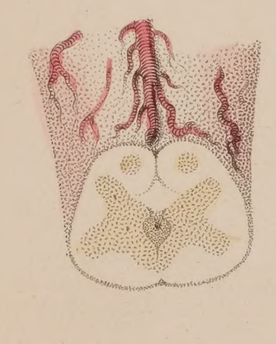

Fig. 6.

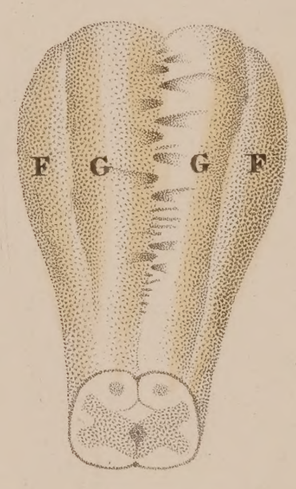

Fig. 7.

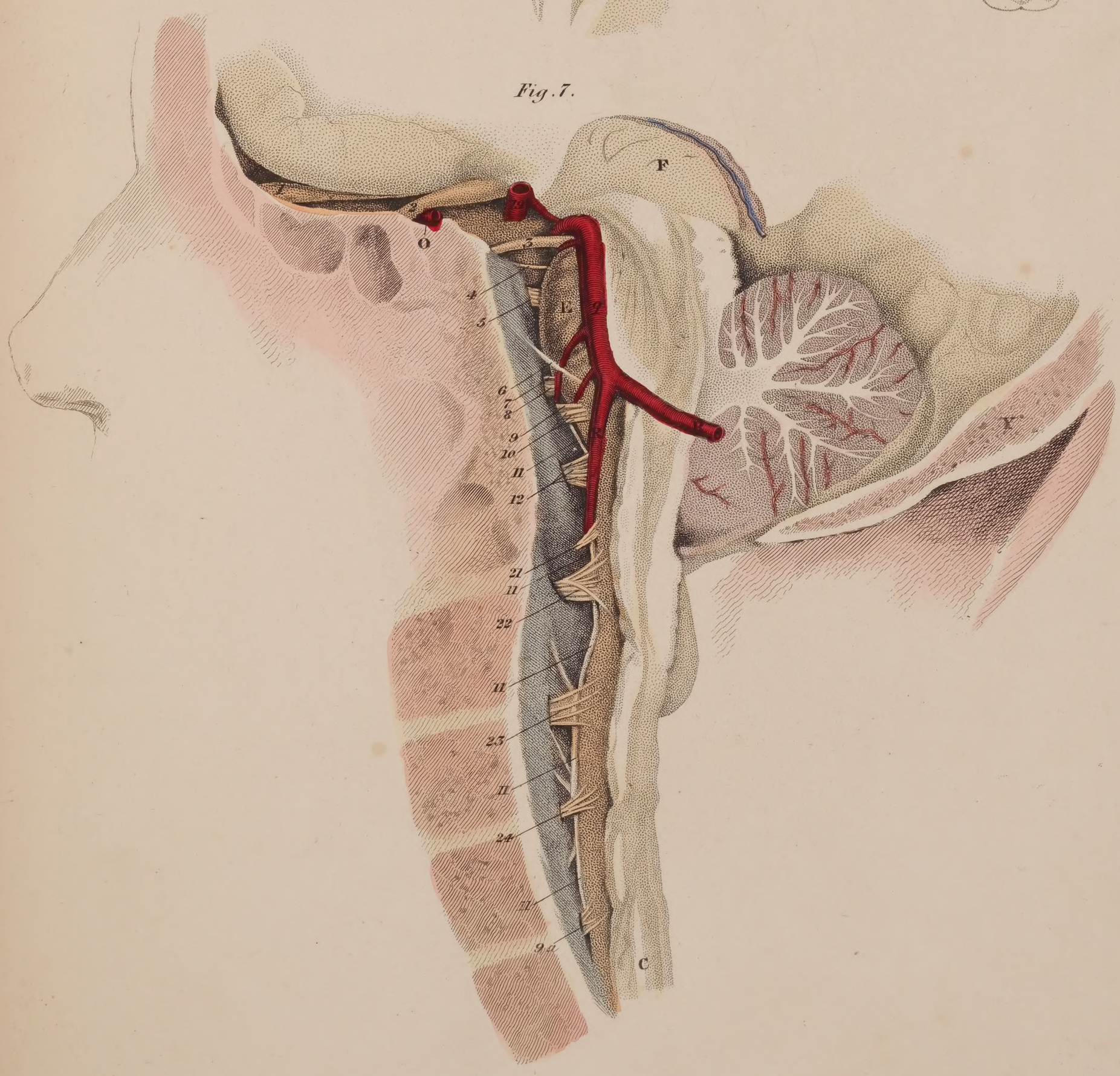

Engd. by W.H.Lizars.

PLATE LXII.

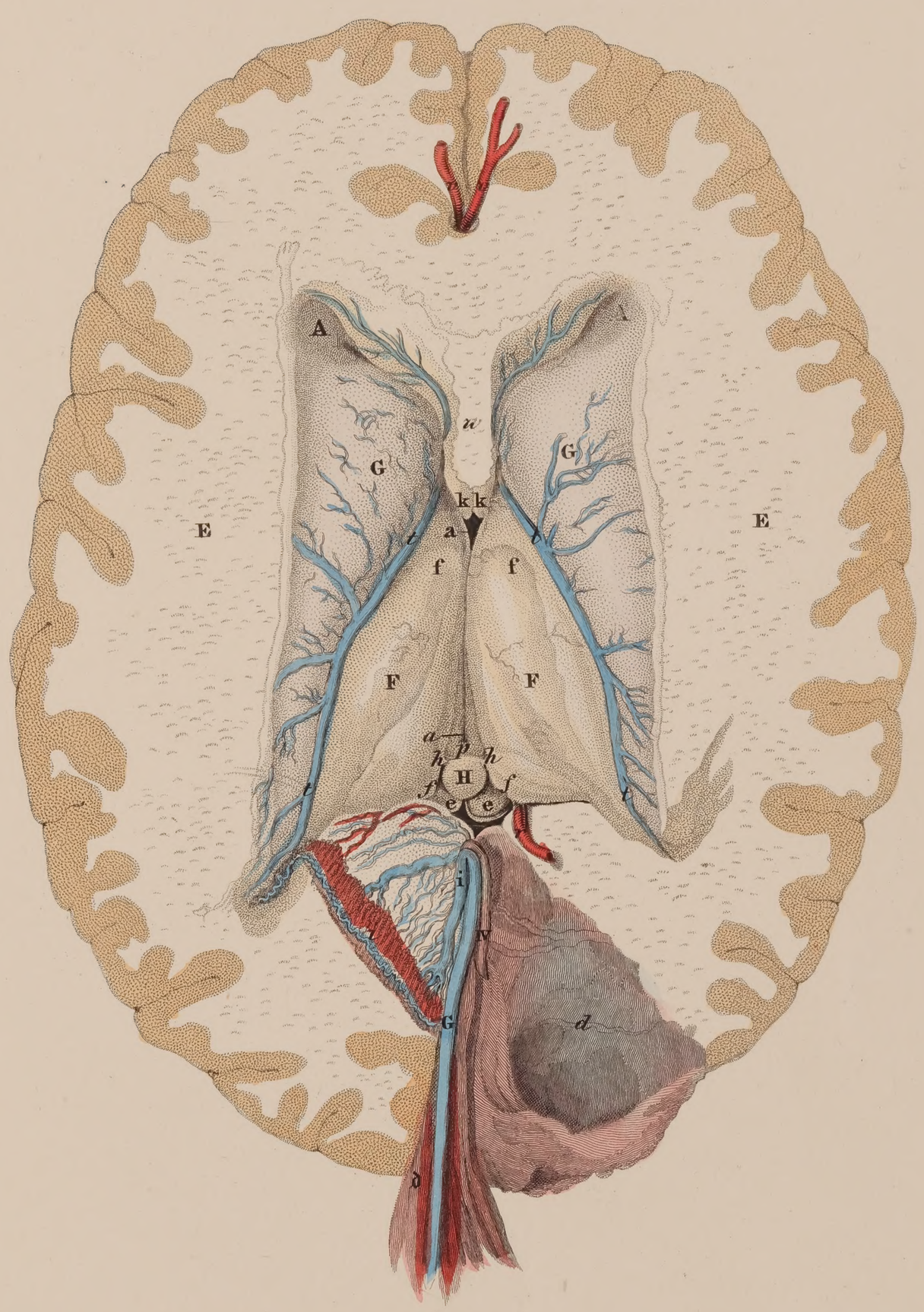

Engraved by W.H.Lizars.

PLATE LXIII.

Engraved by W.H. Lizars.

PLATE LXIV.

Engraved by W.H. Lizars.

PLATE LXV.

Eng.d by W.H. Lizars.

PLATE LXVI.

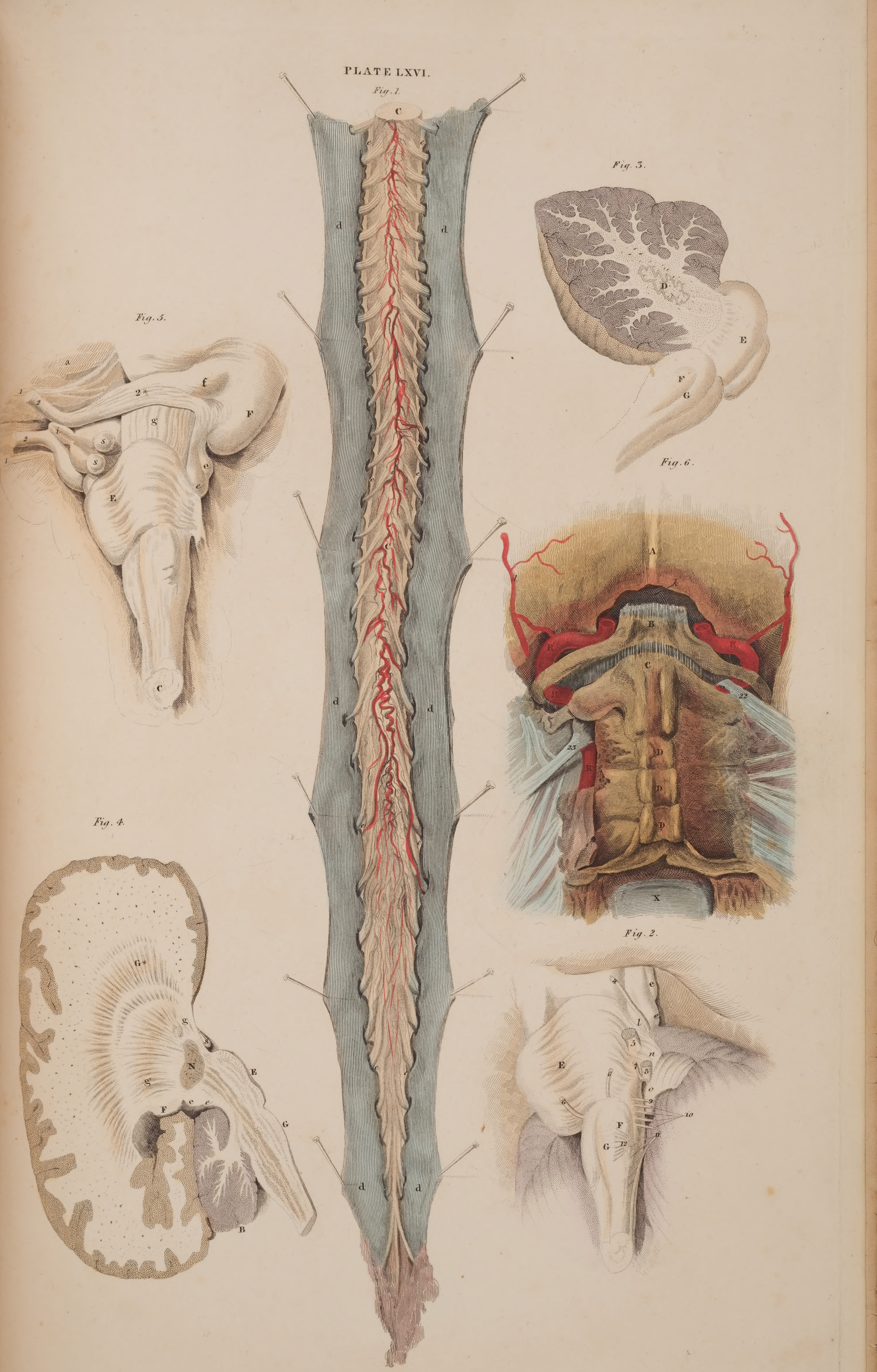

Engd. by W. H. Lizars.

PLATE LXVII.

Engraved by W. H. Lizars.

PLATE LXVIII.

Engd by W.H.Lizars

PLATE LXIX.

Engd by W.H. Lizars

PLATE LXX.

Engraved by W.H.Lizars.

PLATE LXXI.

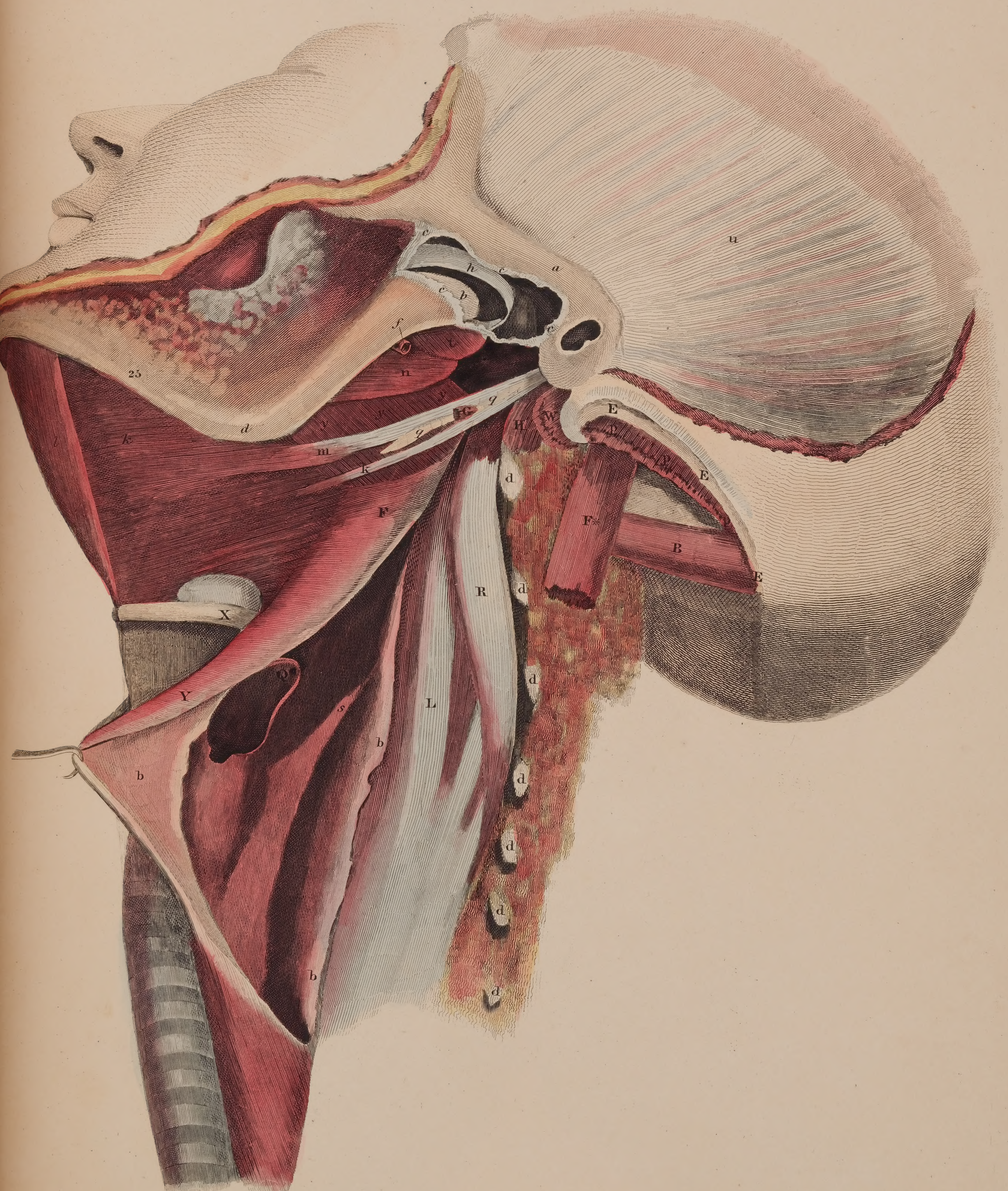

Engd by W. H. Lizars.

PLATE LXXII.

Fig. 2.

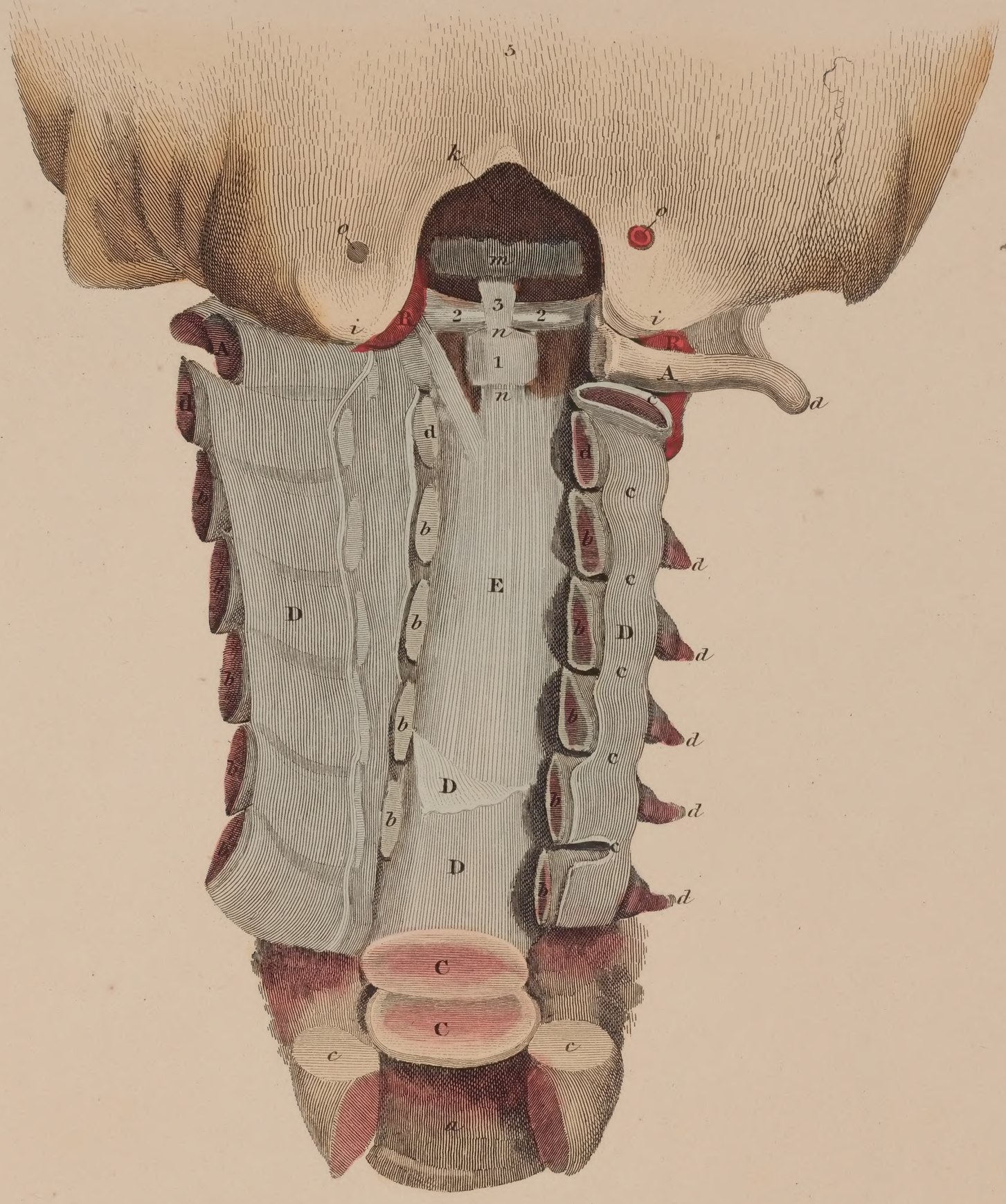

Fig. 1.

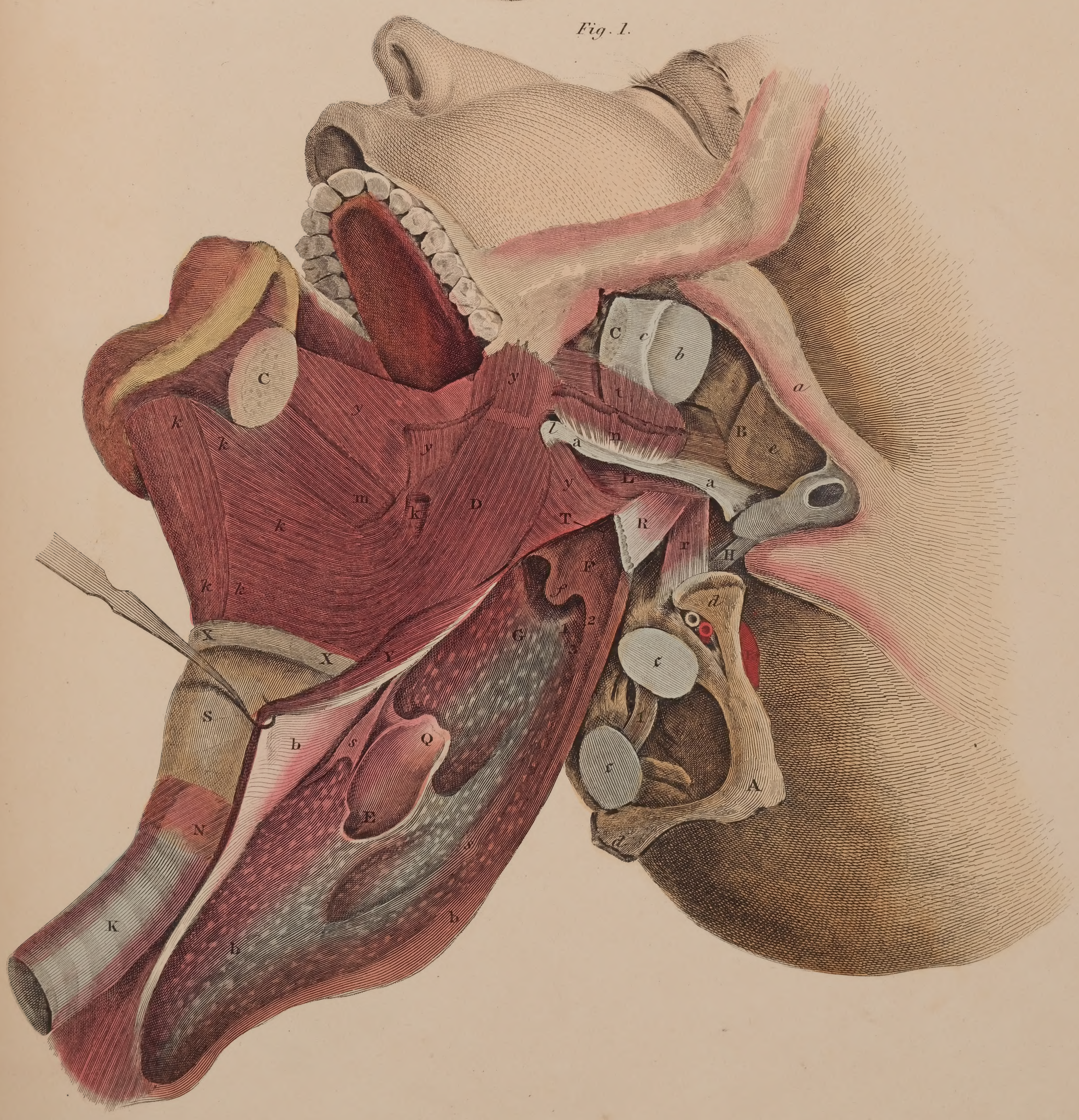

Engd. by W.H. Lizars.

PLATE LXXIII.

Fig. 2.

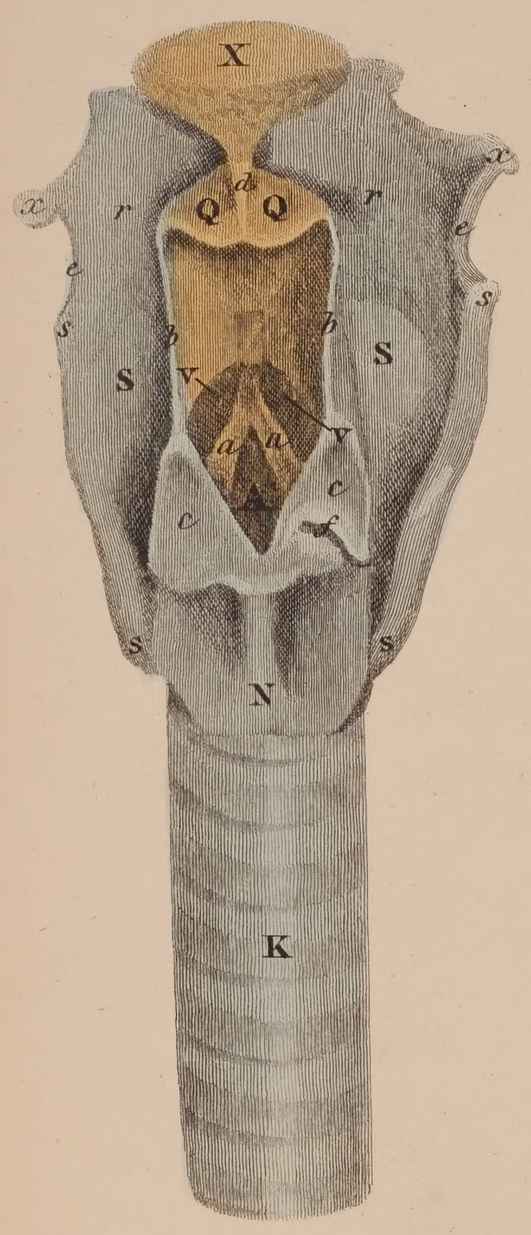

Fig. 3.

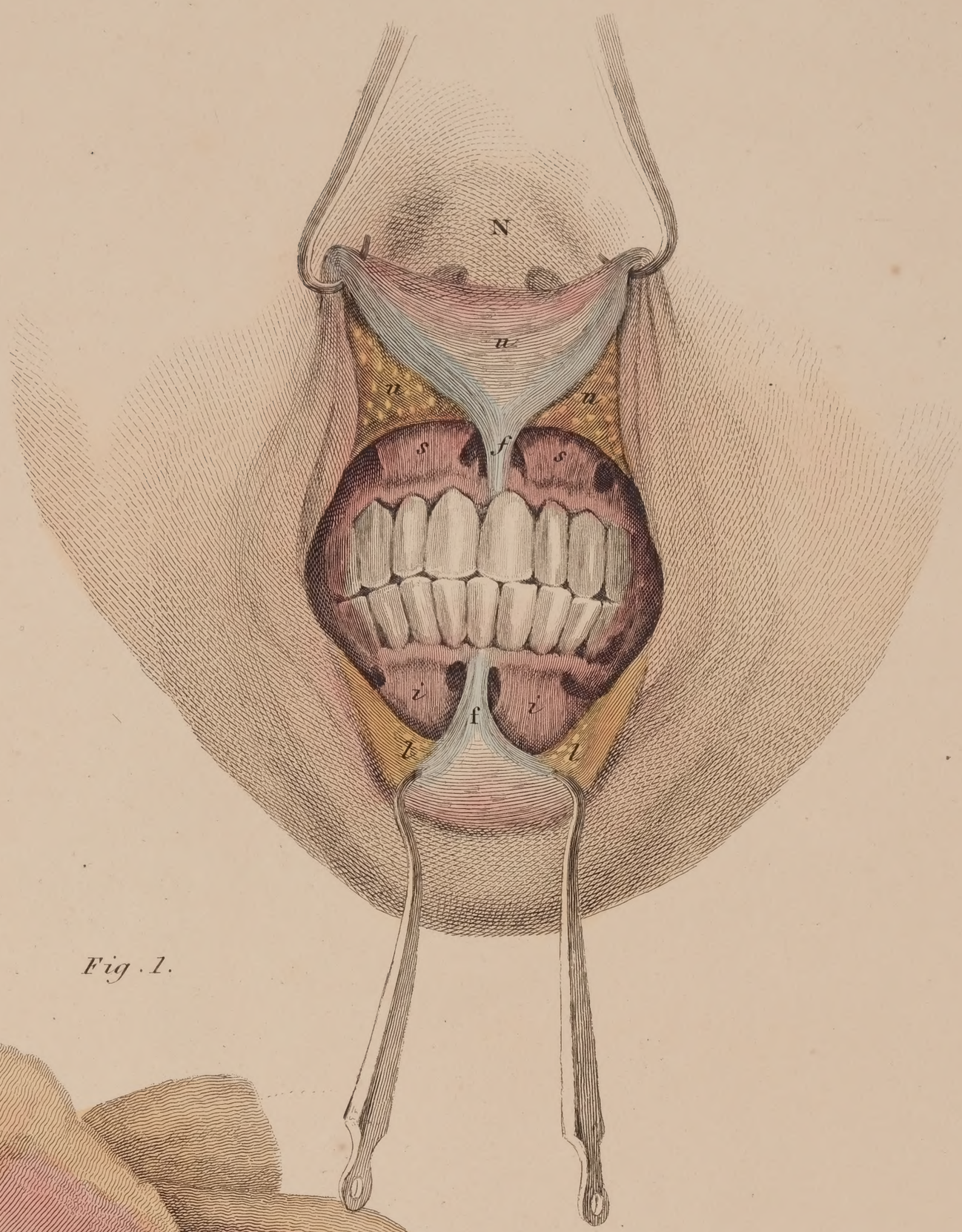

Fig. 1.

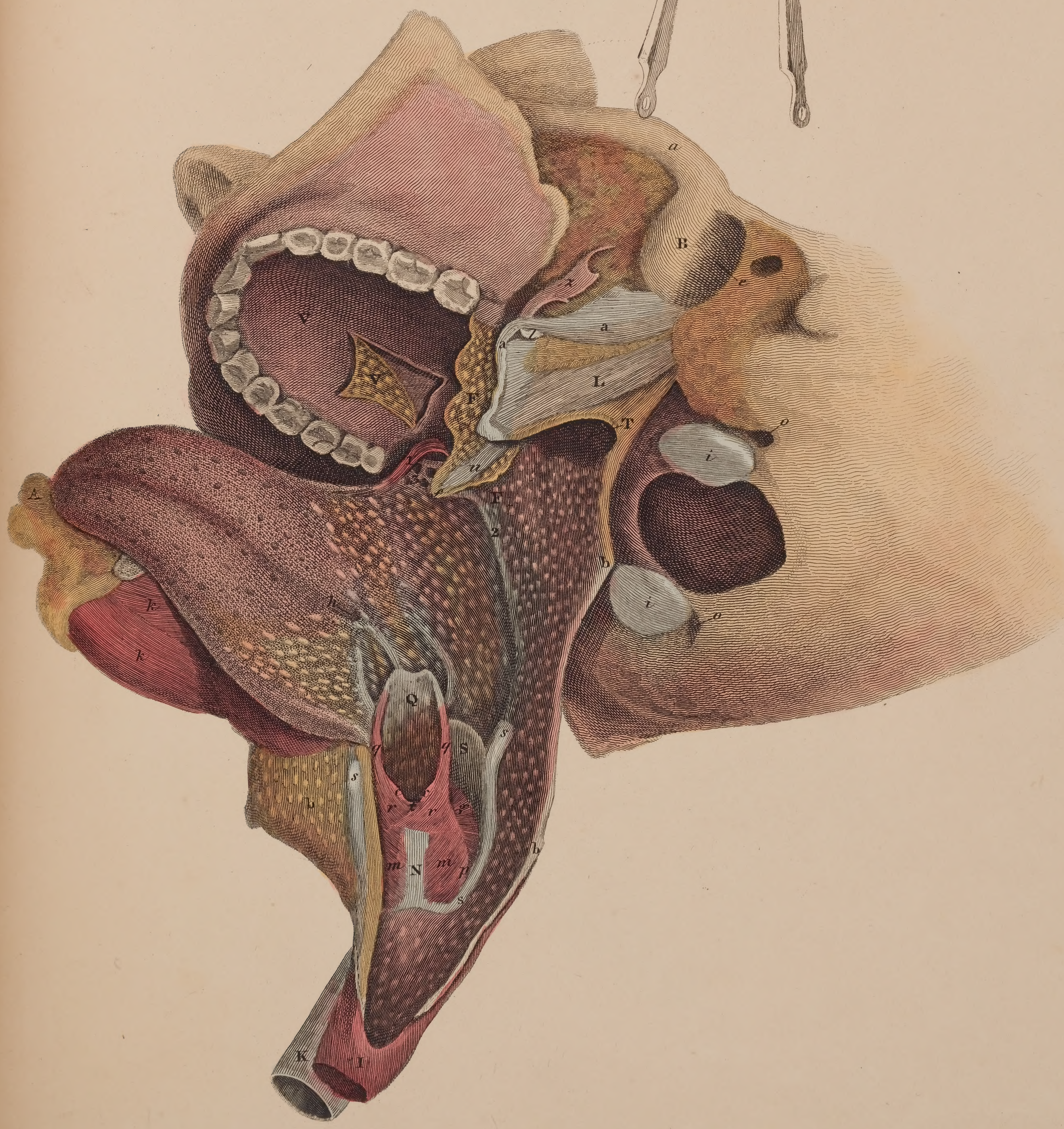

Engd. by W.H. Lizars.

PLATE LXXIV.

Fig. 2.

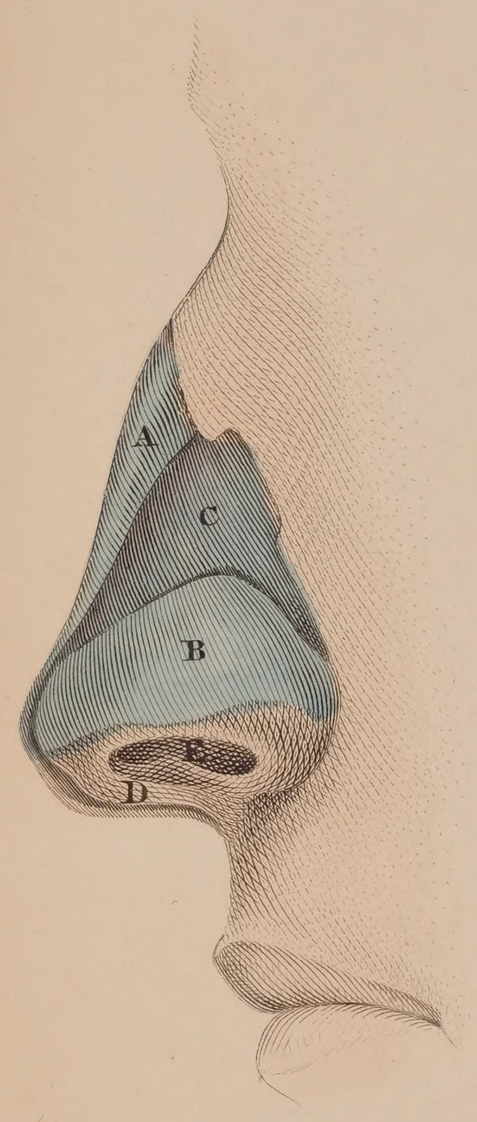

Fig. 3.

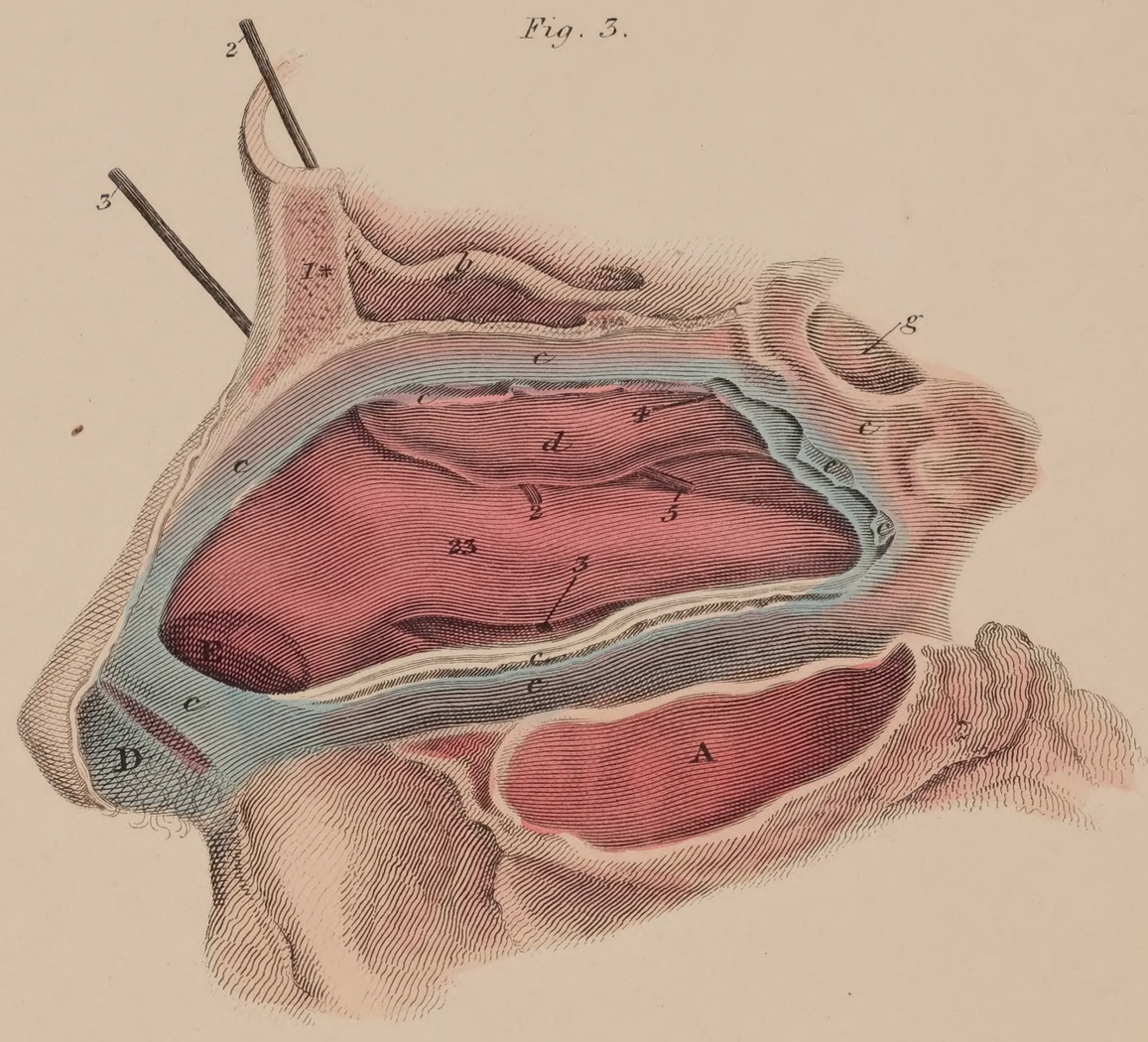

Fig. 1.

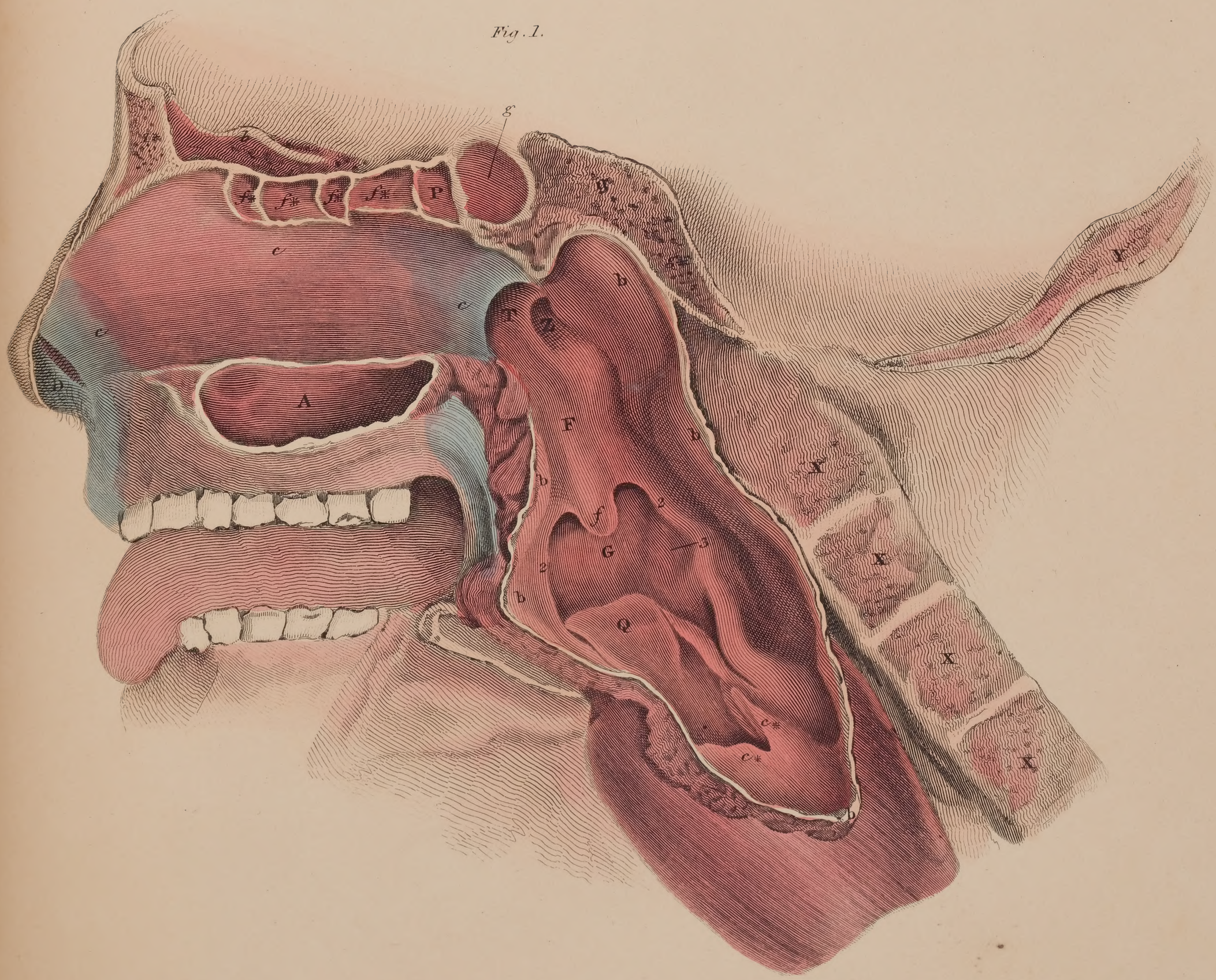

Engd by W.H. Lizars.

PLATE LXXV.

Fig. 1.

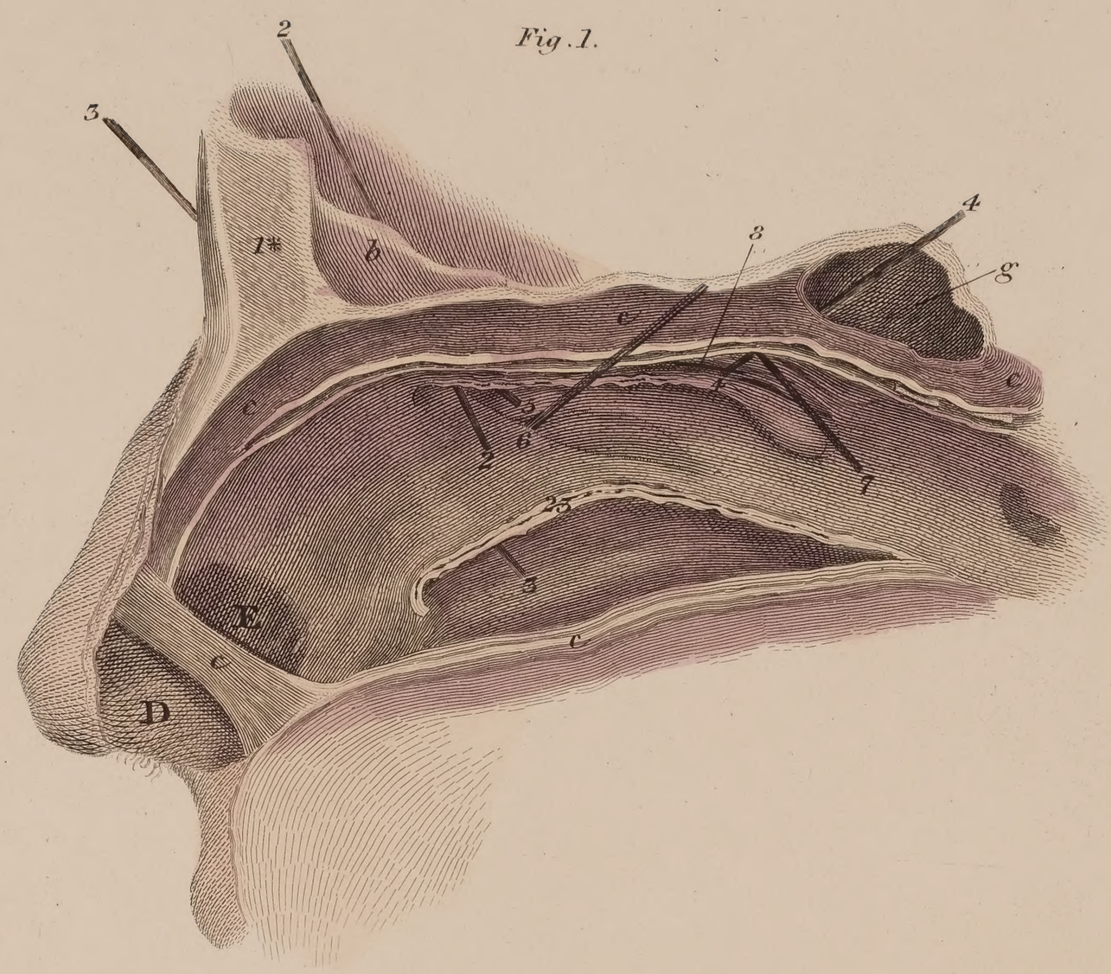

Fig. 2.

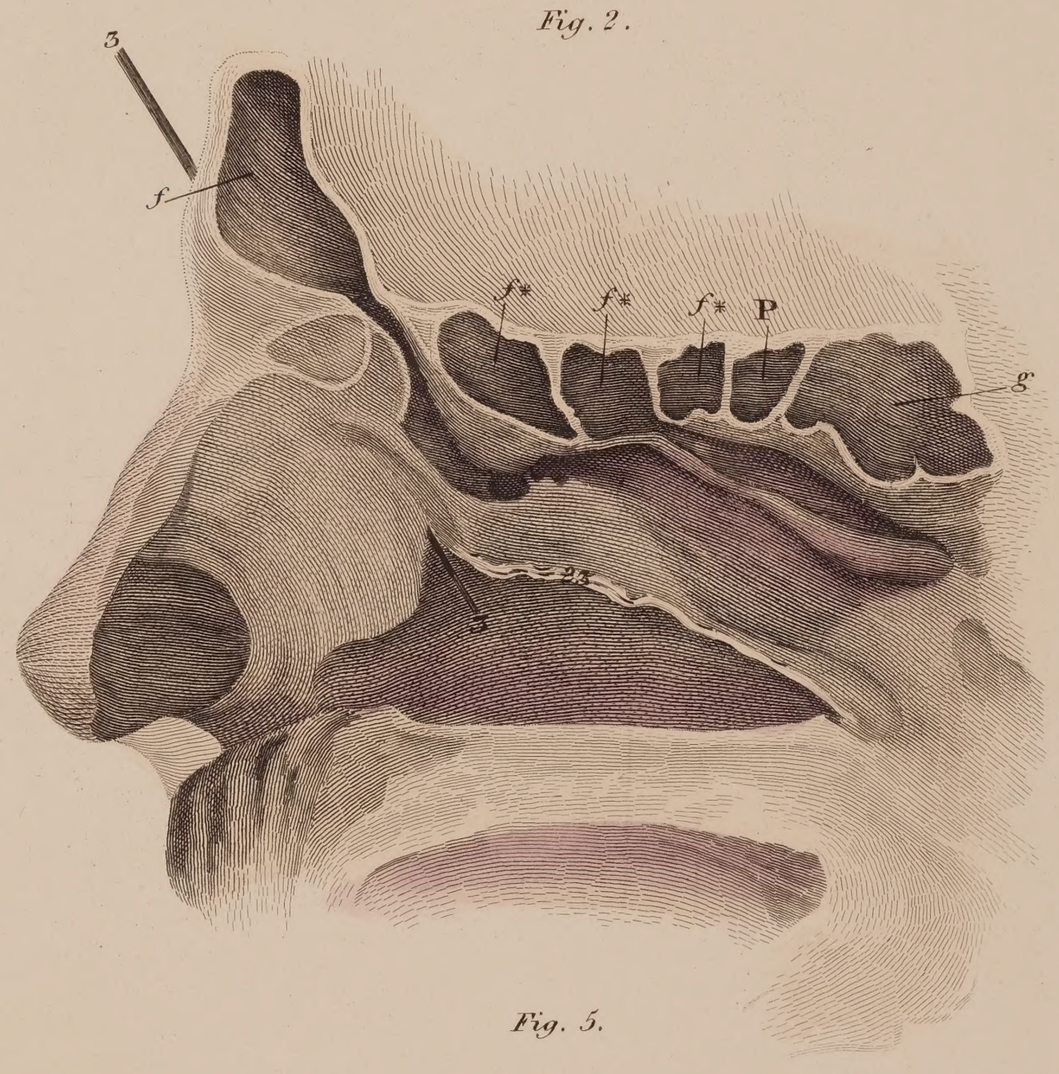

Fig. 3.

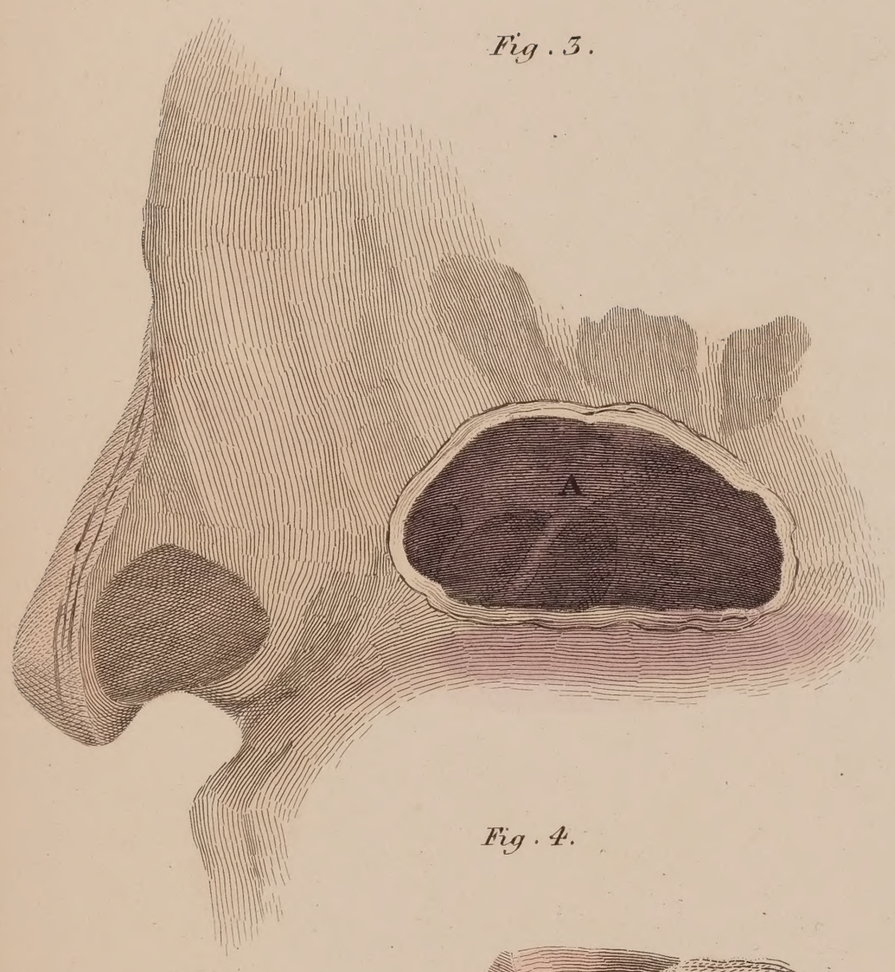

Fig. 4.

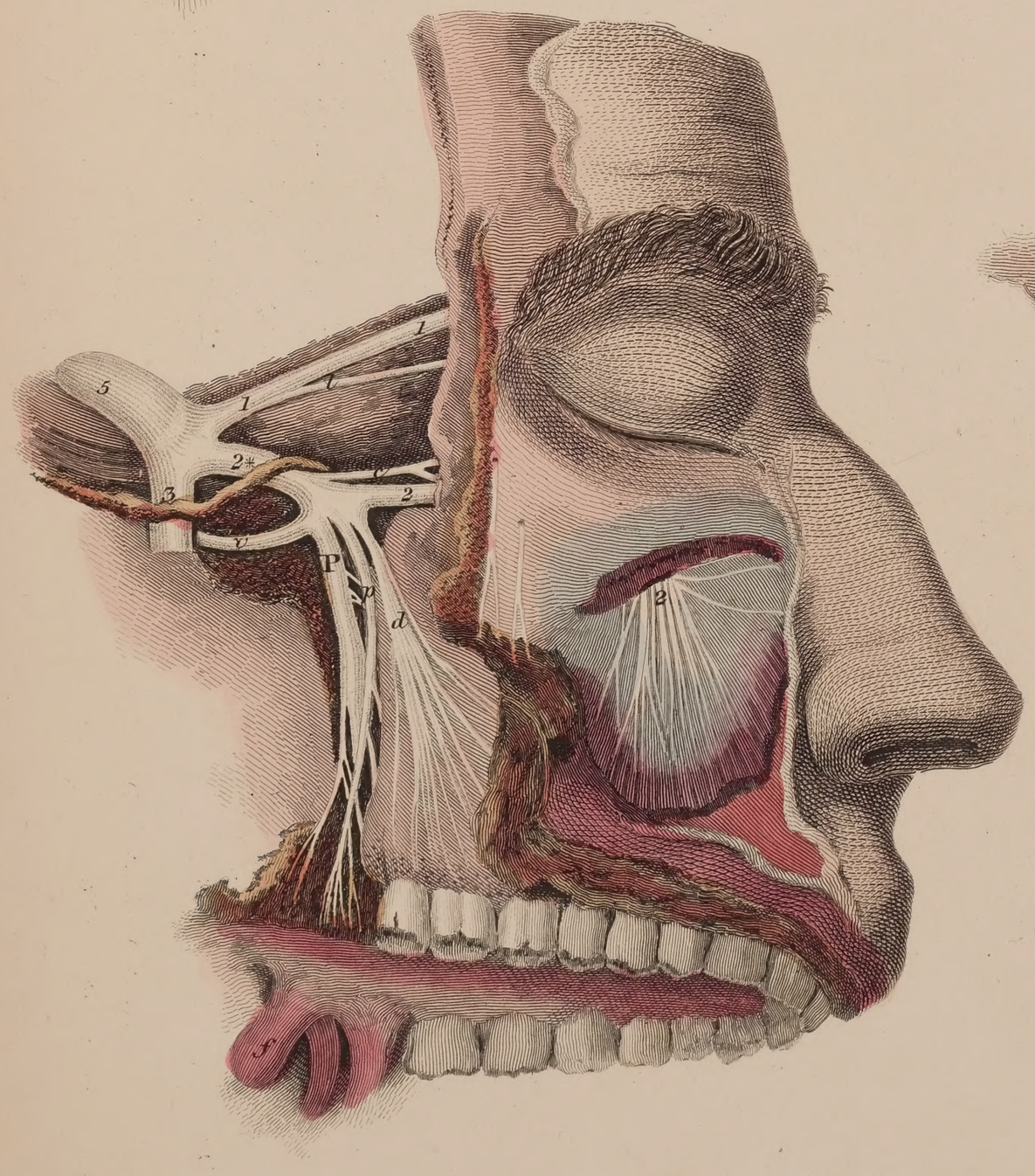

Fig. 5.

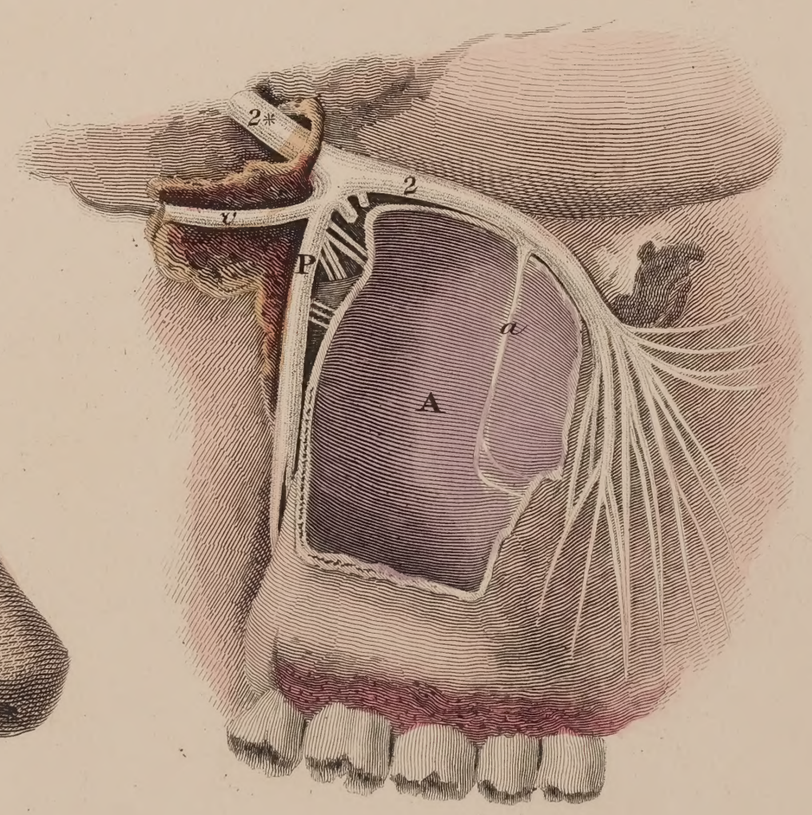

Engd by W.H. Lizars.

Fig. 2.

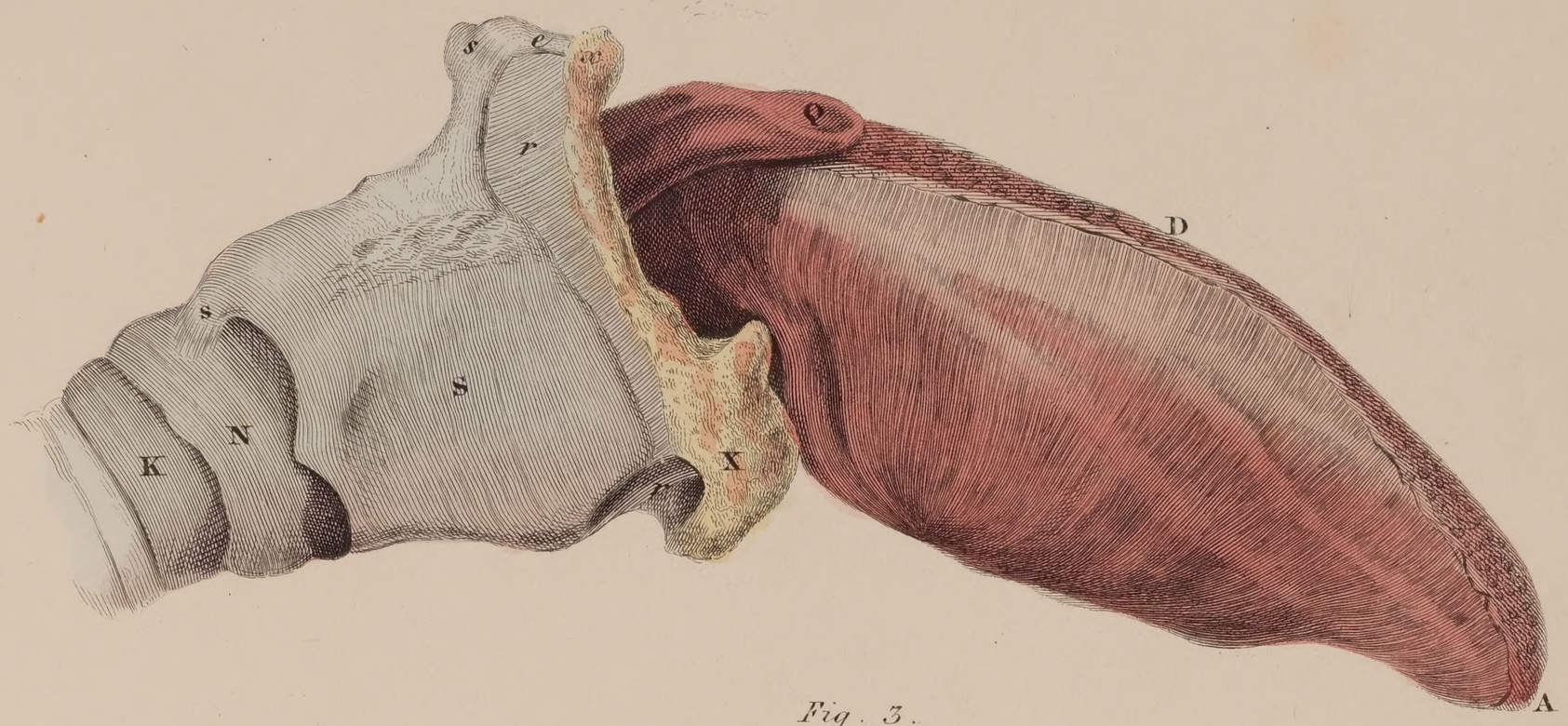

Fig. 3.

Fig. 4.

Fig. 1.

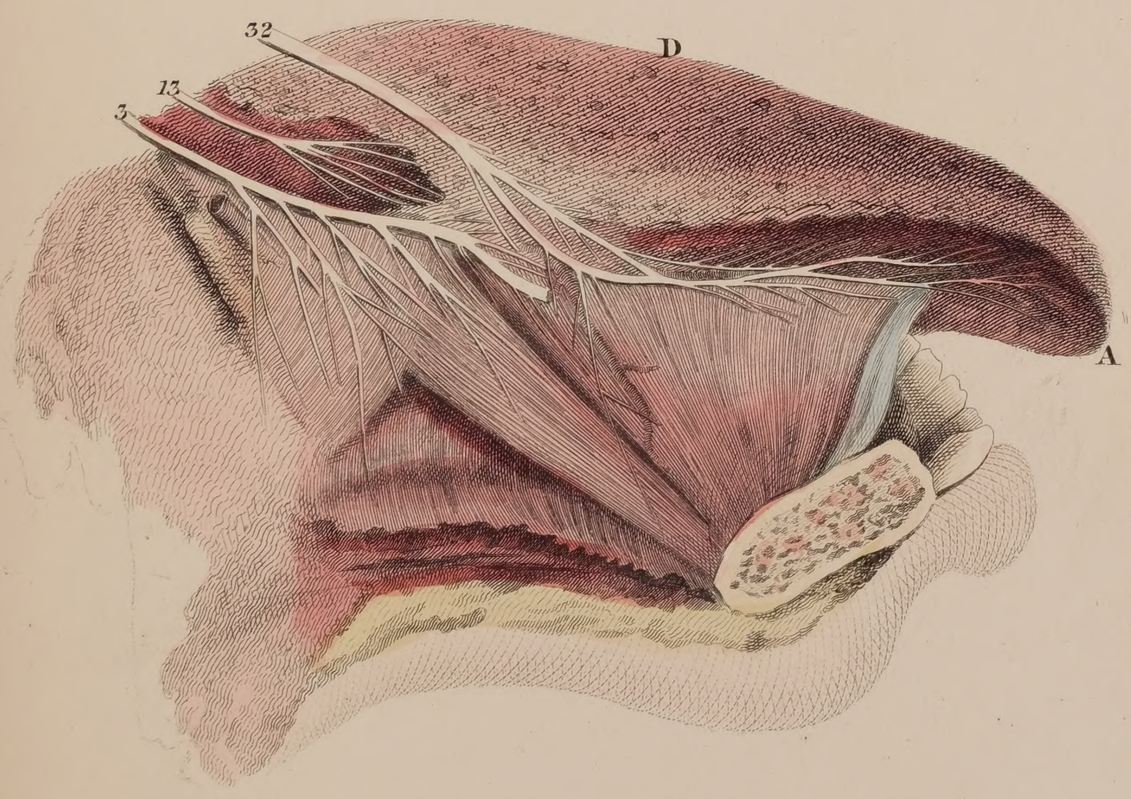

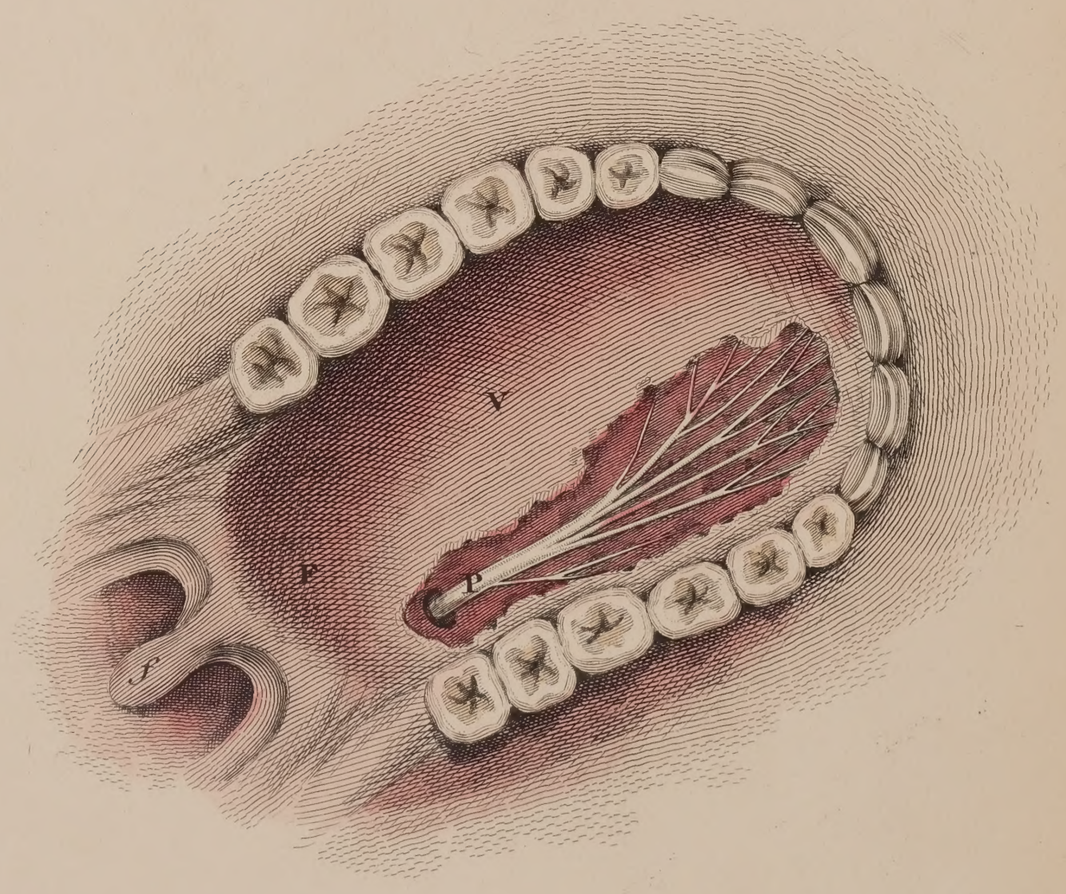

Engd by W.H. Lizars. Edinr.

PLATE LXXVII.

Fig. 1.

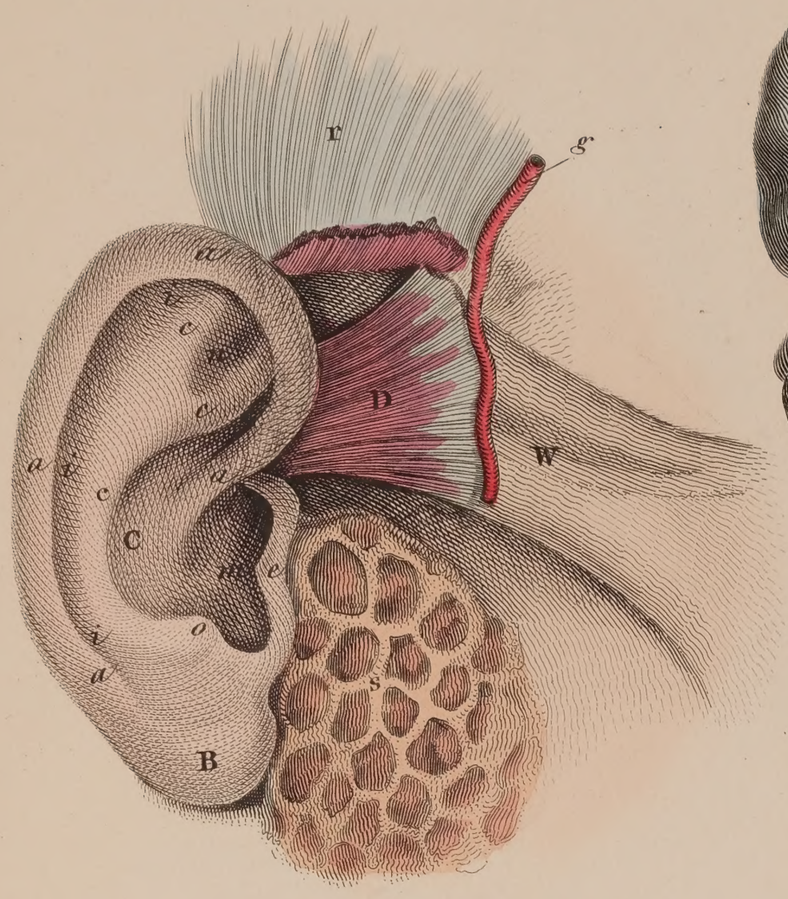

Fig. 4.

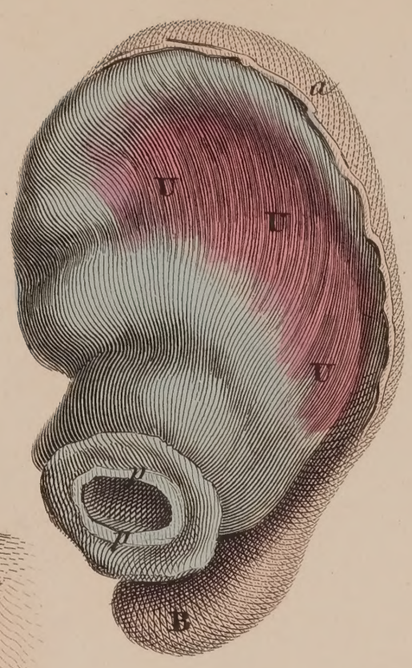

Fig. 2.

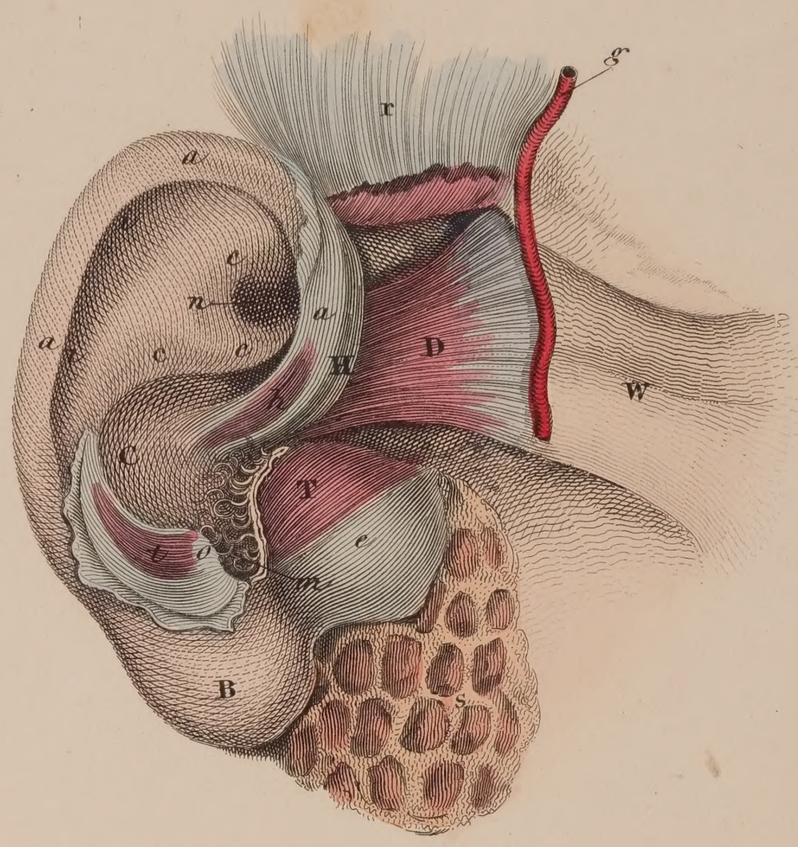

Fig. 3.

Fig. 10.

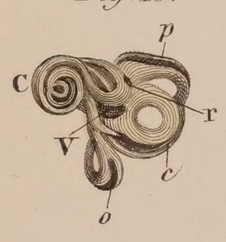

Fig. 11.

Fig. 12.

Fig. 13

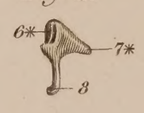

Fig. 14.

Fig. 15.

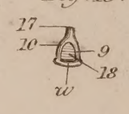

Fig. 7.

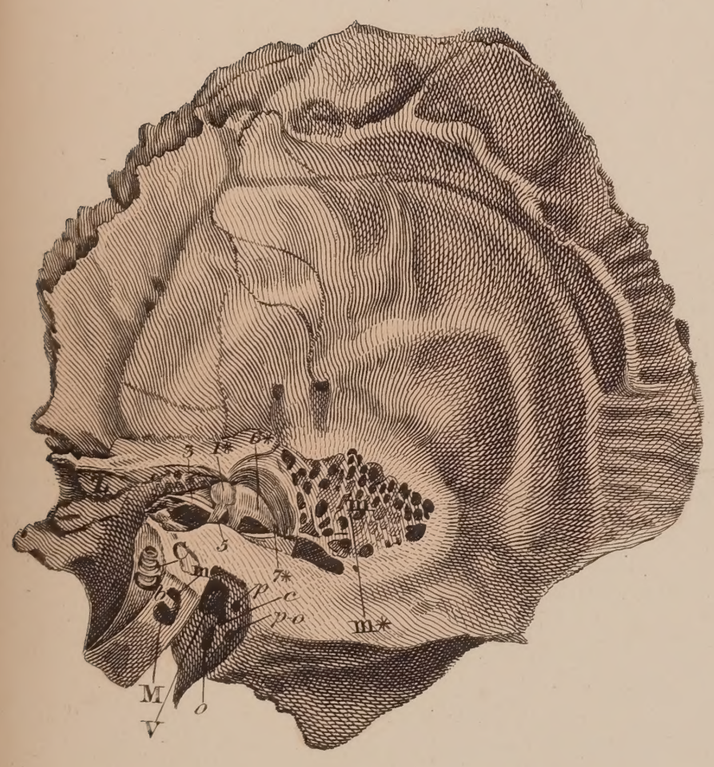

Fig. 16.

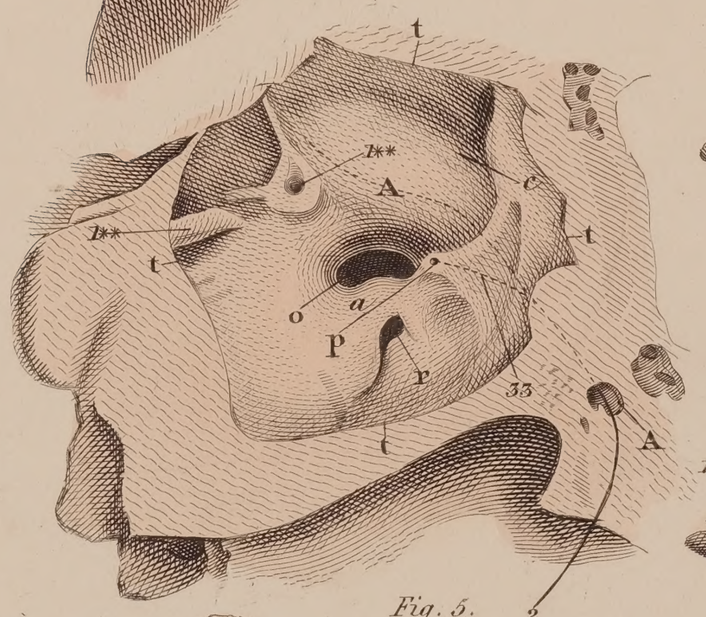

Fig. 5.

Fig. 6.

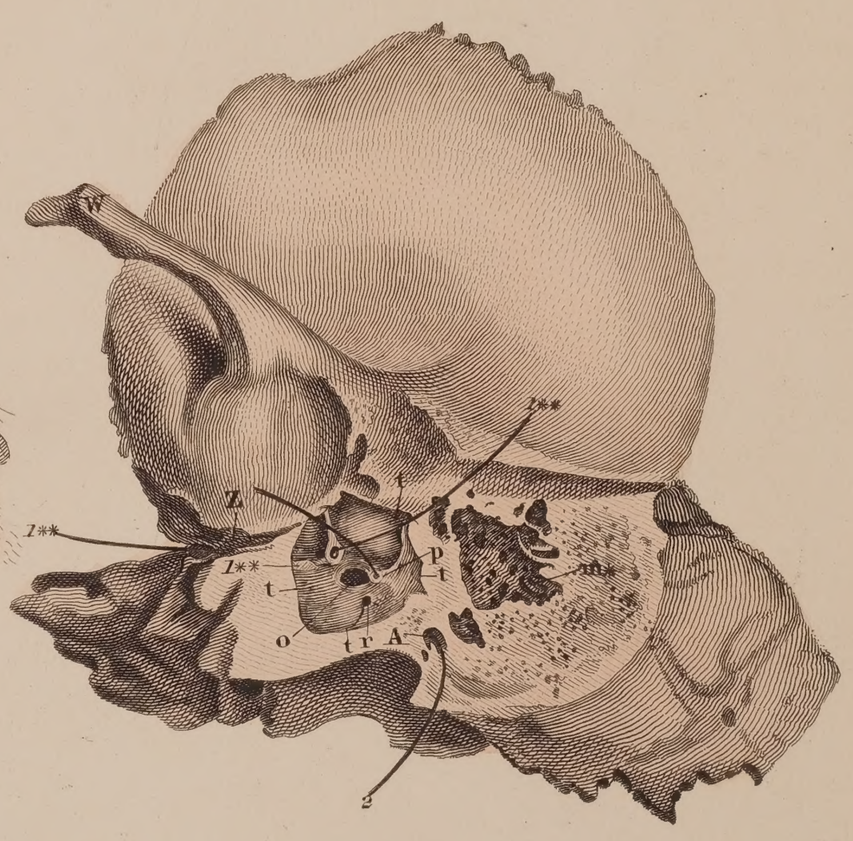

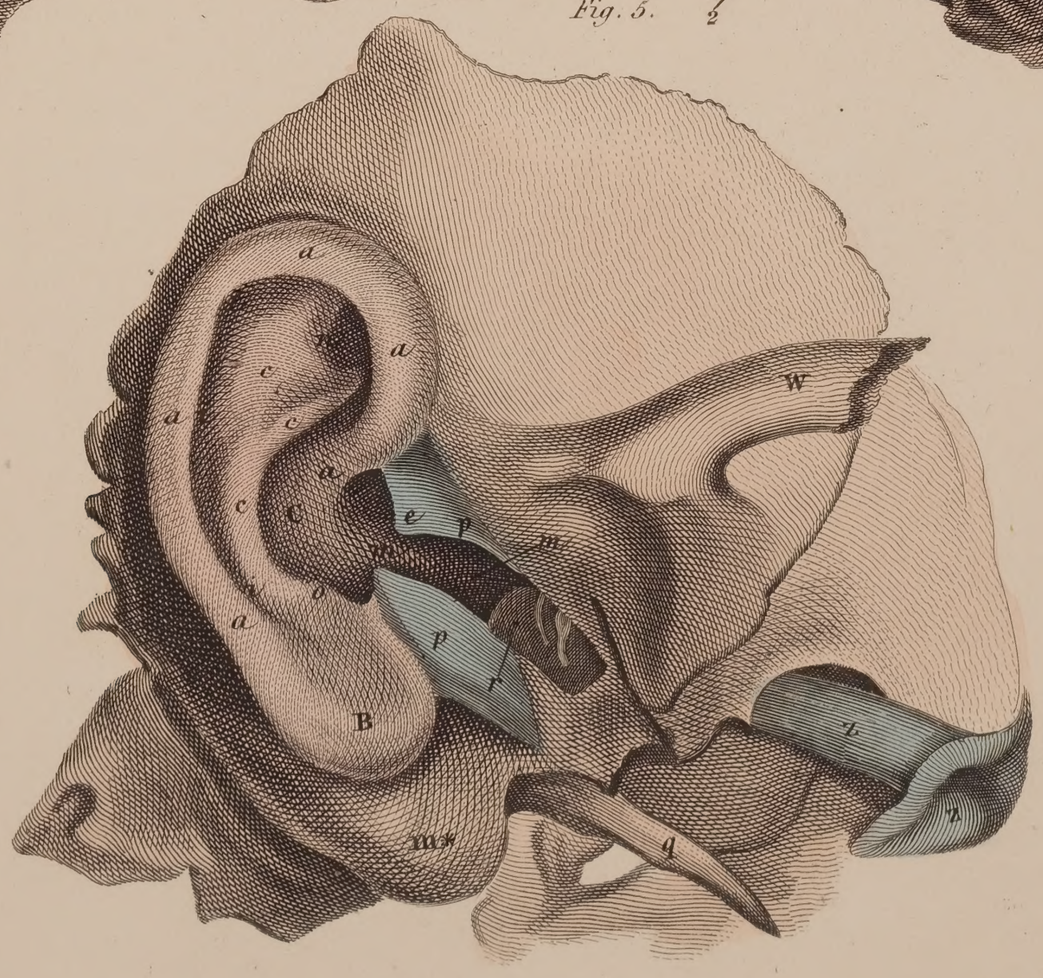

Fig. 9.

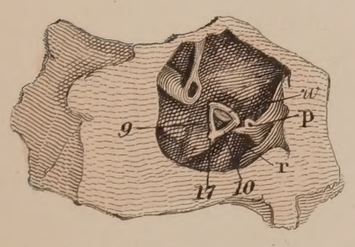

Fig. 8.

Engd. by W.H. Lizars

PLATE LXXVIII.

Fig. 1.

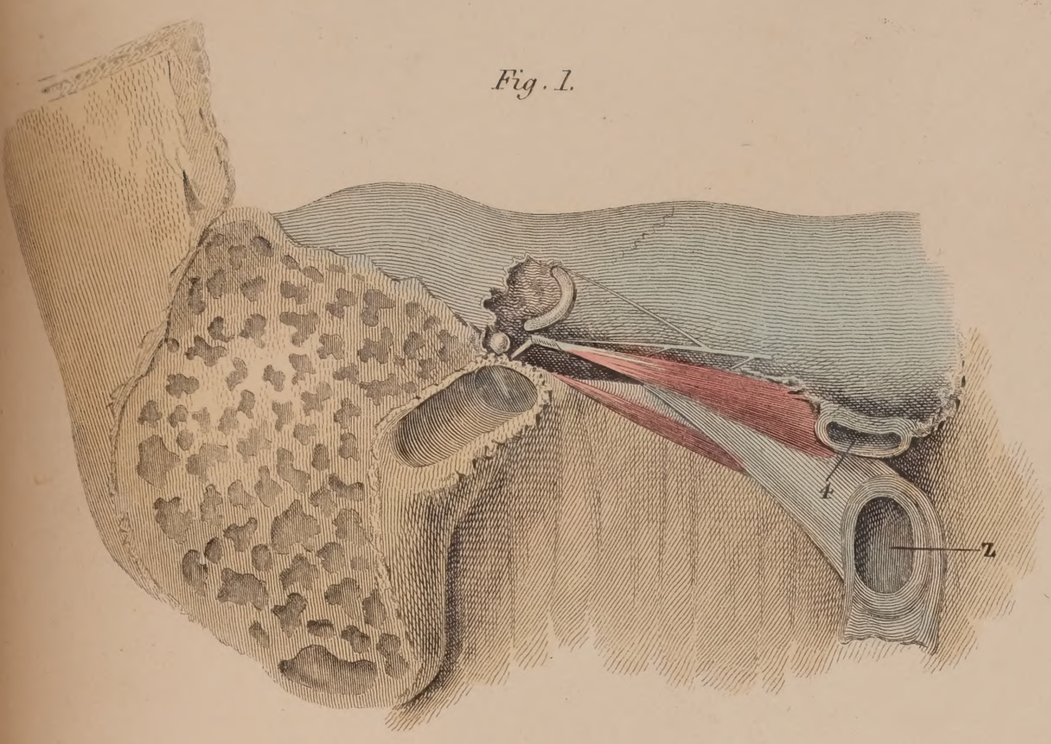

Fig. 3.

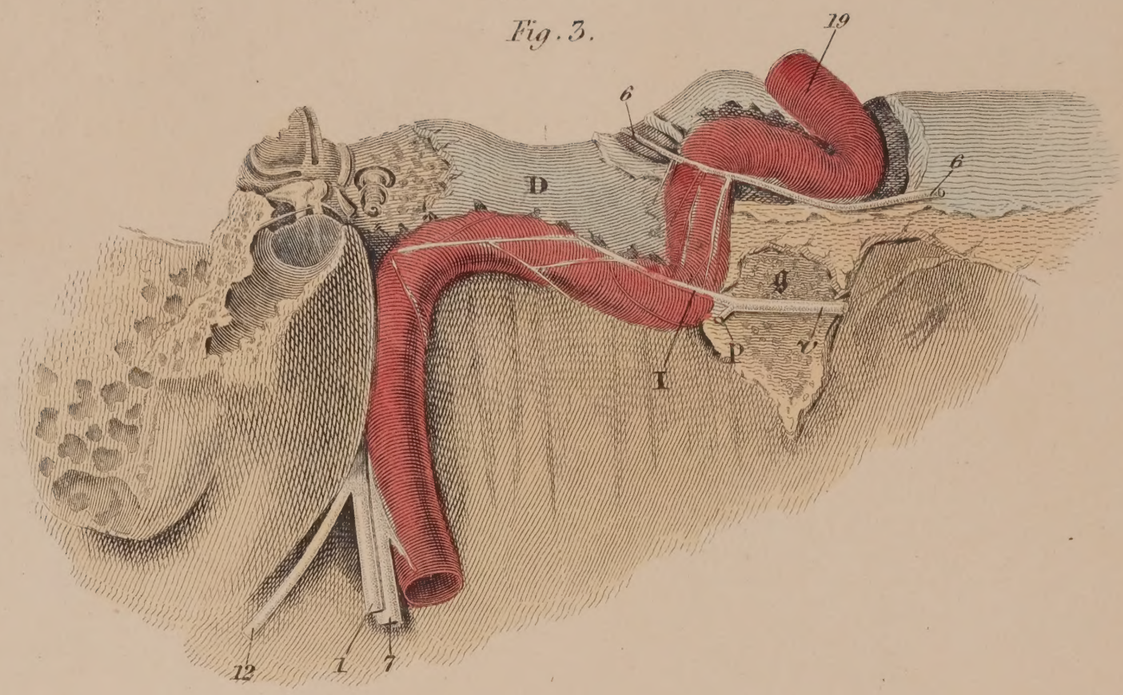

Fig. 14.

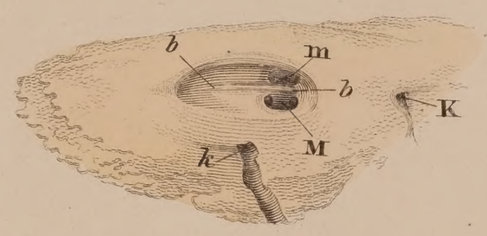

Fig. 4.

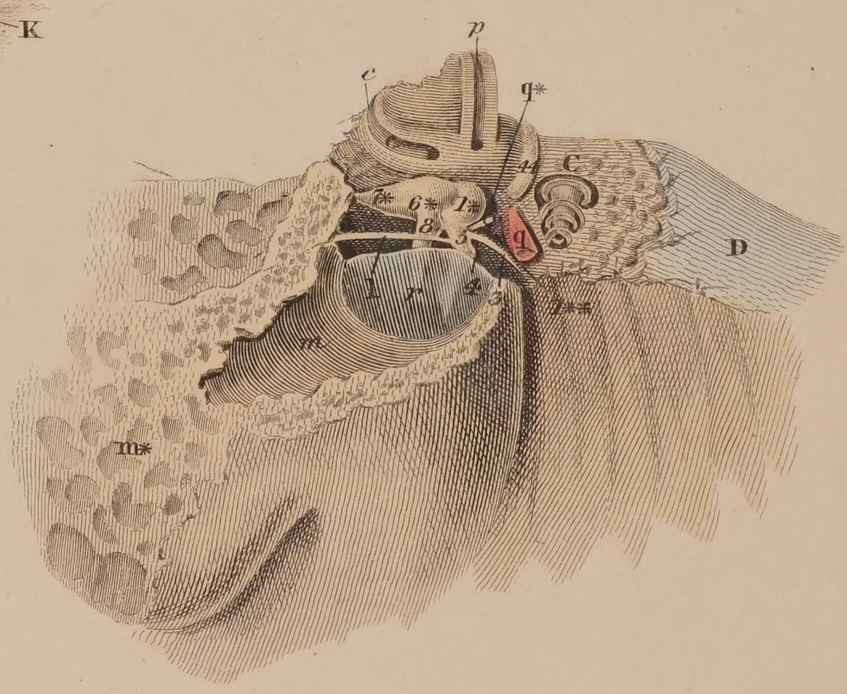

Fig. 2.

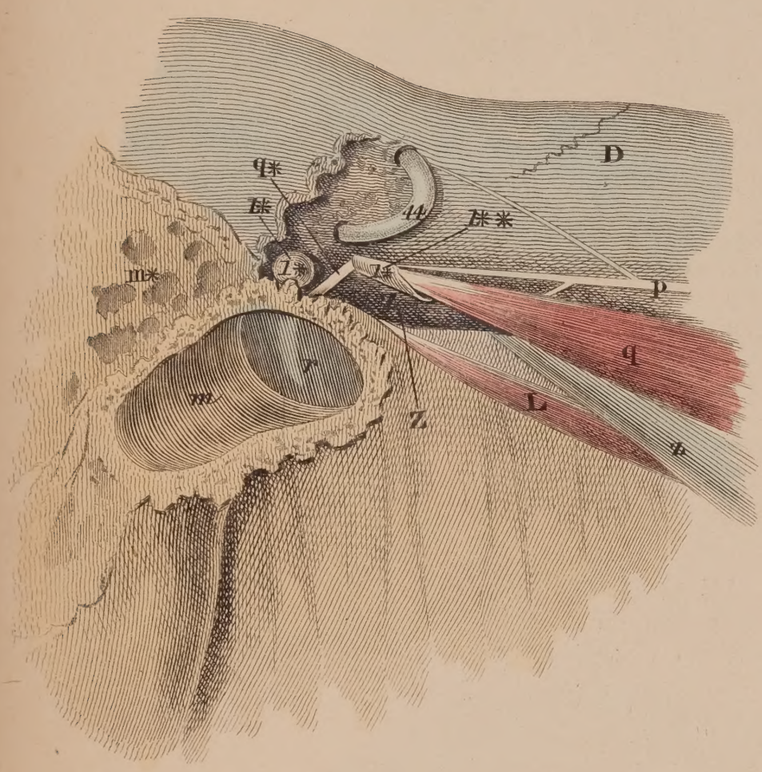

Fig. 11.

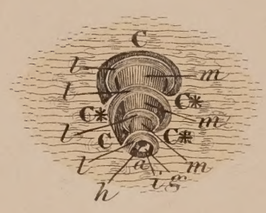

Fig. 13.

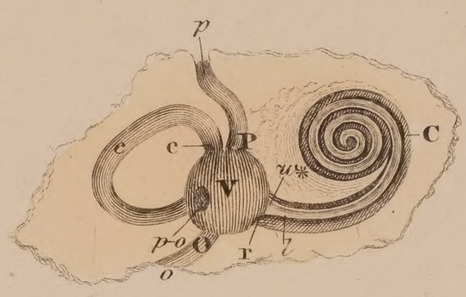

Fig. 7.

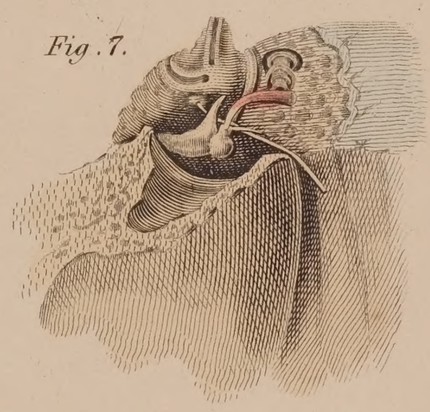

Fig. 9.

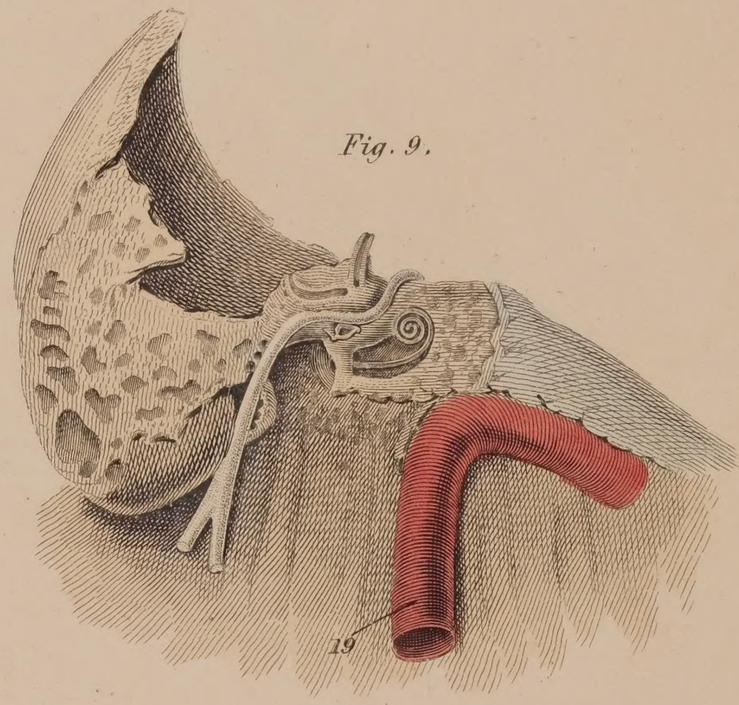

Fig. 5.

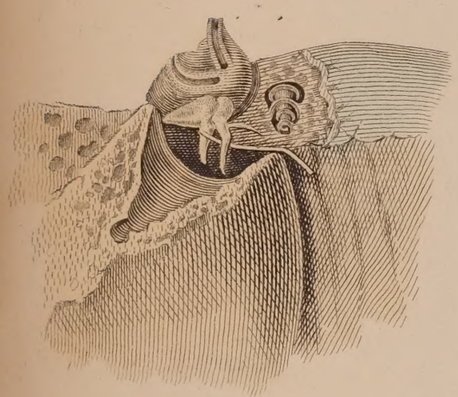

Fig. 8.

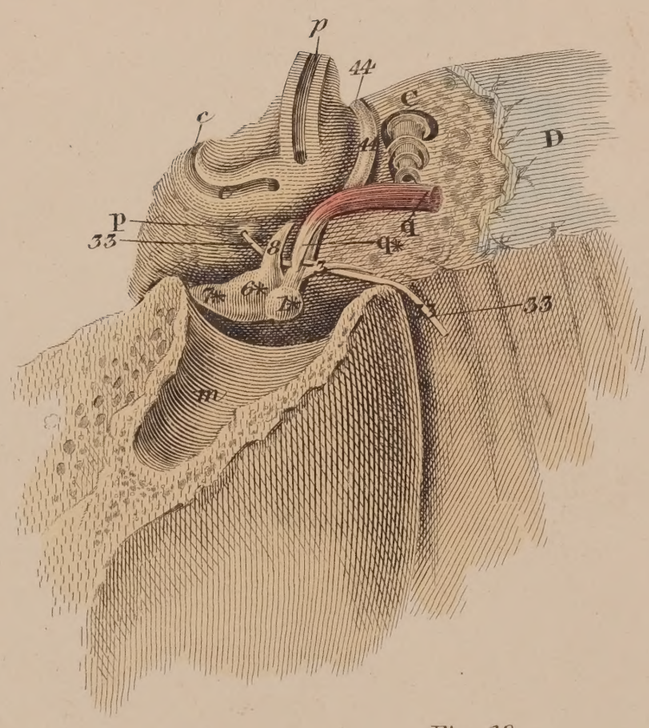

Fig. 6.

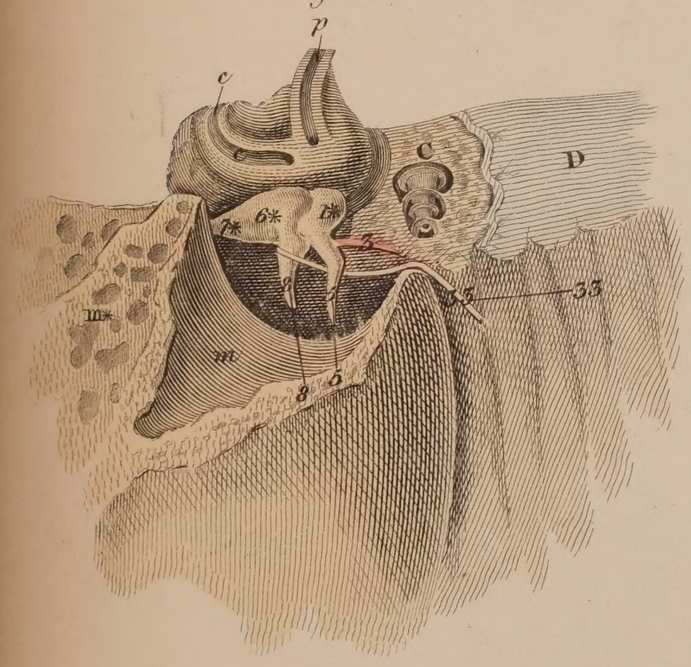

Fig. 10.

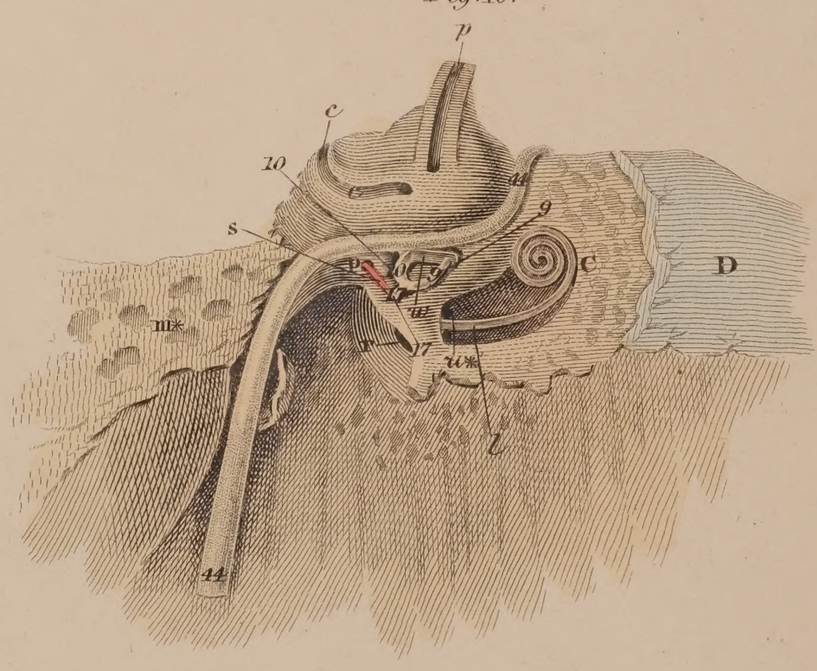

Fig. 12.

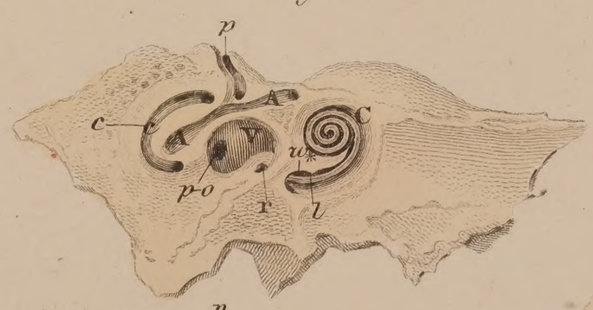

Fig. 16.

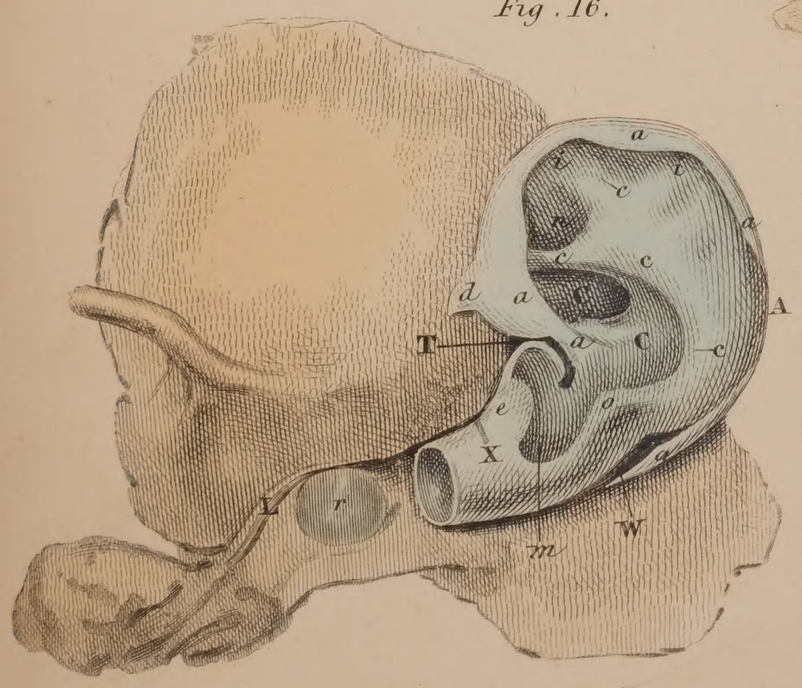

Fig. 17.

Fig. 15.

Engd. by W.H.Lizars.

PLATE LXXIX.

Fig. 3.

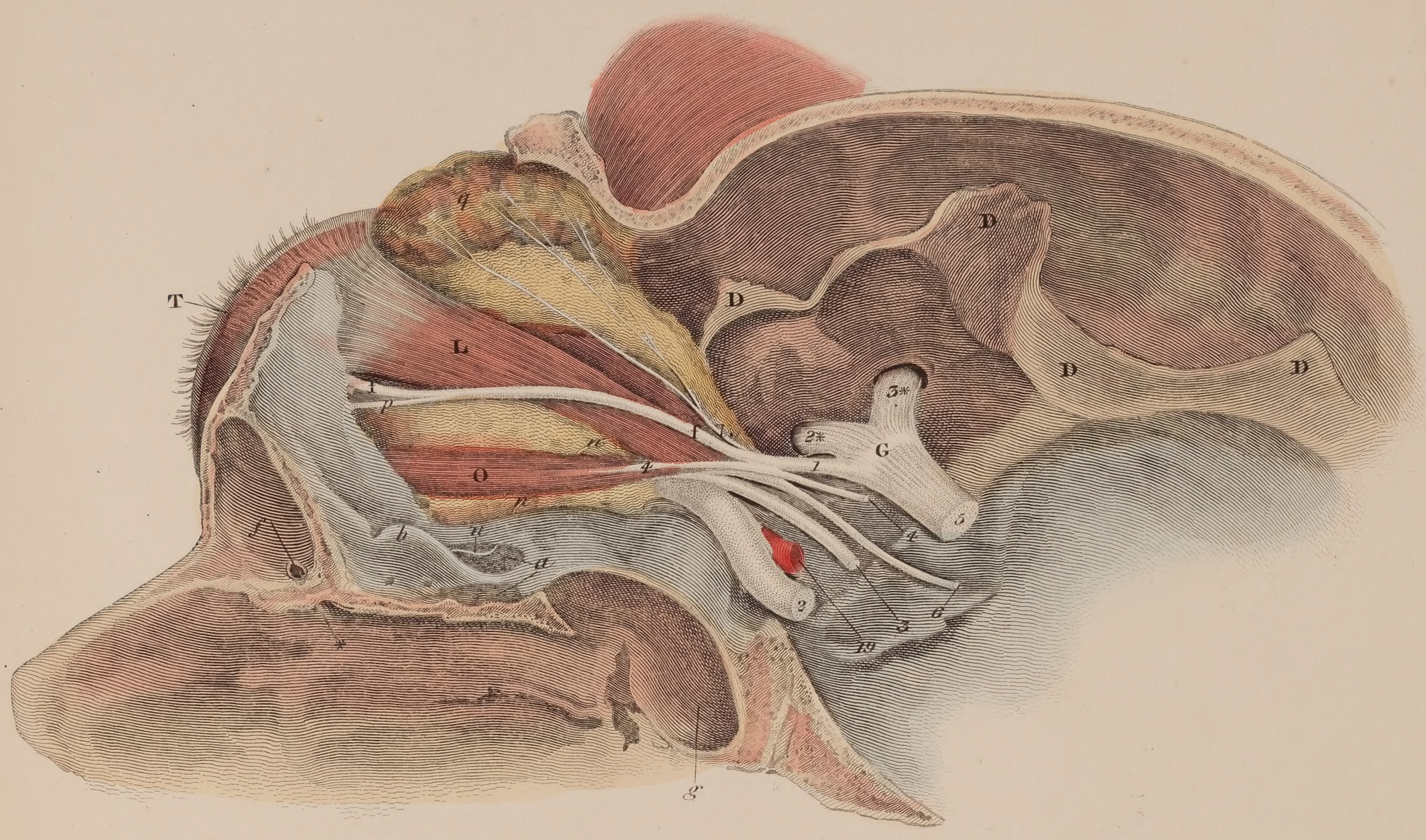

Fig. 1.

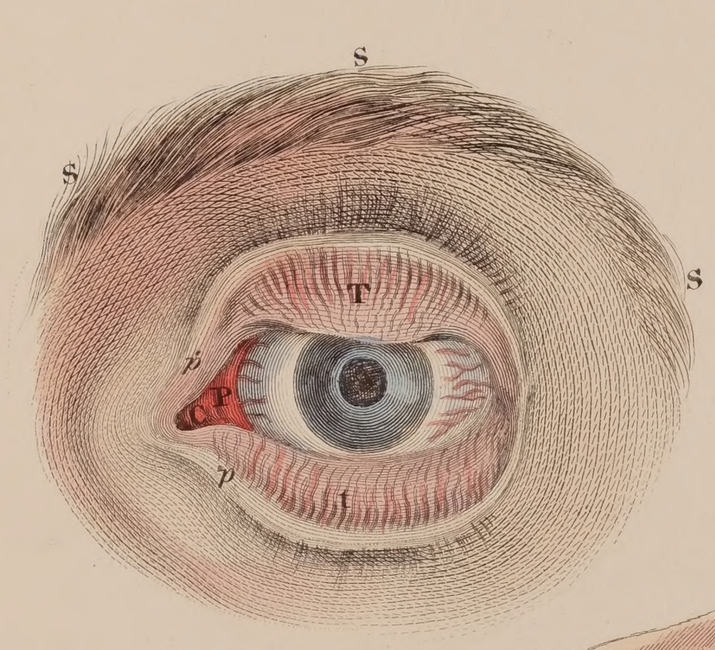

Fig. 2.

Fig. 4.

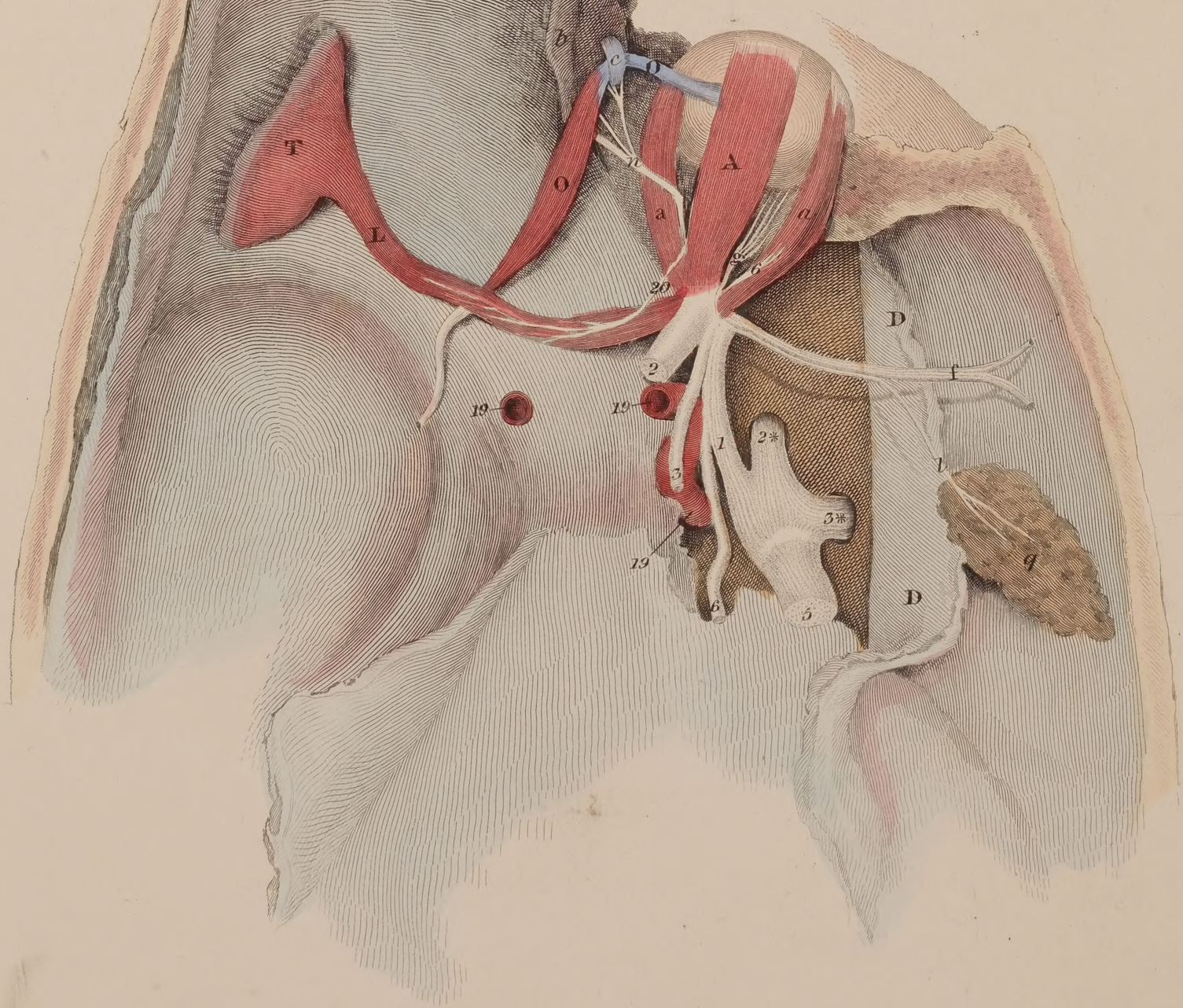

Eng.d by W.H. Lizars.

PLATE LXXX.

Fig. 2.

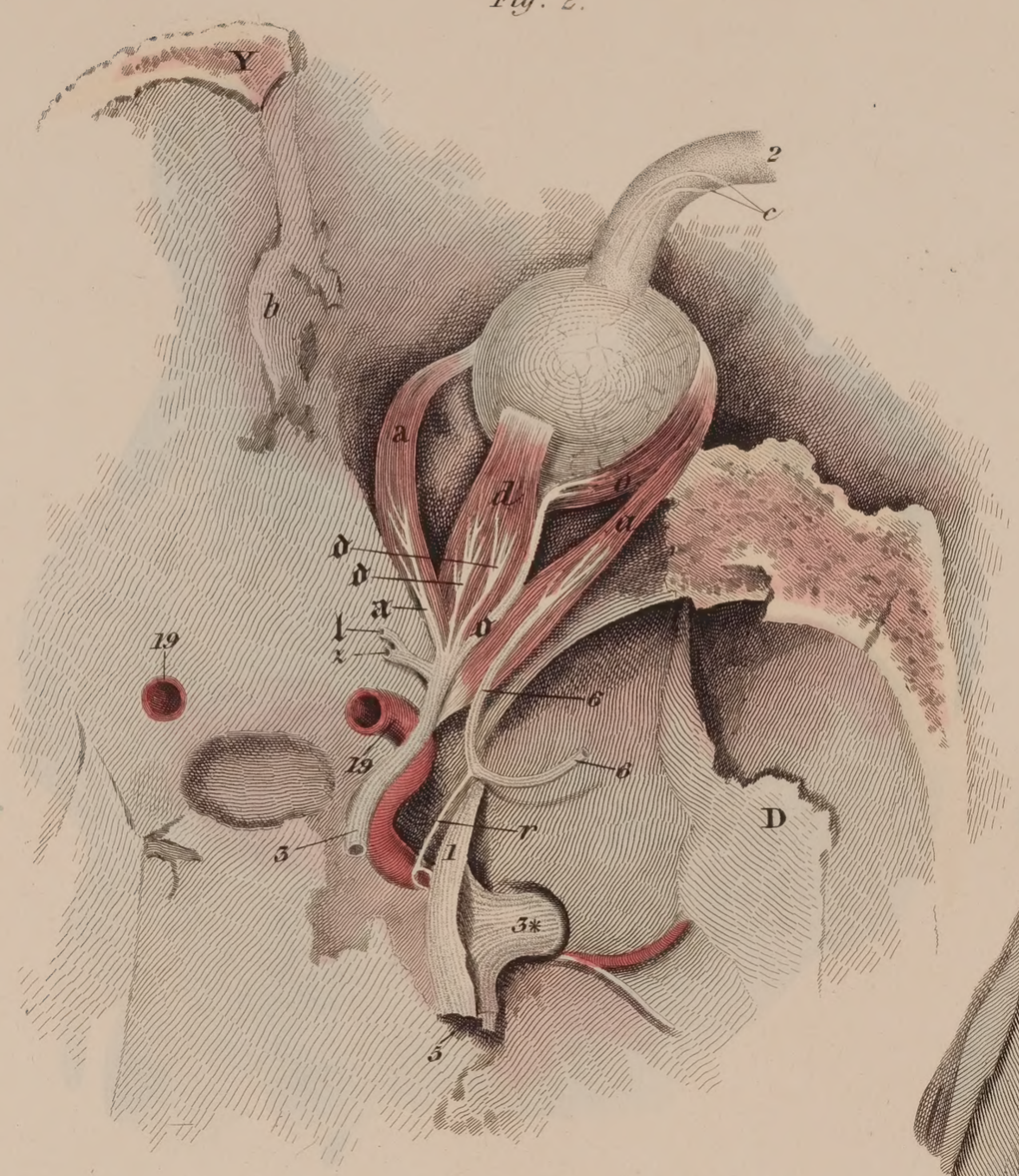

Fig. 3.

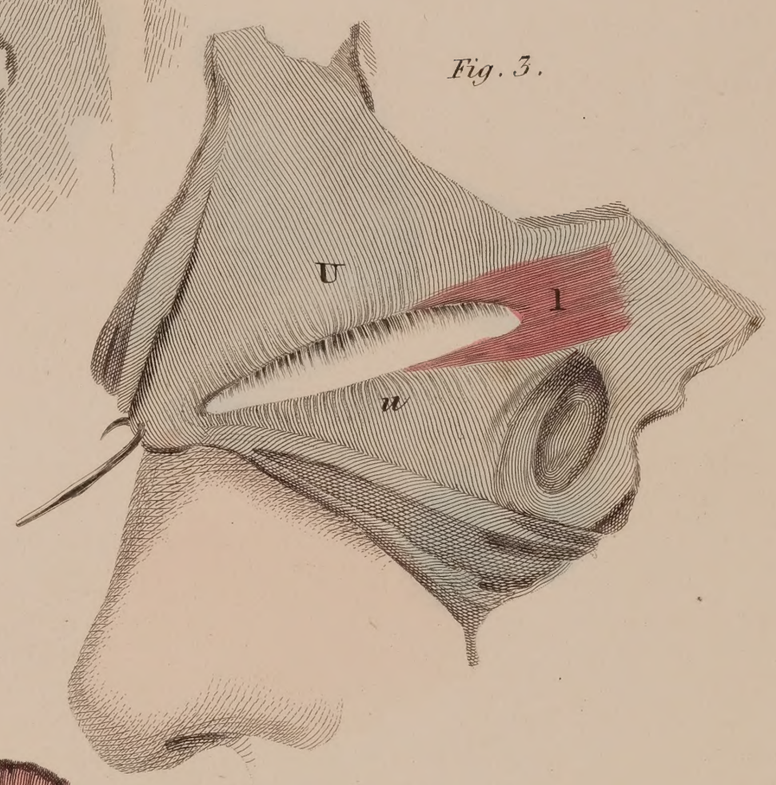

Fig. 1.

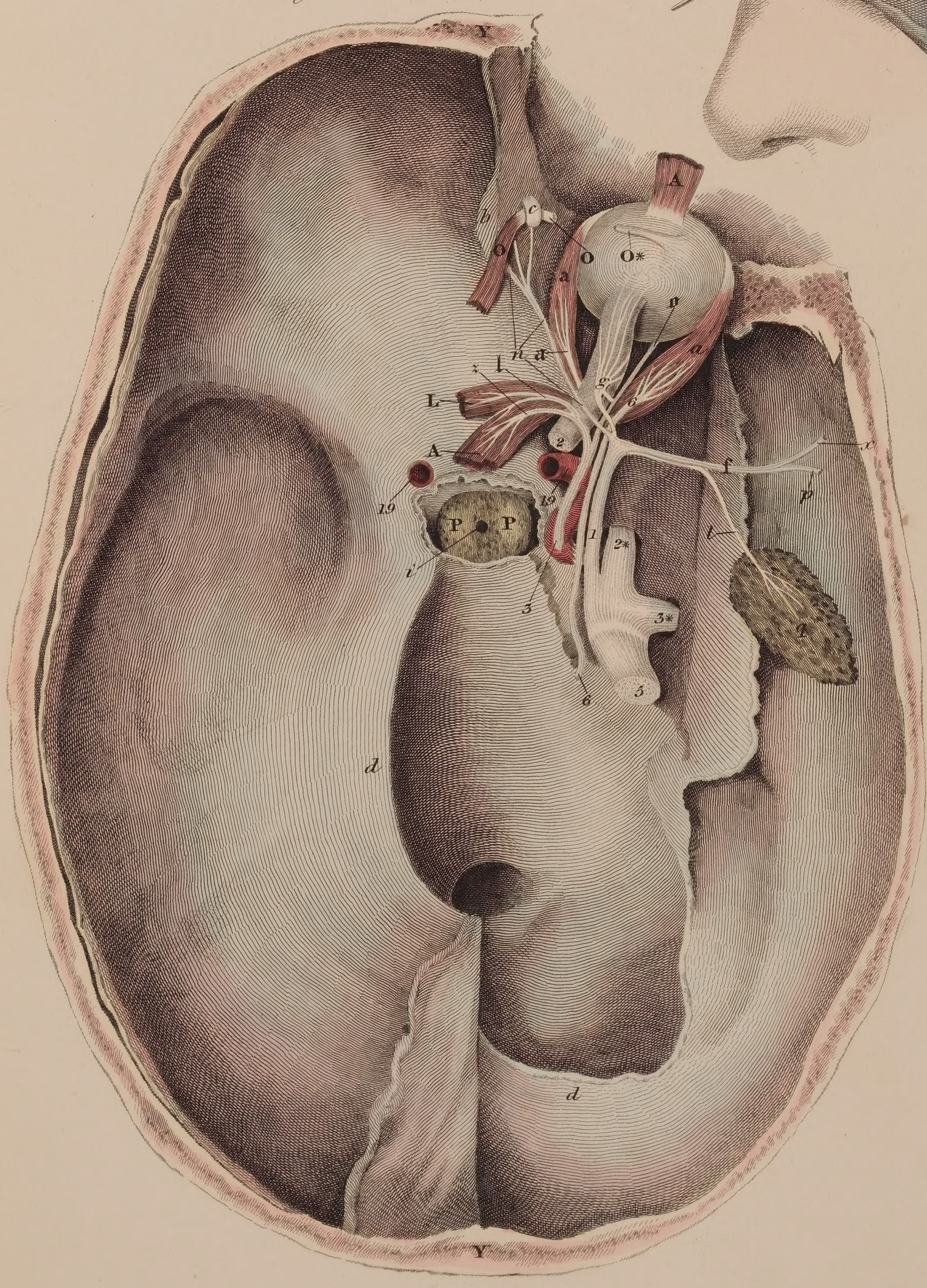

Engraved by W.H. Lizars

PLATE LXXXI.

Fig. 11.

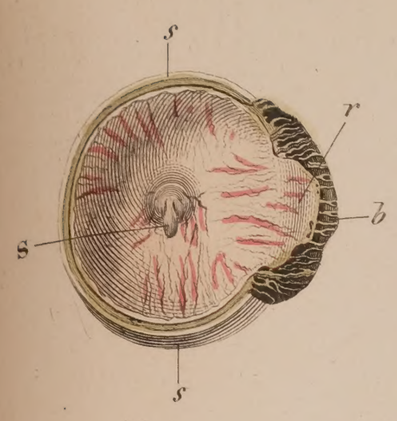

Fig. 10.

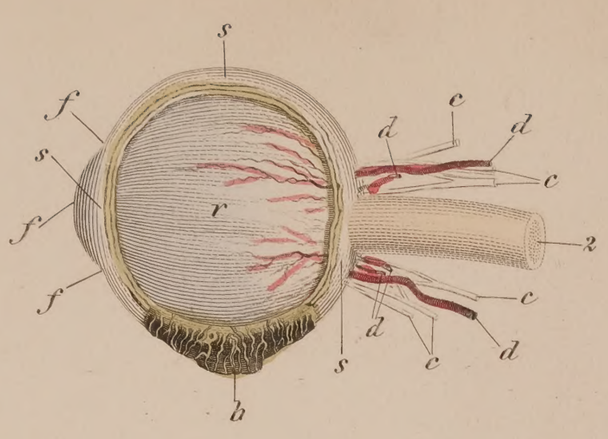

Fig. 8.

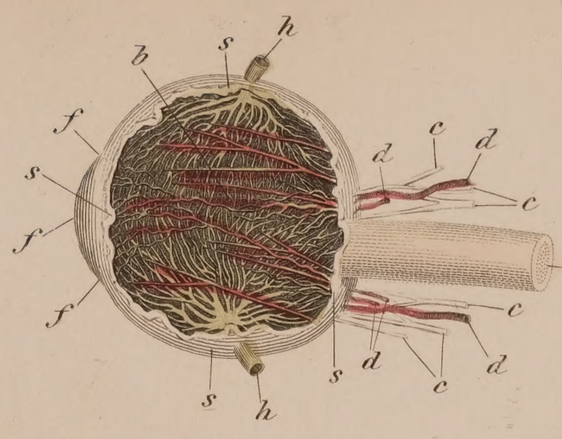

Fig. 1.

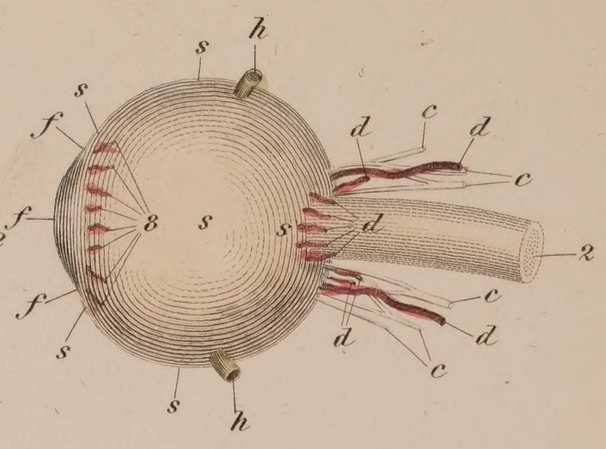

Fig. 6.

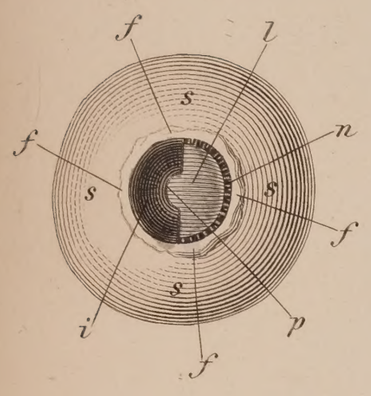

Fig. 7.

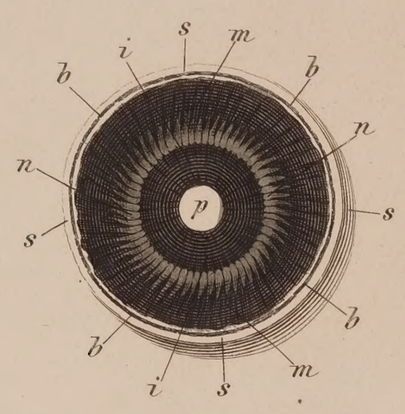

Fig. 9.



Fig. 12.



Fig. 4.

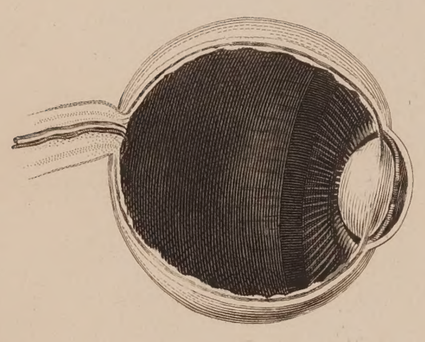

Fig. 14.

Fig. 13.

Fig. 2.

Fig. 5.

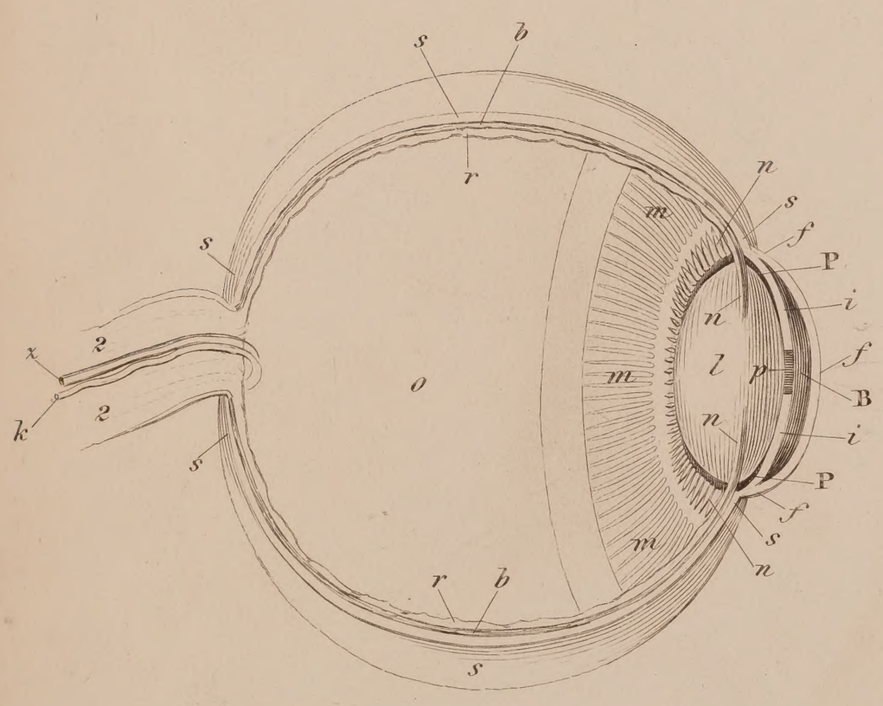

Fig. 3.

Fig. 16.

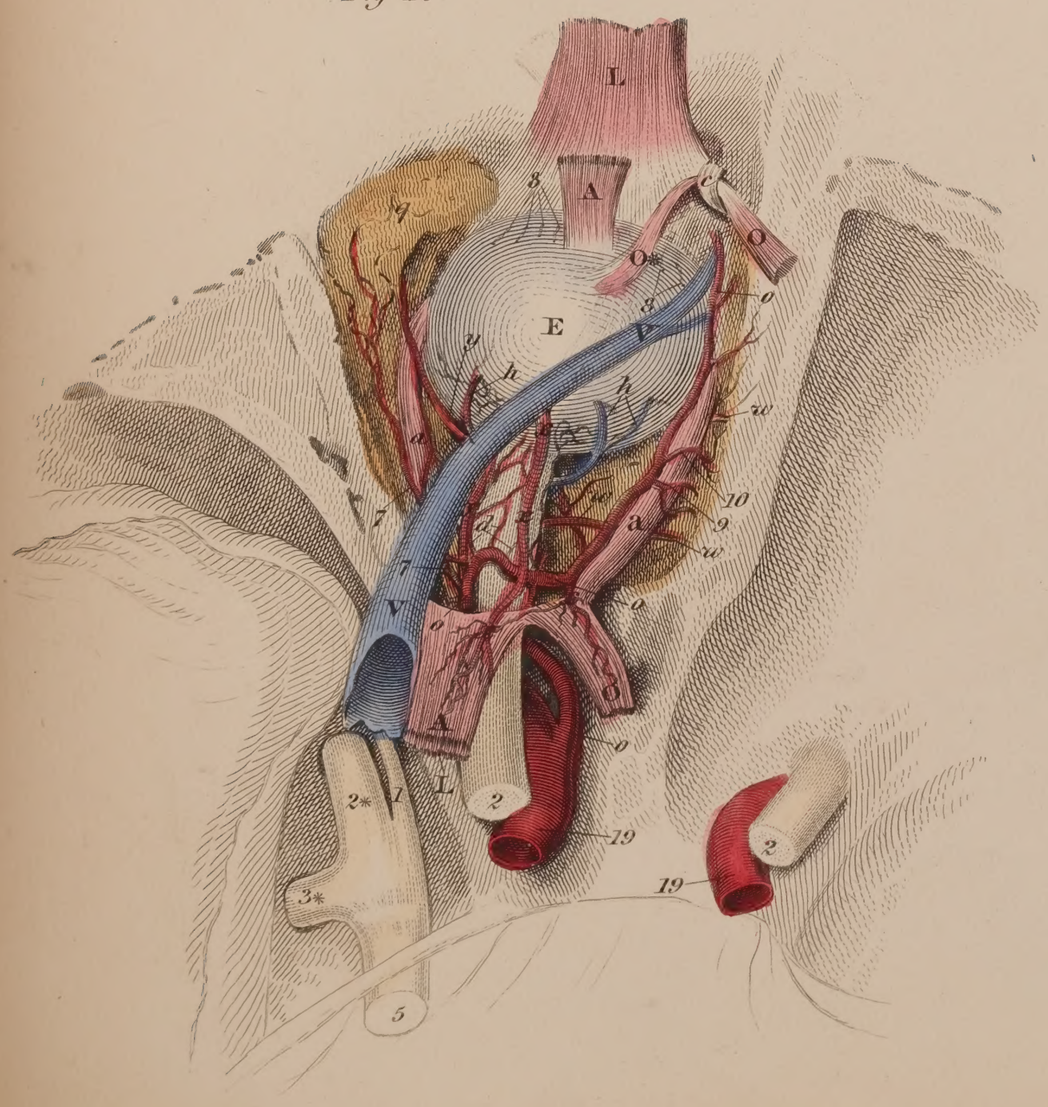

Fig. 15.

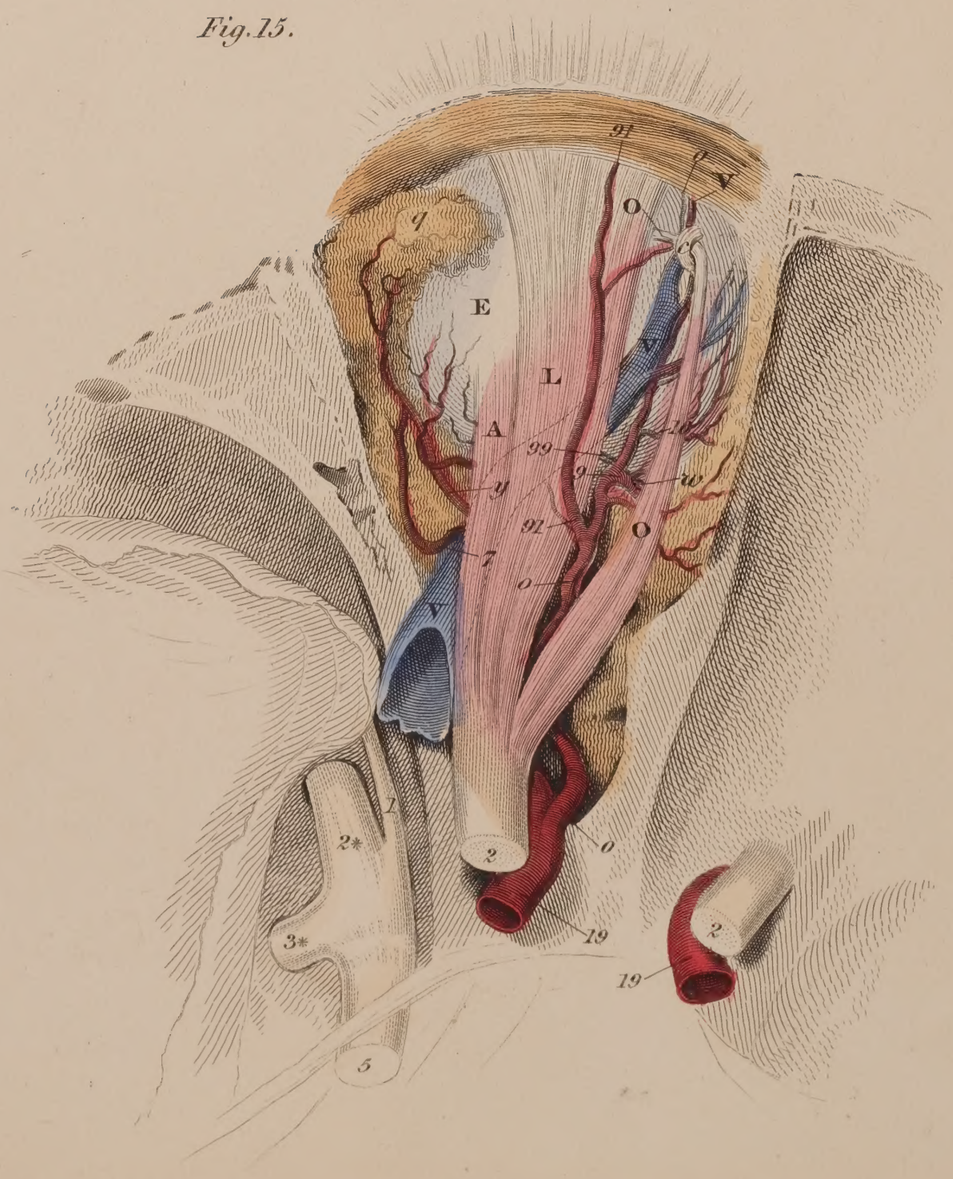

Engd. by W.H. Lizars

PLATE LXXXII.

Fig. 3.

Fig. 1.

Fig. 4.

Fig. 2.

Engd by W.H.Lizars.

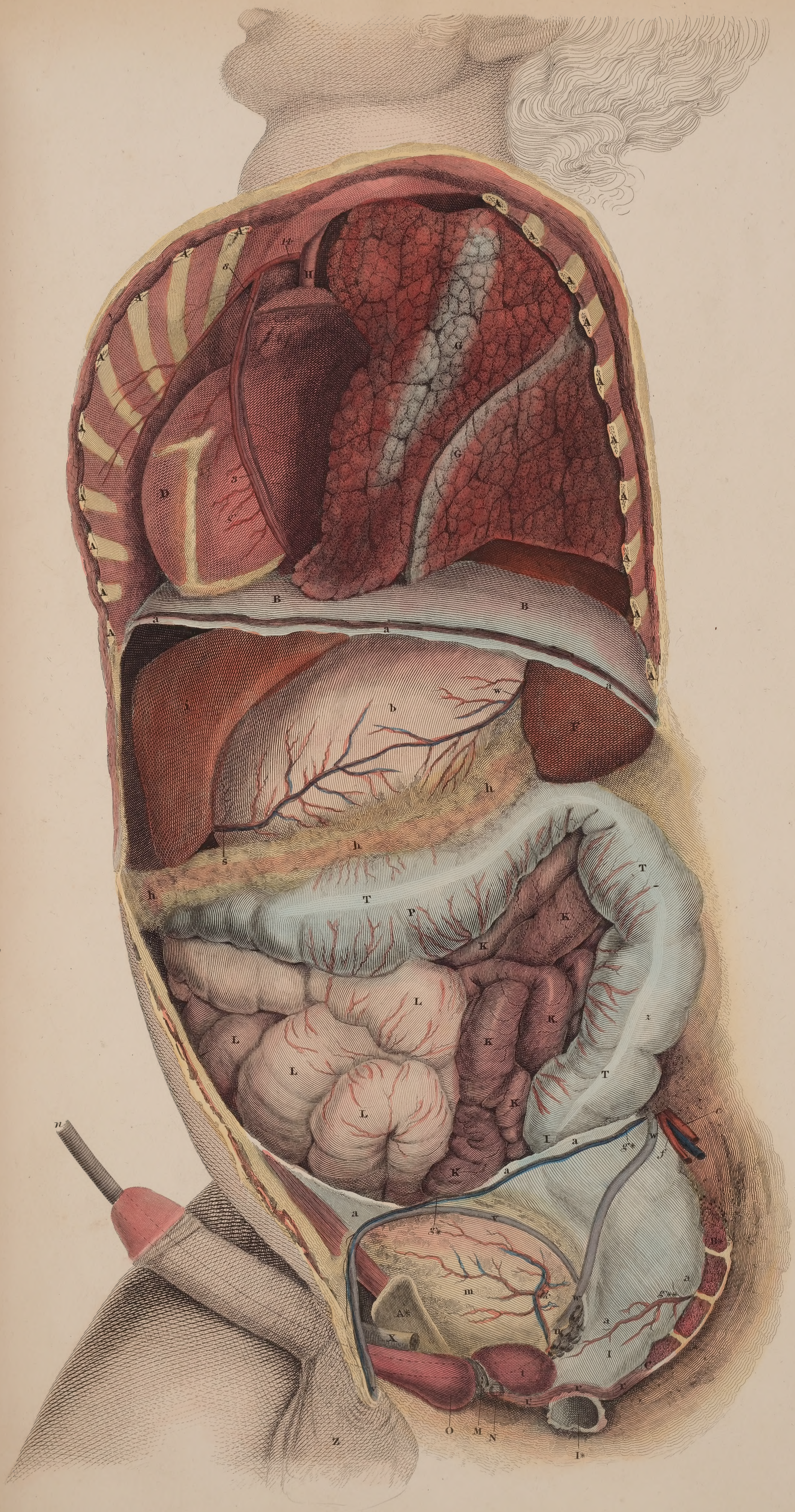

Engd. by W.H.Lizars.

PLATE LXXXIV.

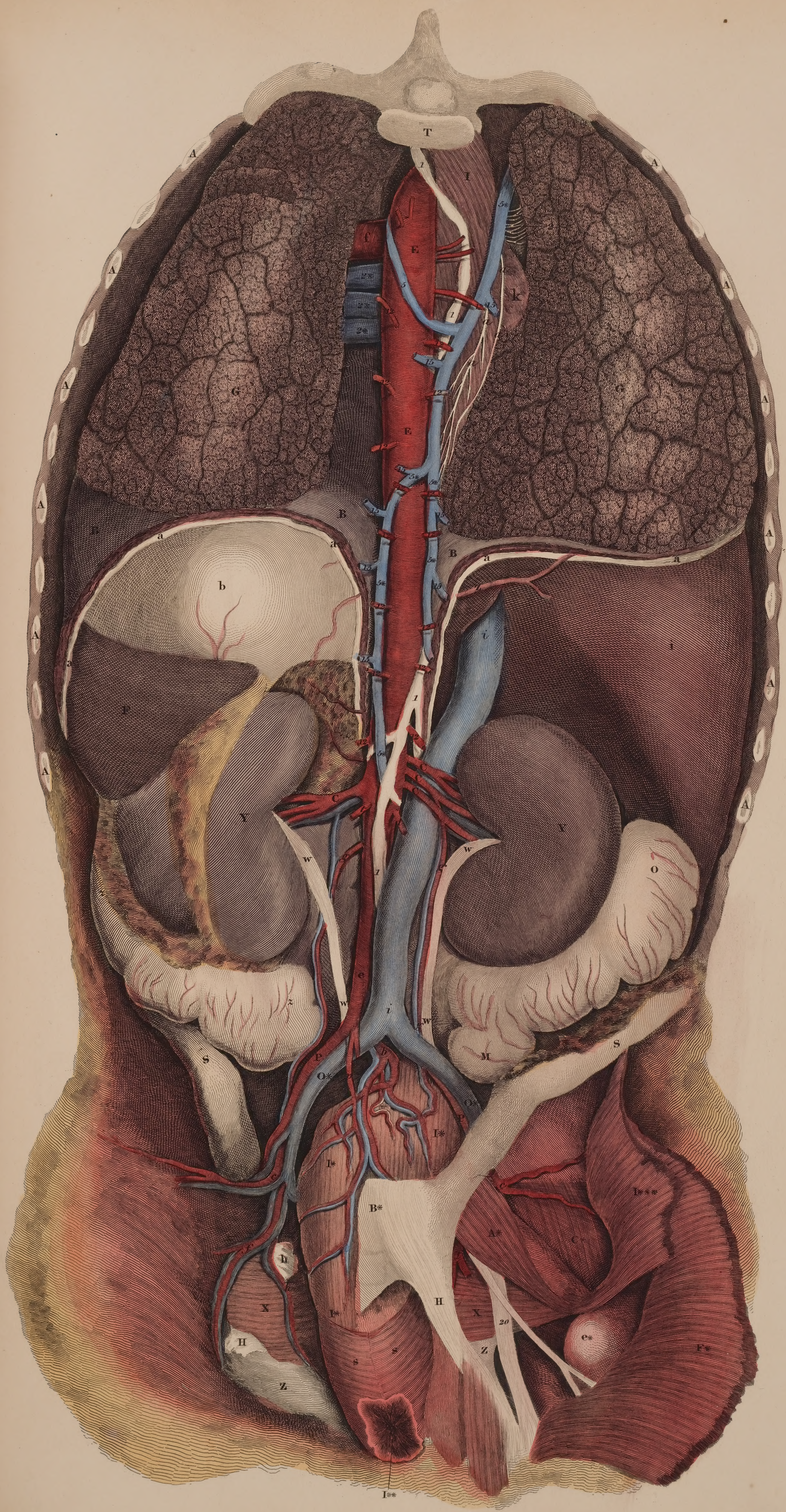

Engraved by W. H. Lizars.

Fig. 2.

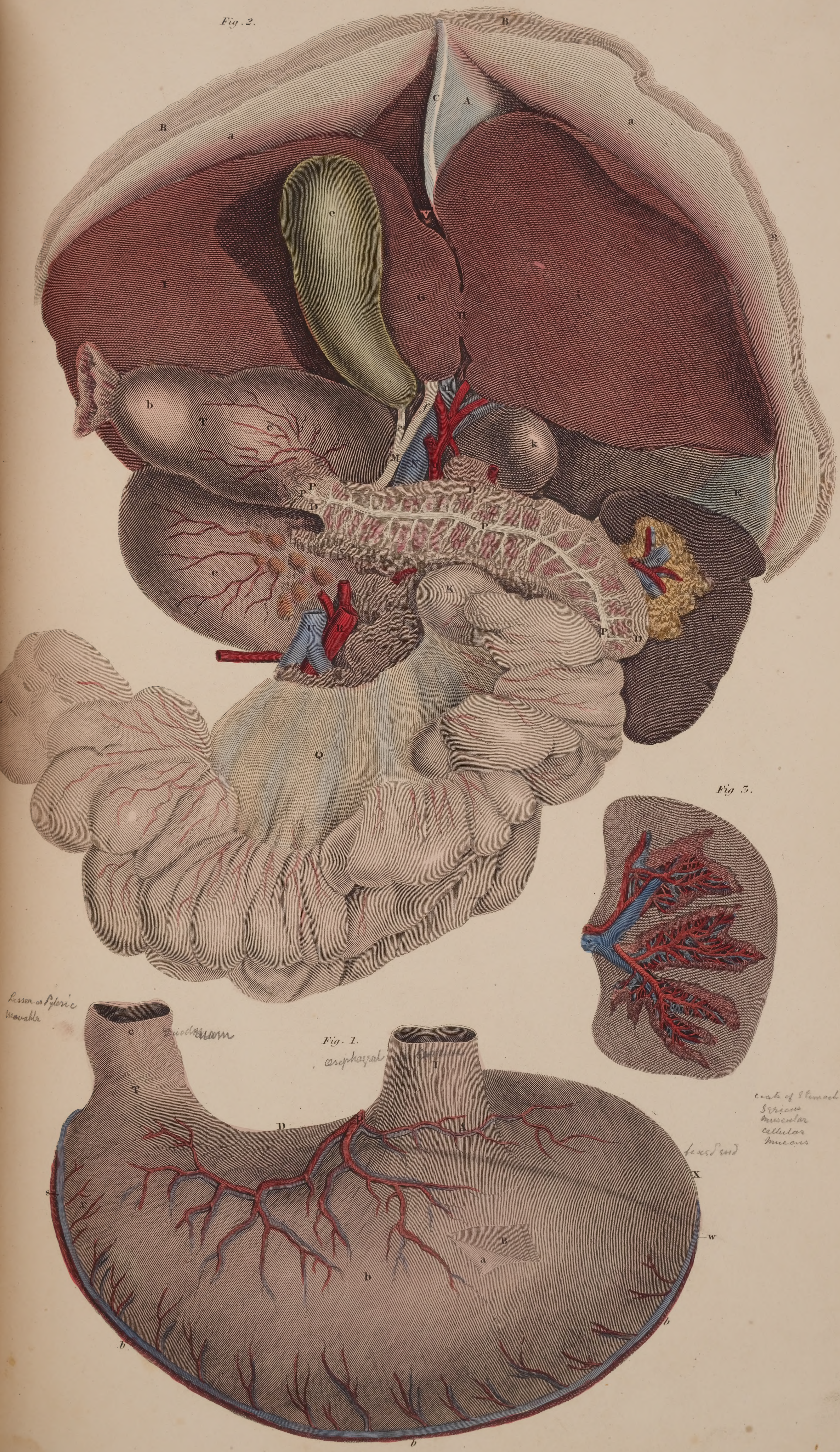

Fig. 3.

Fig. 1.
oesophagal or Cardiac

coats of Stomach
Serious
Muscular
Cellular
Mucous

fixed end

PLATE LXXXVI.

Fig. 2.

Fig. 1.

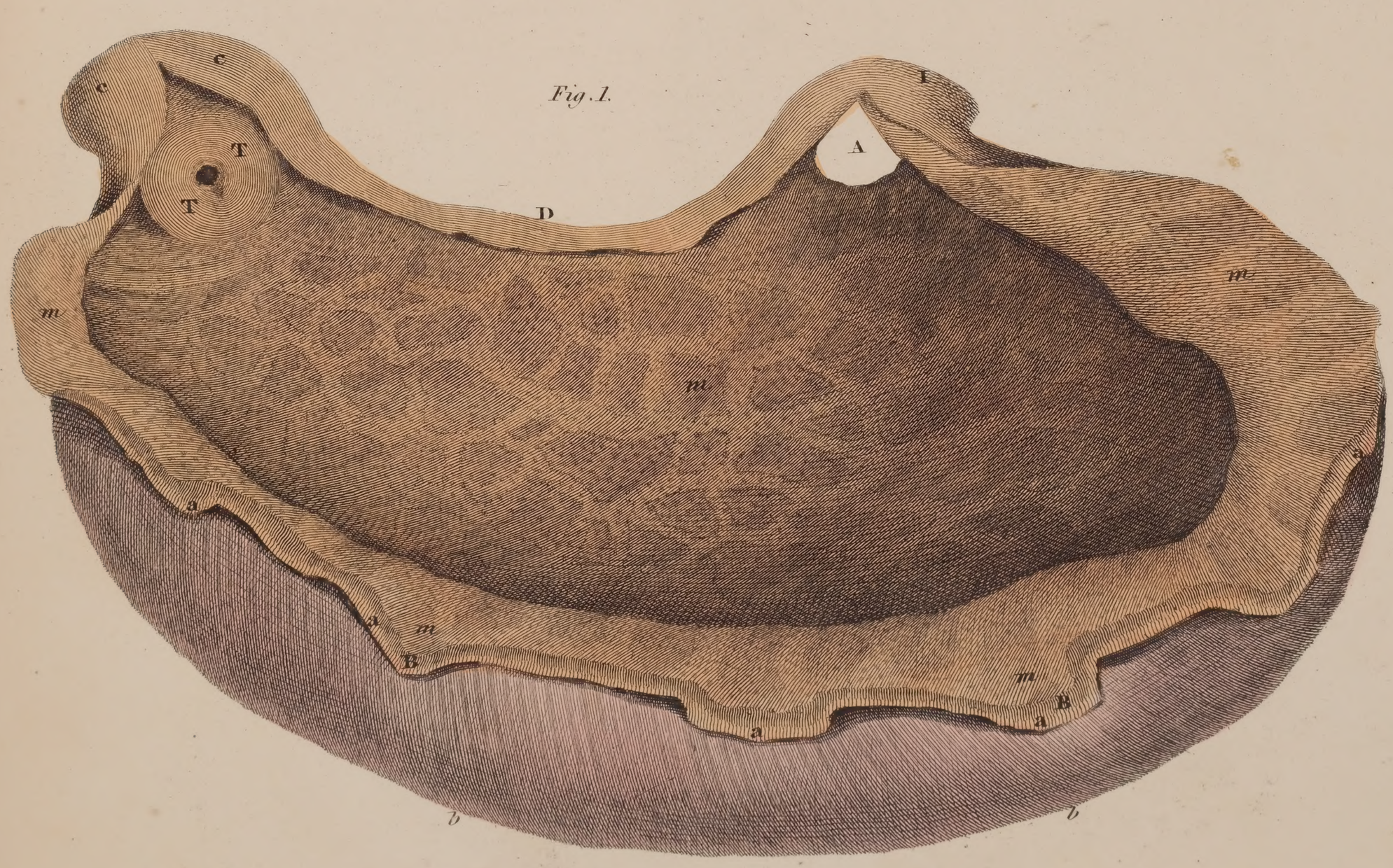

Engd by W.H.Lizars

PLATE LXXXVII.

Engd by W.H.Lizars

PLATE LXXXVIII.

Fig. 2.

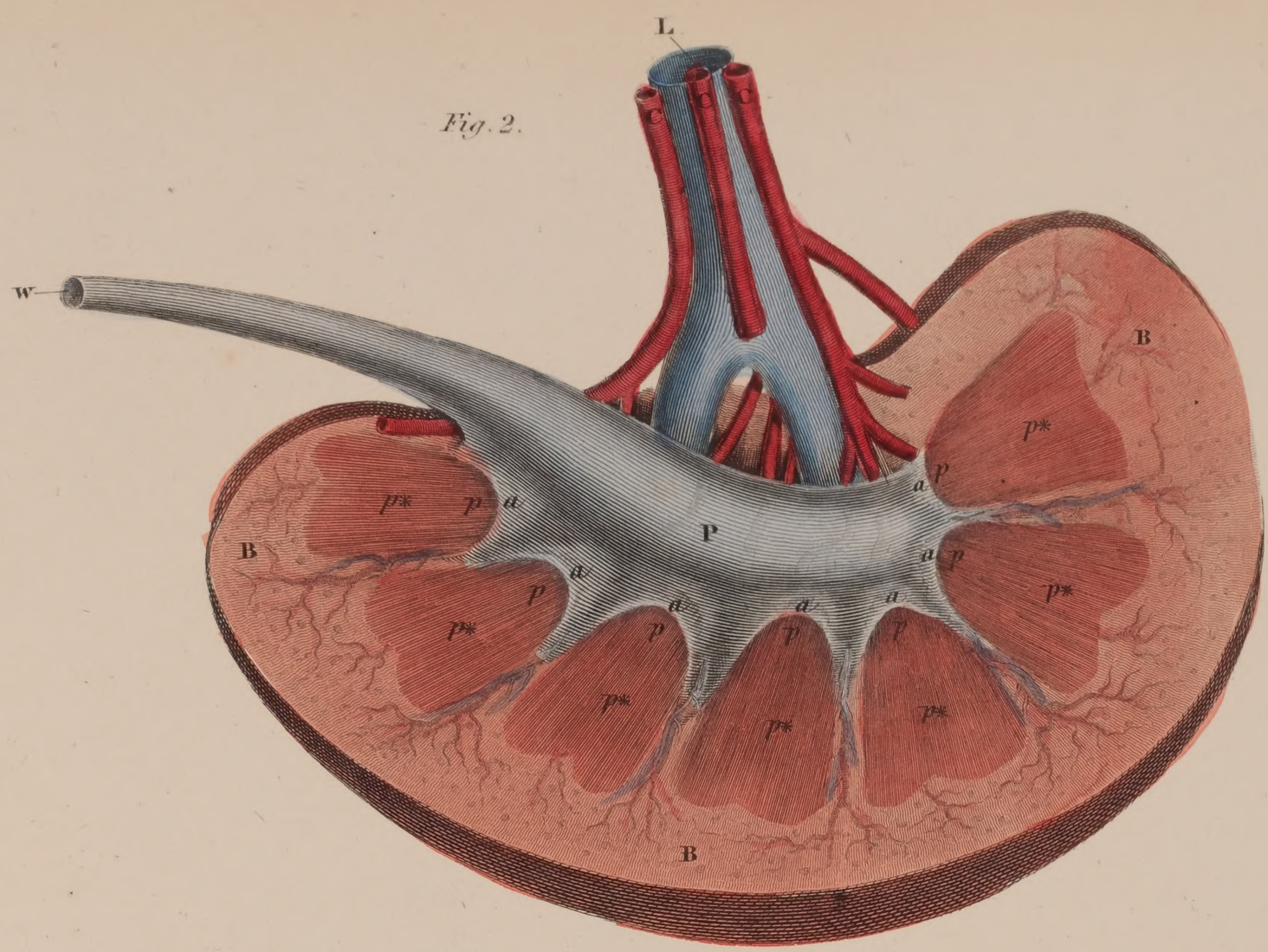

Fig. 3.

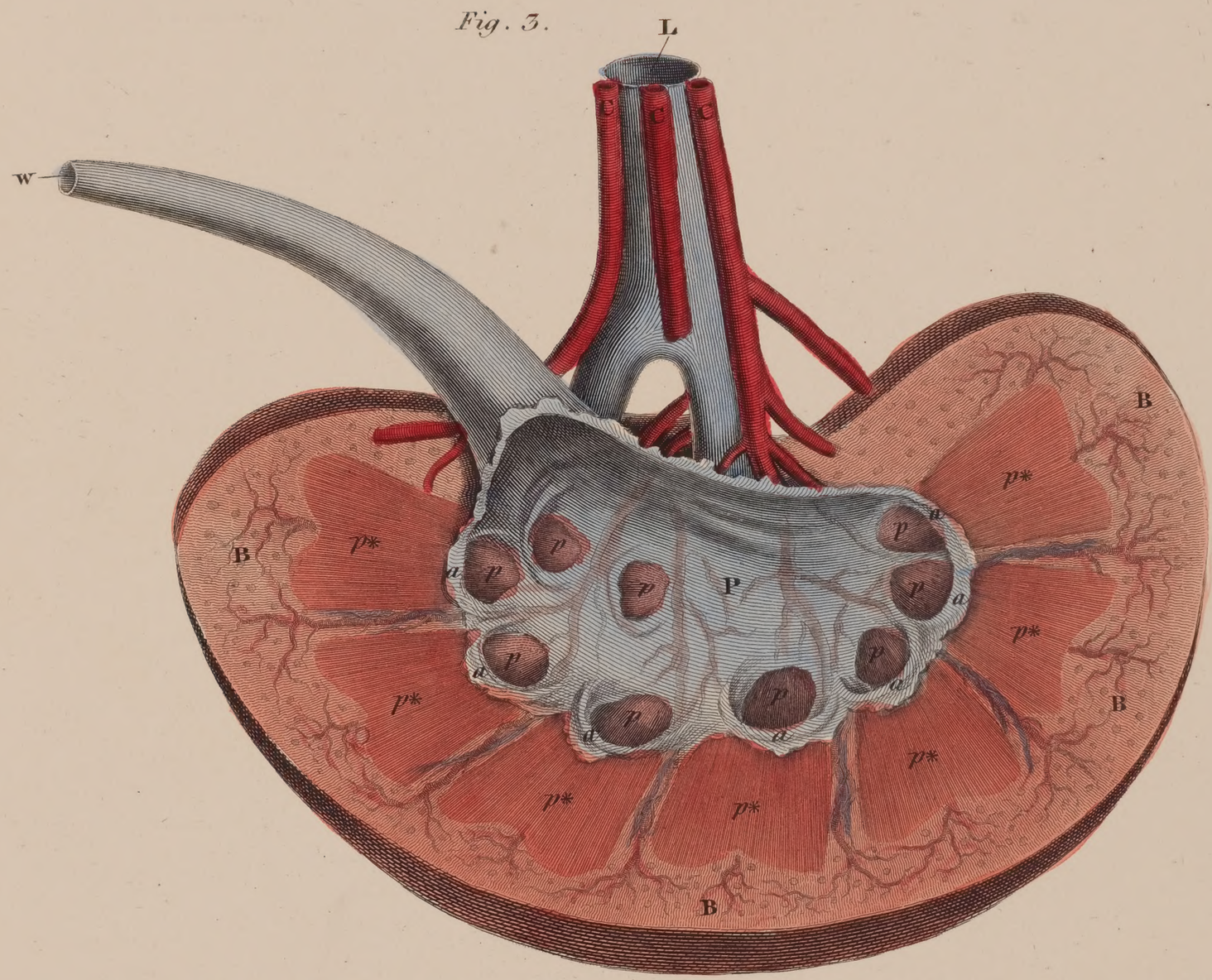

Fig. 1.

Engd. by W.H. Lizars

PLATE LXXXIX.

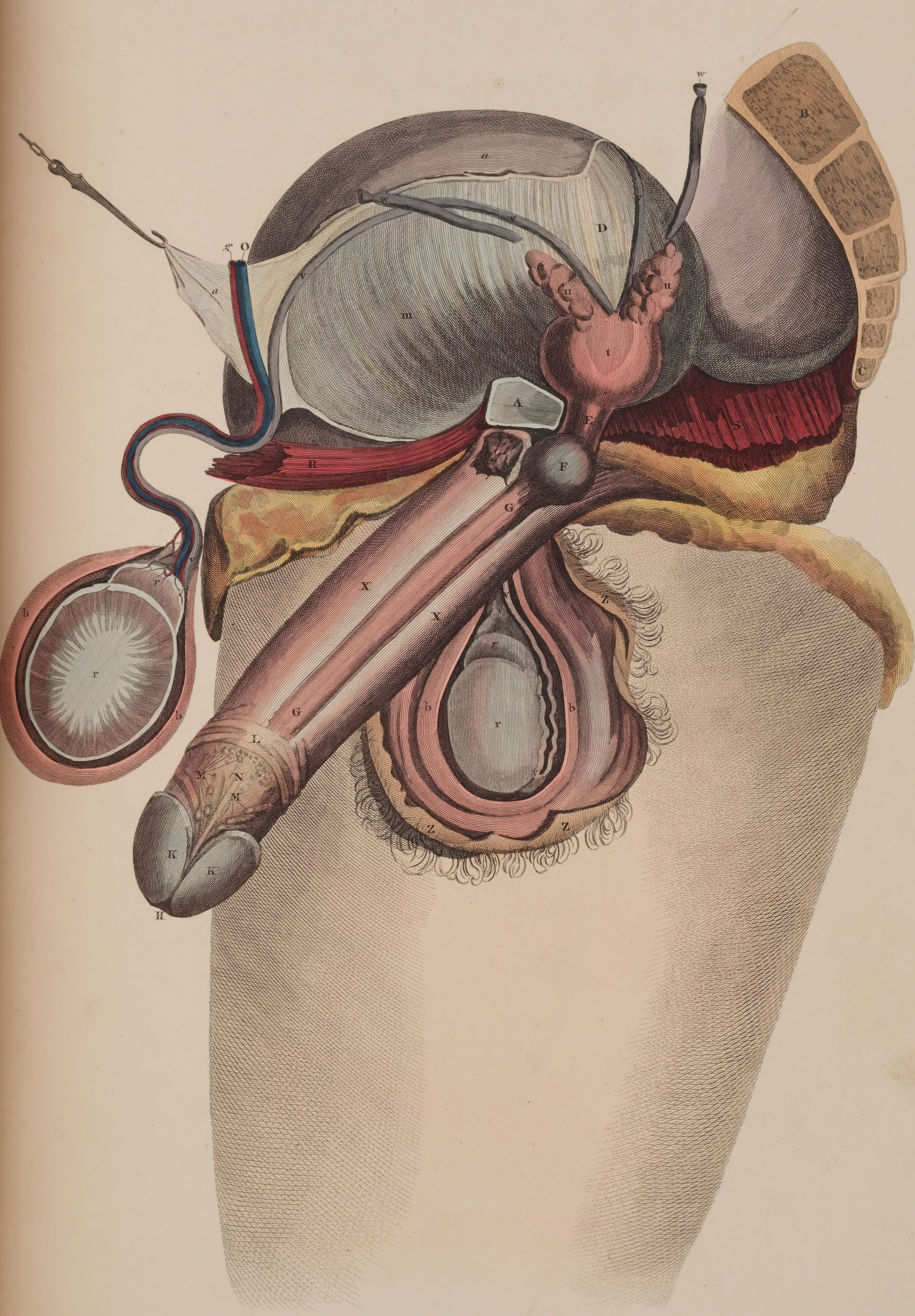

Engd. by W.H.Lizars

PLATE XC.

Engd. by W. H. Lizars

Engd by W. H. Lizars

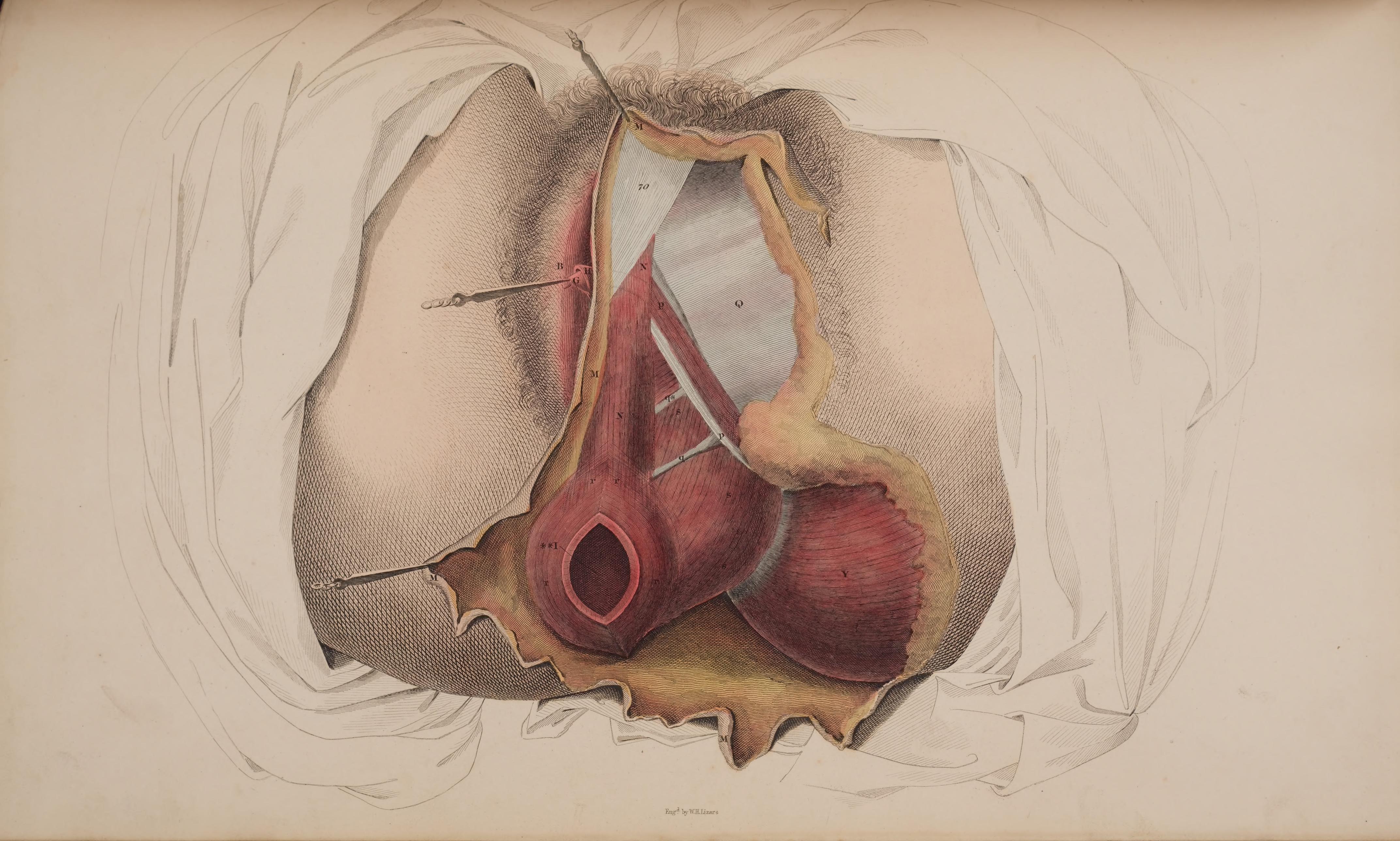

Eng^d by W.H. Lizars

PLATE XCIII.

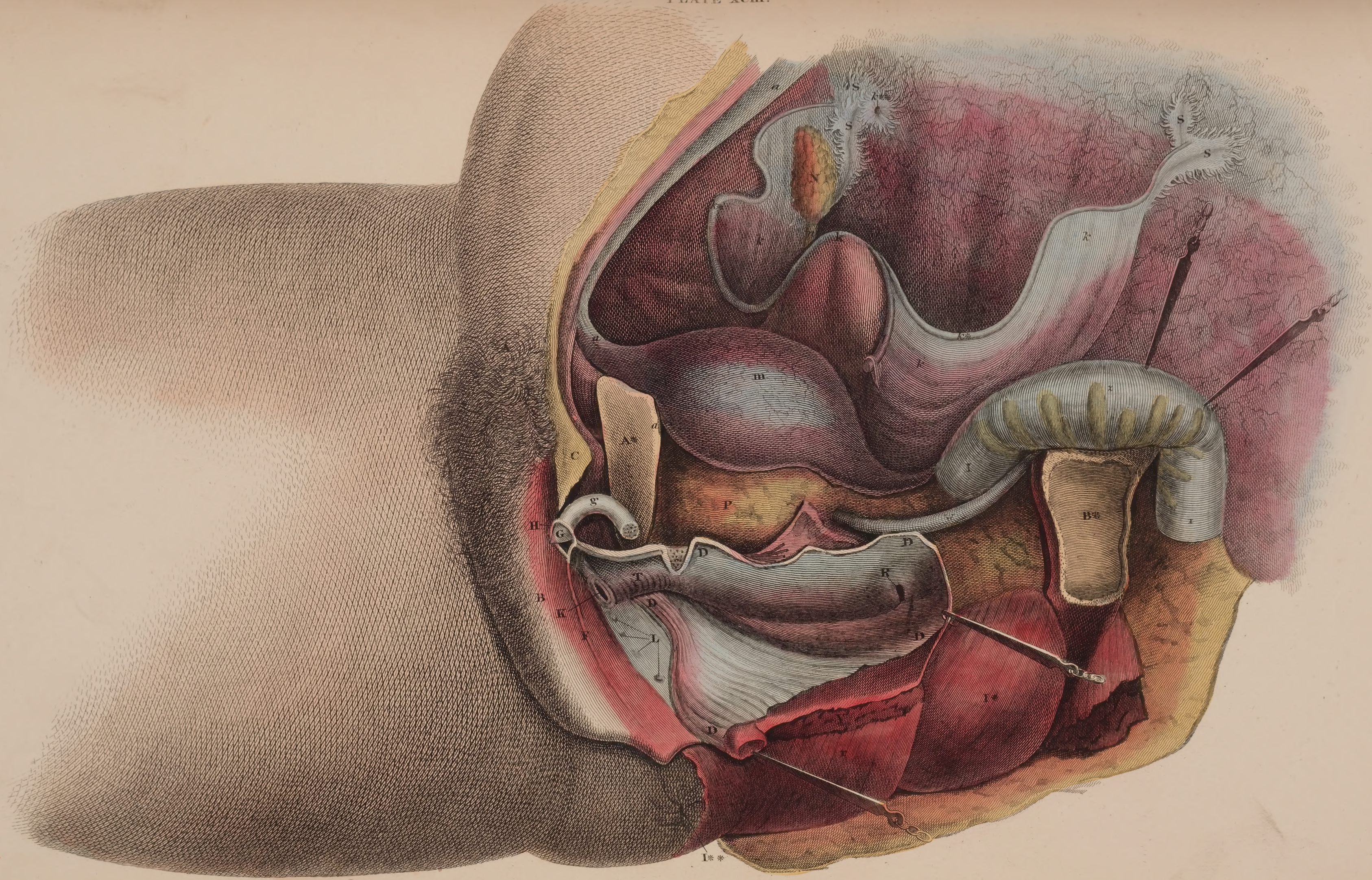

Engd by W.H.Lizars

Fig. 1.
Fig. 2.
S
N
m
Q
A
C
P
H
G
g
U
V
R
B
L
D
k
b
p
d
f
I
Engd by W.H.Lizars

PLATE XCV.

Engd by W.H. Lizars.

PLATE XCVI.

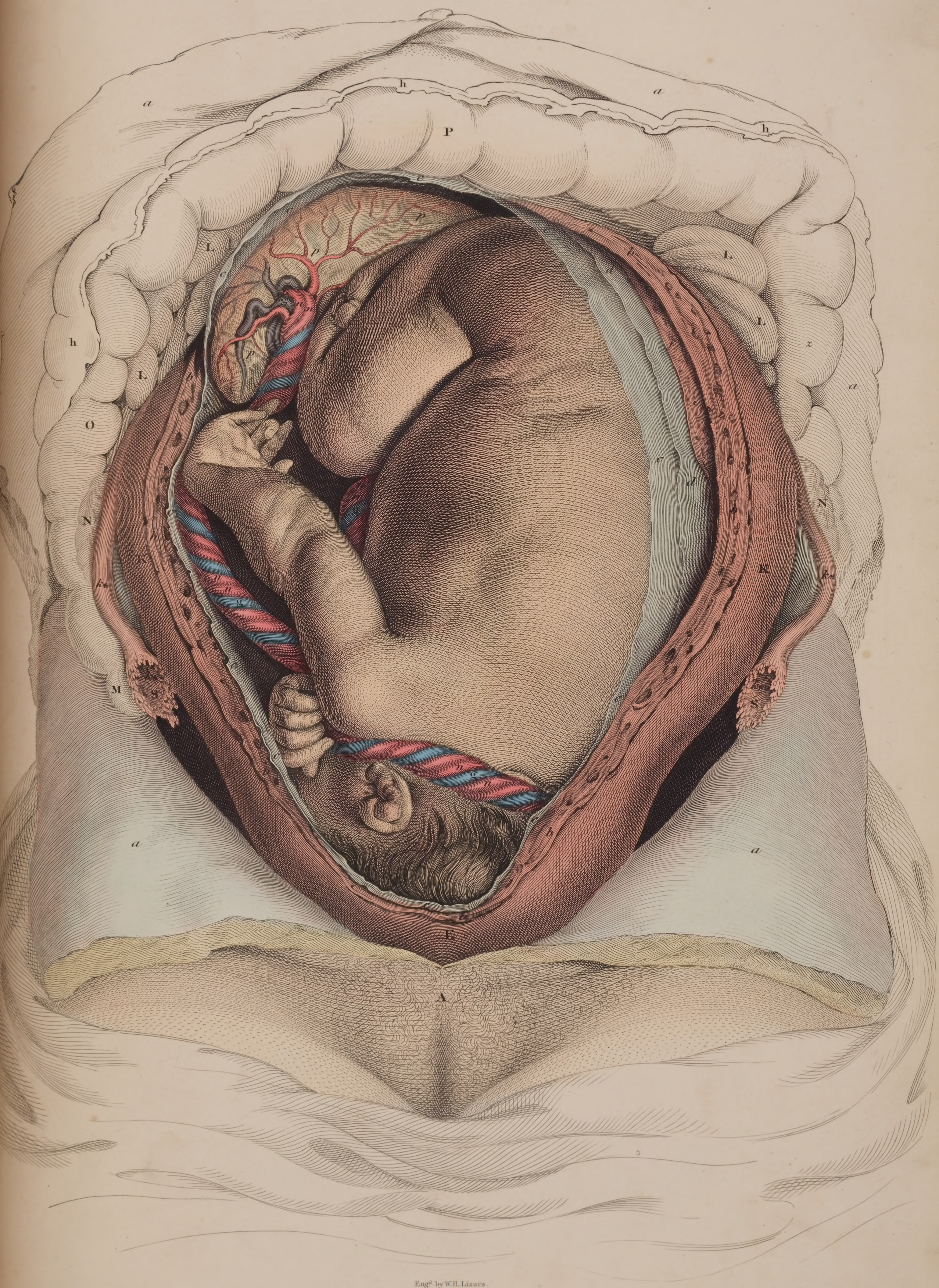

Engd by W.H. Lizars.

PLATE XCVII.

Fig. 2.

Fig. 3.

Fig. 4.

Fig. 5.

Fig. 6.

Fig. 7.



Fig. 8.

Fig. 9.

Fig. 1.

Engd by W.H. Lizars

PLATE XCVIII.

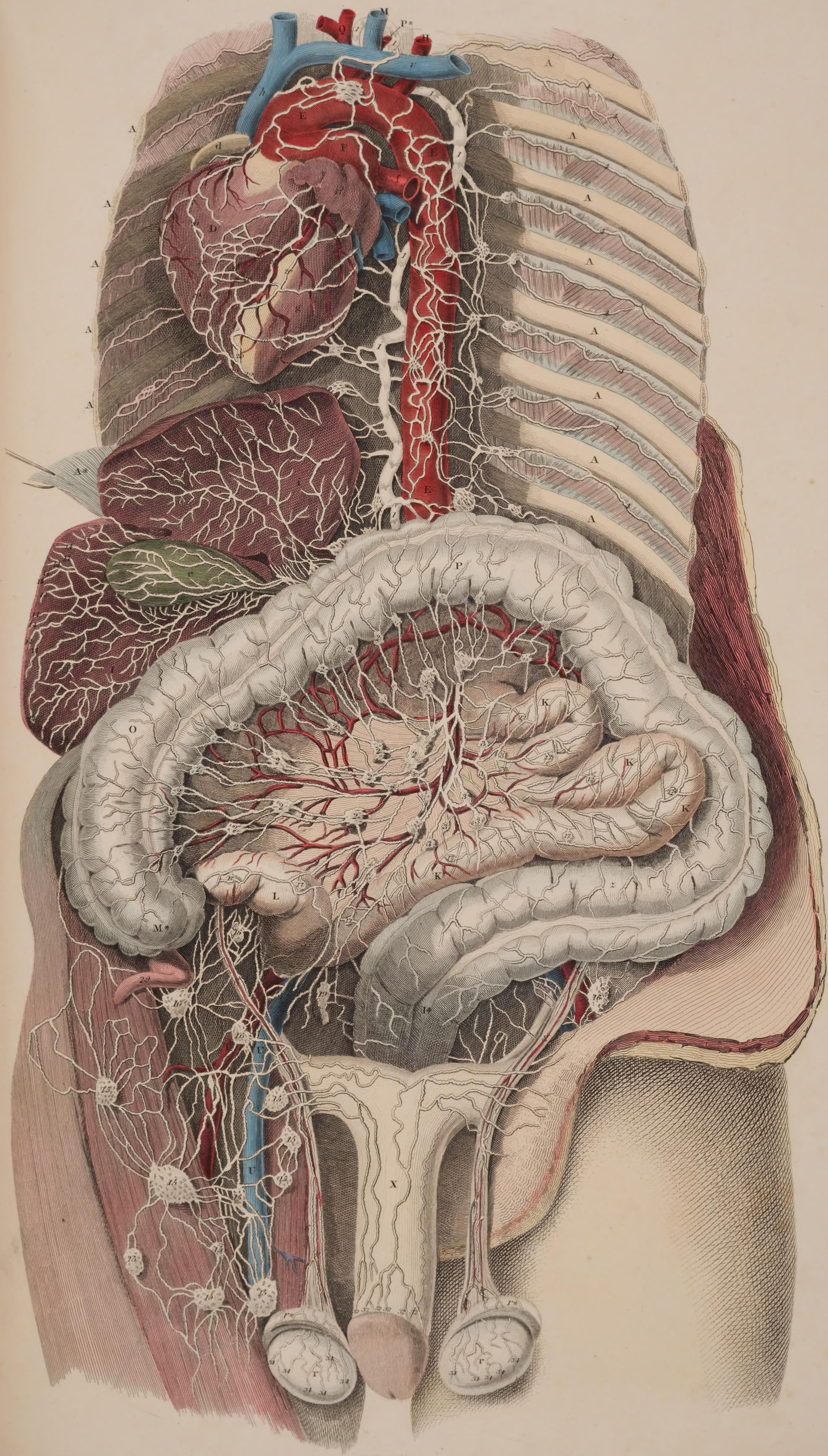

Engd by W.H. Lizars

PLATE XCIX.

Fig. 1.

Fig. 2.

Engd. by W.H.Lizars

PLATE C.

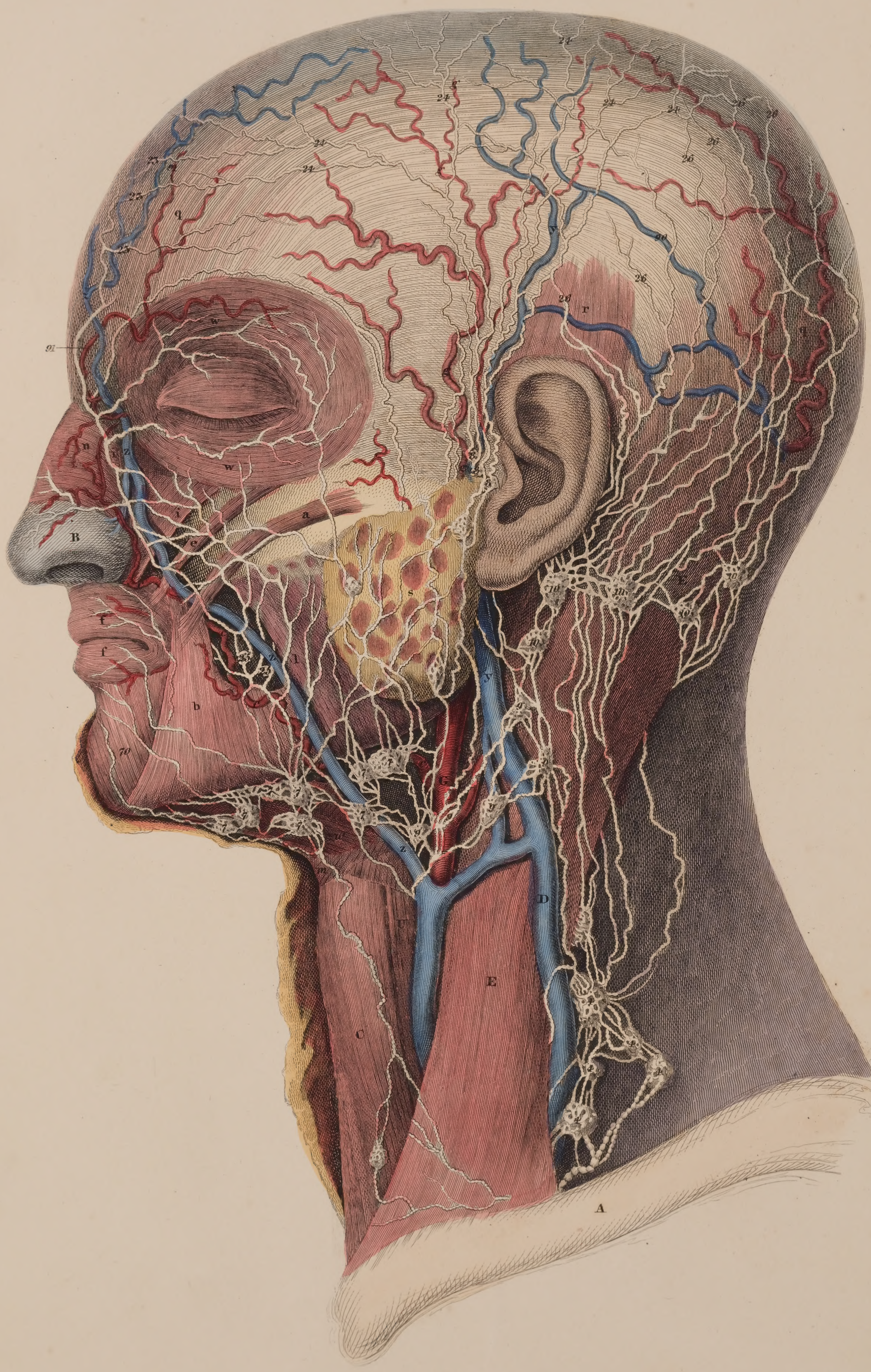

Engd. by W.H.Lizars

PLATE CI.

Engd by W.H.Lizars